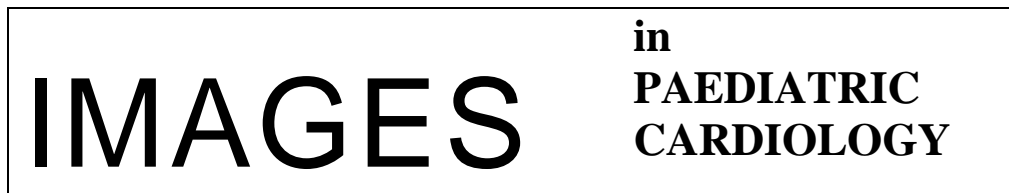

R Abdulla. World wide web and scientific publishing. *Images Paediatr Cardiol*. 1999 Jan-Mar; 1(1): 14–17.



Images Paediatr Cardiol. 1999 Jan-Mar; 1(1): 14–17.

PMCID: PMC3232473

World wide web and scientific publishing

R Abdulla*

* *Editor-in-Chief, Pediatric Cardiology, The Rush Children's Heart Center, 1653 W. Congress Parkway, Chicago, Illinois 60612*

Contact information: Dr. Ra-Id Abdulla, The Rush Children's Heart Center, 1653 W. Congress Parkway, Chicago, Illinois 60612 ; Email: rabdulla@rush.edu

Copyright : © Images in Paediatric Cardiology

This is an open-access article distributed under the terms of the Creative Commons Attribution-Noncommercial-Share Alike 3.0 Unported, which permits unrestricted use, distribution, and reproduction in any medium, provided the original work is properly cited.

Abstract

The relationship of scientific publishing and the world wide web steadily evolves as the internet technology advances in its sophistication and ability to reach an increasing number of people. Many well established medical publication currently publish their journal electronically as well as in print format. Forced by high volume of manuscript submissions as well as financial restraints, some journals publish a number of their articles on the internet alone, while others-such as this journal-are starting an entirely new publication in an electronic version only. The presentation of articles in the field of pediatric cardiology electronically has numerous advantages, particularly the ability to include movie clips, sound and animations in the published articles. This format of publication continues to have limitation. It is still not as widely available as a print journal could be and it is awkward to curl up in bed with a lap top, no matter how small or light it is.

MeSH: Medical illustration, Heart defects, congenital, Publishing

The reciprocating impact of the medical literature and the world wide web in the past decade has led to significant improvements in the arena of medical publishing. Naturally, some negative aspects have accompanied this evolutionary process, but all in all the rewards reaped by medical publishing from the internet has been phenomenal.

The astonishing growth of the internet in a very short period of time was destined to create confusion. A far reaching and extremely affordable means of communication was thrust upon us, and many medical institutions scampered to jump on the band wagon of the world wide web.^{1,2} The initial and most obvious use of this communication outlet was as an advertisement tool. Many medical facilities and physicians constructed web sites advertising what they could do and how they could be reached.

But slowly and steadily, numerous web sites have evolved to offer valuable medical services to patients as well as medical professionals. However, medical publishing firms were better equipped than most to launch sophisticated websites due to the following:

- Their journal already possessed name recognition and a standard of excellence derived from many years of publishing print journals.
- At the final stages of manuscript preparation for the print journals, the articles are already processed in an electronic format, which is easy to transfer into a web page format.
- Images are superbly captured electronically in the process of print journal preparation, and again, these images could be easily exhibited on the internet.
- Many publishing firms, realizing the importance of this media outlet, gathered experienced and dedicated staff for this purpose. This enabled them to produce web pages of high standard and embark on newer and even more advanced concepts, such as providing sound and movie clips to accompany text and still images.

Initially, many of the medical journals which ventured in the world wide web only provided information about the journal, table of contents and some placed the abstracts of their published articles. Over the past two to three years, an increasing number of these journals have made available entire print journal contents on the internet such as *Pediatrics* and *Pediatric Cardiology*. Gaining recognition (indexing) to the article exhibited on the internet was not a concern as these same articles were also published in the print format of these journals. *Pediatrics*, pressured by a high manuscript submission rate, soon thereafter began publishing a number of articles solely on the internet. This practice gained validity when *Index Medicus* decided to list such articles since they are subject to the same stringent process of peer review as the journal's print articles, thus providing legitimacy to the practice of publishing articles exclusively in an electronic version.²

Currently, most major medical journals provide all that is published in the print media on their web pages as well. Some journals have allowed access to subscribers only through specially provided codes. This was a natural progression of events after the initial hype of a new product.

Not long ago, the publishing of journal contents on the internet by major medical journals served merely to widen the spectrum of their audience because of easy accessibility through the internet. Furthermore, it reduced cost as more articles could be published without significant increase in cost, as increasing size or frequency of publication of print journal would. More recently the ability to show movie clips of medical studies such as echocardiograms and angiograms became a new benefit added to the superiority of internet publishing. *Pediatric Cardiology* was the first such journal³ with a movie clip of spontaneous echocardiographic contrast secondary to red blood cell agglutination.⁴

Outside the world of medical publishing, many have attempted to produce web pages aimed to provide medical knowledge. These sites are typically poorly organized with contemptible production. The contents are haphazard and merely follow the whims of the author. A web site would claim to be about congenital heart diseases, but it would only contain information regarding some lesions and totally ignore the remainder. Inconsistency is a hallmark of most such web sites, with little effort to produce an internet resource similar in structure, contents and standards to that of a text book which that same author may produce through the print media.

The reasons for this double standard may be:

- The lack of financial stimulus. Royalties from a published book forces many to produce a better result.
- Any person with a computer and inexpensive software can venture in this field. There is not much to lose, financially at least. Therefore, the dictum of survival of the fittest no longer exists, causing littering of the electronic

highways with many web sites long on claims and titles and short on contents.

- The lack of a supervisory editorial process. Publishing firms choose their editors and authors carefully. Financial gain is a must, therefore, acceptability of the product by the medical community of that specialty is mandatory for success to be achieved. Furthermore, publishers can provide a wide variety of valuable support to the authors.

Images in Paediatric Cardiology is the first journal in our field to venture in producing a purely electronic journal. The nature of the internet would certainly provide it with the ability to publish articles with animations and movie clips. Such a feature would certainly add a great dimension to the medical literature. To demonstrate this, I present three illustrations below.

Figures 1 and 2 demonstrate the formation of the two lateral endothelial tubes in an early embryo. The horse shoe shaped tubes in Figure 2 forms from coalescing angiogenic cells shown in Figure 1. The two lateral tubes approximate each other as the embryo folds laterally, and eventually fuse to form a single, ventrally located heart tube. The images are as clear as they can possibly be, however visualizing such events is extremely difficult due to a three dimensional nature which changes by time.

Figure 3 demonstrates the above process as an animation. Angiogenic cells form in a horse shoe distribution lateral and rostral to the brain plate. Angiogenic cells coalesce to form two lateral and two median endothelial tubes. The two lateral tubes come close together as the embryo folds to fuse and form the single heart tube. The animation clearly illustrates the process described above. If a picture is worth thousand words, then an animation must be worth a million!

Instructions to view the animation

1. **Click on the image on the right to view.**
2. **This is a Quick Time animation and will take a short while to download.**
3. **Click 'back' on your browser to return to this page when done.**

References

1. Abdulla R. Pediatric cardiology and the electronic literature. *Pediatr Cardiol.* 1997;18:321–322. [PubMed: 9270094]
2. Anderson K, Lucey JF. Pediatrics electronic pages: Looking back and looking ahead. *Pediatrics.* 1998;102:124–128. [PubMed: 9714636]
3. Abdulla R. Motion pictures in pediatric cardiology. *Pediatr Cardiol.* 1999;20:241. [PubMed: 10368445]
4. Miller MR, Thompson WR, Casella JF, Spevak PJ. Antibody-mediated red blood cell agglutination resulting in spontaneous echocardiographic contrast. *Pediatr Cardiol.* 1999;20:287–289. [PubMed: 10368455]

Figure 1 Angiogenic cells form in a horse shoe distribution lateral and rostral to the brain plate

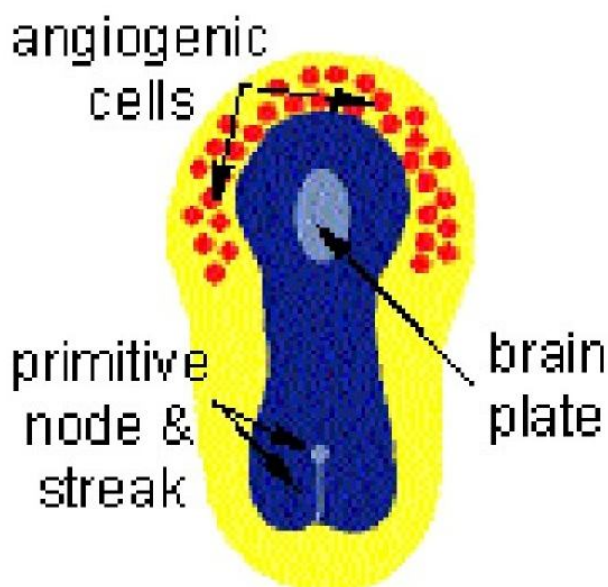


Figure 2 Angiogenic cells coalesce to form two lateral and two median endothelial tubes

