

Review Article

Food for thought: Palatable eponyms from Pediatrics

Lisa Kipersztok, Gwinyai Masukume

Abstract

Food-related medical terms are frequently used in the field of pediatrics for the definition, recognition and diagnosis of disease. Almost 40 food-related medical eponyms used in Pediatrics have been ‘cherry picked’ and described by the authors. Two of these terms have been illustrated. Culinary medical analogies allow healthcare providers to easily interpret the variety of sensations experienced during medical decision-making, providing a better taste for interpreting pathology discovered on physical exam. Despite some misgivings, food-related medical terms make medical education more appetizing and allow for rapid diagnosis of classic presentations.

Key words

Pediatrics, medicine, food, analogy, metaphor

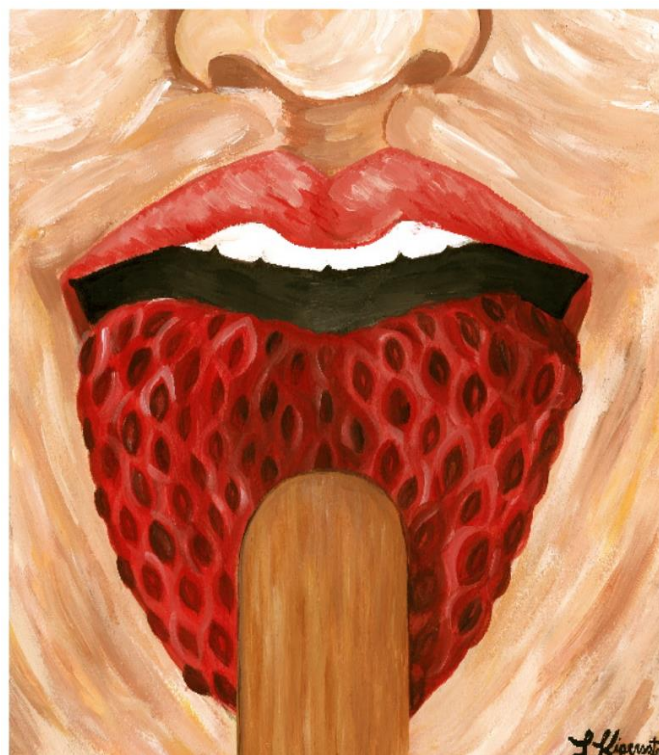
Food for thought

Investigations in obstetrics and gynecology stirred up a wide variety of food-related medical metaphors.¹ Following conception, pregnancy and delivery, the culinary medical journey can continue in the field of pediatrics. As children grow from infancy to childhood, so grows the list of food-related metaphors used by healthcare providers.

With each clinical encounter, there exists a menu of possible medical maladies from which to diagnose. Metaphors, analogies and mnemonics are blended into the endless courses of information provided during medical training. Comparing symptoms and signs of disease to food can make recalling data much more palatable and may allow for rapid diagnosis upon recognition of ‘classic’ presentations.²

Historically, diabetes mellitus was distinguished from diabetes insipidus by carefully inspecting for ‘honey urine’ by color and even a sweet taste.³ While healthcare providers (hopefully) no longer use taste for diagnosis, they continue to interpret all data available. In Pediatrics, one can hear the ‘cracked-pot sound’ of hydrocephalus, feel the ‘palpable olive’ of hypertrophic pyloric stenosis, smell the ‘cheesy odor’ of isovaleric acidemia, and see the ‘strawberry tongue’ of diseases involving superantigens (see Figure 1 and Table 1).

Figure 1: Strawberry tongue, also less commonly known as raspberry tongue (See Table 1)

**Lisa Kipersztok**

Fourth year medical student,
Tufts University School of Medicine,
Boston,
Massachusetts,
United States of America
Group for Research and Advancement of Palatable
Eponyms (GRAPE)

Gwinyai Masukume*

Group for Research and Advancement of Palatable
Eponyms (GRAPE)
Division of Epidemiology and Biostatistics,
School of Public Health,
Faculty of Health Sciences,
University of the Witwatersrand,
Johannesburg, South Africa
parturitions@gmail.com

* Corresponding author

Table 1: 'Cherry picked' food-related medical metaphors in Pediatrics

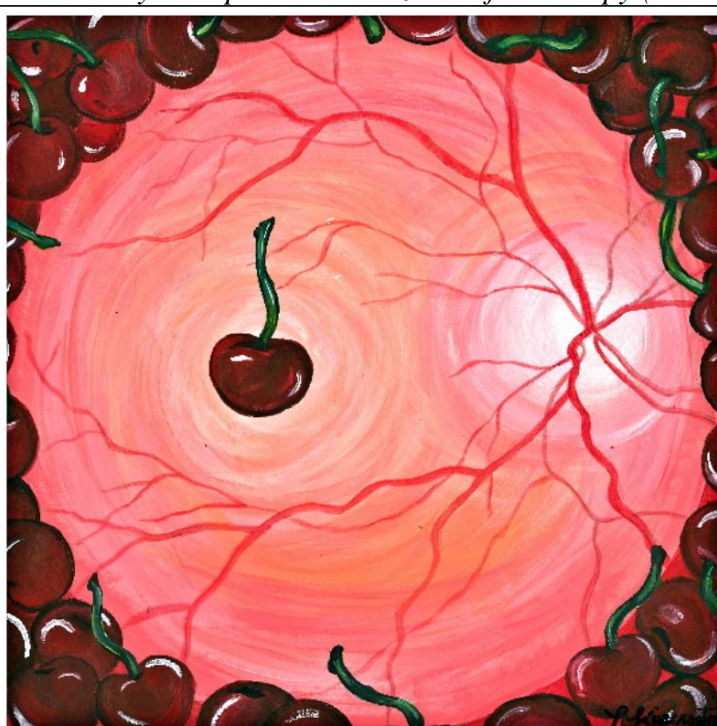Analogy	Brief description
Blueberry muffin baby/rash/syndrome	cutaneous extramedullary hematopoiesis secondary to congenital infections, certain cancers or hematologic abnormalities ⁴
Bread and butter appearance	the two layers of pericardium and intervening fibrin in cases of fibrinous pericarditis and sometimes rheumatic fever ⁵
Cabbage-like odor*, Rancid butter odor	urinary odor due in tyrosinemia type 1 and Oasthouse syndrome, in tyrosinemia type 1 a rancid butter odor can occur ⁶
Carrot-shaped nuclei	microscopic appearance of nuclei in medulloblastoma ⁷
Celery stalk appearance	alternating bands of lucent and sclerotic metaphyseal bone of the femur and tibia on X-ray in patients with congenital rubella and other conditions ⁸
Cheesy odor*	breath and body fluid odor in isovaleric acidemia ⁹
Cherry red epiglottis	swollen epiglottis upon visualization by laryngoscopy, secondary to <i>Haemophilus influenzae</i> type b and other bacterial infections ¹⁰
Cherry-red spot*	appearance of the vascular choroid under the macula on a whitened retina on fundoscopic exam in disorders of lipid metabolism ¹¹ – See Figure 2
Cottage-loaf sign	chest X-ray appearance in patients with total anomalous pulmonary venous connection/drainage/return ¹²
Cracked-pot sign	sound heard upon percussing the head of an infant affected by hydrocephalus ¹³
Dish-face anomaly	congenital midface hypoplasia resulting in flattened features, seen in Larsen syndrome and Binder syndrome (maxillonasal dysplasia) ^{14,15}
Doughnut sign, Sandwich sign	doughnut shape seen on transverse sonography or computed tomography in intussusception; on longitudinal imaging intussusception resembles a sandwich ¹⁶
Egg on a string sign	cardio-mediastinal silhouette seen on chest X-ray in transposition of the great arteries/vessels ¹⁷
Fish odor syndrome*	body odor of rotten fish secondary to an accumulation of trimethylamine in flavin-containing monooxygenase 2 deficiency ¹⁸
Honey-colored crusts	crusts overlying the healing blisters in cases of impetigo, a superficial skin infection caused by <i>Staphylococcus aureus</i> or <i>Streptococcus pyogenes</i> ¹⁹
Hot cross bun head/skull	rare radiographic manifestation in which the skull looks like a hot cross bun due to abnormal bone deposition in congenital syphilis ²⁰
Ice cream sliding off the cone	hip X-ray appearance seen in slipped capital femoral epiphysis ²¹
Maple syrup urine disease*	caramel-like urine odor in individuals with branched-chain alpha-keto acid dehydrogenase complex deficiency ²²
Milk anemia	iron deficiency anemia caused by the substitution of breast milk with cow's milk in early childhood ²³
Mulberry molars	abnormally increased number of cusps in the first permanent molars which occurs in congenital syphilis ²⁴
Oasthouse syndrome*	urine odor of an oasthouse, a building used for drying hops, in disordered methionine metabolism ²⁵
Olive-shaped mass	palpable abdominal mass the shape of an olive found in infants with hypertrophic pyloric stenosis (HPS) ²⁶
Onion skin reaction	periosteal reaction resulting in the layering of periosteum, seen on X-ray in Ewing sarcoma and sometimes in osteomyelitis or osteosarcoma ²⁷
Pancake brain	brain's shape seen on pathologic and radiographic examination in alobar holoprosencephaly ²⁸
Pea soup stool	consistency and appearance meconium or diarrhea secondary to typhoid ²⁹
Port-wine stains	birthmarks the color of port wine typically affecting the face and neck, caused by malformed capillaries in syndromes such as Sturge-Weber ³⁰
Potato chip scales	weeping, crusted scales typically on the face in staphylococcal scalded skin syndrome ³¹

Table 1: ‘Cherry picked’ food-related medical metaphors in Pediatrics Cont.

Analogy	Brief description
Prune belly syndrome	wrinkled abdominal skin caused by the absence of abdominal musculature ³²
Red-currant jelly stool	stool consisting of blood and mucus in cases of intussusception, dysentery or other diseases ³³
Rotten eggs odor*	urine odor in cystinuria ³⁴
Salmon patches	retinal hemorrhage visualized on fundoscopy in sickle cell retinopathy, ³⁵ also used to describe the pink-red ‘stork bite’ of the nape of the neck in infants ³⁶
Salt-pepper retinopathy	focal areas of increased and decreased pigmentation seen on fundoscopy in rubella retinopathy, congenital syphilis or other congenital infections ³⁷
Salt grains	also known as Koplik spots, lesions that resemble grains of white or blue salt splattered on a red buccal mucosa in measles ³⁸
Sausage-shaped mass	right upper quadrant or epigastric mass that feels like a sausage on abdominal palpation in some patients with intussusceptions ³⁹
Strawberry hemangioma	also known as a capillary hemangioma, a benign red-blue tumor of blood vessels which regress by age 10 ⁴⁰⁻⁴¹
Strawberry tongue, Raspberry tongue	bright red tongue with prominent papillae found in diseases likely mediated by superantigens including toxic shock syndrome, scarlet fever and Kawasaki disease ⁴²⁻⁴³ – see Figure 1
Sunflower cataracts*	sunflower appearance of the lens of the eye caused by copper deposition in Wilson’s disease, a disorder of copper metabolism ⁴⁴
Tumbler test aka glass test	controversial clinical sign elicited when a transparent tumbler is pressed against a skin rash, positive for meningococemia if the rash does not blanch ⁴⁵

*Underlying disease is usually inherited in an autosomal recessive manner, Some cutaneous food-related medical terms may not be applicable in those with pigmented skin
Please see the Supplementary appendix for a more detailed table

Figure 2: Cherry-red spot as visualized on fundoscopy (See Table 1)



Discussion

Although food-related eponyms vary across cultures and specialties, they contribute to the medical knowledgebase used by all healthcare providers.² In some instances, the same culinary term has described more than one medical condition. For example, the cottage loaf appearance has been used to refer to radiographic studies of children with total anomalous pulmonary venous connection, but has also been used to describe the appearance of a herniated choroidal melanoma, or a liver protruding through a ruptured diaphragm. Some eponyms have widespread use, found frequently in medical literature. Some are used colloquially, mentioned in operating rooms and pathology laboratories but rarely documented.

It is not possible to classify food-related medical terms into discreet medical specialties because there is substantial overlap between areas of expertise. For example, we covered previously the grape-like appearance of the malignant tumor, sarcoma botryoides,¹⁻² found in young girls that others may classify as being pediatric and others gynecologic.

Food-related medical analogies have rarely been validated in terms of sensitivity, specificity and predictive values, and are not always found in cases of the medical conditions that they describe.⁴⁶ Intussusception, for example, only results in the triad of a sausage-shaped mass, red currant jelly stool and pain in about 15% of cases.³⁹ Additionally, as technology progresses, students and healthcare providers focus less on perfecting their skills of inspection, palpation, percussion and auscultation, and instead rely on easily available imaging studies.⁴⁷ Palpating an olive-shaped mass in children with hypertrophic pyloric stenosis, for example, has decreasing utility in a medical system that promotes early imaging when the disease is suspected.²⁶

Nevertheless, these terms have utility in broadening differential diagnoses when confronted with symptoms and signs of disease, and are easily memorable for rapid recognition in classic cases. Food-related eponyms continue to be taught in medical school classrooms and physical diagnosis courses, and are likely to be retained in the 'visual specialties' of radiology and pathology.⁴⁸ Culinary medical eponyms will continue to spice up the melting pot of medical jargon, particularly in the field of Pediatrics.

While the eponyms described are primarily encountered in Pediatrics, many continue to be discovered as children grow into adulthood, where the list of delicious medical findings will continue. These pediatric culinary terms certainly do not represent the final course in the medical food analogy feast.

Acknowledgements

LK acknowledges her family, her classmates and the pathology professors at Tufts University School of

Medicine for encouraging (and assisting with) her search for food-related terms while she was studying during medical school. GM acknowledges his father. Thank you for everything.

Author contributions

GM conceived the article. Both authors contributed to the writing and editing of the article and approved the final version. LK designed and painted figures 1 and 2.

Competing interests

LK and GM have no financial relationship with any food company or any other organization that may have an interest in the submitted work. GM is the author of the blog <http://foodmedicaleponyms.blogspot.com>, he also blogs at <http://www.improbable.com/> on food-related medical terms.

References

- Masukume G. Food for thought. *Croat Med J.* 2012;53:77-9.
- Masukume G, Zumla A. Analogies and metaphors in clinical medicine. *Clin Med.* 2012;12:55-6.
- Sanders LJ. From Thebes to Toronto and the 21st Century: An Incredible Journey. *Diabetes Spectrum.* 2001;15:56-60.
- Mehta V, Balachandran C, Lonikar V. Blueberry muffin baby: a pictorial differential diagnosis. *Dermatol Online J.* 2008;14:8.
- Cohen MB. Cross your heart: Some historical comments about fibrinous pericarditis. *Hum Pathol.* 2004;35:147-9.
- Enns GM, Packman S. Diagnosing Inborn Errors of Metabolism in the Newborn: Clinical Features NeoReviews. 2001;2:183.
- Kroh H, Bidziński J. Glial differentiation in medulloblastoma. Case report. *Neuropatol Pol.* 1993;31:75-82.
- de Mol AC, Vrancken S, Eggink AJ, Verduyn Lunel FM, Warris A. [The first newborn with congenital rubella syndrome during the rubella epidemic in The Netherlands in 2004/05]. *Ned Tijdschr Geneesk.* 2006;150:741-6.
- Tanaka K, Budd MA, Efron ML, Isselbacher KJ. Isovaleric acidemia: a new genetic defect of leucine metabolism. *Proc Natl Acad Sci U S A.* 1966;56:236-42.
- Tanner K, Fitzsimmons G, Carrol ED, Flood TJ, Clark JE. Haemophilus influenzae type b epiglottitis as a cause of acute upper airways obstruction in children. *BMJ.* 2002;325:1099-100.
- Suvarna JC, Hajela SA. Cherry-red spot. *J Postgrad Med.* 2008;54:54-7.
- Somerville J, Grech V. The chest x-ray in congenital heart disease I. Total anomalous pulmonary venous drainage and coarctation of the aorta. *Images Paediatric Cardiology.* 2009;11:7-9.
- Mouafo Tambo FF, Djientcheu V, Chiabi A, Mbarnjuk SA, Walburga YJ, Mbonda E, et al. Our experience in the management of infantile hydrocephalus: A study on thirty-five regrouped cases in Yaounde, Cameroon. *Afr J Paediatr Surg.* 2011;8:199-202.
- Kaissi AA, Ganger R, Klaushofer K, Grill F. The management of knee dislocation in a child with Larsen syndrome. *Clinics (Sao Paulo).* 2011;66:1295-9.
- Bhatt YC, Vyas KA, Tandale MS, Panse NS, Bakshi HS, Srivastava RK. Maxillonasal dysplasia (Binder's syndrome) and its treatment with costal cartilage graft: A follow-up study. *Indian J Plast Surg.* 2008;41:151-9.

- 16 Park NH, Park SI, Park CS, Lee EJ, Kim MS, Ryu JA, et al. Ultrasonographic findings of small bowel intussusception, focusing on differentiation from ileocolic intussusceptions. *Br J Radiol.* 2007;80:798-802.
- 17 Ferguson EC, Krishnamurthy R, Oldham SA. Classic imaging signs of congenital cardiovascular abnormalities. *Radiographics.* 2007;27:1323-34.
- 18 Li M, Al-Sarraf A, Sinclair G, Frohlich J. Fish odour syndrome. *CMAJ.* 2011;183:929-31.
- 19 Cole C, Gazewood J. Diagnosis and treatment of impetigo. *Am Fam Physician.* 2007;75:859-64.
- 20 Sharma M, Solanki RN, Gupta A, Shah AK. Different radiological presentations of congenital syphilis : four cases. *Indian J Radiol Imaging.* 2005;15:53-7.
- 21 Punnoose AR, Lynn C, Golub RM. JAMA patient page. Slipped capital femoral epiphysis. *JAMA.* 2013;309:620.
- 22 Simon E, Wendel U, Schadewaldt P. Maple syrup urine disease-treatment and outcome in patients of Turkish descent in Germany. *Turk J Pediatr.* 2005;47:8-13.
- 23 Oliveira MA, Osório MM. [Cow's milk consumption and iron deficiency anemia in children]. *J Pediatr (Rio J).* 2005;81:361-7.
- 24 Hillson S, Grigson C, Bond S. Dental defects of congenital syphilis. *Am J Phys Anthropol.* 1998;107:25-40.
- 25 Liddell K. Smell as a diagnostic marker. *Postgrad Med J.* 1976;52:136-8.
- 26 Shaoul R, Enav B, Steiner Z, Mogilner J, Jaffe M. Clinical presentation of pyloric stenosis: the change is in our hands. *Isr Med Assoc J.* 2004;6:134-7.
- 27 Shahid M, Varshney M, Maheshwari V, Mubeen A, Siddiqui MA, Julfiqar J, et al. Ewing's sarcoma of scapula: a rare entity. *BMJ Case Rep.* 2011;2011. pii: bcr0220113810.
- 28 Situ D, Reifel CW, Smith R, Lyons GW, Temkin R, Harper-Little C et al. Investigation of a cyclopic, human, term fetus by use of magnetic resonance imaging (MRI). *J Anat.* 2002;200:431-8.
- 29 Zareen Z, Hawkes CP, Krickan ER, Dempsey EM, Ryan CA. In vitro comparison of neonatal suction catheters using simulated 'pea soup' meconium. *Arch Dis Child Fetal Neonatal Ed.* 2013;98:F241-3.
- 30 Shirley MD, Tang H, Gallione CJ, Baugher JD, Frelin LP, Cohen B, et al. Sturge-Weber syndrome and port-wine stains caused by somatic mutation in GNAQ. *N Engl J Med.* 2013;368:1971-9.
- 31 Turkington C, Dover JS. *The Encyclopedia of Skin and Skin Disorders.* 3rd ed. Facts on File. 2006;319.
- 32 Metwalley KA, Farghalley HS, Abd-Elseyed AA. Prune belly syndrome in an Egyptian infant with Down syndrome: a case report. *J Med Case Rep.* 2008;2:322.
- 33 Toso C, Erne M, Lenzlinger PM, Schmid JF, Büchel H, Melcher G, et al. Intussusception as a cause of bowel obstruction in adults. *Swiss Med Wkly.* 2005;135:87-90.
- 34 Biyani CS, Cartledge, JJ. Cystinuria—Diagnosis and Management. *EAU-EBU Update Series.* 2006;4,175-183.
- 35 Cury D, Boa-Sorte N, Lyra IM, Zanette AD, Castro-Lima H, Galvão-Castro B et al. Ocular lesions in sickle cell disease patients from Bahia, Brazil. *Rev. bras.oftalmol.* 2010;69: 259-263.
- 36 Wirth FA, Lowitt MH. Diagnosis and treatment of cutaneous vascular lesions. *Am Fam Physician.* 1998;57:765-73.
- 37 Sudharshan S, Ganesh SK, Biswas J. Current approach in the diagnosis and management of posterior uveitis. *Indian J Ophthalmol.* 2010;58:29-43.
- 38 Steichen O, Dautheville S. Koplik spots in early measles. *CMAJ.* 2009;180:583.
- 39 Cera SM. Intestinal intussusception. *Clin Colon Rectal Surg.* 2008;21:106-13.
- 40 Tokuda Y, Uozumi T, Sakoda K, Yamada K, Yamanaka M, Nomura S, et al. Giant congenital capillary hemangioma of pericranium--case report. *Neurol Med Chir (Tokyo).* 1990;30:1029-33.
- 41 North PE, Waner M, Mizeracki A, Mihm MC Jr. GLUT1: a newly discovered immunohistochemical marker for juvenile hemangiomas. *Hum Pathol.* 2000;31:11-22.
- 42 Solanki LS, Srivastava N, Singh S. Superantigens: a brief review with special emphasis on dermatologic diseases. *Dermatol Online J.* 2008;14:3.
- 43 Bleggi-Torres LF, de Medeiros BC, Ogasawara VS, Loddo G, Zanis Neto J, Pasquini R, et al. Iatrogenic Wernicke's encephalopathy in allogeneic bone marrow transplantation: a study of eight cases. *Bone Marrow Transplant.* 1997;20:391-5.
- 44 Goyal V, Tripathi M. Sunflower cataract in Wilson's disease. *J Neurol Neurosurg Psychiatry.* 2000;69:133.
- 45 Mant D, Van den Bruel A. Should we promote the tumbler test? *Arch Dis Child.* 2011;96:613-4.
- 46 Spence D. Medical heresy: ditch the eponyms. *BMJ.* 2012;344:e2503.
- 47 Verghese A, Brady E, Kapur CC, Horwitz RI. The bedside evaluation: ritual and reason. *Ann Intern Med.* 2011;155:550-3.
- 48 Lakhtakia R. Twist of taste: gastronomic allusions in medicine. *Med Humanit.* 2014;40:117-8.