

Case Report

Revisiting Plummer Vinson Syndrome – a report of three cases and review

Iftekhar Rasool S.M, Rezwana Begum Md, Ravichandra K, Prasanth P.S

Abstract

Plummer-Vinson or Paterson-Brown-Kelly syndrome (PVS) is characterised by a triad of cervical dysphagia, upper oesophageal web and iron deficiency anaemia. It is known to affect mostly white females, but cases have been reported from other ethnic groups in the literature.

Exact data about epidemiology of the syndrome is not available, but the syndrome is extremely rare. It is considered as a premalignant condition associated with cancers of upper digestive tract.

Herein we report three cases of Plummer Vinson syndrome in Indian women, who presented with significant and long standing dysphagia, sideropenia and post-cricoid webs. Their esophagograms revealed the presence of webs at pharyngoesophageal junction. All the three patients were treated with oesophageal dilation of webs along with iron supplementation. The patients were under regular follow-up for three years after treatment and found to be with normal blood counts with no signs of recurrence and malignancy.

Keywords

Dysphagia, Plummer Vinson syndrome, iron deficiency anaemia, oesophageal webs, deglutition disorders

Introduction

Plummer-Vinson syndrome (PVS) is named after Henry Stanley Plummer and Porter Paisley Vinson, who were physicians on the staff of the Mayo Clinic. In 1912, Plummer reported a series of twenty one patients with long-standing iron deficiency anaemia, dysphagia and spasm of the upper oesophagus without anatomic stenosis, which was described as hysterical dysphagia.¹ In 1919 Vinson reported another case of 'angulation' of the oesophagus and attributed the first description of this entity to the earlier report of Plummer.² Another term is Paterson-Brown-Kelly syndrome, named after Donald Ross Paterson and Adam Brown- Kelly, who were the first to describe the characteristic signs and symptoms (including anaemia) of the syndrome independently in 1919. Paterson gave the fullest description but without reference to anaemia. He was also the first to draw attention to an association with post-cricoid carcinoma. Because of the constant presence of dysphagia associated with the characteristic mucosal lesions and evidence of diminished body iron stores usually associated with low serum iron values, Waldenstrom and Kjellberg introduced the term 'Sideropenic dysphagia' to describe this syndrome.

PVS is a manifestation of severe, long term iron deficiency anaemia causing oropharyngeal dysphagia

Sk. Md. Iftekhar Rasool M.B.B.S (M.D. General Medicine)

Post Graduate student
Department of General Medicine
NRI Institute of Medical Sciences
Mangalgiri, Guntur
Andhra Pradesh.
India.

Rezwana Begum Mohammed B.D.S M.D.S (Oral Medicine & Radiology)*

Assistant Professor,
Department of Oral Medicine & Radiology
GITAM Dental College & Hospital,
Rushikonda,
Visakhapatnam.
Andhrapradesh. India.
dr.rizwanamds@gmail.com

Ravichandra Koganti B.D.S M.D.S (Oral and Maxillofacial Surgery)

Reader
Department of Oral and Maxillofacial surgery
Kalinga Institute of Dental Sciences
Bhubaneswar, Odisha.
India

Prasanth P.S B.D.S M.D.S (Orthodontics & Dentofacial Orthopaedics)

Reader
Department of Orthodontics & Dentofacial Orthopaedics, Indira Gandhi Institute of Dental Sciences
Ernakulam
Kerala.
India.

*Corresponding author

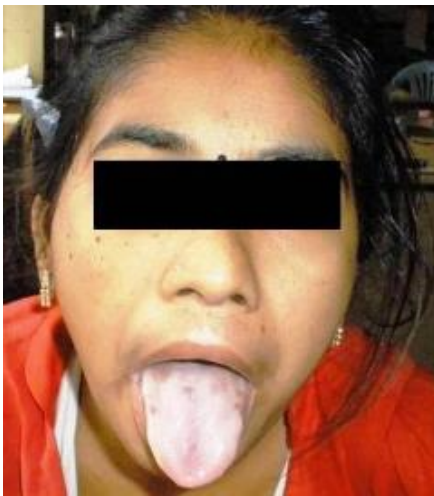Case Report

because of oesophageal webs. This article reports three cases of Plummer Vinson syndrome with significant long standing dysphagia and sideropenia and was treated effectively with dilation therapy and iron supplementation.

Case-1

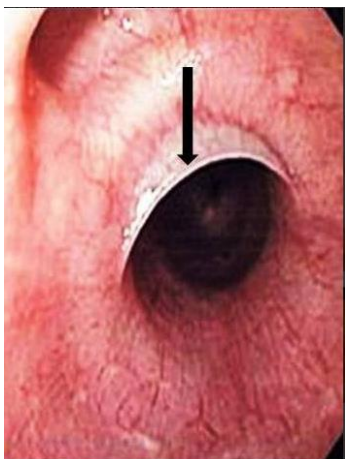
A 20 year old female presented to the outpatient clinic with difficulty in swallowing solids intermittently since eight years. For the past two years, she was unable to take even soft foods. She also had palpitations and breathlessness on exertion since two years. Physical examination revealed pale skin, eyes and oral mucosa with koilonychia and depapillated tongue [Figure-1].

Figure 1: showing bald tongue and pallor skin



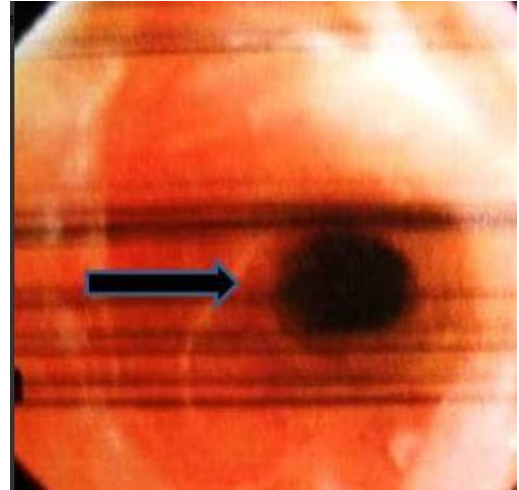
Investigations revealed hypochromic microcytic anaemia with haemoglobin (Hb) of 3.6gm%. Serum iron studies showed decreased serum iron of 25 $\mu\text{g/dl}$ and increased total iron binding capacity of 525 $\mu\text{g/dl}$ suggesting iron deficiency anaemia. Upper gastrointestinal endoscopy was done to assess the cause of dysphagia, which showed a post-cricoid oesophageal web [Figure-2].

Figure 2: Esophageal endoscopy showing web



Fulfilling the classical triad of dysphagia, iron deficiency anaemia and upper oesophageal web, PVS was diagnosed. During endoscopy, balloon dilation of the web [Figure-3] was performed which led to considerable improvement in her dysphagia. The patient was under iron supplementation for six months and follow-up examination showed normal blood counts.

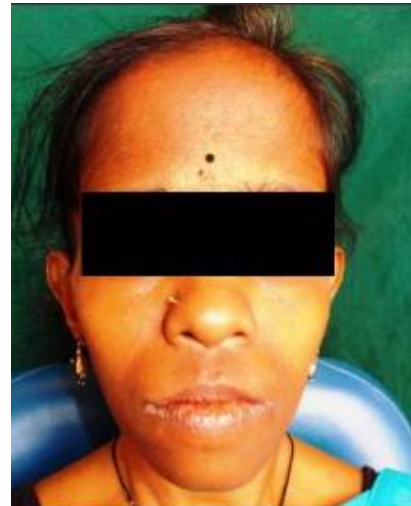Figure 3: showing dilated web after endoscopy



Case-2

A 42 year old female presented with dysphagia, generalized weakness, anorexia and weight loss since three years [Figure-4].

Figure 4: showing pallor skin with angular cheilitis

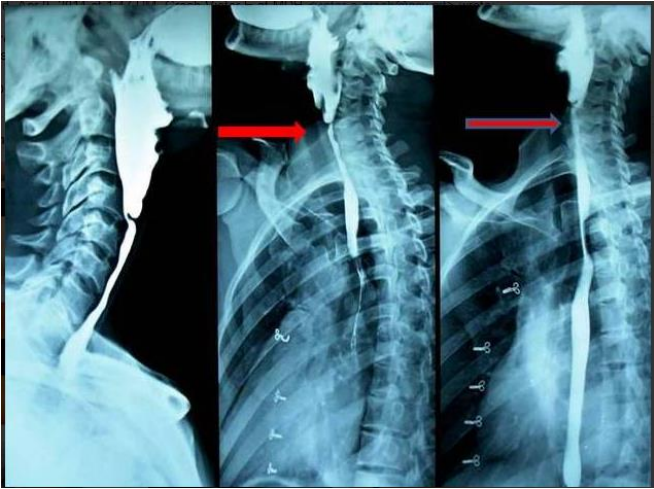

On physical examination, pale skin, glossitis, angular cheilitis and spoon shaped nails were observed. All vital signs were found to be in normal limits. Haematological tests showed the presence of iron deficiency anaemia (serum Fe 30 $\mu\text{g/dl}$, Hb 4.6gm/dl, Hematocrit 19%, Mean corpuscular volume 52fl). Peripheral blood smear revealed anisocytosis and hypochromic anaemia. However, liver and renal functions, enzyme levels and electrolyte levels were

Case Report

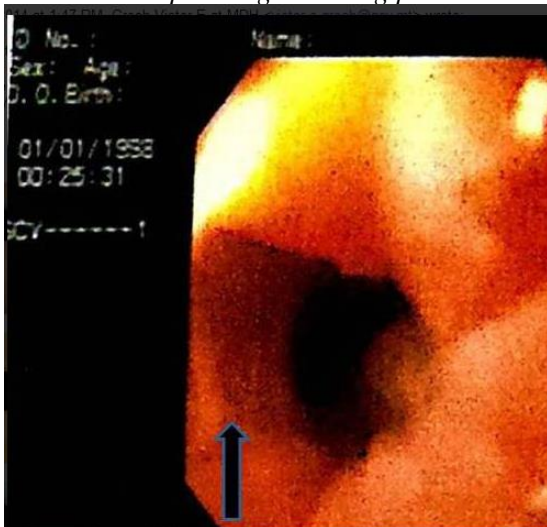
found to be in normal ranges. Barium swallow showed post-cricoid strictures [Figure-5].

Figure 5: Barium swallow showing esophageal stricture



The patient's oesophagogram revealed the presence of a web in the post-cricoid region, which was dilated with Savary Gilliard dilators [Figure-6] up to 12.8mm. The patient was given iron replacement therapy for six months until the haematological tests normalized.

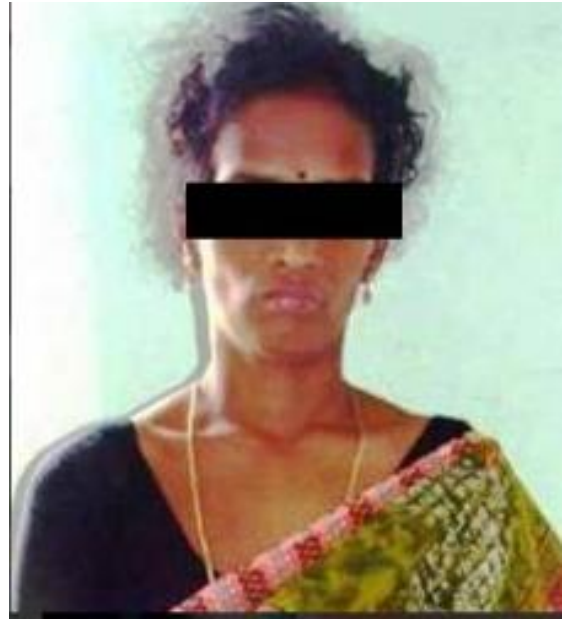Figure 6: Endoscopic image showing post dilated web



Case-3

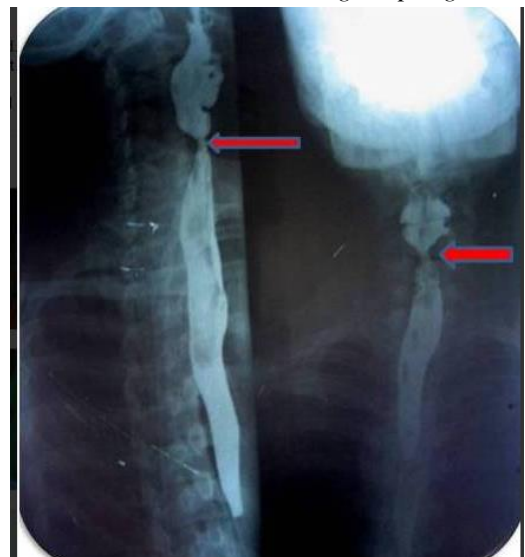A 35 year old female came to the oral medicine department with a complaint of severely decayed teeth in the upper and lower quadrants of the jaw since three years. She also had difficulty in swallowing since two years. She looked emaciated with loss of weight and anorexia [Figure-7]. On physical examination, she showed signs of iron deficiency anaemia such as glossitis, angular cheilitis and koilonychia. Intra oral examination revealed multiple decayed teeth, dry mouth, stomatitis and glossitis.

Figure 7: showing pale skin, sunken cheeks and cheilitis



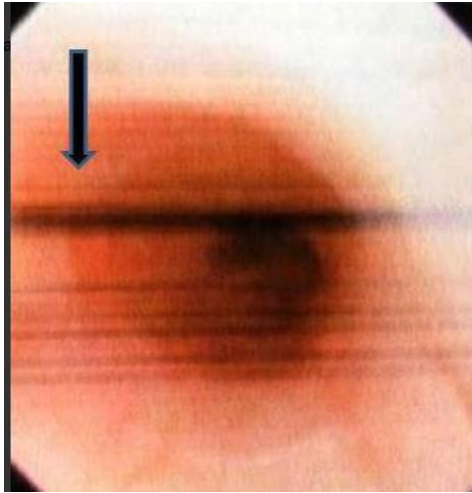
Lab investigations revealed haemoglobin 6g/dl, total leukocyte count (TLC) of 5500/ μ l, mean corpuscular volume (MCV) of 49fl, mean corpuscular haemoglobin (MCH) of 12pg/cell, serum iron 25 μ g/dl, and total iron binding capacity of 490 μ g/dl. A peripheral blood smear showed marked microcytic hypochromic anaemia. Barium swallow and oesophageal endoscopy was done to evaluate the cause of dysphagia. Barium swallow was suggestive of a web at pharyng-oesophageal junction [Figure-8].

Figure 8: Barium swallow showing esophageal stricture



Endoscopic balloon dilation of the web [Figure-9] was done to relieve from dysphagia. She was prescribed oral iron supplements, sialogogues and transfused with packed red blood cells. On follow-up of 6 months, her blood counts normalized and she was referred for restorative procedures for all decayed teeth.

Figure 9: showing post dilated esophageal web



Discussion

PVS is a manifestation of severe, long term iron deficiency anaemia causing oropharyngeal dysphagia because of oesophageal webs. Other features include glossitis, glossopyrosis, glossodynia, angular cheilitis, koilonychia, fragility, thinning of nails, and brittle hair, as presented in our cases. Symptoms secondary to anaemia such as pallor, fatigue, and weakness may also dominate the clinical picture.

PVS is most common in white females of 4th to 7th decade³ but some cases in children and adolescents⁴ are also reported. Most commonly, patients first have dysphagia to solids, but over time, symptoms can progress to dysphagia to liquids, as observed in our cases. Usually the dysphagia is painless and its progression can eventually lead to weight loss. In our cases, dysphagia was the main symptom that led all the three patients to seek medical help and dilation therapy. No exact data about the incidence and prevalence of PVS exist among Indians; only case reports have been published in the literature. Even though iron deficiency anaemia is prevalent among Indians, the incidence of PVS is rare, may be due to the improvement in nutritional status and better treatment of iron deficiency.⁵⁻⁶

The pathogenesis of this syndrome remains unclear, but possible etiopathogenetic mechanisms include iron deficiency, genetic predisposition or autoimmune disorder. It is reported that iron deficiency leads to the reduction of iron-dependent oxidative enzymes, which results in gradual degradation of muscles of the pharynx.⁷ This may also predispose the patients to subsequent neoplastic change in mucosa (squamous cell carcinoma). Iron deficiency is believed to decrease the contraction amplitude of the oesophageal muscle resulting in motility impairment. Celiac disease, thyroiditis, large diaphragmatic hernia, gastric cancer, rheumatoid arthritis, Sjogren's syndrome, and pernicious

anaemia may predispose to PVS. All the reported three cases were not associated with any systemic disorder.

It is important that this syndrome be differentiated from other causes of dysphagia, e.g. malignant tumors, strictures, oesophageal burns, diverticula, motility disorders such as achalasia, spastic motility disorders, scleroderma, diabetes mellitus, gastric oesophageal reflux disease, heterotopic gastric mucosa or blistering skin disease, neuromuscular and skeletal muscle disorders.

The approach begins with laboratory evaluation of CBC count, iron and ferritin studies, antigliadin and antiendomysial antibodies (to rule out celiac sprue). Barium swallow studies and fluoroscopic evaluation suggest the diagnosis and the degree of stenosis. Oesophago-gastro-duodenoscopy helps obtain histological samples to rule out other disorders, confirms the diagnosis and also helps therapeutically in the dilation of webs. Previously mercury/tungsten filled bougies (Maloney/Hurst), bougienage dilators (bougie passed over guidewire; Savary Gilliard or American) and through the scope (balloon dilators) are the commonly used oesophageal dilators.⁸ In most cases, one session of such dilation is usually enough for long term relief but, rarely, multiple sessions may also be warranted. All the three cases presented, were treated with dilation therapy (two cases with balloon dilators and one case with Savary Gilliard dilator) and iron supplementation.

PVS is considered as a precancerous condition and has been identified as a risk factor for developing post cricoid carcinoma of upper gastrointestinal tract.⁹ 4 to 16% of the patients with PVS, mostly women between 15-50 years of age, have been reported to develop oesophageal or pharyngeal cancer.¹⁰ In our cases no signs of recurrence or malignancy were found until three years and the patients are under regular followup as the minimum duration to detect malignant change in PVS cases is not less than five years.¹⁰⁻¹¹

Conclusion

We conclude that the patients presenting with symptoms of iron deficiency anaemia or with dysphagia should be investigated for PVS. Early diagnosis and prevention is necessary which would then depend ideally on the prevention of iron deficiency or, if iron deficiency occurs, on its early diagnosis and on the continued replenishment of the depleted iron stores. Moreover a careful otorhinolaryngological examination should be performed routinely in patients with PVS because of its premalignant potential.

Conflicts of Interest:

The authors declare no conflicts of interest.

Reference

1. Plummer HS. Diffuse dilatation of the esophagus without anatomic stenosis (cardiospasm). A report of 91 cases. *JAMA* 1912; 58: 2013-15.
2. Vinson PP. A case of cardiospasm with dilatation and angulation of the esophagus. *Med Clinics North Am* 1919; 3: 623-7.
3. Wynder EL, Hultberg S, Jacobsson F, Bross IJ. Environmental factors in cancer of the upper alimentary tract. A Swedish study with special reference to Plummer Vinson (Paterson-Kelly) syndrome. *Cancer* 1957; 10:470-82.
4. Mansell NJ, Jani P, Bailey CM. Plummer Vinson Syndrome – a rare presentation in a child. *J Laryngol Otol* 1999; 113:475-76.
5. Novacek G. Plummer Vinson Syndrome. *Orphanet. J Rare Dis.* 2006; 15: 1: 36.
6. Demirci F, Savas MC, Kepke N et al. Plummer-Vinson syndrome and dilatation therapy: A report of two cases. *Turk J Gastroenterol* 2005; 16: 224-27.
7. Anderson SR, Sinacori JT. Plummer Vinson syndrome heralded by post cricoid carcinoma. *Am J Otolaryngol* 2007; 28:22-24.
8. Egan JV, Baro TH, Adler DG, Davila R, Faigel DO, Gan SL et al. Standards of practice committee. Esophageal dilation. *Gastro Intest Endosc* 2006; 63:755-60.
9. Larson LG, Sandstrom A, Westling P. Relationship of Plummer Vinson disease to cancer of the upper alimentary tract in Sweden. *Cancer Res* 1975; 35:3308-3316.
10. Chisholm M. The association between webs, iron and post cricoid carcinoma. *Postgrad Med J* 1974; 50:215-19.
11. Watts JM. The importance of the plummer vinson syndrome in the aetiology of carcinoma of the upper gastrointestinal tract. *Posrgrad Med J* 1961; 37:523-33.
12. Badawy BS, Ahamad MAK, Sayed RH. Role of microsatellites instability in carcinogenesis of postcricoid carcinoma on top of plummer Vinson syndrome. *Indian J Otolaryngol Head Neck Surg* 2010; 62:417-20.