

# Audit on the use of radiological investigations in the management of rhinosinusitis

Stephan Grech, Richard M McKearney, Herman Borg-Xuereb

## Abstract

**Objectives:** The aim of this audit is to establish the cost to the Maltese health system from the use of radiological imaging in managing rhinosinusitis and to identify areas in which these costs can be minimised by following guidelines on the management of rhinosinusitis.

**Methods:** All plain radiographs and computed tomography scans (CT) of the paranasal sinuses requested in the Mater Dei Hospital over a one year period were analysed. Data was collected regarding: the quantity of investigations ordered, age of the patients, cost and requesting department.

**Results:** Over one year: 205 CT scans and 113 sets of plain radiographs of the paranasal sinuses were requested, costing a total of euro103,440. The majority (73%) were elective requests made by ENT consultants. Five percent of CT scans were requested for patients less than 10 years of age.

**Conclusion:** Rhinosinusitis is diagnosed clinically, only requiring radiological investigation in more complex cases best managed by specialists in ENT. Plain radiographs have limited use in the management of rhinosinusitis. Judicious use of imaging requests whilst following clinical guidelines is required to save money and minimise patient exposure to ionising radiation.

## Key Words

Sinusitis, Clinical Audit, X-Ray Computed Tomography

## Introduction

Acute and chronic rhinosinusitis are very common conditions faced by the otolaryngology (ENT) department in Mater Dei Hospital (MDH), affecting 15% of the population in Western countries.<sup>1</sup> Sinusitis refers to the inflammation of the mucosa lining the cavities of the paranasal sinuses and is often accompanied by inflammation of the nasal mucosa, hence the term rhinosinusitis. Patients commonly present with symptoms of nasal blockage, nasal discharge, facial pain and anosmia. Rhinosinusitis is commonly classified into either being acute or chronic according to the duration of symptoms, with acute rhinosinusitis said to last less than 12 weeks and chronic rhinosinusitis longer than this.<sup>2</sup>

The diagnosis and management of rhinosinusitis requires clinical acumen, and on occasion, benefits from the judicious use of radiological imaging. Despite the advancements seen in diagnostic imaging, the diagnosis of sinusitis is still a challenge. The European Position Paper on Rhinosinusitis and Nasal Polyps 2012 recommends that no diagnostic imaging is required for acute rhinosinusitis in adults and children, with the diagnosis being made clinically.<sup>2</sup> Computed Tomography (CT) scanning is however recommended if there are difficulties in management such as: signs of complications, in severe disease or in

**Stephan Grech** M.D. MRCS(Ed)  
Department of Orthopaedics, Mater Dei Hospital,  
Malta

**Richard M McKearney** BSc (Hons), MBChB (Hons)\*  
Department of ENT, Mater Dei Hospital, Malta  
[r.m.mckearney@doctors.org.uk](mailto:r.m.mckearney@doctors.org.uk)

**Herman Borg-Xuereb** FRCS(Ed)(Gen),  
FRCS(Ed)(ENT)  
Department of ENT, Mater Dei Hospital, Malta

\*corresponding author

immunocompromised patients. Patients with these complications and those who are being considered for surgery should ideally be managed by a specialist in ENT and be examined endoscopically prior to ordering further investigations. CT is indicated prior to performing endoscopic sinus surgery as it is essential to assess the individual anatomy of the paranasal sinuses. Plain radiographs are of limited diagnostic use, having been largely superseded by CT scanning owing to the greater definition of the paranasal sinuses that it provides.

Accompanying the rising incidence of this common condition is the financial burden arising from the radiological investigations used in its diagnosis and management. In this relatively inauspicious time it is more pertinent than ever to ensure that finances dedicated to patient care are used with utmost responsibility. As well as the cost of over-investigation, subjecting patients to unnecessary ionising radiation means that patients may receive more harm than good given the limited usefulness of imaging in certain circumstances. Extra care should be taken to avoid exposing young patients (less than 10 years of age) to unnecessary ionising radiation.

The aim of this study is therefore to analyse the cost to the Maltese public health system from the use of radiological imaging in managing rhinosinusitis and to identify areas in which the use of these resources can be made more appropriate by auditing the requests made over a one year period.

## Methods

Data over a period of one year was reviewed, auditing the use of imaging in the management of rhinosinusitis in MDH. All inpatient and outpatient plain radiographs and CT scans of the paranasal sinuses for patients of all ages with clinical signs of acute or chronic rhinosinusitis were analysed. The audit was conducted retrospectively for the time period from the 1<sup>st</sup> January 2009 to the 31<sup>st</sup> December 2009.

## Standards

**Standard 1:** No plain radiographs of the paranasal sinuses should be requested to diagnose rhinosinusitis (target = zero).

**Standard 2:** CT scans should ideally be requested by specialists in ENT, **unless** the patient is already under the care of a non-ENT specialist and: there is very severe disease, the patient is immunocompromised or there are signs of complications (target = 100% CT scans requested by specialists in ENT).

**Standard 3:** No CT scans should be requested for patients of less than 10 years of age unless: there is

very severe disease, the patient is immunocompromised, there are signs of complications or surgery is being considered (target = zero).

The standards of this Audit are based on clinical evidence collated and presented in The European Position Paper on Rhinosinusitis and Nasal Polyps 2012 which provides recommendations for how rhinosinusitis should be diagnosed and managed.<sup>2</sup>

As well as collecting data to assess the compliance with the above standards, data was collected relating to other parameters regarding the imaging requests made. These parameters consisted of:

- the number of each imaging modality requested
- requesting department
- whether investigations were requested as urgent or elective
- the age of the patients imaged
- total cost

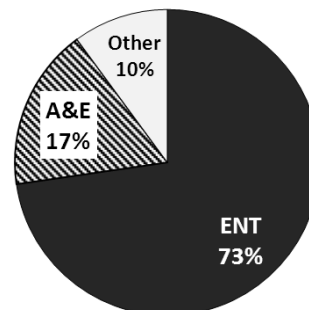
This information was accessed from the Radiology Information System (RIS) and from the local Patient Archive and Communication System (PACS) and recorded and analysed using Microsoft Excel. The costs of the imaging involved were obtained from the billing section of MDH.

## Results

The total sample size for this audit was 318 radiological images. Two hundred and five CT scans and 113 plain sinus radiographs (consisting of three sinus views) were requested over this one year audit period (standard 1).

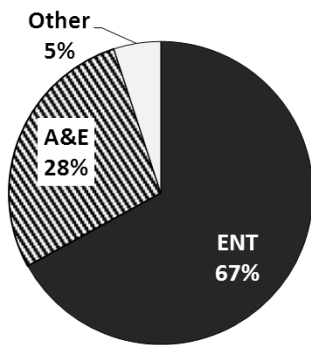
### Requesting Department

Of the 205 CT sinus scans performed, the overwhelming majority were requested by ENT consultants (standard 2:  $n=149$ , 72.7%), with the remainder being ordered by the Accident and Emergency department (A&E) ( $n=36$ , 17.6%) or other departments ( $n=20$ , 9.7%) (Figure 1A).



**Figure 1A:** Percentage of CT scans requested by each department

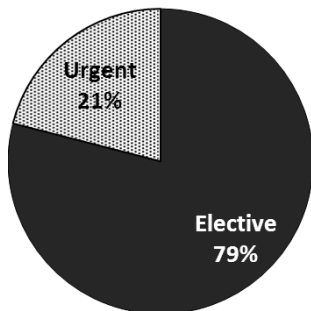
Similarly, of the 113 plain radiograph series requested, most were requested by the ENT department ( $n=76$ , 67.3%) (Figure 1B).



**Figure 1B:** Percentage of plain radiographs requested by each department

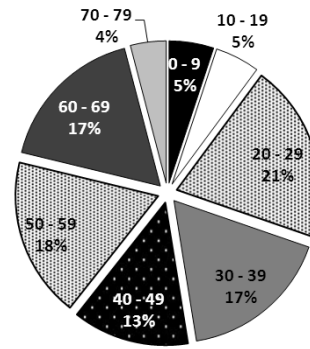
*Elective versus Emergency*

When both imaging modalities were combined ( $N=318$ ), just over one fifth were requested as urgent ( $n=67$ , 21.1%), with the remainder ordered as elective investigations, mostly by ENT consultants in outpatient clinics ( $n=251$ , 78.9%) (Figure 2).

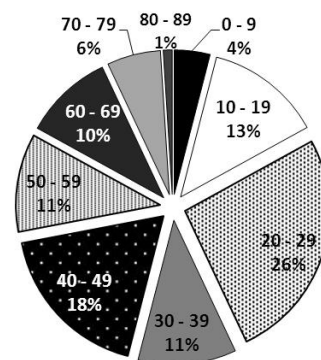


**Figure 2:** Percentage of urgent or elective requests for CT and plain radiographs of the paranasal sinuses

Despite the limited diagnostic usefulness of imaging in the diagnosis of sinusitis in young children and given the increased sensitivity of children to the harmful effects of ionising radiation, a relatively high amount of both CT scans (standard 3:  $n=10$ , 4.9%) (Figure 3A) and plain radiograph series ( $n=5$ , 4.4%) (Figure 3B) were requested for children less than 10 years of age.



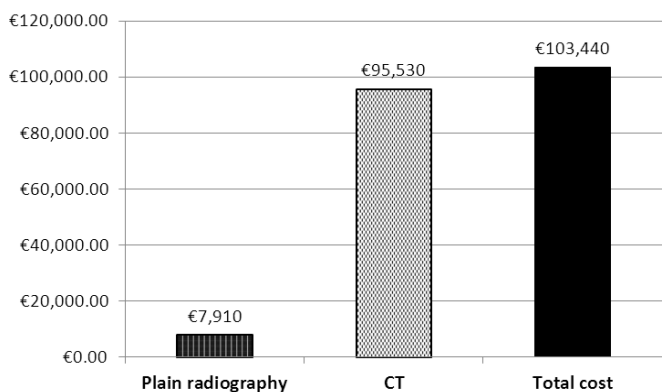
**Figure 3A:** Pie chart demonstrating the age of the patients for which CT scans were requested



**Figure 3B:** Pie chart demonstrating the age of the patients for which plain radiographs were requested

*Total Costs*

For a standard plain radiograph series of 3 images, the total cost is €77. The cost of a CT scan of the sinuses at MDH is €350. The total cost to the Maltese public health system for the imaging alone over this 1-year period is therefore €7,910 for the plain radiographs and €95,530 for the CT scans, making a total of €103,440 (Figure 4). This does not take into account hidden-expenses such as the staff-time involved in carrying out the scans, nor the potential gain in using these imaging resources for the benefit of other patients.



**Figure 4:** Bar chart representing the cost to the Maltese health system from the use of plain radiography and CT in managing rhinosinusitis

### Standards

**Standard 1:** Due to the low sensitivity and specificity of plain radiographs, their use in the diagnosis of rhinosinusitis is no longer recommended. 113 plain sinus radiographs were requested over this one year audit period. The target was zero.

**Standard 2:** Seventy three percent of CT scans were requested by the ENT department. The target was 100%.

**Standard 3:** Five percent ( $n=10$ ) of the 205 CT scans requested were for children of less than 10 years of age. The target was zero.

### Discussion

#### Radiological Imaging in Rhinosinusitis

##### Plain radiography

Plain radiography in acute rhinosinusitis may demonstrate findings of: mucosal thickening, air-fluid levels, and complete opacification of the involved sinuses. Despite findings of mucosal thickening being observed in 90 percent of cases of acute rhinosinusitis, it is a very non-specific finding.<sup>3</sup> Misdiagnosis is highly undesirable as it means that some patients will receive treatment unnecessarily and others with undiagnosed rhinosinusitis may go untreated. Due to the low sensitivity and specificity of plain radiographs, their use in the diagnosis of rhinosinusitis is no longer recommended.<sup>4</sup> For this reason CT has taken over the role of plain radiography. The current waiting time for a routine CT scan can be 2-3 months whereas plain radiography may be available the same day. Despite this, it still remains a fact that plain radiography has a low sensitivity and specificity in the diagnosis of rhinosinusitis and is unable to provide information in the complicated cases of rhinosinusitis for which a CT scan is indicated.

##### Computed tomography

CT scans provide much more information about the anatomy and abnormalities of the paranasal sinuses than plain films. Although more sensitive than plain radiography, CT findings are still relatively non-specific and should therefore be used in conjunction with clinical and endoscopic findings in order to avoid overdiagnosis and therefore overtreatment of patients. CT should therefore not be used routinely as a primary diagnostic step, unless there are worrying clinical features such as unilateral symptoms.<sup>2</sup> The diagnosis of rhinosinusitis is a clinical one, with CT imaging used to guide management in patients who are unresponsive to three months of maximal medical therapy or in complicated cases. CT is essential in assessing the complexity of the sinonasal anatomy prior to performing endoscopic sinus surgery.<sup>5</sup> As well as the cost associated with a CT scan of the sinuses (euro350), patients are also exposed to harmful radiation, quantified at an effective radiation dose of around 1.1mSv per investigation (approximately equivalent to 55 chest radiographs) compared to 0.07mSv for a series of three plain radiographs (approximately equivalent to eight chest radiographs).<sup>6</sup> This ionising effect is not insubstantial and is of particular concern in younger patients. This study found that five percent of CT scans requested were for patients less than 10 years of age. Recent interest has arisen in attempts to improve image quality whilst also reducing the radiation dose.<sup>7</sup>

##### Other imaging techniques

Magnetic Resonance Imaging (MRI) is used secondarily to CT as it has a higher cost, provides poorer imaging of bony anatomy and still produces many false-positive results. It may be used as an adjunct to CT to investigate cases of suspected neoplasia.<sup>2</sup> The use of sinus ultrasound is limited by its poor sensitivity and specificity. It is therefore rarely used in clinical practice.

#### Recommendations for the use of Imaging

The diagnosis of rhinosinusitis is a clinical one based on the following symptoms and signs:

- Symptoms of: nasal blockage/ congestion *OR* nasal discharge (including symptoms of facial pain/ pressure and anosmia).  
*AND*
- Signs of: polyps *OR* mucopurulent discharge *OR* mucosal oedema and obstruction, on endoscopy.<sup>2</sup>

##### Acute rhinosinusitis

According to the guidance provided by The European Position Paper on Rhinosinusitis and Nasal Polyps 2012, plain sinus radiographs are not routinely recommended in managing acute or chronic

rhinosinusitis as thickening of the sinus mucosa is a non-specific finding and may occur in asymptomatic patients. CT should not be used to diagnose acute rhinosinusitis in adults or children unless: there is very severe disease, the patient is immunocompromised or there are signs of complications, in which case the patient should ideally be managed by a specialist in ENT. The 2008 European Commission referral guidelines for imaging concur with these recommendations, advocating the use of CT in cases where maximal medical therapy has been unsuccessful or in cases where complications or malignancy are suspected.<sup>6</sup> If the patient is unresponsive to medical therapies, non-ENT specialists may consider referring the patient to the ENT department where the patient may be examined endoscopically prior to considering radiological investigation

#### *Chronic rhinosinusitis*

CT scanning is not recommended in the management of chronic rhinosinusitis by non-ENT specialists unless there is very severe disease, the patient is immunocompromised or there are signs of complications. Referral to an ENT specialist may be considered if medical management has not improved the patient's symptoms after four weeks or if an operation is to be considered. An ENT specialist may request a CT scan prior to making a decision to perform surgery. A navigation system used during endoscopic sinus surgery is of particular benefit as it provides real-time imaging of the sinuses as the operation progresses.

#### **Cost and Future Audit**

This study brings to light the large financial burden to the health system arising from the costs of imaging used in managing rhinosinusitis. It is the responsibility of health care professionals to ensure that clinical practice makes best use of the resources available in order to maximise the benefit to patients. This study's findings raise the need for future re-audit in this field with particular emphasis on the following audit standards:

1. Patients with rhinosinusitis should be diagnosed clinically without the use of plain radiographs or CT
2. CT scans should ideally be requested by ENT specialists
3. The number of CT scans in patients of less than 10 years of age should be minimised

In order to achieve these standards, it is important that all clinicians treating patients with suspected rhinosinusitis are aware of the guidelines regarding its management. Ways to accomplish this include: presenting the above findings at clinical meetings and

publishing them to highlight the areas in the management of rhinosinusitis which may be improved.

#### **Limitations**

A potential limitation of this study is that we don't know what proportion of patients with rhinosinusitis were diagnosed clinically or by radiographic investigation as we audited all patients for whom imaging was requested. Future audit may consider looking at a sample of patients with rhinosinusitis diagnosed clinically according to the European Position Paper definition of rhinosinusitis and assess how many of these patients underwent imaging and for what purpose.

#### **Conclusion**

The diagnosis of acute and chronic rhinosinusitis is based upon a thorough history and examination. Imaging is not required to make the diagnosis and is only useful in certain situations best managed by the ENT department. The cost to the Maltese public health system from the use of imaging in managing rhinosinusitis is not insignificant (euro103,440), and a proportion of this amount may have been spent unnecessarily, with CT scans being requested which have little or no impact on the management decisions regarding the patients' symptoms. Symptoms of which are largely managed by relatively safe empirical medical therapies anyway. Careful consideration should be taken to decide, prior to requesting any investigation, how it will affect the patient's management and if it will be of benefit to them.

#### **References**

1. Eloy P, Poirrier AL, De Dorlodot C, Van Zele T, Watelet JB, Bertrand B. Actual concepts in rhinosinusitis: a review of clinical presentations, inflammatory pathways, cytokine profiles, remodeling, and management. *Curr Allergy Asthma Rep.* 2011;11:146-62.
2. Fokkens WJ, Lund VJ, Mullol J, Bachert C, Alobid I, Baroody F *et al.* EPOS 2012: European Position Paper on Rhinosinusitis and Nasal Polyps 2012. A Summary for Otorhinolaryngologists. *Rhinology.* 2012;50:1-12.
3. Low DE, Desrosiers M, McSherry J, Garbers G, Williams JW Jr, Remy H *et al.* A practical guide for the diagnosis and treatment of acute sinusitis. *CMAJ.* 1997;156 Suppl 6:S1-14.
4. Iinuma T, Hirota Y, Kase Y. Radio-opacity of the paranasal sinuses. Conventional views and CT. *Rhinology.* 1994;32:134-6.
5. Kazkayasi M, Karadeniz Y, Arıkan OK. Anatomic variations of the sphenoid sinus on computed tomography. *Rhinology.* 2005;43:109-114.
6. European Commission. Referral Guidelines for Imaging. Radiation Protection 118. Final Report to the European Commission for Grant Agreement SUBV99/134996, 2008.
7. Hagtvedt T, Aaløkken TM, Nøthellen J, Kolbenstvedt A. A new low-dose CT examination compared with standard-dose CT in the diagnosis of acute sinusitis. *Eur Radiol.* 2003;13:976-80.