

## Case Report

# Nicorandil-induced oral ulceration

Marilou Ciantar, John Gibson

## Abstract

Oral ulceration has many aetiological factors. The anti-anginal drug Nicorandil is becoming increasingly recognised as a causative factor for oral ulceration. The aim of this case report is to increase awareness among clinicians (medical and dental) that nicorandil can induce extensive oral ulceration and thus should be included in the differential diagnosis when presented with patients complaining of long-standing oral ulceration.

## Case report

Traditionally, standard treatment of angina pectoris has been based on life style changes as well as the use of pharmaceutical agents such as nitrates, beta-blockers and calcium-channel blockers. In cases intolerant of standard treatment or where standard treatment has failed, nicorandil may be used.

Nicorandil (Ikorel<sup>®</sup>, Rhône-Poulenc Rorer Ltd) is a potassium-channel activator with a nitrate component. It is both an arterial- and veno-dilator and is licensed for the long-term treatment of angina. It is usually well tolerated with main reported side-effects of headache and cutaneous vasodilation. Oral ulceration has been reported to be a rare side effect.

However several reports in the literature show that nicorandil-induced oral ulceration can be quite extensive, severe and debilitating.<sup>1-4</sup> Furthermore, the important distinction between nicorandil-induced oral ulceration and other causes of oral ulceration, including oral carcinoma, has to be made due to the different subsequent treatment modalities. Although nicorandil was first used in Europe around 1994, its association with oral ulceration only came to light in 1997<sup>5</sup>, thus its incidence might have been under-reported. This case report describes the presentation and management of such a case.

An 82 year-old lady was referred by her general medical practitioner complaining of oral ulceration. Her main complaint was that of a large, painful ulcer of 9 weeks duration. Her past medical history showed that she suffered from cardiac problems namely atrial fibrillation, angina, hypertension as well as hypothyroidism, oesophagitis and diverticular disease. A malignant melanoma on her left toe was removed surgically 8 years previously. Her medication consisted of losartan, amiodarone, omeprazole, bisoprolol, spironolactone, temazepam, simvastatin, thyroxine, warfarin, GTN spray and nicorandil 20 mg twice daily.

On clinical examination the ulcer was a soft, superficial, non-indurated lesion on the right dorso-lateral surface of her tongue, measuring 2.5 x 1.5 cm (Figure 1a). The ulcer was flat and had an erythematous, serpiginous outline. It did not have rolled borders, did not bleed and the tongue was mobile. Local factors e.g. trauma, haematinic deficiencies and systemic diseases were excluded as causes of the ulcer. Nicorandil seemed to be the likely cause for the ulcer. Some symptomatic relief was obtained with betamethasone mouthwash (0.5mg, 4 times daily). Following consultation with her cardiologist, the

## Key words

Nicorandil, oral, ulcers

**Marilou Ciantar\*** PhD, FFD RCSI  
Unit of Oral Surgery & Oral Medicine  
Dundee Dental Hospital and School  
Email: marilou@ciantar.freeseve.co.uk

**John Gibson** PhD, FDS (OM)  
Unit of Oral Surgery & Oral Medicine  
Dundee Dental Hospital and School  
Email: john.gibson2@nhs.net

\*corresponding author

nicorandil was reduced to 10 mg twice daily. Thereafter, the pain decreased and the ulcer healed in short order (six weeks) without any residual scarring (Figure 1b). On review three months later, the patient was still symptom-free through there was still some depapillation at the previous ulcer site.

## Discussion

Systemic medication is known to have potential adverse side effects on the oral mucosa. Perhaps the most common manifestation is gingival hyperplasia due to phenytoin, nifedipine and cyclosporin. Xerostomia is a common complaint of patients on anti-depressants and antihypertensives, while lichenoid reactions of the oral mucosa have been associated with many drugs. Oral ulceration is known to occur with aspirin (chemical burn, if left to dissolve whilst in contact with the oral mucosa), captopril, gold salts, penicillamine, NSAIDS and cytokine inhibitors.<sup>6</sup> Other drugs e.g. griseofulvin and isoniazide have potential side effects of which oral ulceration may be a manifestation.

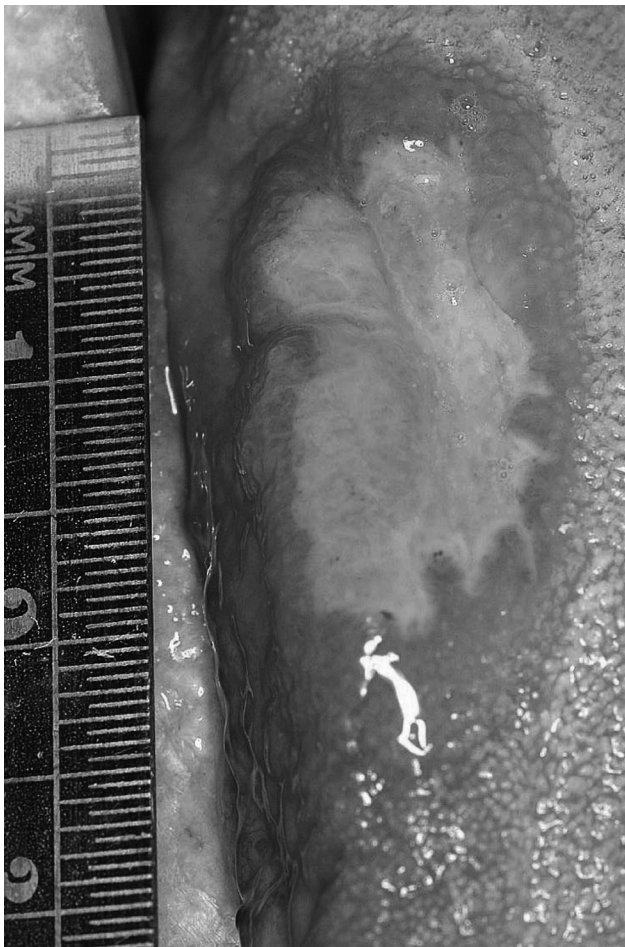
The most common side effect of nicorandil is headache which manifests in the first few days of treatment but decreases with prolonged use. Other side effects include cutaneous vasodilatation with flushing, nausea, vomiting, dizziness and

weakness; rare side effects include, myalgia, rash, reduction in blood pressure and / or increased heart rate, angioedema, hepatic dysfunction, anal ulceration and oral ulceration.<sup>6</sup>

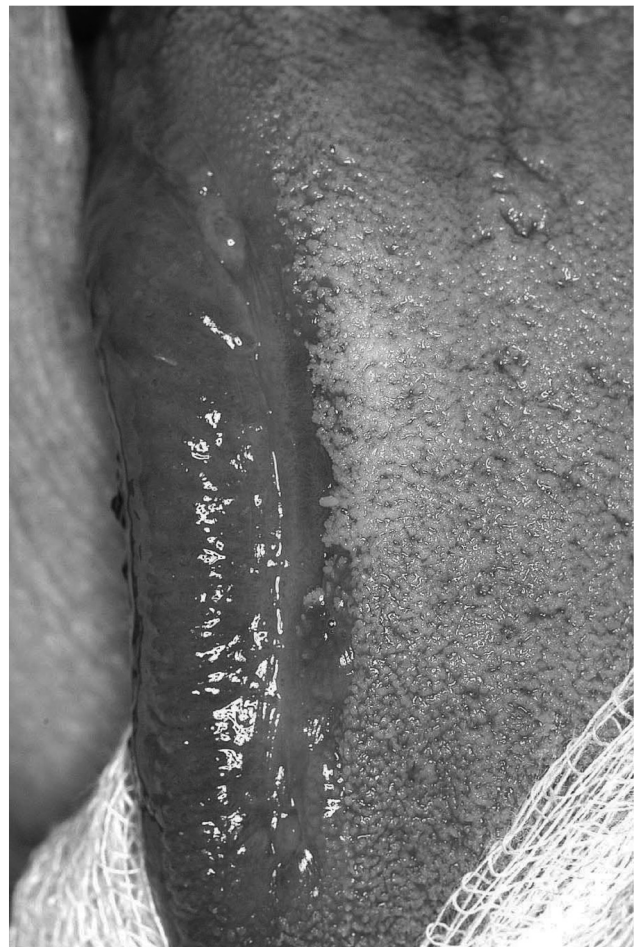Nicorandil-induced oral ulceration seems to have a predilection for the tongue though other sites e.g. buccal mucosa / labial mucosa<sup>14</sup>, gingiva<sup>17</sup> may also be affected. The exact mechanism of ulcer formation is unknown. Although described a rare occurrence, its incidence has been reported to be around 5%<sup>7</sup>. Some case reports have shown that nicorandil seems to be associated with ulceration of other parts of the gastrointestinal tract: anus<sup>8</sup>, gastrointestinal tract<sup>9</sup> and para-stomally.<sup>10</sup> King *et al.*<sup>11</sup> also report perforation of the terminal ileum as a possible complication of nicorandil therapy.

This case report presents a fairly typical picture of nicorandil-induced oral ulceration. Resolution of symptoms following reduction in dose confirmed the diagnosis. The appearance of ulcers seems to be dose-dependent with most patients (as in this case) being on at least 40 mg nicorandil daily.<sup>2-4</sup>

Although clinically they may appear like aphthous ulcers<sup>12</sup>, and have been reported as such<sup>13,14</sup>, nicorandil-induced oral ulcers have certain distinguishing features. Clinically they are larger than minor aphthous ulcers and have an irregular outline. Furthermore they appear on keratinized mucosa (tongue) whilst



**Figure 1a:** Ulcer on presentation



**Figure 1b:** Six weeks after reduction of nicorandil therapy

major aphthae never appear at this site. The lateral border of the tongue is the primary site for oral squamous cell carcinoma (OSCC); certain clinical features distinguish between the two conditions: nicorandil-induced oral ulcers are painful from the outset whilst OSCC may become painful only in the late stages of the disease. Furthermore, an OSCC would normally present as an indurated, exophytic lesion or as a red, white or speckled patch.

It is important to point out that this patient had presented two years earlier with a similar large, sloughing, irregular ulcer on her left cheek. At the time she was on 30 mg nicorandil twice daily. Treatment followed a similar pattern as above. However at that time she was lost to follow up.

It is recognised that nicorandil causes mouth ulceration; however the mechanism by which it does so remains unknown. Ulceration is more likely to occur with higher doses of the drug ( $\geq 40$  mg daily). What is noteworthy is that cessation of the drug is not normally required, with a reduction in dose providing relief from ulceration in most patients.

## References

1. Cribier B, Marquart-Elbaz C, Lipsker D, Alt M, Grosshans E. Chronic buccal ulceration induced by nicorandil. *Br J Dermatol* 1998; 138(2): 372-3.
2. Scully C, Mano A, Felix D, Crighton A, Field A, Porter S. Nicorandil can induce severe oral ulceration. *Oral Surg, Oral Med Oral Pathol, Oral Radiol Endod*. 2001; 91 (2): 189-3.
3. Healy CM, Smyth Y, Flint SR. Persistent nicorandil induced oral ulceration. *Heart*.2004; 90: e38.
4. Webster K, Godbold P. Nicorandil induced oral ulceration. *BDJ*. 2005; 198 (10): 619-1.
5. Boulinguez S, Bedane C, Bouyssou Gauthier ML, Cornee-Leplat I, Truong E, Bonnetblanc JM. Giant buccal aphthosis caused by nicorandil. *Presse Med* 1997; 26(12):558
6. BNF (British National Formulary). BMG publishing group limited & RPS publishing. 2006; 52: 115.
7. Marquat-Elabz C, Lipsker D, Grosshans E, Cribier B. Prevalence and clinical pathological features of nicorandil-induced oral ulceration. *Ann Dermatol Venereol* 1999; 126:587-90.
8. Watson A, Suttie S, Fraser A, O'Kelly T, Loudon M. Nicorandil associated anal ulceration. *Colorectal Dis* 2004; 6: 330-1.
9. Egred M, Andron M, Morrison WL. Nicorandil may be associated with gastrointestinal ulceration. *BMJ* 2006; 332 (7546):889.
10. Abdelraseq AS, Owen CM, Smith L, McAdam JG, Pearson HJ, Leveson SH. Nicorandil-associated para-stomal ulceration: case series. *Eur J Gastroenterol Hepatol* 2006; 12: 1293-5.
11. King PM, Suttie SA, Jansen JO, Watson AJ. Perforation of the terminal ileum: a possible complication of nicorandil therapy. *Surgeon* 2004; 2: 56-7.
12. Shotts RH, Scully C, Avery CM, Porter SR. Nicorandil-induced severe oral ulceration: a newly recognised drug reaction. *Oral Surg Oral Med Oral Pathol Oral Radiol Endod* 1999; 87(6): 706-7.
13. Desruelles F, Bahadoran P, Lacour JP, Perrin C, Santini J, Ortonne JP. Giant aphthous ulcers induced by nicorandil *Br J Dermatol* 1998; 138 (4): 712-3.
14. Gupta A, Morris G. Minor aphthous ulcers induced by nicorandil. *Age Ageing* 2000. 4; 29: 372-3.