

In Practice

Foot Pain

Aaron Formosa

Case Summary

A 36 year old gentleman presented with a three week history of right foot pain. Pain was worse in the morning, especially on taking the first steps of the day. It was described as sharp and pulling in nature and was particularly felt on toe-off. There was no nocturnal pain or pain at rest, and no recent trauma reported. For the previous month, he had been walking for approximately an hour per day, while previously he described a rather sedentary lifestyle.

On examination there was no swelling or skin discoloration. The foot was tender over the calcaneal tuberosity at the origin of the plantar fascia. Examination of the arches of the feet in the supine position was unremarkable. On standing, there was moderate hyperpronation of the feet which became more pronounced on walking.

Assessment of footwear showed increased erosion over the medial aspects of both right and left soles.

Introduction

Foot complaints are very common in general practice and their incidence increases with age. Three out of four people complain of foot pain during the course of a lifetime¹, while approximately 20% of people aged 65 years or older complain of non-traumatic foot problems.²

A differential diagnosis of foot pain is best described by dividing the foot into three distinct areas namely:

- Heel
- Mid-foot
- Forefoot (see Table 1)

History

A good history can provide a wealth of information when it comes to tackling a case of foot pain. A number of questions which should preferably always be asked when dealing with a case of foot pain include:

- Is there any history of trauma?
- Is the pain increasing over time (overload)?
- Is pain worse in the morning (inflammatory process) or in the evening (sprains, fractures)?
- Are there any recent occupational changes?
- Are there any recent changes in footwear?
- Is there any nocturnal pain?
- Are there any recent changes in exercise? (nature of exercise, intensity, rest periods, surface)
- Are there any chronic or recent general medical conditions?

Examination

The aim of the examination is to confirm the diagnosis suggested by the history. It is very important to examine both feet and compare findings. A good amount of information can also be obtained by examining the feet in the supine position as well as while standing and walking. A systematic examination of the foot should include:

- Observation
- Movement
- Palpation

Observation

In the supine position, one looks for swelling, deformities, colour changes, callouses, warts and problems with arches of the feet. Subsequently, the patient is assessed standing up (if

Aaron Formosa MD, FFSFM
Department of Primary Care, Floriana, Malta
Email: aaform@onvol.net

symptoms permit). Here, one can observe any changes in the foot arches. A seemingly normal arch could collapse on weight bearing. Observing a patient while walking gives information regarding hyperpronation or hypersupination of the feet.

Footwear should also be examined. Ideally, the soles of well worn shoes are assessed. The erosion pattern will give information about the gait. In a pronated gait, the medial aspect of the sole of the shoe shows more erosion, while a hypersupination gait will involve the lateral aspect of the sole.

Movement

- *Active Movement:* The patient is asked to go through the range of movement of the foot without assistance. Movements involved are mainly ankle dorsiflexion and plantar flexion and eversion and inversion of the foot.
- *Passive Movement:* The same movements are done passively to check for stiffness, increased or decreased range of movement and to check if pain can be reproduced.
- *Resisted Movement:* The examiner resists movements of the foot causing the patient to do isometric work. This

examination looks at power, the contractile structures (muscles and tendons) and any reproducible pain.

Palpation

The localisation of tenderness should correspond to the anatomical structure involved. The possibility of referred pain to the foot from elsewhere e.g. sciatica, should be kept in mind. Also a change in temperature overlying the involved site could indicate an inflammatory process.

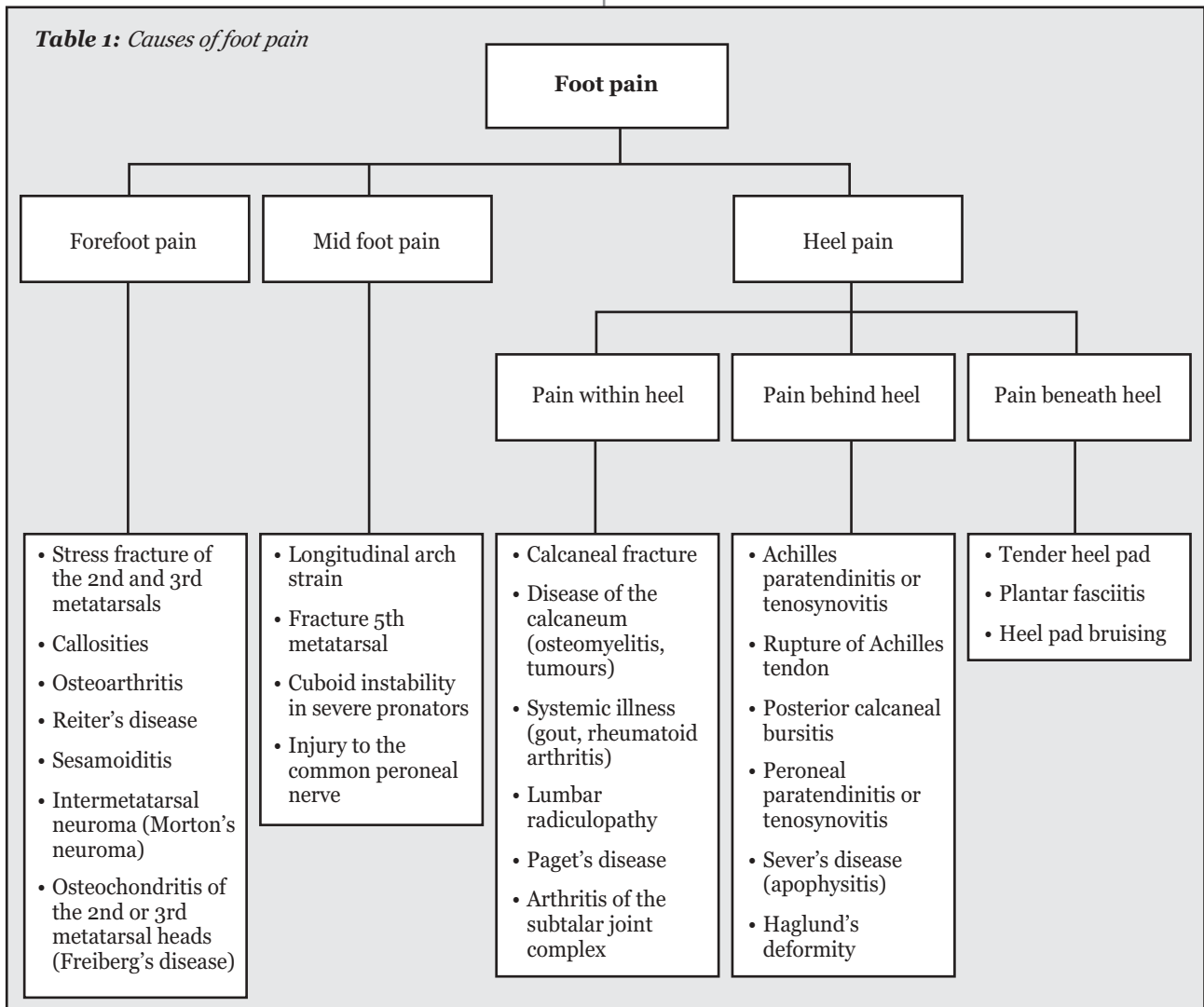
Investigation

There is little point in requesting investigations which will not change management.

Plain X-Rays are the initial investigation commonly requested. Consideration of the most appropriate view is important. In foot injuries, X-Rays are not routinely indicated and should only be requested in the following circumstances:³

- True bony tenderness
- Nocturnal pain with no history of trauma
- Foot pain in children (unless the diagnosis is an obvious one) and

Table 1: Causes of foot pain



- When foot pain is progressing differently or lasting longer than one would expect from the initial diagnosis

Ultrasound can help in the diagnosis of plantar fasciitis. CT and MRI and radioisotope bone scanning could also give useful information. CT and radioisotope bone scanning are mainly used for bone pathology while MRI scans can give information regarding soft tissue problems.

Blood investigations can be diagnostic when systemic disease is suspected. ESR, serum uric acid, rheumatoid factor and alkaline phosphatase are relevant tests.

The ultimate decision on whether one should investigate depends strongly on the history and examination findings.

Plantar Fasciitis

The gentleman discussed in the introductory case presentation had symptoms and clinical signs which are typical of plantar fasciitis.

Plantar fasciitis is a localized degenerative condition of the plantar aponeurosis.⁴ It affects approximately 10% of the population over the course of a lifetime⁵ and this includes both athletes⁶ and sedentary individuals. It most often involves one foot, but it could be bilateral in up to 15% of patients.

The plantar fascia is a dense fibrous membrane extending from the tubercle of the calcaneum to the proximal phalanges. It has three main functions:

- 1) protects the underside of the foot,
- 2) acts as a shock absorber,
- 3) maintains the longitudinal arch.

Predisposing factors for plantar fasciitis

Predisposing factors can be divided into two categories, either anatomic or biomechanical.⁴ Usually it is a combination of factors from both categories which predispose to plantar fasciitis.

Anatomic predispositions include pes planus, pes cavus, hyperpronating gait or leg length discrepancy.

Biomechanical causes include inappropriate footwear (usually flat shoes), muscle tightness, overtraining / overuse or an elevated body mass index (>30 kg/m²). Unaccustomed walking or running and an occupation involving prolonged weight bearing can be classified as risk factors for plantar fasciitis.⁷

Plantar fasciitis can also be associated with severe arthritis, diabetes and Paget's disease, but in 85% of cases the cause is unknown.

Signs and symptoms

Plantar fasciitis characteristically results in heel pain. This is worse during the first few steps on getting out of bed or after prolonged sitting as opposed to a calcaneal stress fracture which would characteristically result in increased pain with activity. The pain in plantar fasciitis is felt during toe-off and improves

with activity. At night, the foot tends to remain in an equinus position and fascial tissue contracts.⁷ Putting weight on the foot puts the plantar fascia under tension. This will subsequently aggravate the pain. Nocturnal pain could be the result of tumours, infections or nerve entrapment (tarsal tunnel syndrome).⁸

On examination, one would find tenderness on the calcaneal tuberosity.

Very often, patients describe an aggravating factor. This could be a sudden increase in walking (or other forms of exercise), changes at work or a change in footwear.

Investigations

Investigations are rarely required and are used to exclude other disorders that can cause inferior heel pain.⁷

A report coordinated by the European Commission, in conjunction with the UK Royal College of Radiologists, in 2001, suggested that plain X-Rays should not be taken routinely in plantar fasciitis as the cause of pain is seldom detectable. Heel spurs are usually associated with plantar fasciitis, but 15-25% of asymptomatic individuals have them.⁷

This percentage increases with age and obesity.^{9,10} Also, many symptomatic patients do not have heel spurs.¹¹ Heel spurs are thought to be caused by plantar fasciitis but are not the cause of the pain unless they are very large.

Ultrasound may detect an increase in the thickness of the plantar fascia and can be helpful to monitor progress.^{12,13}

Nuclear imaging and Magnetic Resonance Imaging are more sensitive in showing inflammatory changes, but the majority of patients can be managed without imaging.

Treatment

Many times, the condition is self limiting. Various treatment options are available, but their efficacy has not yet been established in randomized controlled trials.⁵ Patients should be treated conservatively at first and only in severe cases surgically.⁶ There is a higher risk of continued symptoms in over-weight patients, those with bilateral symptoms and those who have symptoms for a prolonged period before seeking medical attention.^{10,11}

Rest

This can vary from non-weight bearing to lifestyle modifications. The aim should be to relieve the strain on the plantar fascia. Problems arise when patients find it difficult to make alterations to their daily routine e.g an athlete would find it difficult to reduce a training schedule. Similarly, someone might refuse to change the style of shoes being worn.

Pharmaceutical

Non-steroidal anti-inflammatory drugs are often used as the treatment of choice. They are beneficial for their analgesic properties⁴ and help to reduce the inflammatory process. They should be primarily used for short-term pain relief.

Footwear

These should have adequate arch support and shock absorbing qualities. Wolgin et al found that in 14% of patients a change in footwear was the most effective form of treatment.¹⁰ It should be advised in combination with other treatment options.

Orthoses

These also are helpful in supporting the arch and relieving pressure on the mid-foot.¹⁴ It is a very effective mode of treatment⁵, and should particularly be prescribed in patients who stand for long periods and those with excessively low or high arches. Heel supports also physically reduce the pressure on the insertion of the plantar fascia on the calcaneal tubercle. Pre-fabricated orthoses have been found to be the most likely to result in an improvement in symptoms especially when used in conjunction with a stretching programme.¹⁶

Night splints

Dorsiflexion splints have been developed to limit the degree of contraction sustained by the plantar fascia at night. It has been repeatedly reported^{16,17} that one month of regular use of a night splint resulted in a beneficial effect, with an improvement in symptoms of up to 75% of patients at one month follow-up.¹⁷ In contrast, Probe et al¹⁸ showed no statistical difference with the presence or absence of night splints in their treatment protocols.

Physiotherapy

This can have two objectives, pain relief and stretching. Stretching would eventually result in a considerable decrease in symptoms. Stretching programmes of the foot muscles and fascia have been shown to result in a considerable reduction in symptoms.^{19, 20} Pain relief is usually brought about by iontophoresis. This is the use of electrical impulses to drive topical corticosteroids or NSAID's into the deep soft-tissue structures. This treatment modality usually results in significant reduction in pain in the first two weeks of treatment²¹ however, randomized controlled studies are limited.⁵

Physiotherapists also have a role in exercise prescription. This strengthens the major muscles in the lower leg and stretching of the soft-tissue structures in the feet.¹⁴

Corticosteroid infiltration

This is given for its anti-inflammatory properties. It can be given very early on in the course of the problem and repeated on one or two occasions. Although being quite painful, it usually results in rapid relief of symptoms and has positive long-term effects.²² It must be kept in mind however that the infiltration is not curative and should be prescribed in combination with other treatment options. There exists the risk of fat pad atrophy or even rupture of the plantar fascia.²³ Paradoxically, symptoms are actually relieved by rupture, as now the fascia cannot

contract. However, this may result in long-term sequelae e.g. swelling and longitudinal arch strain that would be difficult to resolve.²³

Extracorporeal shockwave therapy (ESWT)

This is a newer form of treatment and uses extracorporeal lithotripsy to reduce the contraction of the plantar fascia. There is no clear consensus as yet about the usefulness of this kind of treatment. Some studies show that it is an effective way to treat plantar fasciitis²⁴⁻²⁶ with a reduction in plantar thickness. Hammer et al, in their various studies reported a reduction in pain in 63-90% of patients.^{25, 26}

In contrast, other studies have concluded that this type of treatment is ineffective.^{27, 28}

Further research is needed to develop evidence based recommendations for the use of ESWT in plantar fasciitis.²⁷

Surgery

This is only needed in about 10% of patients suffering from plantar fasciitis.²⁹ Surgical procedures include open or endoscopic plantar fasciotomy. Heel spur resection was previously popular, but general outcome was poor. Even with fasciotomies, results are sometimes described as moderately satisfying. Thus it is recommended that only patients who fail to respond to non-operative treatment be considered for surgical intervention.³⁰

Conclusion

Overall, treatment for plantar fasciitis is notoriously associated with short-term success and long-term failure. This is because it is relatively easy to reduce the acute inflammatory process and relieve the plantar fascia contraction. However, unless the underlying anatomical and / or biomechanical factors are addressed, symptoms are bound to recur.

References

1. Foot pain: a general description of the causes. <http://www.docpods.com/footpain.htm> (accessed on August 16th, 2005).
2. Gorter K, de Poel S, de Melker R, Kuyvenhoven M. Variation in diagnosis and management of common foot problems by GPs. *Fam Pract.* 2001; 18(6):569-73.
3. European Commission: Referral guidelines for imaging (2001). Office for official publications of the European Commission, Luxembourg.
4. Glazer JL, Brukner P. Plantar fasciitis. *Phys Sportsmed* 2004; 32(11)
5. Crawford F, Thomson C. Interventions for treating plantar heel pain (Cochrane Review 2004). <http://www.update-software.com/abstracts/AB00416.htm> (accessed on July 24th, 2005).
6. Filippou DK, Kalliakmanis A, Triga A, Rizos S, Grigoriadis E, Shipkov CD. Sport related plantar fasciitis. Current diagnostic and therapeutic advances. *Folia Med (Plovdiv)* 2004;46(3):56-60.
7. Singh D, Angel J, Bentley G, Trevino SG. Fortnightly review. Plantar fasciitis. *BMJ* 1997; 315(7101):172-5.
8. Furey JG. Plantar fasciitis. The painful heel syndrome. *J Bone Joint Surg Am* 1975; 57(5):672-3.

9. Tanz SS. Heel pain. *Clin Orthop Relat Res*. 1963;28:169-78.
10. Wolgin M, Cook C, Graham C, Mauldin D. Conservative treatment of plantar heel pain: long-term follow-up. *Foot Ankle Int* 1994 Mar;15(3):97-102.
11. Young CC, Rutherford DS, Niedfeldt NW. Treatment of plantar fasciitis. *Am Fam Physician* 2001; 63(3): 467-74,477-8.
12. Ozdemir H, Yimaz E, Murat A, Karakurt L, Poyraz AK, Ogur E. Sonographic evaluation of plantar fasciitis and relation to body mass index. *Eur J Radiol* 2005; 54(3):443-7.
13. Cardinal E, Chhem RK, Beauregard CG, Aubin B, Pelletier M. Plantar fasciitis: Sonographic evaluation. *Radiology* 1996; 210(1):257-9.
14. Shea M, Fields KB. Plantar fasciitis. *Phys Sportsmed* 2002; 30(7).
15. Lynch DM, Goforth WP, Martin JE, Odom RD, Preece CK, Kotter MW. Conservative treatment of plantar fasciitis. A prospective study. *J Am Podiatr Med Assoc* 1998; 88(8):375-80.
16. Pfeffer G, Bacchetti P, Deland J et al. Comparison of custom and prefabricated orthoses in the initial treatment of proximal plantar fasciitis. *Foot Ankle Int* 1999; 20(4):214-21.
17. Berlet GC, Anderson RB, Davis H, Kiebzak GM. A prospective trial of night splinting in the treatment of recalcitrant plantar fasciitis: the Ankle Dorsiflexion Dynasplint. *Orthopedics* 2002; 25(11):1273-5.
18. Probe RA, Baca M, Adams R, Preece C. Night splint treatment for plantar fasciitis. A prospective randomized study. *Clin Orthop Relat Res* 1999; (368):190-5.
19. Young B, Walker MJ, Strunce J, Boyles R. A combined treatment approach emphasizing impairment-based manual physical therapy for plantar heel pain: a case series. *J Orthop Sports Phys Ther* 2004; 31(11):725-33.
20. DiGiovanniBF, NawoczenskiDA, Lintal ME, Moore EA, Murray JC, Widing GE, Baumhauer JF. Tissue-specific plantar fascia-stretching enhances outcomes in patients with chronic heel pain. A prospective randomized study. *J Bone Joint Surg Am* 2003; 85-A(7):1270-7.
21. Gudeman SD, Eisele SA, Heidt RS Jr, Colosimo AJ, Stroupe AL. Treatment of plantar fasciitis by iontophoresis of 0.4% dexamethasone. A randomized, double-blind, placebo-controlled study. *Am J Sports Med* 1997; 25(3):312-6.
22. Genc H, Saracoglu M, Nacir B, Erdem HR, Kacar M. Long-term ultrasonographic follow-up of plantar fasciitis patients treated with steroid injection. *Joint Bone Spine* 2005; 72(1):61-5.
23. Acevedo JI, Beskin JL. Complications of plantar fascia rupture associated with corticosteroid injection. *Foot Ankle Int* 1998; 19(2):91-7.
24. Hyer CF, Vancourt R, Block A. Evaluation of ultrasound-guided shockwave extracorporeal shock wave therapy (ESWT) in the treatment of chronic plantar fasciitis. *J Foot Ankle Surg* 2005; 44(2):137-43.
25. Hammer DS, Rupp S, Kreutz A, Pape D, Kohn D, Seil R. Extracorporeal shockwave therapy (ESWT) in patients with chronic proximal plantar fasciitis. *Foot Ankle Int* 2002; 23(4):309-13.
26. Hammer DS, Adam F, Kreutz A, Kohn D, Seil R. Extracorporeal shockwave therapy (ESWT) in patients with chronic proximal plantar fasciitis: a 2-year follow-up. *Foot Ankle Int* 2003; 24(11):823-8.
27. Speed CA, Nichols D, Wies J, Humphreys H, Richards C, Burnet S, Hazleman BL. Extracorporeal shockwave therapy for plantar fasciitis. A double blind randomized controlled trial. *J Orthop Res* 2003; 21(5):937-40.
28. Haake M, Buch M, Schoellner C, et al. Extracorporeal shockwave therapy for plantar fasciitis: a randomised controlled multicentre trial. *BMJ* 2003; 27(7406):75.
29. Davis PF, Severud E, Baxter DE. Painful heel syndrome: results of nonoperative treatment. *Foot Ankle Int* 1994; 15(10):531-5.
30. Davies MS, Weiss GA, Saxby TS. Plantar fasciitis: how successful is surgical intervention? *Foot Ankle Int* 1999; 20(12):803-7.

Have you ever felt frustrated when you couldn't communicate with a patient?

Do you have any books which are just taking up precious space?



For the past 18 months, MMSA has been teaching English to refugees at the Hal Far open centre in an attempt to stop your heart sinking when you are faced with such a patient.

We now intend to branch out to Lyster Barracks, a detention centre. People in detention are bored and for this reason MMSA would like collect books to start a library for these people. Books in English, French and Arabic would be much appreciated.

Contact Pamela Miceli
**National Officer on Human Rights
 and Peace Malta Medical Students' Association**

Tel/Fax: (+356) 2595 1899

Email: scorp@mmsa.org.mt

www.mmsa.org.mt