

## Clinical Update

# Radiology

Pierre Vassallo

## Introduction

Radiology is the fastest developing field of medicine and these unprecedented advances have been mainly due to improving computer technology.

Digital imaging is a technology whereby images are acquired in a computer format, so that they can be easily stored and recalled for display on any computer workstation. Digital image acquisition has been used in ultrasound, computed tomography (CT) and magnetic resonance imaging (MRI) from the start. The use of digital imaging in conventional X-rays, known as Computed Radiography, has only recently become possible. Supercomputers now provide the speed required to rapidly process digital image data, while terabyte level storage media allow digital archiving of both radiological images and data.

Ultrasound, CT and MRI have also improved immensely as a result of faster computing, which allows shorter exam times, higher image resolution with improved quality and new exam techniques including large field and realtime imaging, non-invasive angiography and dynamic motion studies. Other recent advances in radiology include new contrast agents, Positron Emission Tomography (PET) scanning and novel interventional techniques.

## Computed radiography

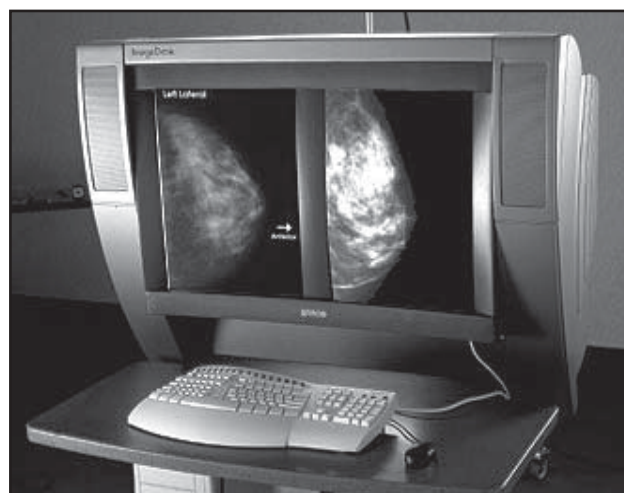Computed radiography is a new way of obtaining radiographs, whereby images are directly or indirectly acquired in digital format and displayed on a computer workstation. These images can be analysed on the computer terminal and stored on digital media such as a hard drive, optical drive or CD/DVD disk. These images may also be transmitted to other computers via a network or the Internet to allow viewing in another medical facility and distance consultation. This technology minimises the risk of film loss and allows image viewing at multiple locations simultaneously immediately after completion of the radiological exam. In addition, previous exams are rapidly accessible for comparison without the need for transporting heavy film folders. Also such images are not prone to degradation in quality.

Digital radiographs may be obtained either indirectly or directly. Indirect X-ray acquisition involves the use of phosphor plates, which replace normal film within an X-ray cassette. Exposure of the phosphor plate to X-rays results in luminescence of the phosphor particles within it. The plates are then scanned using a special laser scanner and the acquired image displayed on a computer monitor. Alternatively, X-ray cassettes may be wholly replaced by a special detector, known as a flat panel detector, which *directly* converts the incident X-ray beam into a digital image (Figure 1). Direct digital radiography is only practical within an X-ray department using fixed radiographic equipment, while indirect radiography is well suited outside an X-ray department to obtain portable X-rays on the wards and in an intensive therapy unit.

Computed radiography is slowly replacing standard film radiography particularly in large hospitals and in order to allow rapid transmission of radiographs to wards, operating theaters and outpatient departments. However, since relatively few sites are equipped with such computer networks and digital X-ray equipment, most radiology work is still done using conventional film technology.

## Spiral CT

The clinical implementation of spiral CT technology has been a major milestone in radiology particularly for body imaging and CT angiography.



**Figure 1:** Digital Mammography Workstation: direct reporting is now possible at a computer console as shown in the diagram.

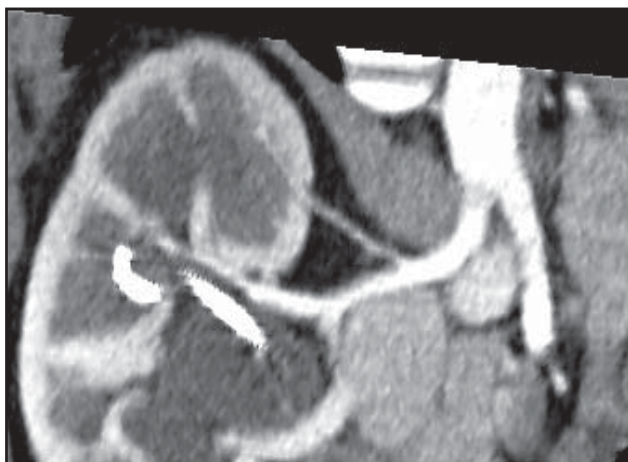**Pierre Vassallo** MD, PhD

Department of Radiology, St Luke's Hospital Guardamangia, Malta  
Email: [pvassallo@mic.com.mt](mailto:pvassallo@mic.com.mt)

Previous conventional CT scanners obtained one slice at a time during breath holding. In the intervening (inter-slice) period, the patient was allowed to breathe and the patient table was moved to a new position to obtain the next slice. This technique had three major drawbacks. Firstly, misregistration of slices occurred due to differences in depth of inspiration between the slices so that significant portions of anatomy were not included on the scan. Secondly, loss of contrast density occurred on intravenous contrast enhanced studies due to long exam times. Thirdly, the prolonged exam times resulted in increased discomfort, especially to seriously ill patients as well as reduced throughput.

Spiral CT technology is based on simultaneous scanning and table movement during a single breath hold. There is therefore no inter-slice time period, scanning is performed continuously so that the whole chest can be scanned within a period of 25 seconds. Since all slices are obtained within the same breath hold, no misregistration is encountered and scans are obtained within the time envelope of maximal intravenous contrast enhancement. Due to shorter exam times, patient throughput is also improved. With this faster scanning technique, one now routinely obtains thinner slices than were previously possible providing more detail in a shorter scan time. In fact, spiral CT does not obtain stacks of single slices, but a volume scan or continuous block of data, which can be re-sliced in thinner sections and in any plane. Volume scanning also allows 3D image reconstruction that is needed for orthopaedic and dental surgical planning, CT angiography (Figure 2), CT bronchography and CT colonography.

A further advancement in spiral CT was the use of multislice acquisition, with scanners now routinely obtaining 8 to 16 slices simultaneously: the latest multislice scanner obtains 64 slices simultaneously. A combination of multislice and spiral CT technology allows highest image resolution within time frames short enough to catch the phase of maximal contrast enhancement required for angiography.



**Figure 2:** *Spiral CT Renal Artery Angiogram: Non-invasive depiction of the renal arteries was achieved with only a peripheral intravenous injection of contrast material.*

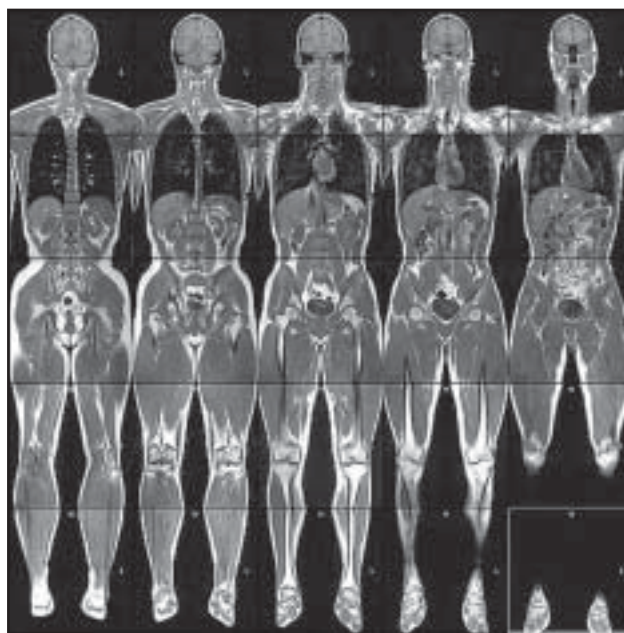
## New MRI techniques

One of the main drawbacks of MR imaging is long scanning times. However, with the development of faster computers, scan time has been reduced. New image acquisition techniques have also been developed using both hardware and software upgrades, which markedly reduce scanning time and allow higher image quality.

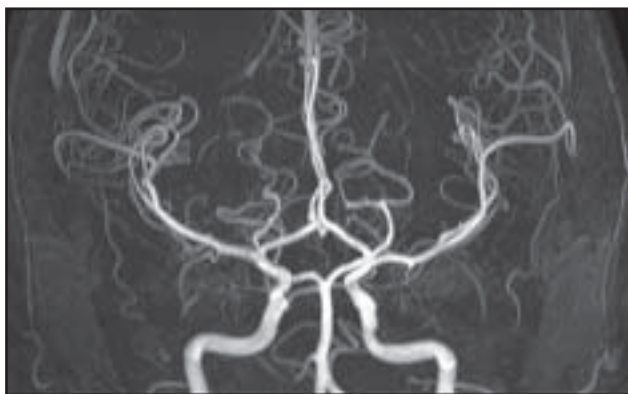
One of the latest techniques presently still under evaluation is whole-body MRI. This technology obtains full-length slices of the whole body in any plane (Figure 3) and it is being proposed as a method for cancer screening. A more promising field for whole-body MRI is staging of known cancer particularly the detection of distant metastases and tumor recurrence.<sup>1</sup> NCI and NIH sponsored diagnostic trials are presently underway aiming at the assessment of the effectiveness of whole-body MRI in detecting distant metastases in patients who have solid tumors or lymphoma.<sup>2</sup> Whole-body MRI is also showing promise as a replacement for radionuclide bone scanning for the detection of bone disease.<sup>3</sup>

MR angiography has established itself as a non-invasive test for detecting large vessel disease (Figure 4); it can depict all arteries from the intracranial level down to the lower limbs. Small vessel disease and very early ischaemia of the brain can be detected by MR perfusion and diffusion imaging.

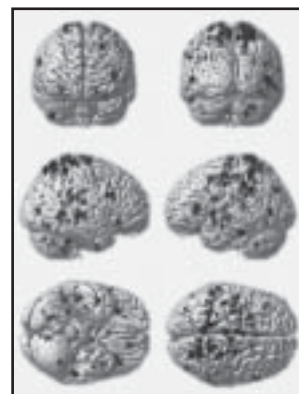
Sub-second MR scans has been achieved both through the use of fast computing and a technology known as Echoplanar Imaging. These techniques are fast enough to allow MR fluoroscopy and realtime interventional procedures. Functional MRI is yet another field made possible by fast scanning protocols; this technique enables distinction of functioning neurons in the brain and allows accurate brain mapping, which is useful for surgical planning (Figure 5).



**Figure 3:** *Whole Body MRI: This technique displays all the organs of the body in excellent detail and may be the method of the future for detecting and staging cancer.*



**Figure 4:** *MR Cerebral Angiogram: This highly detailed demonstration of the intracranial blood vessels was performed without any injection of contrast material.*



**Figure 5:** *Functional MRI: Zones of neuronal activity are depicted in realtime and provide an accurate technique for brain mapping.*

## PET scanning

Positron Emission Tomography (PET) is a technique used in nuclear medicine, whereby normal metabolites are tagged with radiation emitting agents and their distribution within the body can be used to detect disease activity. The most common agent used is fluorodeoxyglucose (FDG). Radiolabelling of fluorine is achieved by bombarding the atoms with a beam of hydrogen ions in a cyclotron; this results in fluorine atoms containing an excess of protons that are unstable and will release a positive electron ( $\beta^+$ , or positron) to achieve stability. This radioactive fluorine is then bound to glucose, which is the main metabolite in the human body. Hence radiolabeled glucose when injected intravenously will accumulate at sites of increased metabolic activity such as within the heart, active portions of the brain and tumors anywhere in the body. These radiolabeled metabolites have a very short emitting half-life and must be produced within a short time before the scan is performed. Brain PET-FDG has been available for about 15 years, but large-bore whole-body PET scanners, which are necessary for cardiac and tumor scanning have only become accessible in the last decade with very few installations due to their high cost.

In cardiology, PET-FDG is most useful in mapping myocardial perfusion, and will detect resting and stress induced ischaemia as well as myocardial viability (Figure 6). In oncology, PET-FDG provides the ultimate in sensitivity for detecting primary tumors and metastases (Figure 7), with specificity being limited, as any tissue with a high metabolic turnover including healing tissue may mimic residual tumor. There is however, no doubt that PET-FDG is extremely valuable in cancer staging and the only problem is its limited availability. Whole body PET-FDG has recently been promoted as a cancer-screening tool on a similar basis as whole body MRI: the value of PET-FDG in this field has yet to be evaluated.

## Tumor-specific contrast agents

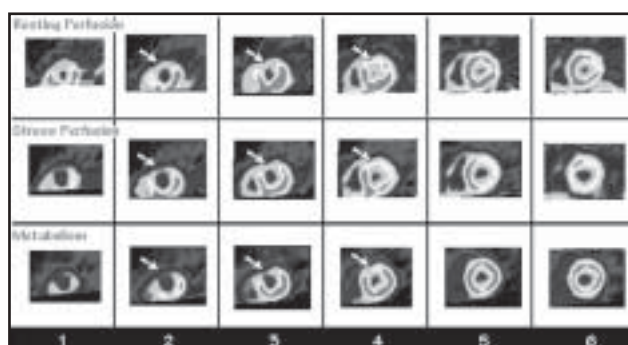
Tumor-specific contrast agents are pharmaceuticals that are targeted to tumors, either specifically or nonspecifically. Monoclonal antibodies are targeted to specific tumors such as adenocarcinoma of the colon. Metalloporphyrins exhibit affinity for many tumor types including carcinoma, sarcoma, neuroblastoma, melanoma and lymphoma.

Monoclonal antibodies (McAb) are used successfully in

nuclear medicine for localization of tumors but attempts at extending this use to MRI with paramagnetic gadolinium-DTPA labeled antibodies was unsuccessful because MRI is not sensitive enough to detect the small amounts of contrast enhancement involved. However, superparamagnetic particles (small iron oxide particles <20nm) may be attached to McAb, which impart a 1000 fold higher contrast than gadolinium.

ProstaScint is a monoclonal antibody scanning technique that has implications in the staging of patients newly diagnosed with prostatic cancer as well as use in evaluating patients believed to have recurrent disease.<sup>4</sup> This monoclonal antibody, or MoAb, reacts with prostate cancer, benign prostatic hypertrophy and to a lesser extent, normal prostate tissue. The MoAb complex is an Indium 111 labeled conjugate of the murine MoAb 7E11-C5.3. This antibody appears to recognize a prostate specific membrane glycoprotein that is chiefly expressed by prostatic epithelial cells, both benign and malignant, and whose DNA coding sequence has partial homology to that of the human transferrin receptor. ProstaScint scanning, therefore, involves an intact IgG1 immunoconjugate reactive with prostate specific membrane antigen (PSMA). Patients having a ProstaScint scan are given an IV injection of 0.5 mg of ProstaScint labeled with approximately 5mCi of 111-indium chloride. Scintigraphy is then performed 4-6 days later with cross-sectional images (SPECT – Single Photon Emission Computed Tomography) taken of the pelvis and abdomen (Figure 8). Although ProstaScint scans are limited for distinction of prostatic cancer from benign hypertrophy, they are extremely useful for detecting distant metastases particularly in lymph nodes. Arcitumomab (CEA-Scan) is a murine monoclonal Fab' fragment, generated from IMM-4 directed against the CEA surface antigen found on colorectal carcinomas. The Tc-99m tag on Arcitumomab can be detected on standard planar scintigrams and are better anatomically located on cross-sectional SPECT scans. During surgery the radioactivity in lymph glands regional to the tumors was measured using a scintillation probe intraoperatively and compared to the much lower activity in healthy nodes.<sup>5</sup> Anti-CEA-scintigraphy turned out to be very reliable in detecting primary and recurrent colorectal cancer, with an overall accuracy of more than 90%.

Porphyrin-based compounds have necrosis avid properties, and in animal models of myocardial infarction, they can depict



**Figure 6:** Myocardial PET-FDG: Arrows indicated left anterior descending territorial ischaemia accentuated during stress with diminished metabolic function, the latter indicating potentially viable myocardium.

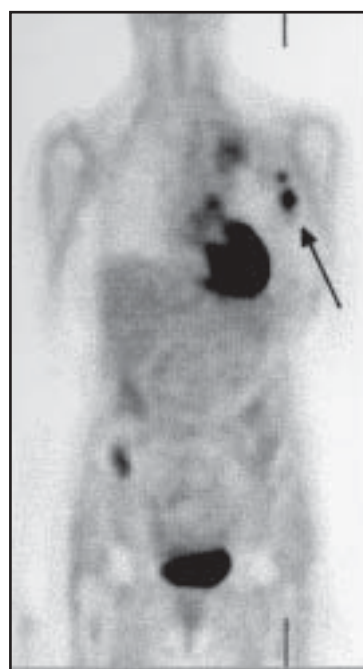the extent of necrosis as defined by histopathology.<sup>6</sup> Porphyrins also occur naturally in plants and animals and all porphyrin molecules feature an aromatic macrocycle ring with a central binding site. This site accommodates transition metals (such as gadolinium), which are held in place by inward-facing nitrogen atoms. Porphyrins are also used in photodynamic therapy of tumors. Their selective retention in tumors has led recently to their study as a MRI contrast media. They contain five nitrogen atoms in the central chelating core and this allows them to form complexes with large trivalent lanthanide metals, which have useful cancer therapy properties. Gd-DTPA mesoporphyrin (generic name: gadophrin) is a substance under development (Schering AG) as a positive enhancing myocardium- and necrosis- targeted MRI contrast agent.

## Interventional radiology

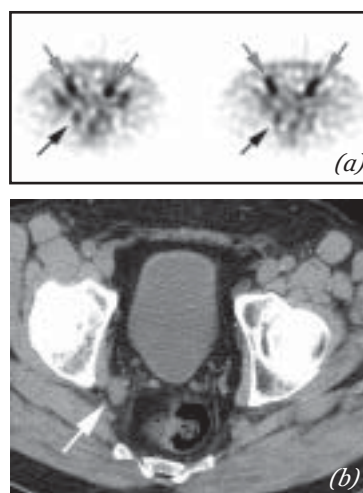
The field of interventional radiology has greatly expanded through the use of new devices, which are constantly being developed. From basic angioplasty using a catheter-mounted balloon, a large variety of stents have been developed. These range from stents for the smallest cerebral and coronary arteries to those fitting the carotid arteries and the whole aorta and its bifurcation. The aim of these interventional techniques is to minimize the morbidity and mortality of surgery. Since restenoses are common with stents (up to 35%), more recently developed drug-eluting stents (DES) are currently under investigation.<sup>7</sup> These stents are impregnated with medication (immunosuppressant and chemotherapeutic agents), which has been proved to reduce rate of restenosis. Initial studies have shown that restenosis rates fall into the low single digits with DES.

## Conclusion

This review of new developments is by no means comprehensive and this paper serves to highlight advances being made in the field of radiology. The main driving force behind these advances has been the increasing demand by the medical community to make early accurate diagnoses using non-invasive tests and administer effective minimally-invasive treatment.



**Figure 7:** Breast Cancer PET-FDG: Uptake of FDG is noted in the left axillary lymph nodes, the left upper mediastinum and the right iliac bone confirming multifocal metastatic disease. The myocardial uptake is normal.



**Figure 8:** ProstaScint scan (a) shows right internal iliac lymphadenopathy (black arrow) which correlates with the finding on CT scan (b), as well as bilateral external iliac lymphadenopathy (light grey arrows) not seen on CT scan.

## References

1. Whole body MRI: Study ID Numbers† CDR0000339811; ACRIN-6660 NLM Identifier NCT00072488
2. Engelhard K, Hollenbach HP, Wohlfart K, von Imhoff E, Fellner FA. Comparison of whole-body MRI with automatic moving table technique and bone scintigraphy for screening for bone metastases in patients with breast cancer. *European Radiol*, 2004;14(1):99-105.
3. Ghanem N, Althoefer C, Hoyerle S, Ghanem-Wiesel C, Winterer J, Langer M. Whole-body MRI in detection of skeletal metastases: a comparison with skeletal scintigraphy and whole-body FDG-PET. *Cancer Imaging* 2002, Abstract pp. 15-15(1).
4. Ross JS, Sheehan CE, Fisher HA, et al. Correlation of primary tumor prostate-specific membrane antigen expression with disease recurrence in prostate cancer. *Clin Cancer Res* 2003; 9: 6357-6362
5. Lechner P, Lind P, Snyder M, Haushofer H. Probe-guided surgery for colorectal cancer. *Cancer Research* 2000; 157: 273-280
6. Ni Y, Cresens E, Adriaens P, et al. Exploring Multifunctional Features of Necrosis Avid Contrast Agents. *Acad Radiol* 2002; 9(suppl 2):S488-S490
7. Panescu D. Drug eluting stents. *IEEE Eng Med Biol Mag* 2004; 23(2):21-3.