

Case Report

Extensive Pulmonary Embolism in Late Pregnancy Associated with Anticardiolipin Antibodies

David P Galea, Mark Formosa, Mark P Brincat,
Louis Buhagiar, Anthony Samuel, Goce Kunovski

Introduction

The leading cause of morbidity and mortality during pregnancy and the puerperium is venous thromboembolism. Though uncommon, the risk is five times higher in a pregnant woman than in a non-pregnant woman of similar age.^{1,2}

In pregnancy, all three underlying factors for venous thrombosis are present: hypercoagulability, venous stasis and vascular damage (Virchow's triad). Of these, the most constant predisposing factor is increasing venous stasis due to the pressure of the gravid uterus on the pelvic vasculature. In addition the presence of a thrombophilia, (congenital or acquired) will increase this risk substantially.

During pregnancy hypercoagulability is a physiological preparation for the haemostatic challenge of delivery. There are increases in procoagulant factors, such as von Willebrand factor, factor VIII, factor V, and fibrinogen together with an acquired resistance to activated protein C and a reduction in protein S. Increases in plasminogen activator inhibitors impair fibrinolysis. The third factor of this triad, vascular damage, is a possible complication of trophoblastic invasion of the uterine spiral arterioles or of delivery.^{1,3}

David P Galea MD

Dept of Obstetrics and Gynaecology,
St Luke's Hospital, Gwardamangia, Malta
Email: dpgalea@yahoo.com

Mr Mark Formosa MD, FRCOG *

Dept of Obstetrics and Gynaecology,
St Luke's Hospital, Gwardamangia, Malta
Email: markf@maltanet.net

Mark P Brincat PhD, FRCOG

Dept of Obstetrics and Gynaecology,
St Luke's Hospital, Gwardamangia, Malta
Email: mpbrincat@keyworld.com

Louis Buhagiar MD, FRCP

Dept of Medicine, St Luke's Hospital,
Gwardamangia, Malta.
Email: louis.buhagiar@govt.mt

Anthony Samuel MD, Dspec MN (Milan)

Dept of Nuclear Medicine, St Luke's Hospital,
Gwardamangia, Malta.
Email: anthony.smanuel@govt.mt

Goce Kunovski MD, Spec in Radiology

Dept of Radiology, St Luke's Hospital,
Gwardamangia, Malta.
Email: goce.kunovski@govt.mt

* corresponding author

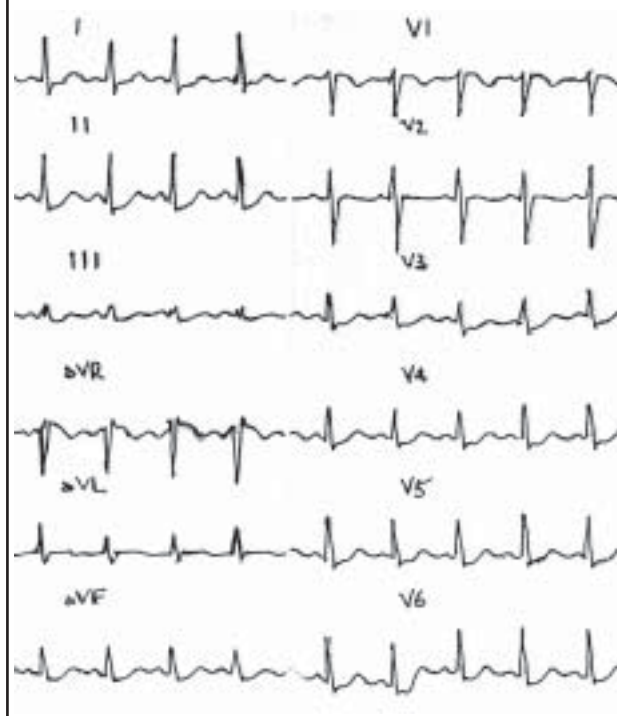
Case Report

A 28 year-old female in her second pregnancy, having had a previous normal full term pregnancy, presented at 34 weeks gestation with a 7-day history of shortness of breath, initially on exertion but on presentation also at rest. The patient had also been complaining of pleuritic chest pain radiating to her back. The patient was admitted to the A&E Department. Arterial blood gases confirmed arterial hypoxaemia and hypocapnia, and an ECG (Figure 1) sustained the possibility of pulmonary thromboembolism.

A diagnosis of pulmonary embolism was made. The patient was transferred to the Coronary Care Unit and fully heparinised (unfractionated heparin), maintaining her APTT between 80 - 100 sec. Doppler investigation of both lower limbs did not reveal any venous thrombosis.

A pulmonary perfusion scan was carried out to confirm diagnosis and assess the severity of the pulmonary embolism. A low dose of tracer was used due to the pregnancy (37 mmol). There was almost absent tracer uptake in the left lung field,

Figure 1: Electrocardiogram on admission showing a sinus tachycardia (100/min), shortened R-R interval and a deep S wave in lead I



absent uptake in the right upper lobe, and absent uptake in the lateral basal segment of the right lower lobe. Extensive bilateral pulmonary embolism was confirmed (Figure 2).

Because of the severity of the embolus, respiratory function was not considered adequate for a normal vaginal delivery and a plan was made for an elective caesarean section at 36 weeks. Since heparin would have to be stopped at least 6 hours prior to surgery, a temporary vena-cava filter was inserted. The interventional radiologist used a Nitinol® temporary filter taking into consideration the age of the patient.

The pulmonary-perfusion scan was repeated prior to the caesarean section and this showed a mild improvement, although generalised impairment was still present. Anticardiolipin antibody levels (IgG) were found to be five times the normal value. This was highly significant and a diagnosis of antiphospholipid antibody syndrome was made.

At 36 weeks gestation an elective lower segment caesarean section was performed in a theatre with facilities for cardiopulmonary bypass at hand.

The patient was again fully heparinised after the caesarean section (Heparin 6500 units/6 hours). Her general condition was stable, and the patient was transferred to the High Dependency Unit.

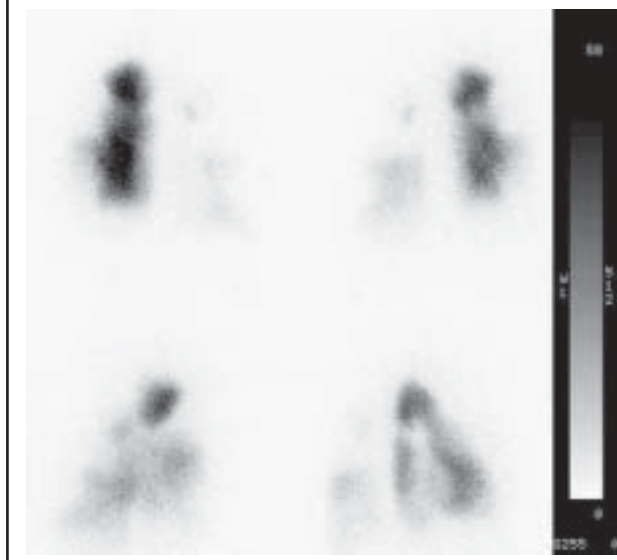
The temporary filter was removed on 4th December 2001, the heparin was again stopped 6 hours before. During the procedure the extent of the inferior vena cava obstruction was assessed. Extensive thrombosis involving the whole of the lower part of the inferior vena cava prompted the decision to insert a permanent Nitinol® vena cava filter. The patient was warfarinised from the next day and she was discharged a week later on Warfarin 8mg daily (INR 2-3).

Discussion

Fatal thromboembolism is the leading cause of maternal mortality in the United Kingdom² and in most countries in Europe. The risks are increased considerably in pregnancy due to the risk factors outlined above, especially in the presence of a thrombophilia (estimated to be increased six-fold in Factor V Leiden mutations). In pregnancy most cases of deep vein thrombosis are iliofemoral rather than calf vein thrombosis (72% vs 9%),^{3,4} and iliofemoral deep vein thrombosis is more likely than calf vein thrombosis to lead to pulmonary thromboembolism.³

Diagnosis depends on a high index of suspicion and immediate appropriate investigation and treatment. The primary diagnostic tool for the diagnosis of pulmonary embolism in both pregnant and non-pregnant patients is the ventilation-perfusion scan.^{3,5} The reluctance to perform radiological studies during pregnancy because of concern about the effects of radiation on fetal development is unjustified, as the estimated exposure of the fetus to radiation during these investigations is small, and has not been associated with a significant risk of fetal injury in studies.^{3,6} In this case the clinical condition of the patient did not correlate with the extent of the

Figure 2: Pulmonary perfusion scintigraphy reveals almost complete absence of perfusion of the left lung with further segmental defects of uptake in the right lung. Scan findings are in keeping with extensive pulmonary embolism



pulmonary compromise; only after the ventilation-perfusion scan did the extent of the embolism become clear.

Continuous, dose-adjusted, intravenous unfractionated heparin was used to anticoagulate this patient. However, most studies indicate that low-molecular-weight heparin is as effective and safe as intravenous heparin for the treatment of acute symptomatic pulmonary embolism. A number of advantages such as a simplified therapeutic regimen and increased bioavailability are evidenced from these studies.^{5,7-10} The use of warfarin in pregnancy is generally contraindicated. However it has been advocated for patients with recurrent pregnancy loss and thromboembolism associated with the presence of antiphospholipid antibodies.^{11,12} Anticoagulation therapy should be continued postpartum with heparin and warfarin; heparin can be discontinued once the level of anticoagulation with warfarin is adequate.

The use of thrombolytic agents during pregnancy has been limited to life-threatening situations because of the risk of maternal bleeding and due to the lack of knowledge of the risk of placental abruption and fetal death due to these drugs.^{3,6,13}

Although filters in the inferior vena cava have been used safely and effectively in pregnant women¹⁴, carefully designed, prospective, randomised studies are needed to clearly establish the safety and utility of vena cava filtration devices. In 1998, Decousus et al¹⁰ published the first and only randomised study of vena cava filters in the prevention of pulmonary embolism. They randomised 400 patients with proximal deep vein thrombosis who were at risk for pulmonary embolism to receive a vena cava filter or no filter and enoxaparin or unfractionated heparin. Four different types of vena cava filters were used. Ventilation-perfusion scans were performed at

baseline and after 8 to 12 days of anticoagulation. Vena cava filters were associated with a significant decrease in the incidence of pulmonary embolism compared with anticoagulation alone (1.1% versus 4.8%, $P=0.03$) at 8 to 12 days after follow-up. After two years, however, this difference was not longer statistically significant although the trend still favoured vena cava filters (3.4% versus 6.3%, $P=0.16$). Symptomatic pulmonary embolism occurred at a similar frequency in both groups after 3 months. Fatal emboli were more common in patients treated solely with anticoagulation (0.5% versus 2.5%).¹⁰

In the light of these data, one can conclude that vena cava filters in combination with standard anticoagulation appear to offer significantly more protection from pulmonary embolism than anticoagulation alone. This additional protection was also noted in other studies.^{15,16} However it appears to be short-lived and does not decrease overall mortality. In addition, vena cava filters are associated with a higher incidence of recurrent deep venous thrombosis over 2 years follow-up.¹⁰

Supra-renal placement is recommended in pregnant women to avoid potential contact between the gravid uterus and the filter. This position also provides additional protection against thromboembolism from pelvic or ovarian veins.¹⁵ At follow-up it is important to ascertain an impairment of renal function due to the potential obstruction of the suprarenal vena cava. Other potential complications with vena cava filtration devices are insertion-site thrombosis, penetration of the inferior vena cava wall by filter prongs, filter metal fatigue, filter migration and tilting.^{15,17}

Many investigations recommend routine anticoagulation after vena cava filter placement.¹⁰ However little data are available to support the utility of this practice. Several case series have attempted to address this issue. Although none were able to demonstrate any benefit of anticoagulation, the retrospective, unrandomised nature of the studies as well as the limited duration and intensity of anticoagulation used in some of the studies suggest that randomised comparisons will be necessary to resolve the issue.¹⁷

50% of thromboembolic events in pregnancy and the puerperium occur in women with an identifiable thrombophilia. However, these thrombophilias also occur in 15% of a Western population. The thrombophilias comprise a rapidly expanding, heterogenous group of largely inherited deficiencies of naturally occurring anticoagulants. Testing must take into account the anticoagulation treatment being given to the patient. A patient on warfarin can be screened for antithrombin III deficiency, but not for protein C and S deficiencies. The opposite holds true for patients on unfractionated or low molecular weight heparin. Molecular analysis (factor II and V) and anticardiolipin antibodies results are not affected by anticoagulation. Acquired thrombophilias due to nephritic syndrome, malignancy and polycythaemia are rare in pregnancy.⁶

Conclusions

Acute severe pulmonary venous thromboembolism is an extremely dangerous complication of what should be a normal physiological state. The possibility of a thrombophilia must always be considered in a pregnant woman if potentially fatal complications are to be avoided. Any chance of survival must rest on a high index of suspicion, prompt appropriate investigation and aggressive management.

Use of the IVC filter is at present limited but may offer the protection required to ensure a successful outcome. More experience on their use is required, especially with permanent filters, but we suggest that at least a temporary filter is mandatory when the patient has been anticoagulated and delivery is approaching.

References

1. Greer IA. Thrombosis in pregnancy: maternal and fetal issues. *Lancet* 1999;353: 1258-65.
2. Department of Health, Welsh Office, Scottish Home and Health Department and Department of Health and Social Services Northern Ireland. Confidential Enquiries into Maternal Deaths in the United Kingdom 1994-1996. London: HMSO 1998.
3. Toglia MR, Weg JG. Venous thromboembolism during pregnancy. *N Engl J Med* 1996;335:108-14.
4. Ginsberg JS, Greer IA, Hirsh J. Use of antithrombotic agents during pregnancy. *Chest* 2001;119:122S-131S.
5. Simmoneau G, Sors H, Charbonnier B, et al. A comparison of low-molecular-weight heparin with unfractionated heparin for acute pulmonary embolism. *N Engl J Med* 1997;337:663-9.
6. Girling J. Thromboembolism and thrombophilia. *Curr Obstet & Gynecol* 2001;11:15-22.
7. Nelson-Piercy C, Letsky EA, de Swiet M. Low molecular weight heparin for obstetric thromboprophylaxis: experience of 69 pregnancies in 61 high risk women. *Am J Obstet Gynecol* 1996;176:1062-8.
8. Ellison J, Walker ID, Greer IA. Antenatal use of enoxaparin for prevention and treatment of thromboembolism in pregnancy. *Br J Obstet Gynecol* 2000;107:1116-21.
9. Thomson AJ, Walker ID, Greer IA. Low molecular weight heparin for the immediate management of thromboembolic disease in pregnancy. *Lancet* 1998;32:1904.
10. Decousus H, Leizorovicz A, Parent F, et al. A clinical trial of vena cava filters in the prevention of pulmonary embolism in patients with proximal deep vein thrombosis. *N Engl J Med* 1998;338:409-415.
11. Menashe Y, Ben-Baruch G, Greenspoon JS, Carp JH, Rosen DJ, Mashiach S, Many A. Successful pregnancy outcome with combination therapy in women with the antiphospholipid antibody syndrome. *J Reprod Med* 1993;38:625-529.
12. Formosa M, Brincat M. Warfarin anticoagulation in pregnancy complicated by antiphospholipid antibody syndrome and heparin allergy. *J Obstet Gynaecol* 1999;19:196.
13. Turrentine MA, Braems G, Ramirez MM. Use of thrombolytics for the treatment of thromboembolic disease during pregnancy. *Obstet Gynaecol Surv* 1995;50:534-541.
14. Aburahama AF, Bolonal JS. Management of deep vein thrombosis of the lower extremity in pregnancy: a challenging dilemma. *Am J Surg* 1999;65:164-7.
15. Greenfield LJ, Cho KJ, Proctor MC, Sobel M, Shah S, Wingo J. Late results of suprarenal Greenfield vena cava filter placement. *Arch Surg* 1992;127:969-73.
16. Narayan H, Cullimore J, Krarup K, Thurston H, Macvicar J, Bolia A. Experience with the Cardial inferior vena cava filter as prophylaxis against pulmonary embolism in pregnant women with extensive deep venous thrombosis. *Br J Obstet Gynaecol* 1992;99:637-40. [Erratum, *Br J Obstet Gynaecol* 1992;99:726]
17. Streiff MB. Vena caval filters: a comprehensive review. *Blood* 2000;95:3669-3677.