

Multiple problems in siblings with Gardner's Syndrome

Hermann Karl Borg*, Charles Swain*

ABSTRACT: The problems encountered in the diagnosis of two siblings suffering from a high penetration variant of Gardner's syndrome are presented. The importance of recognizing the extra colonic manifestations of the syndrome at an early stage and technical difficulties encountered during colonoscopy are noted. Operative procedures available to treat multiple colonic polyps in Gardner's syndrome are discussed in relation to technical problems which may be encountered in the individual case. Hopefully this presentation will highlight the importance of the setting up of a Familial Polyposis Coli Register in Malta in order to facilitate early diagnoses and treatment of the condition.

*Department of Surgery, St Luke's Hospital, Gwardamangia, Malta.

Correspondence: Mr H. K. Borg c/o ENT Department, Southend Hospital, Prittlewell Chase, Westcliff-on-Sea, Essex SS0 0RY, UK

Keywords: Gardner, colonic polyps, familial adenomatous polyposis

Introduction

Gardner first described the development of multiple tumours, including osteomata of the skull, epidermoid cysts and fibromata in patients with familial adenomatous polyposis (FAP) in 1950^{1,2}.

FAP is an autosomal dominant condition characterised by multiple colonic polyps (Figure 1) predisposing to cancer of the colon¹.

The genetic abnormality, which has been localised on chromosome 5, is common to both Gardner's syndrome and FAP and shows variable expression. It leads to a hyperproliferative mucosal abnormality throughout the gastrointestinal tract³.

The presence of one hundred or more adenomatous colorectal polyps with extra-intestinal growths is diagnostic of Gardner's syndrome. Fewer polyps or extra-intestinal growths, together with a strong family history is highly suggestive⁴.

The incidence of FAP is reported to be in the range of 1 in 6,850 to 1 in 223,790 live births⁵.

Although FAP and Gardner's syndrome have been recognised and treated locally for a number of years we have no information about their incidence in Malta.

Patients

The medical history of two siblings with Gardner's syndrome was reviewed.

Case A

A 25 year old woman presented in June 1995 with two episodes of rectal bleeding and suprapubic pain. On examination she had an indurated hypertrophic lower abdominal scar resulting from a laparotomy for colonic perforation due to an ingested needle nine years previously. There was also a pelvic mass which was shown to be a large multilocular ovarian cyst on ultrasound examination. She also had multiple fibromata



Fig.1 - Case A: multiple polyps in colectomy specimen.

in the scalp. Colonoscopy⁶ showed multiple polyps (Figure 2) throughout the colon; none of these was more than 1cm in diameter. Carcino-embryonic antigen was 273.8 U/ml (normal up to 35 U/ml).

Her past medical history includes excision of subcutaneous fibromata from the dorsal spinal region at

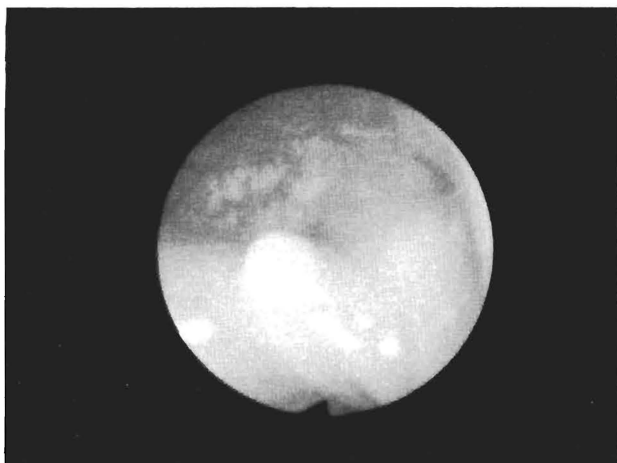


Fig.2 - Case A: colonic polyp of, as seen at colonoscopy.

the age of 12 years, and excision of osteomata of the mandible at 17 years. At the time she was also noted to have other dental abnormalities including supernumerary teeth (Figure 3). A 2.5cm lump arising from the rectus sheet had been excised in 1992. Histology showed well-organised fibrous tissue. She was considered to be at high risk of developing colonic carcinoma and was advised to undergo laparotomy for colonic ablation and excision of the large ovarian cyst. Findings at laparotomy included dense adhesions matting the whole of the small intestine into a solid mass with fibrosis/calcification and severe shortening of the mesentery.

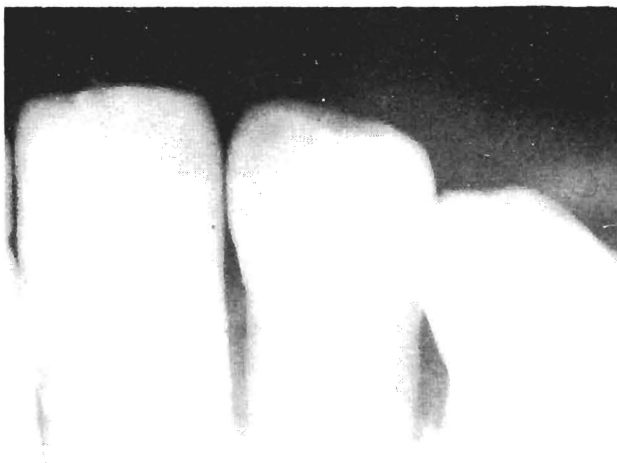

Fig.3 - Case A: supernumerary teeth.
(Archives of Prof G E Camilleri)

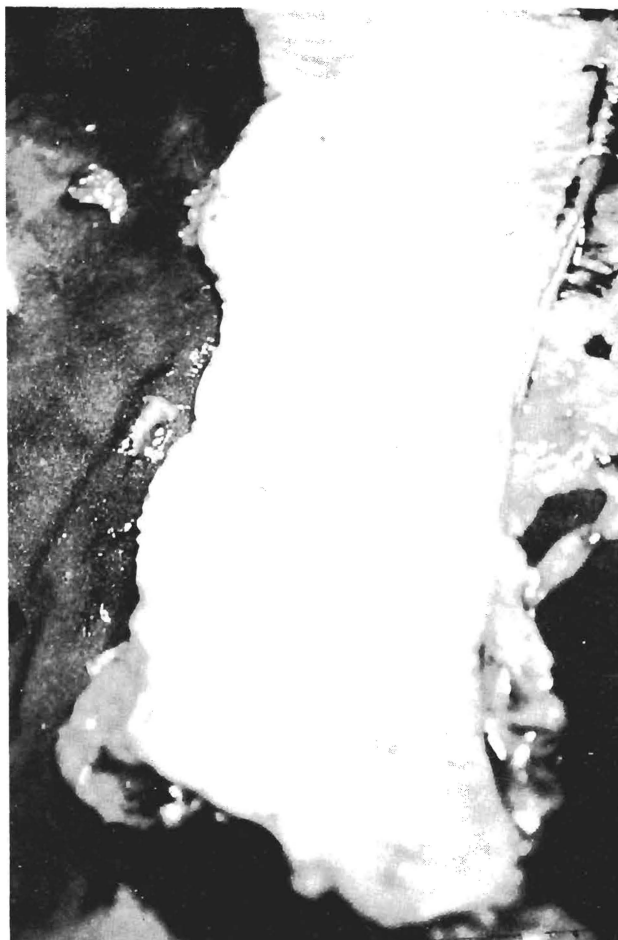

Fig.4 - Case A: multiple polyps in subtotal colectomy specimen.

There was a desmoid tumour arising from the previous laparotomy scar infiltrating all the layers of the abdominal wall. There were a large right and a small left ovarian endometriotic (chocolate) cysts.

A right salpingo-oophorectomy and excision of the left ovarian cyst was followed by a subtotal colectomy (Figure 4). It was technically impossible to construct an ileal pouch due to the severe mesenteric shortening and bowel continuity was restored with an ileo-rectal anastomosis leaving a 5cm cuff of polyp-free lower rectum.

She made an uneventful recovery following this procedure and sigmoidoscopy undertaken six months after surgery showed an intact anastomosis with a polyp-free rectal stump.

Case B

The 29 year old sister of case A, presented around the same time with a mass in the lower abdomen which on close examination was found to be a desmoid tumour arising from a Pfannenstiel incision following lower section caesarean section in 1993 and again in 1994. She also had subcutaneous fibromata over the cervicale spine. Three years previously she had undergone appendectomy and excision of a right ovarian cyst. This was followed 2 months later by exploration of the gridiron incision for a fibrotic mass within it.

At the age of 6 years she was first seen at the dental department with fibrous dysplasia of the mandible and

supernumerary teeth (Figure 5). Subsequently she underwent excision of an alveolar tumour and an osteoma of the mandible. Intravenous pyelography for non-specific abdominal pain showed an ectopic right kidney but no other abnormality.

Colonoscopy⁶ with a standard adult colonoscope failed as the rectosigmoid junction could not be negotiated, presumably due to pelvic fibrosis following repeated abdominal surgery. When the procedure was repeated with a paediatric colonoscope few polyps were noted scattered throughout the colon; none of these was larger than 0.3cm. Ophthalmoscopy showed congenital hypertrophy of the retinal pigment epithelium, another typical marker of Gardner's syndrome with two "Bear patches" of pigmentation in the lower temporal quadrant of the left fundus at the periphery

She has been advised that she will need to have colonic ablation in the near future. It is anticipated that similar technical problems to her sister's case will be met during laparotomy as the obstetrician who performed her second LSCS noted desmoid tumour infiltrating the lower abdominal wall and small bowel adherent to the uterus.

Discussion

Restorative Procto-Colectomy with an ileal pouch is today the ideal surgical procedure for patients with FAP and Gardner's syndrome^{5,7,8}. All the large bowel mucosa is removed preserving normal bowel function with avoidance of a stoma; also sexual function is less likely to be affected^{5,7,8}. It is recognised that mean stool frequency is acceptable with a small incidence of nocturnal incontinence following this procedure. "Pouchitis" is quite rare when restorative proctocolectomy is performed for FAP^{5,7,8}.

As in the case of Case A, it may not be technically possible to construct an ileal pouch due to mesenteric shortening, short bowel adhesions and intra-abdominal desmoids. Ileo-rectal anastomosis is a reasonable alternative in such cases. The inconvenience of a permanent ileostomy is avoided and there is also less risk of sexual and bladder dysfunction if radical rectal dissection has not been undertaken. Following this procedure the patient must attend for sigmoidoscopy to detect and treat polyps in the rectal stump, the incidence of carcinoma here being between 6% at 20 years and 55% at 30 years⁹. Pan proctocolectomy is the operation of choice in FAP and Gardner's syndrome only if there is cancer in the lower rectum^{5,9}.

FAP is a generalised growth disorder. The extra-colonic abnormalities are considered to be due to the variable expression of a single gene defect^{5,10}. Members of a family with FAP show remarkable similar manifestations, as seen in our two siblings who both had dental abnormalities, desmoid tumours, mesenteric fibrosis, retinal pigmentation and epidermoid cysts.

The dental surgeon¹¹ who first treated these two siblings for mandibular osteomata and supernumerary teeth had rightly suspected Gardner's syndrome as the underlying cause of these oral problems. It was, however, years later that the two girls presented with symptoms related to polyposis coli and abdominal desmoids and the serious implications of the underlying conditions were recognised. Surely a Familial Polyposis



Fig.5 - Case B: fibrous dysplasia of the mandible and supernumerary teeth.
(Archives of Prof G E Camilleri)

Coli register would help no end in the early detection and timely treatment of the condition⁹.

Treatment of these extracolonic manifestations represents a difficult clinical challenge in its own right. Desmoids have a notorious tendency to recur and repeated surgery should be avoided¹². They are resistant to radiotherapy and cytotoxic chemotherapy⁵. Treatment with Sulindac with or without Tamoxifen has recently given some encouraging results⁵. Epidermoid cysts and osteomata are usually easier to treat and do not recur once the initial surgery is complete. Epidermoid cysts are rare in children in any condition other than Gardner's syndrome and it has been recommended that these children should be screened for the condition as skin cysts may be evident before the development of colorectal polyps^{5,13}. Congenital hypertrophy of the retinal pigment epithelium requires no intervention as it does not interfere with retinal function¹⁴.

Females with Gardner's syndrome have a 20-160 fold increased risk of developing a thyroid tumour than the general population although their prognosis is similar⁵.

Gardner's syndrome requires surgery to prevent the development of colonic carcinoma and to treat its extra colonic manifestations. Laparotomy is often difficult because of intra abdominal and mesenteric desmoid formation and repeated surgery should be avoided unless absolutely necessary.

Hopefully, the prevalence of the disease in Malta will

soon be established, with the help of the FAP register which has now been set up with the co-operation of the Department of Health Information Unit. The Register should also help to detect new cases earlier than the two cases presented here.

References

1. Stedman's Medical Dictionary 1982: 1387. 24th ed Williams & Wilkins
2. Gardener EJ & FE Stephens. Cancer of the lower digestive tract in one family group. American Journal of Human Genetics 1950; 2: 41-8
3. Lipkin M, WA Blatter, EJ Gardner, et al. Classification and risk assesment of individuals with familial polyposis, Gardners Syndrome and familial non-polyposis colon cancer from [3H] thymidine labelling patterns in colonic epithelial cells. Cancer research 1984; 44: 4201-7
4. Buyse ML. Birth Defects Encyclopaedia; 983 - 985
5. Campbell WJ, RAJ Spence & TG Parks. Familial Adenomatous Polyposis; Br J Sur 1994; 81: 1722-1733
6. Caruana Galizia A. Endoscopy Department. St. Luke's Hospital, Malta. Personal communication
7. Everett W & S.G. Pollard. Restorative proctocolectomy without temporary ileostomy. Br J Sur 1990; 77: 621-622
8. Sagar PM & BA Taylor. Pelvic ileal reservoirs: the options. Br J Sur 1994; 81: 325-332
9. Rhodes M & D.M. Bradburn. Overview of screening and management of familial adenomatous polyposis . Gut 1992; 33 : 125-131
10. Rees M, SEA Leigh, JDA Delhanty & JR Jass. Chromosome 5 allele loss in familial and sporadic colorectal adenomas. Br J Cancer 1989; 59: 361-5
11. Camilleri GE. Department of Dental Surgery, St. Luke's Hospital, Malta. Personal communication
12. Simpson RD, EH Harrison & C Mayo. Mesenteric fibromatosis in familial polyposis, a variant of Gardner's syndrome. Cancer 1964; 17: 526-533
13. Leppard B & HJR Bussey. Epidermoid cysts, polyposis coli; and Gardner's syndrome. Br J Sur 1975; 62: 387-393
14. Blair NP & CL Trempe. Hypertrophy of the retinal pigment epithelium associated with Gardner's Syndrome. Am J Ophthal 1980; 90: 661-667

The copyright of this article belongs to the Editorial Board of the Malta Medical Journal. The Malta Medical Journal's rights in respect of this work are as defined by the Copyright Act (Chapter 415) of the Laws of Malta or as modified by any successive legislation.

Users may access this full-text article and can make use of the information contained in accordance with the Copyright Act provided that the author must be properly acknowledged. Further distribution or reproduction in any format is prohibited without the prior permission of the copyright holder.

This article has been reproduced with the authorization of the editor of the Malta Medical Journal (Ref. No 000001)