



UNIVERSITY OF LEEDS

This is a repository copy of *Bioavailable Trace Metals in Neurological Diseases*.

White Rose Research Online URL for this paper:

<http://eprints.whiterose.ac.uk/105987/>

Version: Accepted Version

---

**Article:**

Poujois, A, Devedjian, JC, Moreau, C et al. (4 more authors) (2016) Bioavailable Trace Metals in Neurological Diseases. *Current Treatment Options in Neurology*, 18 (10). 46. ISSN 1092-8480

<https://doi.org/10.1007/s11940-016-0426-1>

---

© Springer Science+Business Media, New York 2016. This is an author produced version of a paper published in *Current Treatment Options in Neurology*. Uploaded in accordance with the publisher's self-archiving policy. The final publication is available at Springer via <http://dx.doi.org/10.1007/s11940-016-0426-1>

**Reuse**

Items deposited in White Rose Research Online are protected by copyright, with all rights reserved unless indicated otherwise. They may be downloaded and/or printed for private study, or other acts as permitted by national copyright laws. The publisher or other rights holders may allow further reproduction and re-use of the full text version. This is indicated by the licence information on the White Rose Research Online record for the item.

**Takedown**

If you consider content in White Rose Research Online to be in breach of UK law, please notify us by emailing [eprints@whiterose.ac.uk](mailto:eprints@whiterose.ac.uk) including the URL of the record and the reason for the withdrawal request.



[eprints@whiterose.ac.uk](mailto:eprints@whiterose.ac.uk)  
<https://eprints.whiterose.ac.uk/>

# **Bioavailable Trace Metals in Neurological Diseases**

Aurélia Poujois, MD, PhD<sup>1, 2</sup>, Jean-Christophe Devedjian, PhD<sup>3, 4</sup>, Caroline Moreau, MD, PhD<sup>3, 4</sup>, David Devos, MD, PhD<sup>3, 4, 5</sup>, Pascal Chaine, MD<sup>1, 2</sup>, France Woimant, MD<sup>1, 2</sup>, James A. Duce, PhD<sup>6, 7</sup>.

<sup>1</sup> Department of Neurology, University Hospital Lariboisière, Assistance Publique-Hôpitaux de Paris, France

<sup>2</sup> French National Reference Centre for Wilson Disease, University Hospital Lariboisière, Assistance Publique-Hôpitaux de Paris, France

<sup>3</sup> INSERM U1171, Lille University, CHU Lille, France

<sup>4</sup> Department of Medical Pharmacology, Lille University, CHU Lille, France

<sup>5</sup> Department of Movement Disorders and Neurology, Lille University, CHU Lille, France

<sup>6</sup> School of Biomedical Sciences, Faculty of Biological Sciences, University of Leeds, Leeds, West Yorkshire, United Kingdom

<sup>7</sup> Oxidation Biology Unit, The Florey Institute of Neuroscience and Mental Health, The University of Melbourne, Parkville, Victoria, Australia

**Corresponding author:**

Dr Aurélia POUJOIS, aurelia.poujois@aphp.fr

National Reference Centre for Wilson's disease and Neurology Department,  
University Hospital Lariboisière, Assistance Publique-Hôpitaux de Paris, 2 rue  
Ambroise Paré. 75010 Paris, France. Phone +33 49 95 65 27

**Keywords:** copper, iron, manganese, chelation therapy, reactive species,  
neurodegeneration.

## Opinion statement

- Medical treatment in Wilson's disease includes chelators (D-Penicillamine and Trientine) or zinc salts that have to be maintained all the lifetime. This pharmacological treatment is categorized into two phases; the first being a de-coppering phase and the second a maintenance's one. The best therapeutic approach remains controversial, as only a few non-controlled trials have compared these treatments. During the initial phase, progressive increase of chelators' doses adjusted to exchangeable copper and urinary copper might help to avoid neurological deterioration. Liver transplantation is indicated in acute fulminant liver failure and decompensated cirrhosis; in cases of neurologic deterioration, it must be individually discussed. During the maintenance phase, the most important challenge is to obtain a good adherence to lifelong medical therapy.
- Neurodegenerative diseases that lead to a mislocalization of iron can be caused by a culmination of localized overload (pro-oxidant siderosis) and localized deficiency (metabolic distress). A new therapeutic concept with conservative iron chelation rescues iron-overloaded neurons by scavenging labile iron and, by delivering this chelated metal to endogenous apo-transferrin, allows iron redistribution to avoid systemic loss of iron.

## **1. Introduction**

Heavy metals, present in trace concentrations in the environment, are naturally occurring elements with a relative high density compared to water [1]. Some of them (e.g. lead, aluminium, mercury) are non-essential with high degree of toxicity for humans. When absorbed or inhaled in high doses, they usually damage specific organs such as kidneys, bone, brain and nerves (see Table 1) and may also be implicated in the pathogenesis of neurodegenerative diseases, particularly Alzheimer's or Parkinson's disease.

Other bioavailable metals (e.g. copper, iron, zinc, manganese) are essential nutrients for various biochemical and physiological human functions, and especially for brain development and metabolism. When their concentrations are out of the normal range, due to abnormal accumulation or inadequate supply from various origins (i.e. genetic or toxicity), these microelements may play a role in disease pathogenesis, especially through free radical formation.

This article will focus on the neurologic manifestations in connection with copper, iron and manganese, three of these essential nutrients that are normally utilized in biology systems due to their ease in transition of valence state.

### **Copper and Central Nervous System**

#### **1. Copper metabolism and brain pathology**

During a normal diet, the daily intake of copper is about 2-3 mg. It is absorbed by the enterocytes, stored with metallothioneins, copper-selective chaperone proteins and then exported by Cu-ATPase ATP7A to the liver via the portal vein. In hepatocytes, metallothioneins and ATPases (ATP7A and ATP7B) interact and allow the

hepatobiliary system to maintain a physiological copper homeostasis.

Despite the concentration of copper being higher in the liver, it is also predominantly present in the normal brain. It has a heterogeneous distribution with stronger concentration in the grey matter (e.g. basal ganglia, Substantia Nigra, dentate nucleus, cortex) than in the white matter [2]. The current model for copper transport through the brain is that the blood–brain barrier (BBB) regulates the influx of copper into the brain and the blood–CSF barrier (BCB) contributes to the maintenance of the copper homeostasis in the brain extracellular fluids [3]. This tight regulation mediated by specific copper transporters and chaperones present at these two brain barriers, allows the copper concentration in the CSF to be maintained at a 50-100 fold lower level than in the serum [4].

Copper acts as a fundamental catalytic cofactor for numerous enzymes and proteins involved in growth and brain development. Examples include the synthesis of cytochrome C oxidase, superoxide dismutase 1, dopamine-beta-hydroxylase, norepinephrine, and amyloid precursor protein as well as the functioning of ceruloplasmin and others metalloproteins [5]. Deficiency in copper caused by an inadequate supply can result in impaired energy production, increased oxidative damage, tissue iron accumulation as well as aberrant neuropeptide synthesis and processing. Increased CNS copper level is found in genetic disorders such as Wilson's disease (see section below), and in neurodegenerative diseases like Alzheimer's disease and amyotrophic lateral sclerosis where CNS copper is reported to be two-fold higher than in age matched controls [6].

## 2. Disorders caused by a genetic mutation in a copper regulatory protein

*Wilson's disease (WD)*

WD is an autosomal recessive disorder due to mutations in the *ATP7B* (Wilson disease protein) gene that is predominantly expressed in the liver. Defective *ATP7B* function impairs both copper incorporation to ceruloplasmin in hepatocytes and copper release into the bile, resulting in liver copper accumulation with tissue damage [7]. In the absence of diagnosis and treatment at this stage, the hepatic free copper spills into the blood stream and deposits in other organs such as cornea, brain and kidney [8].

Clinical prevalence of diagnosed WD is ~30 per million population, but this is probably an inaccurate estimate as a recent genetic study reported the frequency of individuals predicted to carry two mutant pathogenic *ATP7B* alleles to be 1/7026 [9]. The hepatic disease can remain asymptomatic for years or present as acute transient hepatitis, fulminant hepatic failure, and either compensated or decompensated cirrhosis. Neurological symptoms of WD include dysarthria, tremor, dystonia, parkinsonism, oculomotor abnormalities and dysexecutive syndrome. Psychiatric disorders are essentially depression, bipolar affection and dysthymia [8]. Brain lesions are classically located in basal ganglia, midbrain and dentate nuclei (see Figure 1A) but diffuse cerebral atrophy is frequent. White matter changes with cortical lesions and abnormalities in the corpus callosum are also reported [10, 11]. Other extrahepatic features include corneal Kayser-Fleischer rings, renal manifestations like lithiasis, osteoarticular disorders, myocardial abnormalities, endocrine disturbances and repetitive miscarriages.

WD is biologically characterised by low serum ceruloplasmin and total copper concentrations, associated with increased urinary copper excretion. The relative exchangeable copper (non ceruloplasmin bound copper), measured as a ratio of total copper, appears to be an excellent non-invasive diagnostic marker. At diagnosis,

patients with WD have a rate greater than 15% [12].

More than 500 mutations and 100 polymorphisms of the *ATP7B* gene are reported. The absence of correlation phenotype/genotype, clinical heterogeneity and variable penetrance, signify that genes modifiers may exist and influence the age of disease onset or the phenotype.

With regards to treatment, a low copper diet is recommended and alcohol should be avoided due to its high propensity in causing liver toxicity. Medical treatment is more effective if administrated at an early stage of the disease and maintained for life [13]. It is typically based on copper chelators to promote copper excretion from the body (D-penicillamine (DPA) and triethylenetetramine or Trientine) and zinc salts to increase metallothionein synthesis and reduce copper absorption. In our experience, DPA presents adverse effects in 30% of cases (sensitive reactions, nephrotoxicity, hematological abnormalities, autoimmune diseases and elastopathy). Trientine has the added inconvenience of requiring refrigerated storage and is associated with rare sideroblastic anemia and lupus-like reactions. Adverse effects of zinc salts are essentially gastrointestinal discomfort.

Two phases of treatment can be distinguished: the initial phase and the subsequent maintenance therapy. During the acute phase, the major difficulty is the risk of paradoxical worsening of neurological symptoms. A worsening of the neurological disease is observed more frequently with DPA (13.8%) than with Trientine (8%) or zinc salts (4.3%) [14]. In some cases, neurological deterioration is irreversible, the disease continuing to evolve under treatment. The mechanisms of this paradoxical worsening are discussed: treatment too slow to act in very acute forms, irreversible tissue damage already present, direct effect of the treatment with rapid mobilization and redistribution of copper resulting in high levels of free copper in blood and brain.



So, recommendations by experts emphasize the need of a slow increase in chelators' dose [8]. So far, the best therapeutic approach remains controversial, as no prospective clinical trial has compared the different treatments. A retrospective multicenter study analyzed the treatment outcome in 405 patients receiving DPA or Trientine for at least 6 months [15]. After 4 years of treatment, chelation therapy led to hepatic improvement in more than 90% of patients and neurologic improvement in only 62% of patients, these values did not differ between treatments. However, neurologic deterioration was less frequently observed in patients on DPA first (6/293) than those on Trientine first (4/38) ( $p=0.018$ ). In a retrospective Polish study, 143 consecutive patients diagnosed with symptomatic WD were first line treated with DPA or zinc salts. Neither therapy clearly appeared superior, but early worsening was observed in 35% of patients treated with DPA and 19% of patients with zinc salts [16]. Another retrospective study demonstrated that treatments with chelating agents or zinc salts were effective in most patients with WD and that chelating agents are better at preventing hepatic deterioration [17]. Despite these data do not allow a strong recommendation, in our perspective, patients with newly diagnosed neurological WD will still be treated in first line by chelation therapy. Choice between DPA or Trientine depends of the treatment availability, but regardless of the treatment improvement is not immediate and often takes 3 to 6 months.

The risk of initial neurological worsening could be lessened with tetrathiomolybdate, another copper chelator, which acts by forming a tripartite complex with copper and protein either in the intestinal lumen to prevent copper absorption, or in the circulation where it blocks cellular copper trafficking [18]. However, clinical experience with this drug remains insufficient and international studies are still only in the pipeline.

Liver transplantation should be considered in WD patients with acute liver failure or

decompensated cirrhosis as results are extremely satisfactory with 87% actuarial patient survival rate at 5, 10 and 15 years [19]. However this remains a matter of controversy in cases of neurological worsening without liver failure, despite reports of 70% of these patients improving after transplantation [20]. In our experience, after a mean follow-up of five years, 12 of 16 patients (75%) improved when transplanted for neurologic worsening. So, in this specific indication, liver transplantation must be individually discussed.

During the maintenance phase, the major difficulty is the adherence to the treatment. A regular clinical, biological and liver ultrasound follow-up is essential to make sure of observance, efficiency and tolerance of the treatment, as well as to detect treatment complications, increased liver enzymes (more frequent under zinc therapy) and liver carcinoma. Dose adjustment during the maintenance phase is very important to prevent overtreatment and copper deficiency. After years of regular treatment, more often clinical signs progressively resolve and brain lesions disappear (see Figure 1A).

During pregnancy, treatments must be maintained, but dosages of drugs should be reduced and adapted to urinary copper excretion and exchangeable copper. Since treatment is more effective if initiated early, family screening is essential for this autosomal recessive disorder. In relatives with presymptomatic disease, treatment is mandatory (zinc salts or Trientine). Further treatments should focus on more site-specific copper chelators that can act in the hepatocytes to excrete the copper-complex into the bile. Gene therapy also seems an attractive alternative with effective treatment on WD animal models [21, 22].

### *Menkes disease (MD)*

MD is an X-linked recessive disorder of impaired copper absorption caused by mutations in the *ATP7A* gene. Usually, developmental regression appears in boys

during the first two months of life with axial hypotonia, seizures and psychomotor retardation. Other manifestations are relative to connective damages; coarse hair, ligamentous hyperlaxity, skin hyperelasticity, bladder and ureter diverticula, arterial tortuosities and aneurysms [23]. Magnetic Resonance Imaging (MRI) shows impaired myelination, diffuse brain atrophy and tortuosity of cerebral arteries. Diagnosis of MD can be established by detecting low levels of copper and ceruloplasmin in the serum, and high levels in cutaneous fibroblasts. It is confirmed by identification of the gene mutation. For some patients, parenteral administration of Histidine-copper improves the neurological outcome and increases lifespan, but the prognosis remains inevitably poor. Death usually occurs by 3 years of age, but some patients can survive beyond 10 years. In 5-10 % of the patients, a milder form of MD presents with a later onset, more moderate symptoms and longer survival. Preliminary results of brain-directed *ATP7A* gene therapy using recombinant adeno-associated virus in a mouse model of MD appear highly promising [24].

#### *Other copper disorders*

Occipital horn syndrome and *ATP7A*-related distal motor neuropathy are also associated with *ATP7A* mutations. MEDNIK (mental retardation, enteropathy, deafness, peripheral neuropathy, ichthyosis, and keratoderma) syndrome and Huppke-Brendl syndrome are newly recognised genetic disorders that may indirectly affect the function of *ATP7A* [23, 25]. MEDNIK syndrome is caused by mutations in the *s1A* subunit of adaptor protein complex 1 (AP-1), which leads to detrimental effects on *ATP7A* trafficking [26]. Huppke–Brendel syndrome is caused by mutations in an acetyl-CoA transporter, *SLC33A1*, needed for acetylation of one or more copper proteins [27]. Clinical, biochemical, molecular features and treatment options of these rare diseases are summarized in Table 2.

### 3. Acquired disorders: copper deficiency and copper excess/toxicosis

#### *Acquired Copper deficiency (ACD)*

In developed countries, ACD is rarely due to a low dietary intake of copper (malnutrition or prolonged parenteral nutrition without copper supplementation). Instead, the two main causes responsible for inadequate supply of copper are digestive disorders with impaired absorption and/or consumption of high dose of zinc that provokes a zinc-induced copper deficiency. Digestive conditions can originate from various malabsorption syndromes including celiac disease, inflammatory bowel disease, upper gastro-intestinal surgeries and bariatric surgery to combat obesity. High intake of zinc is usually associated with chronic use of dental adhesives enriched in zinc [8] but prolonged zinc treatment in WD can also cause ACD in extreme cases [28]. The precise molecular mechanisms of ACD are unknown [29]. Manifestations of ACD start with hematologic then neurologic abnormalities. Anaemia and neutropenia are the most common hematologic findings but pancytopenia can be also present [30]. Neurologic symptoms can be initially limited to ascending paresthesias and gait disorder but can also mimic a B12 deficiency phenotype with a posterior cord syndrome or a subacute combined degeneration. On most occasions spinal cord MRI classically shows a posterior high T2 signal in cervical or dorsal level, but it may also be normal. B12 dosage and CSF are always normal. Low serum copper and ceruloplasmin levels confirmed the diagnosis but can be differentiated from WD through urinary copper levels being typically low or normal. Treatment is based on a chronic copper supplementation (but doses and duration are not well established) and is dependent on the management of underlying risk factors. In our experience, copper should be started as rapidly as possible with subcutaneous or parenteral high doses (minimum 4 mg/d) and then maintained over years with oral

intake of a minimum of 2 mg/d copper. Using this regime, disturbances in copper and hematology are rapidly resolved in a few weeks, MRI normalizes in a year but neurologic improvement takes much longer if benefits are seen at all.

### *Acquired copper toxicity*

Acute copper toxicity tends to result from accidental copper contamination of drinking water or other beverages stored within copper-containing vessels. Clinical manifestations range from a metallic taste, nausea, vomiting and diarrhoea, through to jaundice, hemoglobinuria, hematuria, anuria, and oliguria. A lethal dose is ~1000 times the normal dietary intake. Chronic copper poisoning arises from accumulation within the liver but is exceptional due to highly efficient systemic control mechanisms for copper homeostasis that can alter intestinal absorption and biliary excretion in response to the body's copper levels [31].

## **Iron and Central Nervous System**

### 1. Iron metabolism, brain pathology and iron chelation

Iron has allowed the existence of life on earth through an ability to act as an electron donor for photosynthesis and aerobic respiration via mitochondrial oxidative phosphorylation. Iron homeostasis relies on the orchestration of a network of systemic and cellular mechanisms for the acquisition, internal distribution and employment of iron [32-34]. Disruption of links in the metabolic network can lead to mislocalization of iron in specific cellular compartments or tissues (causing localized siderosis and thus damage) and impaired redistribution of iron, generating a "deficiency in the midst of abundance" [35-37].

Damage arising from siderosis is mostly from the potent pro-oxidant and redox-

cycling capacity of iron, making it a key player in upstream mechanisms that precipitate cell death. Iron's catalysis of reactive oxygen species (ROS) formation from by-products of oxygen consumption affects neuronal functions either by directly damaging cell components, through the Fenton reaction, or by chemically affecting signal mediators [38-40].

The recent resumption of interest for iron in the brain pathologies can be explained by several facts. First, iron maldistribution with iron accumulation (i.e. regional siderosis) have been clarified with greater resolution, using a variety of imaging techniques, as an early feature in pathologically affected brain regions from Neurodegeneration with Brain Iron Accumulation (NBIA), Friedreich ataxia (FA), Parkinson's disease (PD), Alzheimer's disease (AD) and Amyotrophic Lateral Sclerosis (ALS). Second, accumulative data demonstrate a pivotal role of iron in the physiopathology of cell death as exemplified by; the defective synthesis of the cluster iron sulfur in FA, the exacerbation of dopamine oxidation in PD, and the involvement of the canonical proteins of AD in iron metabolism (i.e.  $\beta$ -Amyloid precursor protein, Tau, ApoE, presenilin). Finally, therapeutic perspectives with the new concept of conservative iron chelation have shown promising outcomes in preclinical and clinical testing.

Despite these promising advances, the exact contribution of brain siderosis on aetiology of these diseases remains to be fully elucidated. Moreover, while iron accumulation with neurodegeneration has been a major focus of previous research it is increasingly evident that iron deficits caused by maldistribution are just as deleterious to behavioural outcome and increasingly understood to be a major contributor to cognitive impairment in our society (e.g. the association with juvenile obesity and iron deficiency [41]). In all these disorders, the simultaneous dearth and

surplus of regional iron within the brain pose new challenges in drug therapy, with the need to detoxify discrete siderotic foci without affecting essential iron-dependent functions and conversely, replenish iron-deprived regions without overloading those already in surplus. The traditional role of iron chelation therapy has been to reduce body iron burden of excess metal and its safe excretion in a complexed form. However, we and others have introduced a more conservative mode of iron chelation with a dual activity based on scavenging labile metal not considered to be functionally required and redeploying it to cell acceptors or the physiological iron transporter transferrin family. This “scavenging and redeployment” is a proposed mode of action for the prototype drug deferiprone and has been found to correct aberrant iron distribution and minimizing / prevent systemic loss of chelated metal in a range of animal models and humans [42, 43].

## 2. Monogenetic Orphan diseases; Neurodegeneration with brain iron accumulation (NBIA)

NBIA is a heterogeneous group of disorders with a prevalence of  $\sim 0.5 / 100,000$  but a highly variable age of onset, partly depending on the causative genetic abnormality. This syndrome is clinically characterized by the variable combination of i) movement disorders (dystonia/parkinsonism/chorea) that usually are the main manifestation of the disease and predominate in the oro-facial and bulbar muscles, ii) pyramidal syndrome, iii) cognitive deterioration and iv) psychiatric disturbances. Brain MRI shows bipallidal hyperintensity on T2 and T2\* (more sensitive) weighted sequences that reflect the alteration of iron homeostasis in these areas (See Figure 1B). Other clinical or neuroimaging abnormalities can be seen depending on the cause (see Table 3). It is important for clinical practice to keep in mind that a time lag can be observed between clinical manifestations and neuroimaging abnormalities; some

symptomatic patients still have a normal MRI at initial stages and conversely some patients are asymptomatic despite bipallidal hyperintensity.

NBIA can be divided into two groups, primary disorders of iron metabolism (neuroferritinopathy and aceruloplasminemia) and disorders in which alteration of iron homeostasis is secondary to neuronal stress induced from another origin (Panthothenate Kinase Associated Neurodegeneration (PKAN), PhosphoLipase A2 Group VI Associated Neurodegeneration (PLAN), Fatty Acid 2 Hydroxylase associated Neurodegeneration (FAHN), Mitochondrial membrane Protein Associated Neurodegeneration (MPAN), Beta-propeller Protein Associated Neurodegeneration (BPAN), and Coenzyme A synthase Protein Associated Neurodegeneration (CoPAN) [44]. Diagnosis is confirmed by molecular analysis of the various culprit genes. Aceruloplasminemia leads to a dramatic reduction of the ferroxidase activity in ceruloplasmin that prevents astrocytic iron export and the safe incorporation of iron into extracellular transferrin. In the absence of functional ceruloplasmin, astrocytic iron accumulation leads to neurons suffering from iron deprivation in the early stages of the disease, and eventually promotes iron-mediated oxidation. Neuroferritinopathy results from an alteration of iron storage by ferritin polymers with subsequent release of free iron and iron-mediated oxidation. Interestingly, secondary alterations of iron homeostasis are mostly linked to disorders of synthesis and the remodelling of complex lipids. Basically, treatment is symptomatic and currently there are no registered treatments for preventing the gradual pathological deterioration over decades (see Figure 1B). However, the benefit of iron chelator and particularly deferiprone has been proposed through open label trials in PKAN [45-48] despite efficacy remaining to be determined in on going randomized clinical trials.



### 3. Polygenic Neurodegenerative disorders

#### *Parkinson's Disease (PD)*

PD arises from a progressive degeneration throughout the nigrostriatal tract, most marked in the Substantia Nigra pars compacta (SNc). Depletion of striatal dopamine, resulting primarily from loss of SNc neurons, results in characteristic symptoms of disrupted motor coordination and cognitive impairment in the latter stages. Similar to NBIA, PD is characterised by iron accumulation in the basal ganglia with elevation above normal ageing greatest in the SNc [49-55] of patients and animal models [40, 56]. Indeed, since its first anatomopathological description in 1924 [57], iron accumulation has now become a cardinal feature of regional cellular degeneration, as demonstrated with MRI [52, 54, 55] and ultrasound [58]. Several reasons can explain the vulnerability of the SNc to ROS and dysregulation of a pro-oxidant such as iron would clearly exacerbate ROS induced toxicity. Metabolism of dopamine, through pathways in which several are iron-dependent, expose dopaminergic neurons to high ROS productivity. When these dopamine metabolites are produced within vesicles they are comparatively protected against oxidation, but when formed within the cytoplasm become toxic.  $\alpha$ -Synuclein ( $\alpha$ -syn), a pathological protein associated with PD, may be implicated in this altered dopamine metabolite location as a reported role of  $\alpha$ -syn is in the formation of vesicles and PD induced changes to the structure of  $\alpha$ -syn can lead to disrupted vesicle formation. Changes in neurotoxicity within the cytoplasm may be compounded by  $\alpha$ -syn aggregating in PD to form Lewy bodies, another hallmark of PD, which also combines with lipids, redox-active iron and dopamine metabolites to form a site for redox cycling. The aggregation of  $\alpha$ -syn in the presence of iron also has a positive feedback loop whereby together they induce a defective sequestration of dopamine into vesicles,

further enhancing the oxidative metabolism of dopamine into harmful dopamine quinones [59]. Lastly, autonomous pacemaking within the SNc is substantially higher than other dopaminergic regions (e.g. ventral tegmental area and SN pars reticulata), thus creating a higher level of ROS and increasing vulnerability of this region to oxidative stress [38].

The presence of elevated labile iron in the SNc of PD patients, in particular within the mitochondrial subcellular compartment, has been proposed to result from one or more of the following factors [60]; increased iron influx facilitated through transferrin receptor-2/divalent metaltransporter-1 endocytosis or the diffusion of ferric citrate [61]; loss of intracellular homeostatic regulation involving iron, dopamine and neuromelanin [62]; impaired iron efflux [63-65].

Given the deleterious effects of elevated iron in the SNc of PD patients, a therapeutic strategy that reduces the levels of labile iron is likely to be neuroprotective. Chelation as a viable therapeutic strategy requires targeting to all forms of regional siderosis, but with the prerequisite of sparing systemic metal depletion [35, 66]. We and others selected deferiprone (DFP) as a paradigm in the suitability of membrane permeable chelation to confer neuroprotection through conservative iron chelation. Indeed, we demonstrated both with PD models and patients that DFP rescued iron-overloaded dopaminergic neurons by scavenging labile iron, especially from mitochondria, and diminished labile iron-mediated oxidative damage so as to be neuroprotective in animal models and improve symptoms in patients. Moreover, DFP had the capacity to deliver chelated metal to endogenous apo-transferrin (iron unbound transferrin) within extracellular fluid [35], and cause no systemic loss of iron even after 2 years of treatment [43]. These promising results have provided the opportunity to now assess this therapeutic paradigm in a larger population through a European randomised

clinical trial ([www.fairpark2.eu](http://www.fairpark2.eu)).

### *Alzheimer's Disease (AD)*

Iron elevation in affected areas of AD has been well-characterised in living patients using MRI, and in post mortem brains using multiple techniques [40]. While early studies with high field T2-weighted MRI suggested amyloid plaques containing iron [67], more recent developments using 7-T MRI have demonstrated iron deposition also within activated microglia surrounding the plaque [68, 69]. Hippocampal iron accumulation also localizes to neurofibrillary tangle-containing neurons and the neuritic processes surrounding senile plaques in AD [70]. Genetic and biochemical markers have identified a concerted systemic iron homeostatic dysregulation in patients with AD [71] and colleagues have calculated the impact of iron on longitudinal AD outcomes [72]. Using ferritin (the major iron binding protein) in CSF as an index, high brain iron load was found to associate with poorer cognition and brain atrophy over a 6-year period. The magnitude of CSF ferritin on these and other AD outcomes is comparable to the Tau/A $\beta$ <sub>42</sub> ratio typically considered as the best diagnostic CSF biomarker for AD. CSF ferritin levels also formed a remarkable association with CSF ApoE levels and subjects with APOE $\epsilon$ 4 isoform have elevated CSF ferritin compared to patients without this AD risk allele [72]. Intriguingly, iron appears to regulate ApoE expression and secretion from brain derived cells [73]. Lastly, interactions between variants in the transferrin gene (*TF*) and the hemochromatosis gene (*HFE*) also have been identified and replicated in multiple cohorts for association with sporadic AD [74].

A number of additional pathologically relevant proteins associated with AD have also been implicated with regulating cellular iron homeostasis whereby disruption in the expression or location of these proteins exacerbates oxidative stress induced

neurotoxicity. Of particular focus has been the regulatory pathway required to facilitate the cellular efflux of iron. Control of APP expression by iron regulatory protein supports an interaction with iron status [75] and biological evidence has illustrated a role of APP in neuronal iron efflux through interaction with the iron pore ferroportin [76]. Prior to this discovery no mechanism was known for endogenous regulation of neuronal iron export and latter studies have confirmed the requirement of APP on the cell surface to stabilize ferroportin in its functional location [77 , 78 , 79 , 80]. Alterations in the correct processing of APP, as with the AD-associated familial mutation [81], or when APP trafficking to the cell surface is altered [65] leads to neuronal iron accumulation. Subsequent studies have implicated tau in the intracellular trafficking of APP to the cell surface, and accordingly a deficiency in this role of tau leads to reduced APP and ferroportin on the cell surface, intraneuronal iron accumulation and a subsequent increased sensitivity to oxidative stress [65].

Metal chelation therapy is a proposed target for AD but this has principally focused on compounds with a greater affinity for copper and zinc. Preclinical evidence has however indicated that iron selective chelation is neuroprotective in AD models by reducing features of pathology and behavior associated with AD [82]. It has recently been proposed that iron accumulation and other hallmarks of the disease in these models may be alleviated by restoring or substituting the iron regulatory role of the pathological proteins associated with the disease (e.g. APP and tau) [63].

#### *Amyotrophic lateral sclerosis (ALS)*

Many lines of evidence indicate that there is an iron dyshomeostasis in ALS. Indeed, iron serves as an important cofactor for a number of enzymes involved in pivotal biological activities altered in ALS, and the high redox active nature of iron means that it may be a major generator of the free radicals prevalent with the disease.

Serum ferritin levels are higher in ALS patients versus healthy and disease controls [83] and this elevation correlates with a shorter survival time in these patients [84-86]. While total iron levels remain unchanged, altered transferrin saturation in ALS patients supports an altered iron loading [85]. Cerebrospinal fluid of ALS patients also indicates a two-fold increase in levels of inappropriate iron ligands, representing the proportional increase in iron redox activity and hydroxyl radical production compared to controls [87]. Routine MRI studies have also shown hypo-intense signalling in the motor cortex on T2-weighted images in some ALS patients [87-89]. Pathological studies using a histological stain for iron and immunostaining for ferritin confirm this signal to originate from increased iron accumulation in cells resembling microglia from the middle and deep layers of the motor cortex [89].

Irregularities in iron homeostatic pathways have also been observed in mouse models of ALS that carry familial mutations in SOD1 (superoxide dismutase 1). Both the G37R and G93A mutant models have caudal-to-rostral gradient in the spinal cord of iron-related changes at end stage of the disease (i.e. 12 months of age), however in the case of SOD1 (G93A) this distribution showed a reverse pattern at a younger age [90]. The iron responsive protein changes in the cervical region parallel clinical disease evolution. Since mitochondrial disruption is thought to play a major role in ALS, it is worth noting that mitochondrial ferritin (a protein known to trap iron in the mitochondria) is also markedly increased in SOD1 (G37R) mice and could implicate the disease associated iron accumulation with neurodegeneration similar to FA [90].

Iron chelation therapy in rodent models of familial ALS are able to increase the mean life span, spinal motor neuron survival and locomotor function in the SOD1 (G37R) along with the decrease in iron accumulation when the lipophilic iron chelator SIH (salicylaldehyde isonicotinoyl hydrazine) is administered [90]. More recently, VK-28

and M30 have also provided delayed onset of ALS symptoms, lifespan extension and reduced spinal cord motor neuron loss in the SOD1 (G93A) model [91]. We can confirm that an increase in R2\* signal is present within the spinal cord, brainstem and motor cortex of early ALS patients, which is partially corrected by deferiprone at 30 mg/kg/day (publication in preparation). While it is less clear whether iron has a pathological involvement with other ALS-associated proteins such as TDP-43 [92], the sporadic patient and familial ALS SOD1 model data provides a strong case for assessing this therapeutic paradigm in a large population similar to the recent Fairpark randomised clinical trial carried out on PD patients.

### **Manganese and Central Nervous System**

After its absorption by inhalation or through the gastrointestinal tract, manganese (Mn) predominantly accumulates in the liver and the brain (especially in the basal ganglia, SN and the cortex). As with copper, the hepatobiliary system has a major role in the manganese homeostasis. In the gut, dyshomeostasis of other metals may have an effect on Mn absorption as an iron deficiency increases uptake. As with iron and copper, excessive accumulation of this essential nutrient yields toxicity. This may arise through rare mutation such as within the *SLC30A10* gene (syndrome of liver cirrhosis, polycythemia, dystonia and hypermanganesemia) or more often due to excessive exogenous exposure that leads to manganism. Manganism has been described in occupationally exposed workers or drug users of homemade ephedron/methcathinone. Patients may be asymptomatic for months or years after exposure, but progressively develop slow movements, irritability, aggressiveness, and hallucinations. By later stage, features include extrapyramidal syndrome that is unresponsive to L-dopa, tremor, balance disturbances with a dystonic cock-walk gait

and postural instability, facial muscle spasms and cognitive impairment [93, 94]. During the exposure period, and before phenotypic changes, blood and urine Mn levels are high and brain MRI displays a symmetrical high T1 signal in the basal ganglia (mostly in the GP). To date there are no effective treatments for manganism as chelators only decrease Mn levels but don't improve the symptoms, thus indicating that deterioration may still occur even after Mn exposure has stopped.

Chronic liver failure may be another cause of cerebral Mn accumulation as the hepatobiliary system fails to keep metal homeostasis. In this acquired hepatocerebral degeneration, patients may present with parkinsonism, ataxia, tremor and cognitive impairment without signs of toxic-metabolic hepatic encephalopathy and have an abnormal brain MRI with bipallidal T1 hyperintensity. Neuropathologic examination showed that pallidal manganese concentrations are sevenfold higher than controls and fourfold higher than patients suffering from chronic liver failure but with a normal brain MRI [95]. No clinical data exist of the efficacy of lowering Mn by diet or chelating therapy in chronic liver failure but Trientine administration and liver a

## References and recommended reading

1. Fergusson, J.E., *The Heavy Elements: Chemistry, Environmental Impact and Health Effects.*, ed. J.E. Fergusson. 1990: Oxford: Pergamon Press.
2. Krebs, N., et al., *Assessment of trace elements in human brain using inductively coupled plasma mass spectrometry.* J Trace Elem Med Biol, 2014. **28**(1): p. 1-7.
3. Choi, B.S. and W. Zheng, *Copper transport to the brain by the blood-brain barrier and blood-CSF barrier.* Brain Res, 2009. **1248**: p. 14-21.
4. Monnot, A.D., et al., *Regulation of brain copper homeostasis by the brain barrier systems: effects of Fe-overload and Fe-deficiency.* Toxicol Appl Pharmacol, 2011. **256**(3): p. 249-57.
5. **Lutsenko, S., A. Bhattacharjee, and A.L. Hubbard, *Copper handling machinery of the brain.* Metallomics, 2010. 2(9): p. 596-608.**
  - \* Summary of the current knowledge about cerebral copper levels and actions. Fine description of the molecules involved in maintaining copper homeostasis in the brain.
6. Ahuja, A., et al., *Copper mediated neurological disorder: visions into amyotrophic lateral sclerosis, Alzheimer and Menkes disease.* J Trace Elem Med Biol, 2015. **29**: p. 11-23.
7. Zischka, H. and J. Lichtmannegger, *Pathological mitochondrial copper overload in livers of Wilson's disease patients and related animal models.* Ann N Y Acad Sci, 2014. **1315**: p. 6-15.
8. **Woimant, F. and J.M. Trocello, *Disorders of heavy metals.* Handb Clin Neurol, 2014. 120: p. 851-64.**
  - \* Insightful review of the current clinical, diagnostic and treatment challenges in heavy metals disorders
9. Coffey, A.J., et al., *A genetic study of Wilson's disease in the United Kingdom.* Brain, 2013. **136**(Pt 5): p. 1476-87.
10. Trocello, J.M., et al., *Extensive striatal, cortical, and white matter brain MRI abnormalities in Wilson disease.* Neurology, 2013. **81**(17): p. 1557.
11. Trocello, J.M., et al., *Corpus callosum abnormalities in Wilson's disease.* J Neurol Neurosurg Psychiatry, 2011. **82**(10): p. 1119-21.
12. El Balkhi, S., et al., *Relative exchangeable copper: a new highly sensitive and highly specific biomarker for Wilson's disease diagnosis.* Clin Chim Acta, 2011. **412**(23-24): p. 2254-60.
13. **Bandmann, O., K.H. Weiss, and S.G. Kaler, *Wilson's disease and other neurological copper disorders.* Lancet Neurol, 2015. 14(1): p. 103-13.**
  - \*\* A comprehensive review of Wilson's disease including its phenomenology, pathophysiology, imaging findings and treatment.
14. Merle, U., et al., *Clinical presentation, diagnosis and long-term outcome of Wilson's disease: a cohort study.* Gut, 2007. **56**(1): p. 115-20.
15. Weiss, K.H., et al., *Efficacy and safety of oral chelators in treatment of patients with Wilson disease.* Clin Gastroenterol Hepatol, 2013. **11**(8): p. 1028-35 e1-2.
16. Czlonkowska, A., et al., *D-penicillamine versus zinc sulfate as first-line therapy for Wilson's disease.* Eur J Neurol, 2014. **21**(4): p. 599-606.
17. Weiss, K.H., et al., *Zinc monotherapy is not as effective as chelating agents in treatment of Wilson disease.* Gastroenterology, 2011. **140**(4): p. 1189-1198 e1.
18. Brewer, G.J., et al., *Treatment of Wilson's disease with tetrathiomolybdate: V. Control of free copper by tetrathiomolybdate and a comparison with trientine.* Transl Res, 2009. **154**(2): p. 70-7.



19. Guillaud, O., et al., *Long term results of liver transplantation for Wilson's disease: experience in France*. J Hepatol, 2014. **60**(3): p. 579-89.
20. Medici, V., et al., *Liver transplantation for Wilson's disease: The burden of neurological and psychiatric disorders*. Liver Transpl, 2005. **11**(9): p. 1056-63.
21. Delangle, P. and E. Mintz, *Chelation therapy in Wilson's disease: from D-penicillamine to the design of selective bioinspired intracellular Cu(I) chelators*. Dalton Trans, 2012. **41**(21): p. 6359-70.
22. Roybal, J.L., et al., *Early gestational gene transfer with targeted ATP7B expression in the liver improves phenotype in a murine model of Wilson's disease*. Gene Ther, 2012. **19**(11): p. 1085-94.
- 23. Kaler, S.G., *Translational research investigations on ATP7A: an important human copper ATPase*. Ann N Y Acad Sci, 2014. **1314**: p. 64-8.**

\* A general and comprehensive review of disorders due to ATP7A dysfunctions.

24. Donsante, A., et al., *ATP7A gene addition to the choroid plexus results in long-term rescue of the lethal copper transport defect in a Menkes disease mouse model*. Mol Ther, 2011. **19**(12): p. 2114-23.
25. Kaler, S.G., *Inborn errors of copper metabolism*. Handb Clin Neurol, 2013. **113**: p. 1745-54.
26. Martinelli, D., et al., *MEDNIK syndrome: a novel defect of copper metabolism treatable by zinc acetate therapy*. Brain, 2013. **136**(Pt 3): p. 872-81.
27. Huppke, P., et al., *Mutations in SLC33A1 cause a lethal autosomal-recessive disorder with congenital cataracts, hearing loss, and low serum copper and ceruloplasmin*. Am J Hum Genet, 2012. **90**(1): p. 61-8.
28. Teodoro, T., et al., *Recovery after copper-deficiency myeloneuropathy in Wilson's disease*. J Neurol, 2013. **260**(7): p. 1917-8.
29. Prohaska, J.R., *Impact of copper deficiency in humans*. Ann N Y Acad Sci, 2014. **1314**: p. 1-5.
30. Halfdanarson, T.R., et al., *Hematological manifestations of copper deficiency: a retrospective review*. Eur J Haematol, 2008. **80**(6): p. 523-31.
31. Bremner, I., *Manifestations of copper excess*. Am J Clin Nutr, 1998. **67**(5 Suppl): p. 1069S-1073S.
32. Fleming, R.E. and P. Ponka, *Iron overload in human disease*. N Engl J Med, 2012. **366**(4): p. 348-59.
33. Camaschella, C., *Hereditary sideroblastic anemias: pathophysiology, diagnosis, and treatment*. Semin Hematol, 2009. **46**(4): p. 371-7.
34. Cairo, G. and S. Recalcati, *Iron-regulatory proteins: molecular biology and pathophysiological implications*. Expert Rev Mol Med, 2007. **9**(33): p. 1-13.
35. Sohn, Y.S., et al., *Redistribution of accumulated cell iron: a modality of chelation with therapeutic implications*. Blood, 2008. **111**(3): p. 1690-9.
36. Rouault, T.A., *Iron metabolism in the CNS: implications for neurodegenerative diseases*. Nat Rev Neurosci, 2013. **14**(8): p. 551-64.
37. Rouault, T.A., *Biogenesis of iron-sulfur clusters in mammalian cells: new insights and relevance to human disease*. Dis Model Mech, 2012. **5**(2): p. 155-64.
38. Guzman, J.N., et al., *Oxidant stress evoked by pacemaking in dopaminergic neurons is attenuated by DJ-1*. Nature, 2010. **468**(7324): p. 696-700.
39. Milusheva, E., et al., *Increased sensitivity of striatal dopamine release to H<sub>2</sub>O<sub>2</sub> upon chronic rotenone treatment*. Free Radic Biol Med, 2005. **39**(1): p. 133-42.
40. Zecca, L., et al., *Iron, brain ageing and neurodegenerative disorders*. Nat Rev Neurosci, 2004. **5**(11): p. 863-73.

41. Hutchinson, C., *A review of iron studies in overweight and obese children and adolescents: a double burden in the young?* Eur J Nutr, 2016.
42. Cabantchik, Z.I., et al., *Regional siderosis: a new challenge for iron chelation therapy.* Front Pharmacol, 2013. **4**: p. 167.
43. **Devos, D., et al., *Targeting chelatable iron as a therapeutic modality in Parkinson's disease.* Antioxid Redox Signal, 2014. **21**(2): p. 195-210.**
- \*\* Establishes the therapeutic features of chelation modality in PD translational models and in pilot clinical trials.
44. Levi, S. and D. Finazzi, *Neurodegeneration with brain iron accumulation: update on pathogenic mechanisms.* Front Pharmacol, 2014. **5**: p. 99.
45. Zorzi, G., et al., *Therapeutic advances in neurodegeneration with brain iron accumulation.* Semin Pediatr Neurol, 2012. **19**(2): p. 82-6.
46. Zorzi, G., et al., *Iron-related MRI images in patients with pantothenate kinase-associated neurodegeneration (PKAN) treated with deferiprone: results of a phase II pilot trial.* Mov Disord, 2011. **26**(9): p. 1756-9.
47. Abbruzzese, G., et al., *A pilot trial of deferiprone for neurodegeneration with brain iron accumulation.* Haematologica, 2011. **96**(11): p. 1708-11.
48. Cossu, G., et al., *Efficacy and safety of deferiprone for the treatment of pantothenate kinase-associated neurodegeneration (PKAN) and neurodegeneration with brain iron accumulation (NBIA): results from a four years follow-up.* Parkinsonism Relat Disord, 2014. **20**(6): p. 651-4.
49. Connor, J.R., et al., *Cellular distribution of transferrin, ferritin, and iron in normal and aged human brains.* J Neurosci Res, 1990. **27**(4): p. 595-611.
50. Dexter, D.T., et al., *Increased nigral iron content in postmortem parkinsonian brain.* Lancet, 1987. **2**(8569): p. 1219-20.
51. Du, G., et al., *Combined R2\* and diffusion tensor imaging changes in the substantia nigra in Parkinson's disease.* Mov Disord, 2011. **26**(9): p. 1627-32.
52. Peran, P., et al., *Magnetic resonance imaging markers of Parkinson's disease nigrostriatal signature.* Brain, 2010. **133**(11): p. 3423-33.
53. Ducic, T., et al., *X-ray fluorescence analysis of iron and manganese distribution in primary dopaminergic neurons.* J Neurochem, 2013. **124**(2): p. 250-61.
54. Groger, A. and D. Berg, *Does structural neuroimaging reveal a disturbance of iron metabolism in Parkinson's disease? Implications from MRI and TCS studies.* J Neural Transm (Vienna), 2012. **119**(12): p. 1523-8.
55. Wallis, L.I., et al., *MRI assessment of basal ganglia iron deposition in Parkinson's disease.* J Magn Reson Imaging, 2008. **28**(5): p. 1061-7.
56. Przedborski, S. and M. Vila, *The 1-methyl-4-phenyl-1,2,3,6-tetrahydropyridine mouse model: a tool to explore the pathogenesis of Parkinson's disease.* Ann N Y Acad Sci, 2003. **991**: p. 189-98.
57. Lhermitte, J., W.M. Kraus, and D. McAlpine, *Original Papers: ON THE OCCURRENCE OF ABNORMAL DEPOSITS OF IRON IN THE BRAIN IN PARKINSONISM WITH SPECIAL REFERENCE TO ITS LOCALISATION.* J Neurol Psychopathol, 1924. **5**(19): p. 195-208.
58. Berg, D., *Disturbance of iron metabolism as a contributing factor to SN hyperechogenicity in Parkinson's disease: implications for idiopathic and monogenetic forms.* Neurochem Res, 2007. **32**(10): p. 1646-54.
59. Lotharius, J. and P. Brundin, *Pathogenesis of Parkinson's disease: dopamine, vesicles and alpha-synuclein.* Nat Rev Neurosci, 2002. **3**(12): p. 932-42.
60. Hare, D.J. and K.L. Double, *Iron and dopamine: a toxic couple.* Brain, 2016.

61. Moos, T., et al., *Iron trafficking inside the brain*. J Neurochem, 2007. **103**(5): p. 1730-40.
62. Zucca, F.A., et al., *Interactions of iron, dopamine and neuromelanin pathways in brain aging and Parkinson's disease*. Prog Neurobiol, 2015.
63. Wong, B.X. and J.A. Duce, *The iron regulatory capability of the major protein participants in prevalent neurodegenerative disorders*. Front Pharmacol, 2014. **5**: p. 81.
64. Ayton, S., et al., *Ceruloplasmin dysfunction and therapeutic potential for Parkinson disease*. Ann Neurol, 2013. **73**(4): p. 554-9.
65. Lei, P., et al., *Tau deficiency induces parkinsonism with dementia by impairing APP-mediated iron export*. Nat Med, 2012. **18**(2): p. 291-5.
66. Kakhlon, O., et al., *Iron redistribution as a therapeutic strategy for treating diseases of localized iron accumulation*. Can J Physiol Pharmacol, 2010. **88**(3): p. 187-96.
67. Chamberlain, R., et al., *Comparison of amyloid plaque contrast generated by T2-weighted, T2\*-weighted, and susceptibility-weighted imaging methods in transgenic mouse models of Alzheimer's disease*. Magn Reson Med, 2009. **61**(5): p. 1158-64.
68. Yao, B., et al., *Susceptibility contrast in high field MRI of human brain as a function of tissue iron content*. Neuroimage, 2009. **44**(4): p. 1259-66.
69. Zeineh, M.M., et al., *Activated iron-containing microglia in the human hippocampus identified by magnetic resonance imaging in Alzheimer disease*. Neurobiol Aging, 2015. **36**(9): p. 2483-500.
70. Quintana, C., et al., *Study of the localization of iron, ferritin, and hemosiderin in Alzheimer's disease hippocampus by analytical microscopy at the subcellular level*. J Struct Biol, 2006. **153**(1): p. 42-54.
71. Crespo, A.C., et al., *Genetic and biochemical markers in patients with Alzheimer's disease support a concerted systemic iron homeostasis dysregulation*. Neurobiol Aging, 2014. **35**(4): p. 777-85.
72. **Ayton, S., et al., *Ferritin levels in the cerebrospinal fluid predict Alzheimer's disease outcomes and are regulated by APOE*. Nat Commun, 2015. **6**: p. 6760.**

\*\* Identifies that elevated brain iron adversely impacts on AD progression and introduces the concept that brain iron elevation is a possible mechanism for APOE $\epsilon$ 44 being the major genetic risk factor for AD.

73. Xu, H., et al., *Iron Regulates Apolipoprotein E Expression and Secretion in Neurons and Astrocytes*. J Alzheimers Dis, 2016. **51**(2): p. 471-87.
74. Kauwe, J.S., et al., *Suggestive synergy between genetic variants in TF and HFE as risk factors for Alzheimer's disease*. Am J Med Genet B Neuropsychiatr Genet, 2010. **153B**(4): p. 955-9.
75. Rogers, J.T., et al., *An iron-responsive element type II in the 5'-untranslated region of the Alzheimer's amyloid precursor protein transcript*. J Biol Chem, 2002. **277**(47): p. 45518-28.
76. Duce, J.A., et al., *Iron-export ferroxidase activity of beta-amyloid precursor protein is inhibited by zinc in Alzheimer's disease*. Cell, 2010. **142**(6): p. 857-67.
77. **Wong, B.X., et al., *beta-Amyloid precursor protein does not possess ferroxidase activity but does stabilize the cell surface ferrous iron exporter ferroportin*. PLoS One, 2014. **9**(12): p. e114174.**

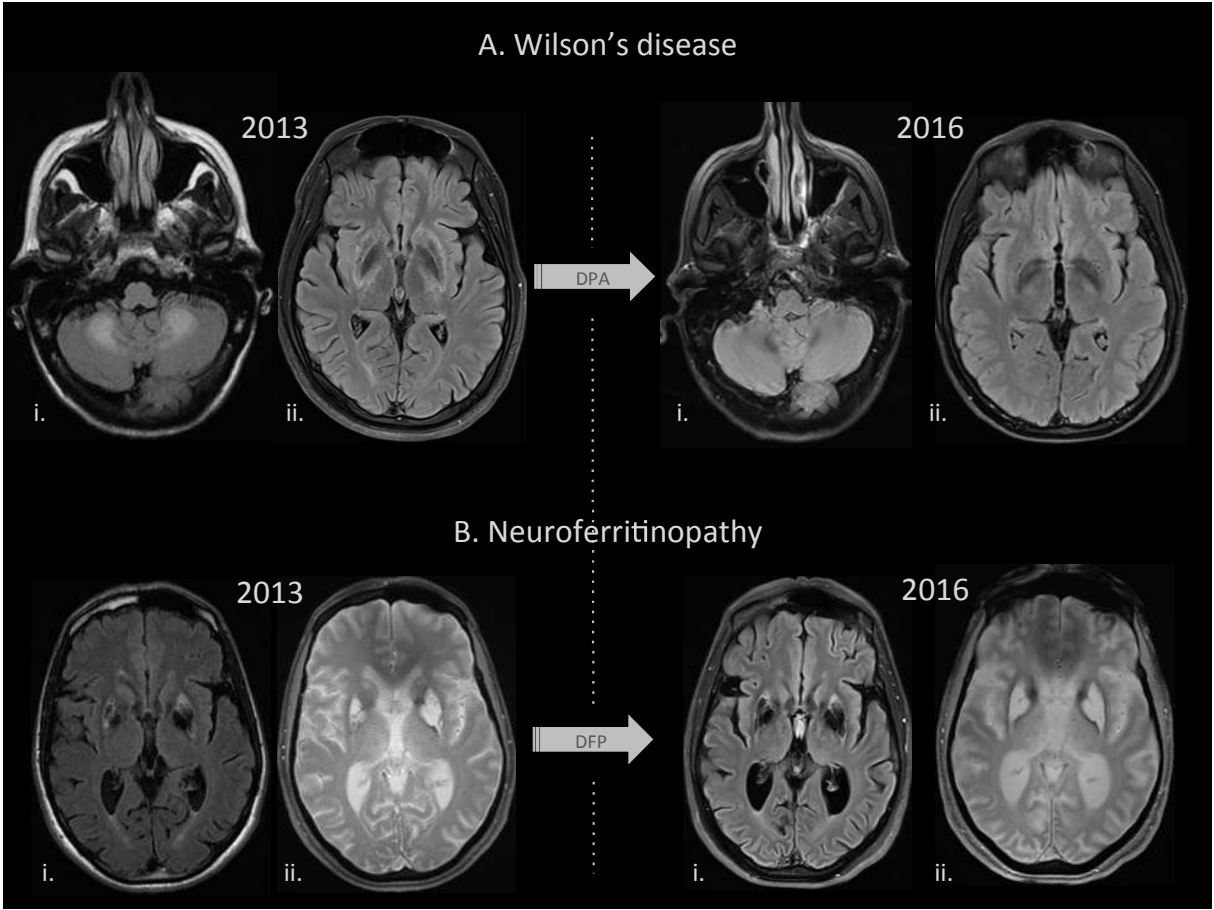
\* Confirms that APP stabilizes ferroportin on the neuronal surface and facilitates iron efflux despite lacking ferroxidase activity.

78. Wan, L., et al., *Overexpression of human wild-type amyloid-beta protein precursor decreases the iron content and increases the oxidative stress of neuroblastoma SH-SY5Y cells*. *J Alzheimers Dis*, 2012. **30**(3): p. 523-30.
  79. Needham, B.E., G.D. Ciccotosto, and R. Cappai, *Combined deletions of amyloid precursor protein and amyloid precursor-like protein 2 reveal different effects on mouse brain metal homeostasis*. *Metallomics*, 2014. **6**(3): p. 598-603.
  80. McCarthy, R.C., Y.H. Park, and D.J. Kosman, *sAPP modulates iron efflux from brain microvascular endothelial cells by stabilizing the ferrous iron exporter ferroportin*. *EMBO Rep*, 2014. **15**(7): p. 809-15.
  81. Wan, L., et al., *beta-Amyloid peptide increases levels of iron content and oxidative stress in human cell and *Caenorhabditis elegans* models of Alzheimer disease*. *Free Radic Biol Med*, 2011. **50**(1): p. 122-9.
  82. Guo, C., et al., *Intranasal deferroxamine reverses iron-induced memory deficits and inhibits amyloidogenic APP processing in a transgenic mouse model of Alzheimer's disease*. *Neurobiol Aging*, 2013. **34**(2): p. 562-75.
  83. Su, X.W., et al., *Serum ferritin is elevated in amyotrophic lateral sclerosis patients*. *Amyotroph Lateral Scler Frontotemporal Degener*, 2015. **16**(1-2): p. 102-7.
  - 84. Veyrat-Durebex, C., et al., *Iron metabolism disturbance in a French cohort of ALS patients*. *Biomed Res Int*, 2014. 2014: p. 485723.**
- \*\* This is the first study to show a higher concentration of serum iron in ALS patients, strengthening the involvement of deregulated iron metabolism in ALS.
85. Nadjar, Y., et al., *Elevated serum ferritin is associated with reduced survival in amyotrophic lateral sclerosis*. *PLoS One*, 2012. **7**(9): p. e45034.
  86. Ikeda, K., et al., *Relationships between disease progression and serum levels of lipid, urate, creatinine and ferritin in Japanese patients with amyotrophic lateral sclerosis: a cross-sectional study*. *Intern Med*, 2012. **51**(12): p. 1501-8.
  87. Ignjatovic, A., et al., *Inappropriately chelated iron in the cerebrospinal fluid of amyotrophic lateral sclerosis patients*. *Amyotroph Lateral Scler*, 2012. **13**(4): p. 357-62.
  88. Langkammer, C., et al., *Mapping of iron deposition in conjunction with assessment of nerve fiber tract integrity in amyotrophic lateral sclerosis*. *J Magn Reson Imaging*, 2010. **31**(6): p. 1339-45.
  89. Kwan, J.Y., et al., *Iron accumulation in deep cortical layers accounts for MRI signal abnormalities in ALS: correlating 7 tesla MRI and pathology*. *PLoS One*, 2012. **7**(4): p. e35241.
  90. Jeong, S.Y., et al., *Dysregulation of iron homeostasis in the CNS contributes to disease progression in a mouse model of amyotrophic lateral sclerosis*. *J Neurosci*, 2009. **29**(3): p. 610-9.
  91. Wang, Q., et al., *Prevention of motor neuron degeneration by novel iron chelators in SOD1(G93A) transgenic mice of amyotrophic lateral sclerosis*. *Neurodegener Dis*, 2011. **8**(5): p. 310-21.
  92. Haraguchi, T., et al., *Coexistence of TDP-43 and tau pathology in neurodegeneration with brain iron accumulation type 1 (NBIA-1, formerly Hallervorden-Spatz syndrome)*. *Neuropathology*, 2011. **31**(5): p. 531-9.
  93. Martinez-Finley, E.J., et al., *Manganese neurotoxicity and the role of reactive oxygen species*. *Free Radic Biol Med*, 2013. **62**: p. 65-75.
  94. Guilarte, T.R., *Manganese neurotoxicity: new perspectives from behavioral, neuroimaging, and neuropathological studies in humans and non-human primates*. *Front Aging Neurosci*, 2013. **5**: p. 23.

95. Klos, K.J., et al., *Brain metal concentrations in chronic liver failure patients with pallidal T1 MRI hyperintensity*. *Neurology*, 2006. **67**(11): p. 1984-9.
96. Shaw, C.A. and L. Tomljenovic, *Aluminum in the central nervous system (CNS): toxicity in humans and animals, vaccine adjuvants, and autoimmunity*. *Immunol Res*, 2013. **56**(2-3): p. 304-16.
97. Andersen, O. and J. Aaseth, *A review of pitfalls and progress in chelation treatment of metal poisonings*. *J Trace Elem Med Biol*, 2016.
98. Sethi, P.K. and D. Khandelwal, *Cadmium exposure: health hazards of silver cottage industry in developing countries*. *J Med Toxicol*, 2006. **2**(1): p. 14-5.
99. Brodtkin, E., et al., *Lead and mercury exposures: interpretation and action*. *CMAJ*, 2007. **176**(1): p. 59-63.
100. Clarkson, T.W., L. Magos, and G.J. Myers, *The toxicology of mercury--current exposures and clinical manifestations*. *N Engl J Med*, 2003. **349**(18): p. 1731-7.

**Figure Legends**

**Figure 1** Examples of brain MRI evolution over three years of chelating treatment metal associated neurological diseases. **A. Wilson’s disease:** bilateral hypersignal in Flair sequences of nuclei dentate (i.) and striatum (ii.). Normalization of brain MRI after three years of chelation by D-Penicillamine (DPA). **B. Neuroferritinopathy:** hyper- and hypo-signal in striatum in Flair sequences (i.) and T2\* (ii.) sequences. Slight worsening of the abnormal signals is observed despite three years of chelation by deferiprone (DFP).



**Table 1** Main characteristics and treatment of poisoning by non-essential heavy metals

<b>Heavy metal</b>	<b>Mode of intoxication</b>	<b>Major sites of accumulation</b>	<b>General presentation</b>	<b>Neurologic presentation</b>	<b>Diagnosis tests</b>	<b>Treatment</b>
Aluminum (Al) [96, 97]	Occupational exposure (inhalation of fumes) Hemodialysis IV boiled methadone	CNS Bones Liver Kidneys	Bone pain Osteomalacia Aplastic bone disease Anaemia	Encephalopathy Seizures Myoclonus Tremor Ataxia Personality changes	Blood Aluminum level	Reduce or remove the source of exposure Chelation by Deferoxamine /Desferrioxamine, deferasirox
Cadmium (Cd) [97, 98]	Chronic Inhalation of fumes or dust (silver jewellery industry)	CNS PNS Kidneys Bones	Renal tubular damage Osteomalacia	Neuropsychiatric manifestations Polyneuropathy	24-hour urinary Cadmium test	Reduce or remove the source of exposure. Discuss chelation by Oral DMSA and/or iv DTPA
Lead (Pb) [97, 99]	Occupational exposure (inhalation) Diet/ ingestion	CNS PNS Liver Kidneys Bone marrow Bone	Digestive signs (abdominal pain, nausea, constipation) Nephropathy Anaemia	Headaches Sleep disturbances Attention deficit Memory disturbances Neuropathy	Blood Lead level	Reduce or remove the source of exposure Discuss chelation by DMSA
Mercury (Hg) [97, 100]	Dental amalgam. Fish consumption (tuna, shark, swordfish)	Gastrointestinal tract CNS PNS Kidneys	Gingivitis Stomatitis Hypersalivation Metallic taste Nephropathy Fatigue	Neuropathy Irritability Tremor Sleep disturbances Memory and concentration deficit	Blood and urine Mercury levels	Reduce or remove the source of exposure Discuss chelation by DMPS

CNS: Central Nervous System; PNS: Peripheral nervous system; DMSA : dimercaptosuccinic acid ; DTPA : Diethylenetriaminepentaacetic acid ; DMPS : dimercaptopropane sulfonate

**Table 2:** Clinical, biochemical, molecular features and treatment options in very rare copper transport disorders.

<b>Disease</b>	<b>Genetic transmission</b>	<b>Molecular defects</b>	<b>Age at diagnosis</b>	<b>Neurological features</b>	<b>Other features</b>	<b>Biochemical findings</b>	<b>Treatment options</b>	<b>Prognosis</b>
<b>Occipital horn syndrome</b> (Elher Danlos syndrome type 9)	X-linked recessive	ATP7A gene	Childhood	Absent or mild dysautonomia Muscle weakness	Occipital exostose, Bladder diverticula, Inguinal hernias, Skin laxity, Hyperelasticity	Serum copper & ceruloplasmin normal or low	Copper replacement discussed	Long-term natural history not known
<b>ATP7A-related distal motor neuropathy</b>	X-linked recessive	ATP7A gene	Adult	Atrophy and weakness of distal muscles in hands and feet, Foot deformities	-	Serum copper & ceruloplasmin normal	Copper replacement discussed	Long-term natural history not known
<b>MEDNIK syndrome</b>	Autosomal recessive	AP1S1 gene	First year of live	Mental retardation Deafness Neuropathy	Enteropathy Ichthyosis Keratoderma	Serum copper & ceruloplasmin low Hepatic copper accumulation	Zinc therapy	Poor
<b>Huppke-Brendl syndrome</b>	Autosomal recessive	SLC33A1 gene	First year of live	Developmental delay, Cerebellar hypoplasia, Hearing loss, Cerebellar hypoplasia and hypomyelination in brain MRI	Congenital cataracts	Serum copper & ceruloplasmin low	None available at present	Poor



**Table 3:** Clinical, biochemical, molecular features and treatment options in very rare Neurodegeneration with Brain Iron Accumulation (NBIA) disorders.

Disease	Genetic transmission	Frequency	Age at diagnosis	Neurological features	MRI characteristics	Neuropathological findings	Treatment options
<b>Pantothenate kinase-associated neurodegeneration (PKAN)</b> (NBIA1)	<i>PANK2</i>	+++	Juvenile to young adulthood	Dystonia Spasticity Parkinsonism Retinopathy	Hypo- with central hyper-intensity of the GP – ‘Eye of the Tiger’	Neuronal loss in GP Reduced myelin Normal SN Widespread gliosis in GP	Baclofen (dystonia) Anti-cholinergic Anti-convulsives (seizures) Benzodiazepines (muscle-relaxation) Iron chelation discussed
<b>PLA2G6-associated neurodegeneration (PLAN)</b> (NBIA2)	<i>PLA2G6</i>	++	Juvenile to young adulthood	Hypotonia Spasticity Dystonia Parkinsonism Optical atrophy	Hypo-intensity of the GP Cerebellar atrophy	Cerebellar, Cortical, GP and Brainstem atrophy	Levodopa/carbidopa (parkinsonism) Baclofen (dystonia) Anti-convulsives (seizures) Benzodiazepines (muscle-relaxation) Iron chelation discussed
<b>Neuroferritinopathy</b> (NBIA3)	<i>FTL</i>	+	Adult	Dystonia Spasticity Parkinsonism	Hypo- and – hyper-intensity of basal ganglia, in particular the GP and SN	Atrophy mostly in Putamen and Cerebellum but also SN Some gliosis	Same as PLAN
<b>Mitochondrial membrane-associated neurodegeneration (MPAN)</b> (NBIA4)	<i>C19orf12</i>	++	Juvenile to young adulthood	Dystonia Spasticity Parkinsonism Optical atrophy	Hypo- and hyper-intensity of the GP Hypo- intensity of the SN. Streaking of MML	Neuronal loss in GP Reduced myelin SN and GP atrophy Widespread gliosis	Same as PLAN

<b>COASY protein-associated neurodegeneration (CoPAN)</b>	<i>COASY</i>	+	Childhood	Dystonia Spasticity Dysarthria Parkinsonism Optical atrophy	Hypo- with central hyper-intensity of the GP	Neuronal loss in GP Reduced myelin Widespread GP gliosis (Similar to PKAN)	Same as PLAN
<b>FA2H-associated neurodegeneration (FAHN)</b>	<i>FA2H</i>	+	Juvenile to young adulthood	Dystonia Ataxia Spasticity	Hypo-intensity of the GP Cerebellar and cortical atrophy	White matter lesions and demyelination Brainstem atrophy	Same as PLAN
<b>Aceruloplasminaemia</b>	<i>CP</i>	+	Adult	Dystonia Dyskinesia Cerebellar ataxia Cognitive impairment	Hyper-intensity of striatum, thalamus and dentate	Severe neuronal atrophy in Putamen and Dentate Nucleus. Atrophy in GP, SN, Cortex & Cerebellum (Purkinje) Widespread gliosis	Same as PLAN CP supplementation discussed
<b><math>\beta</math>-propeller-associated neurodegeneration (BPAN)</b>	<i>WDR45</i>	++	Childhood	Parkinsonism Dystonia Cognitive impairment	Hypo-intensity of the GP/SN with central hyper-intense line Cerebral and Cerebellar atrophy	Neuronal loss in SN & GP Cerebellar atrophy in Purkinje and granular layers Cortical atrophy Gliosis in Putamen and Thalamus	Same as PLAN

GP: globus pallidus; SN: Substantia nigra; MML: Medial medullary lamina

