

## Safety profile and probe placement accuracy of intraspinal pressure monitoring for traumatic spinal cord injury: Injured Spinal Cord Pressure Evaluation study

Isaac Phang, MRCS,<sup>1</sup> Argyro Zoumprouli, MD,<sup>2</sup> Samira Saadoun, PhD,<sup>1</sup> and Marios C. Papadopoulos, MD, FRCS(SN)<sup>1</sup>

<sup>1</sup>Academic Neurosurgery Unit, St. George's, University of London; and <sup>2</sup>Neurointensive Care Unit, St. George's Hospital, London, United Kingdom

**OBJECTIVE** A novel technique for monitoring intraspinal pressure and spinal cord perfusion pressure in patients with traumatic spinal cord injury was recently described. This is analogous to monitoring intracranial pressure and cerebral perfusion pressure in patients with traumatic brain injury. Because intraspinal pressure monitoring is a new technique, its safety profile and impact on early patient care and long-term outcome after traumatic spinal cord injury are unknown. The object of this study is to review all patients who had intraspinal pressure monitoring to date at the authors' institution in order to define the accuracy of intraspinal pressure probe placement and the safety of the technique.

**METHODS** At the end of surgery to fix spinal fractures, a pressure probe was inserted intradurally to monitor intraspinal pressure at the injury site. Postoperatively, CT scanning was performed within 48 hours and MRI at 2 weeks and 6 months. Neurointensive care management and complications were reviewed. The American Spinal Injury Association Impairment Scale (AIS) grade was determined on admission and at 2 to 4 weeks and 12 to 18 months postoperation.

**RESULTS** To date, 42 patients with severe traumatic spinal cord injuries (AIS Grades A–C) had undergone intraspinal pressure monitoring. Monitoring started within 72 hours of injury and continued for up to a week. Based on postoperative CT and MRI, the probe position was acceptable in all patients, i.e., the probe was located at the site of maximum spinal cord swelling. Complications were probe displacement in 1 of 42 patients (2.4%), CSF leakage that required wound resuturing in 3 of 42 patients (7.1%), and asymptomatic pseudomeningocele that was diagnosed in 8 of 42 patients (19.0%). Pseudomeningocele was diagnosed on MRI and resolved within 6 months in all patients. Based on the MRI and neurological examination results, there were no serious probe-related complications such as meningitis, wound infection, hematoma, wound breakdown, or neurological deterioration. Within 2 weeks postoperatively, 75% of patients were extubated and 25% underwent tracheostomy. Norepinephrine was used to support blood pressure without complications. Overall, the mean intraspinal pressure was around 20 mm Hg, and the mean spinal cord perfusion pressure was around 70 mm Hg. In laminectomized patients, the intraspinal pressure was significantly higher in the supine than lateral position by up to 18 mm Hg after thoracic laminectomy and 8 mm Hg after cervical laminectomy. At 12 to 18 months, 11.4% of patients had improved by 1 AIS grade and 14.3% by at least 2 AIS grades.

**CONCLUSIONS** These data suggest that after traumatic spinal cord injury intradural placement of the pressure probe is accurate and intraspinal pressure monitoring is safe for up to a week. In patients with spinal cord injury who had laminectomy, the supine position should be avoided in order to prevent rises in intraspinal pressure.

<http://thejns.org/doi/abs/10.3171/2016.1.SPINE151317>

**KEY WORDS** critical care; monitoring; paralysis; perfusion pressure; spinal cord injury; trauma

**M**ONITORING intracranial pressure (ICP) by inserting a pressure probe into the brain parenchyma is central to the management of patients with traumatic brain injury (TBI).<sup>4,14</sup> ICP is used to compute cere-

bral perfusion pressure (CPP) as the mean arterial pressure (MAP) minus ICP. Management aims to reduce elevated ICP and optimize CPP in order to prevent secondary ischemic brain damage. In contrast to TBI, in traumatic spinal

**ABBREVIATIONS** AIS = American Spinal Injury Association Impairment Scale; ASIA = American Spinal Injury Association; CPP = cerebral perfusion pressure; CPPopt = optimum cerebral perfusion pressure; ICP = intracranial pressure; ISP = intraspinal pressure; MAP = mean arterial pressure; NBD = Neurogenic Bowel Dysfunction; NICU = neurointensive care unit; SCIM III = Spinal Cord Independence Measure III; SCPP = spinal cord perfusion pressure; SCPPopt = optimum spinal cord perfusion pressure; TBI = traumatic brain injury; TSCI = traumatic spinal cord injury; WISCI II = Walking Index for Spinal Cord Injury.

**SUBMITTED** November 5, 2015. **ACCEPTED** January 26, 2016.

**INCLUDE WHEN CITING** Published online April 29, 2016; DOI: 10.3171/2016.1.SPINE151317.

cord injury (TSCI) there is currently no monitoring from the injury site in clinical use to guide the management. As a result, the surgical and anesthetic management of TSCI is variable.<sup>27</sup>

In 2008, we showed that intraspinal pressure (ISP) is elevated after TSCI at the injury site in mice.<sup>22</sup> We subsequently introduced a technique to monitor ISP in patients with TSCI and thus compute spinal cord perfusion pressure (SCPP) as MAP minus ISP.<sup>26</sup> Our analysis shows that the ISP and SCPP waveforms after TSCI have similar characteristics as the ISP and CPP waveforms after TBI, respectively.<sup>24</sup> We, therefore, proposed that the concepts of pressure reactivity (quantified using PRx), optimum cerebral perfusion pressure (CPP<sub>opt</sub>), and compensatory reserve (quantified using RAP), which had been developed for TBI, could also be applied to the damaged spinal cord to yield spinal pressure reactivity (sPRx), optimum spinal cord perfusion pressure (SCPP<sub>opt</sub>), and spinal compensatory reserve (sRAP). After TSCI, bony decompression (i.e., realignment of the fracture and laminectomy) does not effectively reduce the elevated ISP at the injury site.<sup>26</sup> Our data showed that in addition to bony decompression, expansion duraplasty was also required to effectively reduce ISP, increase SCPP, and improve the pressure reactivity at the injury site.<sup>20</sup> Laminectomy with duraplasty after TSCI is analogous to decompressive craniectomy after TBI, which involves not only bony but also dural decompression. The dura is a major, but unappreciated, cause of spinal cord compression after TSCI<sup>18</sup> and may explain why the benefits of early bony decompression (without opening the dura) after TSCI remain controversial.<sup>23</sup>

To monitor ISP, we place a pressure probe intradurally at the injury site using a microscope at the end of posterior spinal fixation.<sup>26</sup> Our data suggest that, at the injury site, subdural ISP is the same as intraparenchymal ISP.<sup>18</sup> It is important to note that ISP at the injury site, where the spinal cord is swollen and compressed against the dura, is different from subdural pressure above or below the injury site and extradural pressure.<sup>18,19,26</sup> The positioning of the ISP probe is, therefore, crucial for accurate measurement of ISP. Since ISP monitoring is invasive there are potential risks, including CSF leakage, pseudomeningocele, CSF or wound infection, spinal cord damage, and hematoma at the injury site. It is also possible that ISP monitoring compromises the care of TSCI patients indirectly, e.g., by prolonging intubation or increasing complications from inotrope use. To date, we have monitored ISP from 42 patients with severe TSCI. Here, we report the accuracy of ISP probe placement and the safety of ISP monitoring.

## Methods

### Institutional Research Board Approval

Approvals for the Injured Spinal Cord Pressure Evaluation study, including the patient information sheet and informed consent form, were obtained from St. George's Joint Research Office and the National Research Ethics Service London—St. Giles Committee. Informed consent was obtained from all patients recruited in the study. Online details are available at [http://elvlm1.co.uk/?page\\_id=73](http://elvlm1.co.uk/?page_id=73).

### Patient Recruitment

Inclusion criteria are: 1) severe TSCI defined as American Spinal Injury Association (ASIA) Impairment Scale (AIS) Grade A, B, or C; 2) age 18 to 70 years; and 3) timing between TSCI and surgery not more than 72 hours. All types of spine trauma were included, including compression, distraction, and rotation. Exclusion criteria are: 1) patients unable to provide consent; 2) other major injuries or comorbidities; and 3) penetrating spinal cord injury. Surgery and early management took place at the neurosurgery unit of St. George's Hospital, a tertiary referral center that covers a population of about 2.5 million in southwest London. Recruitment into the study was discussed with eligible patients and their families on admission, and the patient information sheet was given.

### Surgical Technique

All patients underwent spinal realignment and fixation via a posterior approach. Spinal fixation involved lateral mass screws for cervical injuries and pedicle screws for thoracolumbar injuries. Four of 42 patients underwent additional anterior cervical fixation with plate and screws. For anterior cord compression in the thoracolumbar spine, the surgeon would push the bone fragments from the spinal canal back into the vertebral body via a posterior approach. Following posterior spinal fixation, a Codman Microsensor Transducer (DePuy Synthes) was tunneled through the skin with a 14-gauge introducer. The Codman probe is not labeled for ISP monitoring, as used here. The dura was perforated 1 level below the injury with a 21-gauge needle bent at 90° to prevent damage to the underlying spinal cord. After calibration, the Codman probe was advanced through the dural perforation in the subdural space under the operating microscope until the probe tip was at the level of the injury based on the measurements on the MR scan and ISP recordings. Fibrin glue (Tisseel) was placed on the dura. A wound drain was inserted superficial to the lumbar fascia and allowed to drain under gravity. The Codman probe was secured to the skin with multiple silk sutures, including a tightening stitch around the exit site to prevent CSF leakage.

### Signal Recording

The ISP probe was connected to a Codman ICP box linked via an ML 221 amplifier to a PowerLab running LabChart (version 7.3.5, AD Instruments). Arterial blood pressure was recorded from a radial artery catheter connected to the Philips Intellivue MX800 bedside monitoring system (Philips), which was in turn connected to the PowerLab system. The ISP and arterial blood pressure signals were sampled at 100 Hz or 1 kHz for up to 7 days after surgery. LabChart was used to analyze the signals and compute SCPP, which was defined as MAP minus ISP.

### Thromboprophylaxis

Preoperative thromboprophylaxis was achieved by using antiembolism stockings and intermittent pneumatic foot compression. Postoperatively, in addition to compression stockings, a daily dose of 5000 U of dalteparin sodium was administered subcutaneously starting at 24

hours after surgery. The dalteparin dose was omitted for 24 hours before ISP probe removal.

### Inotropes and Target MAP

Neurointensivists were blind to the ISP and SCPP readings and, therefore, no treatment was initiated in response to changes in these pressures. For the first 28 patients, MAP was treated with norepinephrine according to the neurointensivists' preferences. In the UK, such MAP management is variable.<sup>27</sup> For the next 14 patients, a norepinephrine infusion was administered to support a target MAP of more than 80 mm Hg. Serum lactate and base excess were checked via arterial blood gas analysis at least 3 times per day to assess end-organ ischemia.

### Patient Positioning

Patients were turned from supine to lateral and vice versa every 2 to 3 hours to prevent the development of pressure ulcers. Lateral positioning was achieved by placing 2 or more pillows behind the patient's back to avoid external compression to the wound. The difference in ISP recorded on the observation chart between each turn was averaged for the different injury groups: 1) cervical with laminectomy; 2) cervical without laminectomy; 3) thoracic with laminectomy; and 4) thoracic without laminectomy.

### Patient Imaging

CT and MR scanning of the whole spine were done on admission. Another CT scan was obtained within 48 hours of ISP probe insertion to check the screw and probe positions. An MR scan of the injured spinal cord was obtained at about 2 weeks (i.e., after removing the ISP probe) and 6 to 12 months after surgery.

### Neurological Assessments

A full neurological examination according to the International Standards for Neurological Classification of Spinal Cord Injury was performed on admission, at 2 weeks postoperatively (i.e., before discharge to the rehabilitation facility), and at the outpatient follow-up at 12 to 18 months. At the outpatient follow-up, additional information was collected using the Walking Index for Spinal Cord Injury score (WISCI II),<sup>10</sup> Neurogenic Bowel Dysfunction (NBD) scale,<sup>17</sup> and the sphincter management section of the Spinal Cord Independence Measure III (SCIM III) scale.<sup>1</sup>

### Probe Placement Analysis

The ISP probe was visualized on the postoperative CT scan. The 2-week postoperative MR scan was then compared with the postoperative CT scan. On the 2-week postoperative T2-weighted, midline sagittal MR scan, the injury site was divided into 3 zones. Zone 1 has no CSF signal between the swollen, injured spinal cord and the dura. In Zone 2, which lies on either side of Zone 1, the thickness of the CSF space around the cord is < 50% normal. Zone 3 lies next to Zone 2, away from the injury, and has normal CSF space around the cord. We determined the probe tip position to be adequate/good in Zone 1, adequate/fair in Zone 2, and inadequate in Zone 3.

### Clinical Data Collection

Neurointensive care unit (NICU) nursing charts, drug administration charts, scans, serum biochemistry, and arterial blood gas data were reviewed. Probe-related and nonrelated complications were charted prospectively and reported to the ethics committee. Patient position (supine, lateral) was recorded hourly by the NICU nurse who was looking after the patient.

### Statistics

The 1-sample t-test was performed using Excel 2010 to compare the changes in ISP in the supine versus lateral position. Statistical significance was taken at  $p < 0.05$ .

## Results

### Patient Characteristics

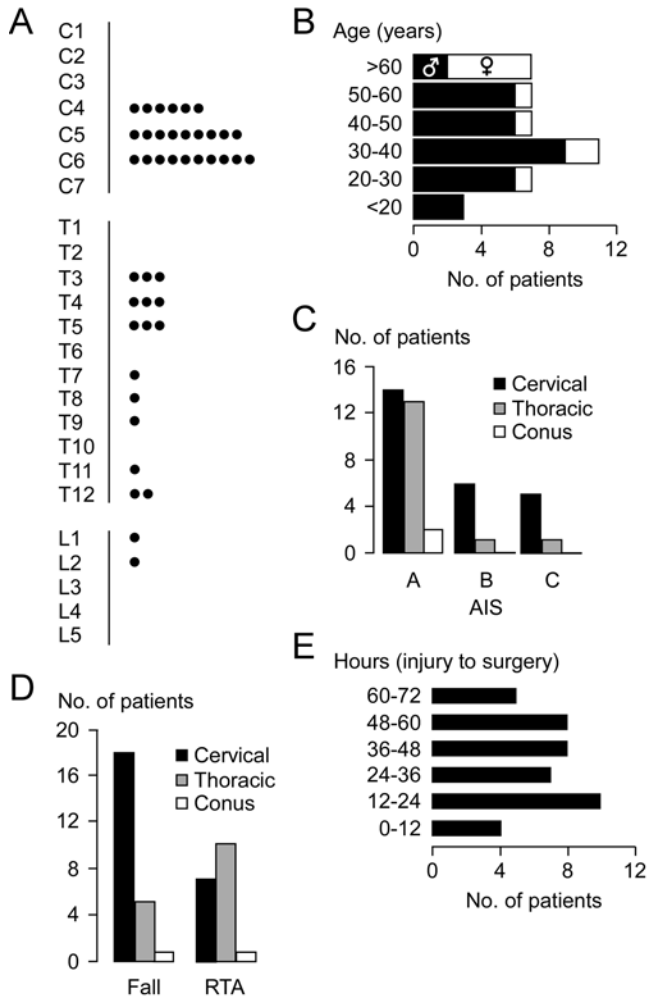
We had 25 (59.5%) cervical, 15 (35.7%) thoracic, and 2 (4.8%) conus medullaris spinal cord injuries (Fig. 1A). The most commonly injured levels were C-5 and C-6. Two-thirds (28 of 42) of the patients were younger than 50 years, and the most frequently injured group was 30- to 40-year-old individuals (Fig. 1B). Overall, the male-to-female ratio was about 3:1: the male-to-female ratio was higher for patients younger than 50 years (7:1), but females predominated with a male-to-female ratio of 2:5 in those older than 50 years. Figure 1C shows the severity of TSCI for each spinal level. Thirteen of 25 (52.0%) cervical TSCIs were classified as AIS Grade A on admission compared with 13 of 15 (76.7%) thoracic TSCIs and 2 of 2 (100%) conus medullaris TSCIs. Overall, 24 of 42 (57.1%) patients had a fall and 18 of 42 (42.9%) had a road traffic accident (Fig. 1D). The most common cause of injury was a fall in cervical TSCI patients (18 of 25 patients; 72.0%) and a road traffic accident in thoracic TSCI patients (10 of 15 patients; 66.7%). Figure 1E shows the hours from injury to surgery, which ranged from 9 to 72 hours with a median of 37 hours.

### Probe Position

Figure 2A and B illustrate the method used to determine the probe position and the definition of the 3 zones in relation to the CSF space around the injured spinal cord. Probe position was adequate in all patients, good in 82%, and fair in 18% (Fig. 2C).

### NICU Management

On average, ISP was approximately 20 mm Hg, MAP was approximately 90 mm Hg, and SCPP was approximately 70 mm Hg during the 7-day monitoring period, with considerable interpatient variability (Fig. 3A). In patients who underwent laminectomy, ISP was significantly higher in the supine compared with the lateral position (Fig. 3B). The average difference in ISP between supine versus lateral patient position ( $\Delta$ ISP) was approximately 2 mm Hg for patients with thoracic laminectomies versus 1 mm Hg for patients with cervical laminectomies. After thoracic laminectomies,  $\Delta$ ISP was up to 18 mm Hg, and  $\Delta$ ISP was up to 8 mm Hg after cervical laminectomies. An increase in ISP while lying supine was observed in all



**FIG. 1.** Patient details. **A:** Neurological level of injury. Each dot represents a different patient. **B:** Age and sex. **C:** Level of injury grouped by AIS grade. **D:** Level of injury grouped by mechanism of injury. **E:** Time from injury to surgery. RTA = road traffic accident.

laminectomy patients, regardless of the type of fracture and regardless of anterior decompression. Postoperative MRI ruled out the presence of hematoma compressing the injured spinal cord. Within 2 weeks, all patients were extubated, though about a quarter received a tracheostomy (Fig. 3C). Tracheostomy was required in 28% of patients with cervical injuries compared with 13% patients with thoracic injuries. Two of 9 (22.2%) patients who had a tracheostomy had lung contusions and/or pneumothorax that was evident on the chest CT scan done on admission. Overall, 9.5% (4 of 42) of our patients required a chest drain. Figure 3D–F summarize the use of norepinephrine, as well as the base excess and lactate concentrations as determined from the arterial blood samples.

**Complications**

Table 1 lists the complications, including those associated with probe insertion as well as other complications. In 3 of 42 patients, we observed CSF leakage from the probe skin site once the probe was removed. In all pa-

**TABLE 1. Complications in TSCI patients who underwent ISP monitoring**

Complication	No. of Patients (%)
<b>Associated w/ ISP probe insertion</b>	
CSF leakage*	3 (7.6)
Probe dislodged	1 (2.9)
Pseudomeningocele†	8 (19.0)
Probe-associated hematoma‡	0 (0.0)
Meningitis	0 (0.0)
<b>Not associated w/ ISP probe insertion</b>	
Deep venous thrombosis/pulmonary embolus§	1 (2.9)
Pneumonia	26 (61.9)
Traumatic vascular injury¶	2 (5.8)
Wound infection	0 (0.0)
Pressure ulcer	3 (7.1)

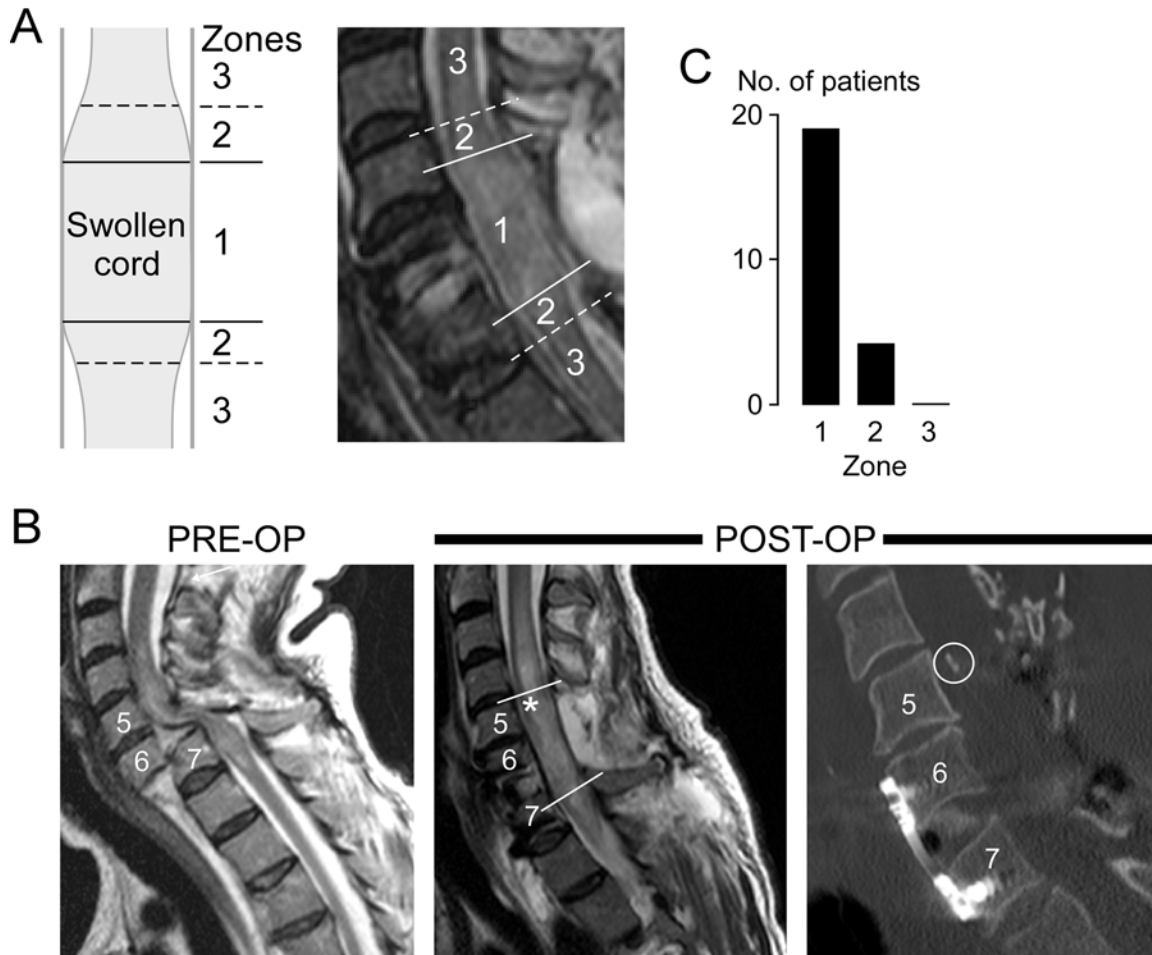
\* Resolved by suturing the wound (2 patients) or lumbar drainage (1 patient).  
 † Evident on MR image obtained within 2 weeks of surgery. In all patients, the pseudomeningocele resolved based on MR done at 3 to 6 months.  
 ‡ Data from 23 of 42 patients.  
 § Patient died suddenly of a pulmonary embolus at 28 days after TSCI.  
 ¶ One AIS Grade B patient had vertebral artery dissection causing impairment of arm motor function but had a full recovery at 2 months. One AIS Grade B patient had sensory deterioration due to vascular injury, without change in AIS grade.

tients, the CSF leaks settled after suturing the skin. In 19% of patients, we observed a pseudomeningocele on the MR scan obtained at 2 weeks after surgery, which disappeared in all patients on the MR scan obtained at 6 months. The pseudomeningocele was a radiological complication and did not appear to compress the spinal cord in any of the patients. There were no serious probe-related complications such as meningitis, wound infection, or spinal cord hematoma. Table 1 also lists the complications not associated with probe insertion. Such complications were related to the initial trauma, immobility, and intubation/ventilation. The only technical problem associated with data collection was the occasional disconnection of the monitoring equipment.

**Neurological Outcome**

We assessed neurological outcome using the AIS grade when the patients were discharged from the neurosurgery unit (Table 2) and at 12 to 18 months later (Table 3). Overall, about 10% of our patients improved by the time they were discharged from neurosurgery: 7.1% of patients improved by 1 AIS grade, and 2.4% improved by 2 AIS grades. At 12 to 18 months, about a quarter of our patients improved neurologically: 11.4% of patients improved by 1 AIS grade, and 14.3% improved by 2 or more AIS grades. Improvement by at least 1 AIS grade was inversely correlated with AIS on admission: improvement was seen in 8.3% of AIS Grade A patients compared with 63.6% of AIS Grade B or C patients. The Supplemental Data show additional outcome measures at 12 to 18 months based on the sphincter management section of SCIM III, NBD, and WISCI II.





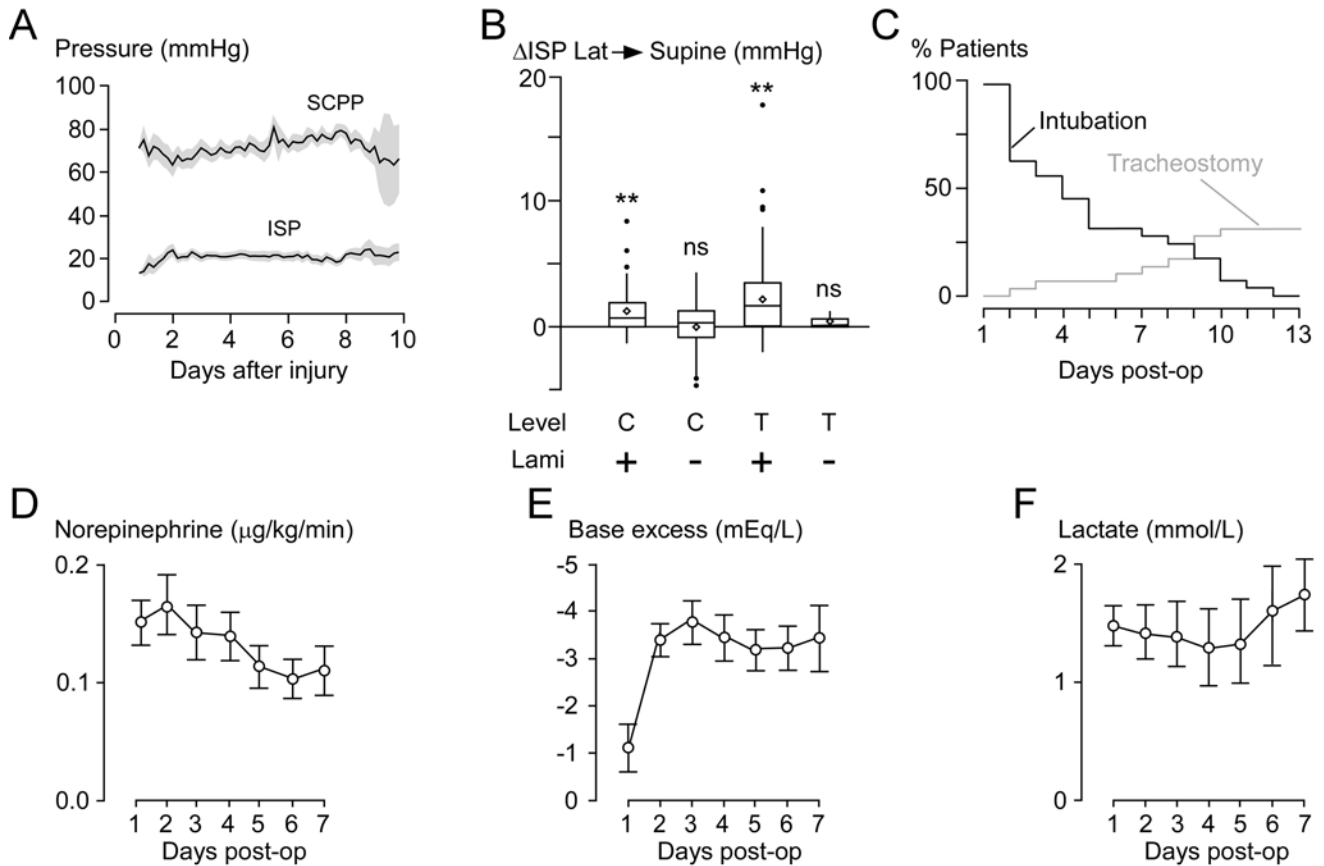
**FIG. 2.** Accuracy of ISP probe placement. **A:** Schematic showing Zones 1 to 3 (left), and representative postoperative sagittal, midline, T2-weighted MRI showing a swollen spinal cord at the level of injury and Zones 1 to 3 (right). **B:** Preoperative sagittal T2-weighted MR image (left), postoperative sagittal T2-weighted MR image at 2 weeks showing the swollen spinal cord (center), and postoperative sagittal CT reconstruction showing the ISP probe (right). The asterisk and circle indicate the position of the ISP probe. **C:** The position of the ISP probe in Zones 1, 2, and 3. Overall, 33% (14 of 42) of patients had no postoperative MRI and 12% (5 of 42) had postoperative MR imaging results that were uninterpretable due to artifacts.

## Discussion

Our key finding is that ISP monitoring is safe. Probe-related complications were CSF leakage from the probe's skin exit site that resolved with suturing and asymptomatic pseudomeningocele that resolved within 6 months. We did not encounter serious complications such as meningitis or spinal cord damage. By comparison, ICP monitoring for brain injury causes intracerebral hematoma in 1.1% to 4.1%<sup>3,12,16</sup> of patients and CSF infection in 0.6% to 7.4% of patients.<sup>3,16,21</sup> ISP monitoring may have a better profile for serious complications than ICP monitoring because the ISP probe is subdural and inserted under direct vision using a microscope, whereas the ICP probe is intraparenchymal and inserted blindly through a twist-drill craniostomy. After the ISP probe was removed, CSF-related complications that were easily treatable or did not require treatment occurred in 28.8% of patients. In contrast, CSF-related complications are uncommon after the ICP probes are removed.<sup>3,16,21</sup> In all patients, the AIS grade at 2 weeks

was the same or better than preoperatively. Therefore, spinal fixation surgery, including probe insertion, did not cause neurological deterioration.

We also assessed NICU management and related complications. As expected for intubated patients, chest infections were common.<sup>13</sup> Though most of our patients were extubated within 2 weeks, a quarter required a tracheostomy. In general, tracheostomy was performed in patients with cervical spinal cord injuries and those with lung contusions. These findings are comparable with published series in which the mean time to extubation was 5 days<sup>5</sup> and 81% of complete cervical SCI patients required tracheostomy.<sup>7</sup> We intentionally did not set ISP or SCPP targets in order to study the injured spinal cord over a range of ISPs and SCPPs. Norepinephrine was used to support blood pressure during 75% (3096 of 4108 hours) of monitored hours without associated complications. By comparison, Inoue et al. reported complications with dopamine or phenylephrine usage such as arrhythmias, acidosis, and skin necrosis.<sup>15</sup> In our laminectomized patients,



**FIG. 3.** Neurointensive care management. **A:** ISP and SCPP versus days after injury (mean ± SEM of 42 patients) **B:** Change in ISP ( $\Delta$ ISP) during patient positioning from lateral to supine in cervical patients with laminectomy (n = 194), cervical patients without laminectomy (n = 183), thoracic patients with laminectomy (n = 278), and thoracic patients without laminectomy (n = 13). Box-and-whisker plot showing the median (horizontal line), mean (diamond), interquartile range (box), 95% confidence interval (whiskers), and outliers (dots). + = laminectomy performed; - = no laminectomy performed; ns = not significant; p = 0.36 for the cervical level; p = 0.34 for the thoracic level; \*\*p < 0.001. **C:** Cumulative frequency of intubated and tracheostomy patients. **D:** Postoperative use of norepinephrine (mean ± SEM). Norepinephrine was used on 145 of 266 monitoring days. Data are missing for 4 of 42 patients. **E:** Postoperative base excess (mean ± SEM). **F:** Postoperative arterial lactate (mean ± SEM).

ISP was significantly higher in the supine than the lateral position by up to 8 mm Hg for cervical injuries and 18 mm Hg for thoracic injuries. This finding has important implications for nursing care: we recommend avoiding wound compression (e.g., by avoiding the supine position or by placing a ring-shaped pillow around the wound). Together, our data suggest that placing an ISP probe may help guide NICU medical and nursing management without major complications.

Even though the ISP probe may not cause detectable spinal cord damage during the monitoring period, the probe

may compromise the long-term recovery of patients. We, therefore, determined the AIS grades of the patients who had ISP monitoring at 12 to 18 months following TSCI. Our data show that the improvements in AIS grades in our patients were comparable to the improvements reported in other series.<sup>8,11</sup> We did not expect improved recovery in our patients, in comparison with published series, because our ISP monitoring study was observational without set ISP or SCPP targets. Though our data suggest that plac-

**TABLE 2.** AIS on admission versus at 2 weeks after surgery

AIS Grade on Admission	AIS Grade at 2 Wks After Surgery*				
	A	B	C	D	E
A	27 (93.1)	2 (7)	0 (0.0)	0 (0.0)	0 (0.0)
B	0 (0.0)	7 (88)	0 (0.0)	1 (13)	0 (0.0)
C	0 (0.0)	0 (0.0)	4 (80)	1 (20)	0 (0.0)

\* Values are shown as the number of patients (%).

**TABLE 3.** AIS on admission versus 12 to 18 months after surgery

AIS Grade on Admission	AIS Grade at 12–18 Mos After Surgery*				
	A	B	C	D	E
A	22 (91.7)	0 (0.0)	0 (0.0)	2 (8.7)	0 (0.0)
B	0 (0.0)	2 (33.3)	1 (16.7)	3 (50.0)	0 (0.0)
C	0 (0.0)	0 (0.0)	2 (40.0)	3 (60.0)	0 (0.0)

\* Values are shown as the number of patients (%). Seven of 42 patients have not reached the 12- to 18-month follow-up, and therefore only 35 of 42 patients are included.

ing an ISP probe is safe, a randomized controlled trial is necessary to definitively conclude that the probe did not compromise long-term recovery.

In earlier studies,<sup>18,19,26</sup> we showed that, after TSCI, 3 intradural compartments form with different pressure profiles: above the injury, at the injury site (where the swollen cord is compressed against dura), and below the injury site. The ISP probe should be placed at the site of injury to monitor the maximum ISP. Technical nuances include measuring the insertion distance on the MR scan and monitoring ISP while inserting the probe. The postoperative CT scans show that ISP probe placement accuracy was adequate in all patients. Intraoperative fluoroscopy could not be used to guide probe insertion because the Codman probe was invisible on fluoroscopy. The chance of probe dislodgment was minimized by suturing the probe to the skin at multiple sites and placing a large, adherent Ioban drape over the probe. By placing a suture at the probe's skin exit site, we eliminated the risk of CSF leakage around the probe.

There is controversy about whether aiming for universal CPP targets with ICP monitoring improves outcome after TBI.<sup>6</sup> Such controversy led to the idea that CPP<sub>opt</sub> is not the same in all patients. It has been suggested that, after TBI, NICU treatment should become individualized based on each patient's CPP<sub>opt</sub>.<sup>2,9</sup> The CPP<sub>opt</sub> for a patient can be defined as the CPP that minimizes PRx: i.e., maximizes vascular pressure reactivity. There were no ISP or SCPP targets in our studies because we have not yet determined the optimal ISP and SCPP after TSCI. Currently, in the UK, arterial blood pressure management after TSCI is variable,<sup>27</sup> whereas in the US the guidelines of the American Association of Neurological Surgeons of 85–90 mm Hg MAP are usually followed.<sup>25</sup> Intervening to elevate the blood pressure without monitoring ISP and SCPP from the injury site is potentially dangerous due to cardiogenic complications.<sup>15</sup> From our experience with ISP/SCPP monitoring, and by analogy with the concept of individualized CPP<sub>opt</sub> in TBI, it seems that SCPP<sub>opt</sub> varies between patients, thus suggesting individualized SCPP management rather than setting generalized guidelines.<sup>20</sup> Currently, ICP monitoring and CPP optimization are the standard of care when managing severe TBI patients in developed countries. Based on our earlier studies<sup>19,20,24,26</sup> and the safety profile of ISP monitoring shown here, we hope that our ISP monitoring technique is used by other centers. Ultimately, a randomized controlled trial is warranted to determine if ISP monitoring and SCPP optimization improve outcome after TSCI.

## Conclusions

After TSCI, intradural placement of the pressure probe is accurate and ISP monitoring for up to a week is safe. In patients with spinal cord injury who underwent laminectomy, the supine position should be avoided to prevent rises in ISP at the injury site.

## Acknowledgments

We thank the neurosurgeons at St. George's Hospital, King's College Hospital, and Hurstwood Park Neurological Centre for help with patient recruitment. We also thank the neuroanesthesia,

operating room, and NICU staff at St. George's Hospital for help with data collection. This study was supported by Wings for Life Spinal Cord Research Foundation (M.C.P. and S.S.), Fletcher Fund/Neurosciences Research Foundation (M.C.P.), and London Deanery (I.P.).

## References

1. Ackerman P, Morrison SA, McDowell S, Vazquez L: Using the Spinal Cord Independence Measure III to measure functional recovery in a post-acute spinal cord injury program. *Spinal Cord* **48**:380–387, 2010
2. Aries MJ, Czosnyka M, Budohoski KP, Steiner LA, Lavinio A, Koliass AG, et al: Continuous determination of optimal cerebral perfusion pressure in traumatic brain injury. *Crit Care Med* **40**:2456–2463, 2012
3. Bekar A, Doğan S, Abaş F, Caner B, Korfali G, Kocaeli H, et al: Risk factors and complications of intracranial pressure monitoring with a fiberoptic device. *J Clin Neurosci* **16**:236–240, 2009
4. Bratton S, Chestnut R, Ghajar J, McConnell Hammond FF, Harris OA, et al: Guidelines for the Management of Severe Traumatic Brain Injury, 3rd Edition. *J Neurotrauma* **24** (Suppl 1):S1–S106, 2007
5. Call MS, Kutcher ME, Izenberg RA, Singh T, Cohen MJ: Spinal cord injury: outcomes of ventilatory weaning and extubation. *J Trauma* **71**:1673–1679, 2011
6. Chesnut RM, Temkin N, Carney N, Dikmen S, Rondina C, Videtta W, et al: A trial of intracranial-pressure monitoring in traumatic brain injury. *N Engl J Med* **367**:2471–2481, 2012
7. Como JJ, Sutton ERH, McCunn M, Dutton RP, Johnson SB, Aarabi B, et al: Characterizing the need for mechanical ventilation following cervical spinal cord injury with neurologic deficit. *J Trauma* **59**:912–916, 2005
8. Curt A, Van Hedel HJ, Klaus D, Dietz V: Recovery from a spinal cord injury: significance of compensation, neural plasticity, and repair. *J Neurotrauma* **25**:677–685, 2008
9. Czosnyka M, Smielewski P, Timofeev I, Lavinio A, Guazzo E, Hutchinson P, et al: Intracranial pressure: more than a number. *Neurosurg Focus* **22**(5):E10, 2007
10. Ditunno JFJ Jr, Ditunno PL, Graziani V, Scivoletto G, Bernardi M, Castellano V, et al: Walking index for spinal cord injury (WISCI): an international multicenter validity and reliability study. *Spinal Cord* **38**:234–243, 2000
11. Fehlings MG, Vaccaro A, Wilson JR, Singh A, W Cadotte D, Harrop JS, et al: Early versus delayed decompression for traumatic cervical spinal cord injury: results of the Surgical Timing in Acute Spinal Cord Injury Study (STASCIS). *PLoS One* **7**:e32037, 2012
12. Gelabert-González M, Ginesta-Galan V, Sernamito-García R, Allut AG, Bandin-Diéguez J, Rumbo RM: The Camino intracranial pressure device in clinical practice. Assessment in a 1000 cases. *Acta Neurochir (Wien)* **148**:435–441, 2006
13. Hunter JD: Ventilator associated pneumonia. *BMJ* **344**:e3325, 2012
14. Hutchinson PJ, Koliass AG, Czosnyka M, Kirkpatrick PJ, Pickard JD, Menon DK: Intracranial pressure monitoring in severe traumatic brain injury. *BMJ* **346**:f1000, 2013
15. Inoue T, Manley GT, Patel N, Whetstone WD: Medical and surgical management after spinal cord injury: vasopressor usage, early surgery, and complications. *J Neurotrauma* **31**:284–291, 2014
16. Koskinen LO, Grayson D, Olivecrona M: The complications and the position of the Codman MicroSensor™ ICP device: an analysis of 549 patients and 650 sensors. *Acta Neurochir (Wien)* **155**:2141–2148, 2013
17. Krogh K, Christensen P, Sabroe S, Laurberg S: Neurogenic bowel dysfunction score. *Spinal Cord* **44**:625–631, 2006

18. Papadopoulos MC: Intrathecal pressure after spinal cord injury. **Neurosurgery** 77:E500, 2015 (Letter)
19. Phang I, Papadopoulos MC: Intraspinal pressure monitoring in a patient with spinal cord injury reveals different intradural compartments: Injured Spinal Cord Pressure Evaluation (ISCoPE) study. **Neurocrit Care** 23:414–418, 2015
20. Phang I, Werndle MC, Saadoun S, Varsos G, Czosnyka M, Zoumprouli A, et al: Expansion duroplasty improves intraspinal pressure, spinal cord perfusion pressure, and vascular pressure reactivity index in patients with traumatic spinal cord injury: injured spinal cord pressure evaluation study. **J Neurotrauma** 32:865–874, 2015
21. Rebeck JA, Murry KR, Rhoney DH, Michael DB, Coplin WM: Infection related to intracranial pressure monitors in adults: analysis of risk factors and antibiotic prophylaxis. **J Neurol Neurosurg Psychiatry** 69:381–384, 2000
22. Saadoun S, Bell BA, Verkman AS, Papadopoulos MC: Greatly improved neurological outcome after spinal cord compression injury in AQP4-deficient mice. **Brain** 131:1087–1098, 2008
23. van Middendorp JJ, Hosman AJF, Doi SAR: The effects of the timing of spinal surgery after traumatic spinal cord injury: a systematic review and meta-analysis. **J Neurotrauma** 30:1781–1794, 2013
24. Varsos GV, Werndle MC, Czosnyka ZH, Smielewski P, Koliass AG, Phang I, et al: Intraspinal pressure and spinal cord perfusion pressure after spinal cord injury: an observational study. **J Neurosurg Spine** 23:763–771, 2015
25. Walters BC, Hadley MN, Hurlbert RJ, Aarabi B, Dhall SS, Gelb DE, et al: Guidelines for the management of acute cervical spine and spinal cord injuries: 2013 update. **Neurosurgery** 60 (Suppl 1):82–91, 2013
26. Werndle MC, Saadoun S, Phang I, Czosnyka M, Varsos GV, Czosnyka ZH, et al: Monitoring of spinal cord perfusion pressure in acute spinal cord injury: initial findings of the injured spinal cord pressure evaluation study. **Crit Care Med** 42:646–655, 2014
27. Werndle MC, Zoumprouli A, Sedgwick P, Papadopoulos MC: Variability in the treatment of acute spinal cord injury in the

United Kingdom: results of a national survey. **J Neurotrauma** 29:880–888, 2012

## Disclosures

The authors report no conflict of interest concerning the materials or methods used in this study or the findings specified in this paper.

## Author Contributions

Conception and design: Papadopoulos, Saadoun. Acquisition of data: Papadopoulos, Phang. Analysis and interpretation of data: Papadopoulos, Phang, Saadoun. Drafting the article: Papadopoulos, Phang, Saadoun. Critically revising the article: Papadopoulos, Zoumprouli, Saadoun. Reviewed submitted version of manuscript: all authors. Approved the final version of the manuscript on behalf of all authors: Papadopoulos. Statistical analysis: Phang. Study supervision: Papadopoulos, Saadoun.

## Supplemental Information

### Online-Only Content

Supplemental material is available with the online version of the article.

*Supplemental Data.* <http://thejns.org/doi/suppl/10.3171/2016.1.SPINE151317>.

### Previous Presentations

Portions of this work were presented (not published) as oral presentations at the International Spinal Research Trust meeting in London, UK, in September 2015 and at the Congress of Neurological Surgeons' meeting in New Orleans in September 2015.

## Correspondence

Marios C. Papadopoulos, Department of Neurosurgery, Atkinson Morley Wing, St. George's Hospital, London SW17 0QT, United Kingdom. email: mpapadop@sgul.ac.uk.