



Title	Methylprednisolone sodium succinate reduces spinal cord swelling but does not affect recovery of dogs with surgically treated thoracolumbar intervertebral disk herniation
Author(s)	Nishida, Hidetaka; Tanaka, Hiroshi; Kitamura, Masahiko; Inaba, Toshio; Nakayama, Masanari
Citation	Japanese Journal of Veterinary Research, 64(3), 191-196
Issue Date	2016-08
DOI	10.14943/jjvr.64.3.191
Doc URL	http://hdl.handle.net/2115/62763
Type	bulletin (article)
File Information	64-3 023.p191-196 NOTE NISHIDA.pdf



[Instructions for use](#)

NOTE

Methylprednisolone sodium succinate reduces spinal cord swelling but does not affect recovery of dogs with surgically treated thoracolumbar intervertebral disk herniation

Hidetaka Nishida^{1,2)}, Hiroshi Tanaka¹⁾, Masahiko Kitamura¹⁾, Toshio Inaba²⁾ and Masanari Nakayama^{1,*}

¹⁾Nakayama Veterinary Hospital, 6-1 Minamifukuro, Nara, Nara, 630-8342

²⁾Department of Advanced Pathobiology, Graduate School of Life and Environmental Sciences, Osaka Prefecture University, 1-58 Rinku Ourai Kita, Izumisano, Osaka, 598-8531, Japan

Received for publication, July 23, 2015; accepted, April 20, 2016

Abstract

The effect of methylprednisolone sodium succinate (MPSS) therapy was studied in 50 dogs with surgically treated Hansen type I thoracolumbar intervertebral disk herniation (TL-IVDH). Administration of MPSS significantly reduced the swelling of the spinal cord. The sensitivity of localization of disk extrusion using myelography in the MPSS group was 92.3%, and in the non-administration group was 83.3%. No significant difference in recovery rate or length of recovery time was found between the two groups. Administration of MPSS reduced spinal cord swelling, but has no effect on recovery in dogs after surgery for TL-IVDH.

Key Words: intervertebral disk herniation, methylprednisolone, myelography

Adjunctive medical therapy for spinal cord injury (SCI) is an active area of clinical and experimental research. Methylprednisolone sodium succinate (MPSS) is believed to contribute to neuronal protection, largely by inhibiting lipid peroxidation, preserving blood flow to the spinal cord, improving ionic homeostasis and reducing the release of excitotoxic glutamate^{10-12,27)}. National Spinal Cord Injury Study trials have reported previously that MPSS improves long-term

functional outcome in SCI human patients²⁻⁵⁾. There has been considerable controversy over the validity of early studies, however, because of their limitations^{17,24)}.

There have been small-scale clinical trials to estimate the efficacy of MPSS therapy for SCI in dogs. One study found that administration of MPSS increased the success rate of decompressive surgery for thoracolumbar intervertebral disk

*Corresponding author: Masanari Nakayama, Nakayama Veterinary Hospital, 6-1 Minamifukuro, Nara, Nara, 630-8342, Japan
Phone: +81-742-25-0007. Fax: +81-742-25-0005. E-mail: nova@nara-nakayamavet.com
doi: 10.14943/jjvr.64.3.191

herniation (TL-IVDH) in dogs²⁵. Another study did not find any positive benefit of perioperative MPSS administration to dogs with TL-IVDH¹, however. The use of MPSS in dogs with IVDH is associated with an increased post-operative complication rate and greater financial cost to the client¹. MPSS therapy remains a controversial topic in veterinary and human medicine^{18,24}.

Acute intervertebral disk extrusion can result in spinal cord swelling and edema visible by myelography²¹. According to Duval *et al.*, evaluation of myelographic spinal cord swelling assists in establishing prognosis⁸. The main purpose of the present study is to assess whether MPSS has an effect on myelography. We also look at the recovery rate and length of recovery time for dogs undergoing MPSS treatment following surgical treatment of TL-IVDH.

Dogs that had paraparesis or paraplegia with deep perception of their hind limbs (grade 3 & 4), and that had been referred for treatment of Hansen type I TL-IVDH from 0 to 4 days after owners became aware of the symptoms, were eligible for inclusion. Neurologic dysfunction was classified²³ as: paraspinal hyperesthesia only (Grade 1), ambulatory paraparesis and ataxia (Grade 2), non-ambulatory paraparesis (Grade 3), paraplegia with intact deep perception (Grade 4), and paraplegia with no deep perception (Grade 5). These were 50 affected dogs. Dogs were assigned to MPSS or non-administration groups in such a way that there would be no differences in age, and body weight. MPSS (30 mg/kg for 30–60 min, IV) was administered 1–3 hr prior to myelography. In 17 out of 26 dogs, MPSS (15 mg/kg, IV) was administered once or twice after the first MPSS administration. No dogs received prophylactic premedication for side effects of MPSS.

Diagnosis of TL-IVDH was made on the basis of myelography, and was confirmed during decompressive surgery. As preanesthesia the dogs received atropine (0.05 mg/kg, IV) and midazolam

(0.2 mg/kg, IV). Anesthesia was induced by propofol (5.0 mg/kg, IV) and maintained by isoflurane and O₂. Radiographic myelography was performed by injection of iohexol (0.45 mL/kg) via lumbar puncture. Myelographic lateral, ventrodorsal, and oblique views were obtained after the iohexol injection so as to evaluate compressive disk materials located circumferentially around the spinal cord in the affected area²⁶. Spinal cord swelling is quantified by calculating the ratio of the length of the loss of the myelographic dye column (ventrodorsal view) to the length of the second lumbar vertebra (L2)⁸ (Fig. 1). If the spinal cord swelling is broad and the level and lateralization of compressive lesion is unclear by radiographic myelography then diagnosis is made according to computed tomographic (CT) myelography. Decompressive surgery was performed immediately after the diagnostic imaging. Hemilaminectomy was performed on the side ipsilateral to the spinal cord compression, as determined by the results of myelography or CT myelography, and all extruded disk material was removed. Postoperative management included the administration of antimicrobials and analgesics, and nursing care to prevent decubital ulcers. The severity of neurological dysfunction was rechecked at 1 day after the operation (post-operation). The outcome was classified as successful (urinary continence regained and able to walk without assistance) or unsuccessful (did not regain urinary continence and remained paraplegic). Values were compared between the two groups by the unpaired t test. The sensitivity of myelography and the recovery rate were analyzed using a Fisher exact test. Values of $p < 0.05$ were considered significant.

The MPSS administration group consisted of 24 Miniature Dachshunds, 1 Shih Tzu and 1 Pekingese, in total 16 males and 10 females, in the age range 3 to 11 years (average 5.9 years); these dogs weighed 4.2 to 10 kg (average 6.1 kg). The non-administration group consisted of 22 Miniature Dachshunds, 1 Toy Poodle and 1

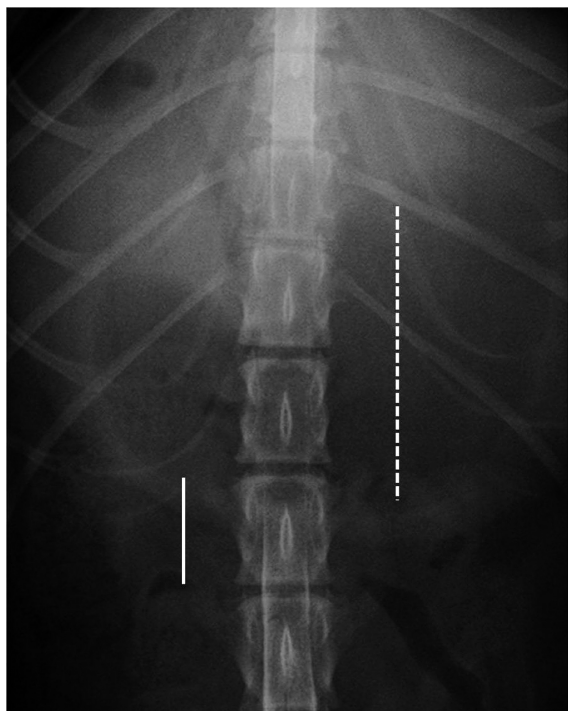


Fig. 1. Myelography of the ventrodorsal view. Spinal cord swelling is measured by calculating the ratio of the length of the loss of the myelographic dye column (dotted line) to the length of L2 (continuous line).

American Cocker Spaniel, in total 18 males and 6 females, in the age range 2 to 12 years (average 5.5 years), and weighed 2.7 to 9.5 kg (average 6.5 kg). There was no significant difference in age ($p = 0.57$) or weight ($p = 0.38$) between the groups.

The sites of disk herniation ranged from T10-11 to L3-4 (Fig. 2). Fig. 3 shows the varying ratio of spinal cord swelling: L2. The range of the swelling: L2 ratio in the group that received MPSS was significantly smaller than in the non-administration group ($p = 0.032$). In the MPSS group, the level and lateralization of disk extrusion was diagnosed in 92.3% (24/26) of dogs by myelography. In the non-administration group, the level and lateralization of disk extrusion was diagnosed in 83.3% (20/24) of dogs by myelography. Just 7.7% (2/26) of dogs in the MPSS group and 16.7% (4/24) in the control group had broad spinal cord swelling, and the

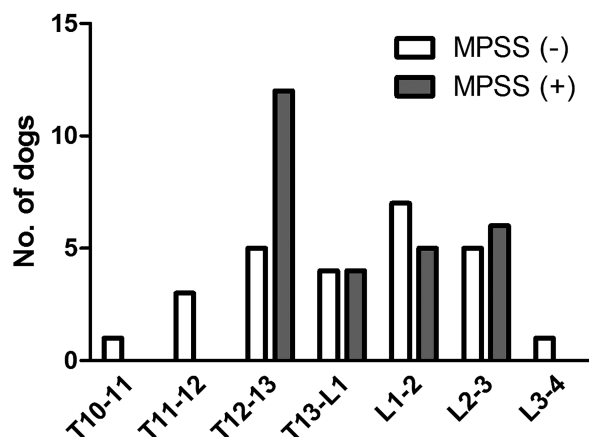


Fig. 2. Sites of disk herniation in 50 dogs with thoracolumbar IVDH. The dogs are partitioned into 2 groups: 26 dogs that received MPSS [black squares], and 24 dogs that received no MPSS [white squares]).

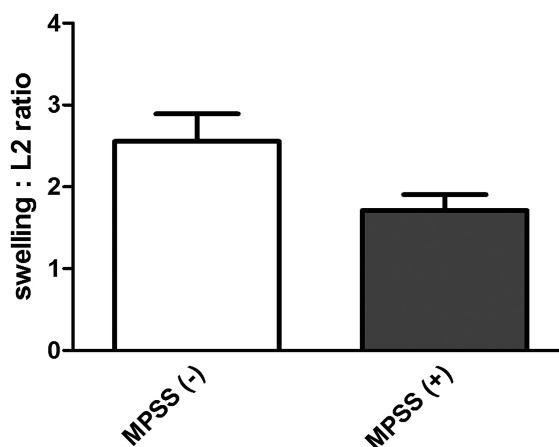


Fig. 3. Observations of a range of spinal cord swelling: L2 ratios. The range of swelling: L2 ratio in the MPSS group (gray squares) is significantly lower than in the non-administration group (white squares) [$P = 0.032$].

levels and lateralization of compressive lesion was unclear by myelography. Diagnosis was made according to CT myelography.

The preoperative severity of TL-IVDH in the MPSS was 3.65, and 3.71 in the non-administration group ($p = 0.69$). There was no significant difference in severity between the MPSS groups (3.58) and non-administration (3.67) post-operation ($p = 0.64$). The recovery rate and length of recovery time were compared for the two groups. In the MPSS group, 24 of 26 dogs

(92.3%) regained the ability to walk at 0 to 30 days after surgery (average 8.7 days). The other two dogs in the MPSS group did not regain the ability to walk. In the non-administration group, 23 of 24 dogs (95.8%) regained the ability to walk at 1 to 22 days (average 7.96 days). There was no significant difference in the recovery rate ($p = 0.53$) or the time to recovery ($p = 0.95$) between the two groups. Ten of 26 dogs (38.5%) in the MPSS group had complications, including loose stool (4/10), diarrhea (5/10), and vomiting (1/10), but these all convalesced after medical therapy during days 3–7.

The level and lateralization of disk extrusion in the non-administration group was successfully diagnosed in 83.3%. This is similar to another report where 78.9% of TL-IVDD patients were diagnosed by myelography¹⁴. Our clinical research showed that administration of MPSS reduced spinal cord swelling and improved the sensitivity of myelography in dogs with TL-IVDH. A single 30 mg/ml dose of MPSS was capable of restoring spinal cord blood flow in an experimental cat contusion model⁹. Administration of MPSS would assist in diagnosing the site of disc extrusion by myelography. In the present study diagnosis was made according to CT myelography if the level and lateralization of compressive lesion by radiographic myelography was unclear. A prospective comparison of CT, nonselective angiographic CT, myelography, and CT myelography in dogs with various myelopathies found that CT myelography was the most sensitive technique for identification of lesions that are compressing the spinal cord, when compared to surgical findings⁷. Use of myelography on a dog with suspected TL-IVDH nowadays is usually due to lack of availability of CT or magnetic resonance imaging (MRI)²². It has been reported that MRI provides more sensitive imaging than myelography for localizing disc extrusion^{6,15} but in small animal practice there is variation in MRI quality. It may be difficult to obtain diagnostic studies of the spine

with low field MRI, particularly in small dogs²².

Our study showed that 38.5% of dogs which received MPSS treatment had complications, and that all dogs convalesced after medical therapy. A recent study of dogs undergoing spinal surgery that had received a single bolus of 30 mg/kg MPSS, followed by a second half to full dose, reported that 90% of the dogs developed occult gastrointestinal hemorrhage¹³. If MPSS is administered too quickly, vomiting can occur²⁰. Slow intravenous injection of MPSS would reduce the side effect.

MPSS has been used in the treatments of acute TL-IVDH cases in small animal practice^{1,25}. The present study covered dogs with Hansen type I TL-IVDH from 0 to 4 days after the owners became aware of the symptoms. It is difficult to determine the exact onset of TL-IVDH because some dogs had pain without any neurological sign, and a worsening of symptom thereafter. Olby *et al.* have recently reported that MPSS did not give any improvement in dogs with acute onset of TL-IVDH—causing paraplegia and loss of pain perception—when used as an adjunctive medical treatment¹⁹. Grade 5 patients had broad spinal cord swelling as a result of severe damage of the spinal cord, with possible difficulty in diagnosing the site of disc extrusion by myelography. Grade 3 and 4 patients were therefore eligible for inclusion in the present study. We found that MPSS did not induce an improvement in clinical signs despite reducing spinal cord swelling. Dogs received MPSS injection as an adjunctive treatment, and hemilaminectomy was performed shortly after the injection. Decompressive surgery may conceal the effect of MPSS in dogs with paresis or paraplegia with deep perception of their hind limbs. In another study, adoption of a swelling: L2 ratio of 5.0 as a cutoff for indication of neurological recovery yielded a sensitivity of 74% and a specificity of 61%⁸. All but two of the patients had less than 5.0 swelling: L2 ratio in the present study. MPSS selectively attenuates oligodendrocyte death but not neuronal cell

death¹⁶⁾. MPSS has limited protective effect in dogs with TL-IVDH.

References

- 1) Boag, A. K., Otto, C. M. and Drobatz, K. J. 2001. Complications of methylprednisolone sodium succinate therapy in dachshunds with surgically treated intervertebral disc disease. *J. Vet. Emerg. Crit. Care*, **11**: 105-110.
- 2) Bracken, M. B., Collins, W. F., Freeman, D. F., Shepard, M. J., Wagner, F. W., Silten, R. M., Hellenbrand, K. G., Ransohoff, J., Hunt, W. E., Perot Jr., P. R., Grossman, R. G., Green, B. A., Eisenberg, H. M., Rifkinson, N., Goodman, J. H., Meagher, J. N., Fischer, B., Clifton, G. L., Flamm, E. S. and Rawe, S. E. 1984. Efficacy of methylprednisolone in acute spinal cord injury. *J. A. M. A.*, **251**: 45-52.
- 3) Bracken, M. B., Shepard, M. J., Hellenbrand, K. G., Collins, W. F., Leo, L. S., Freeman, D. F., Wagner, F. C., Flamm, E. S., Eisenberg, H. M., Goodman, J. H., Perot Jr., P. L., Green, B. A., Grossman, R. G., Meagher, J. N., Young, W., Fisher, B., Clifton, G. L., Hunt, W. E. and Rifkinson, N. 1985. Methylprednisolone and neurological function one year after spinal cord injury. *J. Neurosurg.*, **63**: 704-713.
- 4) Bracken, M. B., Shepard, M. J., Collins, W. F., Holford, T. R., Young, W., Baskin, D. S., Eisenberg, H. M., Flamm, E., Leo-Summers, L., Maroon, J., Marshall, L. F., Perot Jr, P. L., Piepmeyer, J., Sonntag, V. K. H., Wagner, F. C., Wilberger, J. L. and Winn, H. R. 1990. A randomised controlled trial of methylprednisolone or naloxone in the treatment of acute spinal cord injury. *N. Eng. J. Med.*, **322**: 1405-1411.
- 5) Bracken, M. B., Shepard, M. J., Collins, W. F., Holford, T. R., Baskin, D. S., Eisenberg, H. M., Flamm, E., Leo-Summers, L., Maroon, J., Marshall L. F., Perot Jr, P. L., Piepmeyer, J., Sonntag, V. K. H., Wagner, F. C., Wilberger, J. L., Winn, H. R. and Young, W. 1992. Methylprednisolone or naloxone treatment after acute spinal-cord injury. *N. Eng. J. Med.*, **76**: 23-31.
- 6) da Costa, R. C., Parent, J., Dobson, H., Holmberg, D. and Partlow, G. 2006. Comparison of magnetic resonance imaging and myelography in 18 Doberman pinscher dogs with cervical spondylomyelopathy. *Vet. Radiol. Ultrasound*, **47**: 523-531.
- 7) Dennison, S. E., Drees, R., Rylander, H., Yandell, B. S., Milovancev, M., Pettigrew, R. and Schwarz, T. 2010. Evaluation of different computed tomography techniques and myelography for the diagnosis of acute canine myelopathy. *Vet. Radiol. Ultrasound*, **51**: 254-258.
- 8) Duval, J., Dewey, C., Roberts, R. and Aron, D. 1996. Spinal cord swelling as a myelographic indicator of prognosis: a retrospective study in dogs with intervertebral disc disease and loss of deep pain perception. *Vet. Surg.*, **25**: 6-12.
- 9) Hall, E. D., Wolf, D. L. and Braughler, J. M. 1984. Effects of a single large dose of methylprednisolone sodium succinate on experimental posttraumatic spinal cord ischemia. Dose-response and time-action analysis. *J. Neurosurg.*, **61**: 124-130.
- 10) Hall, E. D. 1992. The neuroprotective pharmacology of methylprednisolone. *J. Neurosurg.*, **76**: 13-22.
- 11) Hall, E. D. 1993. Lipid antioxidants in acute central nervous system injury. *Ann. Emerg. Med.*, **22**: 1022-1027.
- 12) Hall, E. D. and Springer, J. E. 2004. Neuroprotection and acute spinal cord injury: a reappraisal. *NeuroRx*, **1**: 80-100.
- 13) Hanson, S. M., Bostwick, D. R., Twedt, D. C. and Smith, M. O. 1997. Clinical evaluation of cimetidine, sucralfate, and misoprostol for prevention of gastrointestinal tract bleeding in dogs undergoing spinal surgery. *Am. J. Vet. Res.*, **58**: 1320-1323.
- 14) Hecht, S., Thomas, W. B., Marioni-Henry, K., Echandi, R. L., Matthews, A. R. and Adams, W. H. 2009. Myelography vs. computed tomography in the evaluation of acute thoracolumbar intervertebral disk extrusion in chondrodystrophic dogs. *Vet. Radiol. Ultrasound*. **50**: 353-359.
- 15) Ito, D., Matsunaga, S., Jeffery, N. D., Sasaki, N., Nishimura, R., Mochizuki, M., Kasahara, M., Fujiwara, R. and Ogawa, H. 2005. Prognostic value of magnetic resonance imaging in dogs with paraplegia caused by thoracolumbar intervertebral disk extrusion: 77 cases (2000-2003). *J. Am. Vet. Med. Assoc.*, **227**: 1454-1460.
- 16) Lee, J. M., Yan, P., Xiao, Q., Chen, S., Lee, K. Y., Hsu, C. Y. and Xu, J. 2008. Methylprednisolone protects oligodendrocytes but not neurons after spinal cord injury. *J. Neurosci.*, **28**: 3141-3149.
- 17) Nesathurai, S. 1998. Steroids and spinal cord injury: revisiting the NASCIS 2 and

- NASCIS 3 trials. *J. Trauma*, **45**: 1088–1093.
- 18) Park, E. H., White, G. A. and Tieber, L. M. 2012. Mechanisms of injury and emergency care of acute spinal cord injury in dogs and cats. *J. Vet. Emerg. Crit. Care*, **22**: 160–178.
- 19) Olby, N. J., Muguet-Chanoit, A. C., Lim, J. H., Davidian, M., Mariani, C. L., Freeman, A. C., Platt, S. R., Humphrey, J., Kent, M., Giovanella, C., Longshore, R., Early, P. J. and Muñana K. R. 2016. A Placebo-Controlled, Prospective, Randomized Clinical Trial of Polyethylene Glycol and Methylprednisolone Sodium Succinate in Dogs with Intervertebral Disk Herniation. *J. Vet. Intern. Med.*, **30**: 206–214.
- 20) Platt, R. S., Abramson, C. J. and Garosi, L. S. 2005. Administering Corticosteroids in Neurologic Diseases. *Compendium*, **27**: 210–220.
- 21) Roberts, R. E. and Selcer, B. A. Myelography and epidurography. 1993. *Vet. Clin. North Am.*, **23**: 307–329.
- 22) Robertson, I. and Thrall, D. E. 2011. Imaging dogs with suspected disc herniation: pros and cons of myelography, computed tomography, and magnetic resonance. *Vet. Radiol. Ultrasound*, **52**: S81–S84.
- 23) Sharp, N. J. H. and Wheeler, S. 2005. *Small animal spinal disorders*. Elsevier Mosby, Philadelphia.
- 24) Short, D. J., El Masry, W. S. and Jones, P. W. 2000. High dose methylprednisolone in the management of acute spinal cord injury - a systematic review from a clinical perspective. *Spinal Cord*, **38**: 273–286.
- 25) Siemering, G. and Vroman, M. 1992. High dose methylprednisolone sodium succinate: an adjunct to surgery in canine intervertebral disk herniation. Scientific meeting abstract. *Vet. Surg.*, **21**: 406.
- 26) Tanaka, H., Nakayama, M. and Takase, K. 2004. Usefulness of myelography with multiple views in diagnosis of circumferential location of disc material in dogs with thoracolumbar intervertebral disc herniation. *J. Vet. Med. Sci.*, **66**: 827–833.
- 27) Taoka, Y., Okajima, K., Uchiba, M. and Johno, M. 2001. Methylprednisolone reduces spinal cord injury in rats without affecting tumor necrosis factor-alpha production. *J. Neurotrauma*, **18**: 533–543.