



THE AGA KHAN UNIVERSITY

eCommons@AKU

Section of Neurosurgery

Department of Surgery

3-1-2021


Management of Intracranial Haemangiopericytomas

Noman Ahmad

Saqib Kamran Bakhshi

Muhammad Shahzad Shamim

Follow this and additional works at: https://ecommons.aku.edu/pakistan_fhs_mc_surg_neurosurg

 Part of the [Nervous System Diseases Commons](#), [Neurosurgery Commons](#), and the [Oncology Commons](#)

Management of Intracranial Haemangiopericytomas

Noman Ahmad, Saqib Kamran Bakhshi, Muhammad Shahzad Shamim

Abstract

Haemangiopericytomas are rare tumours, commonly mistaken as meningiomas on radiology. These tumours are considered malignant and treatment involves aggressive surgery, followed by adjuvant radiation therapy, and close radiological and clinical follow ups. Herein the authors have reviewed the recent literature on the management of these tumours.

Keywords: Brain tumours, radiation therapy, dural based tumours

Introduction

Haemangiopericytomas (HPC) are extremely rare, dural based malignant tumours, comprising of only 0.4% of all intracranial neoplasms.¹ These tumours originate from transformation of pericytes located in capillaries and post capillary venules, and are mostly supratentorial.¹ They commonly arise in individuals in their fourth and fifth decade of life, and unlike meningiomas, have a slight male predominance.^{2,3}

HPC are biologically aggressive, and recurrence following treatment is particularly common, with 5-year local recurrence and metastasis rates in the range of 65% and 33%, respectively.⁴ The mean overall survival for HPC has been reported to be as low as 7 years after diagnosis.⁵ The relatively poor prognosis associated with intracranial HPC has led several investigators to advocate for aggressive treatment combining radical surgical resection with adjuvant radiotherapy. Gamma knife radiosurgery has also been tried for the treatment of small HPC and has been found promising in controlling local tumour growth.

Review of evidence

Extent of resection: Surgical resection has always been the mainstay in the treatment of haemangiopericytoma. In a case series of 40 patients published by Rutkowski et al., patients with gross total resection (GTR) had better overall survival compared to those receiving subtotal resection (STR), regardless of adjuvant radiation.⁶ (Figures 1 and 2). The median survival was 18.8 years for patients receiving GTR compared with 8.75 years for patients receiving STR, with adjuvant radiation.⁶ In another study by Kim et al., the median time for local recurrence of patients subjected to

Section of Neurosurgery, Aga Khan University Hospital, Karachi-Pakistan.

Correspondence: Muhammad Shahzad Shamim. e-mail: shahzad.shamim@aku.edu

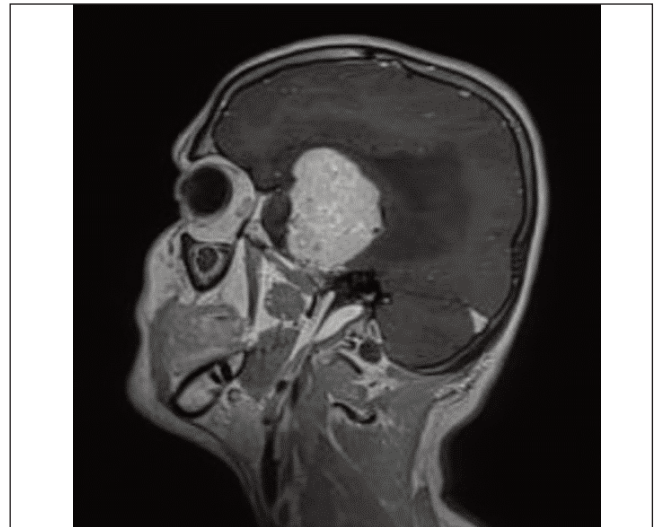


Figure-1: MRI brain T1-post contrast image sagittal section of a 44 years old male patient, showing a homogeneously enhancing, dural based lesion in the right middle cranial fossa. It is displacing the adjacent temporal and frontal lobes, and there is significant peri-lesional oedema. The lesion was surgically resected and histopathology of this lesion was reported as meningeal haemangiopericytoma grade III.

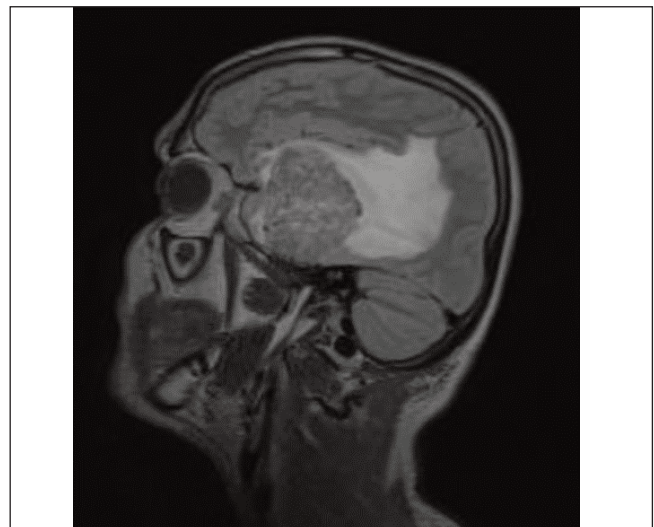


Figure-2: MRI brain FLAIR image sagittal section of the same patient showing significant peri-lesional oedema extending to the frontal, temporal and parietal lobes. Such a finding in dural based lesions otherwise suspected to be meningiomas, should raise the suspicion of HPC.

GTR was 68.3 months; whereas progression free survival with STR was 37.1 months, and biopsy was 3.5 months.⁷

In a large case series of 523 patients with HPC, surgery was performed in 86% of the cases, in which 56.9% patients underwent GTR and 38.6% patients had STR. The results demonstrated significantly better survival in patients with GTR compared to STR (157.97 months vs. 110.75 months).⁸ The 5-year local control rate for patients with GTR and STR were 84% and 38%, respectively, according to another study by Soyuer et al.⁹

Adjuvant radiation therapy: Several studies have supported the use of adjuvant radiation therapy for HPC. This may be in the form of conventional radiation, external beam radiotherapy or stereotactic radiosurgery. According to Soyuer et al., none of the 3 patients who received GTR and adjuvant radiation experienced local disease recurrence, whereas 5 (45%) of the 11 patients who underwent GTR without radiation experienced local recurrence.⁹ Guthrie et al., also reported significantly better results with adjuvant radiation.⁴ In the study, 9 of 17 irradiated tumours recurred at an average of 75 months after surgery, whereas 13 of 15 nonirradiated tumours recurred at an average of 34 months after surgery. Although the difference was not statistically significant, adjuvant radiation improved survival from 62 months to 92 months.⁴ DuFour et al., also found that adjuvant radiation provided benefit with regards to local disease recurrence.¹⁰ In their series, recurrence rates for patients treated with surgery and adjuvant radiation, and patients treated with surgery alone were 12% and 88%, respectively.¹⁰

Management of recurrent intracranial haemangiopericytomas with radiosurgery has also been reported as an effective treatment option. Sheehan et al., reviewed a series of 14 patients with 15 recurrent HPC treated with radiosurgery.¹¹ On follow-up imaging, 12 of the 15 tumours had regressed, although 3 had grown, giving an 80% local control rate.¹¹ In another series by Chang et al., 6 of the 8 patients treated with radiosurgery achieved a reduction in size and local control was achieved in 75% of the cases.¹² However, none of the studies were able to demonstrate an improvement in overall survival of patients receiving adjuvant radiation in any form.

Conclusion

Gross total resection of intracranial HPC seems to offer the best outcome. In cases with residual tumours, adjuvant radiation therapy is recommended. HPC have a high risk of recurrence despite these treatment options.

References

1. Kleihues PD. WHO classification of tumours of the central nervous system. World Health Organization Classification of Tumours. 2007;pp 33-49.
2. Guthrie BL, Ebersold MJ, Scheithauer BW, Shaw EG. Meningeal hemangiopericytoma: histopathological features, treatment, and long-term follow-up of 44 cases. *Neurosurg.* 1989;25:514-22.
3. Woodruff RW, Room MR. Library Tools. *Cancer.* 2012;118:5331-8.
4. Guthrie BL, Ebersold MJ, Scheithauer BW, Shaw EG. Meningeal hemangiopericytoma: histopathological features, treatment, and long-term follow-up of 44 cases. *Neurosurg.* 1989;25:514-22.
5. Chacko G, Chacko AG, Rajshekhar V, Muliylil JP. Intracranial hemangiopericytomas: correlation of topoisomerase II α expression with biologic behaviour. *Surg. Neurol.* 2006;65:11-7.
6. Rutkowski MJ, Jian BJ, Bloch O, Chen C, Sughrue ME, Tihan T, Barani IJ, Berger MS, McDermott MW, Parsa AT. Intracranial hemangiopericytoma: clinical experience and treatment considerations in a modern series of 40 adult patients. *Cancer.* 2012;118:1628-36.
7. Kim YJ, Park JH, Kim YI, Jeun SS. Treatment strategy of intracranial hemangiopericytoma. *Brain Tumor Res Treat.* 2015;3:68.
8. Ghose A, Guha G, Kundu R, Tew J, Chaudhary R. CNS hemangiopericytoma. *Am. J. Clin. Oncol.* 2017;40:223-7.
9. Soyuer S, Chang EL, Seleak U, McCutcheon IE, Maor MH. Intracranial meningeal hemangiopericytoma: the role of radiotherapy: report of 29 cases and review of the literature. *Cancer.* 2004;100:1491-7.
10. Dufour H, Métellus P, Fuentes S, Murracchiole X, Régis J, Figarella-Branger D, Grisoli F. Meningeal hemangiopericytoma: a retrospective study of 21 patients with special review of postoperative external radiotherapy. *Neurosurg.* 2001;48:756-63.
11. Sheehan J, Kondziolka D, Flickinger J, Lunsford LD. Radiosurgery for treatment of recurrent intracranial hemangiopericytomas. *Neurosurg.* 2002;51:905-11.
12. Chang SD, Sakamoto GT. The role of radiosurgery for hemangiopericytomas. *Neurosurg. Focus.* 2003;14:1-5.