

| | |
|-------------|---|
| Title | Loss of Hep Par 1 immunoreactivity in the livers of patients with carbamoyl phosphate synthetase 1 deficiency |
| Author(s) | Yamaguchi, Maki; Kataoka, Tatsuki R.; Shibayama, Takahiro; Fukuda, Akinari; Nakazawa, Atsuko; Minamiguchi, Sachiko; Sakurai, Takaki; Miyagawa-Hayashino, Aya; Yorifuji, Toru; Kasahara, Mureo; Uemoto, Shinji; Haga, Hironori |
| Citation | Pathology International (2016), 68(8): 333-336 |
| Issue Date | 2016-06 |
| URL | http://hdl.handle.net/2433/216061 |
| Right | © 2016 The Authors. Pathology International published by Japanese Society of Pathology and John Wiley & Sons Australia, Ltd. This is an open access article under the terms of the Creative Commons Attribution-NonCommercial-NoDerivs License, which permits use and distribution in any medium, provided the original work is properly cited, the use is non-commercial and no modifications or adaptations are made. |
| Type | Journal Article |
| Textversion | publisher |

Original Article

Loss of Hep Par 1 immunoreactivity in the livers of patients with carbamoyl phosphate synthetase 1 deficiency

Maki Yamaguchi,¹ Tatsuki R. Kataoka,² Takahiro Shibayama,¹ Akinari Fukuda,³ Atsuko Nakazawa,⁴ Sachiko Minamiguchi,¹ Takaki Sakurai,¹ Aya Miyagawa-Hayashino,¹ Toru Yorifuji,⁵ Mureo Kasahara,³ Shinji Uemoto² and Hironori Haga¹

¹Department of Diagnostic Pathology, ²Organ Transplant Unit, Kyoto University Hospital, Kyoto, ³Organ Transplantation Center, ⁴Division of Clinical Pathology, National Center for Child Health and Development, Tokyo, and ⁵Department of Pediatrics, Osaka City General Hospital, Osaka, Japan

The hepatocyte paraffin 1 (Hep Par 1) antibody is widely used as a hepatocyte marker, recognizing carbamoyl phosphate synthetase 1 (CPS1), an essential component of the urea cycle. Various missense, nonsense, and frameshift mutations occur in the *CPS1* gene. In neonatal patients with homozygous CPS1 deficiency (CPS1D), urea cycle defects with resulting severe hyperammonemia can be fatal, though liver transplantation provides a complete cure for CPS1D. We performed Hep Par 1 immunostaining in the explanted livers of 10 liver transplant patients with CPS1D. Seven were negative for Hep Par 1 in the hepatocytes and the other three showed normal diffuse granular cytoplasmic staining. As expected, all three Hep Par 1-positive patients had at least one missense mutation, and all four patients who had only nonsense or frameshift mutations were Hep Par 1-negative. The other three patients were unexpectedly negative for Hep Par 1, even though each had one missense mutation. These results suggest that CPS1D can be related to the loss of Hep Par 1 reactivity due to the loss of protein production, a one amino acid substitution resulting in an abortive protein product, or both. Hep Par 1 immunohistochemistry can be used as a simple method to confirm CPS1D.

Key words: *CPS1*, Hep Par 1, liver transplantation

Correspondence: Tatsuki R. Kataoka, MD & PhD, Organ Transplantation Unit, Kyoto University Hospital, Sakyo-ku, Kyoto, 606-8507, Japan. E-mail: trkata@kuhp.kyoto-u.ac.jp

Received 4 February 2016. Accepted for publication 5 April 2016.

© 2016 The Authors

Pathology International published by Japanese Society of Pathology and John Wiley & Sons Australia, Ltd.

This is an open access article under the terms of the Creative Commons Attribution-NonCommercial-NoDerivs License, which permits use and distribution in any medium, provided the original work is properly cited, the use is non-commercial and no modifications or adaptations are made.

Hepatocyte paraffin 1 (Hep Par 1, clone OCH1E5.2.10) is a mouse monoclonal antibody generated using extracts from formalin-fixed liver tissue.¹ The antibody reacts with the mitochondria of hepatocytes and small intestine epithelium, but not with that of most other tissues.^{1,2} Therefore, this antibody has been used as a marker for hepatocytes and hepatocellular neoplasms in surgical pathology practice. More than a decade after the development of the monoclonal antibody, the antigen was identified as carbamoyl phosphate synthetase 1 (CPS1).³ CPS1 is the rate-limiting enzyme in the urea cycle, synthesizing carbamoyl phosphate from bicarbonate, adenosine triphosphate and ammonia.⁴ This enzyme is the most abundant protein in liver mitochondria, accounting for about 20 % of the total mitochondrial proteins.⁴ This enzyme is composed of an intersubunit interacting domain, a glutaminase domain, a bicarbonate phosphorylation domain, a domain of unknown function, a carbamate phosphorylation domain and an N-acetyl-L-glutamate binding domain,⁵ which the Hep Par 1 antibody recognizes is not known. CPS1 deficiency (CPS1D; OMIM #237300) is an autosomal recessive disorder characterized by hyperammonemia ranging from neonatally lethal to environmentally-induced adult-onset disease.^{4,5} In newborn patients, hyperammonemia manifests after feeding commencement, with symptoms such as vomiting, hypothermia, somnolence, lethargy, apnea, seizure, or coma. Though the initial medical treatment of CPS1D consists of protein restriction and medications such as sodium phenylbutyrate, only liver transplantation can offer complete avoidance of recurrent hyperammonemia and prevent serious neurological damage.⁶ Various types of mutations causing CPS1D have been reported, but missense mutations are the most frequently observed.⁵ Other mutations include small deletions, splice site changes, nonsense mutations, and small insertions.⁵ To our knowledge, Hep Par 1 immunoreactivity has not been studied in the livers of patients with CPS1D; therefore, the aim of our study was to

examine Hep Par 1 immunoreactivity in the livers of patients with CPS1D. In addition, we also investigated Arginase-1 immunoreactivity. The antigen is a binuclear manganese metalloenzyme located downstream of CPS1 in the urea cycle.⁴

MATERIALS AND METHODS

Pathological specimens

Ten liver tissue samples from patients who were clinically diagnosed with CPS1D and underwent liver transplantation at Kyoto University Hospital (Cases #5, #9, and #10) or the National Center for Child Health and Development (Cases #1–#4, #6–#8) between 2006 and 2013 were obtained for this study. Informed consent for genetic testing was obtained from the parents of all patients, and the confidentiality of results was guaranteed. A pericapsular area of liver tissues (wedge biopsy) was taken from each donor during the Living Donor Liver Transplantation (LDLT), and these samples were used as positive controls. There was no pre-transplantation biopsy of the donors. Clinical information on the patients is summarized in Table 1.

Mutational analysis

Genomic DNA was isolated from the peripheral blood of patients before the operation. PCR amplification was performed on the DNA as previously reported.⁶

Immunohistochemical analysis

Representative sections were prepared from formalin-fixed paraffin-embedded tissue blocks. Immunohistochemistry was performed using Benchmark ULTRA (Ventana Medical Systems, Roche Diagnostics, Indianapolis, IN, USA) with diaminobenzidine as a chromogen, followed by light counterstaining with hematoxylin. A monoclonal mouse Hep Par 1 antibody (clone OCH1E15, 1:200 dilution, DAKO, Glostrup, Denmark) and a rabbit polyclonal Arginase-1 antibody (1:2500 dilution,

SIGMA, St Louis, MO) were used. Optimal staining was achieved after microwave pretreatment (60 min; 98 °C; CC1 buffer [10 mmol/L], pH 8.0) for antigen retrieval. Hep Par 1 exhibits a granular cytoplasmic staining pattern. The staining results were categorized into two groups. Hepatocytes with granular staining at low power were considered “positive,” and hepatocytes without granular staining at any power field were considered “negative.” In case of Arginase-1 staining, nuclear and/or cytoplasmic staining at low power were considered “positive”.

RESULTS

Mutational analysis

All samples (Cases #1–10) from the 10 neonatal onset type CPS1D patients were analyzed. Detected mutations are summarized in Table 2. The mutations found in Cases #1–5 have been reported previously.⁶ In total, 12 mutation types were detected in the *CPS1* gene, including 7 missense mutations, 3 nonsense mutations, and 2 frameshift mutations. Four of the 7 missense mutations (c.697C > T, c.2002C > T, c.3540G > A/c.3683G > C, and c.446 T > C) were previously unreported. Time-zero biopsy and donor liver (each 10 cases, total 20 samples) samples were evaluated by Hep Par 1 immunostaining. All control samples tested positive for Hep Par 1 (data not shown). Of the explant samples taken from CPS1D patients, three were positive for Hep Par 1, and 7 were negative. Representative images are shown in Fig. 1. Scattered granular staining of Hep Par 1 in sinusoidal cells was observed in the sample from Case #10 (Fig. 1). Hep Par 1-positive cases (Cases #2, #4, and #5) had missense mutations in at least one allele. In contrast, the other three cases (Cases #3, #7 and #10) with at least one allele containing a missense mutation were Hep Par 1-negative. The other four cases (Cases #1, #6, #8, and #9) without missense mutations had nonsense and/or frameshift mutations in both alleles, and were negative for Hep Par 1. We could not find any relationship between clinical characteristics and immunoreactivity of Hep Par 1.

We also examined Arginase-1 immunoreactivity using Case #5, #9 and #10. In all-examined cases, Arginase-1 had showed positive staining.

DISCUSSION

As expected, samples from patients with nonsense and/or frameshift mutations in both alleles were Hep Par 1-negative; nonsense-mediated mRNA decay (NMD) could explain these results. NMD is also known as mRNA surveillance, and is one of several post-transcriptional mechanisms that control the quality of mRNA function.⁷ NMD prevents the production of truncated proteins that could function in dominant-negative or other

Table 1 Patients with carbamoyl phosphate 1 deficiency

| Case | Age at LTx(month) | Gender | Donor | Reference |
|------|-------------------|--------|--------|--------------|
| #1 | 4 | F | Mother | ⁶ |
| #2 | 6 | F | Father | ⁶ |
| #3 | 8 | F | Mother | ⁶ |
| #4 | 10 | F | Mother | ⁶ |
| #5 | 21 | F | Mother | ⁶ |
| #6 | 6 | F | Mother | Unreported |
| #7 | 7 | F | Father | Unreported |
| #8 | 6 | M | Father | Unreported |
| #9 | 9 | M | Father | Unreported |
| #10 | 9 | M | Father | Unreported |

LTx, liver transplantation.

Table 2 *CPS1* mutations and Hep Par 1 immunostaining patterns

| Case | Mutations | cDNA Allele 1 (amino acid; pattern of mutation) | cDNA Allele 2 (amino acid; pattern of mutation) | Hep Par 1 staining | Arginase-1 |
|------|--------------|---|--|--|------------|
| #1 | Homozygous | c.1528delG (p.510fs514X; Frameshift) | c.1528delG (p.510fs514X; Frameshift) | Negative | N.E. |
| #2 | Heterozygous | c.1528delG (p.510fs514X; Frameshift) | c.2549G > A (p.R850H; Missense) | Positive | N.E. |
| #3 | Heterozygous | c.697C > T (p.R233C; Missense) | c.1528delG (p.510fs514X; Frameshift) | Negative | N.E. |
| #4 | Heterozygous | c.1030 A > G & c.1032C > T/c.4217C > A (p.T344 A/p.T1406 N; Missense/Missense) | c.2002C > T(p.P668S; Missense) | Positive | N.E. |
| #5 | Heterozygous | c.1760G > A (p.R587H; Missense) | c.2494delGinsAA (p.832fs836X; Frameshift) | Positive | Positive |
| #6 | Heterozygous | c.2359C > T (p.R787X; Nonsense) | c.3093C > A (p.Y1031X; Nonsense) | Negative | N.E. |
| #7 | Heterozygous | c.1528delG (p.fs514X; Frameshift) | c.3540G > A/c.3683G > C (p.A1180 T/p.R1228P; Missense/Missense) | Negative | N.E. |
| #8 | Homozygous | c.1528delG (p.510fs514X; Frameshift) | c.1528delG (p.510fs514X; Frameshift) | Negative | N.E. |
| #9 | Heterozygous | c.1528delG (p.510fs514X; Frameshift) | c.3784C > T (p.R1261X; Nonsense) | Negative | Positive |
| #10 | Heterozygous | c.446 T > C (p.L149S; Missense) | c.1528delG (p.510fs514X; Frameshift) | Negative, with granular sinusoidal cell staining | Positive |

N.E., not examined.

deleterious mechanisms by eliminating abnormal transcripts that prematurely terminate translation. Some nonsense or frameshift *CPS1* mutations, including p.R1261X (Case #9), were reported to form premature termination codons, and the mutated mRNAs are subsequently eliminated by the NMD pathway.⁸ In the current case series, p.510fs514X was found in three cases. To our best knowledge, this type of mutation has been reported in six cases including the current cases.⁶ All these cases were Japanese patients, and 6 of 30 cases (20 %) had this type of *CPS1* mutation among Japanese *CPS1D* patients reported. However, this

mutation was not reported in any non-Japanese *CPS1D* patients. p.510fs514X mutation is located exon 14, encoding a region of the bicarbonate phosphorylation domain.⁵ We suppose that the *CPS1* mRNA with p.510fs514X mutation would be eliminated by NMD, as is the case of p.R1261X mutation.

Hep Par 1 staining patterns in cases with missense mutations in at least one of the alleles varied. The p.R850H (Case #2) and p.R587H (Case #5) mutations were recognized by Hep Par 1. The p.P668S mutation or *CPS1* with p.T1406 N mutation or both was also recognized by Hep Par 1. These results make

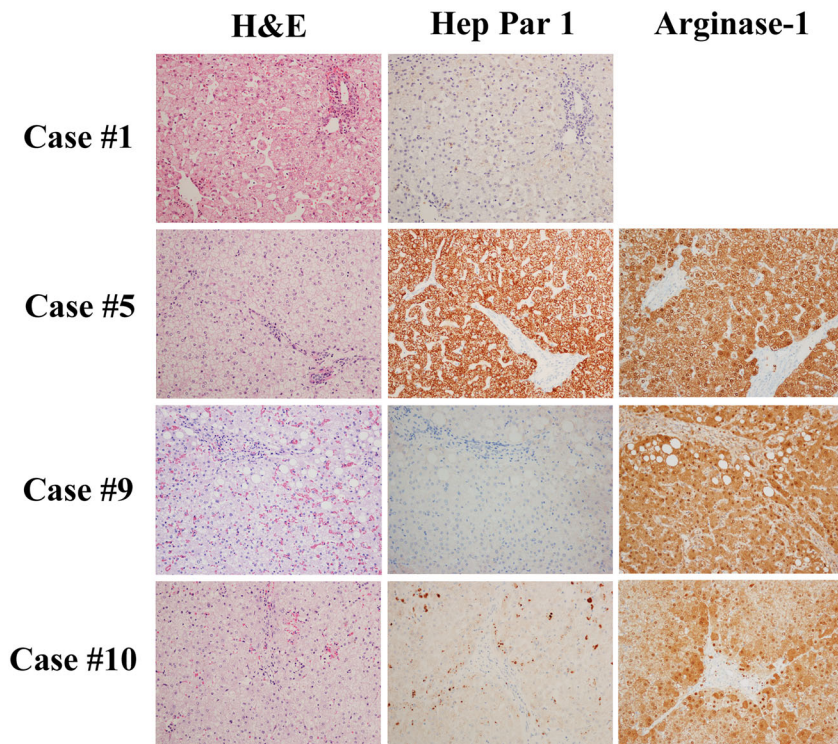


Figure 1 Representative images of the livers of patients with carbamoyl phosphate 1 deficiency. The left column shows H&E staining and the middle column shows Hep Par 1 immunostaining. Case #1 and Case #9 were completely negative for Hep Par 1; Case #5 shows normal hepatocyte granular staining. The hepatocytes in Case #10 were negative for Hep Par 1, and only some sinusoidal cells (Kupffer cells) showed immunoreactivity. The right column shows Arginase-1 immunostaining. Case #5, Case #9 and Case #10 were positive for Arginase-1.

sense since CPS1 proteins with only one amino acid substitution may be fully expressed. However, the p.R233C (Case #3) and p.A1180 T/p.R1228P (Case #7) mutations were not recognized by Hep Par 1. These amino acid substitutions may cause a dramatic change in the sites recognized by Hep Par 1. In Case #10, the hepatocytes were Hep Par 1-negative, but the sinusoidal cells were aberrantly Hep Par 1-positive. Although the mechanism is unclear, CPS1 with p.L149S mutation may excrete CPS1 for processing in Kupffer cells.

Immunohistochemical analysis can be more easily achieved compared to mutational analysis. The results of this study provide evidence for the usefulness of immunohistochemistry to detect certain mutations causing CPS1D. CPS1 is expressed in the small intestinal epithelium in addition to hepatocytes.² Biopsy of the small intestine may be easier than that of the liver, and one report successfully detected CPS1D in duodenal samples.⁹ Therefore, Hep Par 1 immunostaining using biopsied samples from the small intestine or the liver may be helpful for the diagnosis of CPS1D.

ACKNOWLEDGMENTS

The authors thank Ms. Ijiri K (Department of Diagnostic Pathology, Kyoto University Hospital, Kyoto, Japan) for her secretarial assistance. This work was supported by grants from the Ministry of Education, Culture, Sports, Science and Technology, Japan (Grant #911 150 600 013) and FUSO Pharmaceutical Industries, LTD., Japan.

DISCLOSURE STATEMENT

None declared.

REFERENCES

- 1 Wennerberg AE, Nalesnik MA, Coleman WB. Hepatocyte paraffin 1: A monoclonal antibody that reacts with hepatocytes and can be used for differential diagnosis of hepatic tumors. *Am J Pathol* 1993; **143**: 1050–4.
- 2 Mac MT, Chung F, Lin F *et al.* Expression of hepatocyte antigen in small intestinal epithelium and adenocarcinoma. *Am J Clin Pathol* 2009; **132**: 80–5.
- 3 Butler SL, Dong H, Cardona D *et al.* The antigen for Hep Par 1 antibody is the urea cycle enzyme carbamoyl phosphate synthetase 1. *Lab Invest* 2008; **88**: 78–88.
- 4 Mitchell S, Ellingson C, Coyne T *et al.* Genetic variation in the urea cycle: a model resource for investigating key candidate genes for common diseases. *Hum Mutat* 2009; **30**: 56–60.
- 5 Häberle J, Shchelochkov OA, Wang J *et al.* Molecular defects in human carbamoyl phosphate synthetase I: Mutational spectrum, diagnostic and protein structure considerations. *Hum Mutat* 2011; **32**: 579–89.
- 6 Kurokawa K, Yorifuji T, Kawai M *et al.* Molecular and clinical analyses of Japanese patients with carbamoylphosphate synthetase 1 (CPS1) deficiency. *J Hum Genet* 2007; **52**: 349–54.
- 7 Maquat LE, Carmichael GG. Quality control of mRNA function. *Cell* 2001; **104**: 173–6.
- 8 Eeds AM, Hall LD, Yadav M *et al.* The frequent observation of evidence for nonsense-mediated decay in RNA from patients with carbamyl phosphate synthetase I deficiency. *Mol Genet Metab* 2006; **89**: 80–6.
- 9 Hoogenraad NJ, Mitchell JD, Don NA *et al.* Detection of carbamyl phosphate synthetase 1 deficiency using duodenal biopsy samples. *Arch Dis Child* 1980; **55**: 292–5.