



<b>Title</b>	<b>PIMASERTIB and SEROUS RETINAL DETACHMENTS</b>
<b>Author(s)</b>	<b>Alali, Alaa; Bushehri, Ahmad; Park, Jonathan C.; Krema, Hatem; Lam, Wai Ching</b>
<b>Citation</b>	<b>Retinal Cases and Brief Reports, 2016, v. 10, n. 2, p. 191-196</b>
<b>Issued Date</b>	<b>2016</b>
<b>URL</b>	<b><a href="http://hdl.handle.net/10722/228242">http://hdl.handle.net/10722/228242</a></b>
<b>Rights</b>	<b>This work is licensed under a Creative Commons Attribution-NonCommercial-NoDerivatives 4.0 International License.</b>

# PIMASERTIB AND SEROUS RETINAL DETACHMENTS

Alaa AlAli, MD,\* Ahmad Bushehri, MD,† Jonathan C. Park, BSc, FRCOphth,\*  
Hatem Krema, MD, MSc, FRCSEd,\* Wai-Ching Lam, MD, FRCSC\*

**Purpose:** To report a case of multifocal serous retinal detachments associated with pimasertib.

**Methods:** The authors report a 26-year-old patient who developed bilateral multifocal serous retinal detachments appearing 2 days after starting pimasertib (as part of a clinical trial investigating its use in low-grade metastatic ovarian cancer) and rapidly resolving 3 days after stopping it.

**Conclusion:** The mechanism of MEK inhibitor induced visual toxicity remains unclear. The pathophysiology of multifocal serous retinal detachments as a complication of pimasertib is still poorly understood.

RETINAL CASES & BRIEF REPORTS 10:191–196, 2016

*From the Departments of \*Ophthalmology and Vision Sciences, and †Radiation Oncology, University of Toronto, Toronto, Ontario, Canada.*

## Case Report

This unique case demonstrates bilateral serous retinal detachments as a side effect of pimasertib. Pimasertib is an orally bioavailable MEK 1 and 2 inhibitor with potential antineoplastic activity, that is, currently used in clinical trials for ovarian cancer.

A 26-year-old woman, known to have metastatic low-grade serous ovarian cancer, started complaining of blurred vision 2 days after starting pimasertib. This was prescribed as part of a clinical trial, investigating the use of pimasertib versus placebo in the treatment of low-grade metastatic ovarian cancer. Pimasertib is given as a 60-mg tablet daily for 21 days followed by 7 days break and then the cycle is restarted. Snellen visual acuity at presentation was 20/25<sup>+2</sup> in each eye, intraocular pressure was 14 mmHg, and the anterior segment was unremarkable. Fundoscopy showed multifocal serous retinal detachment in both eyes (Figure 1). Optical coherence tomography demonstrated striking bilateral, multifocal serous retinal detachments (Figure 2, A and B). There was no history of steroid use.

Three days after emergently stopping the pimasertib due to her ocular complaint, her vision rapidly returned to normal. Snellen visual

acuity had improved to 20/20 in each eye and funduscopy revealed resolution of the serous retinal detachments (Figure 3). Optical coherence tomography showed near complete resolution of the serous retinal detachments (Figure 4, A and B). Intravenous fluorescein fundus angiography was normal after stopping the medication (Figure 5).

Pimasertib is a MEK 1 and 2 inhibitor that modulates mitogen-activated protein kinases, which are a family of ubiquitous eukaryotic signal transduction enzymes that link extracellular stimuli to intracellular gene expression pathways allowing for various cellular responses, including adaptation and survival.<sup>1</sup> The classic mitogen-activated protein kinase cascade, the Ras/Raf/MEK/ERK cascade, is initiated by the binding of a ligand such as a growth factor, mitogen, or cytokine to its receptor at the cell surface. This cascade is now identified as a target opportunity for the treatment of low-grade ovarian carcinoma.

Pimasertib has been used in clinical trials for the treatment of various types of cancer. Most common adverse events observed include diarrhea, rash, asthenia, anorexia, nausea, vomiting, peripheral edema, anemia, and visual disturbances including retinal vein occlusion, serous retinal detachment, and macular edema (Table 1). The underlying pathology for central serous retinopathy is reversible after drug interruption followed by dose reduction.<sup>2,3</sup>

The mechanism of MEK inhibitor induced ocular toxicity remains unclear. Many of the molecules targeted by anticancer agents are also expressed in ocular tissues, which can explain the ocular toxicity causes by such medications. There is evidence that the mitogen-activated protein kinase pathway regulates tight junctions between retinal pigment epithelial cells so that MEK inhibitors may interfere with fluid transport, resulting in the accumulation of fluid beneath the retina.<sup>4</sup>

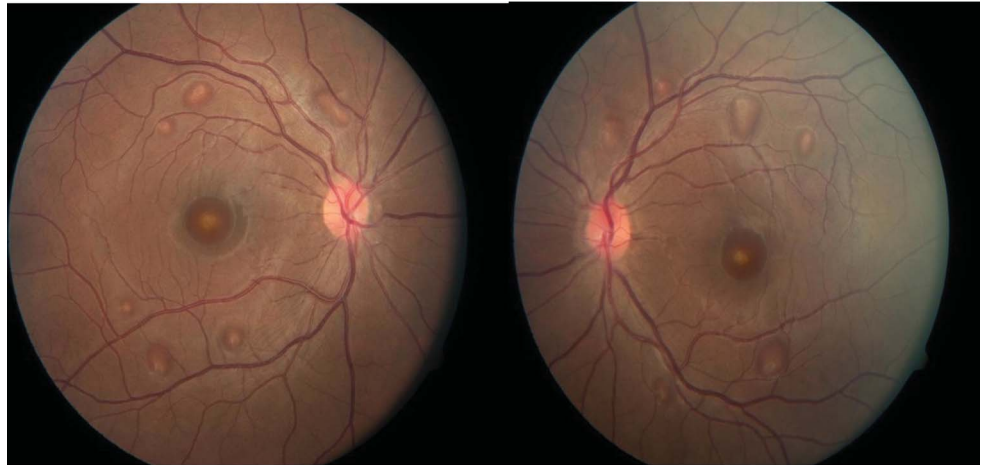
To our knowledge, this is the first case that describes bilateral, multifocal central serous retinopathy appearing 2 days after starting pimasertib for ovarian cancer and rapidly resolving 3 days after stopping pimasertib. Multifocal serous retinal detachments have been reported with the use of other MEK 1 and 2 inhibitors.<sup>4</sup> The pathophysiology of this complication is still poorly understood.

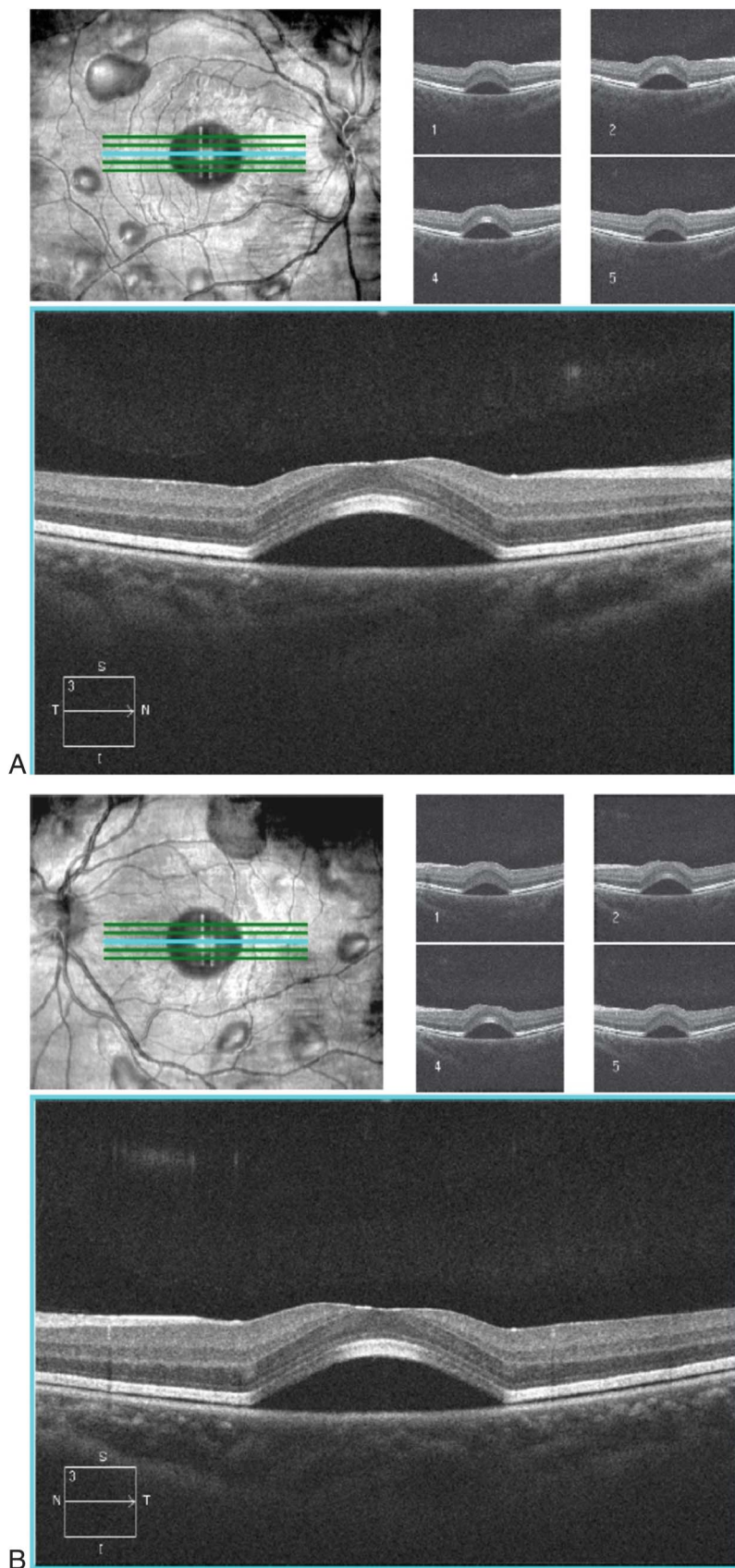
None of the authors have any financial/conflicting interests to disclose.

This is an open access article distributed under the terms of the Creative Commons Attribution-NonCommercial-NoDerivatives License 4.0 (CC BY-NC-ND), which permits downloading and sharing the work provided it is properly cited. The work cannot be changed in any way or used commercially.

Reprint requests: Wai-Ching Lam, MD, FRCSC, Department of Ophthalmology and Vision Sciences, Toronto Western Hospital, University of Toronto, 399 Bathurst Street, Room 6E-432, Toronto, Ontario M5T 2S8, Canada; e-mail: waiching.lam@utoronto.ca

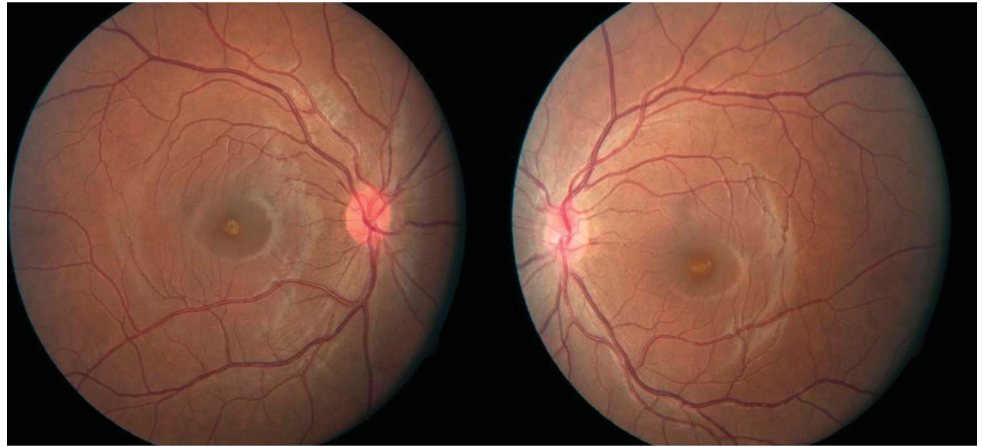**Fig. 1.** Fundoscopic exam showing multi-foci serous retinal detachments.

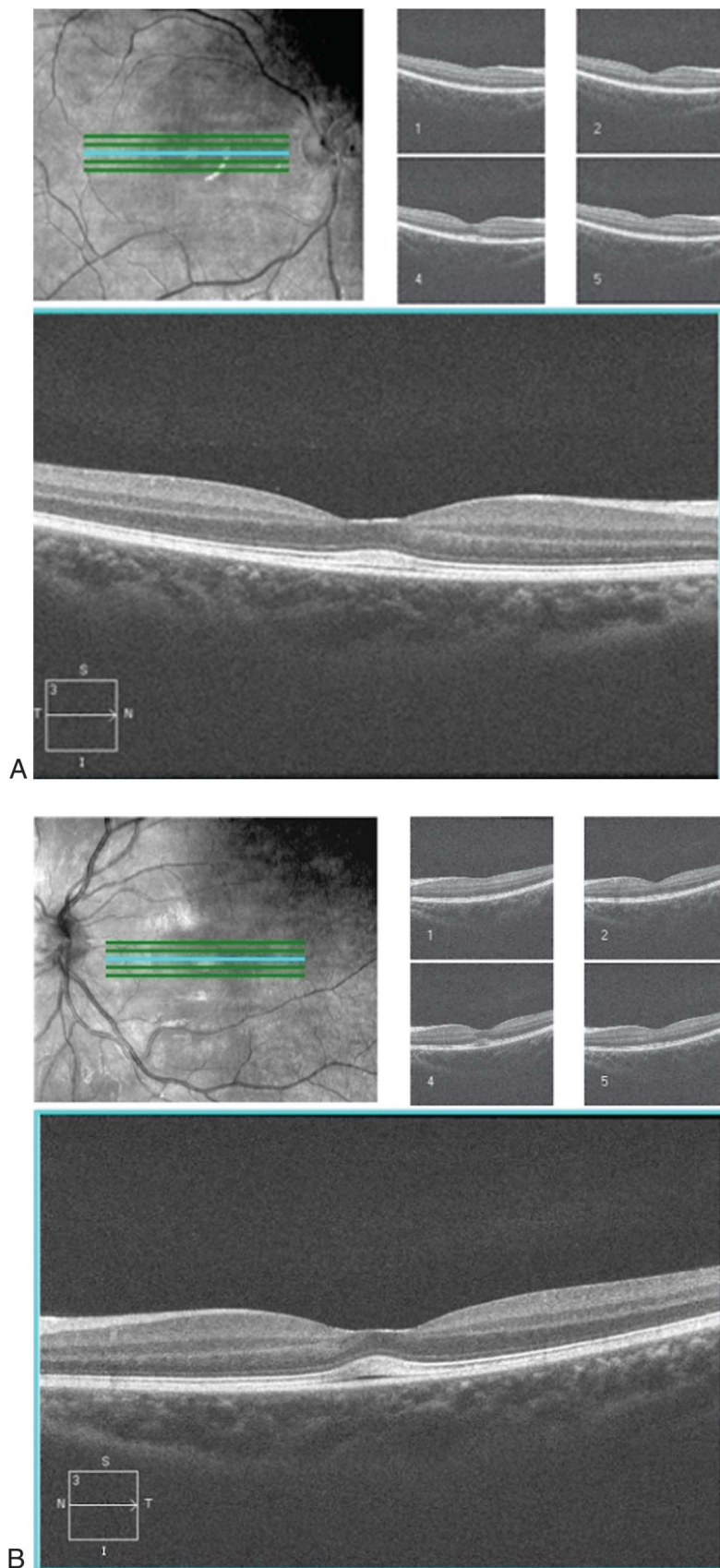




**Fig. 2.** A. Optical coherence tomography of the right eye showing multifocal serous retinal detachments. B. Optical coherence tomography of the left eye showing multifocal serous retinal detachments.

**Fig. 3.** Fundoscopic examination showing resolution of serous retinal detachments.





**Fig. 4.** A. Optical coherence tomography of the right eye showing complete resolution of serous retinal detachments after completing pimaseritib course. B. Optical coherence tomography of the left eye showing almost complete resolution of serous retinal detachments after completing pimaseritib course.

**Fig. 5.** Intravenous fundus fluorescein angiogram of both eyes was normal 3 days after stopping pimasetrib.

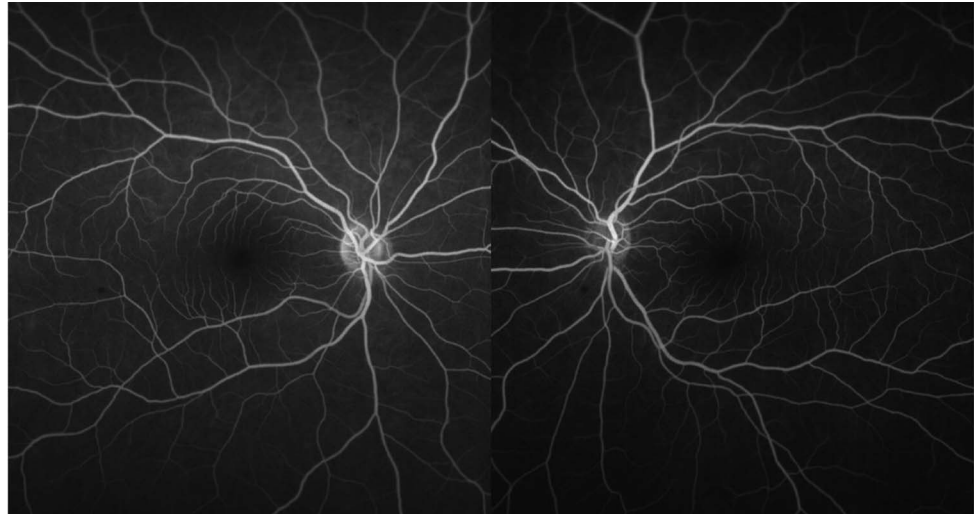


Table 1. Current MEK Inhibitors Clinical Trials and Associated Percentages of Ocular Toxicity as Well as the Most Common Side Effects

Clinical Trial	% of Ocular Toxicity	Most Common Side Effects
CI-1040 <sup>5</sup>	8.9	Nausea, diarrhea, rash, and fatigue
AZD 6244 (oral capsule) <sup>6</sup>	12.2	Nausea, diarrhea, rash, fatigue, and edema
GSK 1120212 <sup>7</sup>	9.0	Diarrhea, rash, fatigue, edema, and dermatitis
RO5126766 <sup>8</sup>	42.3	Diarrhea, rash, edema, elevated creatinine, and blurred vision
PD-0325901 <sup>9</sup>	10.6	Nausea, diarrhea, rash, fatigue, and edema

**Key words:** pimasetrib, MEK 1 and 2, serous retinal detachments.

### References

1. Miller CR, Oliver KE, Farley JH. MEK1/2 inhibitors in the treatment of gynecologic malignancies. *Gynecol Oncol* 2014;133:128–137.
2. Delord J, Houede N, Awada A, et al. First-in-human phase I safety, pharmacokinetic (PK), and pharmacodynamic (PD) analysis of the oral MEK-inhibitor AS703026 (two regimens [R]) in patients (pts) with advanced solid tumors. *J Clin Oncol* 2010;28:15.
3. Houede N, Faivre SJ, Awada A, et al. Safety and evidence of activity of MSC1936369, an oral MEK1/2 inhibitor, in patients with advanced malignancies. *J Clin Oncol* 2011;29:15.
4. McCannel T, Chmlelowski B, Finn RS, et al. Bilateral subfoveal neurosensory retinal detachment associated with MEK inhibitor use for metastatic cancer. *JAMA* 2014;132:1005–1009.
5. Rinehart J, Adjei A, LoRusso P, et al. Multicenter phase II study of the oral MEK inhibitor, CI-1040, in patients with advanced non-small cell lung, breast, colon, and pancreatic cancer. *J Clin Oncol* 2004;22:4456–4462.
6. Banerji U, Camidge DR, Verheul HMW, et al. The first-in-human study of the hydrogen sulfate (Hyd-sulfate) capsule of the MEK1/2 inhibitor AZD6244 (ARRY-142886): a phase I open-label multicenter trial in patients with advanced cancer. *Clin Cancer Res* 2010;16:1613–1623.
7. Gilmartin AG, Bleam MR, Groy A, et al. GSK1120212 (JTP-74057) is an inhibitor of MEK activity and activation with favorable pharmacokinetic properties for sustained in vivo pathway inhibition. *Clin Cancer Res* 2011;17:989–1000.
8. Martinez-Garcia M, Banerji U, Albanell J, et al. First-in-human, phase I dose-escalation study of the safety, pharmacokinetics, and pharmacodynamics of RO5126766, a first-in-class dual MEK/RAF inhibitor in patients with solid tumors. *Clin Cancer Res* 2012;18:4806–4819.
9. LoRusso PM, Krishnamurthi SS, Rinehart JJ, et al. Phase I pharmacokinetic and pharmacodynamic study of the oral MAPK/ERK kinase inhibitor PD-0325901 in patients with advanced cancers. *Clin Cancer Res* 2010;16:1924–1937.