



Title	Glaucoma Drainage Device Tube Retraction and Blockage in a Patient with Iridocorneal Endothelial Syndrome Treated With Nd:YAG Membranectomy
Author(s)	Choy, NKB; Chien, CPY; Lai, JSM; Chan, JCH
Citation	Journal of Clinical & Experimental Ophthalmology, 2015, v. 6, p. 489
Issued Date	2015
URL	http://hdl.handle.net/10722/221999
Rights	This work is licensed under a Creative Commons Attribution-NonCommercial-NoDerivatives 4.0 International License.

Glaucoma Drainage Device Tube Retraction and Blockage in a Patient with Iridocorneal Endothelial Syndrome Treated With Nd:YAG Membranectomy

Bonnie Nga Kwan Choy^{1*}, Carol Pui Yang Chien², Jimmy Shiu Ming Lai¹, Jonathan Cheuk Hung Chan³

¹Department of Ophthalmology, LKS Faculty of Medicine, The University of Hong Kong, Hong Kong SAR, People's Republic of China

²LKS Faculty of Medicine, The University of Hong Kong, Hong Kong SAR, People's Republic of China

³Department of Ophthalmology, Queen Mary Hospital, Hong Kong SAR, People's Republic of China

*Corresponding author: Bonnie Nga Kwan Choy, Department of Ophthalmology, The University of Hong Kong, Room 301, Block B, Cyberport 4, Hong Kong, Tel: 852 2255-5632; Fax: 852 2255-5398; Email: bonniechoykn@gmail.com

Received date: Sep 19, 2015; Accepted date: Oct 23, 2015; Published date: Oct 27, 2015

Copyright: © 2015 Choy BNK, et al. This is an open-access article distributed under the terms of the Creative Commons Attribution License, which permits unrestricted use, distribution, and reproduction in any medium, provided the original author and source are credited.

Abstract

Purpose: To report on a case that demonstrates the successful treatment of tube blockage of the Ahmed Glaucoma Valve at its aqueous entry site by Nd:YAG laser membranectomy.

Method: We report a case of refractory intraocular pressure elevation in a patient with iridocorneal endothelial syndrome after glaucoma drainage device due to blocked tube from the iridocorneal endothelial syndrome membrane.

In July 2014, our patient presented with sudden right eye elevated intraocular pressure to 67 mmHg despite a well-controlled intraocular pressure in the range of teens with timolol alone over the last 2 years. Gonioscopy showed total synechial angle closure and increasing her medical treatment failed to control the intraocular pressure. Ahmed glaucoma valve was implanted successfully. However, recurrence of raised intraocular pressure from partial tube retraction and tube blockage at its aqueous entry site by an endothelial membrane was noted at 2 weeks after the surgery. Nd:YAG laser membranectomy was performed on 2 occasions to restore the patency of the tube shunt. After the second laser membranectomy, the patient's intraocular pressure returned to, and remained at, normal level since.

Conclusion: Tube occlusion by membrane is a well-known complication following glaucoma drainage device tube in patients with iridocorneal endothelial syndrome. Nd:YAG membranectomy is effective to restore the patency of tube lumen without subjecting patients to more invasive surgical interventions including tube extender or another glaucoma drainage device. However, more studies are required to ascertain the long term effect of laser membranectomy to a blocked tube, in comparison to other treatment modalities. To our knowledge, this is the first reported case of using laser membranectomy alone in treating Ahmed glaucoma valve tube obstruction due to a retracted tube blocked by endothelial membrane.

Keywords: Laser membranectomy; Glaucoma drainage devices; Ahmed valve obstruction; Iridocorneal endothelial syndrome

Case presentation

A 62 year-old Chinese female was diagnosed with right eye iridocorneal endothelial syndrome (ICE) in 2012 and her intraocular pressure (IOP) had previously been maintained in the mid-teens on timolol 0.5% alone.

The patient presented with sudden onset of right side headache, right eye pain, redness, and blurred vision in July 2014. Right eye visual acuity was hand movement, and 0.6 on left eye. IOP by Goldmann applanation tonometry were 67 mmHg on right eye and 20 mmHg on left eye. Slit lamp examination revealed right eye corneal edema, and fixed and dilated pupil. There was no pupil block or iris bombe. The left anterior segment was unremarkable. Gonioscopy revealed complete synechial closure over the right eye with gross peripheral iridocorneal adhesions at superior and temporal quadrants; left eye angle was open. Cup disc ratio (CDR) was 0.6 and 0.4 over the right and left eye respectively, which had remained static for more than

2 years. The rest of the retina was unremarkable. As the IOP remains elevated despite maximal topical and systemic glaucoma medications, Ahmed Glaucoma Valve (AGV) implantation was performed on the following day. The surgery was uneventful and the IOP was normalized in the early post-operative period.

However right eye IOP increased to 60 mmHg 2 weeks after the procedure. On slitlamp examination, the tube was retracted with its tip just barely remaining in the anterior chamber (Figure 1). Gonioscopy revealed that the tube opening was covered by a whitish membrane (Figure 2). After considering different surgical options including tube repositioning to a more anterior position and placement of extension tube, we decided to attempt a non-surgical strategy with application of Nd:YAG laser to the tube opening to puncture the ICE membrane with aid of the Latina gonioscopes (used for selective laser trabeculoplasty). The laser energy used was 5 mJ with a total of 23 shots given. The IOP returned to 14 mmHg after the laser membranectomy. The procedure was repeated 4 weeks later for a recurrent blocked tube with ICE membrane leading to IOP elevation of 24 mmHg. The tube remained patent up to the last follow-up 10 months after initial surgery. The IOP

remained normal after the second membranectomy with the use of a single glaucoma medication for better IOP control.

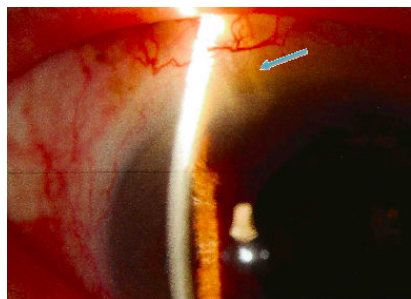


Figure 1: Ahmed glaucoma valve tube lumen that just exited into the anterior chamber.

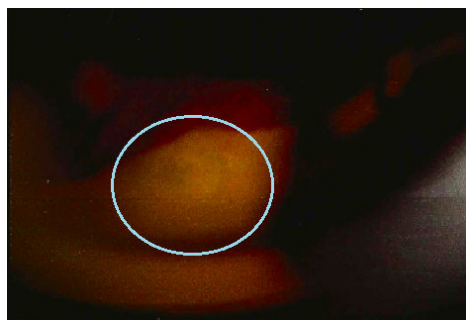

Figure 2: Gonioscopic finding showing the iridocorneal endothelial membrane obstructing the tube lumen.

Discussion

ICE syndrome is a disorder characterized by corneal endothelial cells that behave like epithelial cells, migrating to adjacent structures like the iris and trabecular meshwork, and secreting an abnormal basement membrane, which is similar to Descemet's membrane. Contraction of the membrane results in extensive peripheral anterior synechiae (PAS), iris (and pupillary) changes, and secondary angle-closure glaucoma. It comprises of three clinical variants: Chandler syndrome, progressive iris atrophy and Cogan-Reese syndrome. It is usually unilateral, and is diagnosed in young to middle-aged women. Glaucoma has been reported to occur in 50%-80% of patients [1]. Specular microscopy finding of disseminated or total involvement of the corneal endothelium with ICE cells, which have irregular size and shape, is a strong predictor of glaucoma development.

The management of glaucoma in ICE syndrome is challenging. Medical treatment may initially control the IOP but often becomes ineffective as the disease progresses [1]. Laser trabeculoplasty is technically not possible due to inaccessibility of the trabecular meshwork from synechial angle-closure and/or the overlying cellular membrane. Some investigators believe that laser trabeculoplasty in ICE syndrome may even exacerbate the condition [2].

The reported success rates for trabeculectomy with antifibrotic agents ranges from 60% to 73% at 1 year and 29% at 5 years [1,3]. However, failure occurs earlier than other types of glaucoma due to

younger age of patients, more intense fibrotic response, membrane proliferation and formation of PAS [1,3]. Endothelialization and growth of abnormal basement membrane in the ostium also causes failure. Nd:YAG laser is a non-surgical option way to puncture the ICE membrane occluding the internal ostium.

Glaucoma drainage device (GDD) is a common first line surgical approach for patients with ICE syndrome. As in our patient, the extensive PAS would prevent the creation of an ostium that could communicate with the anterior chamber with trabeculectomy, GDD would be the only surgical option. Long-term surgical outcomes have been reported to be slightly better in GDD than in trabeculectomy [3]. Common complications in GDD include proliferation of the ICE membrane into the tube causing tube occlusion, and the formation of the iridocorneal adhesions and contraction of the membrane could also cause migration of the tube as in our patient. Surgical options include replacement of the retracted tube with a tube extender, tube repositioning to a more anterior position, and introduction of additional GDD. However, all these require an additional surgery and the long-term outcome is uncertain. The use of laser is a promising way to puncture the ICE membrane at the occluded lumen when the tube is still situated within the anterior chamber. It is much easier and faster to perform, eliminates the risks associated with intraocular surgery and the procedure is repeatable. There is a reported case on the use of Nd:YAG laser to restore the tube lumen patency, which was plugged by the PAS and iris and the IOP rose to 28 mmHg [4] and another case which used Nd:YAG laser to puncture the ICE membrane but later required surgical repositioning of the tube 10 weeks later [5]. However, it may be difficult to visualize the transparent membrane during the laser procedure to ensure the patency of the lumen and occlusion may be recurrent, requiring repeated laser treatment. Literature on the use of laser membranectomy is limited, more studies to look for its efficacy is warranted. Nonetheless, as intraocular surgery may be avoided, it is probably worthwhile to attempt laser treatment before considering further surgical intervention.

To conclude, occlusion of GDD tube in ICE patient is not uncommon and additional intervention is often needed to restore tube patency. Laser membranectomy is non-invasive and effective in our patient to restore tube lumen patency although its use was seldom reported in the literature. Further study is needed to compare the effectiveness of different modalities in the management of a blocked GDD tube. To our knowledge, this is the first reported case of treatment with Nd:YAG laser to restore the patency of the AGV tube lumen obstructed by the ICE membrane and the tube remained patent at least 15 months after the initial surgery without additional surgical intervention.

References

1. Laganowski HC, Kerr Muir MG, Hitchings RA (1992) Glaucoma and the iridocorneal endothelial syndrome. *Arch Ophthalmol* 110: 346-350.
2. Olawoye O, Teng CC, Liebmann JM, Wang FM, Ritch R (2011) Iridocorneal Endothelial Syndrome in a 16-Year-Old. *J Glaucoma* 20: 294-297.
3. Doe EA, Budenz DL, Gedde SJ, Imami NR (2001) Long-term surgical outcomes of patients with glaucoma secondary to the iridocorneal endothelial syndrome. *Ophthalmology* 108:1789-1795.
4. Kim DK, Aslanides IM, Schmidt CM Jr, Spaeth GL, Wilson RP, et al. (1999) Long-term outcome of aqueous shunt surgery in ten patients with iridocorneal endothelial syndrome. *Ophthalmology* 106: 1030-1034

Citation: Choy BNK, Chien CPY, Lai JSM, Chan JCH (2015) Glaucoma Drainage Device Tube Retraction and Blockage in a Patient with Iridocorneal Endothelial Syndrome Treated With Nd:YAG Membranectomy. *J Clin Exp Ophthalmol* 6: 489. doi: [10.4172/2155-9570.1000489](https://doi.org/10.4172/2155-9570.1000489)

5. Singh K, Eid TE, Katz LJ, Spaeth GL, Augsburger JJ (1997) Evaluation of Nd:YAG laser membranectomy in blocked tubes after glaucoma tube-shunt surgery. *Am J Ophthalmol* 124: 781-786.