



<b>Title</b>	<b>Intraocular Pressure Elevation in the Contralateral Untreated Eye Following Selective Laser Trabeculoplasty in Rabbit Eyes</b>
<b>Author(s)</b>	<b>Choy, NKB; Chiu, K; Shum, JWH; Lai, JSM</b>
<b>Citation</b>	<b>Journal of Clinical &amp; Experimental Ophthalmology, 2015, v. 6, p. 477</b>
<b>Issued Date</b>	<b>2015</b>
<b>URL</b>	<b><a href="http://hdl.handle.net/10722/221998">http://hdl.handle.net/10722/221998</a></b>
<b>Rights</b>	<b>This work is licensed under a Creative Commons Attribution-NonCommercial-NoDerivatives 4.0 International License.</b>

## Intraocular Pressure Elevation in the Contralateral Untreated Eye Following Selective Laser Trabeculoplasty in Rabbit Eyes

Bonnie Nga Kwan Choy<sup>1\*</sup>, Catherine Kin Chiu<sup>2,3</sup>, Jennifer Wei Huen Shum, Jian Ji<sup>4</sup>, Ai Hua Liu<sup>4</sup>, Wei Liu<sup>4</sup> and Jimmy Shiu Ming Lai<sup>1</sup>

<sup>1</sup>Department of Ophthalmology, LKS Faculty of Medicine, The University of Hong Kong, Hong Kong SAR, People's Republic of China

<sup>2</sup>Research Centre of Heart, Brain, Hormone and Healthy Aging, The University of Hong Kong, Hong Kong SAR, People's Republic of China

<sup>3</sup>State Key Laboratory of Brain and Cognitive Sciences, The University of Hong Kong, Hong Kong SAR, People's Republic of China

<sup>4</sup>Tianjin Medical University Eye Hospital, Tianjin, People's Republic of China

\*Corresponding author: Bonnie Nga Kwan Choy, Department of Ophthalmology, The University of Hong Kong, Room 30, Block B, Cyberport 4, Hong Kong, People's Republic of China, Tel: 852 2255-5632; Fax: 852 2255-5398; Email: [bonniechoyнк@gmail.com](mailto:bonniechoyнк@gmail.com)

Received date: Aug 05, 2015; Accepted date: Sep 16, 2015; Published date: Sep 19, 2015

Copyright: © 2015 Choy BNK et al. This is an open-access article distributed under the terms of the Creative Commons Attribution License, which permits unrestricted use, distribution, and reproduction in any medium, provided the original author and source are credited.

### Abstract

Our study aimed at evaluating if a single session of unilateral selective laser trabeculoplasty would affect the intraocular pressure of the fellow untreated eye in rabbits. Eleven rabbits were involved. 360° selective laser trabeculoplasty with 532 nm frequency-doubled green Nd:YAG laser was performed over the right eyes. The mean intraocular pressure of both eyes at baseline, 3 hours, 24 hours, 3 days and 7 days after laser were measured. The baseline mean intraocular pressure of the right eye and the left eye were  $8.07 \pm 1.72$  mmHg and  $8.27 \pm 1.56$  mmHg respectively ( $p=0.78$ ). The mean intraocular pressure of the treated eye was lower than the baseline from 3 hours through 3 days after laser, with a maximum mean decrease of 1.36 mmHg on Day 3. On the contrary, the mean intraocular pressures of the untreated eyes were higher than the baseline throughout the study, particularly at later course (1.91 mmHg on Day 3 and 1.85 mmHg on Day 7). This suggests the change of intraocular pressure in one eye after selective laser trabeculoplasty, leads to a change in the pressure of the fellow eye. It is thought that a neuronal and humoral response is triggered centrally after unilateral intraocular pressure change. The detailed mechanisms would require further studies to evaluate. The rising intraocular pressure trend in the contralateral untreated eye suggests that response may continue to exert its action for some time after the initial laser. This is the first reported study of intraocular pressure elevation of the untreated eye following contralateral selective laser trabeculoplasty.

**Keywords:** Consensual ophthalmotonic reaction; Intraocular pressure elevation; Selective laser trabeculoplasty

### Introduction

Selective laser trabeculoplasty (SLT) has been used as a non-invasive mean to lower intraocular pressure (IOP). The mechanisms by which SLT works are thought to be multifaceted. SLT induces minimal structural changes in the trabecular meshwork [1] in contrast to argon laser trabeculoplasty. Therefore, the liberation of humoral factors is thought to play a significant role in IOP reduction, which was also observed in animal models involving rabbits [2,3]. There were a few animal studies to suggest that the chemical components of the aqueous was modified after SLT [4,5]. There were suggestions that the liberation of cytokines could trigger the change of IOP in the contralateral untreated eye through central response, and this is termed consensual ophthalmotonic reaction (COR). In previous human studies, it was shown that monocular SLT [6] and argon laser trabeculoplasty [7] resulted in fellow eye IOP reduction. However, COR after trabeculectomy has a more diverse outcome, with an increase, decrease or no change in the fellow eye IOP all having been reported [8-10]. In our study, IOP elevation was demonstrated in the fellow untreated eye following SLT in rabbits, which, to the best of our knowledge, has not been reported in the literature.

### Materials and Methods

A total of 12 blue-purple rabbits of mixed gender, aged 12 months, weighing 2-3.5 kg with normal ocular examination were included. The baseline IOP were measured over both eyes by tonovET tonometer (iCare, Finland) under local anesthesia (0.4% Benoxil, Santen Pharmaceutical Co., Ltd, Osaka, Japan). Five IOP readings were taken each time and the average was used for analysis. The right eye of each rabbit was subjected to 360° SLT with 532 nm frequency-doubled green Nd:YAG laser (Laserex Tango, Ellex Medical Pty. Ltd.) via a gonioscopy laser lens (Ocular Latina SLT Gonio Laser). The settings were spot size of 400  $\mu$ m, duration of 3 ns, power of 0.5-1.1 mJ, and 100 laser spots over 360°. The IOP over both eyes was measured at 3 hours, 24 hours, 3 days and 7 days after SLT using the same technique as baseline measurement. All IOP measurements were performed by the same experienced personnel (CK) at the same time of the day to reduce the possible effect of circadian rhythm (except at 3 hours). The study protocol was approved by the Animal Ethics Committee of the Tianjin Medical University and was conducted conforming to institutional standards.

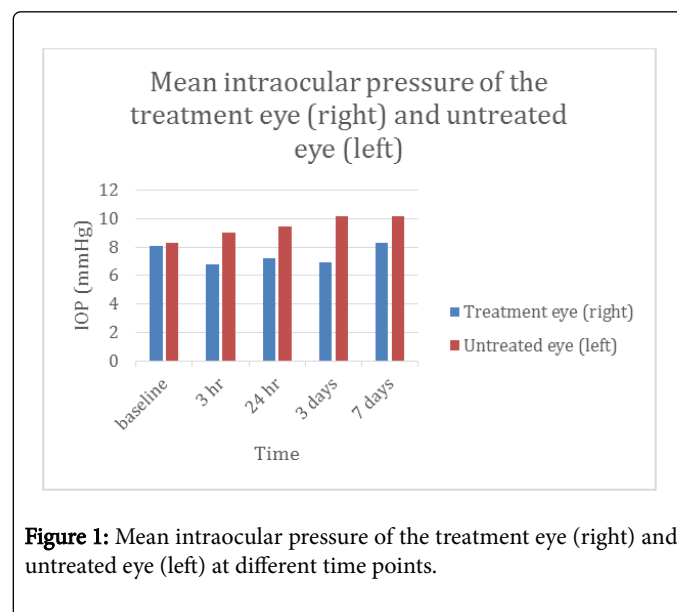
Data is presented as mean  $\pm$  standard deviation. Paired t-test was used to compare the baseline and post-SLT IOP; and unpaired t-test was used to compare the difference of IOP between the 2 eyes at different time points. A  $p$  value  $<0.05$  was considered to reflect significance.

## Results

One out of the 12 rabbits demonstrated inflammatory exudation over the right eye after SLT and was excluded from the study. The IOP of the remaining 11 rabbits were analyzed. The mean IOP of both eyes at baseline, 3 hours, 24 hours, 3 days and 7 days are presented in Figure 1. There was no statistical difference in the baseline IOP between the 2 eyes ( $p=0.78$ ). Following a single session of SLT, right eye IOP was lower than that of left eye from 3 hours to 7 days, and the difference was statistically significant from 3 hours to 3 days. The mean IOP of the treatment eyes were consistently lower than the baseline from 3 hours through 3 days after SLT, although the differences were not statistically significant. On the contrary, the mean IOP of the untreated eyes were consistently higher than baseline throughout the study period (Figure 1). The IOP of the untreated eyes was significantly higher than baseline at 3 days ( $p<0.01$ ) and 7 days ( $p<0.01$ ) (Figure 1), Table 1.

Regarding the change in IOP, a reduction in the mean IOP in the range of 0.85-1.37mmHg compared to the baseline was demonstrated in the treatment eye from 3 hours to 3 days after SLT (Figure 2). However, over the untreated left eyes, there was an increase in IOP demonstrated from 3 hours to 7 days after right eye SLT in the range of 0.71-1.91 mmHg. The effect was more pronounced in the later course when there was a 23% and 22% increase in mean IOP from the

baseline on the 3<sup>rd</sup> and 7<sup>th</sup> day respectively, compared to early post-SLT period (3 hours and 24 hours) (Figure 2).



**Figure 1:** Mean intraocular pressure of the treatment eye (right) and untreated eye (left) at different time points.

	Treatment eye (right) Mean $\pm$ standard variation (95% confidence interval)	Untreated eye (left) Mean $\pm$ standard variation (95% confidence interval)	P value of the difference between the 2 eyes *Unpaired t-test	P value of the difference between intraocular pressure at different time points and the baseline *Paired t-test	
				Treatment eye (right)	Untreated eye (left)
Baseline	8.07 $\pm$ 1.72 (6.91-9.23)	8.27 $\pm$ 1.56 (7.22-9.32)	0.778		
3 hours	6.81 $\pm$ 2.24 (5.31-8.31)	8.98 $\pm$ 2.27 (7.45-10.51)	0.035	0.153	0.402
24 hours	7.23 $\pm$ 1.80 (6.02-8.44)	9.42 $\pm$ 2.75 (7.57-11.27)	0.041	0.273	0.092
3 days	6.91 $\pm$ 2.28 (5.38-8.44)	10.18 $\pm$ 2.83 (8.28-12.08)	<0.01	0.117	0.005
7 days	8.31 $\pm$ 2.40 (6.70-9.92)	10.13 $\pm$ 2.31 (8.58-11.68)	0.085	0.966	0.002

**Table 1:** Mean intraocular pressure of the treatment eye (right) and untreated eye (left) at different time points.

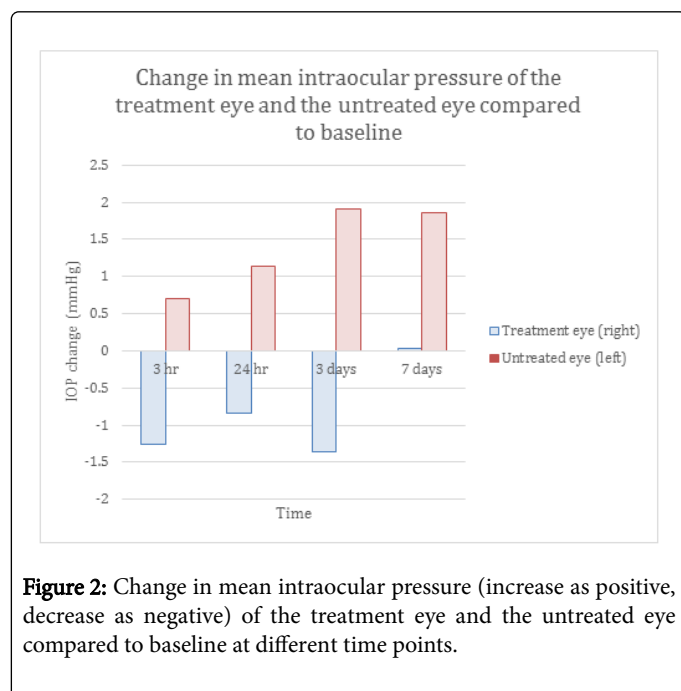
## Discussion

IOP is determined by the balance between the amount and rate of aqueous production and drainage. Both the aqueous production and the outflow facilities are affected by the humoral and vascular response, which is in turn governed by the central nervous system. Therefore, a unilateral change in IOP could lead to a change in IOP of the contralateral eye. This phenomenon is termed consensual ophthalmotonic response (COR). COR has been observed in various animal studies. Intracameral injection of prostaglandin A, E2 and F2a into one eye was shown to result in delayed IOP rise in both the treatment eye and the untreated fellow eye, while the miotic effect was observed in only the treated eye [11]. In another study, a significant

rise in aqueous flow was observed in the fellow eye after unilateral trabeculectomy, suggesting the central influence on aqueous production in both eyes following unilateral IOP reduction [12].

From our results, IOP reduction was observed in the treatment eye as soon as 3 hours after SLT, and the effect was maintained to 3 days. In response to the IOP reduction to the treatment eye, an IOP increase in the fellow eye was seen starting from 3 hours, and the effect lasted till 7 days. This suggested that either IOP reduction in the treated eyes or SLT itself might trigger an almost immediate IOP elevation effect on the fellow eyes. Such immediate effect could possibly be regulated by humoral, vascular and neuronal response, mediated by central system. The IOP elevation over the untreated eyes was the most pronounced

on the 3rd day, which might suggest the IOP regulatory system took time to reach a maximal response.



**Figure 2:** Change in mean intraocular pressure (increase as positive, decrease as negative) of the treatment eye and the untreated eye compared to baseline at different time points.

Despite the IOP reduction effect was lost after the 3rd day over the treatment eyes, the IOP elevation of the untreated eyes was maintained through the 7<sup>th</sup> days. We hypothesize that there was modification in the microscopic structure of the untreated eyes which might involve the ciliary body for aqueous production or the trabecular meshwork for aqueous outflow, to maintain the IOP elevation effect of the untreated eye. However, this hypothesis would need further analysis of the anatomical structure of the IOP-controlling facilities to confirm. In fact, we could see that the IOP elevation in the untreated eyes was even more prominent than the IOP reduction in the treatment eyes from 24 hours to 7 days. Further analysis on this phenomenon would be essential because this might propose a deleterious effect if this happens in human eyes, where the fellow eye IOP might be dangerously elevated in patients receiving unilateral SLT. After 7 days, the IOP lowering effect of SLT was lost in the treated eyes, and the IOP elevation of the fellow eyes was less pronounced than on the 3rd day. One of our hypothesis was that the significantly elevated IOP in the untreated eyes could lead to an auto-regulatory response such that the IOP of both eyes returned to the baseline. However, we could only confirm this observation with more IOP measurements between the 3rd and 7th days, as well as beyond the 7th day.

Rhodes et al. had previously demonstrated in human subjects [6] that the fellow untreated eye showed an IOP reduction following unilateral SLT, which differs from our findings. However, their results could have been confounded by improved glaucoma medication following laser treatment, or even systemic absorption of glaucoma medications. These confounding factors are eliminated in our study.

Limitations of our study include a small sample size. Also, the degree of IOP elevation in the fellow eye was rather small (1.91 mmHg)

and 1.86 mmHg). This could be due to the low baseline IOP (8.27 mmHg) in our rabbits. In future studies, animals with higher baseline IOP could be used to evaluate the IOP response. Furthermore, as our animal sampling represent healthy eyes, whether the same effect and degree of IOP change will be observed in glaucomatous eyes would need to be evaluated in future studies.

In conclusion, we observed an IOP reduction after SLT in rabbit eyes from 3 hours after the procedure. The untreated fellow eyes also demonstrated an elevation of IOP which persisted till 7 days post laser. This suggests there is a regulatory system governing the IOP of both eyes despite treatment on unilateral eye. This possibility of significant IOP elevation in the fellow untreated eye after unilateral SLT has significant clinical implications, especially if SLT is performed unilaterally, and the fellow eye has underlying glaucoma. Further studies on the exact mechanisms and the risk factors (such as the power of SLT, number of repeats of SLT and the type of glaucoma) of the fellow eye IOP elevation would be warranted. To our best knowledge, this is the first animal study looking into the effects of unilateral SLT on the IOP profile over both eyes. This is also the first study which demonstrated an elevation of IOP in the untreated fellow eye following unilateral SLT.

## References

1. Kramer TR, Noecker RJ (2001) Comparison of the morphologic changes after selective laser trabeculoplasty and argon laser trabeculoplasty in human eye bank eyes. *Ophthalmology* 108: 773-779.
2. Gulati V, Pahuja S, Fan S, Toris CB (2013) An experimental steroid responsive model of ocular inflammation in rabbits using an SLT frequency doubled Q switched Nd:YAG laser. *J Ocul Pharmacol Ther* 29: 663-669.
3. Guzey M, Vural H, Satici A (2001) Endothelin-1 increase in aqueous humour caused by frequency-doubled Nd:YAG laser trabeculoplasty in rabbits. *Eye (Lond)* 15: 781-785.
4. Amelinckx A, Castello M, Arrieta-Quintero E, Lee T, Salas N, et al. (2009) Laser trabeculoplasty induces changes in the trabecular meshwork glycoproteome: a pilot study. *J Proteome Res* 8: 3727-3736.
5. Guzey M, Vural H, Satici A, Karadede S, Dogan Z (2001) Increase of free oxygen radicals in aqueous humour induced by selective Nd:YAG laser trabeculoplasty in the rabbit. *Eur J Ophthalmol* 11: 47-52.
6. Rhodes KM, Weinstein R, Saltzman RM, Aggarwal N, Kooner KS, et al. (2009) Intraocular pressure reduction in the untreated fellow eye after selective laser trabeculoplasty. *Curr Med Res Opin* 25: 787-796.
7. Brooks AM, West RH, Gillies WE (1988) Argon laser trabeculoplasty five years on. *Aust N Z J Ophthalmol* 16: 343-351.
8. Yarangümelı A, Köz OG, Kural G (2003) The effect of trabeculectomy on the intraocular pressure of the unoperated fellow eye. *J Glaucoma* 12: 108-113.
9. Vysniauskiene I, Shaarawy T, Flammer J, Haefliger IO (2005) Intraocular pressure changes in the contralateral eye after trabeculectomy with mitomycin C. *Br J Ophthalmol* 89: 809-811.
10. Detorakis ET, Tsiklis N, Pallikaris IG, et al. (2011) Changes in the intraocular pressure of fellow untreated eyes following uncomplicated trabeculectomy. *Ophthalmic Surg Lasers Imaging* 42: 138-143.
11. Beitch BR, Eakins KE (1969) The effects of prostaglandins on the intraocular pressure of the rabbit. *Br J Pharmacol* 37: 158-167.
12. Diestelhorst M, Krieglstein G (1991) The effect of trabeculectomy on the aqueous humor flow of the unoperated fellow eye. *Graefes Arch Clin Exp Ophthalmol* 229: 274-276.