

RVC OPEN ACCESS REPOSITORY – COPYRIGHT NOTICE

This is the peer reviewed version of the following article:

Fitzgerald, E., Priestnall, S. L. and Lamb, C. R. (2016), IMAGING DIAGNOSIS—COMPUTED TOMOGRAPHY OF TRACTION BRONCHIECTASIS SECONDARY TO PULMONARY FIBROSIS IN A PATERDALE TERRIER. *Veterinary Radiology & Ultrasound*. doi:10.1111/vru.12403

which has been published in final form at <http://dx.doi.org/10.1111/vru.12403>.

This article may be used for non-commercial purposes in accordance with [Wiley Terms and Conditions for Self-Archiving](#).

The full details of the published version of the article are as follows:

TITLE: IMAGING DIAGNOSIS—COMPUTED TOMOGRAPHY OF TRACTION BRONCHIECTASIS SECONDARY TO PULMONARY FIBROSIS IN A PATERDALE TERRIER

AUTHORS: Fitzgerald, E., Priestnall, S. L. and Lamb, C. R.

JOURNAL TITLE: *Veterinary Radiology & Ultrasound*

PUBLISHER: Wiley

PUBLICATION DATE: July 2016 (online)

DOI: 10.1111/vru.12403

1 **Imaging diagnosis**

2 **Computed tomography of traction bronchiectasis secondary to pulmonary**
3 **fibrosis in a Patterdale terrier**

4 Ella Fitzgerald, Simon L. Priestnall, Christopher R. Lamb

5 The Royal Veterinary College, University of London

6

7 Address correspondence to: C.R. Lamb, Department of Clinical Sciences and

8 Services, The Royal Veterinary College, Hawkshead Lane, North Mymms,

9 Hertfordshire AL9 7TA, UK

10

11 **Abstract**

12 An 8-year-old, Patterdale terrier was referred for evaluation of tachypnoea, exercise

13 intolerance, and weight loss. Computed tomographic images showed

14 pneumomediastinum, diffuse ground glass opacity, and marked dilatation of

15 peripheral bronchi, but no thickened bronchial walls. The histopathologic diagnosis

16 was diffuse pulmonary interstitial fibrosis, type II pneumocyte hyperplasia, and

17 bronchiectasis. The lack of evidence of primary bronchitis supports a diagnosis of

18 traction bronchiectasis. Traction bronchiectasis can occur as a sequela to pulmonary

19 fibrosis in dogs.

20 Key words: computed tomography, dog, pneumomediastinum, pulmonary fibrosis,

21 traction bronchiectasis

22 Running head: Traction bronchiectasis in a Patterdale terrier

23 **Signalment, history and clinical findings**

24 An 8-year-old female neutered Patterdale terrier had worsening tachypnoea,
25 exercise intolerance and weight loss over a period of 4 months. A short course of
26 broad-spectrum antibiotics and anti-inflammatory drugs had no apparent effect on
27 clinical signs. At referral, there was marked tachypnea (120 breaths per minute) and
28 inspiratory dyspnea. No abnormal breath sounds were identified on auscultation.
29 Mucous membranes were slightly tacky with a normal capillary refill time.
30 Cardiovascular evaluation was unremarkable and body temperature was normal
31 (38°C). Body condition score was 3/9. Haematological and biochemical evaluation
32 revealed slightly increased urea, creatinine, creatine kinase and total protein.
33 Echocardiography revealed no abnormalities. Blood antigen test for canine
34 lungworm (*Angiostrongylus vasorum*) was negative. Shortly after arrival, the patient's
35 respiratory rate and effort increased. The dog became hypoxic and was placed in an
36 oxygen chamber.

37

38 **Imaging diagnosis and outcome**

39 Thoracic radiography at the primary care practice 3 months prior to referral found a
40 pneumomediastinum and diffuse, unstructured interstitial pattern affecting all lung
41 lobes. To further characterize the pulmonary changes computed tomography (CT) of
42 the thorax was performed using a 16-slice scanner (Mx8000 IDT, Philips, Best, The
43 Netherlands) with the dog in ventral recumbency under general anesthesia. The CT
44 settings were 120 kVp, 150 mA, 16 x 1.5 mm collimation, pitch 1, tube rotation time
45 0.5s, and 3mm reconstruction slice thickness. Images were reconstructed using
46 medium and high frequency algorithms. Images were acquired pre- and post-

47 intravenous bolus injection of contrast medium at 600mg/kg body weight
48 (Omnipaque, iohexol, 300 mg I/mL, GE Healthcare AS, Nycoveie 1–2, NO-0401
49 Oslo, Norway). There was a large volume pneumomediastinum and diffuse, uniform
50 pulmonary ground-glass opacity (700HU), and a lack of normal tapering and
51 dilatation of the peripheral bronchi, but no apparent thickening of the bronchial walls
52 (Fig. 1).

53 Dilatation of the peripheral bronchi was considered to be the major finding, indicative
54 of bronchiectasis, whereas pneumomediastinum and pulmonary ground-glass
55 attenuation were non-specific findings. Differential diagnoses for bronchiectasis
56 include primary bronchial disease (i.e. chronic bronchitis) or traction bronchiectasis
57 secondary to pulmonary fibrosis. The history, clinical signs, and lack of bronchial wall
58 thickening supported the latter diagnosis.

59 A post-CT bronchoalveolar lavage revealed a mild neutrophilic inflammation. No
60 bacterial growth was noted after four days of incubation and further culture for
61 *Mycoplasma* spp. was negative. A short trial of systemic steroids and inhaled
62 bronchodilator (Salbutamol) was initiated, and the dog continued to receive
63 supplemental oxygen; however, signs continued to worsen with increasing
64 respiratory rate and effort. The dog was euthanized at the owners' request.

65 At necropsy, there was pneumomediastinum and the lungs were firm and diffusely
66 pale. Multiple small (<2mm diameter) raised foci were noted on the visceral pleural
67 surface, which was thickened and had a wrinkled contour. Histologic examination of
68 the lung found marked thickening of the alveolar septa and subpleural space with
69 fibrous connective tissue. Multiple alveoli were lined by plump cuboidal cells
70 consistent with type II pneumocyte hyperplasia. In addition, the alveolar spaces
71 contained proteinaeous material, foamy macrophages and multinucleate

72 hemosiderin-containing cells (hemosiderophages). Markedly dilated terminal
73 bronchioles were identified adjacent to the pleural surface (Fig. 2). The histologic
74 diagnosis was marked, diffuse, chronic interstitial fibrosis and chronic-active
75 alveolitis with secondary traction bronchiectasis.

76

77 **Discussion**

78 Traction bronchiectasis is an irreversible dilation of the bronchioles that occurs
79 secondary to pulmonary fibrosis.¹ In humans, it is often associated with end-stage
80 lung disease but has also been identified with other chronic lung diseases.² Three
81 mechanisms of bronchial dilation have been described: damage to the bronchial
82 wall, obstruction of the lumen, and traction from surrounding fibrotic tissue.² Damage
83 to the bronchial wall is usually secondary to infection and the associated
84 inflammatory response with release of inflammatory mediators including neutrophil
85 elastases, which degrade mural connective tissue. In chronic bronchitis, thickening
86 of bronchial walls, dilatation of bronchi, and mucus plugging the bronchial lumen may
87 be observed. In traction bronchiectasis, tension arising from contraction of
88 surrounding fibrous tissue dilates the bronchial lumen without other signs of
89 bronchial disease. In each form of bronchiectasis, there is chronic irreversible
90 damage to the supportive connective tissue within the bronchial and bronchiolar
91 wall.²

92 The term “honeycombing” has been associated end-stage interstitial lung fibrosis
93 and describes clusters of subpleural cystic airspaces. Histologically, there is
94 complete loss of acinar architecture.³ In the present case, there was intervening lung

95 between dilated airspaces, hence it would be incorrect to use the term
96 “honeycombing”.⁴

97 Traction bronchiectasis has been reported as a sequela to pulmonary fibrosis in
98 dogs⁵, but not illustrated. *Ante mortem* diagnosis of pulmonary fibrosis is difficult and
99 relies on exclusion of other types of infiltrative disease such as interstitial
100 pneumonia, neoplasia, and non-cardiogenic edema. Definitive diagnosis depends on
101 lung biopsy, which is an invasive procedure with significant morbidity.⁶ In humans,
102 CT findings alone can now be used to diagnose idiopathic pulmonary fibrosis without
103 the need for tissue confirmation.⁷ Traction bronchiectasis is a key criterion for CT
104 diagnosis of pulmonary fibrosis in humans.⁷ Increasing severity of traction
105 bronchiectasis correlates with a poorer prognosis in humans.⁸ However such a
106 correlation has not been made in veterinary medicine. In the present case, the CT
107 finding of peripheral bronchiectasis was an important sign of pulmonary fibrosis.

108 Pneumomediastinum (and pneumothorax) have been observed in dogs with
109 bronchiectasis.⁹ In these cases, air leaks through sites of alveolar rupture, tracks
110 along the bronchovascular interstitium and accumulates within the mediastinum. This
111 is the Macklin effect.¹⁰ The specific site of air leak causing pneumomediastinum was
112 not identified in the present case. It is possible that a sudden increase in the volume
113 of mediastinal air in this patient may account for the acute respiratory
114 decompensation following admission.

115 **References**

- 116 1. Westcott JL, Cole SR. Traction bronchiectasis in end-stage pulmonary fibrosis.
117 Radiology. 1986;**161**:665–9.
- 118 2. Javidan-Nejad C, Bhalla S. Bronchiectasis. Radiol Clin North Am. 2009;**47**:289–
119 306.
- 120 3. Hansell DM, Bankier AA, MacMahon H, McLoud TC, Müller NL, Remy J.
121 Fleischner Society: glossary of terms for thoracic imaging. Radiology.
122 2008;**246**:697–722.
- 123 4. Arakawa H, Honma K. Honeycomb lung: history and current concepts. Am J
124 Roentgenol. 2011; **196**:773–82.
- 125 5. Heikkilä HP, Lappalainen AK, Day MJ, Clercx C, Rajamäki MM. Clinical,
126 Bronchoscopic, Histopathologic, Diagnostic Imaging, and Arterial Oxygenation
127 Findings in West Highland White Terriers with Idiopathic Pulmonary Fibrosis. J
128 Vet Intern Med. 2011;**25**:433–9.
- 129 6. Zekas LJ, Crawford JT, O'Brien RT. Computed Tomography-guided fine aspirate
130 and tissue-core biopsy of intrathoracic lesions in thirty dogs and cats. Vet Radiol
131 Ultrasound. 2005;**46**:200–4.
- 132 7. Gruden JF. CT in Idiopathic Pulmonary Fibrosis: Diagnosis and Beyond. Am J
133 Roentgenol 2016;**206**:495–507.
- 134 8. Edey AJ, Devaraj AA, Barker RP, Nicholson AG, Wells AU, Hansell DM. Fibrotic
135 idiopathic interstitial pneumonias: HRCT findings that predict mortality. Eur
136 Radiol 2011;**21**:1586–93.

137 9. Johnson LR, Johnson EG, Vernau W, KASS PH, Byrne BA. Bronchoscopy,
138 Imaging, and Concurrent Diseases in Dogs with Bronchiectasis: (2003-2014). J
139 Vet Intern Med 2016;**30**:247–54.

140 10. Macklin MT, Macklin CC. Malignant interstitial emphysema of the lungs and
141 mediastinum as an important occult complication in many respiratory diseases
142 and other conditions: interpretation of the clinical literature in the light of
143 laboratory experiment. Medicine 1944;**23**:281–358.

144

145 **List of Author Contributions**

146 Category 1

147 (a) Conception and Design

148 Author name (s) Ella Fitzgerald, Simon L. Priestnall, Christopher R. Lamb

149 (b) Acquisition of Data

150 Author name (s) Ella Fitzgerald, Simon L. Priestnall, Christopher R. Lamb

151 (c) Analysis and Interpretation of Data

152 Author name (s) Ella Fitzgerald, Simon L. Priestnall, Christopher R. Lamb

153

154 Category 2

155 (a) Drafting the Article

156 Author name (s) Ella Fitzgerald, Simon L. Priestnall, Christopher R. Lamb

157 (b) Revising Article for Intellectual Content

158 Author name (s) Ella Fitzgerald, Simon L. Priestnall, Christopher R. Lamb

159

160 Category 3

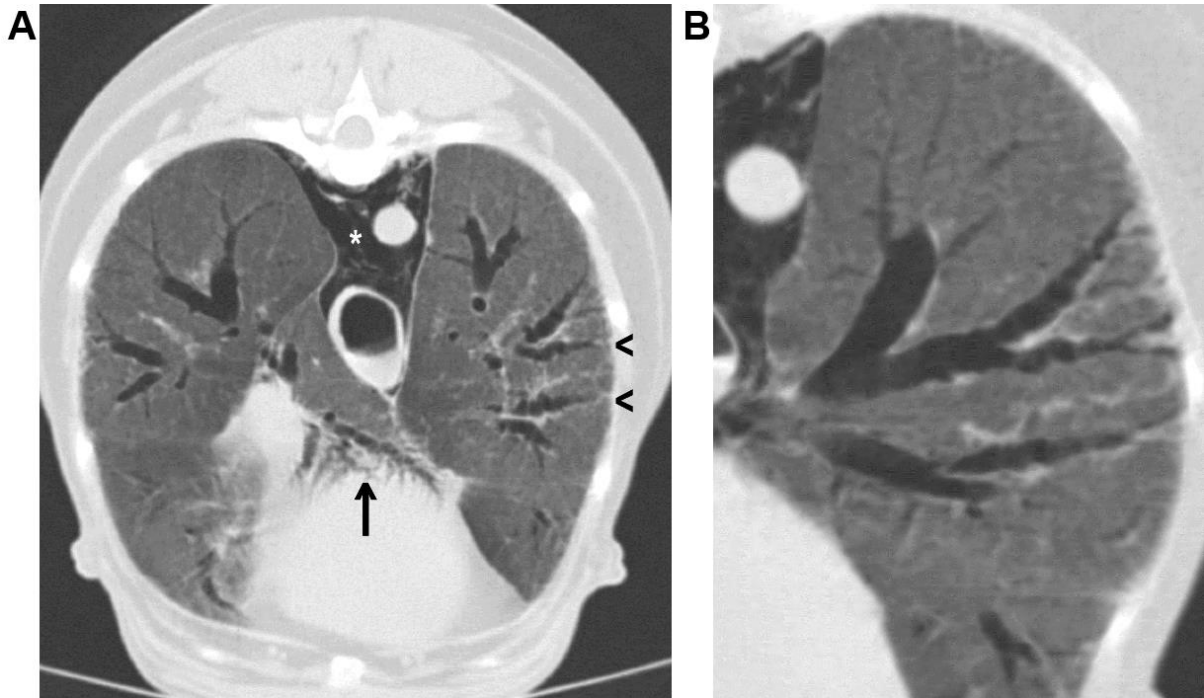
161 (a) Final Approval of the Completed Article

162 Author name(s) Ella Fitzgerald, Simon L. Priestnall, Christopher R. Lamb

163

164 **Legends**

165 Figure 1. Transverse (A) and oblique (B) CT images of the thorax showing
166 pneumomediastinum (*), diffuse ground glass pulmonary opacity, and uneven
167 dilation of the peripheral bronchi in left caudal lobe (arrowheads) and accessory lobe
168 (arrow) compatible with bronchiectasis.



169

170

171 Figure 2. Hematoxylin and eosin-stained histologic sections of lung (A, x20
172 magnification) and (B, x20 magnification) showing a dilated bronchioles (B). The
173 visceral pleural surface of the lung (arrowheads) appears normal, but there is
174 marked fibrosis of the subpleural parenchyma (F). There is a lack of abnormalities
175 affecting the respiratory epithelium of the small bronchiole (arrow). Bar = 1.5 mm

