

Sudden Vision Loss in a Young Patient with Pulmonary Hypertension, A Rare and Unusual Finding

Saba Alkhairy¹ and Saad Aslam*¹

¹Department of Ophthalmology, Dow International Medical College, DUHS, Karachi, Pakistan

ABSTRACT

Loss of vision associated with pulmonary hypertension in the pediatric age group has been rarely reported in the literature and often goes unnoticed for a long period. Pulmonary hypertension may manifest as shortness of breath limiting the activity of the individual, palpitation, headaches, easy fatigability, dizziness been the most common symptoms encountered. However, primary pulmonary hypertension would not present itself instead secondary to other diseases like congenital heart disease, lung disease, connective tissue disorders or genetic diseases. Our case demonstrated a 17-year old individual with a primary complaint of progressive loss of vision in the left eye leading to complete vision loss. The patient experienced dyspnea two years back which exacerbated affecting his normal routine activity. His Echocardiography revealed severe pulmonary hypertension and was started on appropriate medications. His vision worsened and slit-lamp examination revealed multiple hemorrhages. Further investigations with FFA and OCT revealed significant hypoperfusion and significant elevation of the retina of the left eye. Anti-VEGF injections were given in an attempt to restore vision, but it resulted in no further improvement. Our case emphasizes the importance of prompt ophthalmologic examination in Pulmonary Hypertension.

Keywords: *Familial pulmonary hypertension, macular edema, central retinal vein occlusion.*

INTRODUCTION

Pulmonary Hypertension is defined as increased pulmonary arterial pressure which in childhood presents even at rest [1]. Pulmonary Hypertension is a rare and life-threatening disease of both pediatric and adult age groups. The etiology of PH has been classified by the World Health Organization based on the mechanism of an underlying disease. However, the most common cause of Pulmonary Hypertension is Left Heart Failure. Untreated Pulmonary Hypertension leads ultimately to death [2]. Increased venous back pressures dilate the ocular veins, increasing the IOP increasing the risk of ciliary detachment, venous occlusions and several other Ocular complications [2, 3]. Treatment of PAH is usually done systemically aimed to reduce Pulmonary Hypertension thereby reducing the risk of complications leading to organ damage. Ocular manifestations due to Pulmonary Hypertension has not been published extensively. We present the case of a patient who presented with loss of vision due to Central Retinal Vein Occlusion secondary to Pulmonary Hypertension.

CASE PRESENTATION

We are presenting the case of a 17-year old male patient who presented in the Ophthalmology Out-Patient department 4 weeks back with the complaint of a sudden loss of vision in the left eye. The patient

experienced blurring of vision in the left eye more compared to the right eye which gradually increased leading to complete loss of vision. It remained unnoticed until the patient developed difficulty reading at school. On further questioning, it was revealed that the patient had developed dyspnea two years back. The patient never developed any symptoms at all before this event. The patient experienced a significant increase in dyspnea making him short of breath with little exertion. Family history revealed that a paternal female first cousin also has pulmonary hypertension which was detected a few years back.

On visual assessment, his best-corrected vision was 6/12 OD and 1/60 OS without any further improvement on Snellen's Chart. Slit Lamp examination showed a normal anterior segment with a clear cornea, without any flares or cells, the pupil was round and regular with a normal lens as well as no cells in vitreous were visualized. The right eye fundus was normal with a normal optic disk and a healthy macula with the vasculature. Whereas the left eye had a normal anterior segment with a clear cornea however the fundus exam revealed pre-retinal and intraretinal hemorrhages, dilated and tortuous veins and macular edema (Fig. 1A). Goldmann Applanation Tonometry was performed on a slit lamp and intra-ocular pressures were found out to be within normal limits in both eyes. To further investigate, a Fundus Fluorescein Angiography with an SD-OCT was performed which showed normal right eye with normal retinal thickness and a normal FFA clear of hemorrhages, or hypoperfusion (Fig. 1B). However, the left eye Fundus Fluorescein Angiography images revealed areas of hypoperfusion in all four quadrants

*Corresponding Author: Saad Aslam, Department of Ophthalmology, Dow International Medical College, DUHS, Karachi, Pakistan;

Email: saad.aslam1@hotmail.com

Received: April 07, 2020; Revised: December 07, 2020; Accepted: December 09, 2020

DOI: <https://doi.org/10.37184/lnjpc.2707-3521.2.11>

(Fig. 1C). SD-OCT of the left eye showed an abnormally thick retina with significant elevation of the

macula and with hemorrhages as well as areas of hypoperfusion were identified (Fig. 1D).

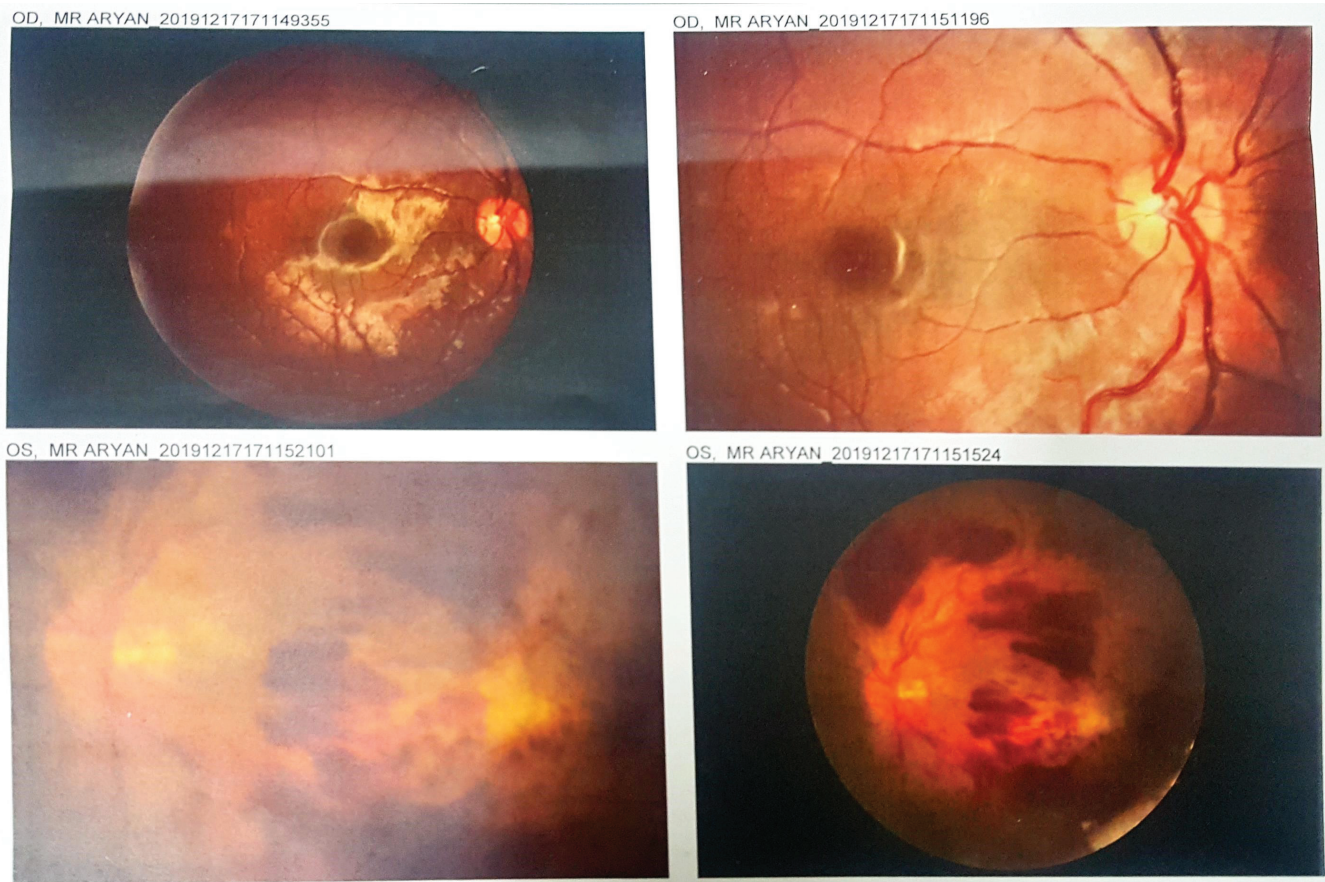


Fig. (1A): Fundus images showing a normal pattern in Right eye (OD). Fundus of Left eye (OS) depicting widespread Intra- Retinal and Pre-Retinal Hemorrhages. OS= Left Eye, OD= Right Eye. Patient reviewed at Department of Ophthalmology, Dow University of Health Sciences, Ojha Campus, Karachi, Pakistan.

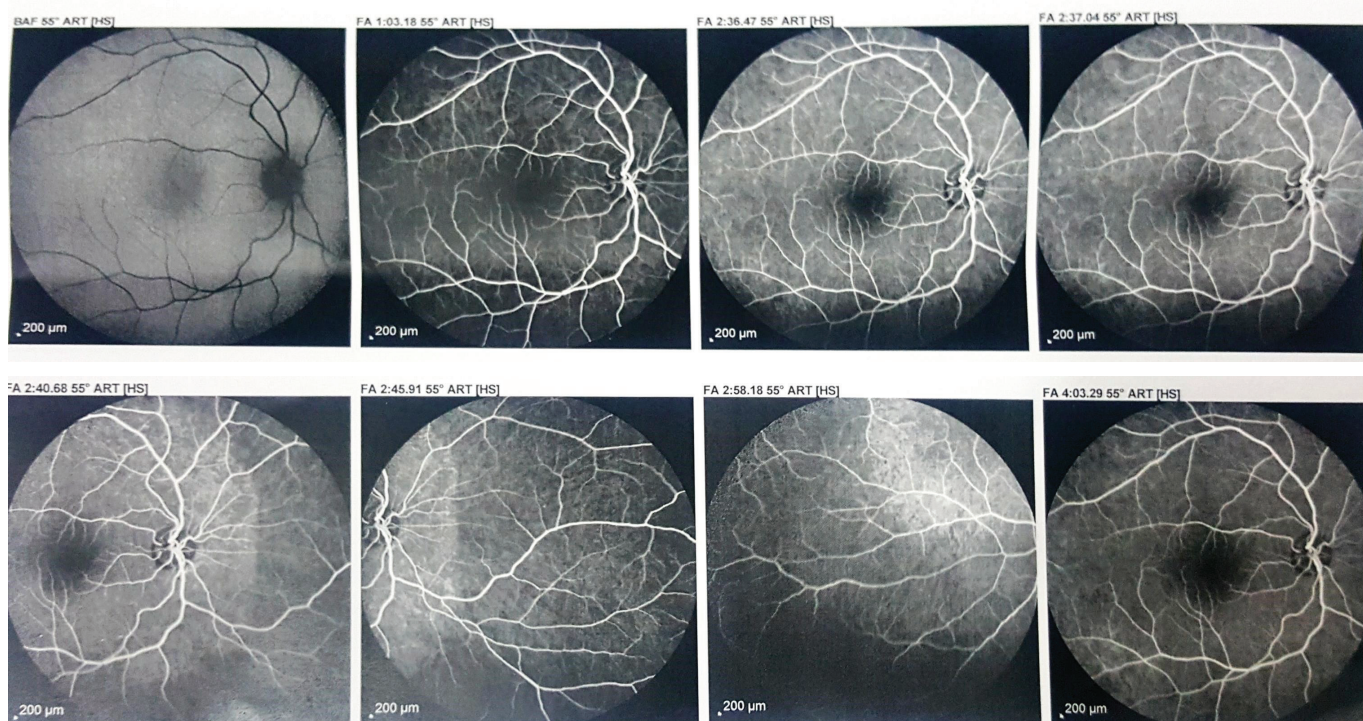


Fig. (1B): FFA images of the Right Eye.

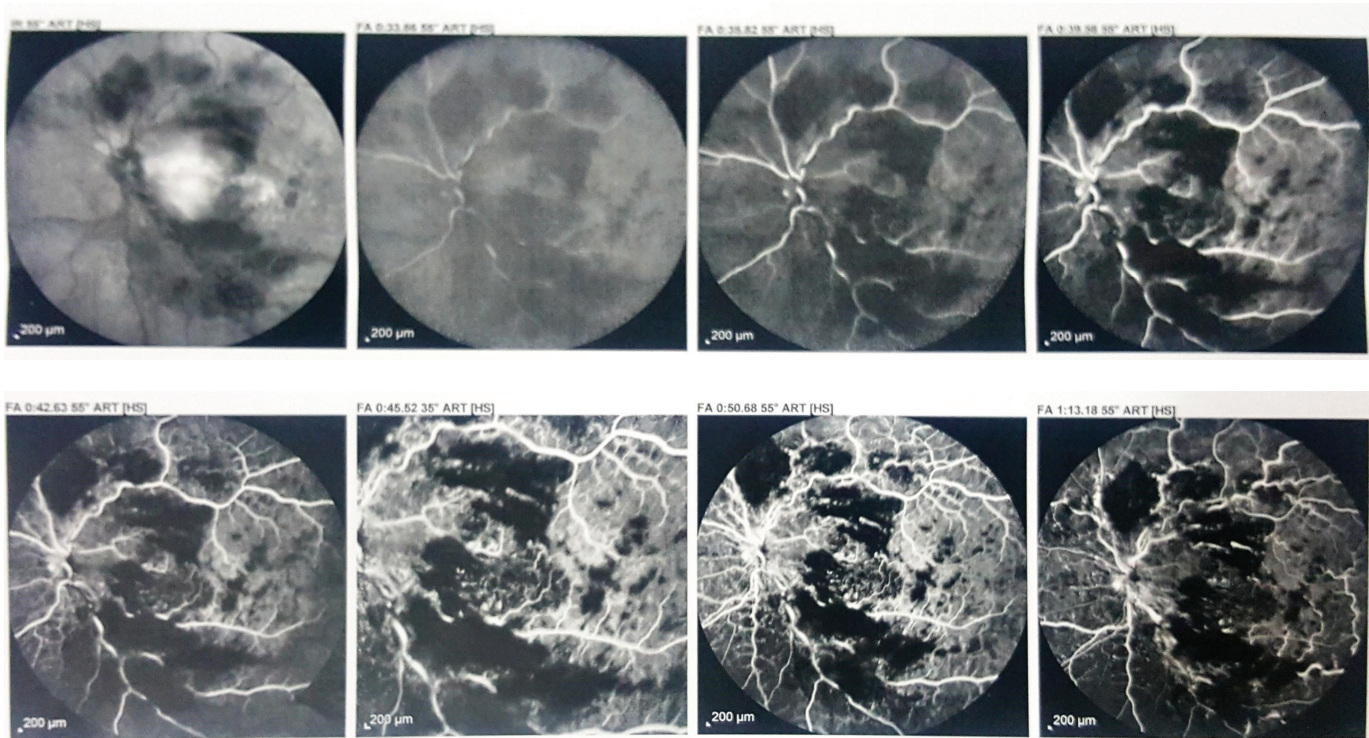


Fig. (1C): FFA images of the Left Eye depicting Intra and Pre- Retinal Hemorrhages and areas of hypoperfusion in all quadrants.

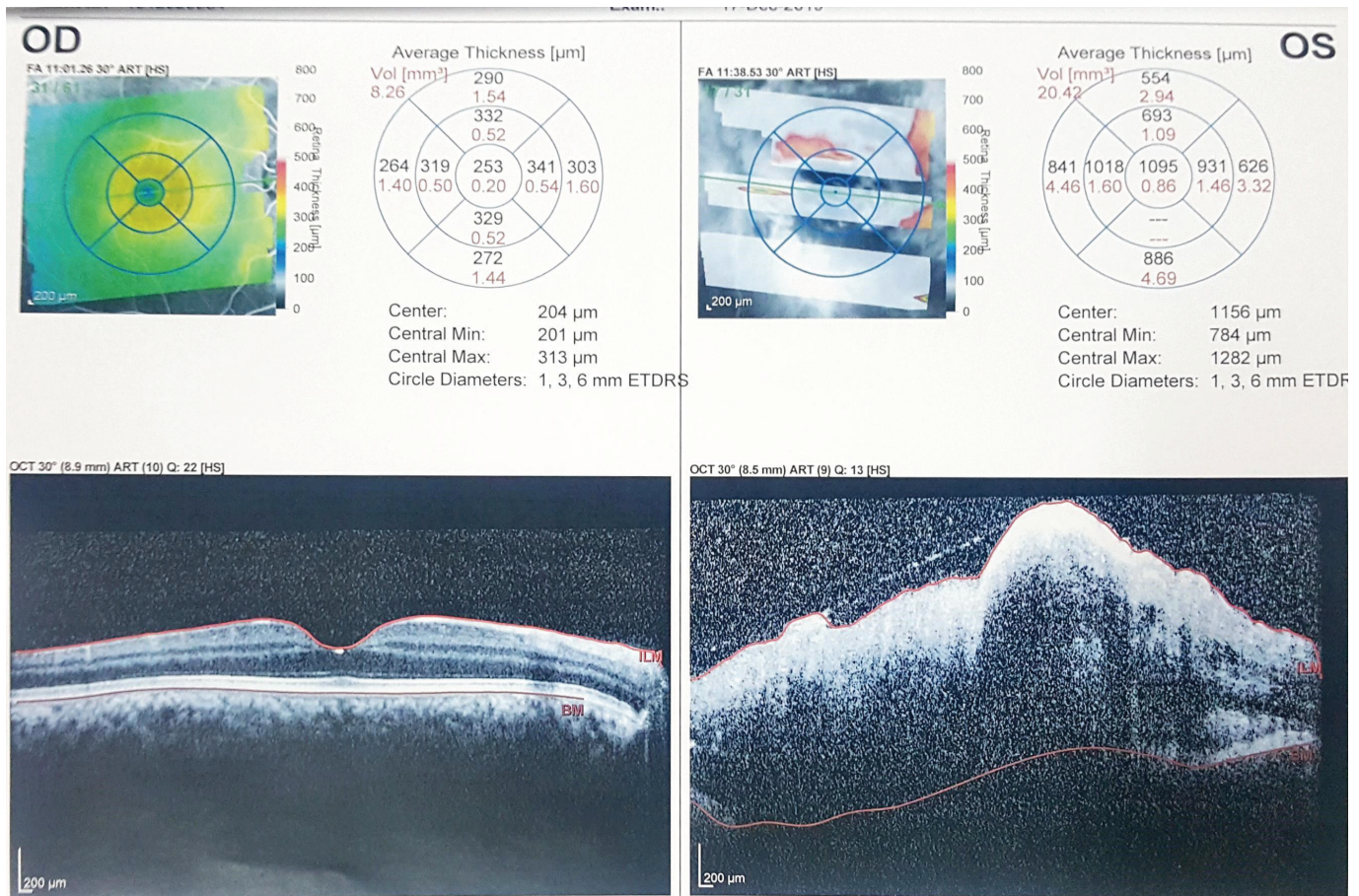


Fig. (1D): Spectral Domain- OCT; Right Eye (OD): Normal thickness Macula with intact Retina. Left Eye (OS): Increased thickness of retina with significant elevation of at the Macula.

Laboratory investigations revealed normal routine lab results with a Hemoglobin level of 14.3g/dl and hematocrit of 44%. Pediatric Transthoracic Echocardiography (Fig. 2) showed severe Pulmonary Hypertension, Dilated IVC, Tricuspid Regurgitation, Right Ventricular Dilatation, and Enlarged Right Atrium, Moderate Pulmonary Regurgitation.

Given the presence of hemorrhages and areas of hypoperfusion in the left eye confirmed on Fundus Fluorescein Angiography and SD-OCT (Fig. 1A-1D), a diagnosis of Central Retinal Vein Occlusion was made, and subsequent treatment was planned.

The patient is currently taking Sildenafil (PDE5 inhibitor), Bosentan (ET-1 Antagonist) and Spironolactone (Potassium-sparing diuretic). After the induction of medications, his episodes of dyspnea improved significantly. Treatment for the left eye was begun with Intra-Vitreous Avastin Injections. Three Intra-Vitreous Avastin Injections were given at regular intervals of one week apart. The patient was again examined after giving Intra-Vitreous Injections, but it did not improve the overall visual acuity as well as the hemorrhages. Treatment with Acetazolamide 250mg BD was begun but it did not resolve his ocular symptoms either.

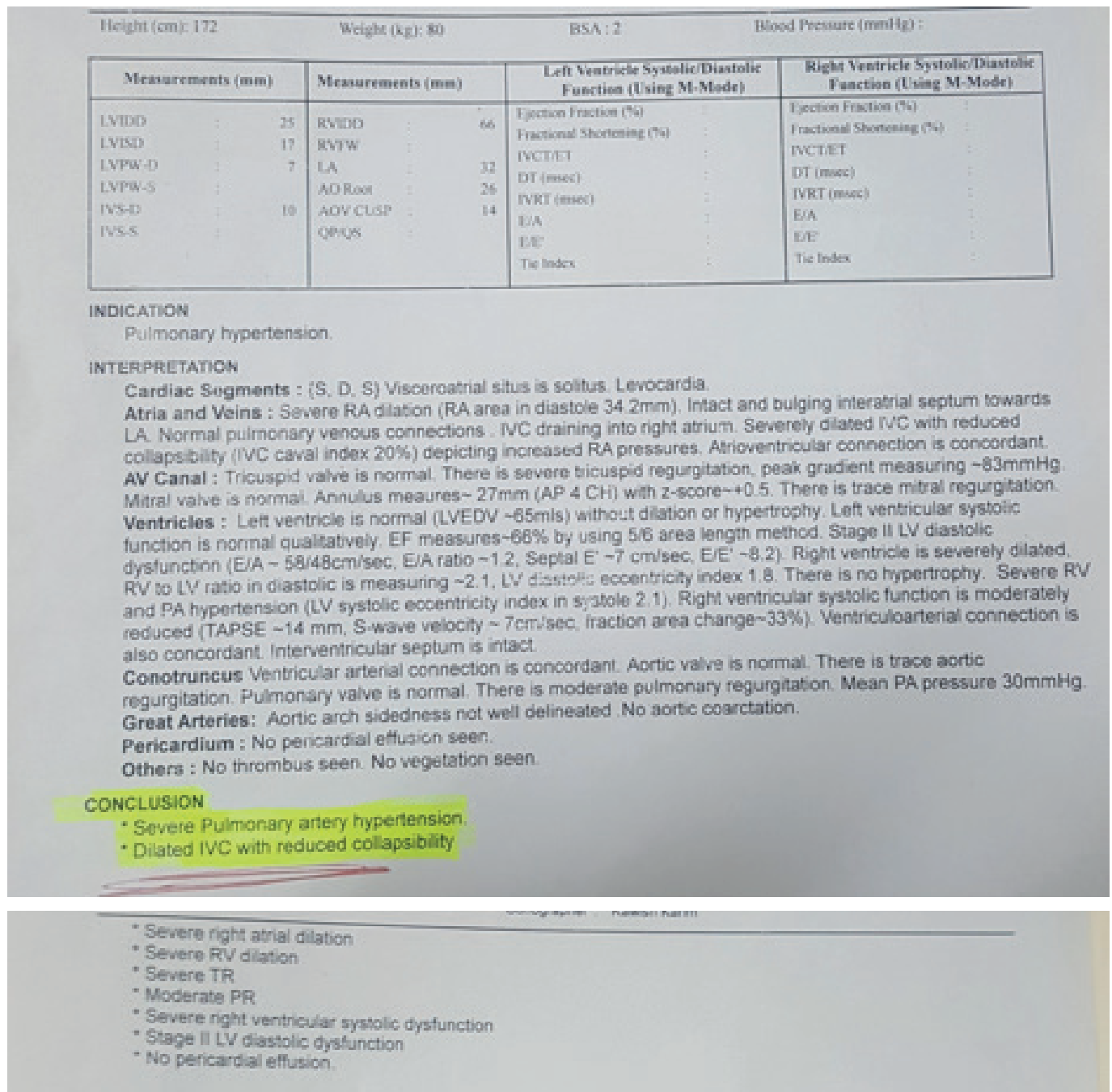


Fig. (2): Pediatric Transthoracic Echocardiography.

DISCUSSION

Pulmonary Arterial Hypertension is a rare disease in infants and children with significant morbidity and mortality. In our case report, we have presented ocular findings that were found in a very young patient, affecting his left eye that significantly deteriorated his visual acuity and is now limited to the only perception of light. The symptoms experienced by patients are non-specific including decreased vision, metamorphopsia, and pain due to increased IOP as reported [2]. Causes of Pulmonary Hypertension include both familial as well as idiopathic type. Primary pulmonary hypertension accounts for about 6% of all cases of pulmonary hypertension, and most of the reported ocular findings are associated with this subtype [2]. Austin et al. described the role of a genetic mutation that occurs in BMPR2 gene [4]. The pathophysiology of the disease reported has been vascular remodeling, lack of endothelin further exacerbated with underlying congenital heart disease. The significance of considering a familial cause of it; is the presentation at a younger age with gene anticipation observed in successive generations [1, 4].

Central Retinal Vein Occlusion, one of the feared complications of Pulmonary Hypertension occurred unilaterally in our patient, a similar article highlighted the importance of managing it earlier on as it increased the chance of involving the fellow eye. Increased IOP results in compressing the central retinal vein significantly [5]. Apart from CRVO our patient's OCT exhibited unusual Macular elevation deteriorating its normal architecture.

As Hammond et al. reported using acetazolamide which subsided macular edema and improved vision [6]. Given the unique nature of the ocular finding in our patient, we did use acetazolamide but to no resolve.

Most certainly it can be concluded that earlier diagnosis and systemic treatment in such a patient with pulmonary hypertension could avoid drastic complications.

CONCLUSION

Given the published evidence and thorough experiences of different ophthalmologists around the world it is pertinent to say that such patients with pulmonary hypertension be referred to ophthalmologists early on to prevent loss of vision associated with it especially patients of pediatric age group, **as our patient developed CRVO secondary to pulmonary hypertension.**

CONFLICT OF INTEREST

The authors declare no conflict of interest.

ACKNOWLEDGEMENTS

Declared none.

REFERENCES

1. Haworth SG. Pulmonary Hypertension in the young. *Heart* 2002; 88(6): 658-64.
2. Lewczuk N, Zdebik A, Bogusławska J, Turno-Kre A, Misiuk-Hojło M. Ocular manifestations of pulmonary hypertension. *Surv Ophthalmol* 2019; 64: 694-9.
3. Feng Z, Dong L, Cao J, Bai J, Yang M, Zheng Y, et al. A case study of ciliary detachment with primary pulmonary hypertension. *Int Ophthalmol* 2018; 38: 375-9.
4. Austin ED, Loyd JE. Genetics and mediators in pulmonary arterial hypertension. *Clin Chest Med* 2007; 28: 43-57.
5. Pham H, Akduman L, Kavali S. Bilateral central retinal vein occlusion in idiopathic pulmonary arterial hypertension. *J Vitreoretin Dis* 2018; 2: 183-7.
6. Hammond CJ, Chauhan DS, Stanford MS. Pulmonary hypertension and diffuse macular edema responsive to acetazolamide. *Arch Ophthalmol* 1998; 116: 1535-6.