

REVIEW ARTICLE

The use of non-surgical interventions in patients with peri-implantitis; a systematic review and meta-analysis

Nizar Almershed, Robert Adams , Joelle Mort , Damian Farnell, David W Thomas & Nicholas Claydon

Cardiff University, University Dental Hospital, Cardiff, UK

Key words:

dental implants, non-surgical, treatment, peri-implantitis

Correspondence to:

Joelle Mort
Oral Surgery StR, University Dental Hospital
Cardiff CF14 4XY
UK
Tel.: 0292 074 2443
email: mortj1@cardiff.ac.uk

Accepted: 21 June 2020

doi:10.1111/ors.12548

Abstract

Objectives: To systematically assess the efficacy of different non-surgical treatment methods to manage peri-implantitis reported to date in the literature, together with its correlation with time following therapy.

Materials and Methods: A systematic literature review was undertaken to identify randomised control trials of the non-surgical management of peri-implantitis published up to November 2019. The search was limited to English language human studies containing follow-up periods of ≥ 3 months and for sample size of 10 or more patients. A meta-analysis was implemented for the following clinical parameters: Peri-implant pocket depth (PPD), bleeding on probing (BOP), clinical attachment level (CAL), radiographic bone loss (RBL) and mucosal recession (MR).

Results: Twelve articles met the inclusion criteria. Two principal treatment modalities were identified; mechanical debridement and laser therapy, with two adjunctive therapies antimicrobial and antiseptic agents. Non-surgical interventions (ultrasonic scalers, Er:YAG laser and powdered air-abrasive devices) showed significant clinical improvement in the short term (<3 months). Clinical benefit was demonstrated with the adjunctive use of antimicrobial agents in the short term but diminished with time. Antiseptic agents alone have no significant effect. Non-surgical therapies applied in these studies failed to arrest mucosal recession, peri-implant bone loss or reduce the counts of viable pathogens in the long term.

Conclusion: The evidence demonstrate that the clinical parameters of peri-implantitis, i.e. BOP, PPD and CAL may all be improved by simple mechanical debridement, using either ultrasonic instrumentation or Er:YAG laser therapy; adjunctive antimicrobial and antiseptic therapy. Further randomised control trials in this area are, however, required.

Introduction

The placement of dental implants has become a popular treatment option, in the replacement of missing teeth, as they can provide a predictable long-term solution with high levels of reported success¹. Following placement, ongoing maintenance of these osseointegrated oral implants is imperative to their success. The most common biological reason for 5-year implant failure is peri-implantitis², which describes the loss of crestal bone surrounding an

implant in conjunction with bleeding on probing +/- peri-implant pocketing. It is assumed this is due to increased bacterial load. However, iatrogenic factors (e.g. excess cement, poorly seated restorations, traumatised bone during implant placement and failed/failing guided bone regeneration) may also contribute to peri-implantitis and its progression³.

The term peri-implantitis was first introduced by Mombelli *et al.*⁴ to describe the inflammation that occurs around a functional and osseointegrated implant that causes osseous destruction. This feature

distinguishes it from other inflammatory processes that can also lead to implant failure, particularly those associated with the initial stages of inflammation and repair which characterise successful osseointegration⁵.

The fundamental principles of the management of peri-implantitis are the reduction in bacterial counts below the threshold borderline for initiating disease, that is, controlling infection in the peri-implant tissues and on the implant surface, reducing protease-mediated responses and suppressing bacterial actions⁶. In clinical practice, peri-implantitis can be managed surgically, non-surgically or via a combination of both approaches.

“Surgical techniques” include: surgical access to allow instrumentation and decontamination of the implant surface, apically repositioned flaps (ARF), implantoplasty and attempted re-osseointegration using bone augmentation techniques⁷. Non-surgical management (NSM) employs a variety of mechanical/physical modalities without surgical access (e.g. curettes, ultrasonic scalers, air-abrasive devices and lasers). These aim to induce physical disruption and removal of the supra and sub-gingival biofilm together with gross debris such as calculus from the implant abutment, neck and fixture surface⁸; representing “closed debridement” of the biofilm on the implant surface⁶.

A number of authors have proposed the NSM of peri-implantitis with lasers as they have physical/ablative properties. Figueroa *et al.*⁹ reports that the outcome for the treatment of peri-implantitis with lasers is dependent on the type of laser employed. The erbium-doped yttrium aluminium garnet laser (Er:YAG) is reported to exhibit increased efficiency in removing sub-gingival plaque and calculus without damage to the implant surface, in contrast to CO₂ lasers¹⁰.

Adjunctive therapies, such as antibiotics and antiseptics (chlorhexidine, hydrogen peroxide and saline), have been utilised in an attempt to improve the outcome of NSM by modifying the local bacterial microflora. While topical antimicrobial agents may modify bacterial adhesion and growth *in vitro* and *ex vivo*, their significance as adjunctive therapies remains unproven⁸. Locally delivered antibiotics (e.g. slow release formulations) have been utilised in combination with NSM in patients with “moderate/deep” peri-implant disease defined as >5 mm bone loss or >50% of the implant length^{11,12}. However, the evidence for this currently appears inconclusive and there is no evidence to support systemic antibiotics in the treatment of peri-implantitis¹³.

The aim of this study was to systematically review the published evidence on the efficiency of different non-surgical treatments to manage implants (and patients) affected by peri-implantitis, to inform their evidence-based treatment.

Material and methods

An electronic and manual search was conducted to identify randomised control trials published in the English Language restricted to human studies. Six databases engines were screened using a combination of Full-text terms and Medical Subject Heading (MeSH) to identify the pertinent articles. These databases were as follows: Cardiff University and NHS Wales Libraries, Cochrane Library – Search Trials (CENTRAL), PubMed, Ovid MEDLINE (R), EMBASE, Web of Science.

Inclusion and exclusion criteria

Clinical studies included in this systematic review met the following criteria: human clinical studies published in the English language, randomised control trials (RCT), patients with peri-implantitis lesions, studies with sample sizes of ≥ 10 patients; studies with a minimum follow-up period of ≥ 3 months.

Studies including surgical management of peri-implantitis were excluded, as were *in vitro* and animal studies, human studies with unclear or missing data, reviews and cohort studies. Cross-sectional and case studies were similarly excluded.

Primary and secondary outcome measures

Primary outcomes were considered to be reductions in bleeding on probing (BOP) and periodontal pocket depth (PPD) and/or gains in clinical attachment level (CAL) following NSM. Secondary outcomes were considered to be assessment of mucosal recession (MR) and radiographic marginal bone levels (RBL).

Qualitative assessment methods (risk of bias)

The Critical Appraisal Skills Program 2017 (CASP 2017) was employed in this systematic review to evaluate the quality of the studies to be included. The risks of bias were categorised as:

1. Low risk: all criteria met
2. Moderate risk: one or two criteria missing
3. High risk: more than two criteria missing

Quantitative assessment (meta-analysis)

Meta-analyses were conducted separately for each of the clinical parameters (PPD, BOP, CAL, RBL and MR). Ten RCTs^{11,14–22} were included in the meta-analyses as they reported mean reductions with standard deviation values in the defined clinical parameters. Two studies were excluded as they neither included data for medians nor standard deviations or they presented incomplete results^{23,24}. In the selected studies, Standardised Mean Difference (SMD) and Weighted Mean Difference (WMD) between control and test groups in association with a 95% confidence interval (CI) were displayed in Forest Plots. Funnel plots, Egger's test and Begg's test were used to indicate possible bias.

Results

Searching process of databases and data extraction

The primary database search revealed 3819 articles on the non-surgical treatment of peri-implantitis, 3070 articles from Cardiff University and NHS Libraries, 134 articles from the Cochrane Library, 81 articles from PubMed, Ovid MEDLINE (R) revealed 50 articles, Embase 52 articles, Web of Science 426 articles and manual search 6 further articles (Figure 1). After removing duplicate studies, 30 articles were identified for further analysis. After thorough review of the full-texts articles, 12 RCTs were selected for inclusion in this study (Table 1). Reasons for exclusion are identified in Table 2^{12,25–40}.

Qualitative assessment of the included studies

The majority of the studies included were at high risk of bias using the CASP 2017 (Table 3) with no studies being low risk of bias.

Quantitative assessment of the included studies

Study criteria are summarised in Table 4a, which include patient profiles and the applied non-surgical interventions. Table 4b summarises the parameters used to assess the efficacy of the applied interventions and the final conclusions of each treatment method.

Non-surgical interventions

The non-surgical interventions in the included studies were categorised into four approaches:

mechanical debridement, laser, antimicrobial agents and antiseptic agents (Table 5).

Meta-analysis results

Generally, the results favour the interventions (with some significant results) for all outcomes except MR and RBL. Sensitivity analysis for the standardised mean difference (SMD) PPD revealed that after removing possible outliers^{11,14} for the standardised mean difference, the overall point estimate is 0.27 which favours the intervention. This result is not significant as the 95% confidence interval (CI) covers the critical line of 0 (Figure 2).

Primary outcomes

Probing pocket depths (PPD)

Sensitivity analysis for the weighted mean difference (WMD) of PPD revealed that following removal of the clear outlier for the standardised mean difference¹⁴, the overall point estimate is 0.77. This indicates that the intervention is favoured. This result is considered significant as the 95% CI does not touch the critical line of 0 (Figure 3).

Bleeding on probing (BOP)

There is some evidence of an outlier for the standardised mean difference for BOP¹¹; funnel plots and Egger's test and Begg's test indicate possible bias. The intervention is favoured as the pooled estimate for the SMD = 0.76. This result is significant because the 95% CI does not cover the critical line of 0 (Figure 4). There was no evidence of an outlier for the weighted mean difference for BOP¹¹; funnel plots and Egger's test and Begg's test indicate little or no bias/outliers. There is some evidence of heterogeneity, though this may reflect the random effects of the meta-analysis. The intervention is favoured as the pooled estimate for the WMD = 15.8. This result is significant because the 95% CI does not cover the critical line of 0 (Figure 5).

Bleeding Sensitivity analysis for the SMD of BOP was performed after removing the clear outlier¹¹. Estimates for SMD were calculated along with funnel plots showing a reduction in the overall point estimate to 0.45 favouring the intervention. This result is not significant though, as the 95% CI touch the critical line of 0 (Figure 6). Egger's and Begg's test indicate possible bias.

Clinical attachment loss (CAL)

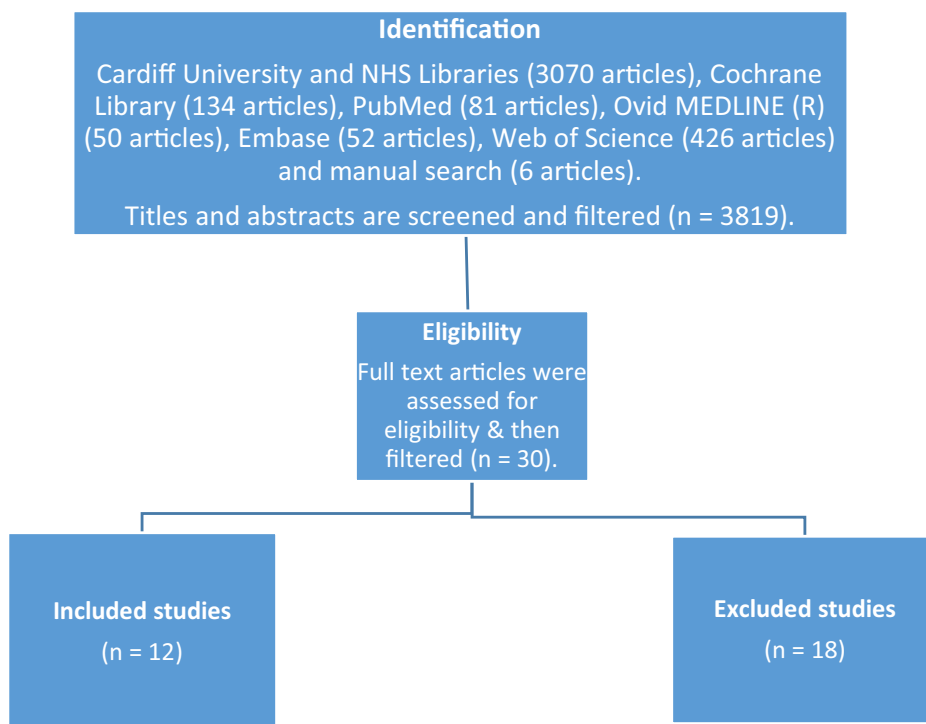


Figure 1 Searching process of the different databases for the non-surgical treatment of peri-implantitis [Colour figure can be viewed at wileyonlinelibrary.com]

Table 1 Included articles in this systematic review

Included articles	
Roos-Jansaker <i>et al.</i> 2017	Renvert <i>et al.</i> 2011
Romeo <i>et al.</i> 2016	Sahm <i>et al.</i> 2011
Arisan <i>et al.</i> 2015	Schwarz <i>et al.</i> 2006
John <i>et al.</i> 2015	Schwarz <i>et al.</i> 2005
Machtei <i>et al.</i> 2012	Karring <i>et al.</i> 2005
Persson <i>et al.</i> 2011	Buchter <i>et al.</i> 2004

There were no outliers for WMD of CAL. The intervention is favoured as the pooled estimate for the WMD = 0.41, although this result is not significant as the 95% CI covers the critical line of 0 (Figure 7). Sensitivity analysis for the SMD CAL: After removing the clear outlier for the standardised mean difference¹¹ and recalculate estimates, the point estimate is 0.09 indicating that the intervention is favoured. This result is not significant though as the 95% CI covers the critical line of 0 (Figure 8).

Secondary outcomes

Radiographic bone levels (RBL)

Table 2 Excluded articles and the reasons of exclusion

Abduljabbar <i>et al.</i> 2017	Peri-implant mucositis and peri-implantitis were not distinguished (mixed cases of both conditions)
Renvert <i>et al.</i> 2006	In-vitro study
Tang <i>et al.</i> 2017	Peri-implant mucositis and peri-implantitis were not distinguished (cases of both conditions were mixed together)
Abduljabbar T 2017, Al Amri <i>et al.</i> 2016, Javed <i>et al.</i> 2016, Karimi <i>et al.</i> 2016	Cohort studies.
Lerario <i>et al.</i> 2016, Mettraux <i>et al.</i> 2016, Salvi <i>et al.</i> 2007	Includes surgical intervention.
Rakasevic <i>et al.</i> 2016	MBL within the normal bone remodelling rate.
Bassetti <i>et al.</i> 2014, Schar <i>et al.</i> 2013	Cases included were peri-implant mucositis
Deppe <i>et al.</i> 2013	Observational study
Renvert <i>et al.</i> 2009, Renvert <i>et al.</i> 2008	Unknown number of patients were affected by peri-implant mucositis and not peri-implantitis
De Araújo Nobre <i>et al.</i> 2006	Prospective clinical trial (No randomisation) Sample size < 10 patients.
Schwarz <i>et al.</i> 2006	The study design does not compare between different treatment approaches.

The result for RBL favours the control as the pooled estimate for WMD = -0.18 and SMD = -0.26. This result is not significant as the 95% CI covers the critical line of 0 in both cases (Figure 9).

Table 3 Risk of bias (CASP 2017)

Risk of bias	Included studies
Low risk	None
Moderate risk	Arisan <i>et al.</i> 2015 Machtei <i>et al.</i> 2012 Renvert <i>et al.</i> 2011 Buchter <i>et al.</i> 2004
High risk	Roos-Jansaker <i>et al.</i> 2017 Romeo <i>et al.</i> 2016 John <i>et al.</i> 2015 Persson <i>et al.</i> 2011 Sahm <i>et al.</i> 2011 Schwarz <i>et al.</i> 2006 Karring <i>et al.</i> 2005 Schwarz <i>et al.</i> 2005

Mucosal recession (MR)

The result of MR favours the control as the pooled estimate for the WMD = -0.09 and SMD = -0.04 . This result is not significant though as the 95% CI covers the critical line of 0 in both cases (Figure 10).

Discussion

One of the aims of management of peri-implantitis is to reduce the bacterial count within the peri-implant tissues, to below the threshold of disease formation, as the relationship between increased bacterial load (poor plaque control) and the formation of peri-implantitis is well established⁴¹. While NSM of peri-implantitis may improve clinical parameters, as described by Persson²⁴ and Mahato⁶, it fails to reduce bacterial counts within the peri-implant tissues. The bacterial biofilm will result in re-colonisation of the implant surface. In practice, effective professional and personal oral hygiene may be hampered by the surface or design of the prosthesis. The findings here suggest that NSM when utilised offers limited clinical improvement after a 6-month observation period post-treatment.

Measures of biofilm removal

Twelve studies included methods of non-surgical mechanical debridement using curettes, air-abrasive devices and ultrasonic devices to disrupt the deposited biofilms on the implant surface. Generally, clinical improvement (PPD, BOP and CAL values) after NSM is evident in the initial 6 months but this then regresses. This is presumably as a result of re-colonisation of the implant surface. The results of the studies were contradictory; Karring¹⁶ showed that

mechanical debridement with curettes was ineffective at reducing PPD and BOP, whereas the use of an ultrasonic scaler showed improvement in BOP. In contrast, Romeo¹⁹ showed a significant reduction in PPD and BOP when using photodynamic therapy (low-power diode laser in conjunction with photosensitising compounds). This may, in part, be explained by the preparatory treatment for the whole oral cavity (with mechanical and manual decontamination procedures) prior to the commencement of the clinical study, and highlights the importance of compliance with oral hygiene regimens following treatment, which is evident in the non-surgical (and surgical) treatment of periodontal disease³.

The use of ultrasonic scalers and abrasive air device (AAD) initially showed improved results, in initial BOP, when compared to curettes. Ultrasonic scalers also showed better results in improving the CAL when compared to both curettes and AAD; Machtei¹⁷ and Roos-Jansaker²⁰ showed clinical improvement in PPD (values > 1 mm) with ultrasonic scalers. Only Romeo¹⁹ was able to demonstrate improvement of PPD values by using curettes alone.

Studies assessed the efficacy of lasers as a debridement method or as adjunctive therapy to disrupt the bacterial biofilm from the implant surface. The data demonstrated that adjunctive use of diode laser do not provide any additional improvement in clinical outcome compared to mechanical debridement alone and cannot be recommended for NSM of peri-implantitis. While Schwarz²² demonstrated the ability of Er:YAG lasers to effectively debride the bacterial biofilm (and they hypothesised reduce the inflammatory process locally), the clinical improvement observed in BOP and PPD using Er:YAG alone is less than that observed with mechanical debridement. Indeed, Roos-Jansaker²⁰ demonstrated ultrasonic scalers induced greater improvement in CAL than Er:YAG laser devices.

Adjunctive antimicrobial therapy

Two studies discussed the effectiveness of adding locally delivered antibacterial agent (adjunctive therapy) to the conventional approach (mechanical debridement by using curettes) in the NSM of peri-implantitis lesions. Combining antimicrobial agents with mechanical debridement using curettes (found to be the least effective debridement method) when compared with AAD and ultrasonic scalers, helped to achieve significant clinical benefit, showing PPD improvement of more than 1 mm and BOP

Table 4a Characteristics of the included studies

Study	Groups	Number of patients	Number of implants	Mean Age (years)	Follow-up Period	Treatment applied	
						Self-performed	Professionally delivered
Arisan et al. 2015	Control	10 patients	24	55.1	6 months	OHI	MD (plastic curette).
	Test	(split mouth design)	24	Range (43–76)			MD (plastic curette) + diode laser 810 nm (energy density: 3 J/cm ² ; power density: 400 mW/cm ² ; energy: 1.5 J; spot diameter: 1 mm; time: 1 min).
Buchter et al. 2004	Control	14	48	55	18 weeks	OHI	MD (hand plastic instrument) + peri-implant defects were repeatedly irrigated with 0.2% CHX.
	Test	14		Range (25–78)			MD (hand plastic instrument) + 8.5% doxycycline hyclate (Atridox™) + peri-implant defects were repeatedly irrigated with 0.2% CHX.
John et al. 2015	Control	13	18	62 ± 13.2	12 months	OHI	MD (carbon curettes) followed by pocket irrigation with 0.1% CHX solution and sub-mucosal application of 1% CHX gel.
	Test	12	18	Range	6 months	OHI	Sub-mucosal AAD used in combination with amino acid glycine powder.
Karring et al. 2005	Control	11 patients (split mouth design)	11	50–78	6 months	OHI	MD (carbon fibre curettes).
	Test	30	37	59.18 ± 9.2	6 months	OHI sodium fluoride toothpaste prescribed	Vector ® (ultrasonic device with hydroxyapatite fluid polish).
Machtei et al. 2012	Control	30	40	27–77	6 months	OHI oscillating-rotating electric toothbrush used	MD (ultrasonic instruments - Electeo Medical System) + biodegradable cross-linked gelatin matrix chip (placebo).
	Test	21	45	68.9 ± 12.5	6 months	OHI	MD (ultrasonic instruments - Electeo Medical System) + matrix containing 2.5 mg CHX chips.
Persson et al. 2011	Control	21	45	68.5 ± 6.4	6 months	OHI	AAD sub-gingival polishing for 15 seconds in each position.
	Test	21	55	68.5 ± 6.4	6 months	Sonic toothbrush used	Er:YAG laser (100 mJ/pulse) and 10 Hz (12.7 J/cm ²).
Renvert et al. 2011	Control	21	45	68.9 ± 12.5	6 months	OHI sonic toothbrush used	AAD using glycine powder.
	Test	21	55	68.5 ± 6.4	24 weeks	OHI oscillating-rotating electric toothbrush used	Er:YAG laser device (cone-shaped glass fibre tip, 12.7 J/cm ²).
Romeo et al. 2016	Control	40	59	Range (34–68)	3 months	OHI	MD (carbon-fibre-reinforced plastic curettes).
	Test	18 patients (split mouth design)	18	72.0 ± 7.0	6 months	OHI	MD (carbon-fibre-reinforced plastic curettes) + laser-assisted antimicrobial photodynamic therapy.
Roos-Jansaker et al. 2017	Control	15	20	60.6 ± 38.6	6 months	OHI	MD (piezoceramic ultrasonic instrument).
	Test	15	23	52 ± 11	12 months	OHI	MD (piezoceramic ultrasonic instrument) + adjunctive Perisolv™ (chloramine).
Sahm et al. 2011	Control	10	20	56 ± 14	6 months	OHI	MD (carbon curettes) followed by pocket irrigation with 0.1% CHX solution and sub-mucosal application of 1% CHX gel.
	Test	10	16	50	6 months	OHI	AAD using glycine powder.
Schwarz et al. 2006	Control	10	20	56 ± 14	6 months	OHI	MD (plastic curettes) + 0.2% CHX pocket irrigation + 0.2% CHX gel.
	Test	10	20	50	6 months	OHI	Er:YAG laser device (cone-shaped glass fibre tip at 12.7 J/cm ²).
Schwarz et al. 2005	Control	10	16	50	6 months	OHI	MD (plastic curettes) + 0.2% CHX pocket irrigation + 0.2% CHX gel.
	Test	10	16	50	6 months	OHI	Er:YAG laser device (cone-shaped glass fibre tip at 12.7 J/cm ²).

MD, mechanical debridement; OHI, oral hygiene instructions; CHX, chlorhexidine; AAD, air-abrasive device.

Table 4b Characteristics of the included studies

Study	Groups	Treatment Outcomes				Conclusion
		PPD reduction (SD) mean, mm	BOP changes mean (SD), %	CAL Changes mean (SD), mm	Mucosal recession mean (SD), mm	
Arisan et al. 2015	Control	4.38 ± 0.42 to 4.17 ± 0.41	100 % to 100%	N/A	N/A	Adjunctive use of laser does not provide any additional benefits on the clinical and microbial outcomes compared to the mechanical debridement alone.
	Test	4.71 ± 0.67 to 4.54 ± 0.74	100 % to 95.8%	N/A	N/A	
Bucher et al. 2004	Control	5.68 ± 0.28 to 5.4 ± 0.34	0.63 ± 0.06 to 0.50 ± 0.07	5.51 ± 0.27 to 5.18 ± 0.33	N/A	Local antimicrobial therapy showed good results when combined to MD on short periods compared to MD alone, mainly in terms of PPD and CAL.
	Test	5.64 ± 0.32 to 4.49 ± 0.29	0.54 ± 0.07 to 0.27 ± 0.06	5.32 ± 0.33 to 4.17 ± 0.30	N/A	
John et al. 2015	Control	3.9 ± 1.1 to 3.5 ± 1.2	94.7 ± 13.7 to 78.1 ± 30 %	5.0 ± 1.5 to 4.5 ± 1.3	1.0 ± 1.1 to 0.9 ± 1.1	Both treatments revealed comparable CAL gains at 12 months but limited. AAD showed significantly higher BOP reduction compared to MD + antiseptic (CHX).
	Test	3.7 ± 1.0 to 3.2 ± 1.1	99.0 ± 4.1 to 57.8 ± 30.7 %	5.2 ± 1.9 to 4.6 ± 1.8	1.5 ± 1.4 to 1.4 ± 1.3	
Karring et al. 2005	Control	6.2 ± 1.6 to 6.3 ± 2.2	72.7 % to 81.8 %	N/A	N/A	MD done by Vector ® system or carbon fibre curettes did not yield consistent elimination of peri-implantitis, with no significant differences between the two methods except in BOP results.
	Test	5.8 ± 1.1 to 5.8 ± 1.2	63.6 % to 36.4 %	N/A	N/A	
Machtei et al. 2012	Control	7.21 to 5.48	100 % to 59 %	7.63 ± 0.3 to 5.94 ± 0.3	N/A	Significant reduction in PPD, gain in CAL and decrease in BOP in sites affected by peri-implantitis.
	Test	7.60 to 5.47	100 % to 42.5 %	7.88 ± 0.2 to 5.7 ± 0.3	N/A	
Persson et al. 2011	Control	PPD Reductions: 0.8 ± 0.5	100 % to (66.7 – 75 %)	N/A	N/A	Air-abrasive scaling or Er:YAG laser methods failed to reduce bacterial counts and in reversing the clinical events in the attempt of treating severe peri-implantitis lesions.
	Test	PPD Reductions: 0.9 ± 0.8	100 % to (37.5– 77.8 %)	N/A	N/A	
Renvert et al. 2011	Control	PPD Reductions: 0.9 ± 0.8	≈ 98 to 75%	N/A	N/A	Air-abrasive scaling or Er:YAG laser methods showed approximate treatment results in severe peri-implantitis. Although PPD and BOP were reduced, clinical improvement was limited.
	Test	PPD Reductions: 0.8 ± 0.5	100 % to 69.1 %	N/A	N/A	

Table 4b (Continued)

Study	Groups	Treatment Outcomes				Conclusion
		PPD reduction (SD) mean, mm	BOP changes mean (SD), mm	CAL Changes mean (SD), mm	Mucosal recession mean (SD), mm	
Romeo et al. 2016	Control	5.0 to 3.0	100 % to 10 %	N/A	N/A	Photodynamic therapy is an effective adjunctive therapy for reducing bacterial counts and improving the values of clinical indices (PPD, BOP and suppuration values).
	Test	5.0 to 2.0	100 % to 0 %	N/A	N/A	
Roos-Jansaker et al. 2017	Control	Median PPD 5.25 to 3.63	0.97 ± 0.12 to 0.31 ± 0.42	Median CAL 7.00 to 5.13	N/A	Both treatment methods showed good clinical improvement. However, complete resolution of inflammation was not routinely achieved.
	Test	Median PPD 5.38 to 3.63	0.97 ± 0.12 to 0.38 ± 0.46	Median CAL 6.63 to 4.63	N/A	
Sahm et al. 2011	Control	4.0 ± 0.8 to 3.5 ± 0.8	95.3 ± 9.6 to 84.3 ± 15.5 %	4.8 ± 1.3 to 4.3 ± 0.9	0.7 ± 0.8 to 0.7 ± 0.7	Both treatments revealed comparable CAL gains at 6 months but limited. AAD showed significantly higher BOP reduction compared to MD + antiseptic (CHX).
	Test	3.8 ± 0.8 to 3.2 ± 0.9	94.6 ± 15.8 to 51.1 ± 24.7 %	4.8 ± 1.3 to 4.4 ± 1.3	1.0 ± 1.1 to 1.2 ± 1.3	
Schwarz et al. 2006	Control	Moderate Lesions: 4.5 ± 0.8 to 4.3 ± 0.5	Moderate Lesions: (Median) ≈ 82 to 50 %	Moderate Lesions: 5.1 ± 1.0 to 5.0 ± 0.9	N/A	Laser treatment of peri-implantitis showed significant reduction in BOP compared to the treatment method which was applied in the control group that consists of MD (plastic curettes) + 0.2 % CHX pocket irrigation + 0.2 % CHX gel. However, after a 6 months follow-up period, laser treatment seemed to have a limited effectiveness particularly in the cases of advanced peri-implantitis.
	Test	Advanced Lesions: 6.0 ± 1.3 to 5.6 ± 0.9	Advanced Lesions: (Median) ≈ (82 - 100) to 67 %	Advanced Lesions: 6.6 ± 1.4 to 6.3 ± 1.1	Advanced Lesions: (Median) ≈ 0.2 mm to 0.5 mm	
	Test	Moderate Lesions: 4.6 ± 0.9 to 4.1 ± 0.4	Moderate Lesions: (Median) ≈ 91 to 34 %	Moderate Lesions: 5.3 ± 1.0 to 5.0 ± 0.7	Moderate Lesions: (Median) ≈ 0.5 mm to 1 mm	N/A
		Advanced Lesions: 5.9 ± 0.9 to 5.5 ± 0.6	Advanced Lesions: (Median) ≈ (67 - 82) to (50 - 67) %	Advanced Lesions: 6.5 ± 1.2 to 6.3 ± 1.1	Advanced Lesions: (Median) ≈ 0.0 mm to 0.4 mm	

Table 4b (Continued)

Study	Treatment Outcomes				Conclusion	
	Groups	PPD reduction (SD) mean, mm	BOP changes mean (SD), %	CAL Changes mean (SD), mm		Mucosal recession mean (SD), mm
Schwarz et al. 2005	Control	5.5 ± 1.5 to 4.8 ± 1.4	80 to 58 %	6.2 ± 1.5 to 5.6 ± 1.4	0.7 ± 0.8 to 0.8 ± 0.8	N/A
	Test	5.4 ± 1.2 to 4.6 ± 1.1	83 to 31 %	5.8 ± 0.9 to 5.1 ± 0.9	0.4 ± 0.6 to 0.5 ± 0.6	N/A

Both treatment modalities showed significant improvements in the clinical parameters applied in this study. In addition, BOP values were significantly reduced with laser treatment in comparison with the treatment method which was offered to the control group (MD + 0.2 % CHX pocket irrigation + 0.2 % CHX gel).

PPD, peri-implant probing depth; BOP, bleeding on probing; CAL, clinical attachment level; RBL, radiographical bone level; MD, mechanical debridement; AAD, air-abrasive device; CHX, chlorhexidine; SD, standard deviation; N/A, not available.

Table 5 Overview of the treatment modalities in the included studies

1. Mechanical debridement (MD)	(a) Curettes (plastic or carbon)	8 studies
	(b) Air-abrasive device (AAD) using glycine powder	3 studies
	(c) Ultrasonic device	3 studies
2. Laser	(a) Laser diode (injection laser)	1 study
	(b) Er:YAG laser	4 studies
	(c) Ultrasonic device	3 studies
3. Antimicrobial agents	(a) Doxycycline hyclate (Atridox™)	1 study
	(b) Laser-assisted antimicrobial photodynamic therapy (PDT)	1 study
4. Antiseptic agents	(a) Chlorhexidine (irrigating solution (0.1%, 0.2%, 1%), chips, gel)	6 studies
	(b) Chloramine (Perisolv™)	1 study

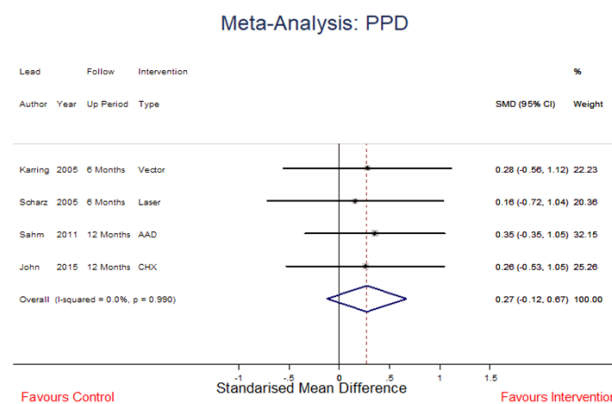


Figure 2 Standardised Mean Difference PPD [Colour figure can be viewed at wileyonlinelibrary.com]

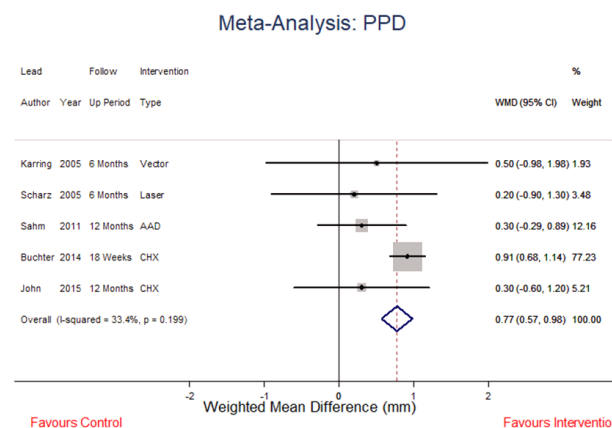


Figure 3 Weighted Mean Difference PPD [Colour figure can be viewed at wileyonlinelibrary.com]

Meta-Analysis: BOP Reduction

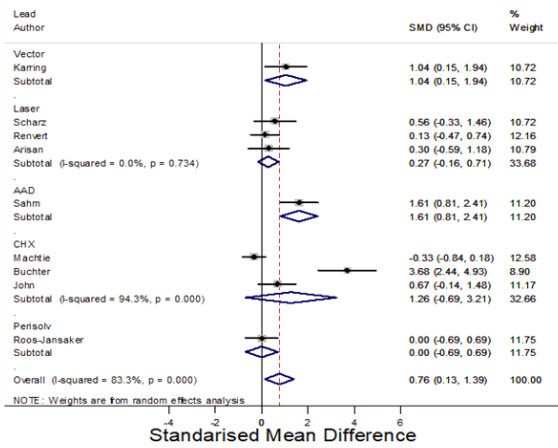


Figure 4 Standardised Mean Difference BOP reduction [Colour figure can be viewed at wileyonlinelibrary.com]

Meta-Analysis: CAL

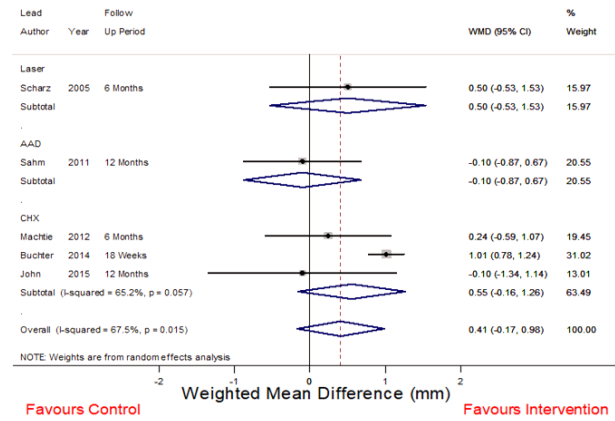


Figure 7 Weighted Mean difference CAL [Colour figure can be viewed at wileyonlinelibrary.com]

Meta-Analysis: BOP Reduction

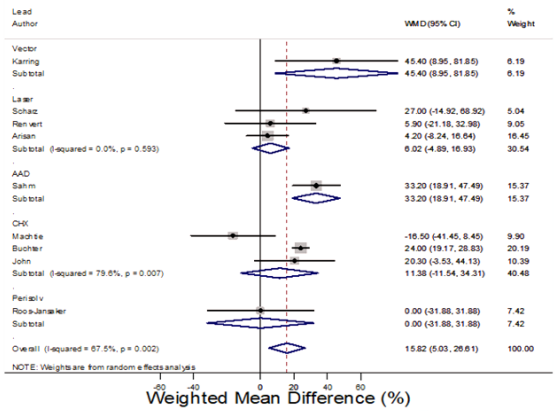


Figure 5 Weighted Mean Difference BOP reduction [Colour figure can be viewed at wileyonlinelibrary.com]

Meta-Analysis: CAL

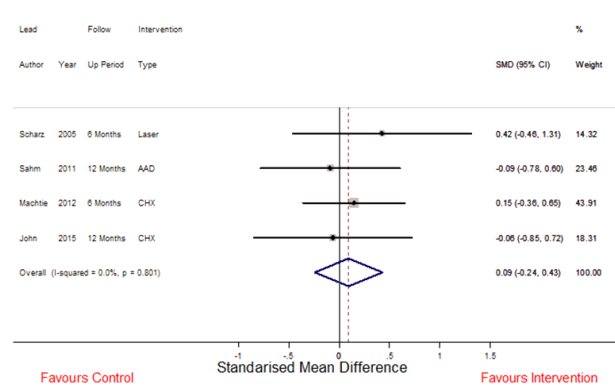


Figure 8 Standardised Mean Difference CAL [Colour figure can be viewed at wileyonlinelibrary.com]

Meta-Analysis: BOP Reduction

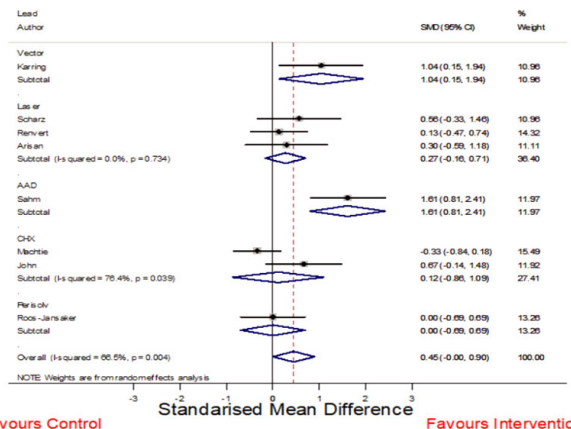


Figure 6 Standardised Mean Difference BOP reduction (outliers removed) [Colour figure can be viewed at wileyonlinelibrary.com]

Meta-Analysis: RBL

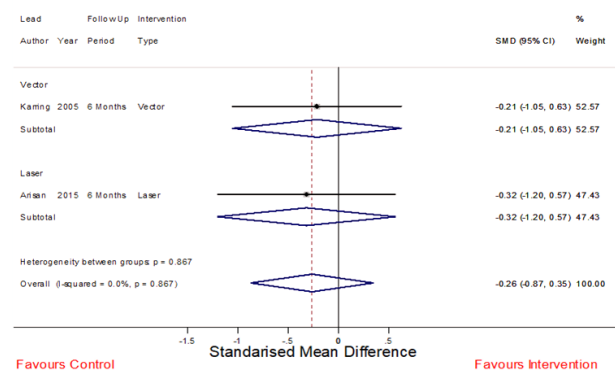


Figure 9 Standardised Mean Difference RBL [Colour figure can be viewed at wileyonlinelibrary.com]

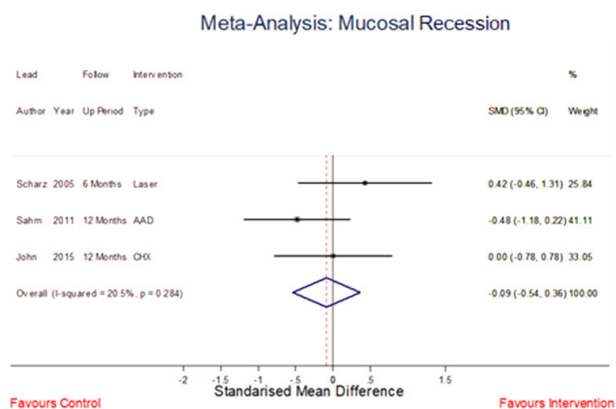


Figure 10 Standardised Mean Difference MR [Colour figure can be viewed at wileyonlinelibrary.com]

reduction by at least 30%. This improvement in clinical parameters was not achieved by any other treatment protocol within the included studies. The addition of chlorhexidine (CHX) in the mechanical debridement procedure failed to show any significant long-term benefit to the final outcome.

The clinical improvement in CAL was also significant (>1 mm) after applying Doxycycline hyclate (Atridox®; DenMat, California, USA). However, the application of continuous CHX irrigation, in this study, may have played a role in achieving this outcome¹¹.

Adjunctive antiseptic agents

The continuous use antiseptic agents may be of benefit in improving the clinical condition of peri-implantitis lesions¹⁷. Unsurprisingly, locally delivered antiseptic agents have been utilised as adjunctive treatments following mechanical debridement in the treatment of peri-implantitis. In these studies, chloramine (Perisolv™; RLS Global AB, Gothenburg, Sweden) and chlorhexidine in solution and gels and as slow-release formulations (Periochip®) have been applied after mechanical debridement. While both PPD and CAL values improved with the addition of chlorhexidine to mechanical debridement, these improvements were, however, not statistically significant when compared with other treatment modalities such as mechanical debridement alone. The use of chlorhexidine chips in NSM of peri-implantitis would seem to offer little clinical benefit. Moreover, Roos-Jansaker²⁰ demonstrated that chloramine fails to show any significant improvement in mucosal inflammation when compared to mechanical debridement alone.

Although a comprehensive analysis was performed, a range of potential bias that may have affected the treatment outcomes must be recognised. These include the definitions of peri-implantitis employed in the included RCTs, the surface design and topography of the implant systems included in the studies, the relatively small number of participants and the risk of selection bias and inclusion criteria within the included RCTs.

Conclusion

This systematic review and meta-analysis confirms the previous studies of Lindhe and Meyle⁴² and Esposito⁴³ and indicate to date, the NSM of peri-implantitis has not been proven to be effective in the long term. No treatment methodologies altered MR and RBL. However, data show that NSM may effectively induce improvements in a number of disease parameters in the short term but their effect on longevity of the implants is questionable.

Conflicts of interest

None.

Funding

None.

References

- Moraschini V, Poubel LAdC, Ferreira VF, Barboza EdSP. Evaluation of survival and success rates of dental implants reported in longitudinal studies with a follow-up period of at least 10 years: a systematic review. *Int J Oral Maxillofac Surg.* 2015;44(3):377–88. <https://doi.org/10.1016/j.ijom.2014.10.023>
- Jung RE, Zembic A, Pjetursson BE, Zwahlen M, Thoma DS. Systematic review of the survival rate and the incidence of biological, technical, and aesthetic complications of single crowns on implants reported in longitudinal studies with a mean follow-up of 5 years. *Clin Oral Implant Res.* 2012;23(Suppl 6):2–21. <https://doi.org/10.1111/j.1600-0501.2012.02547.x>
- Lang NP, Berglundh T; Working Group 4 of Seventh European Workshop on P. Periimplant diseases: where are we now?—Consensus of the Seventh European Workshop on Periodontology. *J Clin Periodontol.* 2011;38(Suppl 11):178–81. <https://doi.org/10.1111/j.1600-051X.2010.01674.x>
- Mombelli A, van Oosten MA, Schurch E Jr, Land NP. The microbiota associated with successful or failing

- osseointegrated titanium implants. *Oral Microbiol Immunol.* 1987;2(4):145–51. <https://doi.org/10.1111/j.1399-302x.1987.tb00298.x>
5. Mouhyi J, Dohan Ehrenfest DM, Albrektsson T. The peri-implantitis: implant surfaces, microstructure, and physicochemical aspects. *Clin Implant Dent Relat Res.* 2012;14(2):170–83. <https://doi.org/10.1111/j.1708-8208.2009.00244.x>
 6. Mahato N, Wu X, Wang L. Management of peri-implantitis: a systematic review, 2010–2015. *Springer-Plus* 2016;5(1):2010–5. <https://doi.org/10.1186/s40064-016-1735-2>
 7. Al-Kadhim KAH, Pritchard MF, Farnell DJJ, Thomas DW, Adams R, Claydon N. Surgical therapy for peri-implantitis management: a systematic review and meta-analysis. *Oral Surgery* 2018;11(3):200–12. <https://doi.org/10.1111/ors.12344>
 8. Romanos GE, Javed F, Delgado-Ruiz RA, Calvo-Guirado JL. Peri-implant diseases: a review of treatment interventions. *Dent Clin North Am* 2015;59(1):157–78. <https://doi.org/10.1016/j.cden.2014.08.002>
 9. Figuero E, Graziani F, Sanz I, Herrera D, Sanz M. Management of peri-implant mucositis and peri-implantitis. *Periodontology 2000* 2014;66(1):255–73. <https://doi.org/10.1111/prd.12049>
 10. Lopez MA, Andreasi Bassi M, Confalone L, Silvestre F, Arcuri C. The treatment of peri-implant diseases: a new approach using hybenx[®] as a decontaminant for implant surface and oral tissues. *Oral Implantol (Rome)* 2016;9(3):106–14. <https://doi.org/10.11138/orl/2016.9.3.106>
 11. Büchter A, Meyer U, Kruse-Lösler B, Joos U, Kleinheinz J. Sustained release of doxycycline for the treatment of peri-implantitis: randomised controlled trial. *Br J Oral Maxillofac Surg* 2004;42(5):439–44. <https://doi.org/10.1016/j.bjoms.2004.06.005>
 12. Salvi GE, Persson GR, Heitz-Mayfield LJA, Frei M, Lang NP. Adjunctive local antibiotic therapy in the treatment of peri-implantitis II: clinical and radiographic outcomes. *Clin Oral Implant Res* 2007;18(3):281–5. <https://doi.org/10.1111/j.1600-0501.2007.01377.x>
 13. van Winkelhoff AJ. Antibiotics in the treatment of peri-implantitis. *Eur J Oral Implantol* 2012;5(Suppl): S43–S50.
 14. Arisan V, Karabuda ZC, Anıcı SV, Topçuoğlu N, Külekçi G. A randomized clinical trial of an adjunct diode laser application for the nonsurgical treatment of peri-implantitis. *Photomed Laser Surg* 2015;33(11):547–54. <https://doi.org/10.1089/pho.2015.3956>
 15. John G, Sahn N, Becker J, Schwarz F. Nonsurgical treatment of peri-implantitis using an air-abrasive device or mechanical debridement and local application of chlorhexidine. Twelve-month follow-up of a prospective, randomized, controlled clinical study. *Clin Oral Invest* 2015;19(8):1807–14. <https://doi.org/10.1007/s00784-015-1406-7>
 16. Karring ES, Stavropoulos A, Ellegaard B, Karring T. Treatment of peri-implantitis by the Vector system. *Clin Oral Implant Res* 2005;16(3):288–93. <https://doi.org/10.1111/j.1600-0501.2005.01141.x>
 17. Machtei EE, Frankenthal S, Levi G, Elimelech R, Shoshani E, Rosenfeld O *et al.* Treatment of peri-implantitis using multiple applications of chlorhexidine chips: a double-blind, randomized multi-centre clinical trial. *J Clin Periodontol* 2012;39(12):1198–205. <https://doi.org/10.1111/jcpe.12006>
 18. Renvert S, Lindahl C, Roos Jansåker A-M, Persson GR. Treatment of peri-implantitis using an Er:YAG laser or an air-abrasive device: a randomized clinical trial. *J Clin Periodontol* 2011;38(1):65–73. <https://doi.org/10.1111/j.1600-051X.2010.01646.x>
 19. Romeo U, Nardi GM, Libotte F, Sabatini S, Palaia G, Grassi FR. The antimicrobial photodynamic therapy in the treatment of peri-implantitis. *Int J Dent* 2016;2016:1–5. <https://doi.org/10.1155/2016/7692387>
 20. Roos-Jansåker A-M, Almhöjd US, Jansson H. Treatment of peri-implantitis: clinical outcome of chloramine as an adjunctive to non-surgical therapy, a randomized clinical trial. *Clin Oral Implant Res* 2017;28(1):43–8. <https://doi.org/10.1111/clr.12612>
 21. Sahn N, Becker J, Santel T, Schwarz F. Non-surgical treatment of peri-implantitis using an air-abrasive device or mechanical debridement and local application of chlorhexidine: a prospective, randomized, controlled clinical study. *J Clin Periodontol* 2011;38(9):872–8. <https://doi.org/10.1111/j.1600-051X.2011.01762.x>
 22. Schwarz F, Sculean A, Rothamel D, Schwenzer K, Georg T, Becker J. Clinical evaluation of an Er:YAG laser for nonsurgical treatment of peri-implantitis: a pilot study. *Clin Oral Implant Res* 2005;16(1):44–52. <https://doi.org/10.1111/j.1600-0501.2004.01051.x>
 23. Schwarz F, Bieling K, Nuesry E, Sculean A, Becker J. Clinical and histological healing pattern of peri-implantitis lesions following non-surgical treatment with an Er:YAG laser. *Lasers Surg Med* 2006;38(7):663–71. <https://doi.org/10.1002/lsm.20347>
 24. Persson GR, Roos-Jansåker A-M, Lindahl C, Renvert S. Microbiologic results after non-surgical erbium-doped:yttrium, aluminum, and garnet laser or air-abrasive treatment of peri-implantitis: a randomized clinical trial. *J Periodontol* 2011;82(9):1267–78. <https://doi.org/10.1902/jop.2011.100660>
 25. Abduljabbar T. Effect of mechanical debridement with and without adjunct antimicrobial photodynamic therapy in the treatment of peri-implant diseases in prediabetic patients. *Photodiagn Photodyn*

- Ther 2017;17:9–12. <https://doi.org/10.1016/j.pdpdt.2016.10.011>
26. Renvert S, Lessem J, Dahlén G, Lindahl C, Svensson M. Topical minocycline microspheres versus topical chlorhexidine gel as an adjunct to mechanical debridement of incipient peri-implant infections: a randomized clinical trial. *J Clin Periodontol* 2006;33(5):362–9. <https://doi.org/10.1111/j.1600-051X.2006.00919.x>
 27. Tang E, Khan I, Andreana S, Arany PR. Laser-activated transforming growth factor- β 1 induces human β -defensin 2: implications for laser therapies for periodontitis and peri-implantitis. *J Periodontol Res* 2017;52(3):360–7. <https://doi.org/10.1111/jre.12399>
 28. Al Amri MD, Kellesarian SV, Ahmed A, Al-Kheraif AA, Romanos GE, Javed F. Efficacy of periimplant mechanical debridement with and without adjunct antimicrobial photodynamic therapy in patients with type 2 diabetes mellitus. *Photodiagn Photodyn Ther* 2016;14:166–9. <https://doi.org/10.1016/j.pdpdt.2016.04.015>
 29. Javed F, Abduljabbar T, Carranza G, Gholamiazizi E, Mazgaj DK, Kellesarian SV *et al.* Efficacy of periimplant mechanical debridement with and without adjunct antimicrobial photodynamic therapy in the treatment of periimplant diseases among cigarette smokers and non-smokers. *Photodiagnosis Photodyn Ther* 2016;16:85–9. <https://doi.org/10.1016/j.pdpdt.2016.09.001>
 30. Karimi MR, Hasani A, Khosroshahian S. Efficacy of antimicrobial photodynamic therapy as an adjunctive to mechanical debridement in the treatment of peri-implant diseases: a randomized controlled clinical trial. *J Lasers Med Sci* 2016;7(3):139–45. <https://doi.org/10.15171/jlms.2016.24>
 31. Lerario F, Roncati M, Gariffo A, Attorresi E, Lucchese A, Galanakis A *et al.* Erratum to: Non-surgical periodontal treatment of peri-implant diseases with the adjunctive use of diode laser: preliminary clinical study. *Lasers Med Sci* 2016;31(1):7. <https://doi.org/10.1007/s10103-015-1817-3>
 32. Mettraux GR, Sculean A, Bürgin WB, Salvi GE. Two-year clinical outcomes following non-surgical mechanical therapy of peri-implantitis with adjunctive diode laser application. *Clin Oral Implant Res* 2016;27(7):845–9. <https://doi.org/10.1111/clr.12689>
 33. Rakašević D, Lazić Z, Rakonjac B, Soldatović I, Janković S, Magić M *et al.* Efficiency of photodynamic therapy in the treatment of peri-implantitis – a three-month randomized controlled clinical trial. *Srp Arh Celok Lek* 2016;144(9–10):478–84.
 34. Bassetti M, Schär D, Wicki B, Eick S, Ramseier CA, Arweiler NB *et al.* Anti-infective therapy of peri-implantitis with adjunctive local drug delivery or photodynamic therapy: 12-month outcomes of a randomized controlled clinical trial. *Clin Oral Implant Res* 2014;25(3):279. <https://doi.org/10.1111/clr.12155>
 35. Schär D, Ramseier CA, Eick S, Arweiler NB, Sculean A, Salvi GE. Anti-infective therapy of peri-implantitis with adjunctive local drug delivery or photodynamic therapy: six-month outcomes of a prospective randomized clinical trial. *Clin Oral Implant Res* 2013;24(1):104–10. <https://doi.org/10.1111/j.1600-0501.2012.02494.x>
 36. Deppe H, Mücke T, Wagenpfeil S, Kesting M, Sculean A. Nonsurgical antimicrobial photodynamic therapy in moderate vs severe peri-implant defects: a clinical pilot study. *Quintessence Int (Berlin, Germany: 1985)*. 2013;44(8):609–18. <https://doi.org/10.3290/j.qi.a29505>
 37. Renvert S, Samuelsson E, Lindahl C, Persson GR. Mechanical non-surgical treatment of peri-implantitis: a double-blind randomized longitudinal clinical study. I: clinical results. *J Clin Periodontol* 2009;36(7):604–9. <https://doi.org/10.1111/j.1600-051X.2009.01421.x>
 38. Renvert S, Lessem J, Dahlén G, Renvert H, Lindahl C. Mechanical and repeated antimicrobial therapy using a local drug delivery system in the treatment of peri-implantitis: a randomized clinical trial. *J Periodontol* 2008;79(5):836–44. <https://doi.org/10.1902/jop.2008.070347>
 39. De Araújo NM, Capelas C, Alves A, Almeida T, Carvalho R, Antunes E *et al.* Non-surgical treatment of peri-implant pathology. *Int J Dent Hyg* 2006;4(2):84–90. <https://doi.org/10.1111/j.1601-5037.2006.00173.x>
 40. Schwarz F, Bieling K, Bonsmann M, Latz T, Becker J. Nonsurgical treatment of moderate and advanced periimplantitis lesions: a controlled clinical study. *Clin Oral Invest* 2006;10(4):279–88. <https://doi.org/10.1007/s00784-006-0070-3>
 41. Schwarz F, Derks J, Monje A, Wang H-L. Peri-implantitis. *J Clin Periodontol* 2018;45(Suppl 20):S246–S266. <https://doi.org/10.1111/jcpe.12954>
 42. Lindhe J, Meyle J, Group DoEWoP. Peri-implant diseases: Consensus Report of the Sixth European Workshop on Periodontology. *J Clin Periodontol* 2008;35(8 Suppl):282–5. <https://doi.org/10.1111/j.1600-051X.2008.01283.x>
 43. Esposito M, Grusovin MG, Worthington HV. Treatment of peri-implantitis: what interventions are effective? A Cochrane systematic review. *Eur J Oral Implantol* 2012;5(Suppl):S21–S41.