

# Online Research @ Cardiff

This is an Open Access document downloaded from ORCA, Cardiff University's institutional repository: <https://orca.cardiff.ac.uk/id/eprint/100677/>

This is the author's version of a work that was submitted to / accepted for publication.

Citation for final published version:

Spiller, Owen Bradley ORCID: <https://orcid.org/0000-0002-9117-6911> 2017.  
Emerging pathogenic respiratory mycoplasma hominis infections in lung transplant patients: time to reassess its role as a pathogen? EBioMedicine 19 , pp. 8-9. 10.1016/j.ebiom.2017.05.002 file

Publishers page: <http://dx.doi.org/10.1016/j.ebiom.2017.05.002>  
<<http://dx.doi.org/10.1016/j.ebiom.2017.05.002>>

Please note:

Changes made as a result of publishing processes such as copy-editing, formatting and page numbers may not be reflected in this version. For the definitive version of this publication, please refer to the published source. You are advised to consult the publisher's version if you wish to cite this paper.

This version is being made available in accordance with publisher policies.

See

<http://orca.cf.ac.uk/policies.html> for usage policies. Copyright and moral rights for publications made available in ORCA are retained by the copyright holders.





## Research Paper

# Cardiothoracic Transplant Recipient *Mycoplasma hominis*: An Uncommon Infection with Probable Donor Transmission



Rahul Sampath<sup>a</sup>, Robin Patel<sup>a,b</sup>, Scott A. Cunningham<sup>b</sup>, Sana Arif<sup>c</sup>, Richard C. Daly<sup>d</sup>, Andrew D. Badley<sup>a</sup>, Mark E. Wylam<sup>e,\*</sup>

<sup>a</sup> Division of Infectious Diseases, Department of Medicine, Mayo Clinic College of Medicine, Rochester, MN 55905, USA

<sup>b</sup> Clinical Microbiology Laboratory, Mayo Clinic College of Medicine, Rochester, MN 55905, USA

<sup>c</sup> Duke University Medical School, Durham, NC 27708, USA

<sup>d</sup> Cardiovascular Surgery, Department of Surgery, Mayo Clinic College of Medicine, Rochester, MN 55905, USA

<sup>e</sup> Division of Pulmonary and Critical Care Medicine, Department of Medicine, Rochester, MN 55905, USA

## ARTICLE INFO

## Article history:

Received 6 March 2017

Received in revised form 11 April 2017

Accepted 18 April 2017

Available online 19 April 2017

## Keywords:

*Mycoplasma hominis*

Cardiothoracic transplantation

Infection

## ABSTRACT

The role of infection with *Mycoplasma hominis* following cardiothoracic organ transplantation and its source of transmission have not been well-defined. Here, we identify and describe infection with *M. hominis* in patients following cardiothoracic organ transplantation after reviewing all cardiothoracic transplantations performed at our center between 1998 and July 2015. We found seven previously unreported cases of *M. hominis* culture positive infection all of whom presented with pleuritis, surgical site infection, and/or mediastinitis. PCR was used to establish the diagnosis in four cases. In two instances, paired single lung transplant recipients manifested infection, and in one of these pairs, isolates were indistinguishable by multilocus sequence typing (MLST). To investigate the prevalence of *M. hominis* in the lower respiratory tract, we tested 178 bronchoalveolar lavage (BAL) fluids collected from immunocompromised subjects for *M. hominis* by PCR; all were negative. Review of the literature revealed an additional 15 cases of *M. hominis* in lung transplant recipients, most with similar clinical presentations to our cases. We recommend that *M. hominis* should be considered in post-cardiothoracic transplant infections presenting with pleuritis, surgical site infection, or mediastinitis. *M. hominis* PCR may facilitate early diagnosis and prompt therapy. Evaluation for possible donor transmission should be considered.

© 2017 The Authors. Published by Elsevier B.V. This is an open access article under the CC BY-NC-ND license (<http://creativecommons.org/licenses/by-nc-nd/4.0/>).

## 1. Introduction

*Mycoplasma hominis* (*M. hominis*) is a mollicute that colonizes the urogenital tract and occasionally causes invasive disease. Extra-genital infections with this organism occur primarily in immunosuppressed persons. *M. hominis* has been linked to pregnancy-related complications and causes meningitis and pneumonia in neonates (Cassell et al., 1991; Samra et al., 2002; Waites et al., 1988). *M. hominis* is not visualizable by gram stain due to its lack of a cell wall, and although it may grow on standard aerobic or anaerobic bacterial culture plates, this method is insensitive and requires highly experienced laboratory personnel to recognize colonies of *M. hominis*. *M. hominis*-specific culture may be performed, but are not widely available, and even if they are available, is not rapid. The route of acquisition of *M. hominis* in patients who undergo cardiothoracic transplantation has not been defined. In two prior reports in *Chest* the authors speculated 1) the organism entered the bloodstream (though blood cultures were negative) of a lung

transplant recipient who developed pleural and pulmonary infection with *M. hominis*. These authors speculated manipulation of the urinary tract with a Foley catheter elicited invasion of lung tissue damaged by transplantation (Lyon et al., 1997) and 2) an 18 year old woman developed diffuse alveolar hemorrhage following bone marrow transplant due to unproven airway or urinary tract colonization (Kane et al., 1994). Herein, we describe seven new cases of *M. hominis* infection in cardiothoracic transplant recipients and review the literature on the topic. We highlight the unique clinical presentation of *M. hominis* in this patient population and present evidence suggesting that this infection may be donor-transmitted. *M. hominis* should be considered in the etiological diagnosis of surgical site infections, mediastinitis and pleuritis after lung or heart-lung transplantation; use of *M. hominis*-specific PCR may expedite diagnosis.

## 2. Methods

The study was reviewed and approved by the Mayo Clinic Institutional Review Board (14-007214). Individual patient consent was not needed.

\* Corresponding author at: Mayo Clinic College of Medicine, 200 First Street, S.W., Rochester, MN 55905, USA.

E-mail address: [wylam.mark@mayo.edu](mailto:wylam.mark@mayo.edu) (M.E. Wylam).

## 2.1. Case Detection

Using our heart and lung transplant database and chart review (between 1998 and July 2015) we found seven (among 182 lung transplants and heart-lung performed and 453 heart transplants) previously unreported cases of culture positive *M. hominis* infection in cardiothoracic transplant recipients (Table 1). In each case routine cultures grew *M. hominis* and no other bacterial pathogens were identified. PCR for *M. hominis* (beginning January 2014), *Ureaplasma urealyticum*, and *Ureaplasma parvum* (beginning January 2015) were requested when suspected infection sites were gram stain negative, and early bacterial cultures were negative with the presence of white blood cells. *M. hominis*, *Ureaplasma urealyticum*, and *Ureaplasma parvum* PCR were specifically performed prospectively on all donor airway specimens beginning in 2015. Importantly, in each case reported herein *M. hominis* was the only infectious agent identified. None of these *M. hominis* cases developed hyperammonemia and none of these cases tested positive for *Ureaplasma* sp. However, we have recently identified a single case of donor bronchus which tested as *M. hominis* PCR negative and *Ureaplasma urealyticum* PCR positive as well as a single case of donor bronchus which tested as *M. hominis* PCR positive and *Ureaplasma urealyticum* PCR negative. Both cases were treated prophylactically without evidence of disease. All *M. hominis* cases and donor surveillance cases were reported to the host organ procurement organization as required by the Organ Procurement Transplant Network. Prior to 2009 all patient received cytolytic induction, after 2009 only heart recipients received cytolytic induction. All patients received intraoperative methylprednisolone. Post-transplant immunosuppression is listed in Table 1.

## 2.2. Literature Review

PubMed was queried beginning in 1950 for *M. hominis* infection and cardiothoracic transplantation.

## 2.3. Surveillance Detection of *M. hominis* DNA in BAL Fluid from Non-cardiothoracic Transplant Immunocompromised Patients

BAL samples submitted for detecting organisms commonly found in immunocompromised hosts undergoing clinically indicated bronchoscopy were tested for *M. hominis* DNA. We used a previously-described real-time PCR assay targeting *M. hominis tuf* (Cunningham et al., 2013). DNA was extracted on the MagNA Pure LC instrument using the MagNA Pure total nucleic acid isolation kit (Roche Applied Science, Indianapolis, IN).

## 3. Results

### 3.1. Patient Evaluation and Donor Characteristics

All patients received standard immunosuppression. All patients had pre-transplant sputum cultures which were negative for *M. hominis*. Routine perioperative bacterial prophylaxis included Vancomycin for 48 h and Cefepime for 48–72 h. Trimethoprim/sulfamethoxazole was typically begun on post-operative day 2 or 3. Any additional bacterial prophylaxis was based upon donor and recipient airway cultures. In all cases clinical signs, including prolonged pleural effusion, prompted routine bacterial and fungal cultures of suspected sites of infection.

**Table 1**  
Summary of 7 Mayo Clinic cases of *Mycoplasma hominis* infection in thoracic transplant recipients.

Case	Age (years) Sex	Transplant indication	Transplant type Immune suppression	Signs or symptoms (days after transplant)	Clinical presentation	Method used to diagnose <i>M. hominis</i> infection	Surgical management	Antimicrobial therapy	Outcome
A (2000)	44M	Secondary pulmonary hypertension	HL ATG/CSA/AZA/Pred	Sternal site infection with sternal dehiscence (15)	Sternal wound infection	Culture-positive surgical debridement specimens	Debridement and sternectomy	Doxycycline and ciprofloxacin × 10 years	Recovered
B (2009)	69M	Idiopathic pulmonary fibrosis	SL ATG/Tacro/AZA/Pred	Dyspnea, unilateral pleural effusion (14)	Pleuritis	Culture positive pleural fluid	Catheter drainage of pleural fluid	Levofloxacin for 3 weeks	Recovered
C (2011)	41F	Pulmonary hypertension	HL ATG/Tacro/Mycop/Pred	Dyspnea, cough with progression to circulatory shock in 48 h (19)	Mediastinitis with aortic anastomotic leak	Culture positive pericardial fluid, periaortic tissue and BAL fluid	Mediastinal debridement (3)	Clindamycin for 4 weeks then doxycycline (lifelong)	Recovered
D (2014)	64M	Idiopathic pulmonary fibrosis	SL Tacro/AZA/Pred	Dyspnea, loculated pleural effusion (16)	Pleuritis	PCR- and culture-positive pleural fluid	Thoracotomy and debridement	Levofloxacin and doxycycline for 6 weeks, followed by doxycycline for 6 months	Slow recovery with multiple subsequent infectious complications
E (2015)	64M	Chronic obstructive lung disease	SL Tacro/AZA/Pred	Fever, leukocytosis and a loculated hydropneumothorax (7)	Pleuritis	PCR- and culture-positive pleural fluid; culture positive debridement specimens (multiple)	Thoracotomy and debridement, wound VAC	Doxycycline (lifelong)	Recovered
F (2015)	70M	Idiopathic pulmonary fibrosis	SL (same donor as D) Tacro/AZA/Pred	Dyspnea, and loculated pleural effusion (21)	Pleuritis	PCR- and culture-positive pleural fluid; culture-positive central venous catheter tip	Pleural fluid aspiration	Doxycycline (lifelong)	Recovered
G (2015)	63M	Idiopathic pulmonary fibrosis	BL Tacro/Myco/Pred	Subcutaneous emphysema (63)	Right bronchial anastomotic leak	PCR positive from both pretransplant donor bronchi and recipient pleural fluid; culture positive from both pretransplant donor bronchi and later bronchial anastomotic eschar	Delayed bronchial anastomotic healing	Levofloxacin and doxycycline (lifelong)	Recovered

M, male; F, female; HL, heart-lung transplant; BL, bilateral lung transplant; SL, single lung transplant; BAL, bronchoalveolar lavage; ATG, antithymocyte globulin; Tacro, tacrolimus; AZA, azathioprine; Pred, prednisone; Myco, mycophenolate mofetil.

*M. hominis* was considered etiologic if routine cultures were negative and *M. hominis* was identified by culture or PCR in presumed sterile sites. Donor characteristics are summarized in Table 2. Although our observations are limited to seven distinct donors among eight recipient cases (including a previously reported case Wylam et al., 2013), several characteristics are noted. The average donor age was 19.7 years (16–23). Six of seven donors had a history of, or tested positive for, drugs of abuse, including methamphetamine and marijuana. In addition, 5 of 7 donors were known tobacco users.

### 3.2. Literature Review

Our review of the literature since 1950 identified 15 cases of *M. hominis* infection in lung, heart or heart-lung transplant recipients (Table 3), one of which was reported from our institution (Wylam et al., 2013). Including our seven new cases, the mean age of the 22 recipients was 47.9 years with 72.7% being male. Pulmonary hypertension, chronic obstructive pulmonary disease (COPD) and pulmonary fibrosis were the most frequent indications for transplantation. Patients developed symptoms a mean of 17.1 days (range 4–63 days) following transplantation. Fever was reported in 8/22 (36%). Pleural/pericardial effusion, chest wall/sternal wound infection, or *M. hominis* bacteremia was evident in 13 (59%) and 12 (55%), and 2 (9%), respectively. All 13 patients with pleural effusions had positive pleural fluid cultures for *M. hominis*. Twelve (55%) patients had *M. hominis* cultured from more than one site; *M. hominis* was isolated from BAL fluid in seven cases.

### 3.3. Detection of *M. hominis* DNA in BAL Fluid from Immunocompromised Patients

In 178 BAL samples obtained from random immunocompromised non-cardiothoracic transplant patients submitted for detecting organisms commonly found in immunocompromised hosts *M. hominis* DNA was not detected in any specimen.

### 3.4. Assessment for Donor-derived Infection

In our Case B of culture proven *M. hominis* single lung transplant associated pleuritis, the donor's other lung was transplanted into a 67 year old female (not included in this report) at our institution who developed superficial wound cellulitis, chest pain and a right-sided hydropneumothorax in the second week post-surgery. A pleural pigtail catheter was placed and routine bacterial cultures on standard media were negative. *M. hominis* PCR testing was not performed. However, imaging showed persistent pleural thickening with fluorodeoxyglucose uptake in the right thoracic cage. She received levofloxacin for diverticulitis and improved clinically. Together, this data suggest the possibility of undiagnosed *M. hominis* infection.

In case G, the donor bronchus culture swab was PCR positive for *M. hominis*. Levofloxacin was given for 2 weeks and doxycycline (life-long) in addition to standard prophylaxis with Vancomycin and Cefepime. Recently, (data not included) we have prophylactically treated one patient whose donor bronchus culture swab was PCR positive for *M. hominis* and one patient whose donor bronchus culture swab was PCR positive for *Ureaplasma urealyticum*. Each patient was treated with doxycycline for 28 days.

Cases E and F (Table 1, Fig. 1) had received single lung transplants from the same donor and each case had transplant site specific infection. Multilocus sequence typing (MLST) was performed on isolates recovered from these two cases and two additional reference isolates (a clinical isolate and the type strain ATCC 23114), using methods described by Sogaard et al. (Sogaard et al., 2002). Briefly, PCR was performed targeting housekeeping genes, *tuf*, *ftsY*, *hitB-hitL*, *uvrA* and *gap*, followed by bidirectional Sanger sequencing. Sequencing data were analyzed (trimming and contig assembly) with the CLC Genomics Workbench (CGW) version 8.0.3 (CLC bio, Cambridge, MA) sequence analysis module. For each target, sequences were aligned and identities calculated using the CGW alignment and tree module. Alignments of the housekeeping genes were joined and a phylogenetic tree constructed using the CGW alignment and tree module. Maximum-likelihood and neighbor joining trees with Jukes-Cantor correction and bootstrap analysis (1000 replicates) were constructed with the CGW software. Isolates recovered from cases D and E were indistinguishable by MLST, with no base pair differences across the five sequenced housekeeping genes (3094 bases). These results suggest common source infection, such as donor-derived infection. No other patients on their hospital unit, other hospital units, or under their surgeons care were infected by *M. hominis*.

## 4. Discussion

*M. hominis* infection in cardiothoracic transplant recipients has been uncommonly reported. The true infection rate may be underestimated in view of difficulties in detecting the organism in clinical specimens and in the use of antibiotic prophylaxis and empiric antimicrobial regimens, such as fluoroquinolones, that do target *M. hominis*. Cardiothoracic transplant patients sustain all of the risks for infection generally encountered in the routine practice of cardiovascular surgery, including *Staphylococcus* species, *Pseudomonas*, and *Serratia*, but fungi especially *Aspergillus* species and *Candida* contribute importantly (Stinson and Oyer, 1995). Donor transmission of infection remains important. Surveillance cultures of donor and recipient, and antimicrobial prophylaxis remain the cornerstone of infection prevention. In the report herein, we note infection with *M. hominis* in the absence of other known infection. The manifestations were often delayed after transplantation by several weeks, and included pleuritis with cellulitis, trapped lung, delayed

**Table 2**  
Donor characteristics associated with the cases described in table and our case described in Reference (Wylam et al., 2013).

Case	Donor age (years) Sex	Donor race	Donor serologies	Drug screen	Other drug history	Tobacco	Donor mechanism of death
A	22 F	Caucasian	CMV +/EBV +	Methamphetamine, tricyclic antidepressant, acetaminophen, aspirin	Alcohol	No	Drug overdose
B	23 M	Hispanic	CMV +/EBV +	Marajuana, ETOH	Alcohol	Yes	CHI
C	19 M	Caucasian	CMV +/EBV +	Negative	Marajuana	Not known	CHI
D/E	16 M	African American	CMV +/EBV +	Negative	Marajuana	Yes	GSW to head
F	23 M	Caucasian	CMV –/EBV +	Negative	Alcohol	Yes, chewing	CHI/MVA
G	19 F	Caucasian	CMV +/EBV +	Methamphetamine	Alcohol	Yes	CHI/MVA
Ref (Wylam et al., 2013)	16 M	African American	CMV +/EBV +	Marajuana	Alcohol	Yes	CHI/MVA

M, male; F, female; CMV, cytomegalovirus; EBV, Epstein-Barr virus; GSW, gun shot wound; CHI, closed head injury; MVA, motor vehicle accident.

**Table 3**Literature review of thoracic transplant recipient infection with *Mycoplasma hominis*.

Case (Ref)	Age (years) Sex	Transplant indication	Transplant type	Signs or symptoms (days after transplant)	Cultures positive for <i>M. hominis</i>	Surgical management	Antimicrobial therapy	Outcome
1 (Hopkins et al., 2002)	52 M	Bronchiectasis	BL	Bilateral pleural effusions, thoracotomy dehiscence, bronchial anastomotic dehiscence (14)	Wound swab and debrided tissue	Bronchial stent placement	Clindamycin and ciprofloxacin followed by oral doxycycline for 6 weeks	Recovered
2 (Hopkins et al., 2002)	55 M	Ischemic cardiomyopathy	H	Sternal dehiscence, fever (8)	Sternal wound swab, pleural fluid	Surgical debridement, drainage	Ciprofloxacin and doxycycline for 14 days	Recovered
3 (Hopkins et al., 2002)	21 M	Dilated cardiomyopathy	H	Sternal wound infection (14)	Sternal wound, pericardial and pleural fluid	Surgical debridement, drains	Ciprofloxacin and doxycycline	Recovered
4 (Hopkins et al., 2002)	17 M	Becker cardiomyopathy	H	Sternal wound, pleural effusion (21)	Sternal wound, pericardial and pleural fluid	Surgical irrigation	Ciprofloxacin and doxycycline for 3 weeks	Recovered
5 (Lyon et al., 1997)	34 M	APL and pulmonary hypertension	BL	Pulmonary infiltrates, pleural effusions (5)	Pleural fluid, bronchial brush specimen, lung biopsy	Surgical debridement	Doxycycline for 4 weeks	Recovered, replaced <i>M. hominis</i> sternal wound infection on day 108
6 (Mitsani et al., 2010)	64 M	Emphysema	BL	Tachycardia, tachypnea (36)	Pericardial fluid	Pericardiocentesis	Doxycycline for 6 week	Recovered
7 (Steffenson et al., 1987)	30 F	Pulmonary hypertension	HL	Cough (3), unstable sternum, fever (24)	Sternum, BAL	Surgical debridement + muscle flap	Clindamycin and doxycycline and gentamicin; duration unknown	Died, day 69 post-transplant
8 (Steffenson et al., 1987)	43 F	Pulmonary hypertension	HL	Dyspnea, pulmonary infiltrates (13), erythema sternal tenderness (17)	Sternal wound, BAL	Superficial I&D with wound packing	Doxycycline and clindamycin and gentamicin	Died, day 37 post-transplant
9 (Boyle et al., 1993)	48 M	Eisenmenger syndrome	HL	Unstable sternum, fever (30)	Sternal wound	Surgical debridement + muscle flap over sternum	Doxycycline for 6 weeks	Relapse of <i>M. hominis</i> empyema seven months later. Placed on doxycycline suppression
10 (Mossad et al., 1996)	41 M	Cystic fibrosis	BL	Sternal wound drainage (22)	Sternal wound culture	Surgical debridement and omental muscle flap	Erythromycin for 14 weeks	Recovered
11 (Gass et al., 1996)	65 M	Alpha-1 antitrypsin deficiency	BL	Pulmonary infiltrates, pleural effusion, fever (7)	Pleural fluid, BAL	Not available	Ciprofloxacin for 4 weeks	Recovered
12 (Gass et al., 1996)	50 M	Emphysema	SL	Pleural effusion, dyspnea (5)	Pleural fluid	None	Ciprofloxacin for 4 weeks	Recovered
13 (Mcmahon et al., 1990)	31 F	Not available	HL	Sternal wound drainage, fever (6)	BAL, sternal wound culture	Debridement + muscle flaps	Clindamycin and doxycycline for 3 weeks	Died <sup>a</sup>
14 (Mcmahon et al., 1990)	43 F	Not available	HL	Sternal wound drainage, fever (13)	BAL, sternal wound	Unknown	Clindamycin and doxycycline for 3 weeks	Died <sup>b</sup>
15 (Wylam et al., 2013)	64 F	Idiopathic pulmonary fibrosis	BL	Confusion, fever, pulmonary infiltrates, coma, hyperammon-emia (4)	Catheter tip (multiple post-mortem tissues PCR positive for <i>M. hominis</i> )	None	Ciprofloxacin	Died

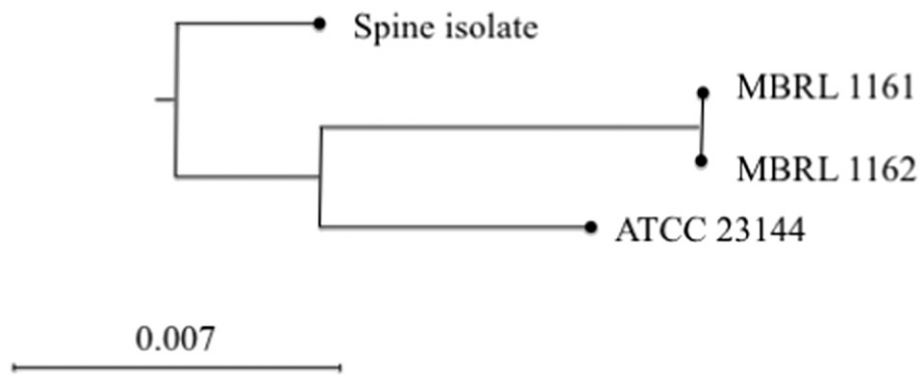
M, male; F, female; HL, heart–lung transplant; BL, bilateral lung transplant; SL, single lung transplant; BAL, bronchoalveolar lavage; H, heart; APL, antiphospholipid antibody syndrome.

<sup>a</sup> After complications with rejection & respiratory failure. Cultures for *M. hominis* were negative at that time.<sup>b</sup> Developed an unstable sternum and CMV pneumonitis.

airway anastomotic healing, and aortic and sternal dehiscence. Treatment included surgical intervention and long-term antibiotics.

*M. hominis* is not stainable by Gram stain and recognition of its pinpoint-sized colonies requires experienced laboratory personnel. BacT/ALERT and BACTEC media (used for blood cultures) contain sodium polyanethol sulfonate, which may inhibit *Mycoplasma* growth (Waites and Canupp, 2001), and growth may not exceed the threshold value for positivity (Waites and Canupp, 2001). Selective *M. hominis* culture media may be useful but remain laborious and expensive.

Since the mid-1990s DNA probe methods using PCR to identify the nucleotide sequences of *M. hominis* have been developed which seek to avoid diagnostic time delays while offering the sensitivity and specificity of conventional culture methods (Yoshida et al., 2003). PCR assays have been designed to target the glyceraldehyde-3-phosphate dehydrogenase gene (*gap*) (Waites et al., 2009), *gidC* (Zhang and Wise, 1996), the *M. hominis* 16S ribosomal RNA gene (Schwab et al., 2012), and, as used herein, *tuf* (Cunningham et al., 2013). We previously reported (in genitourinary specimens) a clinical sensitivity and specificity of 90.7%



**Fig. 1.** Phylogenetic tree based on multilocus sequence typing showing the *M. hominis* isolates from case D (MBRL 1161) and case E (MBRL 1162) to be indistinguishable. The spine isolate represents an isolated from a contemporaneous clinical case of *M. hominis* spinal osteomyelitis; ATCC 23114 is the reference strain.

(95% CI: 77.4%, 97.3%) and 99.2% (95% CI: 97.0%, 99.9%), respectively (Cunningham et al., 2013). For the detection of *M. hominis* PCR tests are faster than culture tests using media supplemented with arginine, allowing the time to diagnosis to be reduced from two to five days to <24 h (Abele-Horn et al., 1996). To date the Federal Drug Administration Center for Devices and Radiologic Health has not approved a nucleic acid based test for the detection of *M. hominis*. Thus, in the U.S. transplant physician will need to consider reference laboratories to perform PCR testing as well as dedicated *M. hominis* cultures and empiric treatment for suspected cases of *M. hominis* infection.

The mode of acquisition of *M. hominis* in cardiothoracic transplant recipients has been uncertain. Colonization rates of donors and recipients have hitherto been uncharacterized (Waite and Canupp, 2001). Lacking the genes coding for a cell wall appears to limit *M. hominis* to a parasitic and saprophytic existence. There are no known natural reservoirs for *M. hominis* though it has been recovered from random public toilet rims (Potasman et al., 1999). *M. hominis* is part of the normal urogenital flora, suggesting a potential endogenous source. Thus, others have speculated without data that *M. hominis* enters the bloodstream from manipulation of the urethra by Foley catheter placement in colonized recipients (Lyon et al., 1997). This rationale is supported by the finding of *M. hominis* sternal wound infection in non-immunocompromised patients undergoing coronary artery bypass grafting without transplantation (Steffenson et al., 1987). A case cluster involving four cases alluded to a common environmental source (Hopkins, 2001; Hopkins et al., 2002), with a suspicion of nosocomial transmission in the four reported cases of *M. hominis* infection occurring over three weeks in the same hospital (Hopkins et al., 2002).

Primary immunodeficiencies are associated with sepsis and septic arthritis due to *M. hominis*. Most reports include patients with common variable immunodeficiency or X-linked agammaglobulinemia (Bloom et al., 2008). Though postpartum septicemia caused by *M. hominis* may be due to genitourinary bacterial translocation (Tully and Smith, 1968), immunodeficiency cases commonly are not associated with urinary tract manipulation. This suggests that dissemination of *M. hominis* may be from acquired from sites outside the genitourinary tract. Though the mechanism(s) required for immunocompetence against *M. hominis* is not clear, we note that in all of our cases pre-transplant immunoglobulin IgA, IgM, IgG and IgG subclasses were determined and values were normal (data not shown) in all cases.

The colonization rate of heart and lung transplant donors with *M. hominis* is not known and may be different from the general population. *M. hominis* may induce exudative pharyngitis (Mufson et al., 1965) and older reports using culture suggest reported it to be recoverable from the respiratory secretions of 1–3% of healthy persons (Hendley and Jordan, 1968) and of ≤8% of persons with chronic respiratory disease (Mufson, 1983). Thus, there is the possibility of transmission related to donor airway colonization, or organ contamination during organ procurement. Donor oral sexual practice may be a risk factor for

*M. hominis* airway colonization as oral sex has been noted as an important route of transmission for *M. hominis* (Edwards and Carne, 1998; Sackel et al., 1979). Our review of the literature (Table 3, cases 11 and 12) describes two recipients who had received lungs from the same donor, supporting the possibility of a donor-derived infection (Gass et al., 1996). Two of their cases (heart and bilateral lung recipients) shared the same donor, although cultures of donor bronchus did not grow *M. hominis*; it is unknown whether *M. hominis*-specific cultures were performed.

Our observations in cases B, E, F, and G suggest that in cardiothoracic transplant recipients, donor-derived acquisition of *M. hominis* is possible. The likelihood that the disease is of donor origin fulfills the term probable donor transmission established by Project NOTIFY (Garzoni and Ison, 2011) as (1) we cannot exclude pre-transplant disease in the recipient; but (2) the disease was documented in more than one recipient (cases E and F) and (3) we provide epidemiologic evidence reporting that in cases D and E there was strain as the isolates were indistinguishable via MLST. Due to a lack of residual specimen, it was not possible to isolate the organism from the donor respiratory tract via culture or detect it by PCR. However, in case G, a donor bronchus swab (the first swab we tested prospectively) tested positive PCR for *M. hominis*. Our surveillance data showing the absence of *M. hominis* DNA by PCR in the BAL samples of unselected immunocompromised hosts suggests that a positive test should be considered significant in the appropriate clinical context. Further studies are needed to evaluate the correlation between clinical infection in cardiothoracic transplant recipients and *M. hominis* positivity in the donor respiratory tract.

We have previously reported detection of *M. hominis* infection in a case of post-lung transplant hyperammonemia (Wylam et al., 2013); the patient had a positive central venous blood culture for *M. hominis* and PCR and immunofluorescence detection of *M. hominis* in multiple post-mortem tissues. Follow-up testing showed the patient to have been co-infected with *Ureaplasma parvum* (Bharat et al., 2015). In follow-up studies, *Ureaplasma* species, both *U. parvum* and *Ureaplasma urealyticum* (without *M. hominis*) were shown to be associated with hyperammonemia in five other lung transplant recipients (Bharat et al., 2015). Therefore, whether or not *M. hominis* plays a role in hyperammonemia in lung transplant patients is unclear. In our cases D, E, F, and G, blood ammonia determined and was not elevated, suggesting that non-systemic *M. hominis* infection is insufficient to cause hyperammonemia in lung transplant recipients.

As *M. hominis* does not produce peptidoglycan, cell wall active antibiotics like  $\beta$ -lactams and vancomycin, commonly used post-transplant, are ineffective. Moreover, *M. hominis* does not require folate and is resistant to folate antagonists (such as trimethoprim/sulfamethoxazole); it is also resistant to aminoglycosides (Sielaff et al., 1996). *M. hominis* is naturally resistant to 14- and 15-membered macrolides, including erythromycin and azithromycin, but is usually susceptible to clindamycin (Furneri et al., 2000). One study tested 110 clinical isolates

of *M. hominis* and found levofloxacin to be inhibitory in all instances, with an MIC<sub>90</sub> of 0.19 µg/ml (Samra et al., 2002). Treatment recommendations for *M. hominis* infection therefore include tetracyclines (doxycycline is preferred), fluoroquinolones and/or clindamycin. Importantly, tetracyclines, fluoroquinolones and clindamycin are not typically included in standard post-transplant prophylactic regimens, nor are they typically included in empiric therapy regimens for surgical site infections. The *tet(M)* determinant confers tetracycline (and doxycycline) resistance; the prevalence of tetracycline resistance in *M. hominis* varies by geographic location and may be as high as 30% (Pogodina, 1975; Samra et al., 2002; Ye et al., 2014). Although susceptibility testing should be used when available, in the absence of definitive evidence, we suggest that combination therapy with a fluoroquinolone and doxycycline may be a preferred regimen for established *M. hominis* infection in cardiothoracic transplant recipients, given the possibility of tetracycline resistance and the potential for selection of fluoroquinolone resistance with fluoroquinolone monotherapy (Bebear et al., 2003). The optimal duration of therapy for *M. hominis* infection in cardiothoracic transplant recipients is not known.

In summary, *M. hominis* is a cause of cardiothoracic transplant infection, presenting with pleuritis, surgical site infection, and/or mediastinitis. We provide evidence that this infection is probably donor-derived. Rapid PCR is an expedient method of detection, used to diagnose four of seven of the cases reported, but does not replace culturing the organism to determine the susceptibility profile. Our current approach is to perform routine PCR for *M. hominis*, *Ureaplasma urealyticum* and *U. parvum* and to perform bacterial culture all donor airways. We perform the same PCR tests on any suspected surgical site infection which is gram stain negative. In addition, we reflexively culture any PCR-positive specimens (e.g., pleural fluid) from cardiothoracic transplant recipients for the purpose of susceptibility testing. Currently, most antibiotic prophylaxis regimens, and regimens for empirical therapy of post-transplant infectious complications do not cover *M. hominis*. Prospective studies are needed to assess the correlation between donor airway positivity for *M. hominis* and clinical infection in transplant recipients.

## Funding Source

None.

## Conflict of Interest

RS, RP, SAC, JJS, SA, RCD, ADB and MEW have no conflicts of interest.

## Author Contributions

MEW, PR, RCD and ADB recognized the potential for investigation. SAC and SA performed the PCR and multilocus analysis. RS performed the literature review and database analysis. RS and MEW drafted and MEW, RP and ADB revised the manuscript. All authors approve of the final version of the manuscript.

## References

- Abele-Horn, M., Wolff, C., Dressel, P., Zimmermann, A., Vahlensieck, W., Pfaff, F., Ruckdeschel, G., 1996. Polymerase chain reaction versus culture for detection of *Ureaplasma urealyticum* and *Mycoplasma hominis* in the urogenital tract of adults and the respiratory tract of newborns. *European Journal of Clinical Microbiology & Infectious Diseases* → *Eur. J. Clin. Microbiol. Infect. Dis.* 15, 595–598.
- Bebear, C.M., Renaudin, H., Charon, A., Clerc, M., Pereyre, S., Bebear, C., 2003. DNA gyrase and topoisomerase IV mutations in clinical isolates of *Ureaplasma* spp. and *Mycoplasma hominis* resistant to fluoroquinolones. *Antimicrob. Agents Chemother.* 47, 3323–3325.
- Bharat, A., Cunningham, S.A., Scott Budinger, G.R., Kreisel, D., Dewet, C.J., Gelman, A.E., Waites, K., Crabb, D., Xiao, L., Bhorade, S., Ambalavanan, N., Dilling, D.F., Lowery, E.M., Astor, T., Hachem, R., Krupnick, A.S., Decamp, M.M., Ison, M.G., Patel, R., 2015. Disseminated *Ureaplasma* infection as a cause of fatal hyperammonemia in humans. *Sci. Transl. Med.* 7, 284re3.
- Bloom, K.A., Chung, D., Cunningham-Rundles, C., 2008. Osteoarticular infectious complications in patients with primary immunodeficiencies. *Curr. Opin. Rheumatol.* 20, 480–485.
- Boyle Jr., E.M., Burdine, J., Bolman III, R.M., 1993. Successful treatment of *Mycoplasma* mediastinitis after heart-lung transplantation. *J. Heart Lung Transplant.* 12, 508–512.
- Cassell, G.H., Waites, K.B., Crouse, D.T., 1991. Perinatal mycoplasmal infections. *Clin. Perinatol.* 18, 241–262.
- Cunningham, S.A., Mandrekar, J.N., Rosenblatt, J.E., Patel, R., 2013. Rapid PCR detection of *Mycoplasma hominis*, *Ureaplasma urealyticum*, and *Ureaplasma parvum*. *Int. J. Bacteriol.* 2013, 168742.
- Edwards, S., Carne, C., 1998. Oral sex and transmission of non-viral STIs. *Sex. Transm. Infect.* 74, 95–100.
- Furneri, P.M., Rappazzo, G., Musumarra, M.P., Tempera, G., Roccasalva, L.S., 2000. Genetic basis of natural resistance to erythromycin in *Mycoplasma hominis*. *J. Antimicrob. Chemother.* 45, 547–548.
- Garzoni, C., Ison, M.G., 2011. Uniform definitions for donor-derived infectious disease transmissions in solid organ transplantation. *Transplantation* 92, 1297–1300.
- Gass, R., Fisher, J., Badesch, D., Zamora, M., Weinberg, A., Melsness, H., Grover, F., Tully, J.G., Fang, F.C., 1996. Donor-to-host transmission of *Mycoplasma hominis* in lung allograft recipients. *Clin. Infect. Dis.* 22, 567–568.
- Hendley, J.O., Jordan Jr., W.S., 1968. *Mycoplasma* pharyngeal flora in civilians. *American Review of Respiratory Disease* → *Am. Rev. Respir. Dis.* 97, 524–532.
- Hopkins, P., 2001. A cluster of mycoplasma hominis infection in heart-lung transplantation. *J. Heart Lung Transplant.* 20, 223–224.
- Hopkins, P.M., Winlaw, D.S., Chhajed, P.N., Harkness, J.L., Horton, M.D., Keogh, A.M., Malouf, M.A., Glanville, A.R., 2002. Mycoplasma hominis infection in heart and lung transplantation. *J. Heart Lung Transplant.* 21, 1225–1229.
- Kane, J.R., Shenep, J.L., Krance, R.A., Hurwitz, C.A., 1994. Diffuse alveolar hemorrhage associated with *Mycoplasma hominis* respiratory tract infection in a bone marrow transplant recipient. *Chest* 105, 1891–1892.
- Lyon, G.M., Alspaugh, J.A., Meredith, F.T., Harrell, L.J., Tapson, V., Davis, R.D., Kanj, S.S., 1997. *Mycoplasma hominis* pneumonia complicating bilateral lung transplantation: case report and review of the literature. *Chest* 112, 1428–1432.
- McMahon, D.K., Dummer, J.S., Pasculle, A.W., Cassell, G., 1990. Extragenital *Mycoplasma hominis* infections in adults. *American journal of medicine* → *Am. J. Med.* 89, 275–281.
- Mitsani, D., Nguyen, M.H., Silveira, F.P., Bermudez, C., Toyoda, Y., Pasculle, A.W., Clancy, C.J., 2010. Mycoplasma hominis pericarditis in a lung transplant recipient: review of the literature about an uncommon but important cardiothoracic pathogen. *Transpl. Infect. Dis.* 12, 146–150.
- Mossad, S.B., Rehm, S.J., Tomford, J.W., Isada, C.M., Taylor, P.C., Rutherford, I., Sorg, S., Mchenry, M.C., 1996. Sternotomy infection with *Mycoplasma hominis*: a cause of "culture negative" wound infection. *J. Cardiovasc. Surg.* 37, 505–509.
- Mufson, M.A., 1983. Mycoplasma hominis: a review of its role as a respiratory tract pathogen of humans. *Sex. Transm. Dis.* 10, 335–340.
- Mufson, M.A., Ludwig, W.M., Purcell, R.H., Cate, T.R., Taylor-Robinson, D., Chanock, R.M., 1965. Exudative pharyngitis following experimental *Mycoplasma hominis*: type 1 infection. *JAMA* 192, 1146–1152.
- Pogodina, V.V., 1975. Elizaveta Nilolaevna Levkovich-75th birthday. *Acta Virol.* 19, 509.
- Potasman, I., Oren, A., Srugo, I., 1999. Isolation of *Ureaplasma urealyticum* and *Mycoplasma hominis* from public toilet bowls. *Infect. Control Hosp. Epidemiol.* 20, 66–68.
- Sackel, S.G., Alpert, S., Fiumara, N.J., Donner, A., Laughlin, C.A., McCormack, W.M., 1979. Oro-genital contact and the isolation of *Neisseria gonorrhoeae*, *Mycoplasma hominis*, and *Ureaplasma urealyticum* from the pharynx. *Sex. Transm. Dis.* 6, 64–68.
- Samra, Z., Rosenberg, S., Soffer, Y., 2002. In vitro susceptibility of *Mycoplasma hominis* clinical isolates to tetracyclines, quinolones and macrolides. *Diagn. Microbiol. Infect. Dis.* 44, 359–361.
- Schwab, J.J., C, S.A., Zomok, C.D., Roden, A.C., Patel, R., 2012. Is *Tropheryma whipplei* or *Mycoplasma hominis* DNA Present in Bronchoalveolar Lavage Fluid from Immunocompromised Hosts? American Society for Microbiology General Meeting in San Francisco, June 16–19, 2012.
- Sielaff, T.D., Everett, J.E., Shumway, S.J., Wahoff, D.C., Bolman III, R.M., Dunn, D.L., 1996. *Mycoplasma hominis* infections occurring in cardiovascular surgical patients. *Ann. Thorac. Surg.* 61, 99–103.
- Sogaard, I.Z., Boesen, T., Mygind, T., Melkova, R., Birkelund, S., Christiansen, G., Schierup, M.H., 2002. Recombination in *Mycoplasma hominis*. *Infect. Genet. Evol.* 1, 277–285.
- Steffenson, D.O., Dummer, J.S., Granick, M.S., Pasculle, A.W., Griffith, B.P., Cassell, G.H., 1987. Sternotomy infections with *Mycoplasma hominis*. *Ann. Intern. Med.* 106, 204–208.
- Stinson, E.B., Oyer, P.E., 1995. Thoracic transplantation. In: Shumway, S.J., Shumway, N.E. (Eds.), *Thoracic Transplantation*. Blackwell Science, Inc., Cambridge.
- Tully, J.G., Smith, L.G., 1968. Postpartum septicemia with *Mycoplasma hominis*. *JAMA* 204, 827–828.
- Waites, K.B., Canupp, K.C., 2001. Evaluation of BacT/ALERT system for detection of *Mycoplasma hominis* in simulated blood cultures. *J. Clin. Microbiol.* 39, 4328–4331.
- Waites, K.B., Rudd, P.T., Crouse, D.T., Canupp, K.C., Nelson, K.G., Ramsey, C., Cassell, G.H., 1988. Chronic *Ureaplasma urealyticum* and *Mycoplasma hominis* infections of central nervous system in preterm infants. *Lancet* 1, 17–21.
- Waites, K.B., Schelonka, R.L., Xiao, L., Grigsby, P.L., Novy, M.J., 2009. Congenital and opportunistic infections: *Ureaplasma* species and *Mycoplasma hominis*. *Semin. Fetal Neonatal Med.* 14, 190–199.
- Wylam, M.E., Kennedy, C.C., Hernandez, N.M., Peters, S.G., Maleszewski, J.J., Cassivi, S.D., Scott, J.P., 2013. Fatal hyperammonemia caused by *Mycoplasma hominis*. *Lancet* 382, 1956.

- Ye, G., Jiang, Z., Wang, M., Huang, J., Jin, G., Lu, S., 2014. The resistance analysis of *Ureaplasma urealyticum* and *Mycoplasma hominis* in female reproductive tract specimens. *Cell Biochem. Biophys.* 68, 207–210.
- Yoshida, T., Maeda, S., Deguchi, T., Miyazawa, T., Ishiko, H., 2003. Rapid detection of *Mycoplasma genitalium*, *Mycoplasma hominis*, *Ureaplasma parvum*, and *Ureaplasma urealyticum* organisms in genitourinary samples by PCR-microtiter plate hybridization assay. *J. Clin. Microbiol.* 41, 1850–1855.
- Zhang, Q., Wise, K.S., 1996. Molecular basis of size and antigenic variation of a *Mycoplasma hominis* adhesin encoded by divergent *vaa* genes. *Infect. Immun.* 64, 2737–2744.