

MASTER OF PHILOSOPHY

**COMPARISON OF TWO DIFFERENT METHODS OF
STEREOSCOPIC VIEWING AND THE EFFECT OF
TEACHING ON THE ASSESSMENT OF THE CUP TO
DISC RATIO FOR GLAUCOMA DETECTION**

MR S JOHNS

**SCHOOL OF OPTOMETRY AND VISION SCIENCES, CARDIFF
UNIVERSITY, CARDIFF, UK**

August 2012

DECLARATION

This work has not previously been accepted in substance for any degree and is not concurrently submitted in candidature for any degree.

Signed (candidate)
Date 30th August 2012

STATEMENT 1

This thesis is being submitted in partial fulfillment of the requirements for the degree of ...MPhil.....(insert MCh, MD, MPhil, PhD etc, as appropriate)

Signed (candidate)
Date 30th August 2012

STATEMENT 2

This thesis is the result of my own independent work/investigation, except where otherwise stated.

Other sources are acknowledged by explicit references.

Signed (candidate)
Date 30th August 2012

STATEMENT 3

I hereby give consent for my thesis, if accepted, to be available for photocopying and for inter-library loan, and for the title and summary to be made available to outside organisations.

Signed (candidate)
Date 30th August 2012

Summary of Thesis

This study examines the effect of teaching on a group of naive observers asked to determine the cup-to-disc ratio of a series of stereo photographs presented by two different methods using custom software StereoDxT developed at Cardiff University. One method of presentation made use of Nvidia 3D software and compatible hardware, while the other was a 'low tech' approach using red-cyan anaglyphs. In order to further inform the results of this study, the members of the glaucoma team at North Devon District Hospital (NDDH), consisting of ophthalmologists, optometrists and other staff, undertook a similar study. An experiment to examine the magnification factor of several different binocular indirect lenses routinely used in the glaucoma clinics was also undertaken.

The study showed observers, following a training session with the more expensive presentation system, improved their performance relative to an expert observer, while those using anaglyph images returned equivocal results. Control observers' performance remained the same throughout the study. When compared against qualified staff at NDDH it was found that generally naive observers could improve their ability to determine cup-to-disc ratios to a similar level of experienced practitioners. It is believed that the anaglyph approach could be a viable alternative to higher cost training 'set ups' provided images are carefully selected and produced in a controlled manner. Measurements of a simulated optic disc taken with the binocular indirect lenses at differing simulated ametropias and working distances were found to be inconsistent with all the lenses tested. This raises concerns that a single manufacturers' magnification factor may not be ideal where accurate measurements of fundal structures such as the optic disc is concerned.

I WOULD LIKE TO DEDICATE THIS WORK TO THE MEMORY OF

MISS DORIS MAY DIBBLE MBE

27TH JULY 1920 – 5TH SEPTEMBER 2011

**FOR ALL THE HELP AND SUPPORT THAT SHE GAVE ME OVER THE
YEARS I KNEW HER AS CHAIR OF THE BARNSTAPLE LEAGUE OF
FRIENDS AND VALUED COLLEAGUE**

AND TO THANK

MR R A GIBSON FRCSE, FRCOphth.

**FOR HIS CONSTANT SUPPORT, COUNSEL AND FRIENDSHIP IN THE 27
YEARS THAT WE WORKED TOGETHER AT NORTH DEVON DISTRICT
HOSPITAL UNTIL HIS RETIREMENT IN JANUARY 2012**

ACKNOWLEDGMENTS

**Professor R North for her help throughout my period of study
Professor J E Morgan for his help in undertaking the training sessions
Dr A Jones for agreeing to be the expert observer
Barnstaple League of Friends for their very kind financial assistance for
this study**

CONTENTS

CHAPTER 1 GENERAL INTRODUCTION

1.1	INTRODUCTION	1
1.2	ANATOMY OF THE EYE IN RELATION TO GLAUCOMA	2
1.2.1	The ciliary body	2
1.2.2	The trabecular meshwork	3
1.2.3	The optic nerve	3
1.3	CLASSIFICATION OF GLAUCOMA	4
1.3.1	Common classification of glaucoma	5
1.3.1.1	Primary open angle glaucoma	5
1.3.1.2	Primary closed angle glaucoma	6
1.3.1.3	Secondary open angle glaucoma	6
1.3.1.4	Secondary closed angle glaucoma	6
1.3.1.5	Congenital glaucoma	7
1.3.2	Spaeth classification of glaucoma	7
1.3.2.1	Generalised Atrophy	7
1.3.2.2	Concentric cupping	7
1.3.2.3	Senile sclerotic	8
1.3.2.4	Venous stasis	8
1.3.2.5	Focal glaucoma	8
1.3.3	Optic nerve head morphology in classification of glaucoma	9
1.4	GLAUCOMA AS A CAUSE OF BLINDNESS	12

1.5	IDENTIFYING GLAUCOMA IN THE TRADITIONAL CLINICAL SETTING	14
1.5.1	Visual fields examination	15
1.5.2	Tonometry	18
1.5.3	Optic Nerve Head examination	20
1.5.3.1	Direct ophthalmoscopy	20
1.5.3.2	Indirect ophthalmoscopy	22
1.5.4	Stereophotography	23
1.6	MODERN TOOLS TO AID IN GLAUCOMA DIAGNOSIS	23
1.6.1	Confocal scanning laser ophthalmoscope	23
1.6.2	Optical coherence tomography	25
1.6.3	Scanning laser polarimetry	28
1.6.4	StereoDx Software	30
1.7	SCREENING VS. CASE DETECTION	35

CHAPTER 2 CONSIDERATION OF THE OPTIC NERVE HEAD IN GLAUCOMA

2.1	THE NORMAL OPTIC NERVE HEAD	40
2.1.1	The normal optic disc diameter	42
2.1.2	The normal optic cup diameter	42
2.1.3	Cup-to-disc ratio, neural retinal rim area and number of nerve fibres	43
2.1.4	Shape of the neural retinal rim	44

2.1.5	Other variations in optic nerve head – Race, Gender, Ametropia and Aging	45
2.1.5.1	Race	45
2.1.5.2	Gender	46
2.1.5.3	Ametropia	46
2.1.5.4	Age	47
2.1.6	Other reported associations in optic nerve head	48
2.2	GLAUCOMATOUS APPEARANCE OF THE OPTIC NERVE HEAD	49
2.2.1	Optic disc size	50
2.2.2	Cup-to-disc ratio Neural retinal rim size	50
2.2.3	Peripapillary chorioretinal atrophy (PPA)	52
2.2.4	Optic disc haemorrhage	54
2.3	CLASSIFICATION, STAGING, SCORING SYSTEMS	57
2.3.1	Considerations for a grading system, the use of scale and measurement variability	58
2.3.2	Staging systems for glaucomatous optic nerve head damage	59
2.3.2.1	Cup Size methods	60
2.3.2.1.1	Armaly's system	60
2.3.2.1.2	Richardson's system	61
2.3.2.1.3	Nesterov's system	62
2.3.2.2	Rim methods	62
2.3.2.2.1	Read-Spaeth system	62
2.3.2.2.2	Shiose's system	63

2.3.2.2.3	Jonas's system	63
2.3.2.2.4	Disc Damage Likelihood Scale	64
2.3.2.2.5	Optic Disc Damage Staging System	66
2.3.2.3	Probability Method	67
2.3.2.4	Merged disc staging/imaging methods	67
2.3.2.5	Cup excavation methods	68
2.4	THE IMPORTANCE OF THE CUP-TO-DISC RATIO MEASUREMENT	69

CHAPTER 3 VIEWING THE OPTIC NERVE HEAD IN THREE DIMENSIONS

3.1	DIRECT AND INDIRECT OPHTHALMOSCOPY	73
3.2	STEREOPHOTOGRAPHY	75
3.2.1	Production of stereoimages of the optic nerve head	76
3.2.2	Methods of viewing stereophotographs	80
3.2.2.1	Printed methods	80
3.2.2.1.1	Side by side prints	80
3.2.2.1.2	Anaglyphs	81
3.2.2.1.3	Lenticular transparency	82
3.2.2.2	35 mm image methods	82
3.2.2.3	Digital image methods	83
3.2.2.3.1	Side by side display	83
3.2.2.3.2	Anaglyphs	83
3.2.2.3.3	Z-screen technology	83

3.2.2.3.4	Liquid crystal shutter goggles	85
3.2.2.3.5	Autostereoscopic screen	86
3.2.2.4	Flicker chronoscopy	87
3.3	ADVANTAGES OF STEREOPHOTOGRAPHS OVER OTHER IMAGING MODALITIES IN ASSESSING THE GLAUCOMATOUS OPTIC NERVE HEAD	88
3.4	THE ROLE OF STEREOPSIS IN VIEWING OPTIC DISC IMAGES	89
3.5	STUDIES ON THE AGREEMENT BETWEEN DIFFERENT OBSERVERS IN THE DETECTION OF GLAUCOMATOUS OPTIC NEUROPATHY	92
3.5.1	Detection	92
3.5.2	Progression	94
3.6	THE EFFECT OF TEACHING ON THE ABILITY TO DETERMINE THE OPTIC DISC AND NEURAL RETINAL RIMS	97
3.6.1	Limited parameters being tested and the use of stereophotographs of the optic nerve head	98
3.6.2	Large numbers, web based delivery and multiple disc characteristics	99

**CHAPTER 4 EFFECT OF TEACHING ON THE DETERMINATION OF
CUP-TO-DISC RATIOS WITH DIFFERENT STEREO
PRESENTATIONS**

4.1	AIM OF STUDY	104
4.2	METHOD	104
4.2.1	Image selection	105
4.2.2	Observer selection	106
4.2.3	Initial assessment of optic nerve head images	107
4.2.4	Teaching of selected observers	108
4.2.5	Second assessment of the optic nerve head	108
4.3	MAIN OUTCOME MEASURES	112
4.4	RESULTS	113
4.4.1	Non-anaglyph group results	114
4.4.2	Anaglyph Group results	119
4.5	Agreement between the two different methods of stereopresentation; anaglyph and non-anaglyph.	124
4.6	DISSCUSSION	126
4.6.1	Performance of anaglyph images	128
4.6.2	Study methodology	131

**CHAPTER 5 BARNSTAPLE STUDY 1, CUP-TO-DISC RATIO
ASSESSMENTS**

5.1	CUP-TO-DISC RATIO ASSESSMENTS	134
5.1.1	Aim of study	134
5.1.2	Method	136
5.1.3	Results	138
5.1.3.1	Planimetric values BGP compared to expert observer and CLG	138
5.1.3.2	Subjective assessment of cup-to-disc ratio differences between BGP and CLG	141
5.1.3.3	BGP differences between subjective and planimetry assessments	142
5.1.3.4	BGP assessment of glaucoma status of each image	142
5.1.4	Discussion	145

**Chapter 6 BARNSTAPLE STUDY 2, FACTORS THAT INFLUENCE
ASSESEMNT OF THE ONH DIMENSIONS USING NC BIO
LENSES**

6.1	METHOD	149
6.2	RESULTS	155
6.3	DISCUSSION	158

CHAPTER 7 GENERAL DISCUSSION, CONCLUSIONS AND FUTURE WORK

7.1	SPECIFIC ISSUES RELATING TO THE STUDY	164
7.2	OBSERVERS' PREFERENCE AND AGREEMENT BETWEEN DIFFERENT METHODS OF STEREOPRESENTATION	168
7.3	COMMON POINTS OF DISCUSSION BETWEEN CARDIFF AND BARNSTAPLE STUDIES	168
7.4	CONCLUSIONS AND RECOMMENDATIONS	171
7.4.1	Conclusion 1	171
7.4.2	Conclusion 2	172
7.4.3	Conclusion 3	172
7.5	RECOMMENDATIONS	173
7.5.1	Recommendations from conclusion 1	173
7.5.2	Recommendation from conclusion 3	174
	REFERENCES	175
	APPENDIX A	215
	APPENDIX B	217

LIST OF FIGURES AND TABLES

FIGURES

Figure 2.1.	Optic nerve head showing several landmarks	41
Figure 2.2.	Optic nerve head image illustrating zones alpha (α) and zone beta (β) PPA	52
Figure 3.1.	Example of Nidek stereophotograph used in the study	76
Figure 3.2.	Z –screen mounted on computer monitor, with examples of passive polarised spectacles (Stereographics Corporation, CA, USA)	84
Figure 3.3.	Nvidia 3D Vision LCS goggles with control emitter (Nvidia Corp. UK)	85
Figure 4.1.	Observer’s view when using StereoDxT software to demarcate the neural retinal rim and the disc rim (labelled scleral rim in software)	107
Figure 4.2.	The trained observer’s view of the StereoDxT software revealed when clicking on ‘expert view’ tab	109
Figure 4.3.	Flow diagram indicating observer groups and the number of images they were asked to assess	111
Figure 4.4.	Non-anaglyph teaching group A – D, cup-to-disc ratio assessments compared with those of the expert before and after teaching	115

Figure 4.5.	Non-anaglyph controls group E – H, cup-to-disc ratio assessments compared with those of the expert at each visit	117
Figure 4.6.	Anaglyph teaching group I – J, cup-to-disc ratio assessments compared with those of the expert before and after teaching.	120
Figure 4.7.	Anaglyph controls group M – P, cup-to-disc ratio assessments compared with those of the expert at each visit	121
Figure 4.8.	Bland and Altman plot showing the level of agreement between cup-to-disc ratios, as determined by the two methods of stereo-presentation	125
Figure 5.1.	Cup-to-disc differences between the BGP and expert observer	138
Figure 5.2.	Cup-to-disc differences BGP and CLG Barnstaple	139
Figure 6.1.	The artificial eye mounted on the slit lamp showing the lens holder in which the ncBIO lenses were placed	151
Figure 6.2.	Knurled rings and the positions the lenses were placed in the artificial eye lens holder	152
Figure 6.3.	Measurement of ‘disc’ height with lenses in position 1	155
Figure 6.4.	Measurement of ‘disc’ height with lenses in position 2	156

Figure 6.5.	Shows the effect of moving the lenses from position 1 to 2	157
Figure 6.6.	Example of Gullstrand type model eye (Institute of Ophthalmology, London)	161
Figure A	Anaglyph teaching group I – J, '10 Discs' after teaching - Appendix A	215
Figure B	Anaglyph controls M – P, '10 Discs' observer first assessment - Appendix A	215

TABLES

Table 1.1.	Summary of associations with different optic nerve head (disc) sub-types	11
Table 1.2.	Shows a summary comparison of the four imaging modalities described previously along with the comparison of direct ophthalmoscopy	34
Table 4.1.	Interpretation of Intraclass Correlation Coefficients (ICC)	113
Table 4.2.	Cup-to-disc ratio differences between each observer and the expert observer and agreement between observers in the non-anaglyph group	118

Table 4.3.	Cup-to-disc ratio differences between each observer and the expert observer and agreement between observers in the anaglyph group	123
Table 5.1.	Cup-to-disc ratio differences between BGP, the expert observer and CLG	140
Table 5.2.	Subjective cup-to-disc ratio differences BGP vs CLG	141
Table 5.3.	Cup-to-disc ratio differences subjective vs planimetric assessments BGP	142
Table 5.4.	BGP assessment of the glaucoma status of each viewed disc	143
Table 6.1.	Summary of the field of view, magnification and working distance of the ncBIO lenses according to manufacturer	153
Table 6.2.	.Distances from front of lens to front of artificial eye	154
Table 7.1.	Cup, rim and disc areas in number of pixels from StereoDxT analysis	169
Table A	Cup-to-disc ratio differences between each observer and the expert and agreement between observers in the anaglyph group '10 Discs' – Appendix A	216

Chapter 1 General Introduction

The following chapters are structured as follows.

- Chapter 1 Provides an overview of anatomy, classification and diagnosis of glaucoma as a sight threatening condition.
- Chapter 2 Discusses the normal optic nerve head (ONH), glaucomatous optic nerve head changes and methods of staging glaucomatous damage
- Chapter 3 Discusses viewing the optic nerve head in 3 dimensions
- Chapter 4 Cardiff experiment, results and discussion
- Chapter 5 Barnstaple study 1, experiment, results and discussion
- Chapter 6 Barnstaple study 2, experiment, results and discussion
- Chapter 7 General discussion points, conclusions and future work

1.1 Introduction

The term 'glaucoma' covers a number of diseases with differing clinical presentation. This presentation involves both varying structural changes to the ocular anatomy and pathophysiological changes. The common feature of all glaucomas is a progressive optic neuropathy which derives from various risk factors associated with visual field loss which, untreated, can lead to blindness (Azuaara-Blanco et al. 2002). While there are a number of glaucoma subgroups, essentially they can be divided into open angle glaucomas, closed angle glaucomas and developmental glaucomas. In the former two types the

distinction relates to the variation in anatomical appearance of the iridocorneal angle and thus indirectly to the mechanism behind the rise in intraocular pressure (IOP) and the resultant damage to the optic nerve head (ONH). The most common type of glaucoma is Primary Open Angled Glaucoma, which is a disease of age, with a prevalence that increases with increasing years (Mitchell et al. 1996).

1.2 Anatomy of the eye in relation to glaucoma

There are three areas that need to be taken into account when considering the anatomy of the eye and how it relates to the disease processes that collectively can be termed glaucoma. These three areas are the ciliary body, the trabecular meshwork and the optic nerve head.

1.2.1 The ciliary body

This structure forms part of the uveal tract and extends posteriorly from the scleral spur to the ora serrata. It is made up of three layers of ciliary muscle and the ciliary processes. These processes are made up of an inner capillary core, stroma and a double layer of epithelium. The epithelial cells are interconnected by specialised junctions that control the passage of water, ions and macromolecules into the aqueous humour (Azura-Blanco et al. 2002). It is the primary function of these processes to produce aqueous humour with a production of about 2-2.5 microlitres per minute under normal conditions.

1.2.2 The trabecular meshwork

This is an area of the eye which, along with the scleral spur, ciliary muscle and Schlemm's canal, work together to provide the conventional aqueous outflow pathway. This area lies within the anterior chamber angle or iridocorneal angle and can be visualised using the technique of gonioscopy in cases of open angle glaucoma, as compared to cases of closed angle glaucoma when these and other structures are not seen. The conventional outflow pathway is responsible for 90% of the aqueous outflow (Alward 2001). The remaining 10% of the outflow is via unconventional routes mainly through the ciliary body face into the supra choroidal space (Bill and Philips 1971).

1.2.3 The optic nerve

This is a cylindrical structure about five centimetres long lying between the retina and the optic chiasm. It can be divided into four parts: the intraocular or optic nerve head, intraorbital, intracanalicular and the intracranial portions. The optic nerve is composed of between 1.2-1.5 million axons along with glial cells, supportive tissue and vascular elements. It is the intraocular portion that undergoes characteristic changes in glaucoma which can be viewed by a number of different means during an ophthalmological or optometric examination of a patient. The optic nerve head (ONH), also known as the optic disc or papillae, is delineated from the retina by the scleral ring of Elschnig and can itself be sub-divided into four parts. These are the

superficial nerve fibre layer, the prelaminar layer, the laminar layer including the lamina cribrosa (a modification of the sclera), and the retrolaminar portion.

1.3 Classification of glaucoma

The way in which glaucoma has been classified has altered over the years (Spaeth 1994). At first it was held to be any non-inflammatory blindness, then from the late 1800s onwards the concept of glaucoma relating to a rise in intraocular pressure (IOP) was proposed by the likes of Bowman and Von Graefe. Since then other proposals have been based on the presenting symptoms and the cause of the rise in IOP. However, in the 1960s it became apparent through published work that many patients with high IOP or ocular hypertension did not have glaucoma (Spaeth 1994). More recent papers also confirm that only a subset of patients with ocular hypertension will develop glaucoma (Friedman et al. 2004; Kass et al. 2002). There has been an estimate made of risk of progression of ocular hypertension to unilateral blindness in untreated ocular hypertension in a fifteen year time frame of between 1.5% and 10.5% (Weinreb et al. 2004), a figure that is reduced to between 0.3% and 2.4% if treatment is instigated. The Ocular Hypertension Treatment Study (OHTS) (Gordon et al. 2002; Kass et al. 2002), a large randomised prospective study designed to evaluate the effectiveness of ocular hypotensive agents on delaying or preventing primary open angle glaucoma (POAG), seems to successfully show that there are a number of predictors to take into account when considering the potential development of glaucoma in a patient presenting with ocular hypertension. Conversely, in

the 1960s others were showing that about one-third of patients presenting with optic nerve head changes and visual field loss considered to be glaucomatous had no elevation in IOP (Spaeth 1994). This led to glaucoma being defined in terms of the mechanism of optic nerve damage and thus a classification based on the appearance of the optic nerve head. This prompted Spaeth to suggest that this method of classification was a new concept (Spaeth 1994).

1.3.1 Common classification of glaucoma

1.3.1.1 Primary open angle glaucoma (POAG)

This is a chronic progressive optic neuropathy. It is diagnosed by characteristic changes at the optic nerve head which comprises of cupping and atrophy of the neural retinal rim along with visual field defects. The iridocorneal angle is open and normal in appearance and usually the intraocular pressure is above 21 mmHg as measured by tonometry at some point in the course of the disease. It is a disease of adult onset and has a prevalence that increases with age (Mitchell et al. 1996). In certain cases the intraocular pressure is considered to be within the normal range for the population, which is usually considered to be between 11 mmHg to 21 mmHg, although this value will vary slightly with the population that is being investigated (Mitchell et al. 1996). Hitchings (1992) suggested that, while previously the figure of up to 35% of all open angle glaucomas fell within this normotensive category, a truer figure for Caucasians was probably nearer 15%.

1.3.1.2 Primary closed angle glaucoma (PCAG)

This is a condition whereby the aqueous outflow is obstructed by either a partial or complete closure of the iridocorneal angle by the peripheral iris. For a diagnosis of PACG, there is the requirement for a careful examination of the iridocorneal angle as the diagnosis is not precluded by the presence of a normal optic nerve head or lack of visual field defect. There is an anatomical predisposition and, although acute presentation can be unilateral, it is a bilateral disease (Kanski 1999).

1.3.1.3 Secondary open angle glaucoma (SOAG)

There are a number of reasons why glaucoma may occur in eyes with an open iridocorneal angle. This may be from the accumulation of material which leads to the obstruction of the trabecular meshwork, abnormalities in the trabecular meshwork or elevated episcleral venous pressure.

Pseudoexfoliation syndrome and pigment dispersion syndrome are two of the more commonly seen conditions in this sub group.

1.3.1.4 Secondary closed angle glaucoma (SCAG)

There are two types of secondary angle closure, one being with pupil block and the other without. Pupil block arises from 360 degree iridolenticular adhesions. Thus the passage of aqueous is obstructed causing an increase in pressure within the posterior chamber of the eye. The result of this is that the iris can then bow forward and appose the trabecular meshwork and the peripheral cornea. Angle closure without pupil block on the other hand results

from chronic anterior uveitis. Synechial angle closure arises from contraction of inflammatory material in the iridocorneal angle.

1.3.1.5 Congenital glaucoma

This can arise as a rare sporadic trabeculodysgenesis or in association with ocular or systemic developmental disorders (Kanski 1999).

1.3.2 Spaeth classification of glaucoma

This is based on the appearance of the optic nerve head.

1.3.2.1 Generalised atrophy

This occurs in what has been presented as acute angle-closure glaucoma.

The optic nerve head becomes pale with minimal cupping.

1.3.2.2 Concentric cupping

This type of optic nerve head change is seen in cases of chronic diffuse glaucoma, where the IOP is raised over a prolonged period of time, giving rise to a round, concentrically enlarging, optic cup, where the neural retinal rim becomes increasingly thinned. In this pattern of glaucomatous damage there are no early signs of notching, haemorrhages or optic pits. This type of damage is seen in the following clinical entities: Primary Open Angle Glaucoma (POAG), Pseudoexfoliative glaucoma, Pigmentary glaucoma and in secondary glaucomas associated with angle-closure, trauma and papillary block.

1.3.2.3 Senile sclerotic

This pattern of optic nerve head change has the appearance of diffuse atrophic cupping which is shallow and associated with marked peripapillary atrophy. The mechanism is possibly a secondary ischaemia caused by elevated IOP, in association with blood vessel disease at the optic nerve head or just simply the latter (Spaeth 1994). As this pattern occurs mainly in the elderly and the main reason for elevation of the IOP in this group is primary open angle glaucoma, it has been suggested that most cases are diagnosed as POAG at present.

1.3.2.4 Venous stasis

This type of glaucoma results from the inability of outflow through the central retinal vein. Retinal veins become engorged and there may be the formation of vascular shunts and haemorrhages. Central retinal vein occlusions may present as a secondary occurrence. Jonas (2003), found that the central retinal vein collapse pressure, a measure of the outflow was higher in patients with primary open angle glaucoma and concluded that this is why there is a higher frequency of retinal vein occlusions in patients with glaucoma.

Furthermore, it has been found that there is a higher retinal vein to retinal artery ratio in patients with primary open angle glaucoma (Jonas et al. 1989b).

1.3.2.5 Focal glaucoma

This type of appearance was first described around 1973 and was called focal ischemic glaucoma. It tends to be found in younger patients with primary open angle glaucoma with a predilection to women. A strong family history,

acquired pits of the optic nerve (APON) and associated peripapillary atrophy are said to occur in all cases and there is generally a lower IOP (Spaeth 1994).

1.3.3 Optic nerve head morphology in classification of glaucoma

Morphology by definition means the scientific study of structure and form, and needs to be distinguished from the term phenotype, which is the physical characteristics of something living, especially those characteristics which can be seen, and topography, which is the physical appearance of natural features, especially the shape of its surface. With reference to the appearance of the optic nerve head, be it observed directly with the ophthalmoscope or by any of the newer imaging methods, such as scanning laser ophthalmoscopy, these terms have been used almost interchangeably by authors to describe the appearance of the optic nerve head.

There have been many publications looking at the appearance of the optic nerve and its relationship to many varying factors in glaucomatous, suspect glaucomatous and non-glaucomatous eyes. There have been published reports on the optic nerve head in different populations such as Vellore in India (Jonas et al. 2003), in the general population in Rotterdam (Ramrattan et al. 1999), and in healthy adults in Germany (Hermann et al. 2004). There have also been numerous papers looking at various features of the optic nerve head, such as disc dimensions (Crowston et al. 2004), peripapillary area (Budde and Jonas 2004; Jonas et al. 2001), blood vessels (Mitchell et al.

2005; Soares et al. 2003), the lamina cribrosa (Healey and Mitchell 2004; Morgan-Davies et al. 2004), and a grey area (Jonsson et al. 2005) on observation. Then there have been publications looking at other ocular correlates with the optic nerve head, such as eye colour (Budde et al. 1998). Further, there have been studies looking at the optic nerve head in relation to such factors as height (Jonas et al. 1998b) and the menstrual cycle in females (Akar et al. 2004).

While not the first observers to determine associations with specific glaucomatous optic nerve head sub-types, Nicolela and Drance (1996) looked at 1711 optic disc stereophotographs of patients with glaucoma, ocular hypertension, and patients suspected of having glaucoma, and identified 117 eyes which demonstrated 'pure' examples of four different optic disc appearances. These sub-types were described as focal ischaemic, myopic glaucomatous, senile sclerotic, and generalised enlargement, as compared with Spaeth (1.3.2). It is this classification of optic disc sub-types that is used on a regular basis at the present time. Having identified these patients with 'pure' optic nerve head (disc) appearance they then set about identifying associations. Table 1.1 summarises their findings. They pointed out that the vast majority of optic discs showed considerable damage or mixed features of sub-types.

Table 1.1: Summary of associations with different optic nerve head (disc) sub types (After Nicolela and Drance 1996)

	Age	Sex	Migraine	Systemic association	PPA	IOP mmHg	Haem	Visual fields
Focal ischemic	Older	women	2.5x more likely			Normal can be >21	++	Dense focal fovea threat
Myopic	Younger		Not associated			Normal can be >21	++	Dense focal fovea threat
Senile sclerotic	Older		Not associated	Heart disease/ Hypertension	yes	Normal can be >21	++	More localise than diffuse
Generalised enlargement	Younger		Not associated			High can be >30	+	diffuse

PPA= Peripapillary Atrophy, Haem = Haemorrhage

Classification of 'pure' optic nerve head appearances was only possible in 6.8% of cases in this study, with a similar result of 5.8% in a further paper (Broadway and Drance 1998). In order for a clinical classification to be useful there is a need for it to be reproducible and to cover a larger percentage of patients. Without a sizable proportion of patients seen in a glaucoma clinic being able to be classified, the possibility of obtaining a better understanding

of primary open angle glaucoma is limited. However, in a clinical situation where observers were forced to classify as many glaucomatous patients as possible into one of the four sub-types together, with the inclusion of two further groups, normal and miscellaneous (where the optic nerve head showed mixed sub-types or advanced glaucomatous change), this figure can be as high as 79.1% (Nicollela et al. 2001a). Further, in this study the reported prevalence of different appearances was given as 26.3% concentric enlargement of the cup enlargement and 18.1% focal loss. An important point also raised by this study is the fact that during a mean interval span of just over eight years, the classification of sub-type remained constant for the majority of patients. Unless the damage to the optic nerve progressed to such a point that the appearance became unclassifiable, the original pattern of damage remained despite a progression in the disease process.

Conversely, there have been a number of papers addressing the morphological appearance of the optic nerve head in specific types of glaucoma; for example, in primary open angle glaucoma (Broadway et al. 1999), in pigmentary glaucoma (Jonas et al. 1998a), and in juvenile-onset glaucoma (Jonas and Budde 2000).

1.4 Glaucoma as a cause of blindness

Primary Open Angled Glaucoma (POAG) is the second largest cause of blindness in Europe (Kocur and Resnikoff 2002), and accounts for 11.6% of people with visual impairment over the age of 75 years in the United Kingdom

(Evans et al. 2004). More recently, work by the RNIB in conjunction with Moorfields Eye Hospital puts the figure for registration due to glaucoma in the years 2009-2010 as 15% in England and Wales (Leamon 2012). It is not, however, clear what percentage of these registrations relate to over 75 year olds or to POAG alone. A population-based study in North London looking at serious eye disease and visual impairment (Reidy et al. 1998) estimated the prevalence of POAG to be 3%, with a further 7% of the population being described as glaucoma suspects. An important feature of this study was that the ratio of undetected to known cases was 3:1 for definite diagnosis of POAG and 5:1 for suspects, a total of 81% of persons not in touch with the eye care community. This figure may not be reflected around the country as socio-economic groups may vary in regions other than North London. It is commonly quoted that half the number of persons with glaucoma are unaware that they have the condition, something which is even higher in the developing world (Quigley 1996). It may be that, as there is no national screening service for glaucoma, these persons are not presenting to their optometrist for an eye examination, although it could be that while they may be presenting they are not being correctly identified by their ocular healthcare practitioner. In the Australian Visual Impairment Study (VIP), a large number of previously undiagnosed glaucoma cases were found (Weih et al. 2001; Wensor et al. 1998). It was found in this population that out of 78 patients with glaucoma who had been seen by an optometrist or an ophthalmologist in the preceding twelve months, 35 (45%) persons remained undiagnosed (Wong et al. 2004). This would raise concerns about the efficacy of case detection. While it was not specified if these patients were seen only within a primary care setting, it

would not be unreasonable to consider that patients attending secondary care facilities for ocular healthcare are also remaining undiagnosed as to their glaucomatous status.

Quigley (1996) estimated the number of people worldwide, with primary glaucoma to have reached 66.8 million by 2000, with 6.7 million suffering from bilateral blindness. This leads to a high global cost both in loss of personal quality of life (Nelson et al. 1999) and financially. In 1997 in the United States of America the costs were estimated to be \$400 million in direct health costs and \$1.3 billion in lost productivity (Fusun Cardakli 2005).

1.5 Identifying glaucoma in the traditional clinical setting

The advice given by the College of Optometrists relating to 'Examining the Patient at Risk from Primary Open Angle Glaucoma' (Optometrists 2005) states that it is good practice for practitioners to include in their examination an assessment of the optic nerve head and tonometry. They also state that an assessment of the central visual fields be undertaken using perimetry with threshold control. Hence these three tests form the mainstay of glaucoma detection in the traditional clinical setting both in the primary and secondary care environment.

Surprisingly, however, there have been limited studies on the discriminating power of these three tests to detect glaucoma especially when used in combination. One study, however, has looked at the sensitivity and specificity

of a range of glaucoma screening tests, both singly and in combination (Harper and Reeves 1999). Harper and Reeves (1999), found that the most significant discriminators of glaucoma were visual field screening, optic disc cupping, and intra ocular pressure in rank order. Further, when these three tests were combined they provided significantly greater discrimination than if used in isolation and in particular to provide high levels of sensitivity and specificity in excess of 0.90 a visual field screening test was essential.

1.5.1 Visual fields examination

Despite the recommendations of the College of Optometrists, which further suggest that where necessary practitioners should consider repeating visual fields assessment to obtain a meaningful result, the undertaking of visual fields both as a screening and monitoring tool is not without problems. These range from patient-related factors, such as poor patient performance and learning effect, through biological factors, such as the amount of nerve fibre damage required before a defect is detected and variability in the disease process, to equipment variables, such as artefacts, errors and noise relating both to hardware and software, and finally to practitioner-related, in the form of being able to analyse and determine appropriateness of diagnosis and the progression of disease.

It is generally held that, in order to detect a visual field defect, there is the need for 40% - 50% of the retinal nerve fibres to be lost (Quigley et al. 1982). Further, it may take a number of years in an eye susceptible to intraocular

pressure (IOP) to develop visual field defects. It has been estimated that this may be in the region of eight years by Goldmann and Gafner in the 1950s, although Speath has pointed out in a review of Viswanathan et al. 2003 that this process is highly variable and could take place in as little time as three to six months. Despite this, it was found in the Bristol Shared Care Glaucoma Study that, of the measurements of cup/disc ratio, IOP and visual fields made between practitioners in the community, Hospital Eye Service and the research team, visual field assessments were the most reliable (Spry et al. 1999). The assessment of visual field defect in this study was a simple one, based on the number of points missed out of the number presented.

However, even given the result in this study, the same group, when looking at Standard Automated Perimetry (SAP), have cautioned that in the clinical setting there is a lack of accuracy and differing precision within the examination (Spry et al. 2003). These authors found that thresholds can be over-estimated, resulting in an observer under-estimating the visual field loss.

One aspect of patient performance that has been recently addressed in some visual field equipment is that of patient fatigue, and it has become reasonably standard within the Hospital Eye Service for visual fields to be carried out using a Humphrey Field Analyser (Carl Zeiss Meditec, Dublin, CA, USA) employing what is known as the Swedish Interactive Thresholding Algorithm (SITA). It has been found that, when using this technique, the time required to carry out a threshold examination of a patients is, on average, reduced by 48.4% using a routinely employed testing protocol of SITA 24-2 when compared with the corresponding 24-2 full threshold test (Sharma et al. 2000).

This reduction in time taken to undertake a visual field assessment would only be of use if the accuracy of the examination remained high. It has been found that this is indeed the case, that both the 24-2 SITA standard and 24-2 SITA fast algorithms have excellent sensitivity and specificity for the detection of glaucomatous visual field loss (Budenz et al. 2002). Sensitivities of SITA standard and SITA fast in all cases of glaucoma were 98% and 95%, respectively, with specificity of both algorithms being 96%. It is also known that the interaction of the person carrying out the visual field examination with the patient can result in an improvement in the reliability of the examination. This interaction can be both in the form of the explanation given to the patient and in the reduction of the effects of fatigue that the patient may be experiencing. To this end it has been recently advocated that a standardised set of patient instructions in the form of a video can help to educate the patient as to what is required of him/herself (Sherafat et al. 2003). This simple aid resulted in an improvement in reliable visual field examinations of 14.5% when compared to a control group who were not given this education.

Despite any methods employed to improve the patient performance, ultimately the problem with visual field examination is the analysis of whether, in the first instance, a defect represents a genuine loss of retinal sensitivity due to a disease process, in this case glaucoma, and then whether during repeat visual fields there is genuine progression. The problem arises insofar that there are no widely accepted standards for defining progression (Kim et al. 2004). Indeed there are a number of different algorithms, for example, the Early Manifest Glaucoma Trial, the Advanced Glaucoma Intervention Study

and the Collaborative Initial Glaucoma Intervention Study. In a study of a number of algorithms it was found that even though they can help to identify change, there was no conclusion as to which was best at identifying true visual field change (Lee et al. 2002). Performance across these algorithms varied with the number of visual fields required to confirm change. Kim et al. (2004), found a modest change of Mean Defect (MD) of only 2dB, confirmed on a single retest six months later, indicated a true glaucoma progression. It is doubtful that this or any other guideline to the progression of visual fields is strictly adhered to in a busy clinical setting, although repeat visual fields are carried out as a matter of course by many differing professionals within glaucoma clinics.

1.5.2 Tonometry

There have been many methods employed for the measurement of intraocular pressure (IOP), some of which are little more than historical, such as the Schiottz tonometer. Others have gained widespread acceptance, such as the Goldmann, and modern non-contact tonometers, such as the Pulsair (Keeler, UK), through to the latest generation that have appeared, like the Pascal tonometer (Kaufmann et al. 2004), OBF tonometer (Morgan and Hosking 2001), the phosphene tonometer (Rietveld et al. 2005), wireless contact lens sensor (Leonardi et al. 2009), Diaton tonometer (Li et al. 2010), and the iCare tonometer (Muttuvelu et al. 2012). At present, all tonometry in the primary and secondary care environments is essentially carried out either with a contact or non-contact applanation tonometer.

The measurement of intraocular pressure is probably the commonest measure made by practitioners in the diagnosis and monitoring of glaucoma. While high IOP remains a risk factor for the development of glaucoma (Gordon et al. 2002), it must also be noted that there is no absolute value of IOP which, if a person has a value lower, they are safe from the development of the disease. Rather, it is the IOP at which any given optic nerve head is susceptible to damage that needs to be recognised.

The accepted value for the mean IOP in the population is around 16 mmHg with no evidence of an independent age effect on IOP (Rochtchina et al. 2002). This finding is in contradiction to other studies that find that there is an increasing level of IOP with age, as reported by (Colton and Ederer 1980), who also emphasise the point that in all the studies they reviewed there was almost universal agreement that distribution of IOPs follow a normal curve up until 21 mmHg pressure and thereafter there is a distinct right skewness. While age may not influence IOP in adults, this may not be the case in children where it has been suggested that, at least for Perkins applanation tonometry, the IOP may not equal that of an adult until 12 years of age (Jaafar and Kazi 1993).

There are, however, a number of sources of error in the recording of IOP in patients, some of these will be dependent on the type of tonometer used, while others will be general errors that could influence the measurement irrespective of the device used. These errors may derive from the instrumentation or from biological attributes of the patient being examined.

Even the technique at present considered to be the 'Gold Standard', that of Goldmann tonometry, is not without its problems. Indeed, in a major review of errors when using a Goldmann-type tonometer there were shown to be six main areas which could be sub-divided into forty-two possible sources of error (Whitacre and Stein 1993). Most recently there has been great debate regarding corneal thickness as a source of error following the publication of the Ocular Hypertension Treatment Study (OHTS) (Gordon et al. 2002), where it was found that corneal thickness was a powerful predictor for the development of Primary Open Angle Glaucoma. The OHTS shows that there are many patients being mis-classified as 'at risk' through erroneous IOP readings as a result of increased corneal thickness when their true reading is probably normal (Brandt 2004). Fundamentally, IOP measurements are subject to numerous errors, many of which may be being ignored by practitioners and it may be that for some glaucoma patients, suspects and indeed those patients who are classified as normal on a basic tonometric investigation, that without accurate procedure and the adjunct of corneal thickness measurement, the true nature of their IOP is being mis-classified.

1.5.3 Optic nerve head examination

1.5.3.1 Direct ophthalmoscopy

The direct ophthalmoscope still remains the instrument of choice in the examination of the internal eye for the majority of community based optometrists. It has been reported that the community optometric assessment of the optic nerve head is in general restricted to the measurement of cup-to-

disc ratio and cup depth (Theodossiades and Murdoch 2001a). This work demonstrated better interobserver agreement if there is intensive training on optic nerve head assessment given prior to the examination of patients. The authors concluded that interpretation of the optic nerve head was improved by a combination of training and the assessment of additional optic nerve head features. In this case the best interpretation came from the C/D ratio, the neural retinal rim colour and the cup shape. Amongst optometrists inter-observer agreement has been found to be best amongst those optometrists that have had residency training compared to those who are not residency trained or those trained in a commercial setting (Spalding et al. 2000).

It would appear that the best sensitivity and specificity in studies using stereophotographs of the optic nerve head or other imaging modalities comes from the combination of optic nerve head parameters. In order to look into how this translated into the clinical setting employing direct ophthalmoscopy, Harper and Reeves (2000) investigated the sensitivities and specificities of a number of optic nerve head parameters both in isolation and combination. They reported that the best parameter in isolation was the narrowest rim width (defined as the rim:disc diameter ratio at the narrowest point excluding the nasal quadrant). The best parameters in combinations were found to be the narrowest rim width and peripapillary atrophy. These two parameters afforded a sensitivity and specificity in screening for glaucoma of 81% and 90%, respectively.

In one study, using the Heidelberg Retinal Tomograph as a reference measure, it was found that the technique of direct ophthalmoscopy was inferior to that of non-contact binocular indirect ophthalmoscopy (ncBIO) (Watkins et al. 2003). They concluded that, in comparing the three examination modalities, direct ophthalmoscopy under-estimated the size of the vertical cup-disc ratio.

1.5.3.2 Indirect ophthalmoscopy

The question as to whether stereoscopic viewing is a more accurate method of examination over monoscopic viewing has been the subject of a number of papers and has been examined in a number of ways. Most make use of stereo photographs versus mono photographs taken either using a simultaneous captured stereo image (Parkin et al. 2001) or in sequentially captured stereo images (Hanson et al. 2001). Other studies have compared clinical stereo viewing by way of slit lamp non-contact indirect biomicroscopy (ncBIO) with monoscopic photographs (Hrynychak et al. 2003) or with modern imaging methods, such as the Heidelberg Retina Tomograph (HRT) (Watkins et al. 2003). Stereoscopic measurements have been found to be larger than monoscopic in some cases (Hanson et al. 2001; Hrynychak et al. 2003) and smaller in others (Parkin et al. 2001). While it is considered that ncBIO viewing is a superior technique (Watkins et al. 2003), a view that is commonly held by many glaucoma practitioners in the clinical setting, this has been questioned in one paper that found little difference in results between observers viewing monoscopic images compared with stereoscopic ones (Parkin et al. 2001).

1.5.4 Stereophotography

Despite the introduction of a number of new technologies in the field of optic nerve head imaging, the 'gold standard' still remains stereoscopic optic disc photography (Parkin et al. 2001). This view is supported by other studies (Correnti et al. 2003; Greaney et al. 2002; Mardin and Junemann 2001). In an analysis of (Correnti et al. 2003), Fellman gave his view as to why stereophotography has the best ability to distinguish normal from glaucomatous (Fellman 2004). He feels that this is because the experienced practitioner, in this case an ophthalmologist, remains the best 'computer system' for evaluating the optic nerve head. In the clinical setting an experienced practitioner will examine a combination of optic nerve head appearances such as rim configuration, pallor, disc size, tilt, peripapillary atrophy, vascular abnormality and the presence of disc haemorrhages alongside cup/disc ratio in making their diagnosis.

1.6 Modern tools to aid in glaucoma diagnosis

1.6.1 Confocal scanning laser ophthalmoscope cSLO

There have been a number of confocal scanning laser ophthalmoscopes (cSLO) available since the 1980s, including the TopconSS, Rodenstock SLO, Heidelberg Retina Tomograph (HRT), the Heidelberg Retina Tomograph 2, and the Heidelberg Retina Tomograph 3. Of these the HRT3 is the only commercial unit available at present. That said, there are still papers being

published looking at the agreement of HRT2 to HRT3 (Koh et al. 2012), and even HRT2 to the original model (Balasubramanian et al. 2011). This instrument has been designed for the purpose of glaucoma detection and is of a compact design with image acquisition being virtually automatic.

cSLO is a technique that employs a diode laser of wavelength 670 nm emitting and collecting thousands of individual monochromatic light pulses and creating a composite image over several milliseconds (Comer and Ciulla 2004). These pulses form an x – y sequential scan of the retinal surface at various focal planes. This is achieved by the confocal aperture, which is used to block reflected and scattered light from outside of the focal plane, being adjusted axially with the effect that the focal plane is adjusted at various depths within the retina. A three-dimensional image is built up from a series of focal planes. The number of planes in the HRT2 is variable at 16 focal planes per mm, depending on the depth of the scan. Scan depth can vary from 0.5 to 4.0mm, hence the number can range from 16 to 64 focal plane scans. The composite coronal scan contains 384 x 384 pixels (147,456 pixels in total) within a 15 degree field of view. Each of these pixels represents the retina height at the corresponding location.

HRT is said to provide the prospect of greater objectivity in the description of optic nerve head topography (Wollstein et al. 1998). Further, it has been shown that HRT is at least as sensitive as expert clinicians in the identification of early glaucomatous changes (Wollstein et al. 2000). Sensitivity and specificity in this study was found to be 84.3% and 96.3%, respectively (the

same values for expert clinicians in the study were 47.1% and 97.6%, with a rise in sensitivity for the best expert to 64.7%). However, more recent papers have reported much lower sensitivities, even as low as 35% (Ramdas et al. 2011). Specificities and sensitivities do vary depending on the analysis looked at, be it Moorfields Regression Analysis (MRA) or the Glaucoma Probability Score (GPS), and also whether you classify borderline results as either test negatives or positives (Jindal et al. 2010). It would appear that the more damaged the optic nerve head, the easier it is to detect early glaucoma. Thus, those optic nerve heads with abnormal global results are more easily distinguished from those with focal abnormalities. Sensitivity and specificity are optimised if the size of the optic nerve head is taken into account (Wollstein et al. 1998). It has also been reported that dilation improved image quality, particularly in patients with moderate lens opacities or miotic pupils (Zangwill et al. 1999). This may be important when evaluating optic nerve head changes over time as poor quality images, for any reason, can cause spurious changes in the computation of the topographical optic nerve head parameters (Zangwill et al. 1999).

1.6.2 Optical coherence tomography (OCT)

This is an optical technology that is analogous to B-scan ultrasonography, only using light instead of sound. The use of light results in high resolution imaging of the retinal structure. There are a number of variants of OCT which are, or have been, available clinically, these being the first generation OCT1 and OCT2, the OCT3, and the research-based titanium sapphire laser. The

instrumentation works by utilising the principal of low coherence interferometry (Grehn and Stamper 2004). Light is projected onto the retina from a superluminescent diode (Thomas and Duguid 2004). A low coherent incident light of 840nm is employed, which is split by a fibre optic Michaelson interferometer into two beams. One beam, the measurement beam, is directed into the patient's eye and is reflected from the interface between intraocular structures according to their thickness, distance and reflectivity (Grehn and Stamper 2004). This measurement beam is combined with the second beam, the reference beam, which has been directed towards a reference mirror at a known variable distance and has returned to the beam splitter, such that the single reference echo is combined with the complex measurement echo, producing optical interference that is then picked up by a photo-detector (Thomas and Duguid 2004). The photo-detector therefore measures the time delay of optical reflections from the intraocular structures.

The technique has a reported theoretical resolution of 14 micrometers in the axial (z) plane, with an x-y resolution of 25 micrometers (Chauhan and Marshall 1999). For the OCT1 and OCT2, the scan comprises of 100 aligned A-scans. In the case of the OCT3, this number is increased to 512 A-scans with an increase in the resolution to 10 micrometers (Sander et al. 2005). The scan length for the OCT2 is therefore optimal if it does not exceed 2mm, whereas the OCT3 can utilise a scan length of 6mm.

OCT is capable of several scan patterns and can scan the macula area, the peripapillary area, and the optic nerve head. There have been numerous

studies that have shown this technique to be capable of detecting glaucomatous change (Bowd et al. 2000; Guedes et al. 2003; Mistlberger et al. 1999; Pieroth et al. 1999). All three areas have been investigated in glaucoma, including the macular area, which has been found to undergo macular thickness changes that are well correlated in visual function and retinal nerve fibre layer structure in glaucoma (Greenfield et al. 2002). Retinal ganglion cells are lost in glaucoma and these cells may constitute 30-35% of the cells in the macula region (Medeiros et al. 2005). This approach would, however, be inappropriate in cases of age-related macula changes and in patients with diabetes. Indeed, despite evidence to suggest significant reduction in the macula thickness as a result of glaucoma, the most sensitive measures of glaucomatous damage have been reported with peripapillary and optic nerve head scans (Medeiros et al. 2005; Wollstein et al. 2005). Of the many reported parameters, it has been found that the best sensitivity, and specificity is given by the rim area and horizontal integrated rim width at 88.5% and 100% sensitivities at 95% and 80% specificity cut offs, respectively (Wollstein et al. 2005). A different method of examining the macular thickness looking at selective layer thickness rather than the total macula thickness is finding favour in a number of recent papers. These thickness scans focus on the Ganglion Cell Complex, defined as the combined thickness of the nerve fibre, ganglion cell and inner plexiform layers (Tan et al. 2009). The reported results suggest that this measure may be a useful tool for detection of early structural damage, including preperimetric cases of glaucoma (Arintawati et al. 2012; Moreno et al. 2011) and in the tracking of glaucoma progression (Tan et al. 2009).

1.6.3 Scanning laser polarimetry (SLP)

This is a technique which uses a diode laser with a wavelength of 780nm to create a polarised laser beam (Munkwitz et al. 2004). By detecting the change in the polarisation of the light, this technique provides a non-invasive, indirect measurement of the retinal nerve fibre layer thickness within the peripapillary area surrounding the optic nerve head. The phase shifting (retardation of light) or change in polarisation of light makes use of the birefringent nature of the retinal nerve fibre layer, with the amount of change being proportional to the amount of nerve fibre tissue present (Nicolela et al. 2001b).

Unfortunately, the retinal nerve fibre layer is not the only ocular structure that displays birefringence and this can lead to artefacts in the measurement. The accuracy of measurements using this technique is dependant on the ability to extract that retardance relating to the retinal nerve fibre layer from the total retardance of the optical system (Bagga et al. 2003). Corneal birefringence consists of two elements, its magnitude and its axis. SLP has a fixed corneal compensation based on the central cornea, but this varies with corneal position. To overcome this, variable corneal compensation, as opposed to fixed compensation, can be used and this has been found to correlate more closely with optical coherence tomography (Bagga et al. 2003). The effect of this important source of artefact is that as the axis of corneal birefringence moves away from that of the fixed compensator the magnitude of the retinal birefringence increases (Greenfield et al. 2002). The effect of this is to falsely

increase the normal measures of retinal nerve fibre thickness, resulting in a reduction of sensitivity and specificity for this technique (Bagga et al. 2003; Greenfield et al. 2002). The use of variable corneal compensation has been found to improve the discriminating power of this technique.

A further technique to neutralise the birefringence of the cornea without the use of a corneal polariser has been suggested by making use of macular birefringence. The macula 'bowtie' patterns can provide a means to quantify corneal birefringence. A drawback of this technique is that it is reliant on the subject having a normal macula histology and so, therefore, cannot be used in cases of macula pathology. A strength of this technique is that it is independent of any magnification effects due to ametropia and does not rely on a reference plane (Weinreb et al. 1998). The technique is, however, observer dependant given that there is a need to define an ellipse at the margin optic nerve head from which a second ellipse is automatically displayed with a given magnification factor of 1.75 disc diameters, from which 200 points are measured along the new ellipse to produce a TSINT graph (Munkwitz et al. 2004). It has been shown that the experience of the user is important (Nicolela et al. 2001b; Weinreb et al. 1998) and therefore there is a need for training to obtain optimised results, as is the need for guidelines in the interpretation of the printouts (Choplin and Lundy 2001).

The technique provides a number of parameters which can be used in analysis, including 'the Number', which is a value between 0 and 100. A higher value being more likely to indicate glaucoma. There seems to be

varying claims for the sensitivity and specificity of this technique (Grehn and Stamper 2004) and these will depend on the type of parameter being studied, the cut-off point used, the experience of the person interpreting the printout (Colen and Lemij 2003), and the severity of the glaucoma at presentation (Greenfield et al. 2002). This therefore leads to a difficulty in comparing papers.

1.6.4 StereoDx software

This software (a version of which will be further utilised in this study), makes use of digital stereoscopic images. These stereoscopic images may be captured as analogue images and digitised using a film scanner, or may be directly captured as a digital output. The digitised/digital images are then viewed using a Z screen (StereoGraphics Corporation, San Rafael, CA). The construction of the Z screen is a liquid crystal film within a glass plate that, when placed over a monitor screen and viewed using Polaroid spectacles, produces stereoscopic depth perception. This is because the polarisation state of the liquid crystal film is rapidly altered in phase with the refresh rate of the monitor, and the spectacles that the observer wears has lenses with polarisation axes such that alternate lines are seen by each eye. The refresh rate of the image exceeds the fusion frequency of the human eye, resulting in the perception of a single stereoscopic image (Sheen et al. 2004). The stereoscopic images are viewed in an “above and below” format with images displayed on alternate lines of a computer monitor (Morgan et al. 2005b).

In order to do this there is a need to compress each image of a stereo pair by 50% of its original height thus resulting in an image resolution reduction in the vertical axis while the horizontal resolution remains unaffected.

Stereoscopic viewing software developed by the School of Optometry and Vision Sciences, Cardiff University (Object Pascal, Delphi 4.0) includes algorithms to convert digital image dimensions into absolute retinal dimensions by use of keratometric, axial eye length and refractive details (Garway-Heath et al. 1998b; Rudnicka et al. 1998). Thus, the software can be used to evaluate the optic nerve head quantitatively. An observer, while viewing the image of an optic nerve head, can use cursors to outline the optic disc at the inner margin of Elschnig's canal and the optic cup. In addition to this, the depth of the cursor can be adjusted to correspond to the level of Elschnig's rim. Therefore, the measurements of the cup are taken from a standardised reference plane. The use of a reference plane is important as there is a need to define where the optic cup begins. Biomicroscopically, with the aid of stereoscopic imaging, the cup may be estimated to begin where there is the first discernable inflection of the surface contour. Clinical estimates of the Cup/Disc Ratio (CDR), at least for those below 0.70, have been shown to be made $\frac{1}{2}$ way down the slope of the neural retinal rim in comparison to scans using OCT (Hrynychak et al. 2004). In the clinical setting, even when viewing the optic nerve head stereoscopically, it can be difficult to make a judgement as to where the optic cup starts and it is sometimes required that other clues, such as the apparent deflection of smaller blood vessels and the use of a slit beam over the nerve head, be employed. Even

then, it may be impossible to be sure of where the cup starts. Only very occasionally can a clinician make use of a reference depth, such as the depth of Elschnig's canal, as an absolute reference plane, as opposed to a relative one, in a busy clinical setting when viewing a patient directly.

The stereoscopic viewing software then estimates the neural retinal rim width at 10 degree intervals around each optic disc – a total of 36 measurements being assessed from which a Cup/Disc Ratio (CDR) is calculated (Sheen et al. 2004).

In the clinical setting the advantage of this system is that the Polaroid spectacles are relatively cheap and robust, and the Z screen allows the simultaneous viewing by more than one observer. This is an essential prerequisite in case conferencing on suspect retinal appearance. It has also been shown that planimetry using this technique takes in the order of two minutes per eye. (Morgan et al. 2005b) drew a number of conclusions regarding the use of this technology in their study, which is the first report of its use in the digital analysis of the optic nerve head. These conclusions are:

- 1 Digital stereoscopic viewing, in isolation, can be used to diagnose glaucomatous optic neuropathy with a sensitivity and specificity that is similar to, or better than, that achieved with other digital imaging methods.

(Sensitivity of between 80.8% – 90.4% for individual subjective analysis, 69.2% - 80.8% for regression analysis of the neural retinal

rim, with corresponding specificities of between 79.6% - 94.4% and 83.3% - 90.7%, respectively).

- 2 The inclusion of quantitative analysis (linear regression based) did not, for the observers in this study, significantly improve the diagnostic precision of this technique for the detection of glaucomatous damage.

Table 1.2: Shows a summary comparison of the four imaging modalities described previously along with the comparison of direct ophthalmoscopy. The StereoDx method of digital stereoscopic analysis is highlighted.

Reference:	Modality	Sensitivity	Specificity
Harper and Reeves (2000)	Direct ophthalmoscopy	81%	90%
Wollstein et al. (2000)	HRT	84.3%	96.3%
Jindal et al. (2010)	HRT (MRA)*	30.6%	98%
	HRT (GPS)*	86.1%	73.5%
Wollstein et al. (2005)	OCT	88.5% 100%	95% 80%
Greaney et al. (2002)	SLP (FCC)**	89%	87%
Medeiros et al. (2003)	SLP (VCC)*	84%	92%
Morgan et al. (2005)	Digital stereoscopic analysis	80.8-90.4%	79.6-94.4%

* These values are when borderline results are included as test negatives

** FCC – fixed corneal compensation, VCC – variable corneal compensation

1.7 Screening vs. case detection

Ninety-six percent of glaucoma referrals are initiated by community optometrists (Bell and O'Brien 1997), with most optometrists considering that they screen for glaucoma. However, this is not true in that they are only involved in the case detection of a self-selected group of patients, namely those patients that choose to attend an optometric practice for an eye examination. Thus in the United Kingdom there is no formal screening programme for glaucoma. The World Health Organisation (WHO) has set a number of criteria to justify screening for a disease.

- 1 The disease must be an important health problem.
- 2 There must be a recognisable late or early stage during which the individuals with the disease can be identified before symptoms develop.
- 3 There must be an appropriate, acceptable and reasonably accurate screening test.
- 4 There must be an accepted and effective treatment for patients with the disease that must be more effective in preventing morbidity when initiated in the early, asymptomatic stage than when begun in the later, symptomatic stage.
- 5 The costs of case finding must be economically balanced in relation to possible expenditure on medical care as a whole.

Michelson and Groh (2001) suggest that these criteria are mainly fulfilled for glaucoma, with 1, 2, 4 and 5 met and 3 still in progress. Their approach for 3 was one utilising telemedicine and what they describe as multimodal examination by a technician (numerous tests employed in the data collection – various visual field tests, tonometry, various optic nerve imaging techniques and a short history) with data sent to a remote reading centre manned by a glaucoma expert. They concluded that this approach increased sensitivity and specificity and decreased the chance of false positive referrals. This German study is not the only reported study using telemedicine to aid in the diagnosis of glaucoma. The Rotterdam Eye Hospital has initiated and evaluated a shared-care tele-ophthalmology service (de Mul et al. 2004). This study was in conjunction with ten optometrists working in “retail optician stores”. Whether the results in this study could be applied to the United Kingdom is debatable, as the ‘gold standard’ in this study were technicians at Rotterdam Eye Hospital, whereas in studies related to aspects of shared care in the UK, the ‘gold standard’ has been optometry-led glaucoma teams or consultant ophthalmologists (Spry et al. 1999; Vernon and Ghosh 2001). In neither of the telemedicine studies was a general population screened. In the German example it was carried out at an industry exhibition, while the Dutch experience, presumably, was on a self-selecting group within the general population.

In the United Kingdom, the National Screening Committee considers chronic glaucoma as a candidate for formal screening (Department of Health 2004). However, although the Eye Care Services Steering Group recommend that

this is achievable in the short term it does not address how this would be realised. Given the figures quoted by this document it would once again appear that this is related to a self-selected group of patients and not the 16.4 million people in the UK population over the age of 50 years as quoted by this work. Using figures extrapolated from data from Nottingham and using a referral refinement system much like the Manchester (Henson et al. 2003) system, this would mean that there would be the need for 53 full time optometrists with a special interest in glaucoma to be trained throughout the country. If optometrists carried out only one session per week it would require 530 trained optometrists. Given that the population at risk is roughly ten times that of the estimated referrals to the Hospital Eye Service this would mean for all the population to be screened, by community optometrists, if that was indeed possible, there would be the need for over 5000 optometrists to do one session per week, this figure being close to the number of optometrists in community practice in the United Kingdom. Obviously, this is not a feasible option.

It is therefore reasonable to assume that, for the foreseeable future, optometrists will be involved in the case detection of glaucoma in a self-selected group of individuals. There has been much debate in the literature over the accuracy and quality of referrals by optometrists to the HES. In a study which looked at 704 referrals it was found that 40% of diagnoses were confirmed as glaucomatous, with a further 32% of patients requiring monitoring in the HES (Tuck and Crick 1991). In a later paper, that looked at the changing pattern of glaucoma patients by optometrists (Vernon 1998), the

author concluded that despite a greater degree of information relating to the optic nerve head appearance and a greater number of patients having a visual field examination, there was no improvement in the accuracy of referrals with regard to the true and false positive rates. Indeed, Vernon suggested that the College of Optometrist guidelines on screening for glaucoma released around that time were possibly to blame for the situation. It was previously shown by the same author that the use of routine field examination resulted in the discovery of ten visual field defects for every glaucoma field defect detected (Vernon et al. 1990). With this in mind, local protocols were developed for the referral of glaucoma suspects and this was reported on by the same author (Vernon and Ghosh 2001). It was somewhat surprising that this study reported that a referral protocol did not improve the diagnostic accuracy of optometrists with, in this instance, a greater degree of false positive referrals being made still on the grounds of visual field interpretation and optic nerve head examination.

Another study that, as part of an intervention trial, provided optometrists with standardised referral criteria, as well as advanced training in optic disc assessment, found that optometrists referred to the referral guidelines on an occasional basis only (Theodossiades et al. 2004). While the study was inconclusive, due to sample size problems, it did raise the point that as the positive predictive value (PPV) was unchanged (it would be expected that if the sensitivity of the optometrists assessments increased then the number of false positive referrals would also potentially increase), the impact in terms of the number of new cases of glaucoma detected by optometrist in the

community may be substantial. One further interesting point made by the authors was that, in the case of the intervention, optometrists informing their patients may have led to other patients who thought that they may have glaucoma presenting for an eye examination. This raises the possibility that the better the population's knowledge of glaucoma is, the more likely a person is to present for examination and from this, that a public health campaign could lead to that better understanding. To this end it has been found that through a public health campaign, utilising both newspaper and local radio, a significant impact was made on the number of people who had heard of glaucoma, but it was not clear how best to use local radio or indeed whether other forms of media would be better considered (Baker and Murdoch 2004).

Glaucoma is a major cause of visual impairment in the United Kingdom and worldwide. It is a disease of various presentations which at the present time is not amenable to mass population screening, so it is generally primary care optometrists who detect most cases on an opportunistic basis in the UK.

Modern technologies are available, but are still mostly used within secondary care, the Hospital Eye Service, which is increasingly being pressured locally and nationally due to an ever greater demand on its glaucoma services.

Despite this, it is still important that ocular healthcare professionals recognise glaucoma in whatever setting they practice, be it primary or secondary ocular healthcare, to limit the amount of impairment that occurs in essentially a treatable ocular condition.

Chapter 2 Consideration of the optic nerve head in glaucoma

2.1 The normal optic nerve head (ONH)

The ONH, or optic disc, is the surface manifestation of the retinal nerve fibres that leave the eye, as viewed clinically by means such as ophthalmoscopy or imaging. The appearance of the optic nerve head can change when observed in an individual depending on several factors, which include the method of viewing (Watkins et al. 2003), the increasing age of the subject (Tsai et al. 1992), observer experience (Spalding et al. 2000), and the presence of several pathological eye conditions.

Included in the pathological conditions is glaucoma, which can be classified as open or closed angle, as described in Chapter one, and as primary or secondary in presentation (1.3.1). The successful diagnosis of this condition is dependant on recognising several signs. However, in its most prevalent form, that of primary open angle glaucoma (Cassard et al. 2012), there are very few, if any, symptoms until late stage disease is achieved. Key to detection of glaucomatous optic neuropathy is an understanding by practitioners of the normal appearance of the optic nerve head (Sing et al. 2000).

The optic disc is that area of the retina that is contained within the structure known as Elschnig's canal, which is seen as a pale line adjacent and inside of which the neural retinal rim (NRR) is found. This area is made up of the

retinal ganglion cell axons and can be seen in many optic nerve heads ending centrally in what is described as the optic cup (see Figure 2.1). The dimensions of all these named regions can vary largely between individuals and even between the eyes of an individual leading to the term relative hypoplasia, which is said to occur in at least 10% of the population (Townsend and Comer 1987).

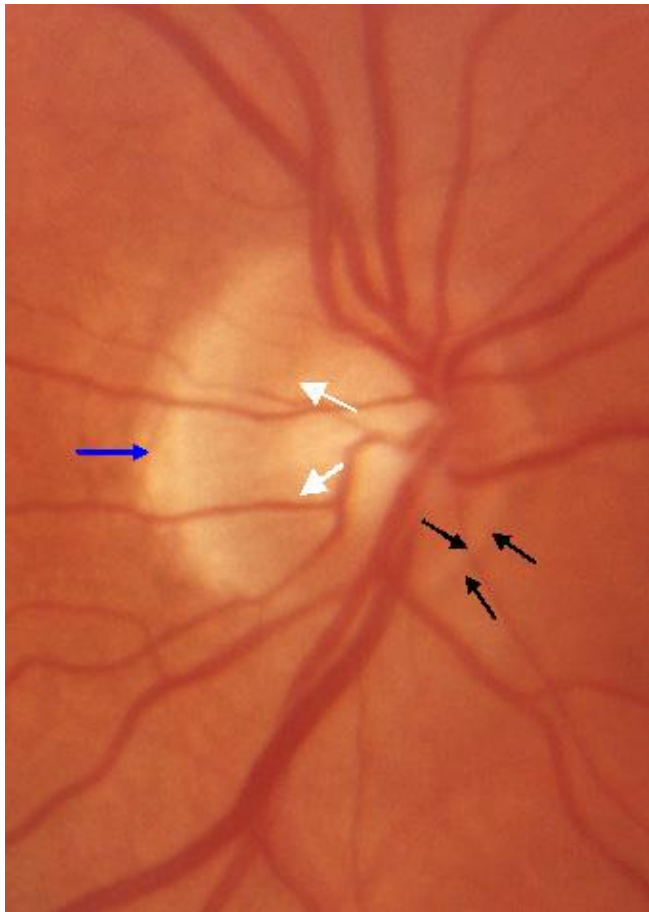


Figure 2.1. Optic Nerve Head showing several landmarks. The black arrows indicate the inner and outer limits of Elschnig's canal; white arrows indicate the optic cup rim or neural retinal rim; blue arrow indicates an area of peripapillary atrophy.

2.1.1 The normal optic disc diameter

The mean optic disc diameter has been found to lie between 1.47 to 1.89 mm, and to depend on the method used to measure the optic nerve and the population being measured (Jonas et al. 1988b; Mansour 1991; Sing et al. 2000). Its shape has been found to be a slight oval with the vertical axis being the longer one (Jonas et al. 1988b). These researchers found the mean vertical diameter to be $1.92 \pm 0.29\text{mm}$, approximately 7-10% larger than the horizontal diameter, and these measurements have been confirmed by similar results from other investigators (Rao et al. 2010). Jonas et al (1988) values lead to a mean optic disc area of $2.69 \pm 0.70\text{mm}^2$ with discs whose area being greater than $2.69 + 2\text{SDs}$, ie 4.09mm^2 , described as macrodiscs, and those being less than $2.69 - 2\text{SDs}$, ie 1.29mm^2 , as microdiscs.

2.1.2 The normal optic cup diameter

The shape of the optic cup has also been described as an oval, but with the horizontal axis being the larger one in greater than 93% of the population (Jonas et al. 1988b). What has been found is that there is correlation between the optic cup diameter and that of the optic disc, in that, generally, the larger the optic disc, the larger the optic cup, with the opposite being found for smaller optic discs, which tend to have smaller optic cups (Jonas et al. 1999). It has been suggested that the size of the cup is ultimately due to

axonal death leading to a space, which occurs in later embryological development to that which determines the size of the optic disc diameter (Sing et al. 2000).

2.1.3 Cup-to-disc ratio, neural retinal rim area and number of nerve fibres

The ratio between the diameter of the optic disc and the optic cup is known as the cup-to-disc ratio. As with the large variation in inter-individual optic disc size, there is also a high inter-individual variation in this ratio with a normal range from 0.0 – 0.9 (Jonas et al. 1988b). In the Blue Mountain study, undertaken on several thousand white patients in an Australian population, it was found that a disc diameter asymmetry of 1mm was accompanied by a 0.7 mm change in the same direction of the cup diameter (Ong et al. 1999).

Neural retinal rim is often quoted to be the most important optic nerve head parameter (Sing et al. 2000; Spaeth et al. 2006), and again this shows inter-individual variation to be positively correlated to optic disc area with larger optic discs having a larger rim area (Caprioli and Miller 1987), and with an increase in the size of the optic disc and the neural retinal rim area also thought to result from an increase in the total number of optic nerve fibres (Jonas et al. 1992). As there are several corresponding variations in measurements relating to the size of the optic disc diameter it is therefore important, in any evaluation of the optic nerve head, to take into account the size of the optic disc diameter, otherwise there is the possibility of falsely

diagnosing glaucoma in an individual with a large disc diameter and missing the diagnosis in one with a small disc diameter.

2.1.4 Shape of the neural retinal rim

In the vast majority of eyes with a vertical oval disc and a horizontally oval cup the neural retinal rim is said to follow a specific configuration known as the 'ISNT' rule, named after Jost Jonas (Jonas et al. 1988b), which is a simple mnemonic for remembering the order of thickness of the neural retinal rim. The broadest rim is to be found in the inferior location of the optic disc, followed by the superior aspect, the nasal aspect and then, finally, the thinnest normal portion of the neural retinal rim at the temporal location. This rule has been described to be largely independent of various optic nerve head parameters, such as disc size, cup size, C/D ratio and neuroretinal rim area, providing the disc itself is of a normal shape. However, it was found that in about 38% of normal eyes the inferior rim is not the thickest (Budde et al. 2000), so while an appearance which does not follow the ISNT rule should be considered suspicious of glaucomatous optic nerve head damage, it has to be viewed in relation to other test results.

2.1.5 Other variations in optic nerve head – race, gender, ametropia and aging

2.1.5.1 Race

Several studies have reported that there are differences in the presentation of the optic nerve head based on ethnicity, which confirms what has been observed in the clinical setting. Research centred on African-Americans comparing their optic nerve head appearance with that of white Americans (Chi et al. 1989; Varma et al. 1994), using older imaging technology, identified several differences in optic nerve head parameters with all being significantly larger in the African-American eye to the white American eye. These parameters were the optic disc area, cup area, cup volume and the Cup/Disc ratio. Studies using more modern technology, primarily Heidelberg Retinal Tomography (HRT) and Optical Coherence Tomography, also show differences (Girkin et al. 2011; Marsh et al. 2010; Seider et al. 2009).

Further studies have looked at other ethnic groups finding that, in addition to white Americans, those of Hispanic ethnicity also have smaller optic discs than African-American subjects, and that people of Asian and Oriental ethnicity have larger discs than both these groups, in addition to African-Americans (Mansour 1991). More recently, HRT studies, although confirming that white Americans have significantly smaller discs than other ethnic groups, did not find any difference between the disc size of African, Asian, Hispanic and Filipino Americans (Seider et al. 2009), and, although it would be expected that blacks had larger cup/disc area ratio than Europeans, this was not found to be the case using HRT (Krueger et al. 2009). However, using

OCT technology other researchers have reported racial differences, including cup-to-disc ratio (Knight et al. 2012).

2.1.5.2 Gender

The effect on the size of the optic disc due to gender is not clear with numerous studies reporting varying results, although most suggest that women have a slightly smaller optic disc than men (Varma et al. 1994). This reduction in disc size has been shown to occur in the horizontal meridian, along with a reduced disc area (Mansour 1991; Quigley et al. 1990). Whilst support for no difference between males and females is given by the fact that the optic nerve count was found not to vary (Jonas et al. 1992), a large population study, the Framington eye study of 2631 individuals, found that women have a significantly smaller mean cup-to-disc ratio both horizontally and vertically than men (Leibowitz et al. 1980).

2.1.5.3 Ametropia

A number of studies have reported either no relationship between refractive error and the appearance of the optic nerve head (Sing et al. 2000; Varma et al. 1994), or a weak relationship to disc area and neural retinal rim (Ramrattan et al. 1999), although this has been shown to only be true over a range of refractive errors from +4.00 dioptres to -8.00 dioptres (Jonas 2005b). Outside of these values the optic disc increases in size in myopia and decreases in size in hypermetropia. This work made use of morphometrically evaluated optic disc photographs, but was later confirmed using HRT technology (Leung

et al. 2007). In addition, an abnormal optic disc shape has been found to be significantly correlated with corneal astigmatism (Jonas et al. 1997).

2.1.5.4 Age

The eye is susceptible to various age-related disease processes, such as cataract formation and age-related macula degeneration, that can reduce the level of vision, along with other changes that have minimal effect on vision despite increasing years, for example various corneal dystrophies. It has, however, been found that advancing years have an effect on the number of nerve fibres in the optic nerve, with reported estimates of loss between 4000 to 5637 axons per year (Balazsi et al. 1984; Jonas et al. 1990b; Jonas et al. 1992). This value equates to approximately 55 000 nerve fibres per decade, which would result in a loss of approximately 30% of nerve fibres after six decades assuming a starting point of a mean number of 1,158,000 nerve fibres. This loss due to the aging process may account for a generalised enlargement of the cup-to-disc ratio without the presence of glaucoma, which is consistent with the reported reduction in the neural retinal rim area with age (Tsai et al. 1992)

2.1.6 Other reported associations in optic nerve head

Other associations have been reported such as birth weight, whereby children of low birth weight, short birth length and small head diameter have been found to have larger cup-to-disc ratios when compared with other children at aged 12 years (Samarawickrama et al. 2009).

Height, and Body Mass Index (BMI) have been shown to affect the neural retinal rim area and cup-to-disc ratio (Zheng et al. 2010), with the role of BMI perhaps serving as an indirect hint for an association between cerebrospinal fluid pressure and glaucoma (Xu et al. 2012).

It has been found that if the diastolic blood pressure is less than 90 mm Hg, resulting from anti-hypertensive treatment in patients without glaucoma, that this is associated with increased cupping and decreased neural retinal rim (Topouzis et al. 2006). This, the authors, feel should point to the role of blood pressure being investigated both as an independent factor and a contributing factor in glaucomatous optic nerve damage.

Conclusion

In conclusion, optic nerve head parameters, such as optic disc size, optic cup size, cup-to-disc ratio and neural retinal rim area, can vary for a number of reasons such that there is a large range of what can be considered normal, influenced by several factors which must be taken into account while accessing the optic nerve head for the presence of glaucomatous damage.

2.2 Glaucomatous appearance of the optic nerve head

The term 'glaucoma' is best considered as an 'umbrella' term to cover a diverse group of diseases that share several common characteristics, one of which is progressive damage to the optic nerve head. Ganglion cell damage occurs in glaucoma, along with their respective axons, which results in progressive and asymmetric changes in the optic cup (Pan and Varma 2011). This process leads to loss of ganglion cells and axons, which is reflected in the optic nerve head as thinning of the neural retinal rim. It has been proposed that this process begins as soon as axonal loss occurs (Quigley 1985) and is the basis for the suggestion that it may be possible to detect changes in the optic nerve before visual field abnormalities present, which has been reiterated by other workers (Weinreb and Khaw 2004). Therefore the recognition of the changes that can be seen at the optic nerve head are of fundamental importance in the early diagnosis and monitoring of glaucomatous optic neuropathy.

Recently there has been a proposal that a systemic approach should be adopted for examining all eyes for signs of glaucomatous damage (Susanna and Vessani 2007). Of the '5R' s, as this set of rules has been termed, three relate directly to the appearance of the optic nerve head and changes that can be seen to occur, one indirectly in terms of the retinal nerve fibre layer, and the final one is related to accurately identifying the limits of the optic disc and therefore its size (Fingeret et al. 2005).

2.2.1 Optic disc size

While it is known that the size of disc varies between races, it is not clear if the size of the disc in itself has any correlation with glaucoma. Indirectly, corneal centre thickness, a risk factor for glaucoma (Gordon et al. 2002), has been shown to be inversely correlated to the disc area (Pakravan et al. 2007). These researchers concluded that patients with thicker corneas may also indicate the presence of a substantially smaller and robust optic nerve head. Conversely thinner corneas may have a larger and deformable optic disc.

2.2.2 Cup-to-disc ratio, neural retinal rim size

Thinning of the neural retinal rim occurs in all sectors of the optic nerve head, but preferential loss in certain sectors can lead to characteristic optic nerve head appearances dependant on the type of glaucoma that an individual has (1.3.2). These various characteristic patterns of neural retinal rim loss, leading to different appearances of the optic nerve head (Broadway et al. 1999; Spaeth et al. 1976), will result in a change in the cup-to-disc ratio, with the preferences depending on the stage of disease (Jonas et al. 1999). For example, in advanced disease in a Japanese population this was found to be generalised enlargement in primary open angle glaucoma and myopic glaucomatous in normal tension glaucoma (Nakazawa et al. 2010), while other researchers, comparing Japanese patients with Normal Tension glaucoma presenting with disc haemorrhages to those who did not, found

localised damage to the neural retinal rim (focal notching) in the infero-temporal sector in the former eyes (Liou et al. 2001). This report does not give details of how advanced the normal tension glaucoma was, but the researchers do point out that it is not clear why some patients have diffuse loss of nerve fibres when others have a focal loss or, indeed, a combination of both.

The following sequence of neural retinal rim thinning with progressive disease has been described infero-temporal, supero-temporal both leading to an enlargement of the optic cup in the vertical direction. The temporal rim is the next to preferentially affected, with the nasal section being the last (Pan and Varma 2011).

Saucerisation of the neural retinal rim has also been described, which is where the rim becomes shallowly sloped, and cupping occurs, which extends to the optic disc margins and has been suggested as an early sign of glaucomatous damage (Phillips et al. 1993) and one that can be seen to reverse in patients that undergo filtration surgery at an early stage in glaucoma (Pederson and Herschler 1982).

Classically it has been taught that a C/D ratio of 0.50 or greater in an eye, or a difference between an individuals two eyes of 0.20 or more, is suspicious of glaucoma (Dielemans et al. 1994). It has been shown that cut-off values such as these for cup-to-disc ratio, in isolation, is not a good indicator of the presence or absence of glaucoma, but that this can be improved relatively

simply by taking into account the size of the optic disc (Crowston et al. 2004). It is, however, well documented that there is a change in the cup-to-disc ratio with progressive disease.

2.2.3 Peripapillary chorioretinal atrophy (PPA)

This lies outside of the disc rim, or Elschnig's canal, and is caused by thinning and degeneration of the chorioretina. There is a long history of association of PPA and glaucoma dating back to Elschnig and Bucklers in the first two decades of the 20th Century (Jonas 2005a) . PPA can be divided into two distinct zones known as alpha and beta zones (Jonas et al. 1989a).

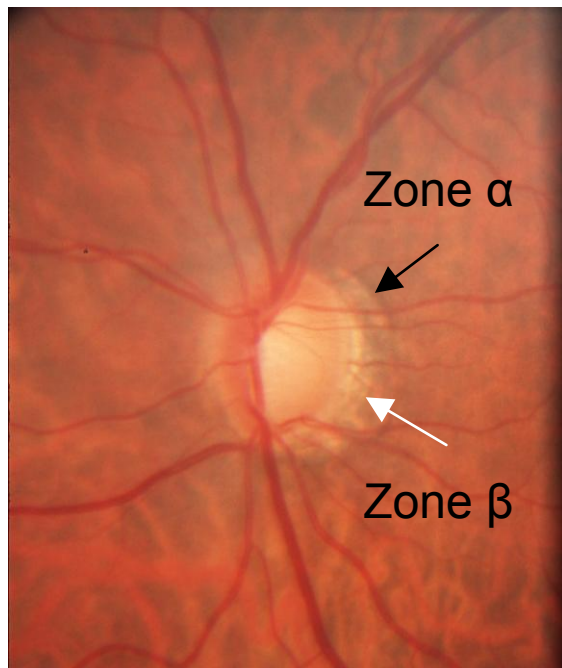


Figure 2.2 Optic nerve head image illustrating zones alpha (α) and zone beta (β) PPA

Zone alpha is the region that is found most peripheral to the disc margin (see Figure 2.2) and is a region of irregular hypo- and hyper-pigmentation of the

retinal pigment epithelium, which in the past has led to the suggestion that there is choroidal thinning occurring, although this has not been confirmed by OCT studies in eyes with PPA (Ehrlich et al. 2011). Zone alpha can be found in normal eyes, as well as eyes with glaucoma (Susanna and Vessani 2007). The area known as beta zone is described as marked atrophy of the retinal pigment epithelium and choriocapillaris allowing visualisation of the larger choroidal vessels and sclera (Jonas 2005a). Recent OCT studies show that there is complete loss of retinal pigment epithelium, along with the photoreceptors which was the most common OCT finding in patients with glaucoma (Manjunath et al. 2011). Na et al. (2010) concluded the same with regards to the photoreceptors, but did not find the RPE/ Bruchs level absent in over 60% of a small number of cases examined. The Beta zone is said to be more common in eyes with glaucomatous optic neuropathy than in normal eyes, and its appearance is also said to be dependant on the type of glaucoma that a patient may have, being significantly larger in eyes with myopic POAG than age-related POAG, and in turn than eyes with secondary glaucomas, with the smallest zones being detected in juvenile glaucoma (Jonas 2005a). PPA in eyes with focal ischaemic changes of the optic nerve head have shown equivocal results. The area of PPA has been shown by various researchers to increase with the progression of glaucoma (Kwon et al. 2003; Uchida et al. 1998), which is in contrast to the lack of progression of PPA seen in other non-glaucomatous conditions causing optic nerve damage (Hayreh and Jonas 2001; Rath et al. 2003). It has been suggested that with very small discs, PPA may indicate glaucomatous neuropathy more so than changes in the cup-to-disc ratio (Jonas et al. 1990a), but despite this and

other associations found to date, Jonas (2005a) states that it remains a second-order variable in the ranking of optic nerve head variables in the detection of glaucomatous optic nerve damage. In patients with glaucomatous visual field loss it has been shown that the presence of beta zone PPA gives rise to greater progression than in patients who do not show this sign, and so it has been suggested that this sub-group of patients should be kept under closer clinical surveillance (Teng et al. 2010).

2.2.4 Optic disc haemorrhage

The presence of optic disc haemorrhages was first described in the late 1880s by Bjerum and is now considered to be indicative of progression if detected in patients with glaucoma. They normally have a feathery appearance, due to alignment of nerve fibre layer in which they lie, and can be seen on the retina adjacent to the optic nerve head or bisecting the retina and the optic disc margin. They can also be found at the level of the lamina cribrosa, but in this position they have a rounded appearance (Susanna and Vessani 2007).

They commonly occur in the infero- and supero-temporal areas (Jonas and Xu 1994), with those occurring in normal tension glaucoma being found temporally and bilaterally (Hendrickx et al. 1994). Usually they are less commonly found in advanced glaucoma, especially where there is no neural retinal rim visible (Jonas and Xu 1994), generally occurring in early to moderate stages, which appears to be supported by the fact that up to half the disc haemorrhages seen occur within the first year, with very few being detected after 5 years (Healey 2011).

Quoted incidence rates of optic disc haemorrhages vary depending on the type of glaucoma being investigated, with the highest being in normal tension glaucoma (11% to 42%) and in primary open angle glaucoma (2% to 37%) (Sonnsjo et al. 2002; Uhler and Piltz-Seymour 2008), in contrast to normal individuals with a prevalence of up to 0.40%, and in cases of ocular hypertension where it extends from the upper end of normal to 10% of individuals. The reason for these variations may be put down to the method of examining for disc haemorrhages and the transient nature of disc haemorrhages. Optic disc haemorrhages resolve in a wide time frame from weeks to several months, but most disappear in about 2 months (Kitazawa et al. 1986). They may also be missed due to the subtle nature of many haemorrhages. Budenz et al. (2006) found that stereo-disc photographs, taken at a frequency of between 6 to 12 month intervals, allowed for better detection than clinical examination with only 15% of disc haemorrhages being recognised by both stereo-disc photographs and clinical examination, whereas Suh and Park (2011) found a better agreement of 61% detected by both stereo-disc photography and clinical examination. The authors concluded that their population, being glaucomatous patients rather than ocular hypertensive patients, along with more frequent follow-up (three monthly compared with six), may have led to the better agreement. Healey (2011) suggests that more frequent examinations may detect more disc haemorrhages. However, this may not be feasible in busy hospital departments, although the move towards virtual clinics, if used with stereo-disc photographs, may possibly improve the detection rate. Another method that may improve detection rates is the use of the direct ophthalmoscope that

has fallen out of favour in hospital-based clinics with the advent of non-contact binocular indirect ophthalmoscopic (ncBIO) lenses. However, due to the reduction in magnification of these ncBIO, disc haemorrhages can be missed, being confused with blood vessels at the disc margin.

The question as to which comes first, disc haemorrhage or optic nerve damage, is not one that is clearly understood at the present moment in time. There are two possible theories. One is that vascular damage proceeds structural damage to the optic nerve head. As a measure of progression in glaucoma or transition from ocular hypertensive state to early glaucoma optic neuropathy, haemorrhages have been found to precede visual field changes by a mean of 16.8 +/- 2.0 months and optic nerve head changes by 23.8 +/- 2.9 months (Siegnier and Netland 1996). The second theory is that it is a result of preceding mechanical damage, which is supported by Law et al. (2001) in a study that lists several optic nerve head characteristics that precede optic disc haemorrhages. These were found to be focal rim notch, thin sloping rim, peripapillary atrophy and superior- inferior asymmetry in 36%, 42%, 79% and 73% of cases, respectively. In the case of focal rim notching, all subsequent haemorrhages were identified at or adjacent to notches, It has also been found that an increase in frequency of optic disc haemorrhages is linked to an increase in the rate of nerve fibre layer defect enlargements and the progression of visual field loss (Nitta et al. 2011).

These points, along with the examination of the Retinal Nerve Fibre Layer (RNFL), make up the FORGE protocol, which consists of five rules to evaluate the optic disc and RNFL for glaucoma (Fingeret et al. 2005).

2.3 Classification, staging, scoring systems

The use of classification, scoring or staging systems is prevalent throughout all walks of life and in all fields of medicine, ophthalmology not being alone. Examples of such systems used in ophthalmology and optometry are dry eye (Bron et al. 2003; Meadows et al. 2012), contact lens complications (Efron 1998; Efron et al. 2011), cataract (Sparrow et al. 2000), scleritis (Sen et al. 2011), papilloedema (Scott et al. 2010) and, of course, glaucoma.

The main areas of grading or staging within the field of glaucoma relate to visual field correlation with glaucomatous eye disease (Susanna and Vessani 2009), and the appearance of the glaucomatous optic neuropathy as seen by the appearance of optic nerve head changes seen in glaucoma (Spaeth et al. 2006). To date there have been 9 different methods expounded in an attempt to grade or stage optic nerve head damage (Brusini et al., 2009; Spaeth et al. 2006), but it is the earliest method, described by Armaly of the cup-to-disc (C/D) ratio (Armaly 1969), that has been universally adopted and remains most used in the United Kingdom, despite many researchers describing failings in this method (Lichter 1976; Spaeth et al. 2006). With the advent of newer imaging modalities, such as the Heidelberg Retina Tomograph (HRT), Scanning Laser Polarimetry SLO, and Optical Coherence Tomography (OCT),

there are newer methods attempting to grade damage (Vessani et al. 2009) and, indeed, with techniques being developed to try and establish the presence of glaucoma in pre-perimetric cases utilising RNFL thickness (Cvenkel and Kontestabile 2011; Nakatani et al. 2011) and, more recently, the thickness of inner retinal layers including the RNFL, GC L and inner plexiform layers, in what is known as the Ganglion Cell Complex (Takagi et al. 2012).

2.3.1 Considerations for a grading system, the use of scale and measurement variability

The purposes of a staging system has been described as firstly to categorise patients into clinical meaningful groups, for example no disease, early or late disease, and secondly to describe the rate of change or progression of disease (Spaeth et al. 2006). Other authors (Henderer et al. 2009; Susanna and Vessani 2007) have stated that the use of staging systems in glaucoma also promotes the careful assessment and documentation of clinical damage thus facilitating the second aspect. Further, staging systems provide a method for communicating, between professionals, an indication of the health of the optic nerve head. In order to achieve these aims, in a consequential way, consideration needs to be given to the scaling of any given system.

Notice must be taken of the difficulties that arise in the division of a continuous scale into categories that are determined subjectively or that are not perfectly consistent (Bailey et al. 1991). Although large intervals between steps are easier to apply and remember in the clinical situation, a staging or grading system employing such an approach will lack the ability to detect

small intervals of change. On the other hand, a system that employs a large number of steps may be difficult to remember and apply in the clinical setting, and may be complicated by the fact that test variability may be larger than individual steps, thus leading to uncertainty as to whether true change is occurring at any given measurement episode (Spaeth et al. 2006).

Practitioner-based methods of staging the optic nerve head vary in the number of steps from 5 to 10, while instrument-based systems give continuous readings.

2.3.2 Staging systems for glaucomatous optic nerve head damage

As stated (in 2.3), there have been nine attempts to produce a method that could describe the amount of glaucomatous damage occurring at the optic nerve head over the last 50 years, if simple drawing methods are ignored as these pre-date staging systems by almost another 50 years (Pickard 1923). Many of these methods are now obscure and in foreign language papers with their only descriptions being found in a review by Spaeth et al. (2006). These can be divided into five groups depending on the method used to determine the level of glaucomatous damage. These method groups are as follows:

Cup Size methods

Rim Width methods

Probability methods

Merged disc staging/imaging methods

Cup excavation methods

2.3.2.1 Cup size methods

2.3.2.1.1 Armaly's system

This has been considered the first workable system to quantify disc damage (Spaeth et al. 2006) and was first described in 1969 (Armaly 1969). This simple method requires an observer to compare the diameter of the optic cup with that of the optic disc and is easily carried out in horizontal, vertical or any oblique axis, although it has been found that in glaucoma detection the vertical measure is more sensitive to damage than any other axis (Jonas et al. 2000). This method has gained widespread popularity becoming a clinical standard worldwide.

The vertical and horizontal Cup-to-disc or C/D ratio has been adopted in numerous studies relating to glaucoma (Feuer et al. 2002; Musch et al. 1999), and significance has been placed on values of C/D ratios in studies such as Collaborative Initial Treatment of Glaucoma Study (Feiner and Piltz-Seymour 2003), where a diagnosis of glaucoma was made on the basis of a large C/D ratio combined with an elevated IOP. It was generally quoted that a vertical C/D ratio over 0.3 is suspicious of glaucoma and that over 0.6 is glaucomatous. However, despite the obvious increase in C/D ratio in patients with glaucomatous optic nerve head damage, the range of ratios in the normal population is so large and the presence or absence of a large cup, per se, does not itself indicate that a patient has, or has not, got glaucoma. It has been found that optic disc size varies in the population (Ramrattan et al. 1999)

and by race (2.1.5.1), and with it the size of the optic disc cup (Healey et al. 1997). To this end, knowledge of the size of the optic disc has been used in conjunction with the C/D ratio to obtain a greater sensitivity in the recognition of glaucomatous optic nerve damage (Garway-Heath et al. 1998a), and various methods of measuring the optic disc size have been described (Haustein et al. 2009; Jonas and Papastathopoulos 1995; Spencer and Vernon 1996). Spaeth considers this to be one of two 'critically serious shortcomings with the cup-to-disc ratio system' (Spaeth et al. 2006), the other being that it is based on the assumption that the cup starts in a central location of the disc and enlarges concentrically, even though it has been shown that the optic cup tends to enlarge along the vertical meridian (Pederson and Anderson 1980).

2.3.2.1.2 Richardson's system

Described nine years after Armaly's method, this is a four-point staging system with stage one being sub-divided into two intervals. It is partially based on the cup-to-disc system, but with reference to visual field measurements and characteristics related to the optic disc rim and systemic status, such as vascular disease (Spaeth et al. 2006). This system is weighted towards early stages of glaucoma and, as with many systems, does not make any correction for the disc size. Also, in common with other systems by Jonas (Jonas et al. 1988a), Nesterov (Nesterov and Listopadova 1981) and Shiose (Shiose 1975), the number of intervals is too small to provide adequate sensitivity (Spaeth et al. 2006).

2.3.2.1.3 Nesterov's system

This is a complex five-point staging system which takes into account different types of optic disc cupping, such as concentric and focal rim loss, combined with characteristics of depth and maximal size of the cup-to-disc ratio found in any meridian (Spaeth et al. 2006). Unlike Richardson's system, it is weighted towards late disc changes and, again, does not correct for disc size, in addition to its complex nature, although Spaeth et al. (2006) considered that this system was a major advancement in that it considered the complete circumferential extent of the neuroretinal rim.

2.3.2.2 Rim methods

2.3.2.2.1 Read-Spaeth System

The authors proposed the concept of measuring the rim width by introducing a six-point staging system based, in the most part, on the cup-to-disc ratiosystem. Read and Spaeth's conclusions were based on the prospective study of discs, and visual fields, in 460 eyes where they noted that, 'cupping' of the optic disc occurred prior to visual field changes. Further, they noted that the onset of visual field loss was related to the remaining neural retinal rim width. Hence, this staging system, correlated disc changes with visual field changes, and divided the six stages into three distinct periods of change. The initial period, when disc changes were more pronounced than visual field changes. The second period, when visual field changes were more

perceptible than disc changes, and the final period, when it was difficult to distinguish both visual field and disc changes. However, this system was never tested and, like Armaly's system, it did not take into account the size of the optic disc (Spaeth et al. 2006).

2.3.2.2.2 Shiose's system

This is a quantitative disc pattern for staging the amount of disc damage, that describes three different patterns of damage, each of which is divided into a five-point staging system (Spaeth et al. 2006). Like Armaly's system it does not take into account the size of the optic disc and suffers, like many other systems, in having too few points, which in this case does not allow for the detection of early change (Spaeth et al. 2006). One further problem with this system is the inability to distinguish the type of damage pattern when trying to distinguish between different types of glaucomatous disc patterns, since the vast majority of discs have features of more than one pattern (Broadway et al. 1999).

2.3.2.2.3 Jonas's system

This is a five-point staging system making use of the radius of the disc rather than the diameter of the optic nerve which, therefore, means that the rim to disk ratio will vary dependant on whether you are looking in the vertical meridian or the horizontal meridian (Spaeth et al. 2006). The stages relate to the presence of notching and temporal rim loss, so a concentrically

progressing optic cup would remain at stage 1 until it reached stage 5, which would be advanced glaucomatous damage with no detectable rim remaining, thus the system is biased towards advanced stages of glaucoma (Spaeth et al. 2006).

2.3.2.2.4 Disc Damage Likelihood Scale (DDLs)

Presently this system is a ten-point staging system (Spaeth et al. 2002) having evolved from earlier versions of a five-point staging system (Spaeth et al. 2006). This system is based on the narrowest width of the neuroretinal rim at any location on the optic disc or, in the case where there is no rim present, the circumferential extent of rim loss. It is a ratio measurement, comparing the radial width of the neural retinal rim to the optic disc in the same axis, and, further relates to the measured size of the optic disc.

When considering an average sized disc, 1.5 to 2.0mm in diameter, stages 1 to 5 represent increasing reduction in rim to disc ratio. Stage 1, is where the ration is 0.4 or more in its narrowest position, stage 2, 0.3 to 0.39, stage 3, 0.2 to 0.29, stage 4, 0.1 to 0.19 and stage 5, less than 0.1 but more than 0 in its narrowest position. Stages 6 to 10 represent increasing degrees of no rim Stage 6, less than 45° of rim absence, stage 7, 46° to 90°, stage 8, 91° to 180°, stage 9, 181° to 270°, and finally stage 10, more than 270° of rim absence. In the case of a small disc (diameter less than 1.5mm) the stage is increase by 1; for large discs (diameter greater than 2.00 mm) it is decreased by 1.

The methodology is designed to record the rim as narrow as possible therefore estimating the cup as large as possible. The staging of these measurements is as stated, then relative to the size of the optic disc that is measured, for example a narrowest rim value of 0.15 will have a stage value of either 5, 4, or 3 if the disc is measured as small, normal, or large, respectively. The stages are grouped as follows: 1 and 2 indicate little likelihood of glaucomatous damage, whereas 9 and 10 indicate advanced glaucomatous disease. The above example indicates that if the disc is measured as small, having a narrowest rim of 0.15 would indicate glaucomatous damage, whereas for normal and large discs, while the disc could be at risk, there is less chance of it being glaucomatous on this measure alone. This staging system has been designed to overcome the limitations of the cup-to-disc ratio system of Armaly and as such has been described as having greater inter- and intra-observer reproducibility (Spaeth et al. 2002). This staging system has also been found to show significant correlation with visual field, HRT and OCT measurements (Abdul Majid et al. 2010; Bayer et al. 2002; Danesh-Meyer et al. 2006; Hornova et al. 2008). The same authors further rated the predictive power of the DDLS to be greater than the cup-to-disc ratio and HRT (Danesh-Meyer et al. 2006). In addition, the DDLS staging system was found to give greater sensitivity and specificity for the detection of progressive glaucomatous damage over time than the cup-to-disc ratio (Henderer et al. 2009).

Despite the suggested improvements over Armaly's method, and it being useful for diagnosis, grouping of severity, monitoring change and determining

rate of change (Spaeth et al. 2006), it is a staging system that has not yet found common use, although it has been incorporated into the reporting system following optic disc analysis in the Kowa non myd WX 3D simultaneous stereo-disc camera (Kowa-Optimed Europe Limited).

2.3.2.2.5 Optic Disc Damage Staging System (ODDSS)

This is the latest system for assessing the optic nerve for glaucomatous damage and was first reported in 2010 (Brusini et al. 2009). The authors state that the DDLS is time-consuming and too complex to use in an everyday clinical setting, but the ODDSS, in addition to the measurement of the size of the optic disc and the assessment of the neuroretinal rim by a six-point staging (described as NR Rim Damage Severity), has a further-four point NR Rim Damage Localisation Assessment. This leads to a three digit alphanumeric code description of an optic disc - for example M4c which describes an optic disc of medium size with complete loss of neuroretinal rim superiorly. One advantage over the DDLS that this system has is in addressing when there is progressive, but unequal, rim loss in both the superior and inferior areas of the optic disc. This would be graded as 'd', whereas, in the DDLS system, progression would not be recorded as an increase in stage until the progressive loss was greater than the initial loss, although it would be obvious clinically that the disc was progressing. The simple exponent of recording stages in quadrants of the optic nerve head would overcome this criticism of the DDLS system as reported by Danesh-Meyer et al. (2006). The ODDSS has been reported to show good sensitivity

and specificity, with fair to good inter- and intra-observer agreement (Brusini et al. 2009).

2.3.2.3 Probability method

Several imaging techniques have been applied in the field of glaucoma, the most notable being the Heidelberg Retina Tomograph (HRT) and the Optical Coherence Tomography (OCT), both of which can provide quantitative estimates of various aspects of the optic disc, such as size, rim area, etc. It has been suggested that these are not true staging systems, but that the measures amount to a probability scale giving the observer the likelihood of the optic nerve being normal or abnormal (Spaeth et al. 2006). This information is often presented in the form of 'traffic lights', with red, amber and green giving an indication of whether there is abnormality or not. This system of presentation has been challenged by some (Chong and Lee 2012), who were concerned that the analysis of instruments such as the HRT and OCT do not, in themselves provide a diagnosis, and there is a danger if practitioners do not view these results without consideration of the clinical presentation.

2.3.2.4 Merged disc staging/imaging methods

In 2003 a paper was published the purpose of which was to correlate 5 phases of optic nerve damage staging, assessed using HRT, with 5 stages of visual field, assessed using conventional automated perimetry, and classified by the authors as Glaucoma Staging System (Sampaolesi et al. 2003). More

recently, the inclusion of the Disc Damage Likelihood Scale (DDLS) in the analysis programme of the Kowa WX3D camera (2.3.2.2.4) is an example of how a staging system can be combined with an imaging system. The camera analysis is such that it can detect the optic disc rim and neural retinal rim automatically and is subject to editing at the discretion of the user, or alternatively the user can manually set both the optic disc rim and cup rim prior to the analysis being undertaken. This is then reported using DDLS stages as a measure of optic nerve head health. Unlike, for example the Heidelberg Retina Tomograph or the Topcon 2000 3D Optical Coherence Tomographer, which only allows the user to set the optic disc rim with the detection of the neural retinal rim being automated by the equipment itself, this system gives control over both these landmarks.

2.3.2.5 Cup excavation methods

In Spaeth's review specific mention is made of two researchers, Meyer and Marinchev. Meyer, in 1970, proposed a system for documenting the appearance of optic nerve excavation based mainly on diagrams, but without any reference to progression of glaucomatous optic neuropathy (Spaeth et al. 2006). This could therefore be considered less useful than Pickard's method of recording optic disc changes in glaucoma from some 50 years earlier (Pickard 1923). Marinchev is reported as having published a similar method of determining the size of optic nerve excavation based on a schematic chart in 1981 (Spaeth et al. 2006).

2.4 The importance of the cup-to-disc ratio measurement

This main section of this study is designed to look at the ability of naïve observers to determine the two optic nerve head parameters that make up the cup-to-disc ratio, specifically correct identification of the optic disc and the optic cup limits, both with and without a formal teaching session by an expert in optic nerve head evaluation. No attempt was made in this study to assess the ability of observers to make a determination of whether the optic nerve heads they were asked to outline had small, normal or large optic disc diameters. Neither were they asked to point out other 'softer' disc variables that could have been used to determine whether the optic nerve head they were looking at was normal, suspicious of glaucoma or showed glaucomatous optic neuropathy. The validity of determining the cup-to-disc ratio has been confirmed in a recent study that describes the use of the cup-to-disc ratio as having a 'renaissance' in the clinical determination of glaucoma, providing the dependence of this value on the optic disc diameter is taken into account (Jonas et al. 2000). This study confirms an earlier one which found that the vertical cup-to-disc ratio with regard to the optic disc size is useful clinically in the detection of glaucoma, especially in the case of small optic disc diameters (Garway-Heath et al. 1998a).

Jonas et al found that the vertical cup-to-disc ratio was the best at distinguishing normal individuals from those with ocular hypertension, and that other values, such as the total neural retinal rim and the retinal rim area to disc ratio, when corrected for optic disc size, were also of benefit (Jonas et al.

2000). The importance of the vertical cup-to-disc ratio is that, with the use of the slit lamp and non-contact binocular indirect lenses (ncBIO) found in every Hospital Eye Service clinic, the optic disc diameter can be easily measured, thus improving the diagnostic accuracy of the examination of the optic nerve head in glaucoma clinics (Haustein et al. 2009; Lim et al. 1996; Papastathopoulos and Jonas 1997). The other measurements need the intervention of imaging techniques and varying degrees of time-consuming analysis ranging from tracing and measuring areas from optic nerve head photographs, providing information regarding the magnification factor of the fundus camera and the optical properties of the eye imaged are known, through the semi-automated analysis of the HRT, which requires an observer to outline the optic disc, to the introduction of automated optic disc topography with many of the new generation of OCT instruments. With the availability of such modern imaging technology this tomographic analysis of an optic disc can take place in approximately 60 seconds (Topcon 2000 3D OCT, for example). However, while it is reported that the repeatability of automated analysis using Cirrus spectral domain OCT was better than those from photographic readers, it has also been shown that the optic disc sizes were described as being slightly smaller using automated analysis (Sharma et al. 2011). This led to only a fair correlation between rim areas using the two techniques. Another study showed good agreement between the automated recognition of the optic disc size between SDOCT and photographs, but only fair agreement between the recognition of the cup (Kotera et al. 2009).

With regard to distinguishing between normal individuals and those with glaucomatous optic neuropathy it has been reported that the Disc Damage Likelihood Scale (DDL_S) (2.3.2.2.4) is somewhat more sensitive than the vertical cup-to-disc ratio corrected for disc diameter (Danesh-Meyer et al. 2006). However, the cup-to-disc ratio, as described by Armaly (1969), is still the staging system that has the most widespread adoption worldwide and, as the measurement of optic nerve diameter can be achieved with relative ease in the clinical setting with ncBIO lenses, together with the slow introduction of semi-automated and automated imaging analysis within the same setting, it remains vital that ophthalmic practitioners are accurate in the recognition of the limits of the optic disc and optic cup such that an accurate determination of the cup-to-disc ratio can be obtained. It is for this reason that this study concentrated on these factors and, hence, the determination of the cup-to-disc ratio assessed directly and indirectly.

Chapter 3 Viewing the optic nerve head in three dimensions: agreement between observers and the effect of teaching on agreement

Changes in the appearance of the optic nerve head in glaucoma, especially in the early stages, can be subtle and therefore it is reasonable to consider that viewing the optic nerve head stereoscopically will enhance the evaluation of such changes (Vingrys et al. 1994). Studies have looked at the evaluation of optic nerve head parameters utilising stereo-viewing versus mono-viewing utilising a number of different techniques - direct ophthalmoscopy (Armaly), gonioscopes (Schwartz et al. 1975), non-contact Binocular Indirect Ophthalmoscopy (ncBIO) (Rumsey et al. 1990), stereo-photographic images (Lehmann et al. 2008; Morgan et al. 2005a; Parkin et al. 2001; Stone et al. 2010). It is, however, the method of evaluating stereophotographs that has become the 'gold standard' in studies with which newer technologies are compared (Morgan et al. 2005a), in the clinical setting evaluation of the optic nerve head using stereo-viewing through a dilated pupil, in recording baseline and progression via photography, and as 'gold standard' stereo-photography (NICE 2009). Morgan et al. (2005a) point out that, although this is the case, the development of analysis of stereo optic disc photographs has not, at the present time, been actively pursued within the clinical setting.

3.1 Direct and indirect ophthalmoscopy

In early studies, Armaly (1967) evaluated 724 patients with direct ophthalmoscopy, and found the mean cup/disc ratio to be 0.25. This was lower than that found using binocular viewing utilising a contact lens and slit-lamp, which was found to be 0.38 (Schwartz et al. 1975). Jonas and Papastathopoulos (1995) also suggested that fundus structures, namely the optic disc, could be measured using a Goldmann contact lens in conjunction with a slitlamp.

With the advent of ncBIO lenses most of the attention has been directed at the performance of this technique in the clinical examination of evaluating the optic nerve head. However, one paper in 2001 looked at the agreement of optometrists against a 'gold standard' reference of a consultant ophthalmologist, with a special interest in glaucoma, when using direct ophthalmoscopy (Theodossiades and Murdoch 2001b). In this study they found that the accuracy of assessment was greatest for the vertical cup-to-disc ratio, which they described as almost perfect, despite this technique not being considered as the 'gold standard' for clinical examination since 2009 (NICE 2009).

The first ncBIO lens available in the United Kingdom was a 90D lens made by Nikon Japan, but, quickly, this type of lens and examination technique became known as 'Volk' and 'Volk assessment' after the company that has produced a wide range of such lenses in varying powers since the original

90D version was issued with an US patent in 1986 (Volk 1986). When the Volk 90D lens was a relatively new technique it was shown that cup-to-disc estimation with this technique was consistent with those from direct ophthalmoscopy (Rumsey et al. 1990). Later, when different lenses of this type were assessed against scanning laser technology in the form of the Heidelberg Retina Tomograph (HRT), it was found that lower power lenses, that is 60D as compared with 90D, were better correlated with measures of optic disc size (Lim et al. 1996). Lim et al. (1996), explained this on the basis of measurement errors being proportionately larger with a small image, as viewed with a 90D lens, than errors of a similar magnitude with larger images obtained with lower powered lenses. A more recent paper has found no statistical difference between HRT values for disc size using 90D, 60D and Superfield lenses, but found a difference using a 78D lens (Haustein et al. 2009). This may explain the differing results of two earlier studies. The first showed that there was a significant difference in the estimation of disc size obtained using a 78D ncBIO lens when compared against planimetry (Spencer and Vernon 1995). The second was where a Zeiss 4 mirror contact lens was compared to a 78D ncBIO lens for optic disc height measurements. The former was found to show greater correlation and better agreement with planimetry than the ncBIO lens (Spencer and Vernon 1996).

The use of ncBIO lenses has become ubiquitous in hospital eye units and is widely used in optometric practice due to their relative ease of use and convenience to practitioner and patient alike, compared with contact lenses, which can also be used to carry out the same tasks. However, not all lenses

have the same performance, yet because of, and even despite their widespread adoption, there is limited research comparing the lenses.

3.2 Stereophotography

As previously stated, many sources conclude that stereophotography of the optic nerve head still remains the 'gold standard' procedure, even with the advent of more advanced imaging modalities. These sources range from scientific papers (Morgan et al. 2005b), professional organisations guidelines, such as the American Academy of Ophthalmology Preferred Practice Guidelines in Glaucoma (Prum et al. 2010), or the Royal College of Ophthalmologists' imaging guidance (Bailey 2009), to government bodies, such as the National Institute for Clinical Excellence (Care 2009; NICE 2009), and even webchats, such as those produced by the Wills Eye Hospital (www.willglaucoma.org).

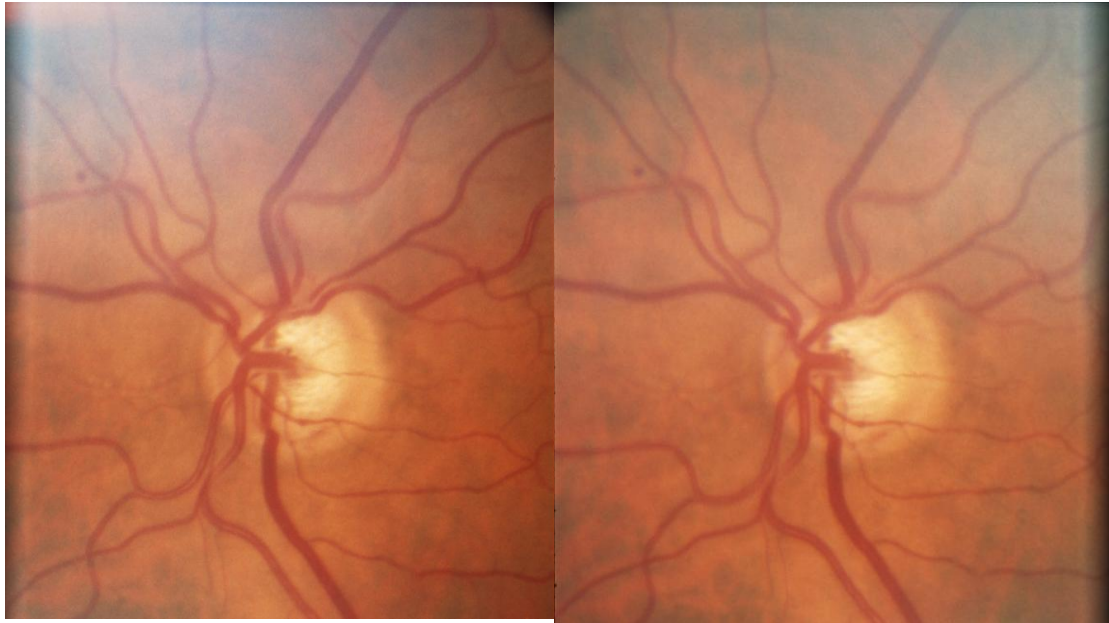


Figure 3.1 Example of Nidek stereophotograph used in the study

3.2.1 Production of stereo-images of the optic nerve head

There are two ways in which a stereo image of the optic nerve head can be realised utilising fundus cameras. The first method is applicable to any fundus camera and is sequential in nature, which means that two images are taken, separated by both distance and time. The distance is produced by lateral movement of the camera between the two images of the same optic nerve head being captured, during which the patient attempts to fixate on the internal fixation device. Depending on the camera and the person undertaking the image capture (imager), the lateral movement can be of variable distance or fixed. Cameras such as the Topcon 50IX (Topcon Great Britain Ltd., Newbury, UK) have a separate base-lock which limits the movement of the camera during sequential recording of images and, as such, provides a fixed stereobase for all images. However, some imagers will base

their lateral movement on the size of the pupil following dilation, which will result in a different stereo-base between patients and potentially between chronology of a single patient. The lack of a fixed stereobase when images are captured using this method can cause a change in the contour of the neural retinal rim and apparent depth and, as such, can create a false impression of progressive glaucomatous optic disc damage (Boes et al. 1996).

In order to obtain an image with a fixed stereo-base, the second method employs a specialist fundus camera is required that allows the simultaneous production of stereo-images with a single image capture. Until recently there has not been a commercially available device in the UK, due to Nidek not having a CE certification. This has led to the suggestion that a conventional fundus camera could be adapted for this purpose (Stingl et al. 2010), but Kowa Optimed Europe has now released the Kowa non myd WX3D, which is capable of producing simultaneous stereo images. It has been reported that the Nidek 3-Dx camera gave significantly better stereo separation than that found using a standard fundus camera (Barry and Eikelboom 1995). At present there is only one publication on the Kowa WX3D (Januschowski et al. 2011), which has non-dilation capability, but there is no reason to believe that a unit of this type would produce images inferior to that of the Nidek 3-Dx camera which found favour in several research papers, and should present the expected benefits of simultaneous recording over sequential recording of images: easier to use (Nidek 3-Dx), an exaggerated or hyperstereopsis effect (Barry and Eikelboom 1995), and a consistent stereo-effect, which is

important to be certain that apparent depth changes are due to progressive optic nerve head change due to glaucoma and not artifactual from varying degrees of stereo angles between chronologically recorded images (Boes et al. 1996).

The resultant images from both methods can be recorded on transparency, film or by digital means, depending on whether the fundus camera is analogue or digital. Analogue images on film or transparency can be digitised at a later point for viewing on a computer screen, and it has been found that observers, when asked to rate images, find both primary recorded digital images, even using a low resolution of 4.9 megapixels (considered to be an acceptable alternative to 35mm slide film) and secondary digitised images, superior to those of 35mm film (Stone et al. 2010).

When, recording images digitally, the value found by Stone et al. (2010) of 4.9 megapixels may sound surprising, given that many manufacturers use this as a measure of resolution. Indeed many manufacturers of ophthalmic instruments are utilising high megapixel consumer and prosumer cameras, as 'recording chips', for example the Nikon D90 SLR at 12.3 megapixels. However, image quality is determined by several factors of which sensor characteristics is only one such factor. The other factors are, spatial resolution, file compression, colour management, exposure, saturation, contrast and a lack of an universal standard (Bennett 2009). Sensor design does have an effect on the recorded image and hence the final image, but it is due to the size of pixels, also known as 'pixel pitch' which benefits image

quality, as the larger the pixels the more sensitive they will be to light. Hence, for a given size of sensor a larger pixel pitch will result in a lower megapixel count but potentially a better image. Larger sensors are also constructed with 'septums' between pixels to restrict light from one pixel causing an effect on a neighbouring pixel. If light is allowed to fall across several pixels, this will lead to a reduction in overall contrast in the final image.

In addition the selection of monitor used to display images will have an effect on the image quality. Monitors have an optimal resolution which is known as the 'native' resolution, which is the number of horizontal and vertical pixels, and like a imaging sensor they also have a 'pixel pitch'. This means that two differing sized monitors , with the same native resolution but with differing 'pixel pitch', will display an image with the same amount of detail but the larger of the two monitors will show a larger image. When viewing an image at 100% this results in one pixel in the image being represented by one pixel on the monitor, therefore if you are looking at two identical sized monitors the one with the higher native resolution/pixel pitch, will provide more detail. Just as with imaging sensors, there are also several other factors that will effect the overall image quality of an image viewed by any monitor which are, brightness, contrast, viewing angle (dependant on LCD screen design), colour depth, connection type and calibration.

The numerous variables will have an effect on the subsequent judgement of a digital image, and it is probably overlooked by many that the production of an image in a digital environment requires more control of exposure than in the

production of analogue images (film). Overexposed optic nerve head images, or those subject to what is termed as 'digital imaging blooming' due to the reflective nature of the optic nerve, will result in unusable images for assessing the cup-to-disc ratio. Equally, it has been found that computer monitors may not provide the optimal viewing for fundal images. In a study, conducted to compare the quality of images viewed on an iPhone 3G (Apple Inc), it was found that reviewers recorded on average higher ratings for images displayed on the iPhone 3g than a computer monitor (Lamirel et al. 2012).

3.2.2 Methods of viewing stereophotographs

The disadvantage of stereophotography of the optic nerve head, when compared with monoscopic images, is that there is no immediate or particularly easy way of viewing these images stereoscopically without some form of intermediate process, which could range from a mechanical device to specialised computer hardware, with or without further specialised software.

3.2.2.1 Printed methods

3.2.2.1.1 Side-by-side prints

The simplest method is to print images of the optic nerve head onto paper and use a mechanical stereoviewer, to align left and right images, thereby producing a stereoscopic view of the optic nerve. This can be achieved using

the basic image manipulation software incorporated in digital imaging software such as ImageNet 2000 (Topcon UK), but the disadvantage is that, although being able to print out to template both stereo-image pairs for the right and the left eyes of a given patient, the images are small and thus the advantage of magnified viewing using a computer monitor is lost. There is often confusion as to whether printed images, or those viewed on a computer monitor provide greater image resolution. This may derive from the standard, dots per inch (DPI) adopted for printing images at maximum quality, being stated as 300dpi, while the 'dpi', for a computer monitor is standard at 72 dpi. Strictly, the measurement for monitors is pixels per inch, not, dots per inch, and it is related to the rendering of fonts on a computer monitor. In order to reproduce a single pixel on the printed page however, it requires 4 to 6 dots to render a colour accurately; hence, dpi will be greater than ppi. In addition, the quality of of a printed image is dependant on the printer and paper combination.

Some practitioners, especially with practice, could also view the images stereoscopically by means of inducing a convergent strabismus, given the correct orientation of right and left images on a page.

3.2.2.1.2 Anaglyphs

It is possible that left and right stereo-images for a given eye can be uploaded to readily available anaglyph software, for example: Z-Anaglyph , freeware download copyright Mr G Rosset (http://rosset.org/graphix/anaglyph/zanag_en.htm)

), and the resulting red/green or red/cyan stereo-anaglyph image could then be printed. This would, of course, require the use of red/green or red/cyan goggles, but these are available at a reasonable cost.

3.2.2.1.3 Lenticular transparency

One paper published in 1996 looked at the technique of auto-stereoscopy in producing a stereo-image that does not need any form of viewing aid. This is made possible by the surface of the transparency being an overlay of linear micro convex lenses (Boes et al. 1996). This technology is still used today, but is commonly seen in 2D displays, that give the illusion of movement. and 3D posters.

3.2.2.2 35 mm image methods

Unless analogue images are digitised for viewing, as below, then, traditionally, these have been viewed using equipment such as a Donaldson stereo-viewer, if sequential full frame images are being viewed. Alternatively, simultaneous stereo-images, which would be recorded as split-frame images, can be viewed on a single frame stereo-viewer (Boes et al. 1996).

3.2.2.3 Digital image methods

3.2.2.3.1 Side-by-side display

The simplest method utilises the digital manipulation software incorporated into imaging software. This may allow the simultaneous presentation of right and left images on a computer screen which can then be viewed with the aid of a mechanical stereo-viewer, to obtain a stereoscopic image of the optic disc. This method has the advantage that the resultant image will be seen with a variable degree of magnification depending on the monitor size.

3.2.2.3.2 Anaglyphs

Stereo-anaglyphs can be generated, as in (3.2.2.1.2), displayed on a computer screen and viewed using simple red/green or red/cyan goggles. Images produced in this way can also be viewed using custom software such as that used in this study, StereoDx developed by Prof James E Morgan, Cardiff University, to allow advanced analysis of the resulting image (Morgan et al. 2005a; Morgan et al. 2005b).

3.2.2.3.3 Z-screen technology

The Z-screen (Stereographics Corporation, CA, USA) stereoscopic visualisation system consists of a filter that circularly polarises light from two images on a screen (Figure 3.2). The resultant images are then alternately

displayed on a Sony Trinitron 19 inch CRT monitor (recommended resolution, 1280 x 1024 at 85Hz) with a refresh rate of 60 Hz (Sony UK Ltd., United Kingdom), which produces flicker-free stereoscopy when an observer wears passive polarised spectacles (Hewitt et al. 2006). This system also makes use of custom software developed by Prof James E Morgan, Cardiff University.



Figure 3.2. Z –screen mounted on computer monitor, with examples of passive polarised spectacles (Stereographics Corporation, CA, USA)

3.2.2.3.4 Liquid Crystal Shutter Goggles




Figure 3.3. Nvidia 3D Vision LCS goggles with control emitter (Nvidia Corp. UK)

As an alternative to the entire computer screen being covered with a filtered screen, as in the Z-screen method, use can be made of a pair of polarised liquid crystal shutter goggles (see Fig 3.3) used in conjunction with interleaved sequential right and left images, with the goggles being synchronously controlled through an infrared emitter (Habib et al. 2008). This method suffers from various problems, with some set-ups reducing the vertical image resolution by 50%, and there being cross-talk between the right and left images. By far the biggest problem encountered by this, and the previous method utilising the Z-screen, is the reduction in brightness of the image by 68% due to the shuttering effect of the goggles, requiring the viewing of

images to take place in a darkened room. However, due to spectral nature of the filters incorporated into the liquid crystal shutter goggles, and similarly, the Z-screen, contrast is not altered by either of these methods.

3.2.2.3.5 Autostereoscopic screen

Lenticular transparencies (3.2.2.1.3) are an example of auto-stereoscopy, with the most commonly seen version of this technology being the parallax barrier display found in the Nintendo 3DS games console. While Nintendo have been reluctant to release sales figures, Wikipedia, reports sales figures of approximately 22 million units worldwide, so it is possible that a large number of individuals of varying age groups have first hand experience of this type of technology.

Within the field of stereoscopic optic nerve head viewing, this technology allows an observer, using a suitable display, such as the Dimensions Technology XLS virtual window via a 3D mode, to be presented with a stereoscopic pair of images at a specific position without the need to wear any form of additional goggles or spectacles. Instead the right and left images are presented directly to the correct eye. In a study by Habib et al (2008), they found that use of this technology provided comparable diagnostic and clinical assessment to liquid crystal shutter goggles, but postulated that they have significant clinical usability over the former method of viewing stereoscopic images.

3.2.2.4 Flicker chronoscopy

First described as a technique to view two chronologically separated monoscopic optic disc images in a stereoscope, and given the name stereochronoscopy, this technique shows up temporal changes immediately as stereo-effects (Goldmann and Lotmar 1977). Vingrys et al. (1994). This technique was used in the Early Manifest Glaucoma Trial to determine one of the main outcome measures of optic disc changes (Heijl et al. 2002; Leske et al. 1999). The original flicker technique involved two optic nerve head photographs super-imposed by projection with a rapid alternating occlusion of images. This results in changes of the optic nerve head appearing as motion (Funk et al. 2002). Despite a number of papers, including recent ones utilising flicker chronoscopy with monoscopic images (Cymbor et al. 2009; Radcliffe et al. 2010; Syed et al., 2011; VanderBeek et al. 2010), which looked at both this technique compared with viewing stereophotographs alone and with various aspects of optic nerve head change in glaucoma, there is no reason why this technique cannot utilise stereoscopic images as opposed to monoscopic images. The use of stereoscopic images was first reported in conjunction with flicker chronoscopy in a paper using this method for the detection of optic disc haemorrhage (Gazzard et al. 2003). The early description of computerised registration for aligning sequential, monoscopic images came from a team at the Pennsylvania School of Medicine who felt that the reason why this technique did not find initial favour was due to difficulty in super-imposing sequential images (Berger et al. 2000). These researchers concluded that digital image processing with flicker technology

could provide a simple and sensitive method of detecting changes in the optic nerve head, such as vessel position, colour and other cues for contour change.

Simultaneous stereoscopic images taken using a Nidek 3Dx camera have successfully been used with Automated Alternation Flicker (AAF), whereby, following import into MatchedFlicker software (EyeIC Inc, PA, USA), the images were automatically aligned and alternated (Syed et al. 2011).

Automated flicker has been shown to be more sensitive than either side by side or individual images in the detection of optic nerve head haemorrhages and the progression of Peripapillary atrophy (PPA) (VanderBeek et al. 2010).

Flicker technology is also incorporated into Kowa 7 non myd fundus camera (Kowa Optimed Europe Limited), which alternates two sequentially taken images of the optic nerve head, giving an impression of three dimensional viewing of the Optic nerve head within the motion of the images seen alternating.

3.3 Advantages of stereophotographs over other imaging modalities in the assessing glaucomatous optic nerve head

The principal advantage of disc photographs over newer imaging technologies is that it is what the clinician is used to seeing in his or her clinical examination, allowing direct comparison within the clinical setting. Fundus cameras are available to more practitioners, both in primary and secondary

care, than instruments such as the Heidelberg Retina Tomograph or Optical Coherence Tomographs. Optic nerve head photographs are readily reproducible and provide a baseline image against which all subsequent images can be judged for progression. Newer imaging modalities are advancing rapidly and it has been reported that this very speed is faster than the progression of optic nerve head disease (Charters 2004). This leads to the problem of newer versions of technology not being fully comparable with older versions, thus being unable to utilise the data gathered at an earlier date, whereas optic nerve head images can be used even if the camera used to record them is different.

These advantages do not necessarily mean that stereophotographs have a definite advantage over newer technologies or, indeed, even lower tech methods, such as clinician drawings. Coleman et al. (1996) found stereophotographs were not appreciably superior to a baseline drawing or description as an identifier of progression and, further, that neither of the methods were more than modestly better than chance.

3.4 The role of stereopsis in viewing optic disc images

Despite stereophotography being considered the 'gold standard', there is both little and contradictory evidence that viewing images stereoscopically adds additional clinical information over monoscopic evaluation of the optic nerve head. It has long been postulated that this is the case, with authors questioning whether stereophotography techniques give greater performance

(Odberg and Riise 1985). More recently Parkin et al. (2001), using a Discam optic disc camera, suggested that there may be little benefit derived from stereo-viewing over monoscopic viewing where the outcome was the measurement of the cup-to-disc ratio. They pointed out that there may have been a subjective benefit in viewing stereoscopic images, but this did not translate to a clinically significant benefit. More recently it was shown that assessment using digital stereoscopic images provided higher estimates of cup-to-disc ratio, which means values for the neural retinal rim width were lower compared to monoscopic viewing (Morgan et al. 2005a), together with higher levels of inter-observer agreement. The results of this study may be in part due to the way the images were viewed, with the advantage of a measuring cursor that could be moved within the stereoscopic image to lie at a level of the structures being observed. This was reported to allow the minimisation of parallax errors in the measurement of neural retinal rim width. This work using digital stereo-images continues the debate on what is the role of stereopsis in viewing the optic nerve head, be it in direct clinical examination utilising a slit lamp and ncBIO lens or in reviewing stereoscopic images.

It is possible that the method of recording stereo-images and viewing them may not be the only factor in play with regard to the role of stereopsis in determining optic nerve head landmarks, such as the edge of the neural retinal rim. It has been shown that amblyopic observers with a stereoacuity of 40 – 100 seconds of arc have a similar performance compared with others with better stereoacuity of 15- 30 seconds of arc (Vingrys et al. 1994). Indeed

even observers with poorer levels of stereoacuity, greater than 200 seconds of arc, were found to perform better than levels of chance. The authors found that the level of disparity predicted by calculation (5.8 μm) did not match that found by experiment (64 μm), and they concluded that low levels of stereopsis are adequate for making depth judgements when viewing stereophotographs and fundal images, meaning that non-amblyopic observers cannot make use of their full stereoscopic potential. They further concluded that the answer lies with work looking at 'feature salience', which is the reduction in ability to make depth judgements based on stereopsis due to the effect of nearby features (Mitchison and Westheimer 1984). Where there are abrupt edges or sudden translation from one level to another, there will be little salience and maximum stereopsis, but it should be noted that monocular cues will also be maximised under these same conditions. However, where there are gentle transitions and shallow edges, salience is maximised, with little by way of stereo cues. Not all optic discs have clear cut neural retinal rim edges with obvious differences in the depth of cup and many may have gentle translations, so it may be that salience has an important part to play in the observation of optic nerve head details. Also, Mitchison and Westheimer (1984) showed that the effect of salience varies between individuals, with some being unaffected by it, others partially affected and yet others having complete suppression of stereopsis. It may be that more practitioners use monocular cues than they think even while viewing the optic disc clinically or utilising stereophotographs. It is possible that those observers with good levels of stereoacuity, and who are not affected by or only partially affected by feature salience, use this to make quicker and more reliable judgements.

Clearly the role of stereopsis in the viewing of stereophotographs is not a simple one and may not be as important as is intuitively suspected by many clinicians.

3.5 Studies on agreement between different observers in the detection of glaucomatous optic neuropathy

There are many studies on the agreement between observers in the detection and progression of glaucomatous optic neuropathy, mostly looking at expert and non-expert ophthalmologists, optometrists with varying degrees of training, and, in some cases, readers at clinical reading centres (Gangaputra et al. 2011). These studies have all used stereo-photographs as the method of viewing optic nerve heads and generally report agreements between observers by the use of kappa and weighted kappa statistics.

While it is convenient to look at these studies in terms of those dealing with detection and progression separately, they all deal with agreement.

3.5.1 Detection

Abrams et al. (1994) looked at the inter-observer agreement among general ophthalmologists compared to optometrists and ophthalmology residents, and reported substantial agreement among ophthalmologists (KW 0.68), which they found was higher than the later two groups (KW 0.56) when estimating the cup-to-disc ratio. When they considered the sensitivity of identifying

glaucomatous optic nerve head damage they found that all ophthalmologists, including residents, were better than optometrists. In a paper looking at the use of a novel digital stereoscopic imaging system (StereoDx) in the diagnosis of glaucoma (Morgan et al. 2005b), it was found that the sensitivity of three ophthalmologists (76.9% - 90.4%) matched and exceeded the sensitivity found in the earlier study of Abrams et al. (1994) of 78%, although as this group included resident ophthalmologists this may be a reason for the difference seen. However, this later study found specificities (79.6% – 94.4%) which were greater than those found in the earlier one, which showed poor specificity across all groups, ophthalmologists, residents and optometrists (47% - 60%).

One study that made use of Intraclass Correlation Coefficients, as opposed to kappa or weighted kappa statistics, looked at the agreement between two trained fellows and their supervisor (Hatch et al. 1999b), and concluded that substantial agreement (ICC 0.74) can be achieved in the estimation of cup-to-disc ratios, both by estimation and planimetry, with the proviso that there is a standard protocol and training.

Turning to the performance of optometrists Spalding et al. (2000) asked 56 optometrists with various training and practice backgrounds to evaluate the cup-to-disc ratio and the presence or absence of glaucomatous optic nerve damage, and concluded that the estimation of cup-to-disc ratios within a group of optometrists varied significantly on the basis of training, practice setting and experience, with the best intra- and inter-observer agreement

occurring for those optometrists who had undergone residency training and practice within a non-commercial setting. This applied to both the estimation of the cup-to-disc ratio and the rating of discs for glaucomatous optic nerve damage. Another paper looking at the ability of optometrists in training (Year 3 and 4 students at the University of Auckland, New Zealand) in comparison with qualified optometrists found that, while inter-observer agreement increased with experience, intra-observer agreement did not (Hanson et al. 2001).

3.5.2 Progression

In several studies the definition of progression of glaucomatous optic nerve damage has been based on, among other factors, the appearance of focal or diffuse narrowing of the neural retinal rim and the increase of the vertical cup-to-disc ratio. Presumably any narrowing of the neural retinal rim will lead to a change in the cup-to-disc ratio, but it may possibly be at another orientation to vertical, hence a distinction was made in some studies. Results vary between studies, with agreements being studied between glaucoma experts, non-experts, and, recently, with the results of glaucoma-qualified optometrists viewed against glaucoma ophthalmologists. In one paper three ophthalmologists involved in the European Glaucoma Prevention Study Group (EGPS) were found to have substantial agreement when looking for change (Zeyen et al. 2003), although the actual reported kappa values between observers were mostly in the range 0.40 to 0.58, which, by the authors definition, would have been considered fair with only a couple of values being

in the 'good' range. Three ophthalmologists acted as consensus for determination of change or stability for each of the stereo-photographs evaluated and this was checked on a separate occasion. The consensus or assignment reproducibility, as it was described, yielded an 'excellent' kappa value at 0.94, which was not reproduced when the EGPS group were reviewed against a second group of expert ophthalmologists, where it was seen to drop to 'good'.

Jampel et al. (2009) concluded in their study that agreement between expert ophthalmologists in determining the progression of glaucomatous optic nerve damage was only 'slight' to 'fair', and noted that, in addition to this, the proportion of discs reported as 'changed' varied considerably between the three expert observers. They cited one limitation to their study as being the use of sequential stereophotographs, stating that if there was a consistent stereopsis level, concordance may have been better. When using simultaneous stereophotographs, the agreement was found to be 'moderate', with kappa values ranging from 0.34 to 0.68 (Azura-Blanco et al. 2003).

Although it is not clear from the short study of Azura-Blanco et al. (2003) what the criteria for change was, they did mask the chronology of images and felt that agreement would have been higher if this was known to the examiners. This was supported by the fact that Jampel et al. (2009) found that, if chronology was masked in the 40% of cases where progression was considered to have occurred, the first image taken of a patient was the worst.

In a study of 37 'non-expert' ophthalmologists, presumably non-glaucoma experts as their status is not defined in the study, it was found that their inter-observer agreement was 'slight' (kappa 0.20), as compared with expert ophthalmologists which was 'moderate' (kappa 0.51) (Breusegem et al. 2011). These researchers also employed a training session for the non-expert ophthalmologists, but found that agreement changed little (kappa 0.27). They felt that both statistically and clinically the agreement was significantly lower than that of the expert ophthalmologists, even after training, and cautioned that screening policies using non-expert ophthalmologists may not have the same benefits as would be expected when compared to glaucoma experts.

In the United Kingdom it has been suggested that there are not enough ophthalmologists available to undertake glaucoma care and, as such, there have been numerous schemes where optometrists have become involved in enhanced roles within the hospital eye service or in the community. In 2006, a national survey identified 36 schemes in England (Vernon and Adair 2010) utilising optometrists, and recently a publication (Marks et al. 2012) looked at optometrists who have undertaken the College of Optometrists higher qualification in glaucoma. As these optometrists held the DipGlauc qualification it means that they have achieved the highest level of accredited-training available at the present time. This publication looked at several aspects of glaucoma assessment and concluded that optometrists achieved a moderate to substantial level of agreement in all but a single area of clinical assessment, which was in optic disc stability. The authors do make the point that, despite weighted kappa values of 0.17 right eye and 0.31 left eye, the

consultants and optometrists were in complete or partial agreement for 95% of eyes, in the evaluation of optic disc stability. This statement, regarding optic disc stability, seems inconsistent but the high percentage agreement comes from the fact that the majority of eyes fell into the stable or probably stable classifications. Both of these were considered by the authors as acceptable to use to calculate the percentage agreement, their argument being that while differences of opinions do often occur, due to the subjective nature of the assessment they do not always lead to differences in management.

In summary, agreement on Cup-to-disc ratio and the identification and progression of glaucomatous optic nerve head damage seems to be 'low' to 'substantial', depending on which authors are consulted, and seems to depend on which professional group is being evaluated. Differences found between ophthalmologists and optometrists vary with their training, practice and experience.

3.6 The effect of teaching on the ability to determine the optic disc and neural retinal rims

The ability to accurately determine the position of the optic disc and neural retinal rims is fundamental in being able to recording the cup-to-disc ratio in any clinical examination, or virtual examination, of a patient by way of stereophotographs of the optic nerve head. Several studies have investigated the effect on optic nerve head assessment following a teaching programme.

Two studies examined the agreement between experts and observers with less experience, with particular reference to the determination of the cup-to-disc ratio (Hatch et al. 1999b; Sheen et al. 2004), while another study concentrated on a larger numbers of participants utilising web-based presentation of monocular images of optic nerve heads (Andersson et al. 2011).

3.6.1 Limited parameters being tested and the use of stereophotographs of the optic nerve head

Several studies on the agreement of clinicians in evaluating the optic nerve head for glaucoma were published in the late 1980s to mid 1990s (Abrams et al. 1994; Tielsch et al. 1988; Varma et al. 1992), and they reported 'poor' to 'substantial' agreement of cup-to-disc ratios (Hatch et al. 1999b). Hatch et al. (1999) pointed out that there was no attempt to train observers before assessing agreements. They conducted their study to determine the effect of a training period, which in this case was a comparison of the primary observer with a person who had just finished his training with the primary observer, and a second person who had spent 4 months in training with the same primary observer. Their outcome was to see if better agreement could be obtained in the assessment of stereoscopic optic nerve head photographs between the three observers. Training comprised of co-examination of 1800 patients, including stereo-disc assessment in the clinical setting on all patients. The agreements were calculated using Interclass coefficients (ICC) and they found almost perfect agreement between the three observers for vertical cup-to-disc

ratio (ICC = 0.83) when viewing stereo optic nerve head images. The authors concluded that clinical training of fellows and residents can produce substantial agreement, and further that an intensive four month training period for trainees, together with a standard protocol for the assessment of optic nerve heads, achieved results comparable to those found between expert observers.

Sheen et al. (2004) evaluated the effect of a training programme on naïve observers using stereo-disc photographs. This work forms the basis for the Cardiff arm of this study comparing two different stereo-presentations, and the effect of training on the agreement between a further group of naïve observers and expert opinion.

3.6.2 Large numbers, web-based delivery and multiple disc characteristics

In the first of two web-based delivered studies (Andersson et al 2011), teaching consisted of a one hour lecture based on the five rules for detection of glaucoma (Fingeret et al 2005). Andersson et al. (2011) presented the systematic approach of evaluating the optic disc size, neuro-retinal rim, retinal nerve fibre layer, peripapillary atrophy and optic disc haemorrhage with a short training session on how to use the system. This lecture took place at Malmo University Hospital, Malmo, Sweden at an international glaucoma meeting in 2008. Ninety-six ophthalmologists took part in the study, with varying degrees of experience in glaucoma practice, which concluded that the

result of the teaching was a small positive effect in diagnostic performance. Diagnostic accuracy was defined as the percentage of correct classifications of 50 optic nerve head photographs for each observer, along with sensitivity and specificity. Sensitivity was found to increase across all groups from ophthalmologists, who were not glaucoma sub-specialists, to expert ophthalmologists, with an increase in sensitivity from 26% in the former group to an 8% increase in sensitivity, even for experts. Specificity was found to be unchanged between pre- and post-lecture assessments.

The second web-based study looked at an even larger number of seemingly self-selected participants (Kong et al. 2011) This project is still available on the internet at www.gone.com and is known as the Glaucoma Optic Neuropathy Evaluation (GONE) project. The website says that it is both a testing and a teaching programme, however there is no teaching element to this website, only a way of benchmarking individual skills in optic disc examination against other participants. In addition to being available on internet, the project has availed itself of additional modern technology and is available as an iPad app for use with a mobile tablet.

Images employed in this web-based system were monoscopic images, as the authors wanted to make the system readily-available without the need for standardised binocular-viewing apparatus. The system asked participants to grade 42 optic nerve heads by asking nine questions for each. These questions were disc size, shape and tilt, PPA, cup-to-disc ratio, cup shape and depth, nerve fibre layer defect and haemorrhage. The GONE system is

said to encourage accurate assessment of the optic nerve by accurate assessment of all relevant morphological features (Kong et al. 2011). For those signing up to the GONE project, feedback is currently given to participants regarding their performance against their peer group, and by the principal investigators who chose the image set, to illustrate a range of optic nerve head features and to reflect various subjective levels of difficulty based on their clinical experience.

While the questions asked represent a comprehensive range of factors to be taken into account when examining the optic nerve head, there are several issues which relate to this project. Firstly, there is no training programme associated with the project; one sample image of relative ease is presented prior to self-registration, which requires the participant to choose from drop down boxes responses for each of the above categories. There is, however, no attempt to explain the choices or give examples on which to base further assessments. An example of where error can occur is the use of the subsequent choices for disc shape, where a participant can choose regular, vertical ovoid or horizontal ovoid. As the normal shape of the optic nerve head is an elongated vertical oval it could be presumed that the correct answer is vertical ovoid, but the correct classification for a normal disc is regular.

With regard to the estimation of cup-to-disc ratio, the choice is limited to 0.1 steps, but since being out by 0.1 would incur an error, it would be useful if there was some guidance on what to do with those cup-to-disc ratios that fall

in between two measures, as it is likely that, just as in the clinical setting if forced to make a determination of this order, a practitioner would err on a larger value, it is not clear what the expert graders are doing.

Secondly, depth estimations are required from monoscopic images, which seems incongruous, and it is probably why the authors found a low inter-observer agreement even between glaucoma sub-specialists for this feature with a quoted value of $k_w = 0.49$. Another problem is based around the assessment of the retinal nerve fibre layer, as the images are not of sufficient quality to display changes, so making a judgement irrelevant in many cases. In the study the authors found that this was the characteristic that had the worst inter-observer agreement amongst trainees.

Clearly, this study was designed as a benchmarking exercise with the teaching element only being that of repetition of optic nerve head characteristics and the ability, once complete, for a participant to review their performance against the expert determination, which had varying degrees of additional information depending on the disc image and peer groups. Kong et al. (2011) only report results relating to medical practitioners within the paper, despite the authors mentioning optometrists in their discussion. The results presented are agreement values. It is therefore unclear what the level of performance would be on a repeat test, as this is not available when you log back into the site at a later date, although it would be possible to register more than once presumably, and whether the project does help in educating practitioners.

Finally with regards to the study, there is the potential for bias due to the fact that not all the participants were self-selected (81% fell in this group), and that the glaucoma sub-specialists (19%) were in fact selected on account of their expertise in optic nerve head evaluations (Kong et al. 2011).

Glaucoma is a disease of age with incidence increasing with increasing years of life and which can cause irreversible visual loss, with patients being eligible for registration, at both Sight Impaired (SI) and Severely Sight Impaired (SSI) levels in the United Kingdom. For this reason there is a need to improve the methods of detection such that improvement in prognosis can be realised due to early detection. It is generally held that optic nerve head changes occur prior to other measurable changes, such as visual field loss. As such it is a reasonable approach to consider the skills of ocular healthcare professionals in the recognition of the early signs of glaucomatous optic nerve head damage, and to try and improve this ability by training. The aim of this thesis is to provide information relevant to the possibility of designing such a web-based training package utilising 3D images of the optic nerve head.

Chapter 4 Effect of teaching on the determination of cup-to-disc ratios with different stereo presentations

4.1 Aim of study

To compare two different methods of stereoscopic viewing, and the effect of teaching, on the assessment of the Cup-to-disc (C/D) ratio for glaucoma detection.

4.2 Method

Two different methods of stereo presentation were compared, both using custom software StereoDxT, (Cardiff University) to present images. The first method displayed stereo-images using Nvidia 3D software (Nvidia Corp. UK), making use of Nvidia 3D Vision Wireless Liquid Crystal Shutter goggle technology in combination with a ViewSonic 120Hz TFT-LCD monitor (ViewSonic Europe Ltd.UK) compatible with Nvidia GeForce 3D Vision. The second being in the form of red/cyan stereo anaglyphs, again being displayed on the same type of ViewSonic monitor (specifications: 24 inch 16:9 display, resolution 1920 x 1080, brightness 300cd/m²), thus representing a 'low-tech' method of presentation.

4.2.1 Image selection

Images were chosen from a series of stereophotographs taken using a Nidek 3Dx fundus camera (Nidek Co. Ltd., Gamagori, Japan), each split-frame slide stereopair having been digitised at high resolution (1250 x 1395 pixels) using a Nikon LS-2000 digitiser (Nikon Corp., Tokyo, Japan) for stereoscopic viewing on a computer monitor. Images were of Caucasian eyes and represented normal and glaucomatous optic nerve heads. The images went through a series of steps in order to obtain the 20 images to be used in the study.

The first step was to exclude those images that were of inferior quality, defined as poor focus, exposure and colour. Starting with 121 possible stereo-pairs, this first exclusion left 74 stereo-pairs for conversion to red-cyan anaglyphs, using Z-Anaglyph (freeware download, copyright Mr G Rosset). The resulting red-cyan anaglyphs, were then re-graded on a laptop (LCD – CCFL screen), on the basis of perceived ease of obtaining a 3D image. At this point the images covered a full range of cup to disc ratios of 0.00 to 0.90, although relatively few images were found to be below 0.30 and above 0.80. 30 images were available to be assessed, using the liquid shutter goggle set-up and images were also excluded, if the stereoscopic view was poor when displayed using the Nvidia 3D system software. This resulted in ten assessment images (Set A) in anaglyph and non-anaglyph (meaning the original colour images from the Nidek camera) form to be used as study images, along with a further ten images for use as teaching images (Set B).

These images were reviewed by an expert observer (glaucoma expert trained to Fellowship level) who demarcated the optic disc margin and the neural retinal rim margin using the StereoDxT software (Prof J Morgan, Cardiff University).

These images were then used for two of the three projects undertaken in this study:

4.2.2 Observer selection

Second year optometry students were recruited as observers in the Cardiff section of the study as they were considered to be suitably naïve observers in terms of optic nerve head assessment, thus allowing for the effect of teaching to be examined. They would have however, viewed the optic nerve head previously in their studies with an ophthalmoscope. The students were allocated to view either anaglyph images or non-anaglyph images, eight in each group. All observers had 50 seconds of arc or better stereoacuity, assessed using the Titmus Fly Test (Titmus Optical Co. Inc., Petersburg, VA). One student was excluded as they had previous experience of imaging of the optic nerve head prior to starting the optometry course at Cardiff University. This resulted in a total of 16 students who were randomly allocated to either the anaglyph or non-anaglyph groups.

4.2.3 Initial assessment of optic nerve head images

All sixteen students were given instruction in the StereoDxT software and shown how to use the tools to outline the optic disc rim and the neural retinal rim. Following this they were asked to delineate both the optic disc rim and the neural retinal rim on ten test images. There were no time limits imposed on the observers and they were allowed to make any corrections they felt were necessary to their contour lines. Once they were completed the “calculate” button was clicked, which calculated the following: Cup area, Rim area, Disc area, Cup-to-disc ratio and linear vertical Cup-to-disc ratio. In addition, these same values were calculated for each 30 degree segment of the whole optic nerve head.

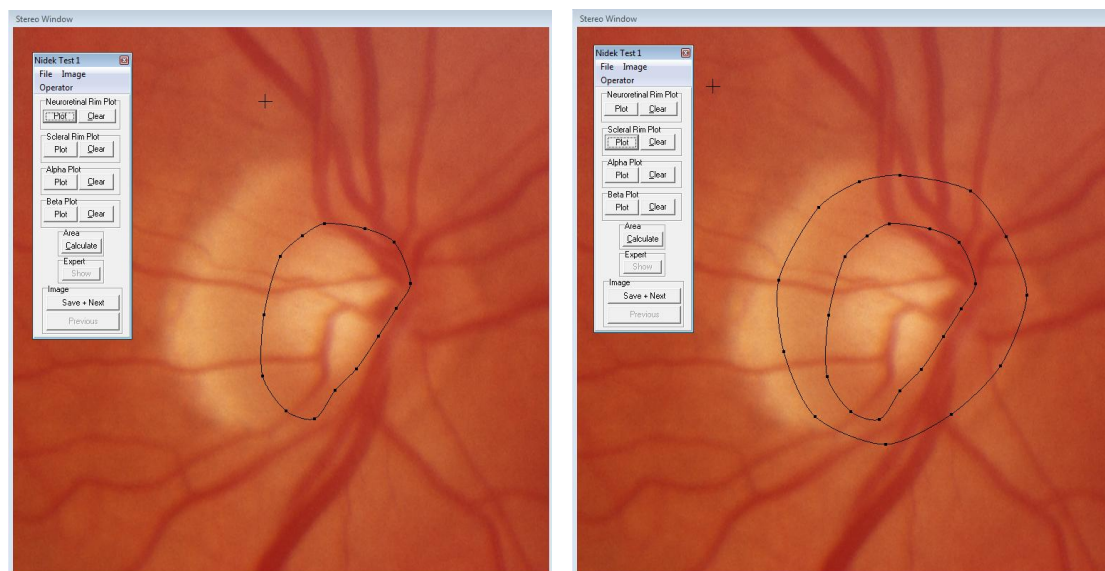


Figure 4.1. Observer's view when using StereoDxT software to demarcate the neural retinal rim and the disc rim (labelled scleral rim in software).

The observers were allocated a letter from A- H if they were in the non-anaglyph group, and I-P if they were in the anaglyph group.

4.2.4 Teaching of selected observers

Eight observers, A-D from the non-anaglyph group and I-L from the anaglyph group, were given a training session undertaken by Prof J E Morgan (Professor in Ophthalmology, Consultant Ophthalmologist) in the correct identification of optic nerve landmarks, namely the disc margin and the neural retinal rim, before being asked to undertake their second assessment of the test images. The teaching took place using a set of images obtained from Kowa WX3D simultaneous stereophotographic fundus camera (Kowa Optimed Europe Ltd.) and all observers, irrespective of whether they had undertaken their initial assessments on non-anaglyph or anaglyph images, were taught using the non-anaglyph system.

4.2.5 Second assessment of the optic nerve head

Observers A-D and I-L were then asked to undertake a second assessment, which was on average 8 weeks (range 3 – 16 weeks), but no later than one week, after the training session. Prior to assessing the ten images again, randomly arranged from the first assessment, the observers were asked to assess a further ten images (Set B) that had been reviewed by the studies expert observer. This time when they had finalised their demarcations they were able to compare it to the expert observer's assessment of the optic disc

rim and neural retinal rim by clicking on the 'expert view' tab (see Figure 4.2) and thus review the accuracy of their determinations on screen.

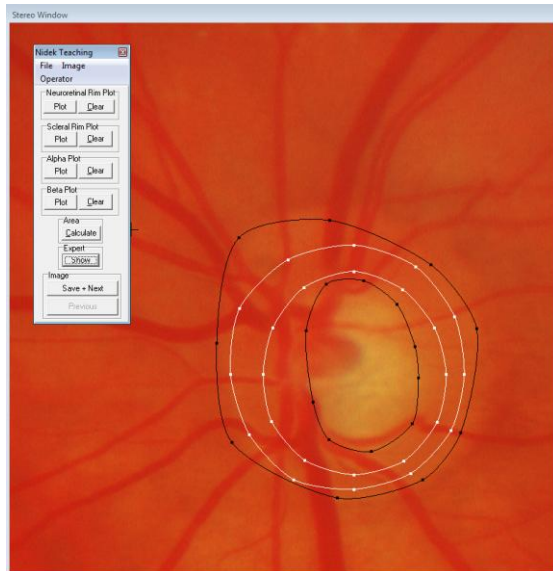


Figure 4.2. The trained observer's view of the StereoDxT software revealed when clicking on the 'expert view' tab (expert determination in white, observers in black).

These ten images (Set B) acted as a teaching set of images which the trained observers could review and further refine their knowledge of disc assessment prior to undertaking the second assessment of the test images (Set A). Set A were viewed either as non-anaglyphs or anaglyph presentations dependant on the original assessment technique undertaken by the observer.

Observers E-H in the non-anaglyph group and M-P in the anaglyph group acted as a control group for the study, as they did not have the teaching set of slides and the tutorial. These eight observers were also asked some time later, on average 10 weeks (range 5 – 15 weeks), to undertake the test again with the same ten test images (Set A). The images at this time were arranged in a different order to that presented to the observers at the initial assessment.

In summary, eight observers were asked to review ten images on two occasions (totalling twenty images) and these acted as the control group. The second group, who were allocated to teaching, therefore reviewed a further ten images and thus totalled thirty images, see Figure 4.3.

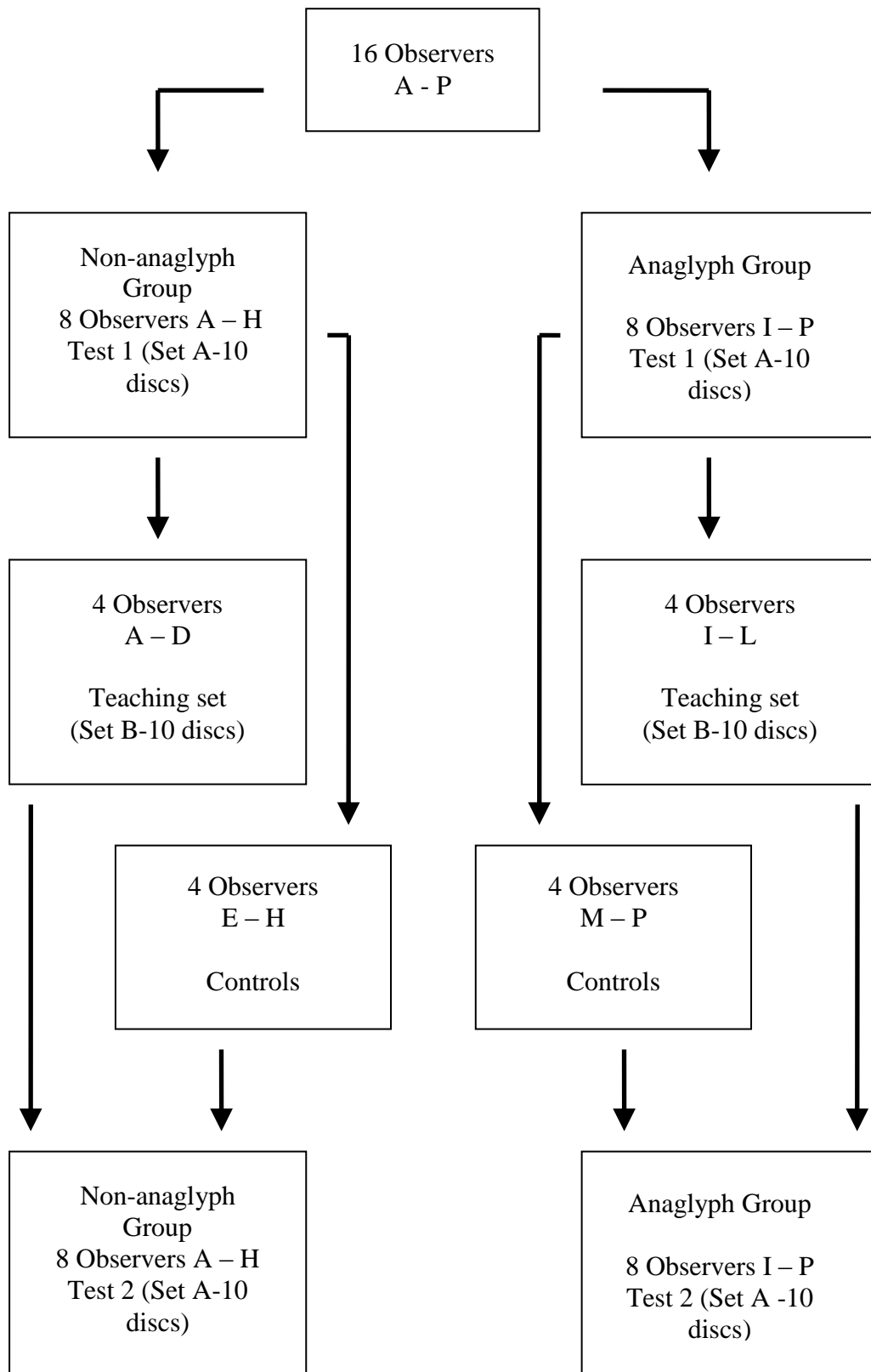


Figure 4.3. Flow diagram indicating observer groups and the number of images they were asked to assess.

4.3 Main outcome measures

Statistical analysis was performed using SPSS v 20 (IBM Corp., New York, USA). SPSS was used for the following statistics: Intraclass correlation coefficients (ICC) and standard deviations (SD). In addition, Microsoft Excel (Microsoft Corp., USA) was used for paired t-tests and Bland-Altman.

4.4 Results

Mean differences between each observer and the expert were calculated, and expressed as root mean squares (RMS), as the differences could be either positive or negative. Paired t - tests were performed on the RMS obtained from those observers for Test 1 and Test 2. Standard deviation (SD) was used to estimate variability between observers and the expert. Intraclass Correlation Coefficients (ICC) were determined for all observers using a two way mixed effect model. ICC were calculated to assess agreement between observers. Interpretation of ICC values from (Hatch et al. 1999a) are shown in Table 4.1.

Table 4.1, Interpretation of Intraclass Correlation Coefficients (ICC)

Intraclass coefficient	Interpretation of agreement
-1.0 to 0.0	Poor agreement
0.01 to 0.20	Slight agreement
0.21 to 0.40	Fair agreement
0.41 to 0.60	Moderate agreement
0.61 to 0.80	Substantial agreement
0.81 to 0.99	Almost perfect agreement
1.00	Perfect agreement

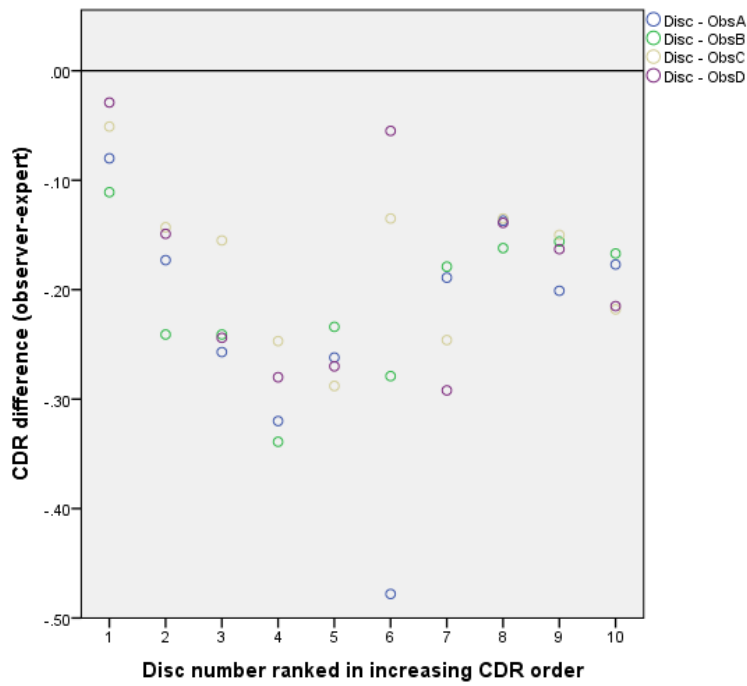
In addition, the largest differences between observers, and the percentage of observer cup-to-disc measurements that differed from those of the expert by ≥ 0.20 for each of the groups, i.e. the teaching group and the control group in both the anaglyph and non-anaglyph test groups, were identified. The reason for analysing those differences of ≥ 0.20 is that this has been reported as an 'accepted traditional criterion for clinically significant change in glaucomatous cupping' (Sheen et al. 2004).

Further, agreement between the two different methods of stereo-presentation was made by means of plotting the expert's determination of the cup-to-disc ratios from both techniques in the method described by Bland and Altman (Bland and Altman 1986), and by using the results for RMS of differences between the observer and expert for both trained groups (anaglyph and non-anaglyph) compared to the control groups as a surrogate measure of agreement.

4.4.1 Non-anaglyph group results

Figure 4.4A shows the differences in the average vertical cup-to-disc ratios between the observers A, B, C and D and the expert before these observers underwent a teaching session, and Figure 4.4B showing the same comparison following their teaching session. The cup-to-disc ratios are ranked along the x-axis from disc 1, with the smallest measured cup-to-disc ratio, to disc 10, with the largest, as assessed by the expert observer. In total, the cup-to-disc ratios ranged from 0.606 to 0.917.

A Observers before undergoing a teaching session.



B After teaching

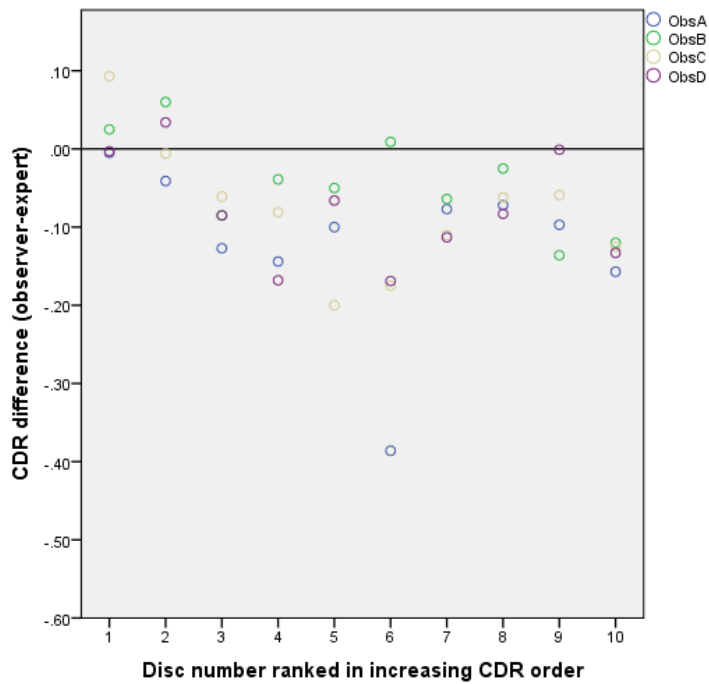


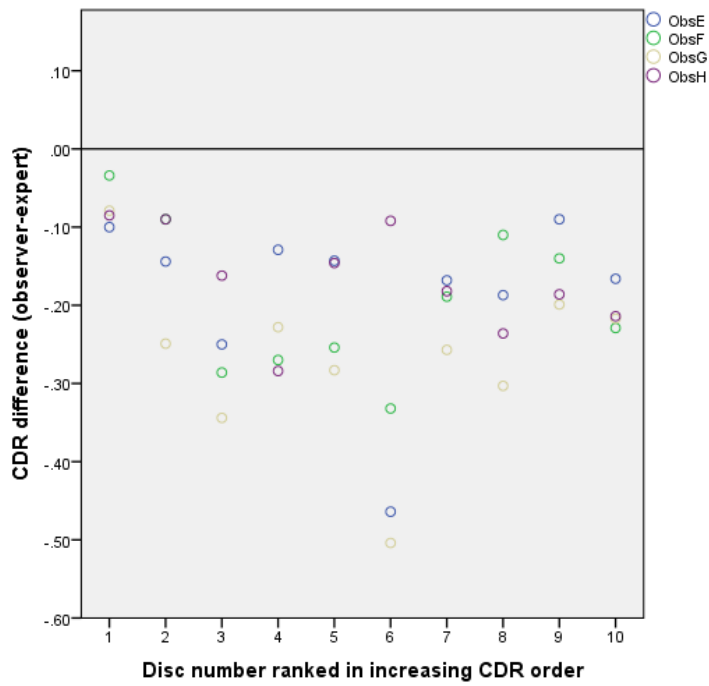
Figure 4.4. Non-anaglyph teaching group A – D, cup-to-disc ratio assessments compared with those of the expert before and after teaching.

The largest difference between any two observers in both of the above comparisons was found with disc number 6, with a difference of 0.42 before teaching and 0.40 after teaching. Before teaching, there were 47.5% of measurements that differed from the assessment made by the expert by ≥ 0.20 units. Following teaching this percentage fell to 5%.

Figure 4.5, shows the same data for observers E- H who were acting as controls for the non-anaglyph test group. Once again the largest difference between the two observers occurred with disc number 6, being 0.41 at the first assessment, but this changed to number 4 following teaching with a difference of 0.29. The percentage of observations that were ≥ 0.20 of the measurements from the expert observer were 47.5% on the first assessment, increasing to 55% on the second assessment.

In both of the above groups, teaching and controls, at the first assessment, all observers under-estimated the cup-to-disc ratio, as compared to the expert opinion. There was no difference in the control group on the second assessment with once again, all the observers under-estimating the cup-to-disc ratio. After teaching 10% of observations were over-estimations, but none of these was greater than 0.10 units.

A Observers first assessment.



B Observers second assessment

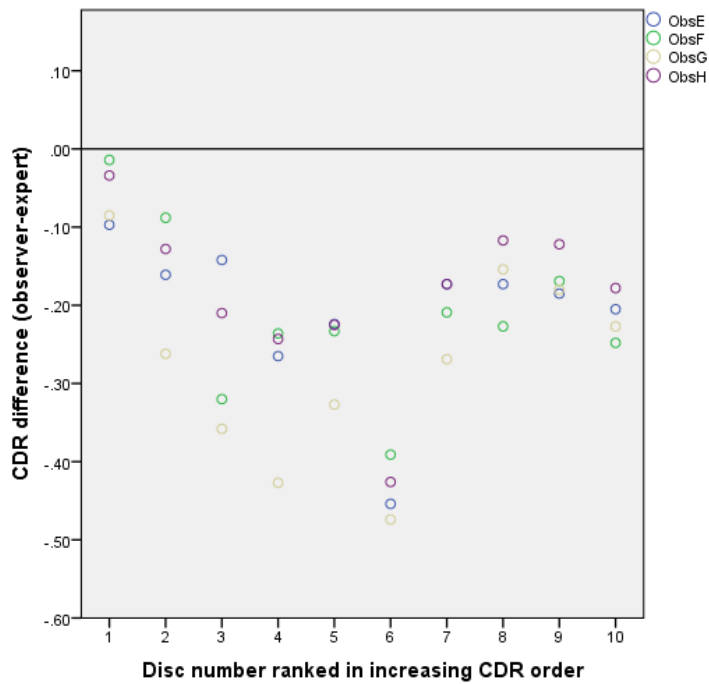


Figure 4.5. Non-anaglyph controls group E – H, cup-to-disc ratio assessments compared with those of the expert at each visit.

Table 4.2. Cup-to-disc ratio differences between each observer and the expert observer and agreement between observers in the non-anaglyph group

Non-Anaglyph test group								
Observer	A	B	C	D	E	F	G	H
1st assessment								
SD of difference	0.111	0.068	0.071	0.093	0.108	0.097	0.110	0.067
RMS	0.251	0.221	0.189	0.204	0.211	0.214	0.286	0.179
ICC for observers A-H = 0.641								
After Teaching								
	A	B	C	D				
SD of difference	0.104	0.062	0.084	0.071				
RMS	0.156	0.073	0.112	0.103				
(t-test) of RMS	0.00005*	0.00050*	0.00563*	0.00884*				
ICC for observers A-H = 0.589								
Control observers								
(No teaching)								
					E	F	G	H
SD of difference								
RMS					0.098	0.107	0.122	0.105
(t-test) of RMS					0.228	0.236	0.300	0.210
					0.30037	0.18770	0.71769	0.66319
ICC for observers E-F = 0.859								

ICC = intraclass correlation coefficient
RMS = root mean square
SD = standard deviation
*Significant difference, P<0.05

From table 4.2, it can be seen that the RMS values for the taught group show improvement in all observers. Paired t-test analysis of the RMS results show significance in all cases.

SD of differences (here used as a measure of variability between expert and observer):

- 1st assessment (All observers) = 0.067 to 0.111
- 2nd assessment (Taught observers) = 0.062 to 0.104
- 2nd assessment (Controls) = 0.098 to 0.122

Intraclass correlation coefficients (ICC) were as follows:

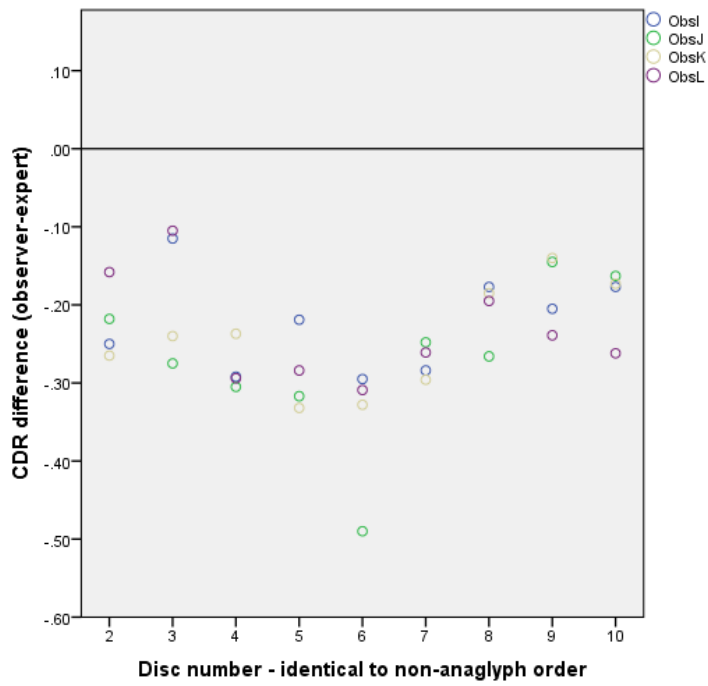
1st assessment (All observers)	substantial
2 nd assessment (Taught observers)	moderate
2 nd assessment (Control)	almost perfect

4.4.2 Anaglyph group results

Figure 4.6 shows differences in the average vertical cup-to-disc ratios between the observers I, J, K and L and the expert before these observers underwent a teaching session, and following their teaching session. The cup-to-disc ratios are ranked along the x-axis in exactly the same order as that used for the non-anaglyph graphs. Information for disc number 1 does not occur in the graphs as this image was unavailable to several of the observers on one occasion during the testing period. For those observers who did undertake the assessment with all 10 images the results can be found in Appendix A.

From Figure 4.6, the largest difference between any two observers in both the above cases was found with disc number 6, with a difference of 0.19 before teaching and 0.48 after teaching. Before teaching there were 64% of measurements that differed from the assessment made by the expert by \geq 0.20 units. Following teaching this percentage fell to 30%.

A Observers before undergoing a teaching session.



B after teaching

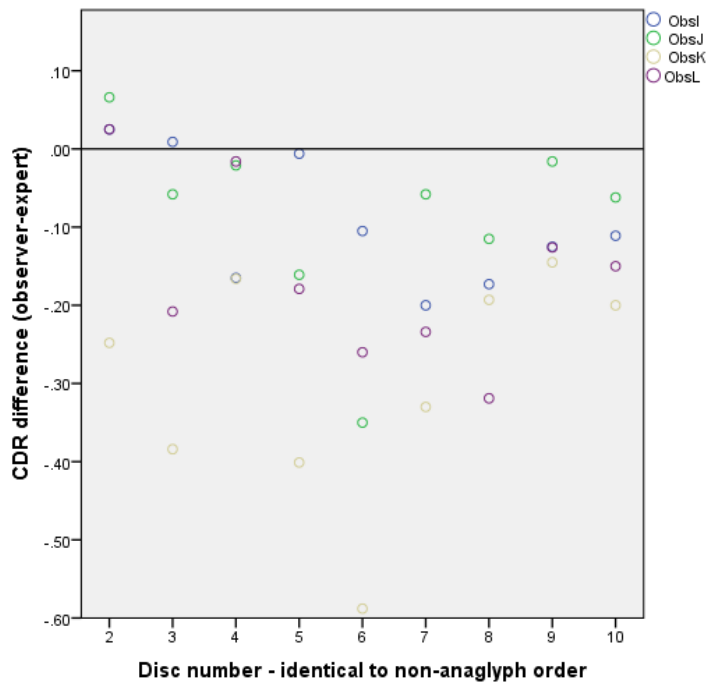
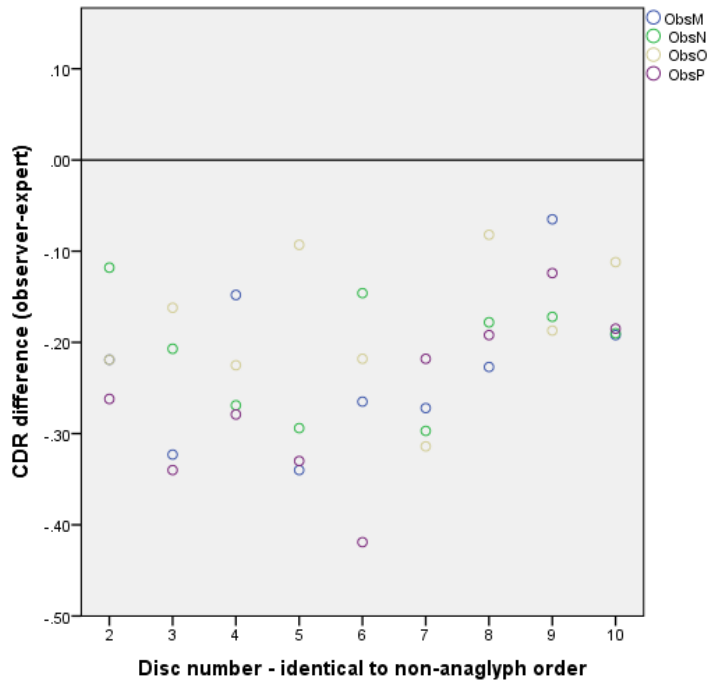


Figure 4.6. Anaglyph teaching group I – J, cup-to-disc ratio assessments compared with those of the expert before and after teaching.

A Observers first assessment



B Observers second assessment

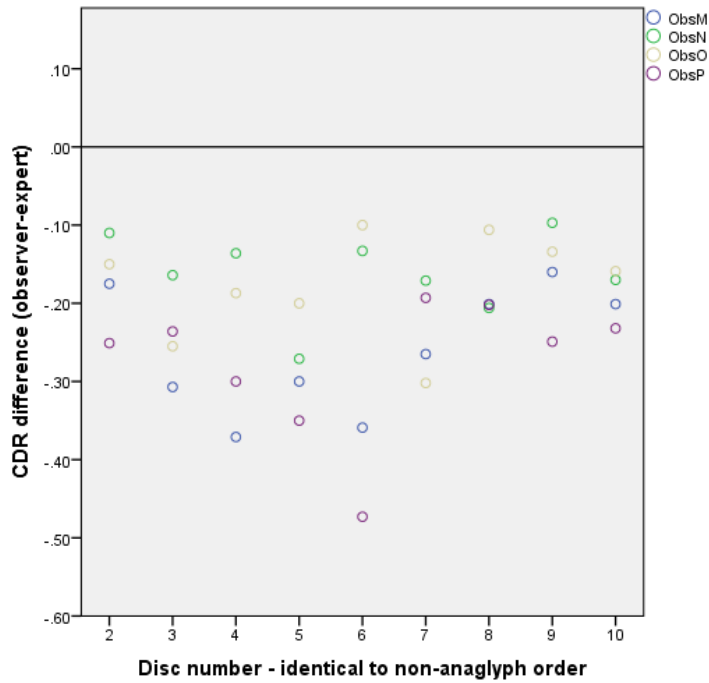


Figure 4.7. Anaglyph controls group M – P, cup-to-disc ratio assessments compared with those of the expert at each visit.

Figure 4.7 shows the same data for observers M - P who were acting as controls for the anaglyph test group. Once again the largest difference between two observers occurred with disc number 6, being 0.27 at the first assessment, increasing, following teaching, to a difference of 0.37. The percentage of observations that were ≥ 0.20 of the measurements from the expert observer were 50% on the first assessment, increasing to 56% on the second assessment.

In both the above groups, teaching and controls, at the first assessment, all observers under-estimated the cup-to-disc ratio, as compared to the expert opinion. There was no difference in the control group on the second assessment with, once again, all the observers under-estimating the cup-to-disc ratio. After teaching 12.5% of observations were over-estimations, but none of these was greater than 0.10 units,

Table 4.3. Cup-to-disc ratio differences between each observer and the expert observer and agreement between observers in the anaglyph group

Anaglyph test group								
Observer	I	J	K	L	M	N	O	P
1st assessment								
SD of difference	0.062	0.101	0.068	0.068	0.086	0.065	0.075	0.092
RMS	0.231	0.286	0.252	0.243	0.242	0.217	0.193	0.275
ICC for observers A-H = 0.749								
After Teaching								
	I	J	K	L				
SD of difference	0.084	0.118	0.144	0.112				
RMS	0.123	0.140	0.325	0.194				
(t-test) of RMS	0.00117*	0.00079*	0.15747	0.14956				
ICC for observers A-H = 0.400								
Control observers								
(No teaching)					M	N	O	P
SD of difference					0.079	0.053	0.067	0.088
RMS					0.270	0.170	0.188	0.288
(t-test) of RMS					0.31077	0.03627*	0.93543	0.48527
ICC for observers E-F = 0.704								

ICC = intraclass correlation coefficient
RMS = root mean square
SD = standard deviation
*Significant difference, P<0.05

‡ Results based on 9 ONH images across all observers

From table 4.3, it can be seen that the RMS values for the taught group show improvement in 3 cases, with 2 showing significance (paired t-test). One observer (K) was worse following the teaching, but the difference was not significant (paired t-test).

SD of differences (here used as a measure of variability between expert and observer):

- 1st assessment (all observers) = 0.062 to 0.101
- 2nd assessment (Taught observers) = 0.084 to 0.144
- 2nd assessment (Controls) = 0.053 to 0.088

Intraclass correlation coefficients (ICC) were as follows:

1 st assessment (All observers)	substantial
2 nd assessment (Taught observers)	fair
2nd assessment (Controls)	substantial

While one observer (K) did not improve performance following the teaching session, one observer (N), found in the control group, improved at the second visit, which was found to be significant (paired t-test).

Disc number 6 was the one that all observers, no matter which type of presentation, had trouble with, leading to ≥ 0.20 underestimation of the cup-to-disc ratio, when compared to the expert observer, in 6.25% of presentations in the non-anaglyph group, and 7% of presentations in the anaglyph group.

4.5 Agreement between the two different methods of stereo-presentation; anaglyph and non-anaglyph

A Bland and Altman plot was constructed to examine the agreement between the different stereo-presentations using the expert observer's vertical cup-to-disc measurements, as determined from anaglyph and non-anaglyph images. Figure 4.8 shows the results obtained.

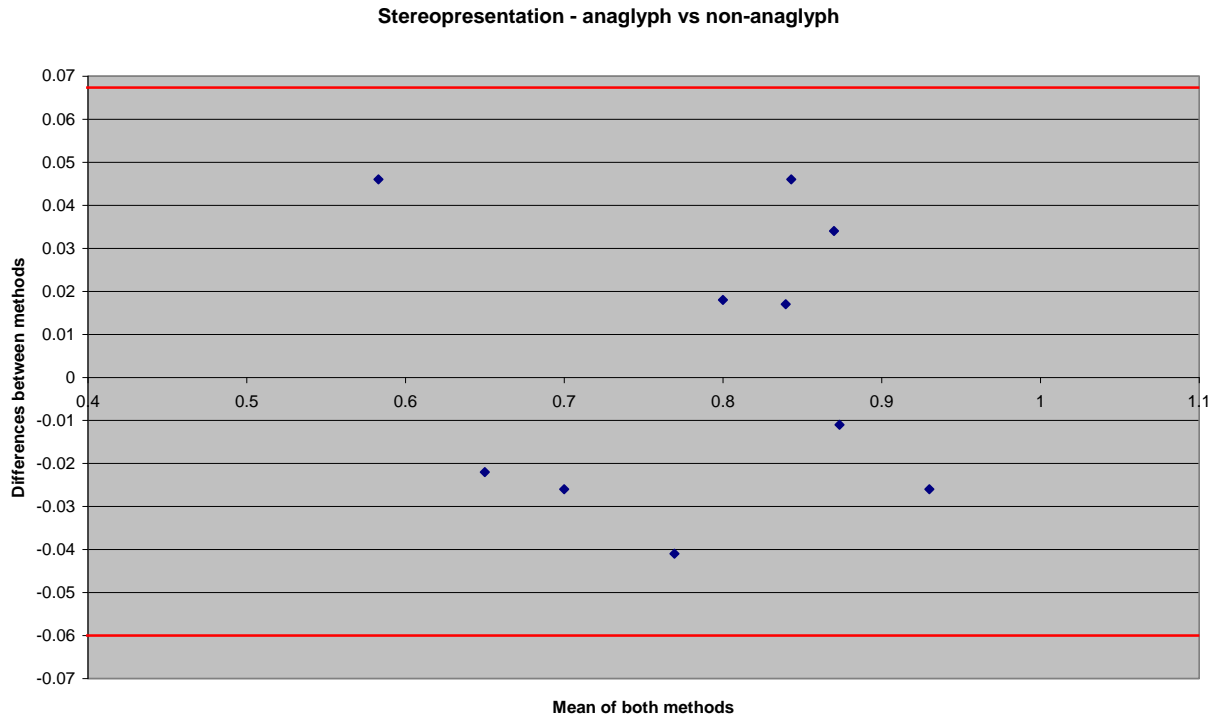


Figure 4.8. Bland and Altman plot showing the level of agreement between cup-to-disc ratios as determined by the two methods of stereopresentation (red lines denote the upper and lower limits of agreement).

The average discrepancy (bias) between the methods was not significant in the clinical setting. There were no outliers and all differences were within 0.05 units. There was no trend and variability looked consistent.

4.6 Discussion

In order to develop a web-based teaching protocol for optic nerve head assessment that utilises stereo-images (one possible utilisation of the software used in this study), it is necessary that the images can be viewed without the need for expensive equipment that may not be available to many practitioners. Also, if additional requirements are needed to view the images, the cost of distributing these to practitioners should be minimal. For this reason it was considered that anaglyphs could be used for this purpose as cardboard red-cyan spectacles are the cheapest way of viewing suitable anaglyphs. To this end there was a need to determine if the performance of this type of stereopresentation was equivalent to other more expensive methods of 3D display and if, following teaching, whether an improvement could be shown using this technique of presentation that could be compared to the alternate more expensive presentation method. While a previous study at Cardiff University made use of Z-Screen technology (Morgan et al. 2005b), for the purpose of this study a more moderate priced set-up (4.2) was employed.

As stated above, the cost of red-cyan spectacles is minimal as this is the commonest way of viewing anaglyph images available. However, it is not the only way and it is known that it suffers from several problems since anaglyphs, in general, present a compromised image to the observer. These problems are: ghosting, retinal rivalry and, of course, incorrect colours. It was not part of the study to compare the performance of different anaglyph set-ups, or indeed to present a detailed discussion on the subject, but it is

important to note some points relating to anaglyphs. Ghosting, or crosstalk, is where there is leaking of one image to the eye that is not supposed to be seeing the information. This results in a loss of image quality and difficulties with fusion of the images (Woods et al 2007). Display monitors and anaglyph spectacles both contribute to anaglyphic crosstalk. The anaglyph images used in this study were simply produced by means of Z-Anaglyph software (freeware download copyright Mr G Rosset) and had no further image manipulation, such as adjustments to the colour channels, colour saturation or the placing of zero parallax, which would be the feature that appeared on the surface of the monitor. Also, the images being viewed were predominately orange/red so the information in the 'parallax detector channel' had a limited range of information available. Given the large number of variables concerned in anaglyph formation, it is probably impossible to provide one optimum image, although for a single given computer based set-up, as opposed to a web-based set-up, it could be possible to optimise the images. One potentially different route would be the use of monochromatic anaglyphs. (Stone et al. 2010) looked at monochromatic stereo-images of the optic nerve head viewed with a stereoscope and found that colour added little to the quality of optic disc parameters, finding that greyscale viewing of the blood vessels and retinal nerve fibre layer was superior. They made the point that, given the restricted colour range of fundus images, colour does not provide additional information over luminance in greyscale images. Most colour sensors are good at recording a full spectrum of colours, but have a difficult time in rendering subtle colour differences in the red, orange and yellow range (Bennett 2009). The linear way in which sensors respond to light, results in a

lack of exposure latitude as compared to film, but this is not restricted to imaging in colour. When imaging in monochrome, blooming or blown highlights are commonly encountered, and need to be addressed not just in terms of exposure but may also need the careful adjustment of gain and gamma. This is especially important as high resolution colour sensors are not fundamentally designed for use in a greyscale mode. Practically this means that if the sensor has a Bayer colour array, high gain settings are required to compensate for the reduction in sensor sensitivity to light loss due the array itself (Bennett 2009). It is probably reasonable to assume that few fundus cameras are subjected to image exposure tests, to set baseline gamma and gain settings, but this should be an essential part of instillation, especially if images are to be recorded in monochrome.

4.6.1 Performance of anaglyph images

When comparing the agreement between the two different stereo-presentations using the results obtained from the expert observer, it was found that the average discrepancy (bias) between the methods was not significant in the clinical setting. There were no outliers and all differences were within 0.05 units. This suggests that the performance of the two stereo-presentations is comparable, as it was also found that the expert observer's results in determining the optic disc rim and cup were highly correlated, with almost perfect agreement between the two methods (ICC = 0.957 $p = < 0.0005$). If there were differences in the presentations, it would be expected

that the performance of the two different observer groups would reflect this, but when the RMS differences between the two observer groups was scrutinised before teaching, this also revealed comparable ranges. The non-anaglyph range was 0.179 to 0.286, compared to anaglyph range which was 0.193 to 0.286. It would be expected, therefore, that there should be a similar performance using both stereo-presentations with regards to the results following the teaching sessions that selected observers undertook. From the results for the non-anaglyph teaching group, it can be seen that the RMS differences were improved and the paired t-test results showed these to be significant for all four observers, ranging from 0.073 to 0.156, as compared to the non-anaglyph control group, where the range was found to be from 0.210 to 0.300. However, for the teaching group in the anaglyph presentations, improvement in the RMS differences was not as clear as in the non-anaglyph group with only two observers showing a significant difference on paired t-test. These two results were within the range found for the non-anaglyph teaching group, but of the remaining two observers, one showed an improvement from 0.243 units, before teaching, to 1.194 after teaching, although this change was not significant. The final observer did not show any improvement and, indeed, was worse following teaching, an effect also found by (Sheen et al. 2004) in one of their observers. Sheen et al. commented that teaching is beneficial for most, but not all observers, and concluded that one use of their teaching programme could be to screen observers to identify those individuals requiring more comprehensive training. However, because there were only four observers in this group, the effect of observer K's performance makes it difficult to be sure if the use of anaglyph images can be

considered to give a truly comparable result to a more expensive method of stereo-presentation.

Given that the performance before teaching is comparable, it may be that the group of observers in the anaglyph teaching group contained naïve observers that did not respond to the teaching programme as readily as to those in the non-anaglyph group. It would have been informative if the teaching groups had been swapped and asked to evaluate the stereo-images for a further time using the method of their corresponding group to see if the if the results obtained reflected the observers per se, or the method of presentation of the images. However, this was not included in the study and so the results, to an extent, are equivocal for the anaglyph test group.

It was expected that second year optometry students would represent a relatively naïve group of observers, but they have had some exposure to glaucomatous changes. They would be aware of the determination of cup-to-disc ratio from their studies so far and this may explain the level of agreement amongst these observers at all stages of the study, when compared with the naïve observers previously used for evaluating a teaching programme (Sheen et al. 2004). An ICC agreement, from their study prior, to teaching was 0.37, compared with an ICC of 0.749 and 0.641 for the anaglyph and non-anaglyph groups in this study.

It is not clear why one observer in the anaglyph control group significantly improved their performance. Observer N may have simply performed better

on the second assessment, or it may be that this observer, knowing that they would be asked to undertake the test again, could have undertaken some personal study on the determination of the optic disc and neural retinal rim. None of the observers were given any instructions on not undertaking personal study between the two assessments. However, it does appear that limited, but targeted, training of relatively naïve observers can yield significant improvement in the accuracy of determination of optic disc margin and neural retinal rim, since it was observed that the majority of observers who underwent the training improved their ability, as measured by RMS difference of cup-to-disc ratios with the expert observer.

4.6.2 Study methodology

When the images were selected for the test set, set A, (see Appendix B), no consideration was given to the difficulty of the discs with regard to assessing their cup-to-disc ratio. In clinical practice, some discs are more difficult to estimate than others, and this may be due to several factors relating both to the observer, and the patient being observed. One such factor is where identification of the cup rim is different when considered in terms of the 'contour' of the neural retinal rim (the cupping), as opposed to the 'pallor' of the disc. Pallor is described as, the maximum colour contrast, or the area of optic disc lacking small blood vessels (Kanski 1989). These do not necessarily have to correspond, and as such is an example where disagreement between observers as to the position of the cup rim can occur. Hence, not having taken into account factors such as this one; there was no

attempt to grade the complexity of the disc. Review of the images selected for the test set, shows this could be a probable reason why image number 6 was the one that had the worst agreement between the expert observer and the naïve observers in all the groups, as this appears to be an optic nerve head where the cupping does not coincide with the pallor, as opposed to the other images in the set. The simple expedient of asking the expert observer to grade the complexity of the discs may have led to removal of this at a pre-testing stage, or at least been able to allocate a degree of difficulty to the images being used.

One area which is open to criticism is the time between the first and second assessments for some of the naïve observers. While it would have been better if all observers repeated their assessments within a shorter time frame, this was not possible due to the difference in geographical location of the observers and the author. This distance, together with having to arrange assessment times around a full time post at North Devon District Hospital, led to limited opportunities to attend Cardiff University. In addition, the second year students were not always available due to time-table changes that meant their free periods were used for additional lectures and visits, limiting the dates available to conduct assessments even further. None of the observers who underwent the training session with Prof J E Morgan (Professor in Ophthalmology, Consultant Ophthalmologist), undertook the second assessment any later than one week after this session, so that there was no delay in testing the effect of this training. It could be questioned, what effect repeating the assessment after a longer interval had elapsed as compared to

a shorter interval, may have had on the observer's performance. At each assessment, whether first or second, the observers were given the same instructions on what was required and shown how to use the software. However, it must be considered that this may not have negated the effect of different intervals between assessments for the observers if this was a source of bias.

Chapter 5 Barnstaple study 1, Cup-to-disc ratio assessments

Two smaller studies were undertaken in the Optometry Department at North Devon District Hospital, Barnstaple.

It is not uncommon in UK ophthalmology departments for different professional practitioners to be involved in glaucoma assessment and for these practitioners to have varying levels of experience (Vernon and Adair 2010). At the North Devon District Hospital, glaucoma care is undertaken by ophthalmologists led by a glaucoma specialist, with middle grade medical staff assisting, and including optometrists, an orthoptist and other practitioners, such as clinical nurse specialists and an imaging technician. All practitioners involved in the glaucoma clinics have varying experience and training.

5.1 Cup-to-disc ratio assessments

5.1.1 Aim of study

The aim was four-fold:

The first aim was to determine the ability of the various practitioners in the glaucoma clinics to accurately determine the cup-to-disc ratio, as this is important for the detection and monitoring of glaucomatous optic neuropathy

The second aim was to determine the relationship between the cup-to-disc ratio subjectively determined by viewing stereoscopic discs and those derived from the StereoDxT software by practitioners involved in glaucoma clinics.

The third aim was to compare the levels of agreement between the glaucoma clinic practitioner and those relatively naïve observers from Chapter 4 who underwent training in recognition of the optic disc and cup margin.

The fourth aim was to compare the grading of the glaucomatous status of each disc by the practitioners involved in the glaucoma clinics with the determination of that made by the Clinical Lead for Glaucoma (CLG).

5.1.2 Method

Ten glaucoma practitioners from several professional groups, covering ophthalmologists, optometrists, clinical nurse specialists and an orthoptist who make up the full glaucoma team at North Devon District Hospital, agreed to undertake the study. One of the ophthalmologists is the Clinical Lead for Glaucoma (CLG) and hence acted as the expert observer for this part of the study, leaving 9 practitioners to act as professional observers. The number of years experience ranged from less than 1 year to 28 years of experience in glaucoma clinics or the detection of glaucoma. The distinction between 'experience' in glaucoma clinics and 'detection' of glaucoma comes from the fact that several practitioners, who do not take part in glaucoma detection, being involved in follow-up clinics which are either medically or non-medically led. As some ophthalmologists with extensive experience of glaucoma detection have only joined the glaucoma service recently, simply recording the number of years involvement in glaucoma clinics did not accurately reflect the true experience of these practitioners. The range of years of experience describes those practitioners who have gained considerable experience at examining glaucoma and suspect glaucoma cases, as well as those practitioners who have several years experience in the glaucoma team, but are involved in follow-up of patients only. This is not to say that the ability of those not involved in glaucoma detection at the initial point of referral are in any way less able to recognised the signs of glaucomatous optic neuropathy.

The Barnstaple Glaucoma Practitioners (BGP) used the non-anaglyph method of viewing the stereo images (4.2). The number of images from Set A they were asked to view was reduced from ten to five, but they were also asked, prior to outlining the optic disc rim, and the neural retinal rim to subjectively estimate the cup-to-disc ratio, as would be the case if they were examining the discs in a clinical setting.

For the comparison with the naïve Cardiff observers, the BGP were assessed against the glaucoma expert observer. For all other measurements, the same practitioners were compared with the results of the CLG, since in the normal clinical examination of patients this person would have the final say on the determination of the optic nerve head features.

Each observer in the BGP group was also asked to determine if the optic disc images viewed appeared to be normal, suspicious of glaucoma, or glaucomatous. They were not asked to take into account any other features apparent in the disc images, although it may be expected that they might have used these in their deliberations.

This part of the study was approved by the Northern Devon Healthcare NHS Trust Research and Development Office.

5.1.3 Results

The same methods were employed to measure variability and agreement between observers and the two expert opinions (expert observer and the CLG) as in Chapter 4. In addition, the agreement between the CLG, with limited exposure of the system, and the expert observer was calculated. Agreement between the clinical estimated values and actual values measured by each observer planimetrically were also calculated.

5.1.3.1 Planimetric values BGP compared to expert observer and CLG

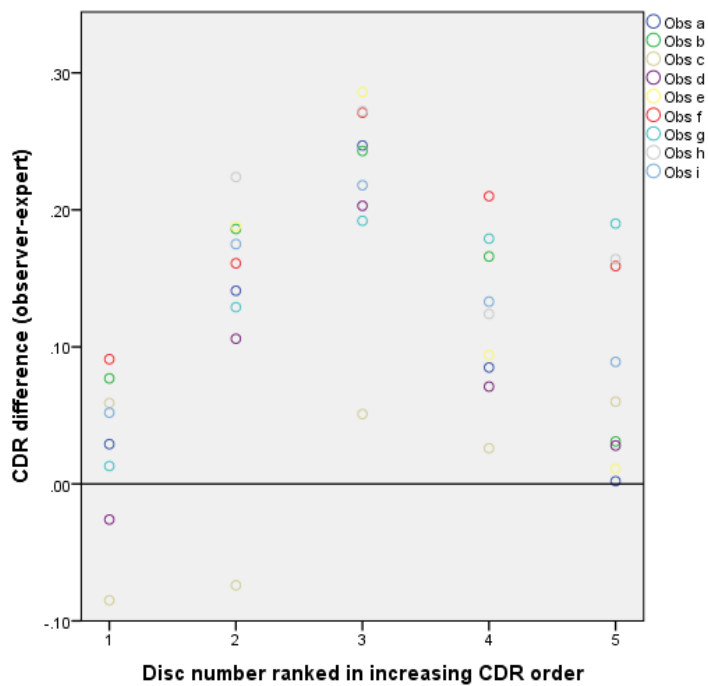


Figure5.1. Cup-to-disc differences between the BGP and expert observer

When comparing the BGP to the expert observer, the largest difference in cup-to-disc ratio between any two observers was found with disc number 2,

with a difference of 0.29. It was found that 20% of the measurements differed from the assessment made by the expert observer by ≥ 0.20 units.

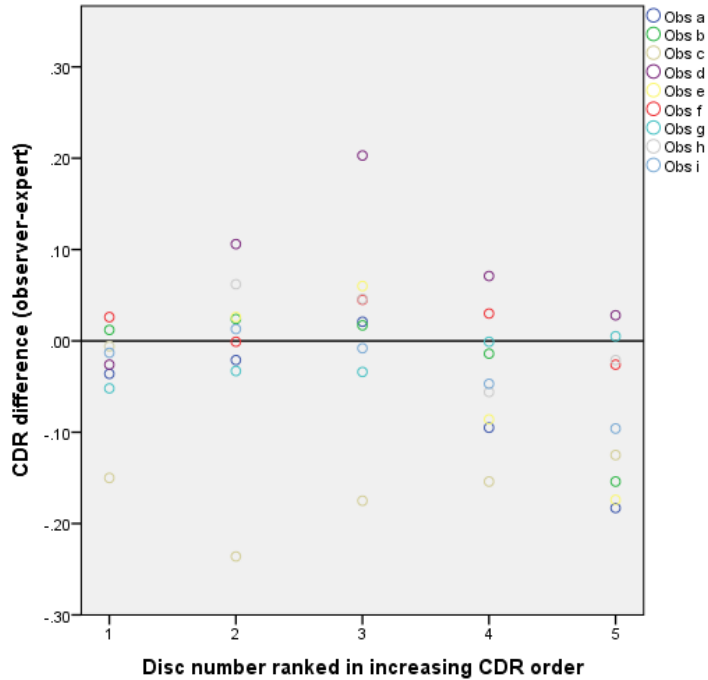


Figure 5.2. Cup-to-disc differences BGP and CLG Barnstaple

When comparing the BGP to the CLG, the largest difference between any two observers was found with disc number 3, with a difference of 0.38. It was found that 4% of the measurements differed from the assessment made by the CLG by ≥ 0.20 units.

Table 5.1. Cup-to-disc ratio differences between BGP, the expert observer and CLG

Barnstaple Glaucoma Practitioners group									
Cardiff Expert									
Observer	a	b	c	d	e	f	g	h	i
SD of difference	0.098	0.086	0.07	0.086	0.11	0.067	0.076	0.083	0.066
RMS	0.133	0.160	0.063	0.109	0.161	0.188	0.156	0.184	0.146
ICC for observers a-i = 0.912									
Barnstaple expert (CLG)									
Observer	a	b	c	d	e	f	g	h	i
SD of difference	0.079	0.075	0.042	0.051	0.094	0.028	0.024	0.049	0.043
RMS	0.095	0.071	0.172	0.098	0.092	0.029	0.032	0.044	0.049
t-test of RMS	0.68818	0.18655	0.00466*	0.99439	0.44282	0.00461*	0.05025	0.01479*	0.06838
ICC for observers a-i = 0.912									

ICC = intraclass correlation coefficient
RMS = root mean square
SD = standard deviation
*Significant difference, P<0.05

Table 5.1, shows the RMS differences of cup-to-disc ratios between each of the 9 glaucoma practitioners and the expert observer’s assessment using the StereoDxT software, along with the RMS differences between them and the Clinical Lead for Glaucoma (CLG) North Devon District Hospital. All observers, except two showed larger differences when compared with expert observer rather than the CLG. Of the remaining 2 observers, observer c showed a reverse trend, with less difference compared with the expert observer rather than the CLG. The second remaining observer, ‘d’, showed no difference when compared to each of the expert observers.

SD (here used as a measure of variability between expert observer, CLG and the BGP):

Compared to expert observer = 0.066 to 0.11

Compared to CLG = 0.024 to 0.094

There was almost perfect agreement between the BGP, with an Intraclass Correlation Coefficient (ICC) of 0.921.

Despite the differences between the BGP, the expert observer and the CLG, only four (including observer g) showed significantly different planimetric determinations between the expert observer and the CLG (paired t –test).

The RMS differences would not be accepted as clinically significant, however they do not reflect the percentage number of assessments that were ≥ 0.20 and would, in practice, be accepted as clinically significant (Sheen et al. 2004).

5.1.3.2 Subjective assessment of cup-to-disc ratio differences between BGP and CLG

Table 5.2. Subjective cup-to-disc ratio differences BGP vs CLG

Barnstaple Glaucoma Practitioners group									
Observer	a	b	c	d	e	f	g	h	i
SD of difference	0.079	0.075	0.042	0.051	0.094	0.028	0.024	0.049	0.043
Subjective assessment RMS	0.114	0.06	0.044	0.059	0.063	0.104	0.114	0.116	0.059

ICC for observers a-i =0.881

Table 5.2 shows the results for the differences in cup-to-disc ratio between the subjective assessment of the disc images, as would be the case in a clinical examination between the observers and the CLG. None of the differences were ≥ 0.20 units (range 0.044 to 0.116).

5.1.3.3 BGP differences between subjective and planimetry assessments

Table 5.3. Cup-to-disc ratio differences subjective vs planimetric assessments BGP

Barnstaple Glaucoma Practitioners group									
Observer	a	b	c	d	e	f	g	h	i
SD of difference	0.079	0.072	0.136	0.038	0.037	0.051	0.125	0.128	0.065
Observers difference subj vs plan RMS	0.079	0.065	0.158	0.078	0.034	0.049	0.112	0.116	0.060
ICC for observers a-i =0.912									
subj = subjective plan = planimetry									

Table 5.3 shows the difference in the value given by each observer subjectively, as would be the case in a clinical examination, compared to the value that they measured planimetrically using the StereoDxT software. Once again, there was no differences ≥ 0.20 units (range 0.034 to 0.158).

5.1.3.4 BGP assessment of glaucoma status of each image

Finally, and while it is extremely difficult to make assessment of the glaucoma status of any patient based purely on the appearance of the optic nerve head,

this question was asked of the observers and compared against the determination of the CLG. The grading was a simple 4 point scale as follows:

1 = normal

2 = possible glaucoma

3 = probable glaucoma

4 = glaucoma

Table 5.4. BGP assessment of the glaucoma status of each viewed disc

Disc	CLG	a	b	c	d	e	f	g	H	i
1	1	1	1	3	1	1	2	1	1	2
2	1	1	1	1	1	1	1	1	1	1
3	1	1	1	3	1	1	3	4	2	3
4	3	4	3	4	3	3	2	2	4	4
5	4	4	4	4	4	4	2	3	4	4

Red numbers indicate where practitioners differed from the CLG, whereas black are where they are in agreement. The CLG assessments are the blue numbers.

64% of the classifications agree with the CLG. Of the 36% that did not, only a quarter were classified as a lower grade than the CLG, the other three

quarters over-estimating the grade, meaning that the observers were more suspicious of glaucoma, which would be better in clinical practice than classifying an optic disc as less suspicious when glaucoma was present. Only one disc was graded the same by all observers and the CLG.

Interestingly, one of the images presented had a very apparent nerve fibre layer bundle defect visible, but not one of the observers commented on this and, when questioned, reported that they did not notice this feature. While this is not conclusive evidence that the observers did not take any other features apart from the appearance of the optic nerve head into account when determining the glaucoma status, it does suggest that any other less obvious clues may have been overlooked.

It should however, be appreciated that the task asked of the BGP, was not one that would have occurred in clinical practice. In clinical practice, other information would have been available, such as, ocular/medical and family history, intra-ocular pressure, visual field status, all of which would have informed the final clinical decision. If this information was available, it may have resulted in a different level of agreement between the BGP and the CLG. It would be tempting, to assume that the agreement would have been improved, since combining test results, leads to a greater sensitivity and specificity as found by Harper and Reeves (1999).

5.1.4 Discussion

There was a difference in opinion between the expert observer and the Clinical Lead for Glaucoma (CLG) as to the cup-to-disc ratio of the test discs with one difference being ≥ 0.20 units, which would be considered clinically significant (Sheen et al. 2004). As previously stated, the agreement between observers varies and this is no different for glaucoma experts, so it is not surprising that the results differ between the two experts in this study.

The RMS of differences between the Barnstaple Glaucoma Practitioners (BGP) and the expert observer were higher than those between the same observers and the CLG. When considering these values in relation to the naive observers the following was found:

Naïve observers

Non-anaglyph group

All observers at first assessment RMS = 0.179 to 0.286

Taught observers at second assessment RMS = 0.073 to 0.156

Control observers at second assessment RMS = 0.210 to 0.300

Anaglyph group

All observers at first assessment RMS = 0.193 to 0.286

Taught observers at second assessment RMS = 0.123 to 0.325

Control observers at second assessment RMS = 0.170 to 0.288

Barnstaple Glaucoma Practitioners

All observers RMS = 0.063 to 0.188

The RMS of difference values are derived from varying numbers of disc assessments between the different groups, non-anaglyph, anaglyph and BGP. The non-anaglyph group viewed 10 discs, the anaglyph group viewed 9 or 10 discs (see 6.1) and the BGP group viewed 5 discs. When comparing the results of the anaglyph group, the values show minimal difference between the RMS values for 9 or 10 images. The results table for those anaglyph observers who assessed 10 images can be seen in Appendix A.

Therefore, the values of the BGP are as expected, and were better than the naïve observers from Cardiff, and, after a number of observers in the non-anaglyph group were given instruction in the correct determination of the optic disc and neural retinal rim, their results rival those of the BGP group.

When comparison is made in relation to determination of the Clinical Lead in Glaucoma (CLG), the range of RMS differences of cup-to-disc ratio is from 0.029 to 0.172, which does not reflect the fact that, except for one observer (c), all of the RMS differences were < 0.10 unit. The reason for this improvement may be that all the practitioners in the BGP group have had exposure, although not through a taught programme, from the CLG to determinations made by the CLG in the case notes when following patients in glaucoma clinics, except, interestingly, observer c, who was the one practitioner with the greatest difference from the CLG and who has only had a few months exposure to the glaucoma clinics in North Devon District Hospital, none of which have been with the CLG. Furthermore, none of the RMS differences between the BGP and either expert were ≥ 0.20 units however.

Part of the study was to examine how the observers 'clinical determination' of the cup-to-disc ratio, (that is the subjective measure of the cup-to-disc ratio based on their preferred method of determining this in a clinical setting), related to the result obtained when the optic nerve was viewed and outlined with the StereoDxT software. The question was whether the clinical examination of the optic nerve head (in this case made through looking at a stereo-image of the optic nerve head) matched the planimetric determination. The results showed that, except for three observers, all differences between the two determinations were < 0.10 unit. It is tempting to suggest that it may be possible to substitute the clinical examination with the 'virtual' review of optic disc images in three dimensions, however, in this case, both the 'clinical

examination' and the 'virtual' were made on the same optic disc image. It may be that viewing the optic nerve head in a truly clinical setting making use of ncBIO lenses and slit-lamp biomicroscopy may not yield a similar result. It was not the scope of this study to address the question of true clinical examination versus 'virtual' assessment, nor whether there would be differences in two different stereo-software presentations, as it may be that different planimetry software may also result in differences.

Chapter 6 Barnstaple study 2, Factors that influence assessment of the ONH dimensions using ncBIO lenses

This experiment was carried out to address the performance of different ncBIO lenses in the measurement of optic disc height and the effect of ametropia and different positioning of the lens relative to the eye. This was to test the assumption that these lenses are of a telecentric design in use within the clinical setting. If this was not the case then there would be differences found in the measurement of heights of objects under differing conditions, and, therefore, that the magnification factor given by manufacturers' of these types of lenses would not hold true. If errors did occur, this could be a source of mis-classification of optic nerve head measurements in a clinical setting and could have significance in the determination of whether glaucomatous optic neuropathy was present or not.

6.1 Method

The study made use of an artificial eye used for training retinoscopy /ophthalmoscopy. The 'eye' had a drawn image of a retina placed in the retinal plane. The artificial eye was then viewed using different ncBIO lenses of varying powers and design, in conjunction with a standard slit-lamp biomicroscope (Haag Streit 900 BQ, Haag-Streit UK). The height of the slit-lamp beam was adjusted to align with the simulated optic disc vertical dimension, as is standard practice in clinical examination of the optic nerve head. A beam width of 1.6 mm was used in the examination. The artificial

eye was held in place conveniently between the chin rest and brow rest of the slit lamp (see Figure 6.1).

Measurements of the object height were made while adjusting the axial length of the artificial eye to cover the range of ametropias from +5.00 dioptres to -5.00 dioptres. Additional trial frame lenses were used to increase the artificial eye range from +3.00 dioptres to +5.00 dioptres. This obviously resulted in a mix of axial and refractive ametropia. While the intention was to continue to increase the range past these limits, with the use of trial lenses it was found that the inability to focus and/or reflections from additional surfaces made this impossible with differing ncBIO lenses.

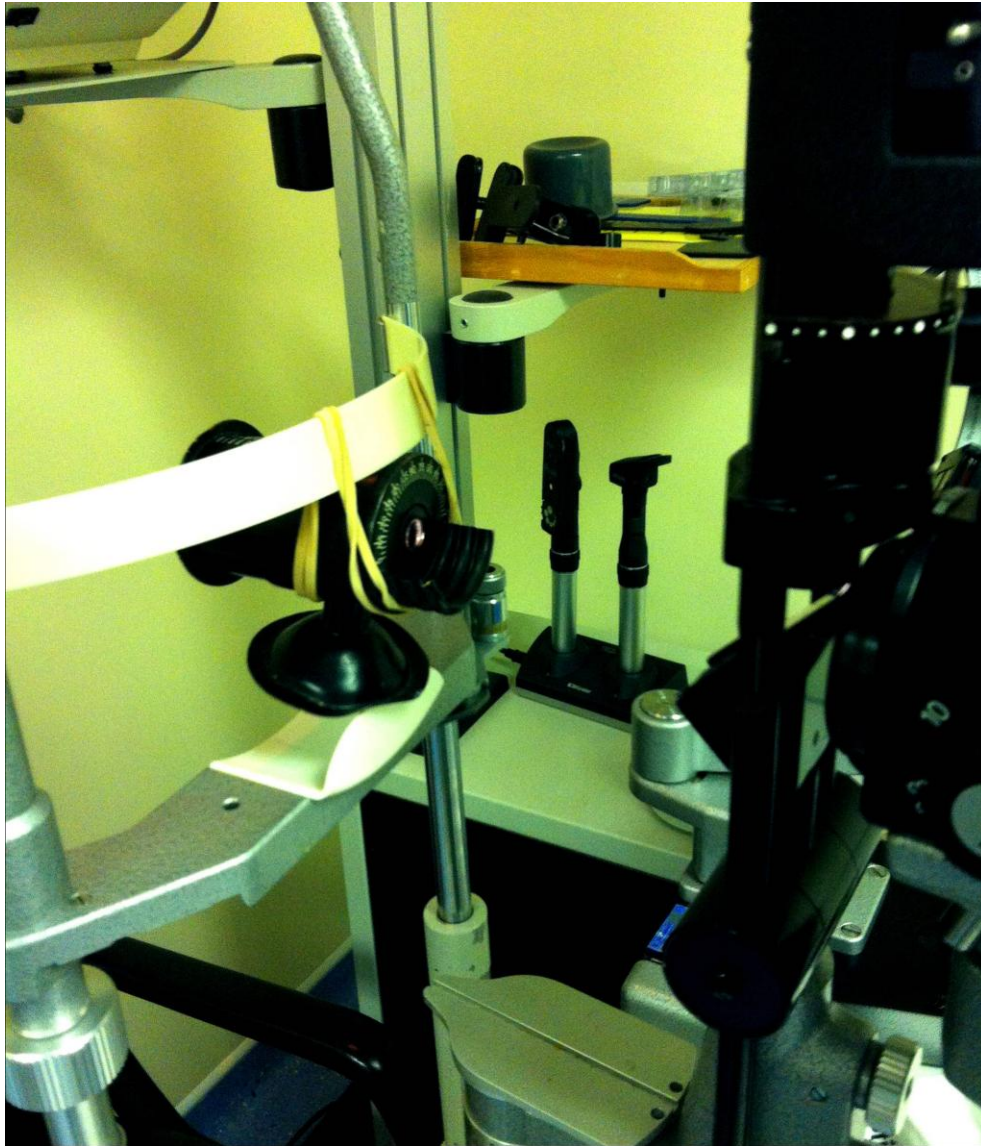

Figure 6.1. The artificial eye mounted on the slit lamp showing the lens holder in which the ncBIO lenses were placed.

Again, conveniently, the artificial eye's lens holder made it possible to easily place each ncBIO lens in the same place for measurement as the lenses used have two 'knurled' rings, which are separated by 3 - 4 mm depending on particular ncBIO lens (see Figure 6.2). This allowed the lenses to be moved by a set distance in order to determine if the lens position had any effect on the measurements obtained for the height of the 'disc' for each ncBIO lens.

The lenses were initially used in position 1 and then moved to position 2 (see Figure 6.2).




Figure 6.2. Knurled rings and the positions the lenses were placed in the artificial eye lens holder

In determining the height of the 'disc', if the measurement fell between two points on the mm scale of the slit lamp beam adjustment then the lower measurement was recorded, as would be the case in the clinical situation, so that any measurement of the cup-to-disc ratio would be viewed relative to a smaller disc diameter, to err on the side of caution when determining the significance of the cup-to-disc ratio.

Four ncBIO lenses were used in this study. All were from (Volk Optical Inc., Mentor, OH) and their details as described by the manufacturer can be seen in Table 6.1.

Table 6.1. Summary of the field of view, magnification and working distance of the ncBIO lenses according to manufacturer.

Lens	Field of view (Degrees)	Image magnification	Laser Spot	Working distance (mm)
Digital High Mag	57/70	1.30 x	0.77 x	13
Super 66	80/96	1.0 x	1.0 x	11
Super Field	95/116	0.76 x	1.3 x	7
90D	74/89	0.76 x	1.32 x	7

Despite a quoted working distance from the manufacturer, clinically these lenses are able to form an image that can be viewed over a range of positions relative to the front of the patients' eye and the working distance is probably not questioned by most practitioners. Table 6.2 shows the distance from the front of the artificial eye to the front of the lens for both positions used for measurement.

Table 6.2. Distances from front of lens to front of artificial eye

Lens	Position 1 (mm)	Position 2 (mm)
Digital High Mag	9	13
Super 66	7	10
Super Field NC	7	10
90D	13*	N/A*

Distances in bold indicate that the lens was at the manufacturer's recommended working distance, whereas those not in bold were not at the manufacturer's recommended distances. Distance in red indicates that the lens was only 1mm different from the manufacturer's working distance.

* In position 1, this lens had to be raised away from the lens holder and, as such, there was the potential for error in working distance. However, the hand holding the lens could maintain its resting position against the lens holder, which could not occur with position 2, hence no measurements were made for this lens at this position.

Consideration was given to making multiple measurements of the 'disc' height, but this is not what occurs in routine clinical practice and therefore only one measurement was made.

6.2 Results

None of the four lenses showed consistent measurement of the 'disc' size over the range of ametropias from -5.00D to +5.00D. Figure 6.3, shows the disc measurements when the lenses were tested in position 1, and Figure 6.4, when measurements were made in position 2. In Figure 6.3 most of the values for the Super Field NC and the 90D lenses overlap, which is what would be expected, as the Super Field NC is often described as a wide-angle 90D, and both lenses share the same magnification as described by the manufacturer.

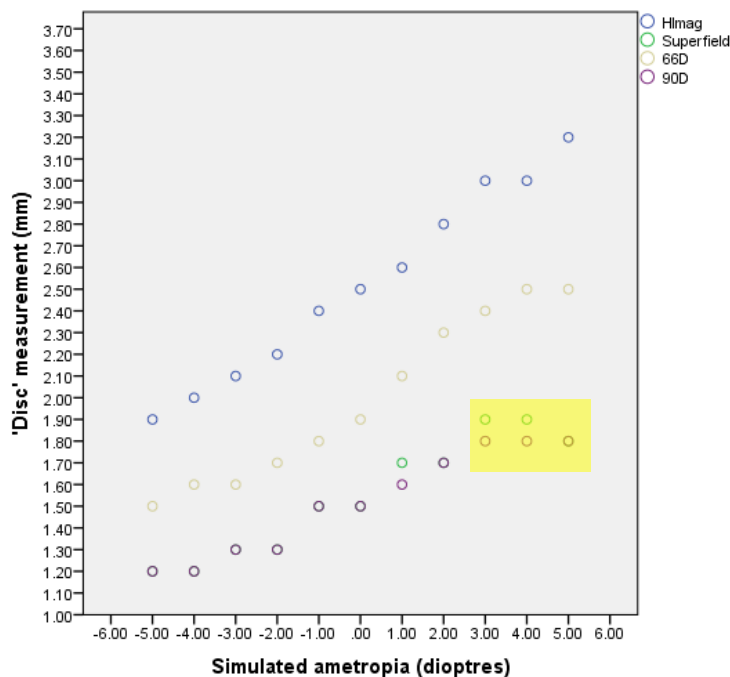


Figure 6.3. Slit-lamp measurement of 'disc' height (mm) with lenses in position 1. Simulated ametropias from -5.00D to +3.00D are axial whereas those for +4.00D and +5.00D are axial and refractive.

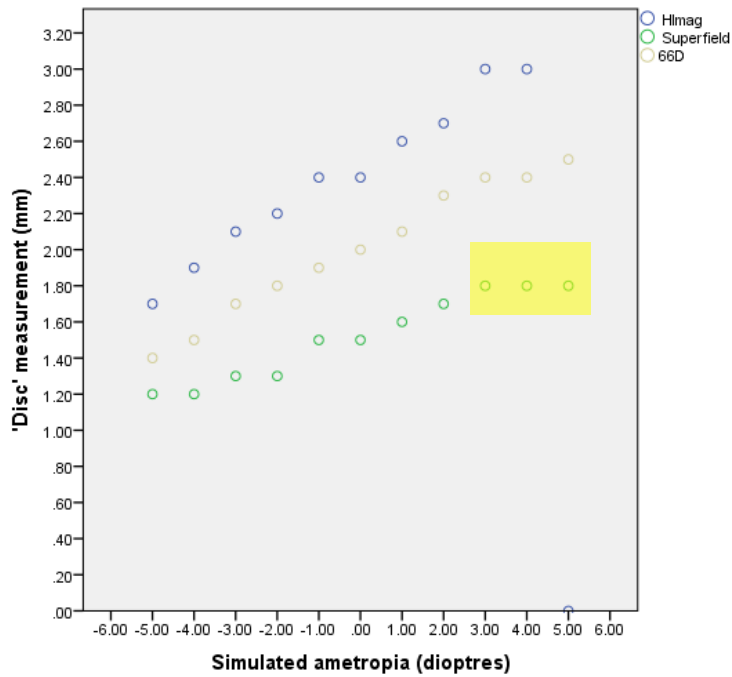


Figure 6.4. Slit -lamp measurement of 'disc' height (mm) with lenses in position 2. Simulated ametropias from -5.00D to +3.00D are axial whereas those for +4.00D and +5.00D are axial and refractive.

In both positions, all lenses resulted in a smaller reading of the painted 'disc' when the simulated ametropia was myopic, with the largest readings occurring when the simulated ametropia was hypermetropic. Where the simulated ametropia was made up of both axial and refractive elements, the 90D and Super Field NC appear to plateau in both positions 1 and 2 (highlighted area).

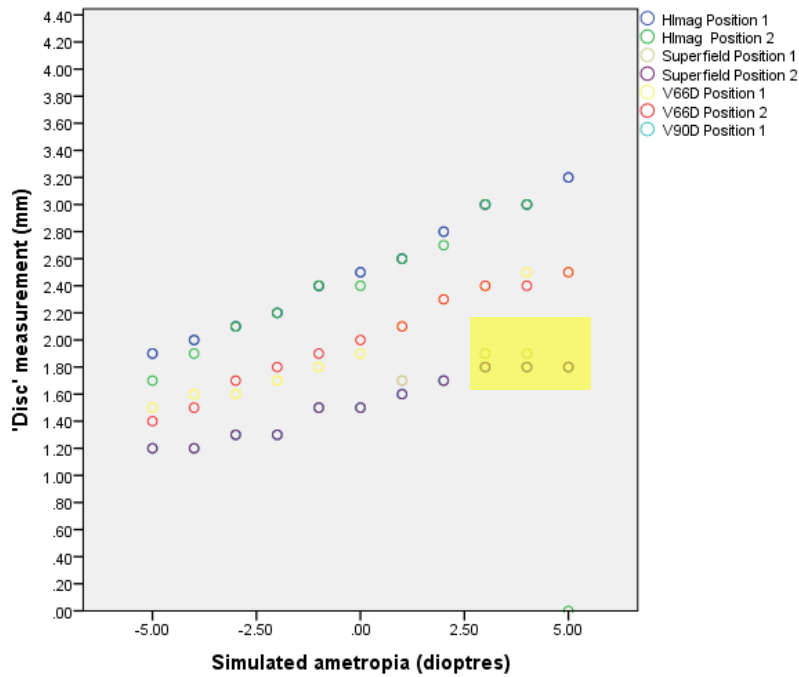


Figure 6.5. Shows the effect of moving the lenses from position 1 to 2

From Figure 6.5, the only lens that shows any degree of consistency between position 1 and position 2 is the Superfield NC lens, also suggesting that the 90D would give similar results if it had been possible to examine this lens in position 2.

6.3 Discussion

Previous work has shown that applying a single magnification factor to all ncBIO when viewing eyes of varying levels of ametropia may not be appropriate (Ansari-Shahrezaei et al. 2001; Ansari-Shahrezaei and Stur 2002, 2005). These researchers looked at a number of different ncBIO lenses, including three used in this study, the Super 66, Super Field NC and the 90D, all from Volk Optical Inc, Mentor, OH. In order to calculate the true size of any area of regard in the fundus of a patient, various parameters need to be known, which are the eye's ametropia, keratometry and axial length, along with magnification of the instrumentation used to view the fundus and its position relative to the eye. These factors, if known, will enable the true size of a fundal object to be ascertained, as the total magnification of the system will be known. Clearly, in clinical practice this is not considered and if measurements taken from the fundus are corrected then a simple manufacturer derived magnification factor is utilised. As previously stated, this would be acceptable if the system is telecentric, that there is a constant relationship between magnification of the ncBIO and slit-lamp system, but this has not been found for several lenses (Ansari-Shahrezaei and Stur 2002, 2005). They found a change in magnification from myopia to hyperopia of -12.95 to +16.2% (Super 66), -13.3 to +14.0% (Super Field NC) and -15.1 to 13.7% (90D), although there was a constant relationship between -5.00D to +5.00D for the 90D lens. They concluded that, for higher refractive errors, it is difficult to place the focal plane of the ncBIO lens such that it is coincident with the first principal plane of the eye (Ansari-Shahrezaei and Stur 2002).

Haustein et al (2009), compared measurements of disc area, measured using

several different ncBIO lenses, and results obtained using the HRT II (Heidelberg Engineering, Heidelberg, Germany). They found that the estimated values, which were corrected, using the magnification factors supplied by the manufacturer, showed differences which were not statistically significant to the HRT II for two of the lenses in this study. These lenses were the 90D and the Super Field NC. The range of ametropias covered was +3.75 to -8.00D and although smaller than that simulated using a model eye, did however, have the advantage of comparing results obtained in a clinical setting on 'real patients'.

This study, however, indicated that, in addition to the lack of consistency for the Super 66 and the Super Field NC lens, there was no constant relationship for the 90D lens over the range of minus to plus 5.00D, as described by Ansari-Shahrezaei and Stur.

There may be some reasons for these results. The first is that, in order to have a replicated distance for each lens at each simulated refractive error, the lenses were placed in the artificial eyes lens holder. Table 6.2 shows the distances in mm that this produced for each of the lens. If all the lenses were used at a distance differing from the recommended working distance, then it may be that the variation seen in the measurements, across the different ametropias, would occur. However, two of the lenses, the Digital High Mag in position 2 and the Super Field NC in position 1, were at the recommended working distance, and the Super 66 in position 2 was only 1mm out from the working distance stated by the manufacturer. It is known from the study by Ansari-Shahrezaei et al (2001) that moving the lens away from the focal

plane/first principal plane produces a change in magnification. In the clinical setting it is unlikely that all practitioners accomplish this precise positioning of the lens for all patients irrespective of their ametropia, so it is not inconceivable that an effect on the magnification of retinal details, in this case the optic nerve head, is, in fact, present in clinical measurements. While varying magnification would explain most of the readings seen, it does not explain why the Super Field NC, which is so often known as the 'wide 90', did not show more consistency over the range of simulated ametropias, as it could be expected to follow the pattern found by Ansari-Shahrezaei and Stur. The measurements with the 90D at an incorrect working distance did agree with those of the Super Field NC.

The second reason that different results found may be down to the use of the artificial eye in this study. The results were obtained using an artificial eye designed to teach retinoscopy and was air-filled with a simple lens, whereas the artificial eye used by the Ansari-Shahrezaei et al studies utilised a much more 'realistic' model eye based on the Gullstrand's schematic eye, and one that was filled with saline rather than air. They were able to obtain results over a much larger range of simulated ametropias (plus and minus 12.00D, approximately) than could be obtained by using a simple artificial eye. Work undertaken at an earlier time using such a Gullstrand type model eye (Institute of Ophthalmology, London) in the Optometry department in North Devon, while looking at the magnification factor of the department's Topcon 50IX fundus camera, allowed for a range of simulated ametropias of -14.00D to +11.00D. Clearly this earlier model eye (see Figure 6.6) has advantages over the simple artificial eye used in this study. The use of an artificial eye

designed for training retinoscopy may have resulted in incorrect determination of the effect of ametropia and viewing distances on the size of retinal structures. It does, however, lend weight to the observation that a single magnification factor may not be sufficient for this type of fundal viewing lens (Ansari-Shahrezaei et al. 2001).




Figure 6.6. Example of Gullstrand type model eye (Institute of Ophthalmology, London).

The use of ncBIO lenses in clinical examinations and the reliance of a single magnification factor, where required, may not be appropriate in all cases, and this could lead to errors when determining the size of the optic nerve head. If a clinician is then using this knowledge to assess the disc, for example using the Disc Damage Likelihood Scale (DDLS), then this could lead to an inappropriate application of the staging system. In the glaucoma assessment clinics at North Devon District Hospital, the cup-to-disc ratio has been assessed relative to the disc size, with reference to what is an expected cup-to-disc ratio and what would be expected at 95% confidence level, using

tables derived from the work of Garway-Heath (Garway-Heath et al. 1998a). So knowledge of the disc size is paramount in determining suspicion of glaucoma in new patient attendances.

The largest range of measurement was found to occur with the Digital High Mag lens, where the results varied from a minimum value of 1.90mm, at 5.00D, to 3.20mm at 5.00D, a difference of 1.30mm (uncorrected values), which, if applying the manufacturer's magnification factor, would give values between 1.50mm and 2.50mm (corrected values). If taking the DDLS staging as an example once again (small discs <1.50mm, normal discs 1.50 – 2.00mm, large discs > 2.00mm), the range of values obtained would indicate a disc size that could be mistaken for a large disc (possibly under-estimating the presence of glaucoma), when it was, in fact, a normal size disc and, of course, equally the opposite could apply.

The design of the model eye used in this study, may have introduced other potential areas for error. It contained one lens presumably based on the reduced schematic eye, and therefore in the region of 60D, however the ncBIO manufacturer's recommended distances of 'lens to eye' may be irrelevant under these conditions. Given that the anterior focal point of a schematic eye is different to that of the human eye, and values vary depending on the exact schematic used, it may be that the assumption that some lenses were at or near the correct working distance and others were not, is not true. The schematic eye held to be the most accurate is that of Gullstrand (Miller 2008), and has an anterior focal point at 15.70mm from the cornea surface whereas other schematic eyes which treat the human eye

more simply have differing anterior focal points, for example Listings at 16.70mm and Donder's at 15.00mm. Also, in the model eye used, the retinal was on a flat plane which Anasari-Shahrezaei and Stur (2005) point out only approximates the retina as the slit-lamp biomicroscope and ncBIO lenses are designed for use with a curved field of regard.

One decision in this study, namely that only one measurement was undertaken of 'disc height', may be viewed critically as a limitation. The study was undertaken not in the clinical setting where this would apply. In an attempt therefore to replicate the clinical setting this may have influenced the results. Multiple measurements would have allowed accurate interpretation of the values observed at each ametropia and it may be that observations such as the plateau effect seen for the 90D and Super Field NC lens were just erroneous measures, or conversely, may have proved this effect which can only be alluded at under the present study.

It is difficult, therefore, to recommend a particular ncBIO lens as having superior performance over another, for the assessment of the optic nerve head. Having reviewed the work by Ansari-Shahrezaei et al (2001), Ansari-Shahrezaei and Stur (2002, 2005) Haustein et al (2009) and the results of this study, it is possible that the Super Field NC , and by implication 90D lenses may have more latitude than other lenses, particularly in terms of eye to lens position. Whether, this out-weighs the advantage of lower power lenses such as the Super 66, in the clinical setting, due to the better axial and linear magnification of lower power lenses is beyond the scope of this study.

Chapter 7 General Discussion, Conclusions and Future Work

Both methods of stereo-viewing, non-anaglyph and anaglyph, show similar results and are suitable for the design of training programmes. Despite the observers preference for the non-anaglyph method, the anaglyph method has the advantage of minimal cost compared to the additional hardware costs required for non-anaglyph presentation. This would make this method of stereo-presentation attractive for a web-based training programme to aid in the determination of cup-to-disc ratio assessments. Such a programme could be of value to various groups, such as optometry students and pre-registration optometrists, junior medical staff and general practitioners. There is enough evidence to suggest that even qualified practitioners with experience in glaucoma could benefit from such training if it could be made readily available, especially as a web-based application. The other advantage is that these forms of stereo-presentation can be delivered to more than one practitioner at a time, allowing for a multiple-user experience with peer interaction.

7.1 Specific issues relating to the study

Several issues regarding both the images used and the software employed arose during the course of this study. Image selection was initially made using a laptop computer and the quality of image was graded on a simple three point scale: A - being the highest quality image, B - medium quality and C - the lowest quality, taking into account various factors, which were clarity of

the image, colour, from the point of view that some images had very poor colour rendition such as to make it difficult to differentiate the disc from the surrounding fundus, exposure and depth of 3D effect. The value for cup-to-disc ratio was also considered in the selection of images. While the judgement of image quality was subjective in manner, it was found that the grading of images, and, to an extent, the cup-to-disc ratio, varied depending on type of monitor used. Before a final selection was made, the images were viewed on 3 different monitors, a laptop (LCD – CCFL screen), a cathode-ray display, although the use of this type of display is probably limited at this point in time, and a Samsung LCD display. Thus an attempt was made to have images that showed some consistency over various monitors. Consideration was given to whether the final viewing set-up was to be standardised, but given that there would not be control over how images are viewed in any future web-based training package, the decision was made not to attempt this during the study. Initially, the study was set-up on one computer/monitor combination, but in order to undertake multiple observer tests at a single assessment, a second computer/monitor set-up using the same components was employed.

When the final selection of images was considered, decisions were made using stereo-anaglyph versions of the images. When the same non-anaglyph versions were loaded into the testing and training sections of the StereoDxT software, it became clear that a number of the images could not be displayed in a stereo form. For this reason these images had to be eliminated. While it was not clear why these images were not displaying in stereo form, the

assumption was that the original images, as supplied, were not a true pair of stereo-images and were just copies of one image, as opposed to two displaced images. The final image selection presented both in anaglyph and non-anaglyph form could be viewed using either the Liquid Crystal Shutter Goggles or red/cyan spectacles.

There were also software issues that had to be addressed during the setting-up of the study, as the StereoDxT version was a 'stripped-down' version from that used in previous studies (Morgan et al. 2005a; Sheen et al. 2004). Some issues were easily addressed, such as the failure of the software if the disc rim and neural retinal rim outlines inadvertently crossed, or the failing of the 'swap' button, which is designed to reverse an image presented in reverse stereopsis. There was one change in the software which did cause problems for some observers, and which did not come to light until the study was underway. In the version used by Morgan et al. (2005a), the StereoDx had a stereoscopic cursor that could be adjusted in the stereoscopic image so that it appeared at the same depth as the feature being measured. In their study the use of such a cursor was credited with being one of the factors that may have resulted in level of agreement obtained from the three observers that compared favourably with those of expert observers. The presence of such a stereoscopic cursor allowed for the minimisation of parallax errors in measurements. The lack of this stereocursor in the StereoDxT software used for this study may have resulted in two observers having difficulty with delineating the optic disc and cup rim due to diplopia when trying to view the image while concentrating on the cursor. This was reported for a couple of

the images used in the study by the two observers. Other observers didn't report diplopia, but had more difficulty with some images than others in being able to plot the outlines of the optic disc and cup. The expert observer also commented on difficulties with some images, reportedly due to 'fusion' problems. Given that some of these images had been used for previous studies, it is reasonable to assume that the problems faced by some of the naïve observers was due to this lack of functionality in the StereoDxT software.

During one of the testing assessments, one of the computers was found to have been unavailable. This was the computer that was used to undertake anaglyph testing and in setting-up the remaining computer, so that the observers who had been booked for this assessment could undertake the anaglyph testing, it was found that one image, Disc number 1, could not be found on this machine, and so the testing had to proceed with only 9 disc images available to the observers. For this reason the results presented for the anaglyph test group were for the 9 images viewed across the whole number of observers. The mixed results where values vary between 9 and 10 disc images, can be found in Appendix A. As stated previously, in comparing the results of the anaglyph group, the values showed minimal difference between the RMS values for 9 or 10 images.

7.2 Observers' preference and agreement between different methods of stereopresentation

12 out of the 16 observers in the Cardiff study experienced the non-anaglyph form of stereo-presentation, either directly as they were allocated to this method for the duration of the study, or indirectly, if they were in the anaglyph group and underwent the teaching which was carried out using the Liquid Crystal Goggles method of stereo-presentation. It was reported by all those who had access to this method that this was a far better way of viewing stereo-images. While this may be down to the observers' personal taste in terms of viewing experience, the results from the Cardiff study show that there is good correlation between the two methods of presentation.

7.3 Common points of discussion between Cardiff and Barnstaple studies

One aspect common to both the Cardiff and Barnstaple studies is the fact that the only result being considered was the vertical cup-to-disc ratio, which is reasonable given that this is most sensitive to the detection and progression of glaucoma (Jonas et al. 2000). However, when examining the complete reports generated by the StereoDxT software it became clear that, even though an observer may record a high level of agreement in this value when compared with either of the expert observers, the observer may not be arriving at this value in the same way as the expert. It may be that the cup-to-disc value is correct or near-correct, but the determination of the optic disc

and neural retinal rims do not coincide with that of either expert observer. For example, looking at observers 'e' and 'h', they both agreed a vertical cup-to-disc ratio of 0.501 exactly, but by examining the other data generated by the StereoDx software, it is clear that the results were obtained from different measurements of the optic nerve head being examined. The results are shown in Table 7.1.

Table 7.1. Cup, rim and disc areas in number of pixels from StereoDxT analysis

	Observer e	Observer h
Cup area	30387	26301
Rim area	72905	56652
Disc area	103292	82953

Observer h's measurements range from 13 -22% smaller than those for observer e. The implication is that, although it is possible to get similar and, indeed, exact vertical cup-to-disc values, the location of the optic disc rim and neural retinal rim may not be perceived identically by any two observers, and, as such, any teaching programme would need to take this into account.

Another point is that the determination of 'clinical examination' versus planimetric assessment of the cup-to-disc was only done by the professional observers in the Barnstaple Glaucoma Group assessments. It is perhaps tempting to apply the results across both this group and the Cardiff University

naïve observers, however, this relationship may not hold true, so while this part of the Barnstaple studies can inform the results for professional observers, it cannot be extrapolated to include the other observers taking part.

Hatch et al. (1999), state that 'Analysed agreement rather than simple correlation: analysis of agreement measures whether observations are identical, whereas analysis of correlation measures whether observations have a linear relationship.' In order to do this they used Intraclass Correlation Coefficients (ICC) to test inter-observer agreement and it was this method that was followed in this study. ICC values for the Barnstaple Glaucoma Group were almost perfect for both the 'clinical' estimation of the cup-to-disc ratios and the planimetric determinations of the cup-to-disc ratio, being 0.881 and 0.912 respectively. The inter-observer agreement for the Cardiff naïve observers in both anaglyph and non-anaglyph groups ranged from fair to almost perfect (0.40 to 0.859). However, caution should apply to interpreting these measures. While it is correct to say that the naïve observers showed good agreement in their determination of the cup-to-disc ratio, this does not mean that they were accurate in their determination. In fact, the highest ICC of 0.859 in any of the naïve observer groups (the non-anaglyph control group) indicates that they have almost perfect agreement with one another, but they were not accurate in their cup-to-disc ratio compared with the expert observer. All observers had a RMS of difference > 0.20 units, in one case being as high as 0.30 units. While it is therefore tempting to see high agreement and equate it as accuracy, this is not always the case, as clearly demonstrated by the above example.

7.4 Conclusions and Recommendations

There are several conclusions that can be drawn from this study which are:

7.4.1 Conclusion 1

The anaglyph method of presentation could likely be used for teaching especially in the form of a web-based programme, but with the proviso that:

- (i) the images are carefully selected for this purpose – it may mean that a simple conversion, as used in this study, is not sufficient to produce an optimised image for viewing in anaglyph form;
- (ii) if a non-adjustable cursor is to be used then it should appear in the same plane, or as closely as possible to that of the ONH being under determination, to avoid the possibility of diplopia or rivalry between the cursor and the image. This requires optimisation of the image as in (i);
- (iii) without the inclusion of expert determinations within any teaching programme, an individual could be ‘fooled’ about their ability to determine cup-to-disc ratios. It is therefore important that anybody undertaking a teaching programme has access to an expert opinion at some point in the teaching programme to allow direct comparisons with their determination of optic disc rim and cup.

- (iv) the images are graded as to their complexity and either only those of comparable complexity are used or, if they differ which would better reflect the 'real world', this is taken into account and information is communicated to those undertaking the programme regarding this aspect.

7.4.2 Conclusion 2

It is possible that even naïve observers can be taught to determine ONH landmarks (disc rim and neural retinal rim) to a level found in specialist clinical practice within a hospital glaucoma service.

7.4.3 Conclusion 3

The use of 'Volk' lenses, with the assumption that they are telecentric in design, is questionable. Despite them being ubiquitous in the clinical setting, they should be looked at in further detail, as not all lenses perform in the same way, which could lead to mis-classification of glaucoma.

Magnification varies with ametropia and working distance, and, therefore, as disc size is calculated based on a single magnification factor at the present time, these calculations could result in incorrect measurements of the optic disc in clinical practice.

7.5 Recommendations

7.5.1 Recommendations from Conclusion 1

That further study into the optimisation of anaglyph images should be undertaken if it is desired to progress the achievement of a web-based training programme for the determination of cup-to-disc ratios. Anaglyphs represent a cheap method of displaying and viewing 3D images and can allow for a multiple viewer experience, depending on the end user interface (large screen monitors or even projection devices could conceivably be used).

Factors that could be considered in the optimisation of anaglyphs are to determine:

- (i) whether a different form of anaglyph stereo-image provides better quality viewing for an observer and more accurate determination of cup-to-disc ratios;
- (ii) whether the use of monochromatic anaglyphs are better for teaching than colour ones. One study has suggested that colour adds little to the quality of optic nerve parameters (Stone et al. 2010), and it may be that monochromatic anaglyphs are easier to produce and view than anaglyphs based on colour images;

- (iii) the optimal setting for anaglyph conversion to be used with fundus images and whether these improve the determination of cup-to-disc ratios.

7.5.2 Recommendation from Conclusion 3

The evaluation of disc size measurements with different ncBIO lenses should be repeated using a Gullstrand type model eye, as it is important, in the clinical setting, to know if 'Volk' lenses are indeed telecentric in clinical practice. Alternatively, given the ability to measure the optic nerve head, with modern instrumentation, such as, the HRT the effect of ametropia and lens to eye distance could be made in 'real patients'. This approach would, potentially offer the opportunity to personalise magnification factors for individual practitioners and ncBIO lens combinations.

References

Abdul Majid, A. S. et al. 2010. Correlation between disc damage likelihood scale and optical coherence tomography in the diagnosis of glaucoma. *Ophthalmologica* 224(5), pp. 274-282.

Abrams, L. S. et al. 1994. Agreement among optometrists, ophthalmologists, and residents in evaluating the optic disc for glaucoma. *Ophthalmology* 101(10), pp. 1662-1667.

Akar, M. E. et al. 2004. The effect of the menstrual cycle on optic nerve head analysis in healthy women. *Acta Ophthalmol Scand* 82(6), pp. 741-745.

Alward, W. L. M. 2001. *Colour Atlas of Gonioscopy*. The Foundation of the American Academy of Ophthalmology.

Andersson, S. et al. 2011. The effect of education on the assessment of optic nerve head photographs for the glaucoma diagnosis. *BMC Ophthalmol* 11, p. 12.

Ansari-Shahrezaei, S. et al. 2001. Biomicroscopic measurement of the optic disc with a high-power positive lens. *Invest Ophthalmol Vis Sci* 42(1), pp. 153-157.

Ansari-Shahrezaei, S. and Stur, M. 2002. Magnification characteristic of a +90-diopter double-aspheric fundus examination lens. *Invest Ophthalmol Vis Sci* 43(6), pp. 1817-1819.

Ansari-Shahrezaei, S. and Stur, M. 2005. Magnification-corrected indirect biomicroscopy of the optic nerve head. *Graefes Arch Clin Exp Ophthalmol* 243(3), pp. 257-262.

Arintawati, P. et al. 2012. The Applicability of Ganglion Cell Complex Parameters Determined From SD-OCT Images to Detect Glaucomatous Eyes. *J Glaucoma*.

Armaly, M. F. 1969. The optic cup in the normal eye. I. Cup width, depth, vessel displacement, ocular tension and outflow facility. *Am J Ophthalmol* 68(3), pp. 401-407.

Azuara-Blanco, A. et al. 2002. *Hanbook of Glaucoma*. 1 ed. Martin Dunitz Ltd.

Azuara-Blanco, A. et al. 2003. Clinical agreement among glaucoma experts in the detection of glaucomatous changes of the optic disk using simultaneous stereoscopic photographs. *Am J Ophthalmol* 136(5), pp. 949-950.

Bagga, H. et al. 2003. Scanning laser polarimetry with variable corneal compensation and optical coherence tomography in normal and glaucomatous eyes. *Am J Ophthalmol* 135(4), pp. 521-529.

Bailey, C. 2009. Royal College of Ophthalmologists Ophthalmic Service Guidance Ophthalmic Imaging.

Bailey, I. L. et al. 1991. Clinical grading and the effects of scaling. *Invest Ophthalmol Vis Sci* 32(2), pp. 422-432.

Baker, H. and Murdoch, I. E. 2004. Can a public health package on glaucoma reach its target population? *Eye* 18(5), pp. 478-482.

Balasubramanian, M. et al. 2011. Agreement between the Heidelberg Retina Tomograph (HRT) stereometric parameters estimated using HRT-I and HRT-II. *Optom Vis Sci* 88(1), pp. 140-149.

Balazsi, A. G. et al. 1984. The effect of age on the nerve fiber population of the human optic nerve. *Am J Ophthalmol* 97(6), pp. 760-766.

Barry, C. J. and Eikelboom, R. H. 1995. Comparison of stereo optic disc photographs from the Nidek 3-Dx and Zeiss retinal cameras. *Aust N Z J Ophthalmol* 23(3), pp. 203-205.

Bayer, A. et al. 2002. Validity of a new disk grading scale for estimating glaucomatous damage: correlation with visual field damage. *Am J Ophthalmol* 133(6), pp. 758-763.

Bell, R. W. and O'Brien, C. 1997. Accuracy of referral to a glaucoma clinic. *Ophthalmic Physiol Opt* 17(1), pp. 7-11.

Bennett 2009. Maximizing Quality in Ophthalmic Digital Imaging. *The Journal of Ophthalmic Photography* 31(1), pp. 32-39.

Berger, J. W. et al. 2000. Computerized stereochronoscopy and alternation flicker to detect optic nerve head contour change. *Ophthalmology* 107(7), pp. 1316-1320.

Bland, J. M. and Altman, D. G. 1986. Statistical methods for assessing agreement between two methods of clinical measurement. *Lancet* 1(8476), pp. 307-310.

Boes, D. A. et al. 1996. Relative optic cup depth assessments using three stereo photograph viewing methods. *J Glaucoma* 5(1), pp. 9-14.

Bowd, C. et al. 2000. The retinal nerve fiber layer thickness in ocular hypertensive, normal, and glaucomatous eyes with optical coherence tomography. *Arch Ophthalmol* 118(1), pp. 22-26.

Brandt, J. D. 2004. Corneal thickness in glaucoma screening, diagnosis, and management. *Curr Opin Ophthalmol* 15(2), pp. 85-89.

Breusegem, C. et al. 2011. Agreement and accuracy of non-expert ophthalmologists in assessing glaucomatous changes in serial stereo optic disc photographs. *Ophthalmology* 118(4), pp. 742-746.

Broadway, D. C. and Drance, S. M. 1998. Glaucoma and vasospasm. *Br J Ophthalmol* 82(8), pp. 862-870.

Broadway, D. C. et al. 1999. Optic disk appearances in primary open-angle glaucoma. *Surv Ophthalmol* 43 Suppl 1, pp. S223-243.

Bron, A. J. et al. 2003. Grading of corneal and conjunctival staining in the context of other dry eye tests. *Cornea* 22(7), pp. 640-650.

Brusini, P. et al. Optic disc damage staging system. *J Glaucoma* 19(7), pp. 442-449.

Brusini, P. et al. 2009. Optic disc damage staging system. *J Glaucoma* 19(7), pp. 442-449.

Budde, W. M. and Jonas, J. B. 2004. Enlargement of parapapillary atrophy in follow-up of chronic open-angle glaucoma. *Am J Ophthalmol* 137(4), pp. 646-654.

Budde, W. M. et al. 2000. Influence of optic disc size on neuroretinal rim shape in healthy eyes. *J Glaucoma* 9(5), pp. 357-362.

Budde, W. M. et al. 1998. Optic disc size and iris color. *Arch Ophthalmol* 116(4), p. 545.

Budenz, D. L. et al. 2006. Detection and prognostic significance of optic disc hemorrhages during the Ocular Hypertension Treatment Study. *Ophthalmology* 113(12), pp. 2137-2143.

Budenz, D. L. et al. 2002. Sensitivity and specificity of the Swedish interactive threshold algorithm for glaucomatous visual field defects. *Ophthalmology* 109(6), pp. 1052-1058.

Caprioli, J. and Miller, J. M. 1987. Optic disc rim area is related to disc size in normal subjects. *Arch Ophthalmol* 105(12), pp. 1683-1685.

Care, N. C. C. f. A. 2009. Glaucoma:Diagnosis and management of chronic open angle glaucoma and ocular hypertension.London:

Cassard, S. D. et al. 2012. Regional variations and trends in the prevalence of diagnosed glaucoma in the medicare population. *Ophthalmology* 119(7), pp. 1342-1351.

Charters, L. 2004. Stereo disc imaging still gold standard for glaucoma imaging. *Ophthalmology Times*.

Chauhan, D. S. and Marshall, J. 1999. The interpretation of optical coherence tomography images of the retina. *Invest Ophthalmol Vis Sci* 40(10), pp. 2332-2342.

Chi, T. et al. 1989. Racial differences in optic nerve head parameters. *Arch Ophthalmol* 107(6), pp. 836-839.

Chong, G. T. and Lee, R. K. 2012. Glaucoma versus red disease: imaging and glaucoma diagnosis. *Curr Opin Ophthalmol* 23(2), pp. 79-88.

Choplin, N. T. and Lundy, D. C. 2001. The sensitivity and specificity of scanning laser polarimetry in the detection of glaucoma in a clinical setting. *Ophthalmology* 108(5), pp. 899-904.

Colen, T. P. and Lemij, H. G. 2003. Sensitivity and specificity of the GDx: clinical judgment of standard printouts versus the number. *J Glaucoma* 12(2), pp. 129-133.

Colton, T. and Ederer, F. 1980. The distribution of intraocular pressures in the general population. *Surv Ophthalmol* 25(3), pp. 123-129.

Comer, G. M. and Ciulla, T. A. 2004. Diagnostic imaging of retinal disease. *Int Ophthalmol Clin* 44(4), pp. 1-15.

Correnti, A. J. et al. 2003. Comparison of optic nerve head assessment with a digital stereoscopic camera (discam), scanning laser ophthalmoscopy, and stereophotography. *Ophthalmology* 110(8), pp. 1499-1505.

Crowston, J. G. et al. 2004. The effect of optic disc diameter on vertical cup to disc ratio percentiles in a population based cohort: the Blue Mountains Eye Study. *Br J Ophthalmol* 88(6), pp. 766-770.

Cvenkel, B. and Kontestabile, A. S. 2011. Correlation between nerve fibre layer thickness measured with spectral domain OCT and visual field in patients with different stages of glaucoma. *Graefes Arch Clin Exp Ophthalmol* 249(4), pp. 575-584.

Cymbor, M. et al. 2009. Concordance of flicker comparison versus side-by-side comparison in glaucoma. *Optometry* 80(8), pp. 437-441.

Danesh-Meyer, H. V. et al. 2006. Comparison of disc damage likelihood scale, cup to disc ratio, and Heidelberg retina tomograph in the diagnosis of glaucoma. *Br J Ophthalmol* 90(4), pp. 437-441.

de Mul, M. et al. 2004. Improving the quality of eye care with tele-ophthalmology: shared-care glaucoma screening. *J Telemed Telecare* 10(6), pp. 331-336.

Department of Health, N. E. C. S. G. 2004. National Eye Care Steering Group
- First report.

Dielemans, I. et al. 1994. The prevalence of primary open-angle glaucoma in
a population-based study in The Netherlands. The Rotterdam Study.
Ophthalmology 101(11), pp. 1851-1855.

Efron, N. 1998. Grading scales for contact lens complications. *Ophthalmic
Physiol Opt* 18(2), pp. 182-186.

Efron, N. et al. 2011. A survey of the use of grading scales for contact lens
complications in optometric practice. *Clin Exp Optom* 94(2), pp. 193-199.

Ehrlich, J. R. et al. 2011. Peripapillary choroidal thickness in glaucoma
measured with optical coherence tomography. *Exp Eye Res* 92(3), pp. 189-
194.

Evans, J. R. et al. 2004. Causes of visual impairment in people aged 75 years
and older in Britain: an add-on study to the MRC Trial of Assessment and
Management of Older People in the Community. *Br J Ophthalmol* 88(3), pp.
365-370.

Feiner, L. and Piltz-Seymour, J. R. 2003. Collaborative Initial Glaucoma
Treatment Study: a summary of results to date. *Curr Opin Ophthalmol* 14(2),
pp. 106-111.

Fellman, R. M. D. 2004. Comparison of Optic Nerve Head Assessment With a Digital Stereoscopic Camera (Discam), Scanning Laser Ophthalmoscopy, and Stereophotography. *Evidence-Based Eye Care* 5(1), pp. 26-27.

Feuer, W. J. et al. 2002. The Ocular Hypertension Treatment Study: reproducibility of cup/disk ratio measurements over time at an optic disc reading center. *Am J Ophthalmol* 133(1), pp. 19-28.

Fingeret, M. et al. 2005. Five rules to evaluate the optic disc and retinal nerve fiber layer for glaucoma. *Optometry* 76(11), pp. 661-668.

Friedman, D. S. et al. 2004. An evidence-based assessment of risk factors for the progression of ocular hypertension and glaucoma. *Am J Ophthalmol* 138(3 Suppl), pp. S19-31.

Funk, J. et al. 2002. [Flicker comparison of optic disc photographs: sensitivity and specificity]. *Klin Monbl Augenheilkd* 219(12), pp. 862-865.

Fusun Cardakli, U. 2005. Glaucoma, Suspect, Adult. *emedicine*.

Gangaputra, S. S. et al. 2011. Morphologic assessment for glaucoma in the Multicenter Uveitis Steroid Treatment (MUST) trial. *Ocul Immunol Inflamm* 19(4), pp. 267-274.

Garway-Heath, D. F. et al. 1998a. Vertical cup/disc ratio in relation to optic disc size: its value in the assessment of the glaucoma suspect. *Br J Ophthalmol* 82(10), pp. 1118-1124.

Garway-Heath, D. F. et al. 1998b. Measurement of optic disc size: equivalence of methods to correct for ocular magnification. *Br J Ophthalmol* 82(6), pp. 643-649.

Gazzard, G. et al. 2003. Optic disc hemorrhage in Asian glaucoma patients. *J Glaucoma* 12(3), pp. 226-231.

Girkin, C. A. et al. 2011. Variation in optic nerve and macular structure with age and race with spectral-domain optical coherence tomography. *Ophthalmology* 118(12), pp. 2403-2408.

Goldmann, H. and Lotmar, W. 1977. Rapid detection of changes in the optic disc: stereo-chronoscopy. *Albrecht Von Graefes Arch Klin Exp Ophthalmol* 202(2), pp. 87-99.

Gordon, M. O. et al. 2002. The Ocular Hypertension Treatment Study: baseline factors that predict the onset of primary open-angle glaucoma. *Arch Ophthalmol* 120(6), pp. 714-720; discussion 829-730.

Greaney, M. J. et al. 2002. Comparison of optic nerve imaging methods to distinguish normal eyes from those with glaucoma. *Invest Ophthalmol Vis Sci* 43(1), pp. 140-145.

Greenfield, D. S. et al. 2002. Correction for corneal polarization axis improves the discriminating power of scanning laser polarimetry. *Am J Ophthalmol* 134(1), pp. 27-33.

Grehn, F. and Stamper, R. 2004. *Glaucoma*. Springer.

Guedes, V. et al. 2003. Optical coherence tomography measurement of macular and nerve fiber layer thickness in normal and glaucomatous human eyes. *Ophthalmology* 110(1), pp. 177-189.

Habib, M. S. et al. 2008. Assessment of stereoscopic optic disc images using an autostereoscopic screen - experimental study. *BMC Ophthalmol* 8, p. 13.

Hanson, S. et al. 2001. Observer experience and Cup:Disc ratio assessment. *Optom Vis Sci* 78(10), pp. 701-705.

Harper, R. A. and Reeves, B. C. 1999. Glaucoma screening: the importance of combining test data. *Optom Vis Sci* 76(8), pp. 537-543.

Hatch, W. V. et al. 1999a. Interobserver agreement of Heidelberg retina tomograph parameters. *J Glaucoma* 8(4), pp. 232-237.

Hatch, W. V. et al. 1999b. Agreement in assessing glaucomatous discs in a clinical teaching setting with stereoscopic disc photographs, planimetry, and laser scanning tomography. *J Glaucoma* 8(2), pp. 99-104.

Haustein, M. et al. 2009. [Measurement of the disc area by indirect ophthalmoscopy]. *Ophthalmologe* 106(2), pp. 141-148.

Hayreh, S. S. and Jonas, J. B. 2001. Optic disc morphology after arteritic anterior ischemic optic neuropathy. *Ophthalmology* 108(9), pp. 1586-1594.

Healey, P. 2011. Optic disc haemorrhage: the more we look the more we find. *Clin Experiment Ophthalmol* 39(6), pp. 485-486.

Healey, P. R. and Mitchell, P. 2004. Visibility of lamina cribrosa pores and open-angle glaucoma. *Am J Ophthalmol* 138(5), pp. 871-872.

Healey, P. R. et al. 1997. Relationship between cup-disc ratio and optic disc diameter: the Blue Mountains Eye Study. *Aust N Z J Ophthalmol* 25 Suppl 1, pp. S99-101.

Heijl, A. et al. 2002. Reduction of intraocular pressure and glaucoma progression: results from the Early Manifest Glaucoma Trial. *Arch Ophthalmol* 120(10), pp. 1268-1279.

Henderer, J. et al. 2009. Evaluating a new disc staging scale for glaucomatous damage: the ability to detect change over time. *Eur J Ophthalmol* 19(3), pp. 404-410.

Hendrickx, K. H. et al. 1994. Cumulative incidence of patients with disc hemorrhages in glaucoma and the effect of therapy. *Ophthalmology* 101(7), pp. 1165-1172.

Henson, D. B. et al. 2003. Community refinement of glaucoma referrals. *Eye* 17(1), pp. 21-26.

Hermann, M. M. et al. 2004. Optic nerve head morphometry in healthy adults using confocal laser scanning tomography. *Br J Ophthalmol* 88(6), pp. 761-765.

Hewitt, A. W. et al. 2006. Tools for cup:disc ratio measurement. *Clin Experiment Ophthalmol* 34(3), pp. 288-289; author reply 289.

Hornova, J. et al. 2008. Correlation of Disc Damage Likelihood Scale, visual field, and Heidelberg Retina Tomograph II in patients with glaucoma. *Eur J Ophthalmol* 18(5), pp. 739-747.

Hrynychak, P. et al. 2003. A comparison of cup-to-disc ratio evaluation in normal subjects using stereo biomicroscopy and digital imaging of the optic nerve head. *Ophthalmic Physiol Opt* 23(1), pp. 51-59.

Hrynychak, P. et al. 2004. A comparison of cup-to-disc ratio measurement in normal subjects using optical coherence tomography image analysis of the optic nerve head and stereo fundus biomicroscopy. *Ophthalmic Physiol Opt* 24(6), pp. 543-550.

Jaafar, M. S. and Kazi, G. A. 1993. Normal intraocular pressure in children: a comparative study of the Perkins applanation tonometer and the pneumatonometer. *J Pediatr Ophthalmol Strabismus* 30(5), pp. 284-287.

Januschowski, K. et al. 2011. [Stereometric parameters of the optic disc. Comparison between a simultaneous non-mydratic stereoscopic fundus camera (KOWA WX 3D) and the Heidelberg scanning laser ophthalmoscope (HRT III)]. *Ophthalmologe* 108(10), pp. 957-962.

Jindal, S. et al. 2010. Comparison of the diagnostic ability of Moorfield's regression analysis and glaucoma probability score using Heidelberg retinal tomograph III in eyes with primary open angle glaucoma. *Indian J Ophthalmol* 58(6), pp. 487-492.

Jonas, J. B. 2005a. Clinical implications of peripapillary atrophy in glaucoma. *Curr Opin Ophthalmol* 16(2), pp. 84-88.

Jonas, J. B. 2005b. Optic disk size correlated with refractive error. *Am J Ophthalmol* 139(2), pp. 346-348.

Jonas, J. B. et al. 2000. Ranking of optic disc variables for detection of glaucomatous optic nerve damage. *Invest Ophthalmol Vis Sci* 41(7), pp. 1764-1773.

Jonas, J. B. and Budde, W. M. 2000. Optic nerve head appearance in juvenile-onset chronic high-pressure glaucoma and normal-pressure glaucoma. *Ophthalmology* 107(4), pp. 704-711.

Jonas, J. B. et al. 2001. Central retinal vessel trunk exit and location of glaucomatous parapapillary atrophy in glaucoma. *Ophthalmology* 108(6), pp. 1059-1064.

Jonas, J. B. et al. 1999. Ophthalmoscopic evaluation of the optic nerve head. *Surv Ophthalmol* 43(4), pp. 293-320.

Jonas, J. B. et al. 1998a. Optic disc morphology in pigmentary glaucoma. *Br J Ophthalmol* 82(8), pp. 875-879.

Jonas, J. B. et al. 1990a. Glaucomatous optic nerve atrophy in small discs with low cup-to-disc ratios. *Ophthalmology* 97(9), pp. 1211-1215.

Jonas, J. B. et al. 1998b. Optic disc dimensions, body length, and body weight. *Br J Ophthalmol* 82(2), p. 197.

Jonas, J. B. et al. 1988a. Optic disc morphometry in chronic primary open-angle glaucoma. II. Correlation of the intrapapillary morphometric data to visual field indices. *Graefes Arch Clin Exp Ophthalmol* 226(6), pp. 531-538.

Jonas, J. B. et al. 1988b. Optic disc, cup and neuroretinal rim size, configuration and correlations in normal eyes. *Invest Ophthalmol Vis Sci* 29(7), pp. 1151-1158.

Jonas, J. B. et al. 1997. Optic disc shape, corneal astigmatism, and amblyopia. *Ophthalmology* 104(11), pp. 1934-1937.

Jonas, J. B. et al. 1990b. Histomorphometry of the human optic nerve. *Invest Ophthalmol Vis Sci* 31(4), pp. 736-744.

Jonas, J. B. et al. 1989a. Parapapillary chorioretinal atrophy in normal and glaucoma eyes. I. Morphometric data. *Invest Ophthalmol Vis Sci* 30(5), pp. 908-918.

Jonas, J. B. et al. 1989b. Parapapillary retinal vessel diameter in normal and glaucoma eyes. I. Morphometric data. *Invest Ophthalmol Vis Sci* 30(7), pp. 1599-1603.

Jonas, J. B. and Papastathopoulos, K. 1995. Ophthalmoscopic measurement of the optic disc. *Ophthalmology* 102(7), pp. 1102-1106.

Jonas, J. B. et al. 1992. Human optic nerve fiber count and optic disc size. *Invest Ophthalmol Vis Sci* 33(6), pp. 2012-2018.

Jonas, J. B. et al. 2003. Optic disc morphology in south India: the Vellore Eye Study. *Br J Ophthalmol* 87(2), pp. 189-196.

Jonas, J. B. and Xu, L. 1994. Optic disk hemorrhages in glaucoma. *Am J Ophthalmol* 118(1), pp. 1-8.

Jonsson, O. et al. 2005. Epidemiology of the optic nerve grey crescent in the Reykjavik Eye Study. *Br J Ophthalmol* 89(1), pp. 36-39.

Kanski 1989. *Clinical Ophthalmology, A Systematic Approach Second edition*. Butterworth-Heinemann Ltd, p.

Kanski, J. J. 1999. *Clinical Ophthalmology A Systematic Approach*. Fourth Edition ed. Butterworth Heinemann.

Kass, M. A. et al. 2002. The Ocular Hypertension Treatment Study: a randomized trial determines that topical ocular hypotensive medication delays or prevents the onset of primary open-angle glaucoma. *Arch Ophthalmol* 120(6), pp. 701-713; discussion 829-730.

Kaufmann, C. et al. 2004. Comparison of dynamic contour tonometry with goldmann applanation tonometry. *Invest Ophthalmol Vis Sci* 45(9), pp. 3118-3121.

Kim, J. et al. 2004. The Advanced Glaucoma Intervention Study (AGIS): 14. Distinguishing progression of glaucoma from visual field fluctuations. *Ophthalmology* 111(11), pp. 2109-2116.

Kitazawa, Y. et al. 1986. Optic disc hemorrhage in low-tension glaucoma. *Ophthalmology* 93(6), pp. 853-857.

Knight, O. J. et al. 2012. Effect of race, age, and axial length on optic nerve head parameters and retinal nerve fiber layer thickness measured by Cirrus HD-OCT. *Arch Ophthalmol* 130(3), pp. 312-318.

Kocur, I. and Resnikoff, S. 2002. Visual impairment and blindness in Europe and their prevention. *Br J Ophthalmol* 86(7), pp. 716-722.

Koh, V. et al. 2012. Comparing stereometric parameters between Heidelberg Retinal Tomography 2 and 3 in Asian eyes: the Singapore Malay Eye Study. *J Glaucoma* 21(2), pp. 102-106.

Kong, Y. X. et al. 2011. Glaucomatous optic neuropathy evaluation project: a standardized internet system for assessing skills in optic disc examination. *Clin Experiment Ophthalmol* 39(4), pp. 308-317.

Kong, Y. X. et al. 2011. Glaucomatous optic neuropathy evaluation project: a standardized internet system for assessing skills in optic disc examination.

Clin Experiment Ophthalmol 39(4), pp. 308-317.

Kotera, Y. et al. 2009. Comparison of spectral domain optical coherence tomography and color photographic imaging of the optic nerve head in management of glaucoma. *Ophthalmic Surg Lasers Imaging* 40(3), pp. 255-263.

Krueger, H. et al. 2009. [Comparing specific disc findings of a European and a Bantu population]. *Klin Monbl Augenheilkd* 226(10), pp. 844-848.

Kwon, Y. H. et al. 2003. Rate of optic disc cup progression in treated primary open-angle glaucoma. *J Glaucoma* 12(5), pp. 409-416.

Lamirel, C. et al. 2012. Nonmydriatic digital ocular fundus photography on the iPhone 3G: the FOTO-ED study. *Arch Ophthalmol* 130(7), pp. 939-940.

Law, S. K. et al. 2001. Optic disk characteristics before the occurrence of disk hemorrhage in glaucoma patients. *Am J Ophthalmol* 132(3), pp. 411-413.

Leamon, S. 2012. *CVI data 2009-2010* RNIB and Moorfields Eye Hospital NHS Foundation Trust. Available at: <URL:

http://www.rnib.org.uk/aboutus/Research/reports/otherresearch/Pages/CVI_2008_9.aspx> [Accessed:

- Lee, A. C. et al. 2002. Infrequent confirmation of visual field progression. *Ophthalmology* 109(6), pp. 1059-1065.
- Lehmann, M. V. et al. 2008. 3D vs 2D qualitative and semiquantitative evaluation of the glaucomatous optic disc atrophy using computer-assisted stereophotography. *Eye (Lond)* 22(5), pp. 628-635.
- Leibowitz, H. M. et al. 1980. The Framingham Eye Study monograph: An ophthalmological and epidemiological study of cataract, glaucoma, diabetic retinopathy, macular degeneration, and visual acuity in a general population of 2631 adults, 1973-1975. *Surv Ophthalmol* 24(Suppl), pp. 335-610.
- Leonardi, M. et al. 2009. Wireless contact lens sensor for intraocular pressure monitoring: assessment on enucleated pig eyes. *Acta Ophthalmol* 87(4), pp. 433-437.
- Leske, M. C. et al. 1999. Early Manifest Glaucoma Trial: design and baseline data. *Ophthalmology* 106(11), pp. 2144-2153.
- Leung, C. K. et al. 2007. Optic disc measurements in myopia with optical coherence tomography and confocal scanning laser ophthalmoscopy. *Invest Ophthalmol Vis Sci* 48(7), pp. 3178-3183.

Li, Y. et al. 2010. Transpalpebral measurement of intraocular pressure using the Diaton tonometer versus standard Goldmann applanation tonometry.

Graefes Arch Clin Exp Ophthalmol 248(12), pp. 1765-1770.

Lichter, P. R. 1976. Variability of expert observers in evaluating the optic disc.

Trans Am Ophthalmol Soc 74, pp. 532-572.

Lim, C. S. et al. 1996. A simple clinical method to measure the optic disc size in glaucoma. *J Glaucoma* 5(4), pp. 241-245.

Liou, S. Y. et al. 2001. Morphometric characteristics of optic disk with disk hemorrhage in normal-tension glaucoma. *Am J Ophthalmol* 132(5), pp. 618-625.

Manjunath, V. et al. 2011. Analysis of peripapillary atrophy using spectral domain optical coherence tomography. *Ophthalmology* 118(3), pp. 531-536.

Mansour, A. M. 1991. Racial variation of optic disc size. *Ophthalmic Res* 23(2), pp. 67-72.

Mardin, C. Y. and Junemann, A. G. 2001. The diagnostic value of optic nerve imaging in early glaucoma. *Curr Opin Ophthalmol* 12(2), pp. 100-104.

Marks, J. R. et al. 2012. Agreement between specially trained and accredited optometrists and glaucoma specialist consultant ophthalmologists in their management of glaucoma patients. *Eye (Lond)* 26(6), pp. 853-861.

Marsh, B. C. et al. 2010. Optic nerve head (ONH) topographic analysis by stratus OCT in normal subjects: correlation to disc size, age, and ethnicity. *J Glaucoma* 19(5), pp. 310-318.

Meadows, J. F. et al. 2012. Development of the 4-3-2-1 meibum expressibility scale. *Eye Contact Lens* 38(2), pp. 86-92.

Medeiros, F. A. et al. 2005. Evaluation of retinal nerve fiber layer, optic nerve head, and macular thickness measurements for glaucoma detection using optical coherence tomography. *Am J Ophthalmol* 139(1), pp. 44-55.

Michelson, G. and Groh, M. J. 2001. Screening models for glaucoma. *Curr Opin Ophthalmol* 12(2), pp. 105-111.

Miller 2008. Basic and Clinical Science Course, Section 3, Clinical Optics. pp. 105-108.

Mistlberger, A. et al. 1999. Heidelberg retina tomography and optical coherence tomography in normal, ocular-hypertensive, and glaucomatous eyes. *Ophthalmology* 106(10), pp. 2027-2032.

Mitchell, P. et al. 2005. Retinal vessel diameter and open-angle glaucoma: the Blue Mountains Eye Study. *Ophthalmology* 112(2), pp. 245-250.

Mitchell, P. et al. 1996. Prevalence of open-angle glaucoma in Australia. The Blue Mountains Eye Study. *Ophthalmology* 103(10), pp. 1661-1669.

Mitchison, G. J. and Westheimer, G. 1984. The perception of depth in simple figures. *Vision Res* 24(9), pp. 1063-1073.

Moreno, P. A. et al. 2011. Spectral-domain optical coherence tomography for early glaucoma assessment: analysis of macular ganglion cell complex versus peripapillary retinal nerve fiber layer. *Can J Ophthalmol* 46(6), pp. 543-547.

Morgan-Davies, J. et al. 2004. Three dimensional analysis of the lamina cribrosa in glaucoma. *Br J Ophthalmol* 88(10), pp. 1299-1304.

Morgan, A. and Hosking, S. 2001. Ocular blood flow tonometer reproducibility: the effect of operator experience and mode of application. *Ophthalmic Physiol Opt* 21(5), pp. 401-406.

Morgan, J. E. et al. 2005a. Digital imaging of the optic nerve head: monoscopic and stereoscopic analysis. *Br J Ophthalmol* 89(7), pp. 879-884.

Morgan, J. E. et al. 2005b. Discrimination of glaucomatous optic neuropathy by digital stereoscopic analysis. *Ophthalmology* 112(5), pp. 855-862.

Munkwitz, S. et al. 2004. Sensitivity and specificity of scanning laser polarimetry using the GDx. *Br J Ophthalmol* 88(9), pp. 1142-1145.

Musch, D. C. et al. 1999. The Collaborative Initial Glaucoma Treatment Study: study design, methods, and baseline characteristics of enrolled patients. *Ophthalmology* 106(4), pp. 653-662.

Muttuvelu, D. V. et al. 2012. Precision and accuracy of the ICare tonometer - Peripheral and central IOP measurements by rebound tonometry. *Acta Ophthalmol* 90(4), pp. 322-326.

Na, J. H. et al. 2010. Characterization of peripapillary atrophy using spectral domain optical coherence tomography. *Korean J Ophthalmol* 24(6), pp. 353-359.

Nakatani, Y. et al. 2011. Evaluation of macular thickness and peripapillary retinal nerve fiber layer thickness for detection of early glaucoma using spectral domain optical coherence tomography. *J Glaucoma* 20(4), pp. 252-259.

Nakazawa, T. et al. 2010. Different types of optic disc shape in patients with advanced open-angle glaucoma. *Jpn J Ophthalmol* 54(4), pp. 291-295.

Nelson, P. et al. 1999. Patients' perception of visual impairment in glaucoma: a pilot study. *Br J Ophthalmol* 83(5), pp. 546-552.

Nesterov, A. P. and Listopadova, N. A. 1981. [Classification of physiological and glaucomatous extraction of the optic disk]. *Vestn Oftalmol* (2), pp. 17-22.

NICE 2009. Glaucoma:Diagnosis and management of chronic open angle glaucoma and ocular hypertension.London:

Nicolela, M. T. and Drance, S. M. 1996. Various glaucomatous optic nerve appearances: clinical correlations. *Ophthalmology* 103(4), pp. 640-649.

Nicolela, M. T. et al. 2001a. Agreement among clinicians in the recognition of patterns of optic disk damage in glaucoma. *Am J Ophthalmol* 132(6), pp. 836-844.

Nicolela, M. T. et al. 2001b. Scanning laser polarimetry in a selected group of patients with glaucoma and normal controls. *Am J Ophthalmol* 132(6), pp. 845-854.

Nitta, K. et al. 2011. [Relationship between the frequency of disc hemorrhage and the enlargement of nerve fiber layer defects and the deterioration speed of visual field loss in normal-tension glaucoma with wedge-shaped nerve fiber layer defects]. *Nihon Ganka Gakkai Zasshi* 115(9), pp. 839-847.

Odberg, T. and Riise, D. 1985. Early diagnosis of glaucoma. The value of successive stereophotography of the optic disc. *Acta Ophthalmol (Copenh)* 63(3), pp. 257-263.

Ong, L. S. et al. 1999. Asymmetry in optic disc parameters: the Blue Mountains Eye Study. *Invest Ophthalmol Vis Sci* 40(5), pp. 849-857.

Optometrists, C. o. 2005. *College's Guidelines for Professional Conduct*.

Pakravan, M. et al. 2007. Central corneal thickness and correlation to optic disc size: a potential link for susceptibility to glaucoma. *Br J Ophthalmol* 91(1), pp. 26-28.

Pan, Y. and Varma, R. 2011. Natural history of glaucoma. *Indian J Ophthalmol* 59 Suppl, pp. S19-23.

Papastathopoulos, K. I. and Jonas, J. B. 1997. [Ophthalmoscopic assessment of the size of the optic nerve papilla]. *Klin Monbl Augenheilkd* 211(5), pp. 291-295.

Parkin, B. et al. 2001. A comparison of stereoscopic and monoscopic evaluation of optic disc topography using a digital optic disc stereo camera. *Br J Ophthalmol* 85(11), pp. 1347-1351.

Pederson, J. E. and Anderson, D. R. 1980. The mode of progressive disc cupping in ocular hypertension and glaucoma. *Arch Ophthalmol* 98(3), pp. 490-495.

Pederson, J. E. and Herschler, J. 1982. Reversal of glaucomatous cupping in adults. *Arch Ophthalmol* 100(3), pp. 426-431.

Phillips, C. I. et al. 1993. Saucerisation (recession) of neuro-retinal rim is characteristic of glaucoma. *Jpn J Ophthalmol* 37(2), pp. 171-177.

Pickard, R. 1923. A Method Of Recording Disc Alterations And A Study Of The Growth Of Normal And Abnormal Disc Cups. *Br J Ophthalmol* 7(2), pp. 81-90.

Pieroth, L. et al. 1999. Evaluation of focal defects of the nerve fiber layer using optical coherence tomography. *Ophthalmology* 106(3), pp. 570-579.

Prum, B. et al. 2010. Primary Open-Angle Glaucoma PPP.

Quigley, H. A. 1985. Early detection of glaucomatous damage. II. Changes in the appearance of the optic disk. *Surv Ophthalmol* 30(2), pp. 111, 117-126.

Quigley, H. A. 1996. Number of people with glaucoma worldwide. *Br J Ophthalmol* 80(5), pp. 389-393.

Quigley, H. A. et al. 1982. Optic nerve damage in human glaucoma. III. Quantitative correlation of nerve fiber loss and visual field defect in glaucoma, ischemic neuropathy, papilledema, and toxic neuropathy. *Arch Ophthalmol* 100(1), pp. 135-146.

Quigley, H. A. et al. 1990. The size and shape of the optic disc in normal human eyes. *Arch Ophthalmol* 108(1), pp. 51-57.

Radcliffe, N. M. et al. 2010. Comparison of stereo disc photographs and alternation flicker using a novel matching technology for detecting glaucoma progression. *Ophthalmic Surg Lasers Imaging* 41(6), pp. 629-634.

Ramdass, W. D. et al. 2011. Heidelberg Retina Tomograph (HRT3) in population-based epidemiology: normative values and criteria for glaucomatous optic neuropathy. *Ophthalmic Epidemiol* 18(5), pp. 198-210.

Ramrattan, R. S. et al. 1999. Determinants of optic disc characteristics in a general population: The Rotterdam Study. *Ophthalmology* 106(8), pp. 1588-1596.

Rao, H. L. et al. 2010. Agreement among 3 methods of optic disc diameter measurement. *J Glaucoma* 19(9), pp. 650-654.

Rath, E. Z. et al. 2003. Correlation between optic disc atrophy and aetiology: anterior ischaemic optic neuropathy vs optic neuritis. *Eye (Lond)* 17(9), pp. 1019-1024.

Reidy, A. et al. 1998. Prevalence of serious eye disease and visual impairment in a north London population: population based, cross sectional study. *Bmj* 316(7145), pp. 1643-1646.

Rietveld, E. et al. 2005. Clinical evaluation of the pressure phosphene tonometer in patients with glaucoma. *Br J Ophthalmol* 89(5), pp. 537-539.

Rochtchina, E. et al. 2002. Relationship between age and intraocular pressure: the Blue Mountains Eye Study. *Clin Experiment Ophthalmol* 30(3), pp. 173-175.

Rudnicka, A. R. et al. 1998. Magnification characteristics of fundus imaging systems. *Ophthalmology* 105(12), pp. 2186-2192.

Rumsey, K. E. et al. 1990. Monocular vs. stereoscopic measurement of cup-to-disc ratios. *Optom Vis Sci* 67(7), pp. 546-550.

Samarawickrama, C. et al. 2009. Birth weight and optic nerve head parameters. *Ophthalmology* 116(6), pp. 1112-1118.

Sampaolesi, R. et al. 2003. [Correlation between confocal tomography of the optic nerve (HRT) and the perimetric frequency doubling technology]. *Klin Monats Augenhelkd* 220(11), pp. 754-766.

Sander, B. et al. 2005. Enhanced optical coherence tomography imaging by multiple scan averaging. *Br J Ophthalmol* 89(2), pp. 207-212.

Schwartz, J. T. et al. 1975. Acquired cupping of the optic nerve head in normotensive eyes. *Br J Ophthalmol* 59(4), pp. 216-222.

Scott, C. J. et al. 2010. Diagnosis and grading of papilledema in patients with raised intracranial pressure using optical coherence tomography vs clinical expert assessment using a clinical staging scale. *Arch Ophthalmol* 128(6), pp. 705-711.

Seider, M. I. et al. 2009. Optic disk size variability between African, Asian, white, Hispanic, and Filipino Americans using Heidelberg retinal tomography. *J Glaucoma* 18(8), pp. 595-600.

Sen, H. N. et al. 2011. A standardized grading system for scleritis. *Ophthalmology* 118(4), pp. 768-771.

Sharma, A. et al. 2011. Comparison of automated analysis of Cirrus HD OCT spectral-domain optical coherence tomography with stereo photographs of the optic disc. *Ophthalmology* 118(7), pp. 1348-1357.

Sharma, A. K. et al. 2000. Comparison of the Humphrey swedish interactive thresholding algorithm (SITA) and full threshold strategies. *J Glaucoma* 9(1), pp. 20-27.

Sheen, N. J. et al. 2004. Digital stereoscopic analysis of the optic disc: evaluation of a teaching program. *Ophthalmology* 111(10), pp. 1873-1879.

Sherafat, H. et al. 2003. Effect of a patient training video on visual field test reliability. *Br J Ophthalmol* 87(2), pp. 153-156.

Shiose, Y. 1975. [Quantitative analysis of "optic cup" and its clinical application. III. A new diagnostic criterion for glaucoma using "quantitative disc pattern" (Shiose) (author's transl)]. *Nihon Ganka Gakkai Zasshi* 79(5), pp. 445-461.

Siegner, S. W. and Netland, P. A. 1996. Optic disc hemorrhages and progression of glaucoma. *Ophthalmology* 103(7), pp. 1014-1024.

Sing, N. M. et al. 2000. The normal optic nerve head. *Optom Vis Sci* 77(6), pp. 293-301.

Soares, A. S. et al. 2003. Retinal arterial diameter changes in progressive and nonprogressive glaucoma. *J Glaucoma* 12(3), pp. 243-249.

Sonnsjo, B. et al. 2002. Disc haemorrhages, precursors of open angle glaucoma. *Prog Retin Eye Res* 21(1), pp. 35-56.

Spaeth, G. L. 1994. A new classification of glaucoma including focal glaucoma. *Surv Ophthalmol* 38 Suppl, pp. S9-17.

Spaeth, G. L. et al. 2002. The disc damage likelihood scale: reproducibility of a new method of estimating the amount of optic nerve damage caused by glaucoma. *Trans Am Ophthalmol Soc* 100, pp. 181-185; discussion 185-186.

Spaeth, G. L. et al. 1976. The optic disc in glaucoma: pathogenetic correlation of five patterns of cupping in chronic open-angle glaucoma. *Trans Sect Ophthalmol Am Acad Ophthalmol Otolaryngol* 81(2), pp. 217-223.

Spaeth, G. L. et al. 2006. Systems for staging the amount of optic nerve damage in glaucoma: a critical review and new material. *Surv Ophthalmol* 51(4), pp. 293-315.

Spalding, J. M. et al. 2000. Optic nerve evaluation among optometrists. *Optom Vis Sci* 77(9), pp. 446-452.

Sparrow, N. A. et al. 2000. Decimalization of The Oxford Clinical Cataract Classification and Grading System. *Ophthalmic Epidemiol* 7(1), pp. 49-60.

Spencer, A. F. and Vernon, S. A. 1995. Optic disc measurement: a comparison of indirect ophthalmoscopic methods. *Br J Ophthalmol* 79(10), pp. 910-915.

Spencer, A. F. and Vernon, S. A. 1996. Optic disc height measurement with the Zeiss 4-mirror contact lens and 78 dioptre lens compared. *Eye (Lond)* 10 (Pt 3), pp. 371-376.

Spry, P. G. et al. 2003. Measurement error of visual field tests in glaucoma. *Br J Ophthalmol* 87(1), pp. 107-112.

Spry, P. G. et al. 1999. The Bristol Shared Care Glaucoma Study: reliability of community optometric and hospital eye service test measures. *Br J Ophthalmol* 83(6), pp. 707-712.

Stingl, K. et al. 2010. Adaptation of a digital camera for simultaneous stereophotography in ophthalmology. *Br J Ophthalmol* 94(10), pp. 1288-1290.

Stone, R. A. et al. 2010. Utility of digital stereo images for optic disc evaluation. *Invest Ophthalmol Vis Sci* 51(11), pp. 5667-5674.

Suh, M. H. and Park, K. H. 2011. Period prevalence and incidence of optic disc haemorrhage in normal tension glaucoma and primary open-angle glaucoma. *Clin Experiment Ophthalmol* 39(6), pp. 513-519.

Susanna, R., Jr. and Vessani, R. M. 2007. New findings in the evaluation of the optic disc in glaucoma diagnosis. *Curr Opin Ophthalmol* 18(2), pp. 122-128.

Susanna, R., Jr. and Vessani, R. M. 2009. Staging glaucoma patient: why and how? *Open Ophthalmol J* 3, pp. 59-64.

Syed, Z. A. et al. Automated alternation flicker for the detection of optic disc haemorrhages. *Acta Ophthalmol*.

Syed, Z. A. et al. 2011. Automated alternation flicker for the detection of optic disc haemorrhages. *Acta Ophthalmol*.

Takagi, S. T. et al. 2012. Macular retinal ganglion cell complex damage in the apparently normal visual field of glaucomatous eyes with hemifield defects. *J Glaucoma* 21(5), pp. 318-325.

Tan, O. et al. 2009. Detection of macular ganglion cell loss in glaucoma by Fourier-domain optical coherence tomography. *Ophthalmology* 116(12), pp. 2305-2314 e2301-2302.

Teng, C. C. et al. 2010. Beta-Zone parapapillary atrophy and the velocity of glaucoma progression. *Ophthalmology* 117(5), pp. 909-915.

Theodossiades, J. and Murdoch, I. 2001a. What optic disc parameters are most accurately assessed using the direct ophthalmoscope? *Eye* 15(Pt 3), pp. 283-287.

Theodossiades, J. and Murdoch, I. 2001b. What optic disc parameters are most accurately assessed using the direct ophthalmoscope? *Eye (Lond)* 15(Pt 3), pp. 283-287.

Theodossiades, J. et al. 2004. Glaucoma case finding: a cluster-randomised intervention trial. *Eye* 18(5), pp. 483-490.

Thomas, D. and Duguid, G. 2004. Optical coherence tomography--a review of the principles and contemporary uses in retinal investigation. *Eye* 18(6), pp. 561-570.

Tielsch, J. M. et al. 1988. Intraobserver and interobserver agreement in measurement of optic disc characteristics. *Ophthalmology* 95(3), pp. 350-356.

Topouzis, F. et al. 2006. Association of blood pressure status with the optic disk structure in non-glaucoma subjects: the Thessaloniki eye study. *Am J Ophthalmol* 142(1), pp. 60-67.

Townsend, J. C. and Comer, G. W. 1987. Relative hypoplasia of the optic nerve. *J Am Optom Assoc* 58(6), pp. 494-498.

Tsai, C. S. et al. 1992. Age-related decline of disc rim area in visually normal subjects. *Ophthalmology* 99(1), pp. 29-35.

Tuck, M. W. and Crick, R. P. 1991. Efficiency of referral for suspected glaucoma. *Bmj* 302(6783), pp. 998-1000.

Uchida, H. et al. 1998. Increasing peripapillary atrophy is associated with progressive glaucoma. *Ophthalmology* 105(8), pp. 1541-1545.

Uhler, T. A. and Piltz-Seymour, J. 2008. Optic disc hemorrhages in glaucoma and ocular hypertension: implications and recommendations. *Curr Opin Ophthalmol* 19(2), pp. 89-94.

VanderBeek, B. L. et al. 2010. Comparing the detection and agreement of parapapillary atrophy progression using digital optic disk photographs and alternation flicker. *Graefes Arch Clin Exp Ophthalmol* 248(9), pp. 1313-1317.

Varma, R. et al. 1992. Expert agreement in evaluating the optic disc for glaucoma. *Ophthalmology* 99(2), pp. 215-221.

Varma, R. et al. 1994. Race-, age-, gender-, and refractive error-related differences in the normal optic disc. *Arch Ophthalmol* 112(8), pp. 1068-1076.

Vernon, S. A. 1998. The changing pattern of glaucoma referrals by optometrists. *Eye* 12 (Pt 5), pp. 854-857.

Vernon, S. A. and Adair, A. 2010. Shared care in glaucoma: a national study of secondary care lead schemes in England. *Eye (Lond)* 24(2), pp. 265-269.

Vernon, S. A. and Ghosh, G. 2001. Do locally agreed guidelines for optometrists concerning the referral of glaucoma suspects influence referral practice? *Eye* 15(Pt 4), pp. 458-463.

Vernon, S. A. et al. 1990. Screening for glaucoma in the community by non-ophthalmologically trained staff using semi automated equipment. *Eye* 4 (Pt 1), pp. 89-97.

Vessani, R. M. et al. 2009. Comparison of quantitative imaging devices and subjective optic nerve head assessment by general ophthalmologists to differentiate normal from glaucomatous eyes. *J Glaucoma* 18(3), pp. 253-261.

Vingrys, A. J. et al. 1994. The role that binocular vision and stereopsis have in evaluating fundus features. *Optom Vis Sci* 71(8), pp. 508-515.

Volk, D. 1986. Indirect ophthalmoscopy lens for use with slit lamp biomicroscope.

Watkins, R. et al. 2003. Vertical cup-to-disc ratio: agreement between direct ophthalmoscopic estimation, fundus biomicroscopic estimation, and scanning laser ophthalmoscopic measurement. *Optom Vis Sci* 80(6), pp. 454-459.

Weih, L. M. et al. 2001. Prevalence and predictors of open-angle glaucoma: results from the visual impairment project. *Ophthalmology* 108(11), pp. 1966-1972.

Weinreb, R. N. et al. 2004. Risk assessment in the management of patients with ocular hypertension. *Am J Ophthalmol* 138(3), pp. 458-467.

Weinreb, R. N. and Khaw, P. T. 2004. Primary open-angle glaucoma. *Lancet* 363(9422), pp. 1711-1720.

Weinreb, R. N. et al. 1998. Detection of glaucoma with scanning laser polarimetry. *Arch Ophthalmol* 116(12), pp. 1583-1589.

Wensor, M. D. et al. 1998. The prevalence of glaucoma in the Melbourne Visual Impairment Project. *Ophthalmology* 105(4), pp. 733-739.

Whitacre, M. M. and Stein, R. 1993. Sources of error with use of Goldmann-type tonometers. *Surv Ophthalmol* 38(1), pp. 1-30.

Wollstein, G. et al. 2000. Identifying early glaucomatous changes. Comparison between expert clinical assessment of optic disc photographs and confocal scanning ophthalmoscopy. *Ophthalmology* 107(12), pp. 2272-2277.

- Wollstein, G. et al. 1998. Identification of early glaucoma cases with the scanning laser ophthalmoscope. *Ophthalmology* 105(8), pp. 1557-1563.
- Wollstein, G. et al. 2005. Comparison of three optical coherence tomography scanning areas for detection of glaucomatous damage. *Am J Ophthalmol* 139(1), pp. 39-43.
- Wong, E. Y. et al. 2004. Detection of undiagnosed glaucoma by eye health professionals. *Ophthalmology* 111(8), pp. 1508-1514.
- Xu, L. et al. 2012. Neuroretinal rim area and body mass index. *PLoS One* 7(1), p. e30104.
- Zangwill, L. M. et al. 1999. Optic disc topographic measurements after pupil dilation. *Ophthalmology* 106(9), pp. 1751-1755.
- Zeyen, T. et al. 2003. Reproducibility of evaluation of optic disc change for glaucoma with stereo optic disc photographs. *Ophthalmology* 110(2), pp. 340-344.
- Zheng, Y. et al. 2010. Influence of height, weight, and body mass index on optic disc parameters. *Invest Ophthalmol Vis Sci* 51(6), pp. 2998-3002.

Appendix A

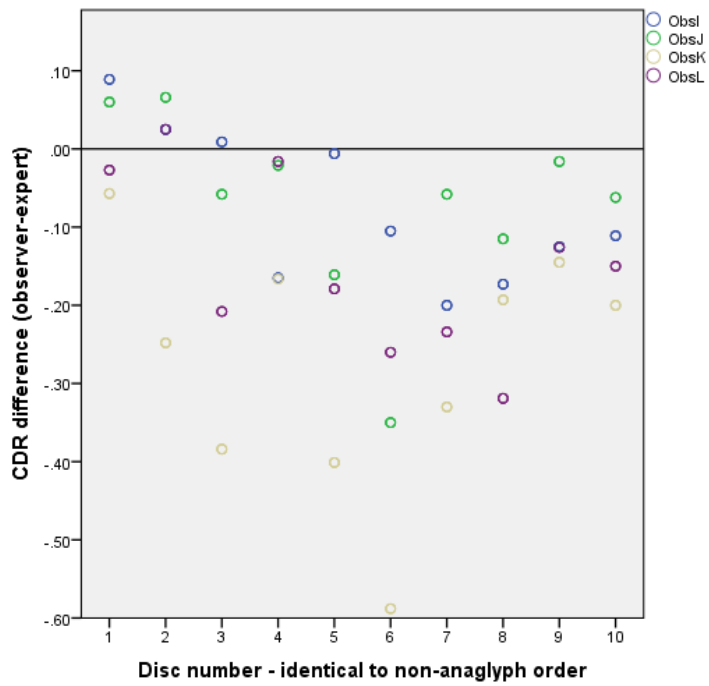


Figure A. Anaglyph teaching group I – J, '10 Discs' after teaching

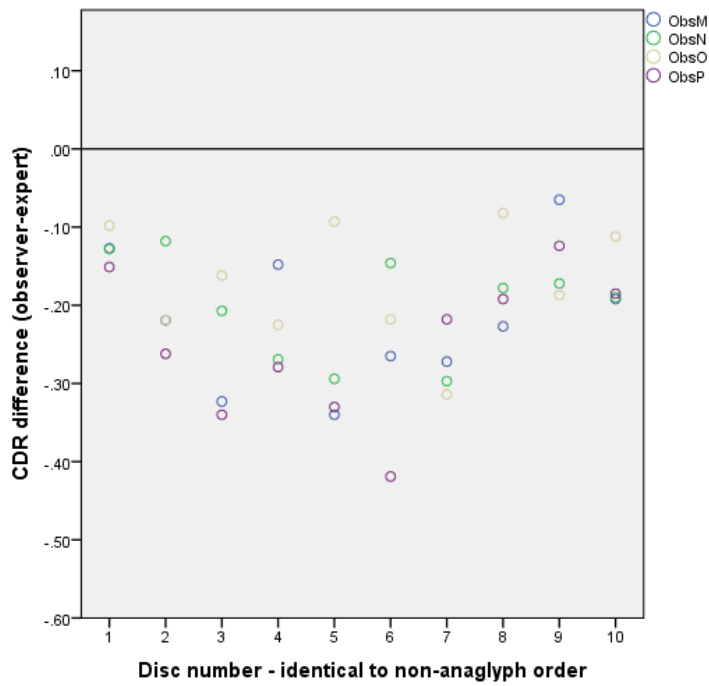


Figure B. Anaglyph controls M – P, '10 Discs' observer first assessment

Table A. Cup-to-disc ratio differences between each observer and the expert and agreement between observers in the anaglyph group '10 Discs'

Anaglyph test group								
Observer	I	J	K	L	M	N	O	P
1st assessment								
SD of difference	0.062	0.122	0.081	0.828	0.087	0.066	0.075	0.093
RMS	0.231	0.272	0.241	0.231	0.233	0.169	0.185	0.265
ICC for observers A-H = 0.749								
After Teaching								
	I	J	K	L				
SD of difference	0.098	0.120	0.156	0.114				
RMS	0.120	0.134	0.309	0.184				
(t-test) of RMS	0.00318*	0.00025*	0.19506	0.12052				
ICC for observers A-H = 0.394								
Control observers								
(No teaching)					M	N	O	P
SD of difference					0.079	0.053	0.067	0.088
RMS					0.270	0.170	0.188	0.288
(t-test) of RMS					0.31077	0.03627*	0.93543	0.48527
ICC for observers E-F = 0.704								

ICC = intraclass correlation coefficient
RMS = root mean square
SD = standard deviation
*Significant difference, P<0.05

‡ Results based on 9 or 10 ONH images (see discussion)

indicates values calculated where 10 images were available

Appendix B

Test images used in study arranged in order corresponding to graphs:

Image 1

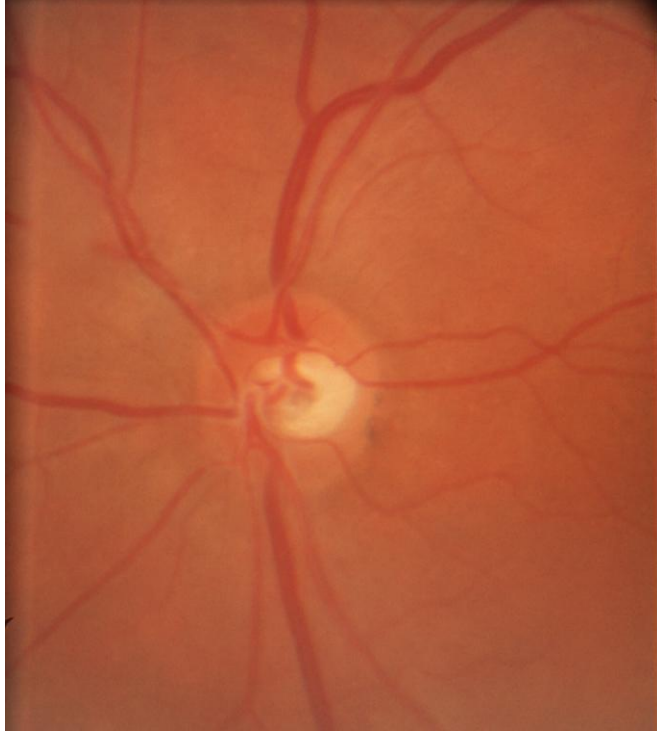


Image 2

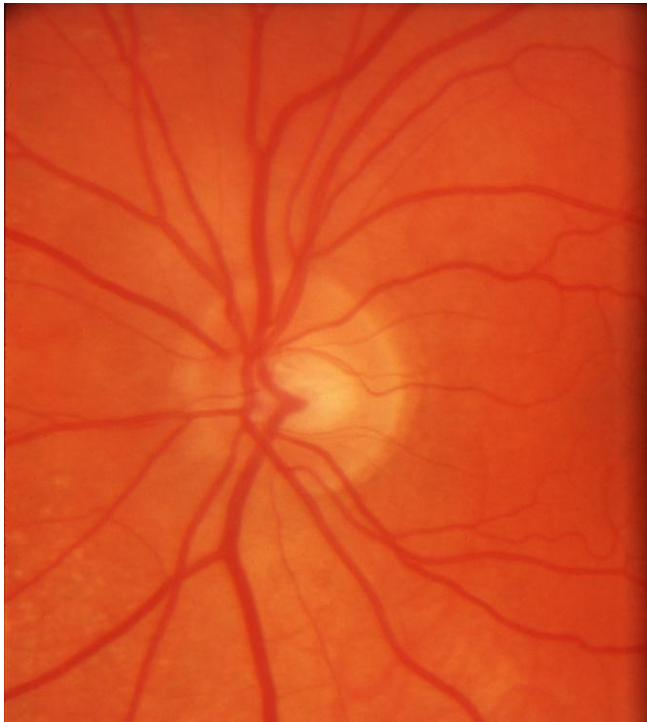

Image 3

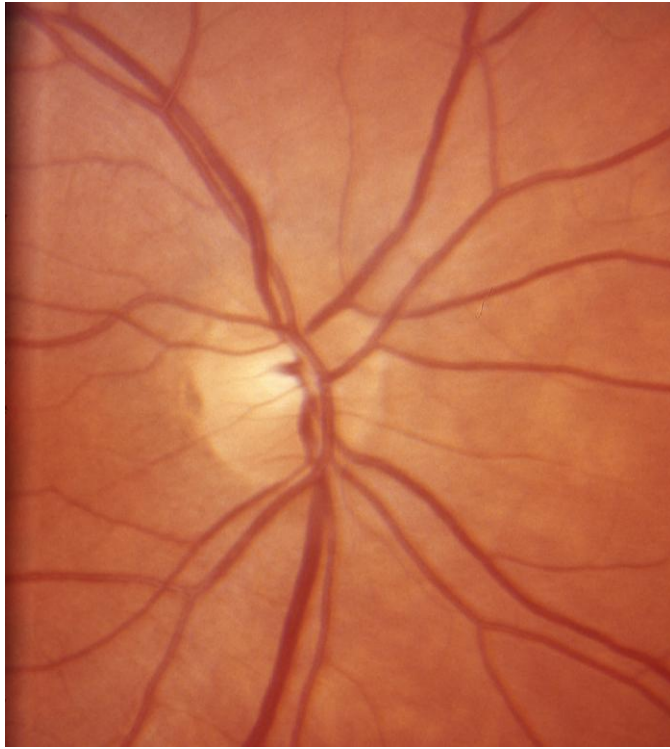


Image 4

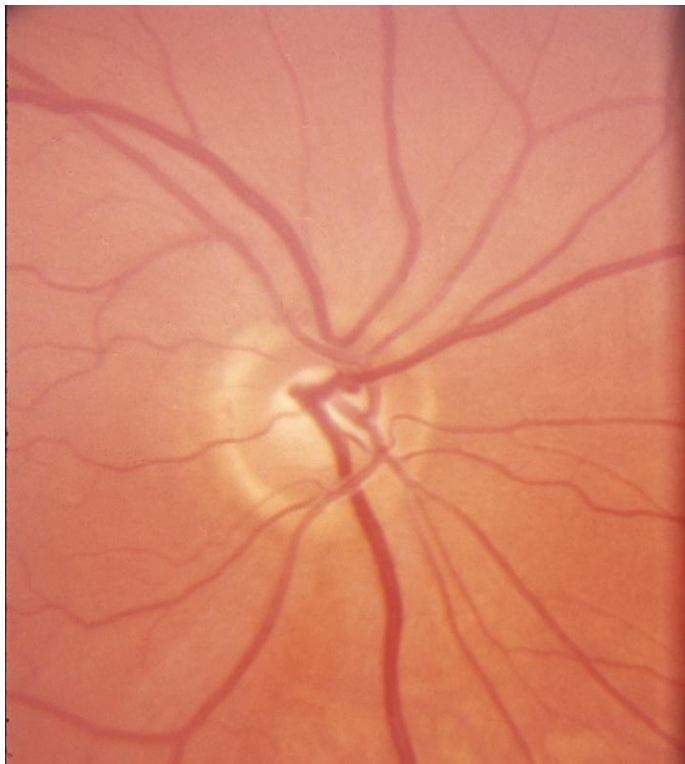


Image 5

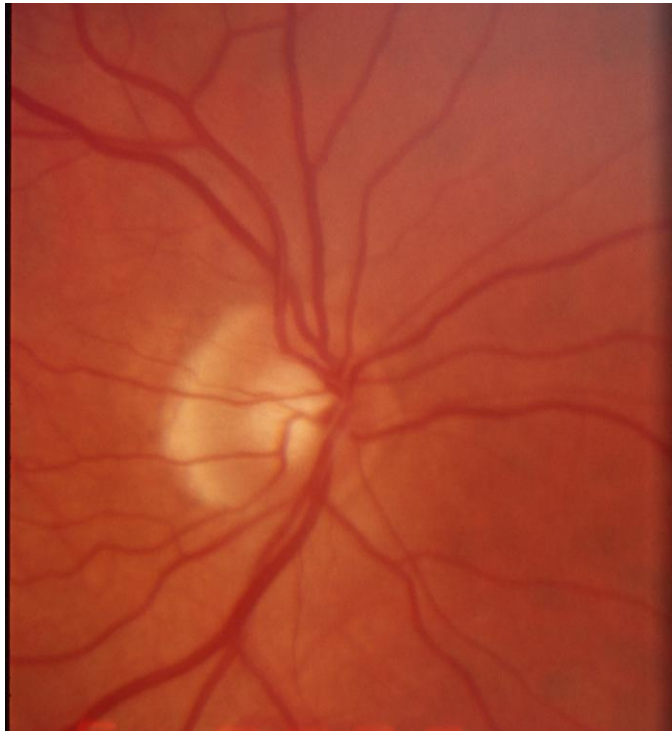

Image 6

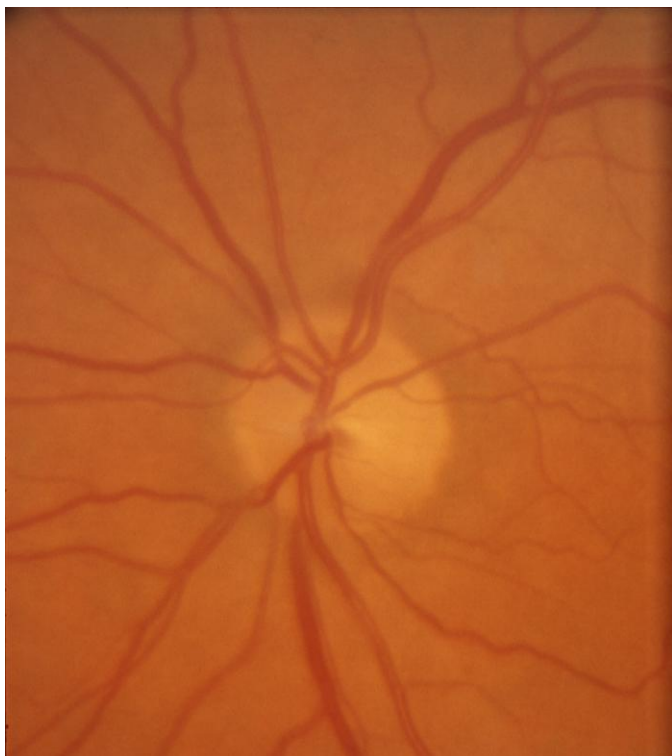

Image 7

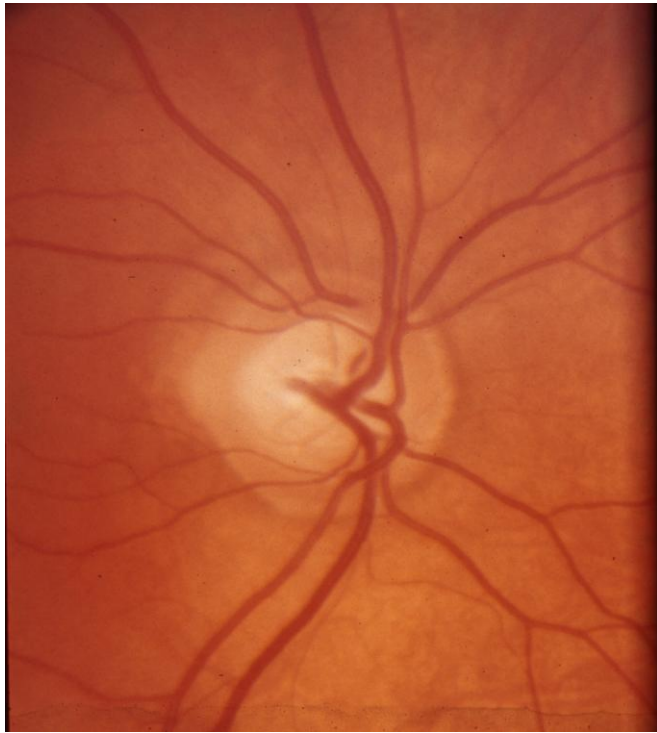


Image 8

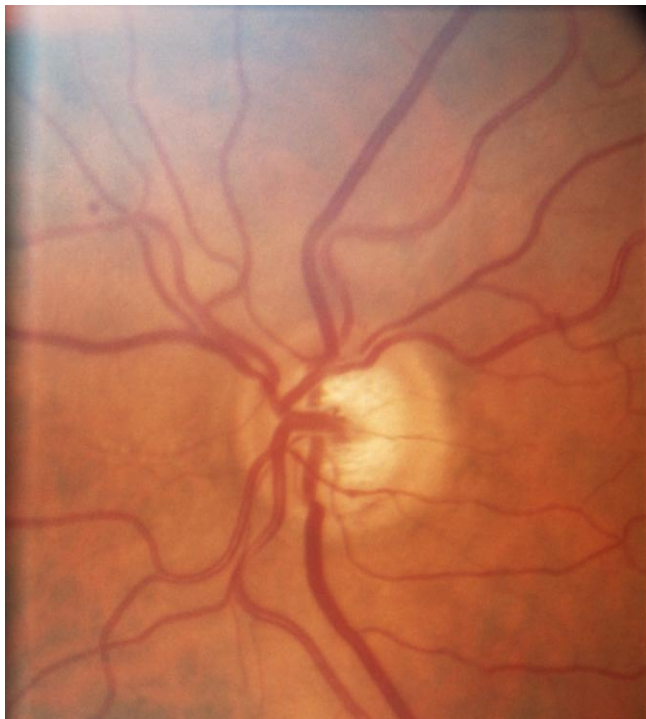

Image 9

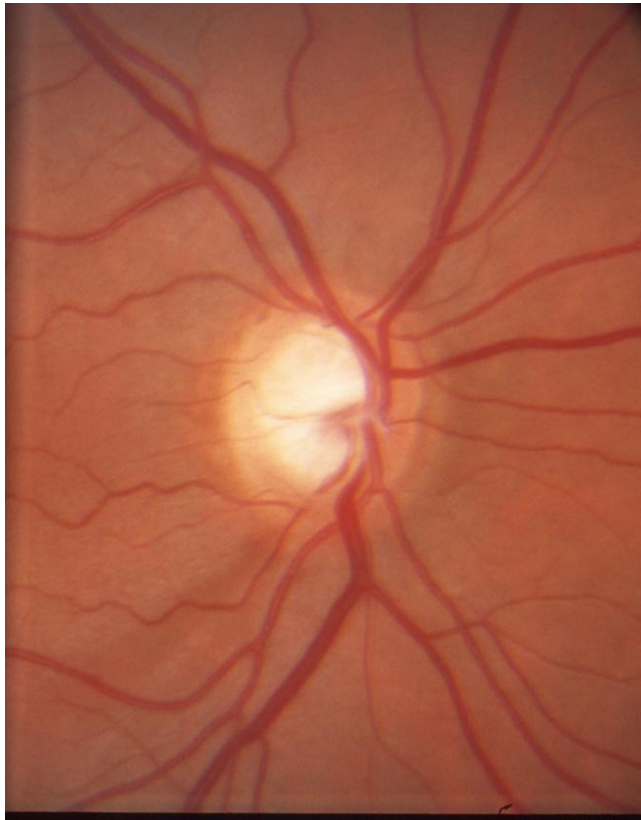

Image 10

