

Characterization of White Matter Damage in Ischemic Leukoaraiosis with Diffusion Tensor MRI

Derek K. Jones, David Lythgoe, Mark A. Horsfield, Andrew Simmons, Steve C. R. Williams and Hugh S. Markus

Stroke. 1999;30:393-397

doi: 10.1161/01.STR.30.2.393

Stroke is published by the American Heart Association, 7272 Greenville Avenue, Dallas, TX 75231

Copyright © 1999 American Heart Association, Inc. All rights reserved.

Print ISSN: 0039-2499. Online ISSN: 1524-4628

The online version of this article, along with updated information and services, is located on the World Wide Web at:

<http://stroke.ahajournals.org/content/30/2/393>

Permissions: Requests for permissions to reproduce figures, tables, or portions of articles originally published in *Stroke* can be obtained via RightsLink, a service of the Copyright Clearance Center, not the Editorial Office. Once the online version of the published article for which permission is being requested is located, click Request Permissions in the middle column of the Web page under Services. Further information about this process is available in the [Permissions and Rights Question and Answer](#) document.

Reprints: Information about reprints can be found online at:
<http://www.lww.com/reprints>

Subscriptions: Information about subscribing to *Stroke* is online at:
<http://stroke.ahajournals.org/subscriptions/>

Characterization of White Matter Damage in Ischemic Leukoaraiosis with Diffusion Tensor MRI

Derek K. Jones, MSc; David Lythgoe, PhD; Mark A. Horsfield, PhD; Andrew Simmons, PhD; Steve C.R. Williams, PhD; Hugh S. Markus, DM

Background and Purpose—Information on the neuropathological changes underlying ischemic leukoaraiosis is only available postmortem, and there are limited data on histological appearances early in the disease. Diffusion tensor imaging allows determination of the directionality of diffusion, which is greater in the direction of white matter bundles. Therefore, the technique might be expected to show loss of anisotropy (directional diffusion) in leukoaraiosis.

Methods—Nine patients with ischemic leukoaraiosis (radiological leukoaraiosis and clinical lacunar stroke) and 10 age-matched controls were studied. Diffusion tensor imaging was performed, and maps of diffusion trace and fractional anisotropy were constructed. Mean values of trace and fractional anisotropy were determined in standard regions of the anterior and posterior white matter in both hemispheres.

Results—In all patients with ischemic leukoaraiosis, a characteristic abnormal pattern was found, with loss of anisotropy and increased trace in the white matter. For example, in the right anterior white matter mean (SD) trace/3 was 1.12 (0.33) $\times 10^{-3} \text{ mm}^2 \text{ s}^{-1}$ in patients and 0.75 (0.11) in controls ($P=0.001$). In the same region, fractional anisotropy was 0.53 (0.11) in patients and 0.78 (0.09) in controls ($P<0.001$). Within the white matter regions, there was a strong negative correlation between mean diffusivity and anisotropy ($r=-0.92$, $P<0.0001$).

Conclusions—The characteristic pattern found on diffusion tensor imaging in this patient group is consistent with axonal loss and gliosis leading to impairment to and loss of directional diffusion. The “in vivo histological” information obtained may be useful in monitoring disease progression and in investigating the pathogenesis of the cognitive impairment that may be present. (*Stroke*. 1999;30:393-397.)

Key Words: cerebrovascular disorders ■ leukoaraiosis ■ magnetic resonance imaging

Lacunar infarction accounts for approximately one fourth of all strokes.¹ It results from ischemia in the territory of the deep perforating end arterioles and subsequent small discrete areas of white matter infarction. Lacunar stroke is frequently accompanied by more extensive white matter damage visible on neuroimaging, with periventricular areas of either rarefaction on CT imaging or high signal on T2-weighted MRI, an appearance referred to as leukoaraiosis.² The clinical features associated with this radiological appearance are highly variable and include lacunar stroke, subcortical dementia, gait disorder, or parkinsonian features.³ Leukoaraiosis may also be asymptomatic, and frequently patients with more extensive white matter abnormalities may have no clinical deficit, or a much less severe deficit, than patients with less extensive neuroimaging abnormalities. Furthermore, high signal appearance on MR in the periventricular white matter is not unique to ischemia and can result from other pathologies.

In this report we use the term ischemic leukoaraiosis to describe this radiological appearance in patients who also

have lacunar stroke and/or a subcortical dementia believed to be of vascular origin. In such patients postmortem studies usually reveal a reduced myelin content, axonal loss, and gliosis, which is often accompanied by small discrete lacunar infarcts.³ However, there is limited information about the underlying pathological changes early in the disease because patients may survive many years and biopsy is not clinically indicated. The recently developed MR technique of diffusion tensor imaging gives information on directionality and integrity of white matter tracts and may allow “histological information” to be obtained in vivo in such patients.

The major use of diffusion-weighted imaging to date has been to identify regions of acute ischemia within hours of onset. A diffusion reduction is seen, which may result from restriction of extracellular diffusion⁴ or from impairment of intracellular diffusion due to increased viscosity of intracellular water and/or reduced intracellular cytoplasmic streaming. This is detected as a drop in signal intensity, as indicated by a pulse sequence designed so that the signal intensity is

Received August 21, 1998; final revision received October 13, 1998; accepted October 15, 1998.

From the Division of Medical Physics, Leicester Royal Infirmary, Leicester (D.K.J., M.A.H.); Department of Clinical Neuroscience, Kings College School of Medicine and Dentistry and Institute of Psychiatry, London (D.L., A.S., S.C.R.W., H.S.M.); and Neuroimaging Department, Maudsley Hospital, London (A.S., S.C.R.W.), UK.

Correspondence to Dr Hugh Markus, Department of Clinical Neurosciences, Institute of Psychiatry, De Crespigny Park, Denmark Hill, London, UK SE5 8AF. E-mail h.markus@iop.bpmf.ac.uk

© 1999 American Heart Association, Inc.

Stroke is available at <http://www.strokeaha.org>

TABLE 1. Clinical Features in Patients With Ischemic Leukoaraiosis

Patient No.	Sex	Age, y	Age at Onset, y	HT	DM	Smoker	Cognitive Impairment	Clinical Features
1	M	73	70	+	-	+	+	Recurrent dysarthria and hemiparesis
2	M	46	45	-	-	-	-	Dysarthria and hemiparesis
3	M	57	55	+	-	+	+	Recurrent hemiparesis and hemisensory loss
4	M	71	69	+	-	+	-	Recurrent hemiparesis and dysarthria
5	F	51	48	-	-	-	+	Recurrent hemiparesis and dysarthria
6	F	73	72	+	-	+	+	Hemiparesis, dysarthria, parkinsonian features
7	M	44	40	-	-	-	-	Recurrent hemiparesis and dysarthria
8	F	67	60	+	-	-	+	Hemiparesis
9	M	74	71	+	-	+	-	Recurrent hemiparesis

HT indicates hypertensive; DM, diabetes mellitus; smoker, current or ex-smoker; and cognitive impairment, impairment on routine neuropsychological testing.

dependent on the diffusion path length of water molecules; this is conventionally expressed using the apparent diffusion coefficient (ADC).⁵ Diffusion tensor MRI can also provide information about the integrity of axonal tracts.^{6,7} In normal white matter, the rate of diffusion of water molecules is not the same in all directions. For example, diffusion along the long axis of a bundle of neurons is less restricted than across it, and consequently the ADC at a point varies according to the direction in which it is measured. This directional dependence and the resulting ambiguities in the measurement of ADC⁸⁻¹¹ prompted the introduction of diffusion tensor imaging. Diffusion tensor imaging involves the measurement of diffusion from a series of images weighted to diffusion in different directions, and the diffusion tensor is a mathematical entity that completely characterizes diffusion in all directions.⁶ This information can be used in 2 ways. First, it allows an estimation of the diffusion trace that is independent of the orientation of the sample with respect to the imaging system representing the sum of the ADCs measured in 3 orthogonal directions. Second, the tensor components reflect the extent to which the ADCs vary in different directions or the extent to which diffusion is directional or anisotropic. Several indices of anisotropy have been derived, but one of the most robust is fractional anisotropy, as proposed by Basser and Pierpaoli^{12,13}; a higher fractional anisotropy value indicates greater directionality. In free fluid, such as in the cerebrospinal fluid (CSF)-filled ventricles, the fractional anisotropy is zero, and in very ordered bundles of fibers, the fractional anisotropy approaches unity.

This technique has recently been used to construct maps of the directionality of white matter tracts within the normal brain, as well as in a single patient with stroke to show disruption of specific tracts to the region of infarcted cortex.⁷ We hypothesized that in ischemic leukoaraiosis, loss of anisotropy occurs because of axonal loss and gliosis, and therefore diffusion tensor imaging would show an abnormal pattern in this disease.

Subjects and Methods

Subjects

We studied 9 patients (mean age, 62 years; range, 44 to 74 years; 6 male) presenting to a specialized cerebrovascular neurology clinic with

recurrent lacunar strokes and leukoaraiosis demonstrated on CT and/or routine MR scans. All patients were studied at least 3 months after their last stroke. Clinical details are shown in Table 1. Six had evidence of mild cognitive impairment on routine neuropsychological testing. Three had had only single clinical lacunar strokes, while the remainder had experienced recurrent events. Carotid stenosis (>30%) was excluded in all by duplex ultrasound. In addition, we studied 10 age-matched normal community controls (mean age, 66 years; range, 53 to 77 years; all male), of whom 2 had treated hypertension, but none had diabetes. All subjects gave signed informed consent, and the study was approved by the local hospital ethics committee.

To compare the diffusion characteristics of leukoaraiosis with those of mature infarcts, we also studied 3 patients who had large ipsilateral anterior circulation infarcts with corresponding clinical deficits at least 3 months previously, secondary to ipsilateral >70% carotid stenosis (all male; aged 63, 64, and 79 years).

MR Imaging

MRI was performed with the use of a General Electric Signa (1.5-T) system (General Electric Medical Systems), with actively shielded magnetic field gradients and retrofitted resonant gradient coils (ANMR). The image acquisition was performed in the resonant mode with a maximum gradient strength of $23 \text{ mT} \cdot \text{m}^{-1}$ operating at 1 kHz, while the square (nonresonant) gradient pulses used for diffusion encoding were restricted to a maximum amplitude of $10 \text{ mT} \cdot \text{m}^{-1}$. The subject's head was secured in a quadrature birdcage head coil that was used for both radio frequency transmission and MR signal reception by means of foam padding and a strap stretched across the forehead. Daily quality assurance was performed to ensure high signal-to-ghost ratio, high signal-to-noise ratio, and excellent temporal stability by means of an automated quality control procedure.¹⁴

For diffusion tensor imaging, a spin echo-planar imaging pulse sequence was used with additional identical diffusion-encoding gradient pulses placed on either side of the 180° refocusing pulse (echo time, 170 ms; repetition time, 3000 ms; image matrix, 256×128 ; field of view, 40 cm; slice thickness, 5 mm; slice gap, 2.5 mm; number of slices, 7). A total of 56 axial images at each slice location were acquired for the purposes of calculating the diffusion tensor in each patient, consisting of 8 gradient amplitudes (equally spaced in squared amplitude) applied in 7 noncolinear directions (x , y , z , xy , xz , yz , xyz). The duration of diffusion-encoding gradients was 50 ms, and their maximum amplitude was limited by our hardware constraints to $10 \text{ mT} \cdot \text{m}^{-1}$. The maximum b factor, which quantifies the degree of diffusion weighting, was $614 \text{ s} \cdot \text{mm}^{-2}$. For each axis or combination of axes, b values were linearly incremented from 0 to $614 \text{ s} \cdot \text{mm}^{-2}$ in 8 equivalent steps. The diffusion tensor was calculated for each voxel following the method of Basser et al,⁶ and the trace and fractional anisotropy values were calculated to produce images of these indices together with a T2-weighted image. The value of trace/3 was used in the analysis, since the trace is equal to 3 times the mean diffusivity.

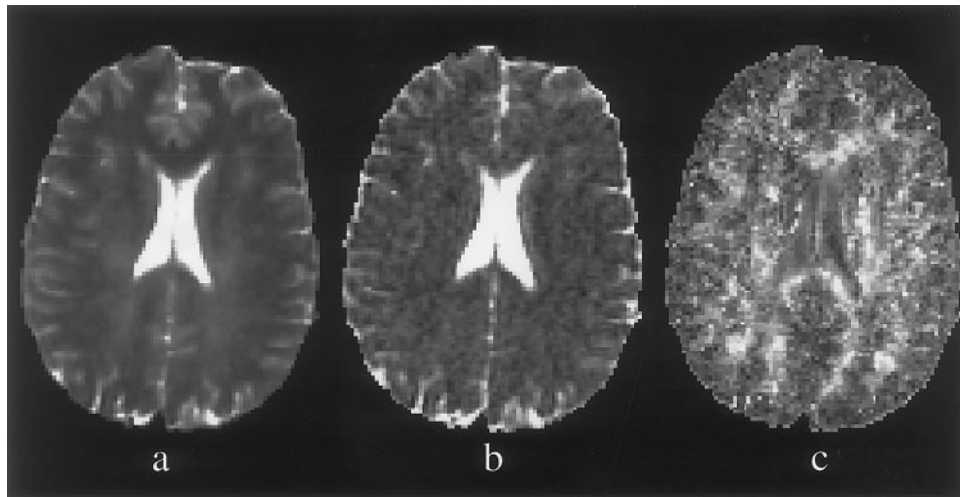


Figure 1. Typical T2-weighted (a), trace (b), and fractional anisotropy (c) images obtained from a control. On the trace image, diffusion is seen to be greatest in the CSF-filled ventricles and sulci, where there is little restriction to diffusion, and lower in tissue. Regions where the tissue is highly ordered appear brighter on the fractional anisotropy image (eg, corpus callosum). Regions where diffusion is effectively isotropic, such as in the ventricles, have lower intensity.

MR Data Analysis

Data were analyzed on an independent workstation (Sun Sparcstation, Sun Microsystems) with the use of the *dispim* image display program (David Plummer, University College Hospital, London, England). Regions of interest were positioned bilaterally in standard areas of frontal and parietal white matter adjacent to the horns of the lateral ventricles (see Results), and mean trace and fractional anisotropy values were recorded. In addition, regions of interest were placed in the center of mature infarcts in the 3 patients with carotid artery disease.

We investigated whether there were any significant differences in trace or fractional anisotropy values in left- versus right-sided and anterior versus posterior regions of the brain using Student's *t* test for paired data. The data from each region were then compared between the patient and the control groups with Student's unpaired *t* test. Finally, Pearson's linear correlation coefficient was calculated for the correlation between the trace and fractional anisotropy for all cases.

Results

Trace and fractional anisotropy brain images from a typical age-matched control are shown in Figure 1. The signal intensity in the trace image shows the directionally averaged amount of diffusion. Diffusion is greatest in the CSF-filled ventricles and sulci, where there is little restriction to diffusion, and lower in tissue. The fractional anisotropy image has higher intensity in regions that are highly ordered (such as the white matter of the corpus callosum and internal capsule), whereas it is lower in regions of "free" diffusion such as the ventricles, where, neglecting directional flow, diffusion is effectively isotropic.

In all patients with ischemic leukoaraiosis, a characteristic abnormal pattern of both diffusion trace and fractional anisotropy was found. Figure 2 shows typical results obtained

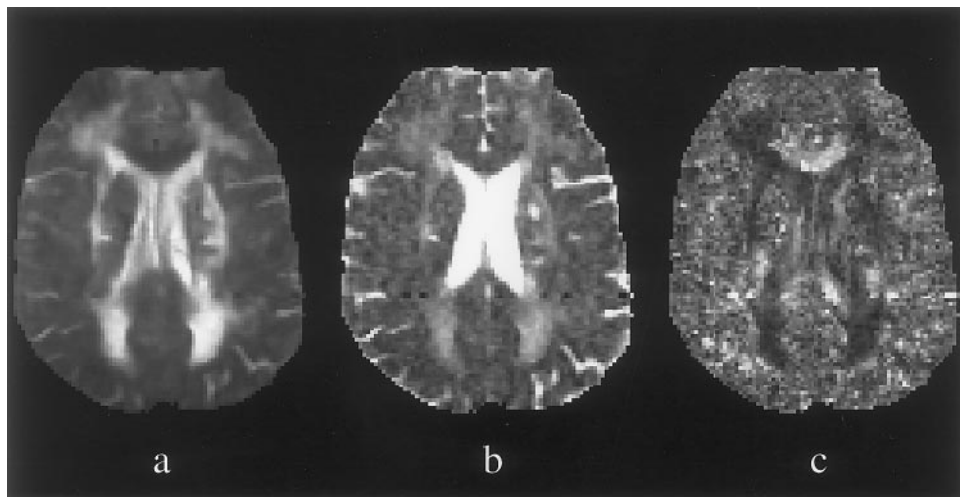


Figure 2. Typical T2-weighted (a), trace (b), and fractional anisotropy (c) images obtained from a patient. The T2-weighted image shows regions of increased signal intensity adjacent to the horns of the lateral ventricles. The trace image reveals a clear distinction between the boundaries of the ventricles and the areas of leukoaraiosis, suggesting that there is some restriction to the diffusing water molecules in the regions of leukoaraiosis. The fractional anisotropy image reveals a substantial loss of anisotropy in the regions of leukoaraiosis. Also seen are small discrete regions of high trace signal intensity, which are not readily visualized on the T2-weighted image. These appearances most likely represent mature lacunar infarcts.

from a patient. There are regions of increased signal intensity adjacent to the horns of the lateral ventricles in the T2-weighted echo-planar image. The trace image reveals a clear distinction between the boundaries of the ventricles and the regions of leukoaraiosis, indicating that although water mobility is elevated in regions of leukoaraiosis compared with the controls, the rate of diffusion is not that of free water. This suggests some restriction to the paths of the diffusing water molecules. The fractional anisotropy image reveals a substantial loss of anisotropy in the regions of leukoaraiosis compared with normal-appearing white matter.

Region of interest analysis demonstrated that in the patients with ischemic leukoaraiosis, the fractional anisotropy was significantly lower and the trace significantly higher in the periventricular regions compared with controls (Table 2). There was no significant difference between left and right or anterior and posterior white matter within each subject group, and therefore a comparison was made between the trace and fractional anisotropy from all regions of interest for all patients and also for controls. Results are plotted in Figure 3. There was a highly significant negative correlation between trace and anisotropy (Pearson's $r = -0.92$; $P < 0.0001$). Regions of interest placed in the center of the mature infarcts in the patients with carotid stenoses demonstrated that in these latter regions the trace is substantially higher than in regions of leukoaraiosis of the same fractional anisotropy, approaching that of free water at body temperature (Figure 3).

Discussion

Our results demonstrate that there is a characteristic pattern of abnormalities on diffusion tensor imaging in the white matter of patients with ischemic leukoaraiosis. There was a moderate elevation in diffusion trace with a marked loss of fractional anisotropy. The elevation of trace was less than that found in large mature infarcts secondary to carotid artery stenosis. These changes are consistent with axonal loss and proliferation of glial cells known to occur in ischemic leukoaraiosis.^{3,15} The loss of highly ordered axons will result in increased diffusion, but the extent of this increase is limited by the accompanying gliosis; therefore, the diffusion trace is lower than that seen in the center of the large, presumably necrotic, carotid stenosis infarcts in which the diffusion trace approached that seen in free water. In normal white matter, the highly directional white matter tracts

TABLE 2. Diffusion Trace/3 and Fractional Anisotropy Values in Patients and Controls

	White Matter Region			
	R Anterior	R Posterior	L Anterior	L Posterior
Trace/3 ($\times 10^{-3} \text{ mm}^2 \text{ s}^{-1}$)				
Patients	1.12 (0.33)	1.13 (0.14)	1.13 (0.27)	1.17 (0.30)
Controls	0.75 (0.11)	0.79 (0.07)	0.82 (0.11)	0.82 (0.07)
<i>P</i>	0.001	<0.001	0.003	0.003
Fractional anisotropy				
Patients	0.53 (0.11)	0.50 (0.10)	0.55 (0.15)	0.51 (0.14)
Controls	0.78 (0.09)	0.73 (0.06)	0.75 (0.12)	0.70 (0.06)
<i>P</i>	<0.001	<0.001	0.006	0.001

Mean (SD) values are shown for the 4 white matter regions studies.

result in a high degree of directional diffusion and therefore a high fractional anisotropy. In ischemic leukoaraiosis, both the loss of these ordered axonal tracts and the accompanying nondirectionally orientated gliosis result in a marked loss of fractional anisotropy.

These imaging abnormalities have a number of potential clinical applications. The extent and spatial pattern of the loss of fractional anisotropy may correlate with clinical parameters, particularly the degree of cognitive impairment. By deriving maps of the orientation of white matter tracts,⁷ it may be possible to correlate disruption of particular tracts with loss of specific cortical functions and the pattern of any cognitive impairment. Monitoring the degree of reduction in fractional anisotropy and the increase in trace may allow monitoring of disease progression.

To ensure homogeneity, we limited our study to patients with ischemic leukoaraiosis, defined as clinical lacunar stroke as well as radiological leukoaraiosis. Nevertheless, even within our group of patients clinical heterogeneity may exist. In many cases, particularly those with hypertension, the pathogenesis is likely to be small-vessel disease with lipohyalinosis of the small perforating arteries.³ However, the same clinical presentation can occur in patients without obvious conventional risk factors, as was the case in 3 of our patients. In some of these patients the underlying disorder may be CADASIL (cerebral autosomal dominant arteriopathy with subcortical infarcts and leukoencephalopathy)¹⁶; 2 of these 3 patients had a family history of stroke. With the discovery of mutations in the *Notch3* gene in families with CADASIL,¹⁷ it may be possible to determine whether there is any difference in the white matter appearances on diffusion tensor imaging between this condition and small-vessel disease associated with hypertension. Genetic testing was not performed in our patients. Nevertheless, one would expect many similarities; although the histological appearance of the perforating arteries themselves differs in CADASIL, neuropathologically multiple small deep infarcts are seen, accompanied by diffuse myelin and axonal loss and gliosis.¹⁶

One might expect diffusion tensor imaging to be able to identify areas of acute lacunar infarction characterized by

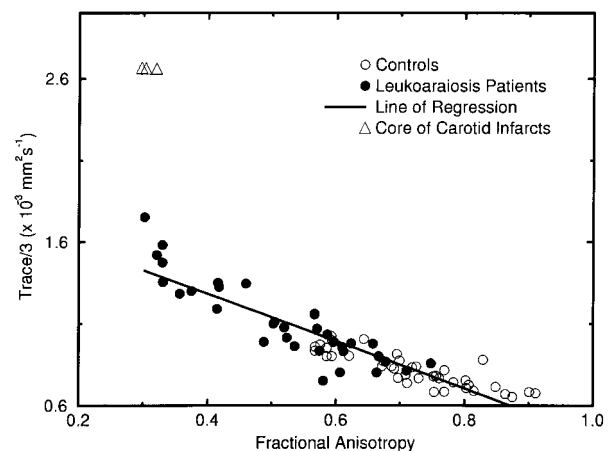


Figure 3. Mean diffusivity (trace/3) vs fractional anisotropy in leukoaraiosis patients, controls, and patients with infarcts secondary to carotid stenosis. The regression line is derived from all points except those in patients with carotid stenosis.

reduced diffusion (low tensor trace) within regions of leukoaraiosis. After an acute ischemic insult in animal models of stroke, a reduction in ADC is seen within minutes. In humans, reduced ADC has been observed within hours of stroke. The natural history of cerebral infarction appears to be that the ADC then slowly returns toward normal. This point is reached at a variable time but usually at ≈ 10 days, after which it rises to the levels seen in the mature infarcts in this study.¹⁸ We found no discrete regions of low ADC in this study, but we chose patients who had had no recent clinical event and only performed imaging on one occasion. Serial imaging may show asymptomatic acute events. It has recently been shown that diffusion-weighted imaging in patients with recent symptoms due to lacunar infarction can demonstrate regions of acutely damaged tissue in patients who have preexisting ischemic damage.¹⁹

The trace image highlighted small discrete regions of hyperintensity within regions of leukoaraiosis in some patients, as shown in Figure 2. These were not easily discernible on the T2-weighted image because of the surrounding high signal intensity of the leukoaraiosis. These regions, which were hypointense on routine clinical T1-weighted images, had a signal intensity on the trace image approaching that in the ventricles, suggesting little or no restriction to diffusion. This is consistent with the appearance of areas of mature lacunar infarction. In one patient, such a region was in a position identical to that of an internal capsular lacunar infarct visible on CT imaging after, but not before, an appropriate right hemiparesis developed.

Theoretically, one would expect the minimum value of fractional anisotropy to be zero. The minimum recorded value in this study was in the region of 0.3, which we believe was caused by a systematic bias in our data due to noise. The fractional anisotropy index measures the deviation from a perfectly isotropic system, ie, a system in which the amount of signal attenuation is the same for a given diffusion weighting, regardless of the direction in which the diffusion weighting is applied. Noise in the system leads to variations in the measured signal intensity for repeated measurements, and these errors propagate through the calculations, resulting in an estimated diffusion tensor that is anisotropic, even in isotropic conditions. This was confirmed by measurements in a large water phantom where the anisotropy is zero but was measured to be 0.3. There was no direction in which the ADC was consistently greatest, which serves to illustrate that the deviation from isotropy is due to noise rather than to a systematic error in the calculation of the diffusion tensor. Furthermore, by lowering the resolution of the images of the water phantom and therefore increasing the signal-to-noise ratio, the measured fractional anisotropy was again reduced. Because of equipment constraints, the maximum b factor we were able to use was $614 \text{ s} \cdot \text{mm}^{-2}$; this quantifies the degree of diffusion weighting. With newer MR systems, a higher b factor per unit time can be achieved, and this will result in an improvement in the signal-to-noise ratio.

We have shown a characteristic pattern of abnormality on diffusion tensor imaging in patients with ischemic leukoaraiosis consistent with the neuropathological changes of axonal loss and gliosis. This technique may have a number of applications in this disease, including improving diagnosis and monitoring the

course of disease, as well as providing new insights into the pathophysiology early in the disease course.

Acknowledgments

Our development of diffusion tensor imaging was supported by a Wellcome Trust grant (043235/Z/94/Z). Its application to patients with leukoaraiosis was supported by a grant from the Stroke Association of the UK. We are grateful to Professor Steve Jackson for help with recruiting controls subjects and to Caroline Andrews and Amanda Glover for help with MRI.

References

- Bamford J, Sandercock P, Dennis M, Burn J, Warlow C. Classification and natural history of clinically identifiable subtypes of cerebral infarction. *Lancet*. 1991;337:1521–1526.
- Hachinski VC, Potter P, Merskey H. Leuko-araiosis. *Arch Neurol*. 1987;44:21–23.
- Brown MM. Leuko-araiosis. In: Donnan GA, Norrving B, Bamford JM, Bogousslavsky J, eds. *Lacunar and Other Subcortical Infarctions*. Oxford, England: Oxford University Press; 1995.
- Warach S, Chien D, Li W, Ronthal M, Edelman RR. Fast magnetic resonance diffusion-weighted imaging of acute human stroke. *Neurology*. 1992;42:1717–1723.
- Le Bihan D, Breton E, Lallemand D, Grenier P, Cabanis E, Laval-Jeantet M. MR imaging of intravoxel incoherent motions: application to diffusion and perfusion in neurologic disorders. *Radiology*. 1986;161:401–407.
- Basser PJ, Mattiello J, Le Bihan D. MR diffusion tensor spectroscopy and imaging. *Biophys J*. 1994;66:259–267.
- Makris N, Worth AJ, Sorensen AG, et al. Morphometry of in vivo human white matter association pathways with diffusion-weighted magnetic resonance imaging. *Ann Neurol*. 1997;42:951–962.
- Moseley ME, Cohen Y, Kucharczyk J, Mintorovitch J, Asgari HS, Wendland MF, Tsuruda J, Norman D. Diffusion-weighted MR imaging of anisotropic water diffusion in cat central nervous system. *Radiology*. 1990;176:439–445.
- Chenevert TL, Brunberg JA, Pipe JG. Anisotropic diffusion in human white matter: demonstration with MR techniques in vivo. *Radiology*. 1990;177:401–405.
- Doran M, Hajnal J, Van Bruggen N, King MD, Young IR, Bydder GM. Normal and abnormal white matter tracts shown by MR imaging using directional diffusion weighted sequences. *J Comput Assist Tomogr*. 1990;14:865–873.
- Hajnal JV, Doran M, Hall AS, Collins AG, Oatridge A, Pennock JM, Young IR, Bydder GM. MR imaging of anisotropically restricted diffusion of water in nervous system: technical, anatomic and pathologic considerations. *J Comput Assist Tomogr*. 1991;15:1–18.
- Basser PJ, Pierpaoli C. Microstructural and physiological features of tissues elucidated by quantitative-diffusion-tensor MRI. *J Magn Reson Series B*. 1996;111:209–219.
- Wu O, Weisskoff RM, Copen WA, Rosen BR, Sorensen AG. Comparison of scalar metrics of anisotropy in ischemic brain using diffusion weighted magnetic resonance imaging. In: Proceedings of the International Society for Magnetic Resonance in Medicine Fifth Annual Scientific Meeting; April 12–18, 1997; Vancouver, Canada. Abstract 227.
- Simmons A, Moore E, Williams SCR. Automated quality control for functional MRI studies. *Neuroimage*. 1997;5:S466. Abstract.
- Pantoni L, Garcia JH. Pathogenesis of leukoaraiosis: a review. *Stroke*. 1997;28:652–659.
- Baudrimont M, Dubas F, Joutel A, Tournier-Lasserre E, Bousser MG. Autosomal dominant leukoencephalopathy and subcortical ischemic stroke: a clinicopathological study. *Stroke*. 1993;24:122–125.
- Joutel A, Corpechot C, Ducros A, Vahedi K, Chabriat H, Mouton P, Alamowitch S, Domenga V, C'ecillion M, Marechal E, Maciazek J, Vayssiere C, Cruaud C, Cubanis EA, Ruchoux MM, Weissenbach J, Bach JF, Bousser MG, Tournier-Lasserre E. *Notch3* mutations in CADASIL, a hereditary adult-onset condition causing stroke and dementia. *Nature*. 1996;386:707–710.
- Welch KMA, Windham J, Knight RA, Nagesh V, Hugg JW, Jacobs M, Peck D, Booker P, Dereski MO, Levine SR. A model to predict histopathology of human stroke using diffusion and T2-weighted magnetic resonance imaging. *Stroke*. 1995;26:1983–1989.
- Singer MB, Chong J, Lu D, Schonewille WJ, Tuhim S, Atlas SW. Diffusion weighted MRI in acute subcortical infarction. *Stroke*. 1998;29:133–136.