

Review

Paediatric Histoplasmosis 2000–2019: A Review of 83 Cases

Rebecca MacInnes¹ and Adilia Warris^{1,2,*}

¹ Aberdeen Fungal Group, Institute of Medical Sciences, University of Aberdeen, Aberdeen AB25 2ZD, UK; rebecca.macinnes.15@abdn.ac.uk

² MRC Centre for Medical Mycology, University of Exeter, Geoffrey Pope Building, Stocker Road, Exeter EX4 4QD, UK

* Correspondence: a.warris@exeter.ac.uk; Tel.: +44-1392-727593

Abstract: Histoplasmosis is an endemic fungal infection that is confined to specific geographical regions. *Histoplasma* spp. are primary pathogens that cause disease in both immunocompetent and immunocompromised patients, ranging from a single-organ (mostly affecting the lungs) infection to life-threatening disseminated disease. Knowledge about the clinical epidemiology relies on data from adult populations; little is known about the patient and disease characteristics in the paediatric population. Therefore, a structured review of published cases of paediatric histoplasmosis between 2000 and 2019 was performed. A literature search of PubMed was conducted and the epidemiological and clinical data from 83 cases were analysed. The mean age at presentation was 9.5 ± 5.5 years, and 51% were girls. Two-thirds of the children were immunocompromised. The majority of children presented with disseminated disease. The most frequently observed clinical symptoms were respiratory symptoms, alongside non-specific systemic features, including fever, myalgia, fatigue and weight loss. The mortality rate was 11%. Histoplasmosis affects children of any age. Being immunocompromised is a risk factor for severe and disseminated disease. The lack of specific presenting features leads to underreporting and delay in diagnosis. To improve the recognition and outcome of histoplasmosis in childhood, increased awareness and surveillance systems are warranted.

Keywords: histoplasmosis; disseminated disease; children; infants; treatment; *Histoplasma* spp.



Citation: MacInnes, R.; Warris, A. Paediatric Histoplasmosis 2000–2019: A Review of 83 Cases. *J. Fungi* **2021**, *7*, 448. <https://doi.org/10.3390/jof7060448>

Academic Editors: Nathan C. Bahr and Mathieu Nacher

Received: 14 May 2021
Accepted: 1 June 2021
Published: 4 June 2021

Publisher's Note: MDPI stays neutral with regard to jurisdictional claims in published maps and institutional affiliations.



Copyright: © 2021 by the authors. Licensee MDPI, Basel, Switzerland. This article is an open access article distributed under the terms and conditions of the Creative Commons Attribution (CC BY) license (<https://creativecommons.org/licenses/by/4.0/>).

1. Introduction

Histoplasmosis was first described in a paediatric patient in 1934, almost 30 years after the first adult patient with fatal disseminated histoplasmosis was described by Samuel Darling in 1906 [1,2]. Histoplasmosis is caused by the dimorphic fungus *Histoplasma capsulatum*, which can be divided into two varieties: *H. capsulatum* var. *capsulatum* and *H. capsulatum* var. *duboisii* [3]. *H. capsulatum* var. *duboisii* is found in Africa, whereas *H. capsulatum* var. *capsulatum* is most prevalent in the other endemic regions [4]. In addition to the traditional endemic regions, including the Ohio and Mississippi River Valleys in the United States, Central and South America and Africa, the true global distribution of histoplasmosis has recently been reported to be much more widespread [5]. Seroprevalence data and epidemiological studies from South-East Asia (in particular Thailand), Queensland and New South Wales in Australia, the Po Valley area in Italy, Quebec and Ontario in Canada and an increased number of states in the United States show that histoplasmosis is endemic across the world [5]. *Histoplasma* conidia are found in these geographic areas in soil contaminated with bird and bat guano. Activities disturbing the soil lead to the release of the infectious conidia into the air, with infection acquired by inhaling contaminated air.

Every year, thousands of people in North and Central America and Africa are infected with *Histoplasma* spp.; however, most healthy individuals remain asymptomatic, as shown by an outbreak that occurred in Iowa in 1964 [6]. Six thousand people had asymptomatic infections whilst only 87 had pulmonary disease and 1 had disseminated disease. Immunocompromised patients are at risk of developing more severe primary infections, as well as

reactivation of latent histoplasmosis and progression to disseminated disease, especially in patients with HIV [7].

Histoplasmosis in children can be asymptomatic or present as acute pulmonary histoplasmosis or disseminated histoplasmosis. Isolated single-organ infections are rarely reported [3,4]. Acute pulmonary histoplasmosis tends to be self-limiting and presents with fever, headache, malaise, chest pain and cough [8]. Presenting signs and symptoms of disseminated histoplasmosis are fever, malaise, anorexia and weight loss, hepatosplenomegaly, lymphadenopathy, mucous membrane ulceration and skin lesions [9–11]. Clinical features of histoplasmosis are non-specific and can mimic malignancies or tuberculosis [12,13].

In children living in endemic areas, asymptomatic histoplasmosis is common [14]. However, infants and immunocompromised paediatric patients are at higher risk of developing more severe disease [4,15]. Most knowledge of paediatric histoplasmosis is derived from outbreaks and case reports, and clinical management is based on adult data and experience [16]. This gap in knowledge increases the risk of late diagnosis or initial misdiagnosis, which can lead to more severe disease, and therefore, significant morbidity and mortality for children living in endemic areas. The aim of this study was to review all reported unique paediatric cases of histoplasmosis from 2000 to 2019 and extract data regarding the patient demographics, clinical features, diagnostic modalities, treatment and outcome to provide a comprehensive overview of childhood histoplasmosis.

2. Materials and Methods

A systematic literature search was conducted using PubMed. The following search terms: (histoplasmosis) OR (*Histoplasma*) were used. The following limits were applied to the search: “humans”, “age: 0–18 years” and “published between 1 January 2000–1 January 2019”. Cases were included in accordance with the inclusion and exclusion criteria (Table 1). This was done first through title analyses, then abstract analyses. Lastly, full-text analyses of the remaining results were conducted to produce a final set of studies included for final review. Diagnosis of histoplasmosis was defined as: identification of *Histoplasma* spp. via histopathological examination of tissue samples or culture or molecular methods and/or positive *Histoplasma* antigen and/or positive *Histoplasma* antibody detection. If the diagnostic modality was not specified, cases were included only if a definitive diagnosis was disclosed. Cases that did not disclose diagnostic information and specified the diagnosis as “probable” were excluded. Additionally, cases in which the age was not specified were excluded. In order to prevent selection bias, the entire search and selection process was repeated by another independent assessor (A.W.). Any inconsistencies were discussed until there was an agreement as to what studies should be included.

For each case, the following data were recorded: age, gender, disease type (single organ vs. disseminated disease), sites of infection, comorbidities, clinical features, diagnostic test results, treatment and patient outcome. When data on the infection sites were not explicitly provided, clinical features, radiographic findings or specimens used to identify the presence of *Histoplasma* spp. were used to define this. Data were managed in Microsoft Excel® and descriptive statistics were used to present the data. Statistically significant results were defined as $p < 0.05$. As the sample sizes were small, when assessing the clinical significance of two nominal variables, Fisher’s exact test was used.

Table 1. Inclusion and exclusion criteria that were used in the literature search.

	Inclusion Criteria	Exclusion Criteria	
Patient characteristics	<18 years	Exclusively ≥ 18 years	
	Diagnosis of histoplasmosis	No diagnosis of histoplasmosis	
Study	Published 1 January 2000–1 January 2019	Published before 1 January 2000	
	Full text	No full text	
	English language	Not in the English language	
	Paediatric data distinguishable from adult data	Paediatric data indistinguishable from adult data	
	Original case reports of histoplasmosis		No original case reports of histoplasmosis
			Population study in which the characteristics of individual cases were not described
Outcome measures	≥ 5 of the following outcomes described: age, gender, infection type, underlying conditions, presenting signs and symptoms, method(s) of diagnosis, treatment and patient outcome	Systematic/literature reviews	
		<5 of the following outcomes described: age, gender, infection type, underlying conditions, presenting signs and symptoms, method(s) of diagnosis, treatment and patient outcome	

3. Results

Our search strategy yielded a total of 309 papers for histoplasmosis, of which 244 papers were excluded and 65 studies were included in this review. The process of inclusion and exclusion is outlined in Figure 1. Out of the 65 papers included in the case analysis, 83 cases were identified [17–81]. The details of the individual cases included in this review are presented in Supplementary Table S1.

3.1. Patient Characteristics

The mean age (\pm standard deviation) at presentation was 9.5 ± 5.5 years, with a median age of 11 years; range: 1 month–17 years (Table 2). Of the 83 patients, 13 (15.6%) were infants (≤ 2 years). Gender was reported in 82 cases, of which 42 were female (51.2%). Most cases were reported from North America (63.9%), followed by Asia (16.9%), South America (12%) and Africa (6%). Of the 53 cases presented in North America, one young infant was diagnosed in a non-endemic area of the United States. Infection was most likely acquired via vertical transmission, with the mother being previously infected in Guatemala. The one child reported in Europe was thought to have acquired the infection in the Democratic Republic of Congo.

The patient's health status was specified in 70 cases, and 49 (72.5%) had an underlying condition reported, resulting in some form of immunosuppression (Table 2). Primary immunodeficiencies, including the hyper-IgE syndrome ($n = 4$), STAT-1 mutation ($n = 2$), T-cell deficiency ($n = 1$), interferon-gamma-receptor-1 deficiency ($n = 1$), common variable immunodeficiency ($n = 1$) and hemophagocytic lymphohistiocytosis ($n = 1$), as well as HIV, were the most common cause of immunosuppression (20.4% and 18.4%, respectively), followed by a history of renal transplantation (16.3%).

3.2. Disease Characteristics

Disease characteristics could be retrieved from 78 out of 83 cases (94%) (Table 3). Of these, 62 presented with a disseminated form of histoplasmosis, 12 had isolated pulmonary histoplasmosis, 2 had an isolated central nervous system infection, 1 suffered from laryngeal histoplasmosis and 1 had an isolated bone infection. The most commonly infected sites were the lungs (55.8%), followed by the lymphatic system (39%) and bone

marrow (31.2%) (Table 3). No differences in the infection sites or types of diseases were observed when comparing immunocompromised to immunocompetent patients ($p > 0.05$, Fisher's exact test).

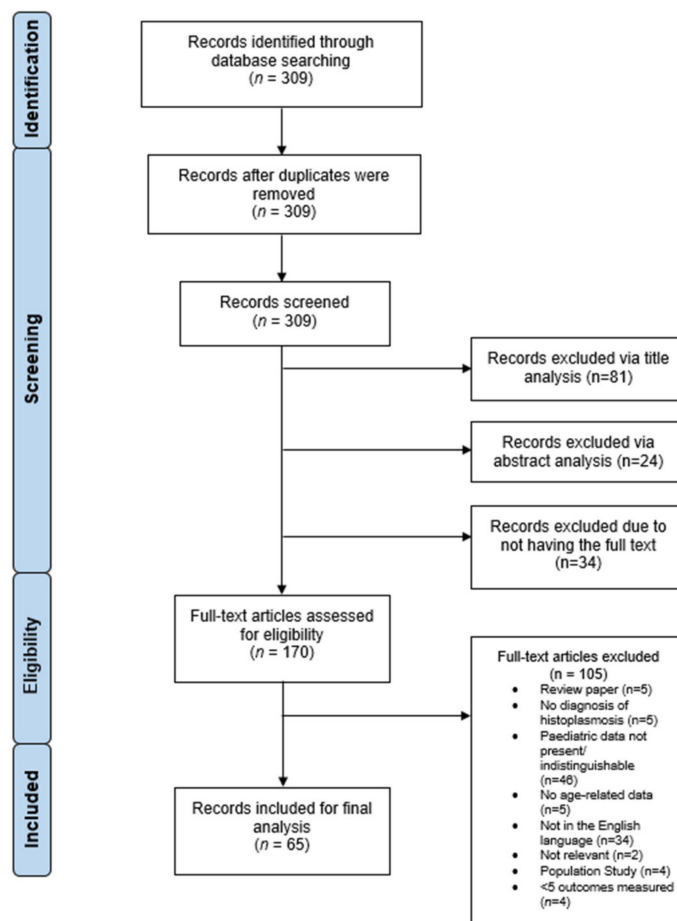


Figure 1. PRISMA flow chart demonstrating the process of inclusion/exclusion of histoplasmosis studies for analysis. The initial literature search found 309 papers related to histoplasmosis. Of these, 81 were excluded via title analysis, 24 were excluded via abstract analysis and 34 had no access to the full text. This left 170 studies, of which, 105 were excluded via full-text analysis; a total of 65 studies were included in the final analysis. Diagram adapted from Moher, D., Liberati, A., Tetzlaff, J., Altman, D.G., The PRISMA Group. (2009).

3.3. Clinical Disease Presentation

Data on the presented clinical signs and symptoms was available for 78 out of 83 cases (94%). Fever was the most commonly presented feature, occurring in 53 cases (67.9%), followed by cough (29.5%) and weight loss (28.2%) (Figure 2). Less frequent signs and symptoms included ($\leq 10\%$): nausea/vomiting ($n = 8$), diarrhoea ($n = 7$), bone/joint pain ($n = 7$), anorexia ($n = 6$), chest pain ($n = 5$), night sweats ($n = 5$), bone/joint swelling ($n = 4$), myalgia ($n = 4$), dysphagia/odynophagia ($n = 4$), seizures ($n = 3$) and slurred speech ($n = 2$). In one case, the diagnosis of histoplasmosis was an accidental finding.

3.4. Diagnosis

Details of the diagnostic modalities used were available for 94% of the paediatric patients. Histopathology or direct demonstration of *Histoplasma* spp. confirmed the diagnosis in 44 (56.4%) children, whilst a positive culture was obtained in 15 (19.2%) children. The identification of specific antibodies was performed in 37 cases, either via immunodiffusion ($n = 7$), complement fixation ($n = 8$) or a combination of both ($n = 10$).

In 12 patients, the method of antibody detection was not mentioned. *Histoplasma* antigen detection was performed in 35 cases. Molecular methods were used to confirm the presence of *Histoplasma* spp. in two cases. Table 4 provides a detailed overview of which samples were used for the diagnosis.

Table 2. Patient demographics and characteristics of 83 children with histoplasmosis.

Age (<i>n</i> = 83)	
Mean ± SD	9.5 ± 5.5 years
Median (range)	11 years (1 month–17 years)
Gender (<i>n</i> = 82)	
Female/male	42 (51.2%)/40 (48.8%)
Underlying condition (<i>n</i> = 70)	
None	21 (30.0%)
Primary immunodeficiency *	10 (14.3%)
HIV/AIDS	9 (12.9%)
Renal transplant	8 (11.4%)
Crohn's disease	6 (8.6%)
Juvenile rheumatoid arthritis	6 (8.6%)
Haematological malignancy &	4 (5.7%)
Other #	5 (7.2%)
Disease Type (<i>n</i> = 78)	
Disseminated	62 (79.5%)
Pulmonary	12 (15.4%)
Central nervous system	2 (2.6%)
Other §	2 (2.6%)
Geographic Area (<i>n</i> = 83)	
North America	53 (63.9%)
Asia	14 (16.9%)
Europe	1 (1.2%)
Africa	5 (6.0%)
South America	10 (12.0%)

* Hyper-IgE syndrome (*n* = 4), STAT1 mutation (*n* = 2), T-cell deficiency (*n* = 1), interferon-gamma-receptor-1 deficiency (*n* = 1), common variable immunodeficiency (*n* = 1), hemophagocytic lympho-histiocytosis (*n* = 1).

& Acute lymphoblastic leukaemia (*n* = 2), acute myeloid leukaemia (*n* = 1), Hodgkin's lymphoma (*n* = 1).

Idiopathic chronic anterior uveitis (*n* = 2) and juvenile systemic lupus erythematosus (*n* = 1) treated with immunosuppression; gastrointestinal stromal tumor (*n* = 1) and Wilms tumor (*n* = 1) treated with chemotherapy; EBV infection (*n* = 2); tuberculosis (*n* = 1). § Osseous (*n* = 1) and laryngeal (*n* = 1) infections.

3.5. Treatment and Outcome

Treatment details were retrieved for 69 (83%) patients (Table 5). Seven children did not receive antifungal treatment, and for six children, treatment was not specified. The most common antifungal regimen was an initial treatment with amphotericin B, followed by itraconazole, followed by an itraconazole treatment, especially in those with isolated pulmonary infection (50%). Alternative azoles used included ketoconazole, fluconazole, voriconazole and posaconazole. The mean (± standard deviation) duration of the antifungal treatment was 9.0 ± 7.4 months. Outcome data were available for 73 children (Tables 3 and 5). The majority of patients were successfully treated (*n* = 56, 76.7%). The mortality rate was 11.0% (*n* = 8). No differences in mortality were observed between the

immunocompromised and immunocompetent paediatric patients ($p > 0.05$ using Fisher's exact test).

Table 3. Disease characteristics and outcome compared between immunocompetent and immunocompromised children with histoplasmosis.

	Total	Immunocompromised	Immunocompetent
Infection site	$n = 78$	$n = 40$	$n = 23$
Lungs	43 (55.8%)	26 (65%)	10 (43.5%)
Lymph nodes	30 (39%)	16 (40%)	7 (30.4%)
Bone marrow	24 (31.2%)	16 (40%)	6 (26.1%)
Skin	12 (15.6%)	7 (17.5%)	4 (17.4%)
Central nervous system	8 (10.4%)	2 (5%)	3 (13%)
Bone	6 (7.8%)	2 (5%)	2 (8.7%)
Other *	13 (16.9%)	12 (3%)	1 (4.3%)
Disease type	$n = 78$	$n = 41$	$n = 23$
Disseminated	62 (79.5%)	36 (87.8%)	16 (69.6%)
Single organ	16 (20.5%)	5 (12.2%)	7 (30.4%)
Lungs	12 (15.4%)	4 (9.8%)	4 (17.4%)
Central nervous system	2 (2.6%)	-	2 (8.7%)
Other	2 (2.6%)	1 (2.4%), larynx	1 (4.3%), bone
Outcome	$n = 73$	$n = 43$	$n = 19$
Cure	35 (47.9%)	20 (46.5%)	10 (52.6%)
Clinical improvement	21 (28.8%)	11 (25.6%)	7 (36.8%)
Recurrence	6 (8.2%)	4 (9.3%)	1 (5.3%)
Death	8 (11%)	5 (11.6%)	1 (5.3%)
Lost to follow-up	3 (4.1%)	3 (7%)	-

* Other infection sites included: pericardium ($n = 1$), gastrointestinal tract ($n = 4$), larynx ($n = 1$), soft tissue ($n = 2$), liver ($n = 2$), spleen ($n = 1$), pancreas ($n = 1$), eye ($n = 1$).

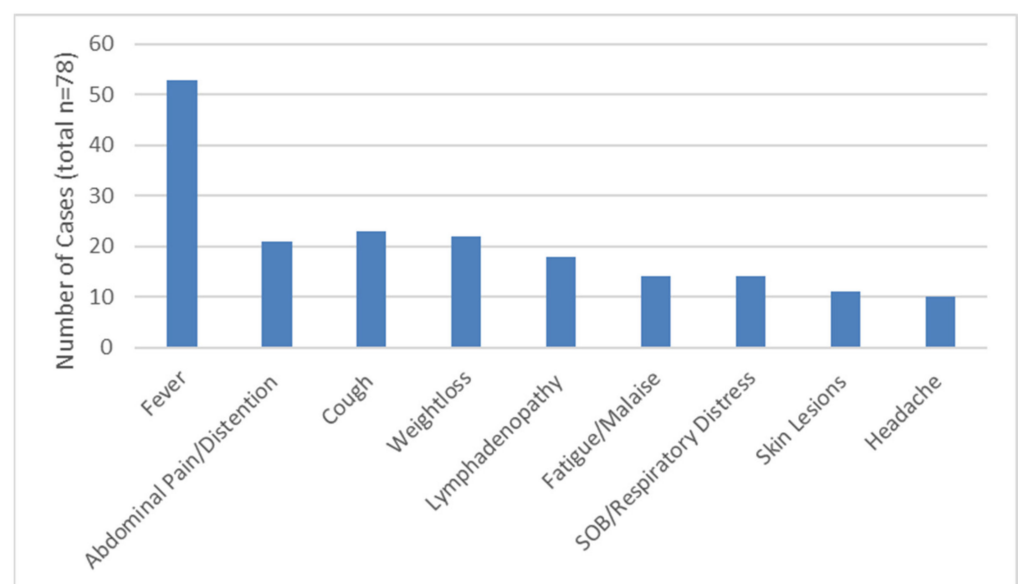


Figure 2. The most commonly presented features of the 78 children with histoplasmosis.

Table 4. Tissue and body fluids that were used to diagnose histoplasmosis in 83 paediatric patients.

	Number of Samples	Antibody	Antigen	Culture	Histopathology	Microscopy
Urine	24	-	24	-	-	-
Blood/serum	51	37	13	4	-	-
Bone marrow #	16	-	-	5	14	-
Lymph node	15	-	-	5	13	-
Bronchoalveolar lavage fluid	6	-	-	1	-	5
Skin #	7	-	-	3	5	-
Lung tissue	6	-	-	-	6	-
Cerebrospinal fluid	5	-	4	2	-	1
Bone	5	-	-	1	5	-
Gastrointestinal tissue	4	-	-	2	3	-
Other *	5	-	2	-	3	-
Not specified	11	-	10	-	1	-

* Larynx exsudate ($n = 1$), joint tissue ($n = 2$), pericardial fluid ($n = 1$), pleural fluid ($n = 1$), soft tissue ($n = 1$); # molecular methods were used on one bone marrow sample and one skin sample.

Table 5. Treatment and outcome of 83 children with histoplasmosis.

Antifungal Therapy	Number of Patients	Cured or Clinical Improvement	Recurrence	Death	Lost to Follow-Up/Not Specified
Antifungal Therapy					
AmB → Itra	31	23 (74.2%)	2	-	6
Itra only	18	15 (83.3%)	1	-	2
AmB only	11	6 (72.7%)	-	5	-
AmB → other azoles	6	5 (83.3%)	1	-	-
Other azoles	3	2 (66.7%)	1	-	-
None	7	4 (57.1%)	-	3	-
Not specified	6	1 (16.7%)	1	-	4

4. Discussion

Our systematic and extensive review of the literature produced over a period of 20 years resulted in the identification of 83 unique cases of paediatric histoplasmosis fulfilling the criteria to be included in this review. Our review complements the few data available that were derived from single-centre or single-country clinical studies in the United States and Latin America [15,82–84].

The age range and gender distribution were comparable to the previously published data and show that children of all ages are susceptible to developing symptomatic histoplasmosis [82–86]. Infants are considered to be at a higher risk of developing a more severe and disseminated form of the disease [15]. All the 13 infants included in our study presented with disseminated disease, except one; however, the outcomes were comparable between infants and children aged >1 year in our study (10% vs. 11%).

The majority of the children included in this review were living in North America (63.9%). Histoplasmosis is the most common endemic mycosis in North and Central America and was initially believed to be geographically restricted to these areas. More recently, the presence of *Histoplasma* spp. in other geographic areas, including regions in Africa, Asia and South America, is appreciated and clinical disease is increasingly being recognised [18,87–94]. Our review seems to indicate that there is an underreporting of

paediatric histoplasmosis from Africa (only 6% of the cases). Two recent reviews focusing on African histoplasmosis reported that 25% and 30% of the 57 and 94 cases, respectively, were children [95,96]. Lack of awareness and clinical recognition, as well as a lack of management resources, might well explain this observation. *Histoplasma* antigen testing is not available in many endemic areas [97], resulting in under-diagnosis and -reporting. Cases that presented outside the endemic areas are considered as “import diseases”, as illustrated by two paediatric patients included in our study [55,67]. Histoplasmosis was reported in Europe as a consequence of international travel and migration [3].

Disseminated disease was the most common presentation of histoplasmosis in our study (79.5%), followed by isolated pulmonary histoplasmosis (15.3%). The high number of paediatric patients that presented with disseminated disease is most likely not a reflection of the actual clinical epidemiology of histoplasmosis in infants and children. Publication bias and the high number of children being immunocompromised that were included in this review may have resulted in this remarkable observation. Other studies have reported lower rates of disseminated disease in non-selected paediatric patient cohorts, ranging between 29% and 64% [82,84]. Although a higher number of immunocompromised children included in our review suffered from disseminated disease (87.8% vs. 69.6%), this was not a statistically significant difference.

A high percentage (66.7%) of the children in our study suffered from an underlying condition that resulted in them being immunocompromised. HIV/AIDS, primary immunodeficiency and the receipt of a renal transplant were the most commonly reported co-morbidities. HIV/AIDS is a well-known risk factor for developing histoplasmosis [98,99] and was one of the main underlying conditions reported in our study. All children infected with HIV ($n = 9$, 12.9%) presented with disseminated disease. Histoplasmosis in kidney transplant patients carries high morbidity and mortality [100,101]. Of the nine children who developed histoplasmosis after kidney transplantation, all but one presented with disseminated disease and one child died. Unfortunately, this diagnosis was only made at the autopsy [60].

An underlying primary immunodeficiency was present in 10 children, rendering them susceptible to developing severe and disseminated histoplasmosis [23,25,29,38,41,44,59,71]. The importance of the IL-12/IFN- γ pathway and Th17-mediated responses in antifungal immune defenses is well acknowledged [102]. An increasing number of both paediatric and adult patients with inborn errors in those pathways have been reported, including patients with CD40L deficiency, IL12 or IFN- γ receptor deficiency and defects in STAT1 or STAT3 [103]. It is remarkable that the presentation of gastro-intestinal histoplasmosis mimics Crohn’s disease in patients with hyper IgE syndrome [103–105]. As an invasive fungal disease can be a presenting symptom of primary immunodeficiency, an immunological workup, including an HIV test, should be performed in a child diagnosed with severe and/or disseminated histoplasmosis.

Fever, cough and weight loss were the most frequently reported symptoms, with lymphadenopathy and/or hepatosplenomegaly being common findings on physical examination. The non-specific signs and symptoms of histoplasmosis are well known, and therefore, the differential diagnosis can cover a wide range from common childhood pneumonia, to tuberculosis, to systemic diseases, including malignancies. Knowledge of the geographic distribution of *Histoplasma* spp. and recognising host factors that expose the patient to increased risk of developing histoplasmosis will be of value for enabling a timely diagnosis and management.

Isolated CNS infection occurred in two immunocompetent children [34,46]; however, 10.4% had some form of CNS involvement. This is in contrast with the observations done in 48 Colombian children with histoplasmosis in which CNS involvement was observed in 48% of those with disseminated histoplasmosis [82]. Delay in diagnosis and/or routine screening for CNS involvement might explain the observed differences. Involvement of the CNS in adult patients with histoplasmosis is a rare finding [106,107].

Proving a diagnosis of histoplasmosis includes demonstrating the presence of the fungus via histopathology or direct microscopy in a tissue sample from an affected site

or recovery of the fungus via a culture in a specimen from a normally sterile site [108]. A proven diagnosis, as defined by the EORTC-MSG consensus definitions, was obtained in 75.6% of the paediatric patients presented in this review. *Histoplasma* antibody testing and antigen testing were performed to make a diagnosis in 47.4% and 44.9% of children, respectively. For the antibody testing, standard assays employing either complement fixation or immunodiffusion are available, with a reported sensitivity as high as 90% [109]. Paediatric-specific data about the performance of these assays are scarce, but two paediatric single-centre studies do suggest that a high percentage of children with histoplasmosis test antibody positive [82,84]. The same holds true for antigen testing, which has been used most commonly on urine samples with reported sensitivities between 76 and 90%. Sensitivity is lower when serum samples are used, with some good experiences reported using CSF and bronchoalveolar lavage samples aiding in the diagnostic process [109].

To treat paediatric histoplasmosis, the Infectious Disease Society of America (IDSA) guideline recommends following the treatment indications and regimens as used in adults [16]. Itraconazole can be used for mild-to-moderate disease, with amphotericin B (2–4 weeks) as the initial treatment for more severe and disseminated disease, followed by itraconazole for a total duration of 3 months. A longer duration of treatment is recommended depending on the severity of the histoplasmosis, concomitant use of immunosuppressive drugs or primary immunodeficiency. In our study, the majority of the patients (59%) received either itraconazole or a combination of amphotericin B followed by itraconazole. In addition, 11 (13%) patients received only amphotericin B, or amphotericin B followed by another azole ($n = 9$, 10.8%). The duration of treatment was remarkably long, with a mean of 9 months ($+/-7.4$ months). The high percentage of disseminated infections and the underlying immunocompromised conditions certainly influenced these prolonged treatment courses. No differences were noted in outcomes between immunocompromised and non-immunocompromised conditions and between the treatment regimens used. The mortality rate was 11% and comparable to observations amongst 40 infants with histoplasmosis [15], but higher than the 2.7% of 73 children with histoplasmosis reported by Quilletta et al. [84]. A study of 57 paediatric oncology patients with histoplasmosis showed no case fatalities [83], while a Colombian paediatric study could not report on mortality due to the retrospective nature of the study [82]. The higher mortality in our study is most likely explained by the higher number of children with immunosuppressive conditions, but a publication bias cannot be excluded.

To summarise, our literature review of 83 cases of paediatric histoplasmosis shows that especially children with underlying immunocompromised disorders are at risk for disseminated disease and present with aspecific signs and symptoms. Our review indicates that there is an underreporting of paediatric histoplasmosis in Africa, with a lack of awareness and clinical recognition, as well as a lack of management resources being the most likely explanations. In addition, the real clinical epidemiology of paediatric histoplasmosis is unknown, as mild disease and pulmonary histoplasmosis might go unnoticed and/or undiagnosed. Paediatric histoplasmosis is characterised by significant morbidity, with a fatal outcome in 11% of cases. Improved surveillance and awareness are warranted to obtain a better insight into the clinical epidemiology and to enable a timely diagnosis and treatment.

Supplementary Materials: The following are available online at <https://www.mdpi.com/article/10.3390/jof7060448/s1>, Table S1: Details of 83 paediatric histoplasmosis cases included in this review.

Funding: A.W. is supported by the MRC Centre for Medical Mycology (grant MR/N006364/2) at the University of Exeter.

Institutional Review Board Statement: Not applicable.

Informed Consent Statement: Not applicable.

Conflicts of Interest: The authors declare no conflict of interest.

References

1. Darling, S. A protozoan general infection producing pseudo tubercles in the lungs and focal necroses in the liver, spleen and lymph nodes. *J. Am. Med. Assoc.* **1906**, *46*, 1283–1285. [[CrossRef](#)]
2. Dodd, K.; Tompkins, E.H. A Case of Histoplasmosis of Darling in an Infant. *Am. J. Trop. Med. Hyg.* **1934**, *14*, 127–137. [[CrossRef](#)]
3. Manfredi, R.; Mazzoni, A.; Nanetti, A.; Chiodo, F. Histoplasmosis capsulati and duboisii in Europe: The impact of the HIV pandemic, travel and immigration. *Eur. J. Epidemiol.* **1994**, *10*, 675–681. [[CrossRef](#)] [[PubMed](#)]
4. Kauffman, C.A. Histoplasmosis: A Clinical and Laboratory Update. *Clin. Microbiol. Rev.* **2007**, *20*, 115–132. [[CrossRef](#)]
5. Ashraf, N.; Kubat, R.C.; Poplin, V.; Adenis, A.; Denning, D.W.; Wright, L.; McCotter, O.; Schwartz, I.S.; Jackson, B.R.; Chiller, T.; et al. Re-drawing the Maps for Endemic Mycoses. *Mycopathologia* **2020**, *185*, 843–865. [[PubMed](#)]
6. Medeiros, A.; Marty, S.; Tosh, F.; Chin, T. Erythema nodosum and erythema multiforme as clinical manifestations of histoplasmosis in a community outbreak. *N. Engl. J. Med.* **1966**, *274*, 415–420. [[CrossRef](#)] [[PubMed](#)]
7. Cunha, V.S.; Zampese, M.S.; Aquino, V.R.; Cestari, T.F.; Goldani, L.Z. Mucocutaneous manifestations of disseminated histoplasmosis in patients with acquired immunodeficiency syndrome: Particular aspects in a Latin-American population. *Clin. Exp. Dermatol.* **2007**, *32*, 250–255. [[CrossRef](#)] [[PubMed](#)]
8. Goodwin, R.A.; Loyd, J.E.; Prez, R.M.D. Histoplasmosis in Normal Hosts. *Medicine* **1981**, *60*, 231–266. [[CrossRef](#)]
9. Goodwin, R.A.; Shapiro, J.L.; Thurman, G.H.; Thurman, S.S.; Prez, R.M.D. Disseminated Histoplasmosis. *Medicine* **1980**, *59*, 1–33. [[CrossRef](#)]
10. Reddy, P.; Gorelick, D.F.; Brasher, C.A.; Larsh, H. Progressive disseminated histoplasmosis as seen in adults. *Am. J. Med.* **1970**, *48*, 629–636. [[CrossRef](#)]
11. Smith, J.W.; Utz, J.P. Progressive Disseminated Histoplasmosis. *Ann. Intern. Med.* **1972**, *76*, 557–565. [[CrossRef](#)]
12. Liu, B.; Qu, L.; Zhu, J.; Yang, Z.; Yan, S. Histoplasmosis mimicking metastatic spinal tumour. *J. Int. Med. Res.* **2017**, *45*, 1440–1446. [[CrossRef](#)]
13. Kabangila, R.; Semvua, K.; Rambau, P.; Jackson, K.; Mshana, S.; Jaka, H.; Peck, R. Pulmonary histoplasmosis presenting as chronic productive cough, fever and massive unilateral consolidation in a 15-year-old immune-competent boy: A case re-port. *J. Med. Case Rep.* **2011**, *5*, 374. [[CrossRef](#)] [[PubMed](#)]
14. Hage, C.A.; Wheat, L.J.; Loyd, J.; Allen, S.D.; Blue, D.; Knox, K.S. Pulmonary Histoplasmosis. *Semin. Respir. Crit. Care Med.* **2008**, *29*, 151–165. [[CrossRef](#)] [[PubMed](#)]
15. Odio, C.M.; Navarrete, M.; Carrillo, J.M.; Mora, L.; Carranza, A. Disseminated histoplasmosis in infants. *Pediatr. Infect. Dis. J.* **1999**, *18*, 1065–1068. [[CrossRef](#)] [[PubMed](#)]
16. Wheat, L.; Freifeld, A.; Kleiman, M.; Baddley, J.; McKinsey, D.; Loyd, J.; Kauffman, C. Clinical Practice Guidelines for the Management of Patients with Histoplasmosis: 2007 Update by the Infectious Diseases Society of America. *Clin. Infect. Dis.* **2007**, *45*, 807–825. [[CrossRef](#)] [[PubMed](#)]
17. Li, W.; Sharma, M. Unusual cause of infant pancytopenia: Granulomatous bone marrow lesion with disseminated histoplasmosis. *Blood* **2018**, *131*, 1154. [[CrossRef](#)]
18. Gupta, A.; Ghosh, A.; Singh, G.; Xess, I. A twenty-first-century perspective of disseminated histoplasmosis in India: Literature review and retrospective analysis of published and unpublished cases at a tertiary care hospital in North India. *Mycopathologia* **2017**, *182*, 1077–1093. [[CrossRef](#)]
19. Ferguson-Paul, K.; Park, C.; Childress, S.; Arnold, S.; Ault, B.; Bagga, B. Disseminated histoplasmosis in pediatric kidney transplant recipients—A report of six cases and review of the literature. *Pediatr. Transpl.* **2018**, *22*, 13274. [[CrossRef](#)]
20. Sethi, S.K.; Wadhvani, N.; Jha, P.; Duggal, R.; Sharma, R.; Bansal, S.; Kher, V. Uncommon cause of fever in a pediatric kidney transplant recipient: Answers. *Pediatr. Nephrol.* **2017**, *32*, 1527–1529. [[CrossRef](#)]
21. Leitão, T.M.J.S.; Jorge, I.F.; Freitas, A.E.H.A. Enlarged hilar lymph node due to Histoplasma. *Rev. Soc. Bras. Med. Trop.* **2016**, *49*, 663. [[CrossRef](#)] [[PubMed](#)]
22. Mathews, D.M.; John, R.; Verghese, V.; Parmar, H.; Chaudhary, N.; Mishra, S.; Mathew, L. Histoplasma capsulatum Infection with Extensive Lytic Bone Lesions Mimicking LCH. *J. Trop. Pediatr.* **2016**, *62*, 496–499. [[CrossRef](#)] [[PubMed](#)]
23. Ferguson-Paul, K.; Mangum, S.; Porter, A.; Leventaki, V.; Campbell, P.; Wolf, J. Hemophagocytic Lymphohistiocytosis and Progressive Disseminated Histoplasmosis. *Emerg. Infect. Dis.* **2016**, *22*, 1119–1121. [[CrossRef](#)] [[PubMed](#)]
24. Thapa, S.; Jha, S.C.; Trotter, A.B. Persistent Fever and Skin Lesions Due to Histoplasmosis in a Boy from Rural Nepal. *Am. J. Trop. Med. Hyg.* **2016**, *94*, 249–250. [[CrossRef](#)]
25. Odio, C.; Lee Milligan, K.; McGowan, K.; Rudman Spergel, A.; Bishop, R.; Boris, L.; Urban, A.; Welch, P.; Heller, T.; Kleiner, D.; et al. Endemic mycoses in patients with STAT3-mutated hyper-IgE (Job) syndrome. *J. Allergy Clin. Immunol.* **2015**, *136*, 1411–1413. [[CrossRef](#)]
26. Agarwal, P.; Capoor, M.; Singh, M.; Gupta, A.; Chhakhuak, A.; Debatta, P. An unusual presentation of disseminated histoplasmosis: Case report and review of pediatric immunocompetent patients from India. *Mycopathologia* **2015**, *180*, 359–364. [[CrossRef](#)]
27. Vergidis, P.; Avery, R.K.; Wheat, L.J.; Dotson, J.L.; Assi, M.A.; Antoun, S.A.; Hamoud, K.A.; Burdette, S.D.; Freifeld, A.G.; McKinsey, D.S.; et al. Histoplasmosis Complicating Tumor Necrosis Factor- α Blocker Therapy: A Retrospective Analysis of 98 Cases. *Clin. Infect. Dis.* **2015**, *61*, 409–417. [[CrossRef](#)]

28. Robayo Moriones, C.; Ortiz Guerra, C. Histoplasmosis laryngeal: Report first case in Colombia. *Colomb. Med. (Cali.)* **2014**, *45*, 186–189. [[CrossRef](#)]
29. Shukla, A.; Shah, C.; Hardik, P.; Gupte, P. A probable case of histoplasmosis presenting as portal hypertension and bone lesion in a case of common variable immunodeficiency syndrome. *J. Postgrad. Med.* **2015**, *61*, 49–50. [[CrossRef](#)]
30. Listernick, R. A 6-Year-Old Male with Daily Fever Accompanied by Nausea and Abdominal Pain. *Pediatr. Ann.* **2014**, *43*, 210–213. [[CrossRef](#)]
31. Haselow, D.T.; Safi, H.; Holcomb, D.; Smith, N.; Wagner, K.D.; Bolden, B.B.; Harik, N.S. Histoplasmosis Associated with a Bamboo Bonfire—Arkansas, October 2011. *MMWR. Morb. Mortal. Wkly. Rep.* **2014**, *63*, 165–168.
32. Ubesie, A.; Okafo, O.; Ibeziako, N.; Onukwuli, V.; Mbanefo, N.; Uzoigwe, J.; Bede, C.; Ibe, B. Disseminated Histoplasmosis in a 13-year-old girl: A case report. *Afr. Heal. Sci.* **2013**, *13*, 518–521. [[CrossRef](#)] [[PubMed](#)]
33. Centre for Disease Control and Prevention (CDC). Histoplasmosis in a state where it is not known to be endemic—Montana, 2012–2013. *Am. J. Transpl.* **2014**, *14*, 229–232. [[CrossRef](#)]
34. Schuster, J.E.; Wushensky, C.A.; Di Pentima, M.C. Chronic Primary Central Nervous System Histoplasmosis in a Healthy Child With Intermittent Neurological Manifestations. *Pediatr. Infect. Dis. J.* **2013**, *32*, 794–796. [[CrossRef](#)] [[PubMed](#)]
35. Ecka, R.S.; Bhatia, P.; Varma, N.; Marwaha, R.K. Disseminated Histoplasmosis with Peripheral Blood Spill Over. *Indian J. Pediatr.* **2013**, *81*, 313–314. [[CrossRef](#)]
36. Richmond, B.W.; Worrell, J.A.; Bastarache, J.A.; Gervich, D.H.; Slattery, W.R.; Loyd, J.E. Histoplasmosis of Uncommon Size. *Chest* **2013**, *143*, 1795–1798. [[CrossRef](#)] [[PubMed](#)]
37. Hata, J.; Johnson, M.; Booth, G. Neonatal alloimmunization: A rare case of multiple alloantibody formation in a patient with disseminated histoplasmosis. *Transfusion* **2013**, *53*, 1140–1141. [[CrossRef](#)]
38. Sampaio, E.P.; Hsu, A.P.; Pechacek, J.; Bax, H.I.; Dias, D.L.; Paulson, M.L.; Chandrasekaran, P.; Rosen, L.B.; Carvalho, D.S.; Ding, L.; et al. Signal transducer and activator of transcription 1 (STAT1) gain-of-function mutations and disseminated coccidioidomycosis and histoplasmosis. *J. Allergy Clin. Immunol.* **2013**, *131*, 1624–1634. [[CrossRef](#)]
39. Dall Bello, A.; Severo, C.; Guazzelli, L.; Oliveira, F.; Hochhegger, B.; Severo, L. Histoplasmosis simulando neoplasia primária de pulmão ou metástases pulmonares. *J. Bras. Pneumol.* **2013**, *39*, 63–68. [[CrossRef](#)]
40. Huang, L.; Wu, Y.; Miao, X. Localized *Histoplasma capsulatum* osteomyelitis of the fibula in an immunocompetent teenage boy: A case report. *BMC Infect. Dis.* **2013**, *13*, 132. [[CrossRef](#)]
41. Johansen, M.; Hoyer, M.; Kleiman, M. Transcatheter treatment of SVC syndrome from histoplasmosis-related mediastinal fibrosis in a 9-year old male. *Catheter. Cardiovasc. Interv.* **2013**, *82*, 708–711. [[CrossRef](#)]
42. França, C.M.P.; Cavalcante, E.G.; Ribeiro, A.S.M.; Oliveira, G.T.; Litvinov, N.; Silva, C.A. Disseminated histoplasmosis in a juvenile lupus erythematosus patient. *Acta Reum. Port.* **2013**, *37*, 276–279.
43. Gonçalves, D.; Ferraz, C.; Vaz, L. Posaconazole as rescue therapy in African histoplasmosis. *Braz. J. Infect. Dis.* **2013**, *17*, 102–105. [[CrossRef](#)] [[PubMed](#)]
44. Rana, C.; Krishnani, N.; Kumari, N.; Shastri, C.; Poddar, U. Rectal histoplasmosis in Job’s syndrome. *Indian J. Gastroenterol* **2012**, *32*, 64–65. [[CrossRef](#)] [[PubMed](#)]
45. Quilter, L.A.S.; Kleiman, M.B.; Kirsch, E.; Wheat, L.J. Disseminated Histoplasmosis of Infancy in one of the Twins. *Pediatr. Infect. Dis. J.* **2012**, *31*, 990–991. [[CrossRef](#)] [[PubMed](#)]
46. Threlkeld, Z.; Broughton, R.; Khan, G.; Berger, J. Isolated *Histoplasma capsulatum* meningoencephalitis in an immunocompetent child. *J. Child. Neurol.* **2012**, *27*, 532–535. [[CrossRef](#)] [[PubMed](#)]
47. Roby, B.B.; Drehner, D.; Sidman, J.D. Pediatric Tracheal and Endobronchial Tumors: An Institutional Experience. *Arch. Otolaryngol. Head Neck Surg.* **2012**, *137*, 925–929. [[CrossRef](#)]
48. Lim, L.T.; Ruzmetova, N.; Ballinger, S.H.; Moorthy, R.S. Acute pulmonary histoplasmosis in a patient with uveitis after infliximab therapy. *Int. Ophthalmol.* **2011**, *31*, 349–351. [[CrossRef](#)]
49. Zahn, M.; Hesson, M.; Morton, R.; Wheat, L.J. Granulomatous pleuritis caused by histoplasmosis in a healthy child. *Pediatr. Pulmonol.* **2011**, *46*, 729–731. [[CrossRef](#)]
50. Zöllner, M.; Rezende, K.; Birman, S.; Elias, C.; Arisawa, E.; Santos, M. Clinical and evolutionary characteristics of four patients with pulmonary histoplasmosis reported in the Paraíba Paulista Valley region. *Rev. Soc. Bras. Med. Trop.* **2010**, *43*, 599–601. [[CrossRef](#)]
51. Dhawan, J.; Verma, P.; Sharma, A.; Ramam, M.; Kabra, S.; Gupta, S. Disseminated cutaneous histoplasmosis in an immunocompetent child, relapsed with Itraconazole, successfully treated with Voriconazole. *Pediatr. Dermatol.* **2010**, *27*, 549–551. [[CrossRef](#)] [[PubMed](#)]
52. Dotson, J.; Crandall, W.; Mousa, H.; Honegger, J.; Denson, L.; Samson, C.; Cunningham, D.; Balint, J.; Dienhart, M.; Jaggi, P.; et al. Presentation and outcome of histoplasmosis in pediatric inflammatory bowel disease patients treated with anti-tumor necrosis factor alpha therapy: A case series. *Inflam. Bowel Dis.* **2011**, *17*, 56–61. [[CrossRef](#)] [[PubMed](#)]
53. Updesh, M.; Sachdeva, S.; Das, R. Peripheral smear discloses histoplasmosis. *Blood* **2010**, *115*, 3653. [[CrossRef](#)]
54. Tschudy, J.; Michail, S. Disseminated Histoplasmosis and Pneumocystis Pneumonia in a Child with Crohn Disease Receiving Infliximab. *J. Pediatr. Gastroenterol. Nutr.* **2010**, *51*, 221–222. [[CrossRef](#)]
55. Alverson, B.; Alexander, N.; LeGolvan, M.P.; Dunlap, W.; Levy, C. A human immunodeficiency virus-positive infant with probable congenital histoplasmosis in a nonendemic area. *Pediatr. Infect. Dis. J.* **2010**, *29*, 1055–1057. [[CrossRef](#)] [[PubMed](#)]

56. Perko, R.; Messinger, Y.; Moertel, C. Pseudometastasis secondary to histoplasmosis infection: False-positive PET/CT findings. *Pediatr. Blood Cancer* **2009**, *54*, 621–623. [[CrossRef](#)] [[PubMed](#)]
57. Hage, C.; Bowyer, S.; Tarvin, S.; Helper, D.; Kleiman, M.; Wheat, L.J. Recognition, diagnosis and treatment of histoplasmosis complicating tumor necrosis factor blocker therapy. *Clin. Infect. Dis.* **2010**, *50*, 85–92. [[CrossRef](#)] [[PubMed](#)]
58. Pamnani, R.; Rajab, J.; Githang'a, J.; Kasmani, R. Disseminated histoplasmosis diagnosed on bone marrow aspirate cytology: Report of four cases. *East. Afr. Med. J.* **2010**, *86*, 102–105. [[CrossRef](#)]
59. Steiner, S.; Kleiman, M.; Corkins, M.; Christenson, J.; Wheat, L. Ileocecal histoplasmosis simulating Crohn disease in a patient with hyperimmunoglobulin E syndrome. *Pediatr. Infect. Dis. J.* **2009**, *28*, 744–746. [[CrossRef](#)]
60. Vargas, F.; Gedalia, A.; Craver, R.D.; Vehaskari, V.M. Recurrence of granulomatous interstitial nephritis in transplanted kidney. *Pediatr. Transplant.* **2009**, *14*, 54–57. [[CrossRef](#)]
61. Srinivasan, A.; Kleiman, M.B.; Debelenko, L.; Stokes, D.; De Vincenzo, J.; Wheat, J.L. False-negative histoplasma antigen in acute pulmonary histoplasmosis. *Pediatr. Infect. Dis. J.* **2009**, *28*, 447–449. [[CrossRef](#)]
62. Pereira, G.; Pádua, S.; Park, M.; Muller, R.; Passos, R.; Menezes, Y. Chronic meningitis by histoplasmosis: Report of a child with acute myeloid leukemia. *Braz. J. Infect. Dis.* **2008**, *12*, 555–557. [[CrossRef](#)]
63. Freifeld, A.; Proia, L.; Andes, D.; Baddour, L.M.; Blair, J.; Spellberg, B.; Arnold, S.; Lentnek, A.; Wheat, L.J. Voriconazole Use for Endemic Fungal Infections. *Antimicrob. Agents Chemother.* **2009**, *53*, 1648–1651. [[CrossRef](#)] [[PubMed](#)]
64. Garcia-Guiñón, A.; Torres-Rodríguez, J.; Ndidongarte, D.; Cortadellas, F.; Labrín, L. Disseminated histoplasmosis by *Histoplasma capsulatum* var. *duboisii* in a paediatric patient from the Chad Republic, Africa. *Eur. J. Clin. Microbiol. Infect. Dis.* **2008**, *28*, 697–699. [[CrossRef](#)]
65. Qureshi, A. A case of histoplasmosis mimicking tuberculosis. *J. Pak. Med. Assoc.* **2008**, *58*, 457–458.
66. Rafee, Y.; Xavier, A.; Antoine, M.; Borokin, M.; Rongkavilit, C. An Infant with Fever, Hepatosplenomegaly and Pancytopenia. *Pediatr. Infect. Dis. J.* **2008**, *27*, 571. [[CrossRef](#)]
67. Loulergue, P.; Bastides, F.; Baudouin, V.; Chandenier, J.; Mariani-Kurkdjian, P.; Dupont, B.; Viard, J.; Dromer, F.; Lortholary, O. Literature review and case histories of *Histoplasma capsulatum* var. *duboisii* infections in HIV-infected patients. *Emerg. Infect. Dis.* **2007**, *13*, 1647–1652. [[CrossRef](#)]
68. Hunstad, D.; French, A. Histoplasmosis in a child with JRA on low-dose methotrexate. *Rheumatology* **2007**, *46*, 177–178. [[CrossRef](#)] [[PubMed](#)]
69. Mosam, A.; Moodley, V.; Ramdial, P.K. Persistent pyrexia and plaques: A perplexing puzzle. *Lancet* **2006**, *368*, 551. [[CrossRef](#)]
70. Garrido, L.; Mata-Essayag, S.; Hartung, D.C.; Eugenia, L.M.; Pacheco, I.; Fuentes, Z. Pulmonary histoplasmosis: Unusual histopathologic findings. *Pathol. Res. Pract.* **2006**, *202*, 373–378. [[CrossRef](#)] [[PubMed](#)]
71. Zerbe, C.S.; Holland, S.M. Disseminated Histoplasmosis in Persons with Interferon-Receptor 1 Deficiency. *Clin. Infect. Dis.* **2005**, *41*, 38–41. [[CrossRef](#)]
72. N'Golet, A.; N'Gouoni, B.G.; Moukassa, D.; Nkoua-Mbon, J.B. Maxillary African histoplasmosis: Unusual diagnostic problems of an unusual presentation. *Pathol. Res. Pract.* **2005**, *200*, 841–844. [[CrossRef](#)] [[PubMed](#)]
73. Steiner, S.; Cox, E.; Gupta, S.; Kleiman, M.; Fitzgerald, J. Esophageal diverticulum: A complication of histoplasmosis in children. *J. Pediatr.* **2005**, *146*, 426–428. [[CrossRef](#)] [[PubMed](#)]
74. Wood, K.; Hage, C.; Knox, K.; Kleiman, M.; Sannuti, A.; Day, R.; Wheat, L.; Twigg, H. Histoplasmosis after Treatment with Anti-Tumor Necrosis Factor- α Therapy. *Am. J. Respir. Crit. Care Med.* **2003**, *167*, 1279–1282. [[CrossRef](#)] [[PubMed](#)]
75. Kane, J.M.; Schmidt, K.; Conway, J.H. Fever, hepatosplenomegaly and pancytopenia in a 5-month-old infant. *Arch. Pediatr. Adolesc. Med.* **2003**, *157*, 201–205. [[CrossRef](#)]
76. McGraw, E.P.; Kane, J.M.; Kleiman, M.B.; Scherer, L. Cervical abscess and mediastinal adenopathy: An unusual presentation of childhood histoplasmosis. *Pediatr. Radiol.* **2002**, *32*, 862–864. [[CrossRef](#)]
77. Verhaert, K.; Rodriguez, M.; Mendoza, G.; Delgadillo, J.-L.; Casaer, P. Polyarthritides and humeral epiphysial separation in an infant with acute disseminated histoplasmosis. *Pediatr. Infect. Dis. J.* **2002**, *21*, 352–353. [[CrossRef](#)] [[PubMed](#)]
78. Ramdial, P.; Mosam, A.; Dlova, N.; Satar, N.B.; Aboobaker, J.; Singh, S. Disseminated cutaneous histoplasmosis in patients infected with human immunodeficiency virus. *J. Cut Pathol.* **2002**, *29*, 215–225. [[CrossRef](#)]
79. Sáez-Llorens, X. Starry, starry night. *Pediatr. Infect. Dis. J.* **2002**, *21*, 254. [[CrossRef](#)]
80. Ormerod, L.D.; Qamar, T.U.; Toller, K.; Cooperstock, M.S.; Caldwell, C.W.; Giangiacomo, J. Acute disseminated histoplasmosis with multifocal choroiditis in a child. *Pediatr. Infect. Dis. J.* **2000**, *19*, 479–481. [[CrossRef](#)]
81. Tutor, J.D.; Schoumacher, R.A.; Chesney, J.P. Chylothorax associated with histoplasmosis in a child. *Pediatr. Infect. Dis. J.* **2000**, *19*, 262–263. [[CrossRef](#)] [[PubMed](#)]
82. López, L.F.; Valencia, Y.; Tobón, Á.M.; Velásquez, O.; Santa, C.D.; Cáceres, D.H.; Restrepo, Á.; Cano, L.E. Childhood Histoplasmosis in Colombia: Clinical and Laboratory Observations of 45 Patients. *Med. Mycol.* **2016**, *54*, 677–683. [[CrossRef](#)] [[PubMed](#)]
83. Adderson, E.E. Histoplasmosis in a pediatric oncology center. *J. Pediatr.* **2004**, *144*, 100–106. [[CrossRef](#)] [[PubMed](#)]
84. Quелlette, C.P.; Stanek, J.R.; Leber, A.; Ardura, M.L. Pediatric histoplasmosis in an area of endemicity: A contemporary analysis. *J. Pediatr. Infect. Dis. Soc.* **2019**, *8*, 400–407. [[CrossRef](#)] [[PubMed](#)]
85. Vega, W.; Almeida, R.; Miño, G.; Gené, J.; Guarro, J. A quick and cost-effective method for diagnosing disseminated histoplasmosis in children. *Diagn. Microbiol. Infect. Dis.* **2007**, *57*, 405–408. [[CrossRef](#)] [[PubMed](#)]

86. Chu, J.H.; Feudtner, C.; Heydon, K.; Walsh, T.J.; Zaoutis, T.E. Hospitalizations for Endemic Mycoses: A Population-Based National Study. *Clin. Infect. Dis.* **2006**, *42*, 822–825. [[CrossRef](#)]
87. Faiolla, R.C.L.; Coelho, M.C.; Santana, R.D.C.; Martinez, R. Histoplasmosis in immunocompetent individuals living in an endemic area in the Brazilian Southeast. *Rev. Soc. Bras. Med. Trop.* **2013**, *46*, 461–465. [[CrossRef](#)] [[PubMed](#)]
88. Bahr, N.C.; Antinori, S.; Wheat, L.J.; Sarosi, G.A. Histoplasmosis Infections Worldwide: Thinking Outside of the Ohio River Valley. *Curr. Trop. Med. Rep.* **2015**, *2*, 70–80. [[CrossRef](#)]
89. Zurita, J.; Denning, D.W.; Paz-Y-Miño, A.; Solís, M.B.; Arias, L.M. Serious fungal infections in Ecuador. *Eur. J. Clin. Microbiol. Infect. Dis.* **2017**, *36*, 975–981. [[CrossRef](#)]
90. Norkaew, T.; Ohno, H.; Sriburee, P.; Tanabe, K.; Tharavichitkul, P.; Takarn, P.; Puengchan, T.; Bumrungsri, S.; Miyazaki, Y. Detection of Environmental Sources of *Histoplasma capsulatum* in Chiang Mai, Thailand, by Nested PCR. *Mycopathologia* **2013**, *176*, 395–402. [[CrossRef](#)]
91. Goswami, R.; Pramanik, N.; Banerjee, D.; Raza, M.; Guha, S.; Maiti, P. Histoplasmosis in eastern India: The tip of the iceberg? *Trans. R. Soc. Trop. Med. Hyg.* **1999**, *93*, 540–542. [[CrossRef](#)]
92. Gughani, H.C.; Muotoe-Okafor, F. African histoplasmosis: A review. *Rev. Iberoam. Micol.* **1997**, *14*, 155–159.
93. Oladele, R.; Ayanlowo, O.; Richardson, M.; Denning, D. Histoplasmosis in Africa: An emerging or a neglected disease? *PLoS Negl. Trop. Dis.* **2018**, *12*, 0006046. [[CrossRef](#)]
94. Antinori, S. *Histoplasma capsulatum*: More Widespread than Previously Thought. *Am. J. Trop. Med. Hyg.* **2014**, *90*, 982–983. [[CrossRef](#)]
95. Develoux, M.; Amona, F.M.; Hennequin, C. Histoplasmosis Caused by *Histoplasma capsulatum* var. *duboisii*: A Comprehensive Review of Cases From 1993 to 2019. *Clin. Infect. Dis.* **2020**. [[CrossRef](#)] [[PubMed](#)]
96. Amona, F.M.; Denning, D.W.; Moukassa, D.; Develoux, M.; Hennequin, C. Histoplasmosis in the Republic of Congo dominated by African histoplasmosis, *Histoplasma capsulatum* var. *duboisii*. *PLoS Negl. Trop. Dis.* **2021**, *15*, 0009318. [[CrossRef](#)] [[PubMed](#)]
97. Couppié, P.; Aznar, C.; Carme, B.; Nacher, M. American histoplasmosis in developing countries with a special focus on patients with HIV: Diagnosis, treatment and prognosis. *Curr. Opin. Infect. Dis.* **2006**, *19*, 443–449. [[CrossRef](#)] [[PubMed](#)]
98. Wheat, J.; Hafner, R.; Korzun, A.; Limj, M.; Spencer, P.; Larsen, R.; Hecht, F.; Powderly, W. Itraconazole treatment of disseminated histoplasmosis in patients with the acquired immunodeficiency syndrome. *Am. J. Med.* **1995**, *98*, 336–342. [[CrossRef](#)]
99. McKinsey, D.S.; Spiegel, R.A.; Hutwagner, L.; Stanford, J.; Driks, M.R.; Brewer, J.; Gupta, M.R.; Smith, D.L.; O'Connor, M.C.; Dall, L. Prospective Study of Histoplasmosis in Patients Infected with Human Immunodeficiency Virus: Incidence, Risk Factors and Pathophysiology. *Clin. Infect. Dis.* **1997**, *24*, 1195–1203. [[CrossRef](#)]
100. Nieto-Ríos, J.; Serna-Higuita, L.; Guzman-Luna, C.; Ocampo-Kohn, C.; Aristizabal-Alzate, A.; Ramírez, I.; Velez-Echeverri, C.; Vanegas-Ruiz, J.; Zuleta, J.; Zuluaga-Valencia, G. Histoplasmosis in renal transplant patients in an endemic area at a reference hospital in Medellín, Colombia. *Transpl. Proc.* **2014**, *46*, 3004–3009. [[CrossRef](#)]
101. Cuellar-Rodriguez, J.; Avery, R.K.; Lard, M.; Budev, M.; Gordon, S.M.; Shrestha, N.K.; Duin, D.V.; Oethinger, M.; Mawhorter, S.D. Histoplasmosis in Solid Organ Transplant Recipients: 10 Years of Experience at a Large Transplant Center in an Endemic Area. *Clin. Infect. Dis.* **2009**, *49*, 710–716. [[CrossRef](#)]
102. Lee, P.P.-W.; Lau, Y.-L. Cellular and Molecular Defects Underlying Invasive Fungal Infections—Revelations from Endemic Mycoses. *Front. Immunol.* **2017**, *8*, 735. [[CrossRef](#)] [[PubMed](#)]
103. Lovell, J.P.; Foruraghi, L.F.; Freeman, A.F.; Uzel, G.; Zerbe, C.S.; Su, H.; Hsu, A.P.; Holland, S.M. Persistent nodal histoplasmosis in NF- κ B essential modulator (NEMO) deficiency: Report of a case and review of infection in primary immunodeficiencies. *J. Allergy Clin. Immunol.* **2016**, *138*, 903–905. [[CrossRef](#)] [[PubMed](#)]
104. Alberti-Flor, J.; Granda, A. Ileocecal histoplasmosis mimicking Crohn's disease in a patient with Job's syndrome. *Digestion* **1986**, *33*, 76–180. [[CrossRef](#)] [[PubMed](#)]
105. Robinson, W.; Arnold, S.; Michael, C.; Vickery, J.; Schoumacher, R.; Pivnick, E.; Ward, J.; Nagabhusanam, V.; Lew, D. Case report of a young child with disseminated histoplasmosis and review of hyperimmunoglobulin E syndrome (HIES). *Clin. Mol. All.* **2011**, *9*, 1–7.
106. Wheat, L.J.; Batteiger, B.E.; Sathapatayavongs, B. *Histoplasma capsulatum* Infections of the Central Nervous System. *Medicine* **1990**, *69*, 244–260. [[CrossRef](#)]
107. Epelboin, L.; Dione, A.; Serris, A.; Blanchet, D.; Bidaud, B.; Walter, G.; Abboud, P.; Mosnier, E.; Gaillet, M.; Michaud, C.; et al. Histoplasmosis of the central nervous system: A case series between 1990 and 2019 in French Guiana. *Am. J. Trop. Med. Hyg.* **2021**. online ahead of print. [[CrossRef](#)] [[PubMed](#)]
108. Donnelly, J.P.; Chen, S.C.; Kauffman, C.A.; Steinbach, W.J.; Baddley, J.W.; Verweij, P.E.; Clancy, C.J.; Wingard, J.R.; Lockhart, S.R.; Groll, A.H.; et al. Revision and Update of the Consensus Definitions of Invasive Fungal Disease From the European Organization for Research and Treatment of Cancer and the Mycoses Study Group Education and Research Consortium. *Clin. Infect. Dis.* **2019**, *71*, 1367–1376. [[CrossRef](#)]
109. Linder, K.A.; Kauffman, C.A. Current and New Perspectives in the Diagnosis of Blastomycosis and Histoplasmosis. *J. Fungi* **2020**, *7*, 12. [[CrossRef](#)]