

# Psychomotor delay, dysmorphism and epilepsy with underlying genetic etiology: A case report of first child with a genetically confirmed diagnosis of Angelman Syndrome on a hospital-based setting in Iraq

Nebal W. Saadi\*

MBChB, FICP, CABP, DCH, FIBPN

**Abstract:**

In this case report we discuss essential issue to be considered with regard to the clinical genetic testing in the epilepsies. The identification of genes that influence risk for the epilepsies has extremely important implications for both research and clinical practice. In a research context, information obtained may lead to the development of new treatments targeted to specific mechanisms, or even to ways of preventing epileptogenesis. In clinical practice, the use of genetic information can either clarify the diagnosis in people already known or suspected to have epilepsy (diagnostic testing), or to predict onset of epilepsy in people at risk of developing epilepsy because of a family history (predictive testing). This 8-year old girl presented because of rapid regression in the cognitive function and had disturbed consciousness which started few weeks before admission. History of delayed milestones, epilepsy, subtle facial dysmorphism, ataxic gait and happy demeanor collectively raised suspicion of genetic/metabolic disorder. Genetic study discovered a deletion involving the maternally derived chromosome 15q11 region and this deletion is associated with Angelman Syndrome.

**Keywords:** Angelman Syndrome, Iraqi children, Clinical genetic testing.

*J Fac Med Baghdad*  
2016; Vol.58, No. 4  
Receive July. 2016  
Accepted sept.2016

**Introduction:**

Angelman syndrome is a neurogenetic imprinting disorder attributable to the reduced expression of the maternally inherited ubiquitin-protein ligase E3A gene (UBE3A) on chromosome 15. (1-4) Genetic imprinting is a process of transcription regulation based on a specific parental inheritance pattern. One allele on either the maternally or paternally inherited chromosome remains active, whereas the homologous allele inherited from the other parent is epigenetically suppressed. A number of genes in the chromosomal 15q11.q13 region are imprinted, including UBE3A, which exhibits imprinting in the central nervous system. (4-8) In England during the 1960s, pediatrician Dr. Harry Angelman identified a constellation of neurologic and non-neurologic clinical findings shared among three patients he had treated in the hospital at various times. Angelman went on to publish his landmark report "Puppet Children" in 1965 with the discovery of what became known as happy puppet syndrome. This name was based on the described phenotype, with frequent paroxysms of laughter and ataxic movement. This nomenclature has historical significance but is no longer used, as the name Angelman syndrome was introduced in 1982. (1)

Case report: Muhsen H.A.G. is 8-year old girl from the North of Iraq was admitted on November, 2015 because of increasing frequency of seizures for two weeks before admission. She had intellectual impairment and psychomotor delay noted since the

infancy period. She developed epilepsy at age of 18 months and was treated by Na Valproate which was received till age of 7 years. Four months before admission, her seizure got worsened after a period of complete control during last 5 years, so this drug was reduced gradually and Carbamazepine was added. Two weeks before admission, she developed frequent seizures with the following semiology; loss of consciousness, generalized stiffening of the body, frothy secretion from mouth and back-rolling of the eyes. Those episodes were not associated with vomiting, loss of sphincter control, tongue bite nor trauma. There was no history of fever, no changes in bowel motion nor respiratory symptoms. She had skin lesion which was nodular, itchy scattered along the armpit and right scapular region. On examination: the child was unconscious, lying in bed with repetitive myoclonic jerks involving head, limbs and trunk. She has fair complexion with blond hair and blue eyes. Subtle facial dysmorphism (especially the prominent long jaw) was noted. There were no palpable lymph nodes, jaundice, pallor nor cyanosis. The chest examination showed bilateral crepitation. Abdomen was soft and no organ was palpated. Neurological examination revealed comatose child during first two days after admission. Initially cranial nerves could be assessed roughly; she had normal eye movement without limitation, symmetrical facial expression during pain induction, normal pupillary size and reaction to light, fundi were normal. Tone of the limbs were slightly increased, Deep tendon reflexes could be elicited. After regaining consciousness, she was gradually able to move limbs symmetrically and power was roughly

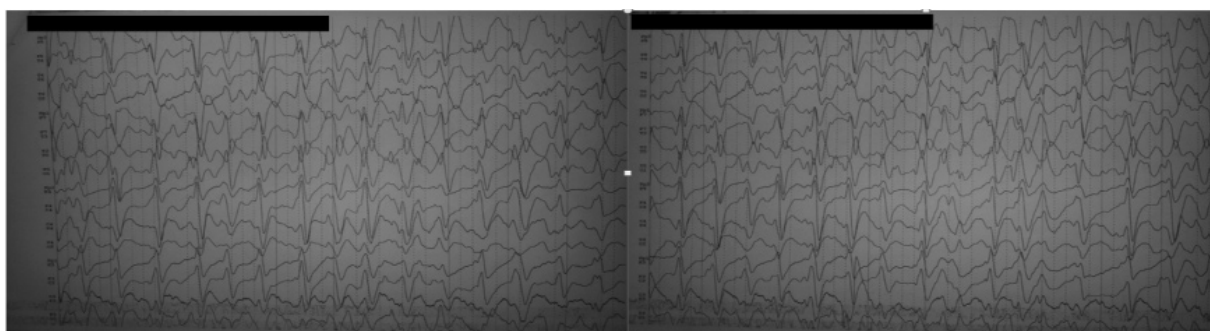
\*Dept. of Paediatrics / College of Medicine-University of Baghdad.  
Nebalpedneu2013@gmail.com

assessed to be equal to grade four. Aggressive treatment with anticonvulsant drugs (starting protocol for status epilepticus with infused Phenobarbital and then Phenytoin) was started, Na Valproate was re-inserted and Carbamazepine was reduced gradually but in a fast manner. Also Calcium was infused as there was reduced total serum Calcium (6.4 mg/dl). She regained consciousness but with unawareness of the surrounding and wasn't able to talk or walk but sat with very prominent jerky movement which then declined in numbers and severity. She was afebrile and hemodynamically stable. Feeding was improving. Vomiting reduced, she was sleepy, parenteral anticonvulsants were changed to oral syrups. With improving awareness, social interaction, feeding and after reduction of the abnormal convulsive movement, she was discharged on [Depakin syrup, 275 mg twice/day, Phenytoin syrup 30 mg twice/day and Calcium and Vitamine D syrup, teaspoonful twice/day]. The mother had poor antenatal care, but uneventful pregnancy. She was a product of normal vaginal home delivery and full term, with unremembered birth weight, with no post-natal complications nor admission to the neonatal care unit. Initially she was breast fed, then changed to family ordinary food. She didn't receive any vaccine, had no previous surgery and no allergy to a known medication nor having blood transfusion before, but she had a history of ear and chest infections. She had delay in acquiring milestones, sat at thirty six months of age, walked two months later. Family described visual behavior which might indicate gradual impairment of

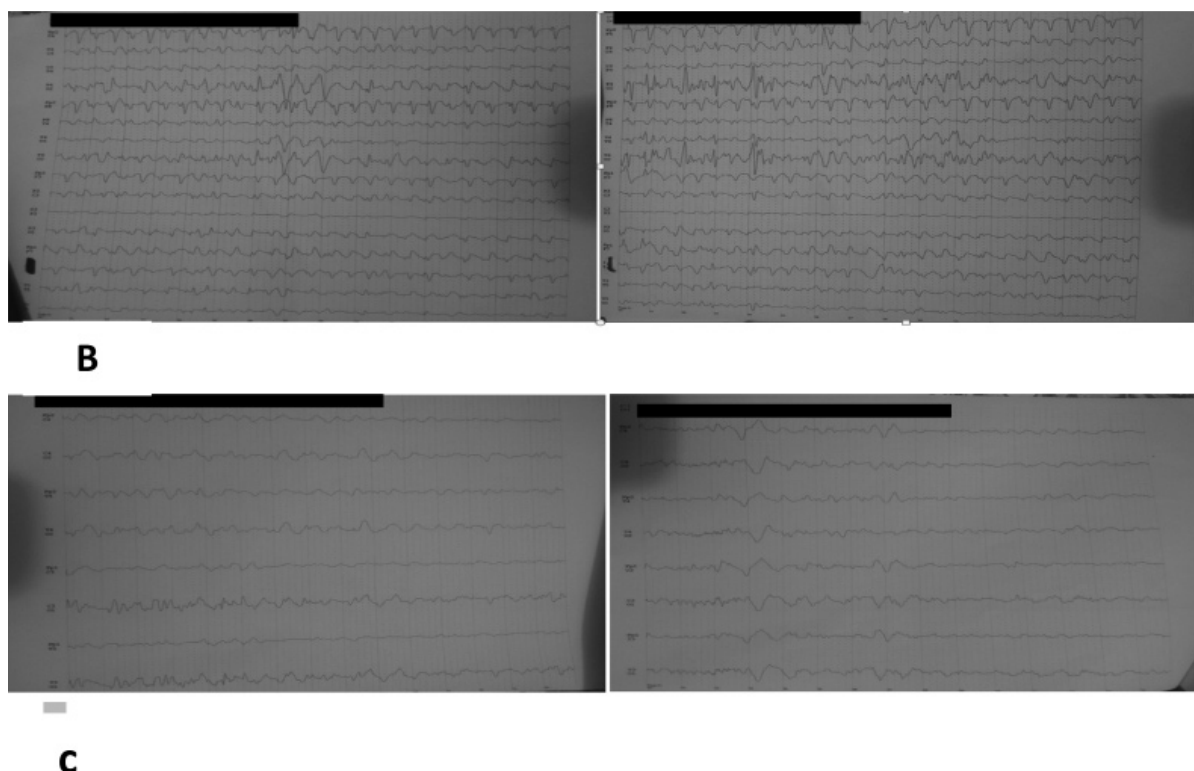
vision. Despite that delay, she is able to recognize her parents, says Baba, Mama, follow simple instructions, and walk with mild instability. However, the aforementioned slowly acquired skills were lost gradually during the two months preceding her admission. Her father is forty one - year old man, middle school graduate and her mother is thirty five - year old woman, a primary school graduate. They are first degree cousins. No similar case or hereditary disorder was reported in the family. Investigations done while in the hospital revealed CBC : Hb 12.8 g/dl , WBC 16.9 , Platelet 232,000/mm<sup>3</sup> , total serum Ca 6.4 mg/dl, Blood urea 24 mg/dl , serum Creatinine 0.8 mg/dl, Total serum Bilirubin 0.5 mg/dl, liver enzymes [SGOT 4 IU/L, SGPT 7 IU/L], ALP 165 IU/L . Second serum Calcium level was 9 mg/dl. Magnetic resonance imaging of brain was normal. Child's morphology and clinical history raised suspicion of Phenylketonuria (PKU) and therefore Tandem Mass Spectrometry was sent for and it was normal. Electroencephalogram was done repetitive epileptiform discharges was seen which indicated status epilepticus (Fig 2). Angelman Syndrome was suspected clinically and genetic test was sent to Germany. By Methylations-Specific MLPA (MS – MLPA), a heterozygous deletion of the PWS/AS region (chr 15q 11) of chromosome 15 and complete loss of mythelation of 15q11 imprinting region were found. These results suggest that the deletion involved the maternally derived 15q11 region and this deletion is associated with Angelman Syndrome.



**Fig (1):** Facial appearance of the 8 - year old child with Angleman Syndrome. Fair complexion, blond hair and subtle dysmorphic features like prominent jaw (prognathism), pointed chin, broad and flat nose, broad forehead, long face, happy and smiling demeanor.



A



**Fig 2:** (A) first electroencephalography showed long runs of generalized slow spike – wave activity in a status epilepticus manner, repeated throughout the record with generalized distribution. (B+C) improvement in the EEG findings while the patient was receiving increased dosages of Antiepileptic drugs.

#### **Discussion:**

Up to our knowledge, that was the first time that physicians in Iraq and namely pediatric neurologists, are being able to change the label “clinical suspicion” into confirmed diagnosis by the aid of genetic tests. Many children patients are encountered daily in the Children Welfare Teaching Hospital on inpatient or outpatient settings, presenting because of neurological features that necessitate detailed approach by history, general, systemic and neurological examination and laboratory tests. Yet, significant percentage of those patients is labeled as clinically suspicious disorders because of lack or inaccurate investigations that are necessary for the confirmation of the diagnosis. Patients with delayed milestones (psychomotor delay or regression) and epileptic disorders are one kind of problems faced by the pediatric neurologists in terms of reaching confirmed diagnosis. Since the beginning of 2015, genetic tests became obtainable to a certain degree and few cases were sent for since then. Our patient and her family were very lucky to present in this era of having genetic tests. In clinical practice, positive diagnostic testing results can clarify the diagnosis, provide important prognostic or treatment information and possibly save the patient and the family from expensive and uncomfortable or even invasive tests. <sup>(9)</sup> Some patients might be relieved or comforted to have a genetic explanation for their seizures or those of their family members. Either a positive or a negative test result could have

implications for reproductive decisions. With regard to the predictive testing, a negative test result can relieve anxiety and reduce the need for monitoring to detect seizures. A positive test result is likely to raise anxiety but could also enable a person to prepare for possible onset of seizures, and possibly take precautions to prevent accidents in case seizure onset should occur. It could also guide clinicians regarding the need for further investigations when seizures begin, depending on the clinical setting. In the future, prophylactic medication could theoretically be considered in some cases (although this approach has not been tested). On the other hand, genetic testing also has potential harmful effects; it can contribute to psychological distress, adverse labeling and discrimination in health insurance, life insurance and employment. The identification of genetic etiology could affect the family communication dynamics and social relationships. <sup>(9)</sup> Four genotypic mechanisms that confer the Angelman syndrome phenotype are currently known, the most common (68%) involves a microdeletion of the 15q11.2-13.1 region. <sup>(10)</sup> The majority of these deletions occurs de novo, and demonstrates a very low recurrence rate. Mutation of the maternal UBE3A gene, comprise the second most common genotype (12%). <sup>(11)</sup> These cases, in contrast to the deletion cohort, exhibit up to a 50% recurrence rate. <sup>(5,11,12)</sup> Paternal uniparental disomy, results from the inheritance of two paternal copies of chromosome 15 (7%), typically in the setting of a somatic segregation error or,

much less frequently, with Robertsonian translocation. <sup>(5,10,13)</sup> Recurrence is quite low (<1%) in cases of non-Robertsonian uniparental disomy. <sup>(5)</sup> The fourth Angelman syndrome genotype, an imprinting defect, is also quite rare (2-4%). <sup>(5)</sup> In these cases, despite biparental inheritance, the maternal allele is suppressed, secondary to aberrant methylation. Imprinting defects can occur via one of two primary mechanisms, i.e., a deletion within the imprinting center of chromosome 15 upstream of UBE3A, or more commonly through a primary epimutation. <sup>(5,10)</sup> Imprinting center deletions can recur in up to 50% of siblings. <sup>(5)</sup> Children with AS have a distinct phenotype that consists of developmental delay, microbrachycephaly, widely-spaced teeth, and prominent mandible. They have profound language delay with minimal or no speech. There are jerky, ataxic gait with raised arms and distinctive behavioral phenotype consists of hyperactivity, and happy smiling demeanor. Seizures can be difficult to control in some children. <sup>(14)</sup> Seizures can be severe, myoclonic, tonic-clonic, atonic and absences. <sup>(15)</sup> Electroencephalogram results are almost universally abnormal for individuals with Angelman syndrome. <sup>(16,17)</sup> Common background abnormalities include intermittent rhythmic delta waves (84%), Intermittent rhythmic  $\theta$  waves (44%), and posterior dominant rhythm slowing (44%). <sup>(17)</sup> Not uncommonly, individuals with Angelman syndrome manifest prolonged seizures. The prevalence of status epilepticus has been reported at up to 91%, and is often recurrent. <sup>(18,19)</sup> Nonconvulsive status epilepticus is more common than convulsive status epilepticus, and may be clinically described in a variety of ways, including reduced alertness, atypical absence status, atonic head drops, or erratic myoclonic movements. <sup>(20,18,21,22,19,23)</sup> Myoclonic status is characterized by long, recurrent periods of myoclonus with a clinical correlate of impaired attention and complex movements. <sup>(24)</sup> Although uncommon in the Angelman syndrome population, 37-51% of reported cases with myoclonic status and nonprogressive encephalopathy have occurred in individuals with Angelman syndrome. <sup>(24,25)</sup> Electrical status epilepticus of sleep, was also described in one Angelman syndrome case report. <sup>(26)</sup> Seizures in Angelman syndrome are often refractory to medications, and are clinically challenging to manage. Only 23% of individuals have been shown to respond to either their first or second medication, and 47-77% required combination therapy. <sup>(27,28,29)</sup> An electronic questionnaire-based study conducted through the Angelman Syndrome Foundation assessed epilepsy treatment in 461 subjects. <sup>(28)</sup> Valproate was the most frequently prescribed medication, as reported by 62% of the cohort. Each of several additional medications was used by 20-34% of the cohort: clonazepam, phenobarbital, topiramate, carbamazepine, lamotrigine, and levetiracetam. Dietary therapies, including the ketogenic diet and low glycemic index treatment, have produced promising results for individuals with Angelman syndrome. <sup>(28,18,30)</sup> Children with Angelman syndrome should not experience developmental regression. Thus, any child who clinically presents with a loss of previously obtained skills should be evaluated for an exacerbation of seizure activity

or other systemic pathology. <sup>(1)</sup> Symptomatic treatment is needed like physiotherapy, education, management of sleep disorders, treatment of epilepsy as aforementioned. <sup>(31)</sup> The diagnosis of AS is established in a proband who meets the consensus clinical diagnostic criteria and /or who has findings on molecular genetic testing that suggest deficient expression or function of the maternally inherited UBE3A allele. DNA methylation analysis is typically the first test ordered which identifies 80% of individuals with AS. If DNA methylation analysis is normal, testing UBE3A by sequencing analysis is performed first to detect pathogenic variant. If this cannot be identified, then testing gene-target deletion/duplication analysis or testing multi-gene panel if this individual with AS features has normal DNA methylation analysis. If both single gene testing or multi-gene testing have not confirmed a diagnosis, then more comprehensive genomic testing (if available) like Whole Exome Sequencing, Whole Genome Sequencing or Whole Mitochondrial sequencing may be considered. <sup>(32)</sup>

#### **Conclusion:**

Suspicion of genetic disorders encountered in the epilepsy setting, by pediatric neurologist ought to be raised in presence of certain features. The identification of genes that influence risk for the epilepsies has extremely important implications for clinical practice; both as diagnostic and predictive techniques, thus availability of the main genetic testing and knowing how to approach to them become essential.

#### **References:**

1. Ronald L. Thibert DO, Anna M. Larson BA, David T. Hsieh MD, Annabel R. Raby, Elizabeth A. Thiele MD, PhD. *Neurologic Manifestations of Angelman Syndrome. Pediatric Neurology* 2013 ; 48:271-279
2. Knoll JH, Nicholls RD, Magenis RE, Graham JM Jr, Lalonde M, Latt SA. *Angelman and Prader-Willi syndromes share a common chromosome 15 deletion but differ in parental origin of the deletion. Am J Med Genet* 1989;32:285-90.
3. Kishino T, Lalonde M, Wagstaff J. *UBE3A/E6-AP mutations cause Angelman syndrome. Nat Genet* 1997;15:70-3.
4. Albrecht U, Sutcliffe JS, Cattanach BM, Beechev CV, Armstrong D, Eichele G, et al. *Imprinted expression of the murine Angelman syndrome gene, UBE3A, in hippocampal and Purkinje neurons. Nat Genet* 1997 Sep;17(1):75-8.
5. Dagli A, Buiting K, Williams CA. *Molecular and clinical aspects of Angelman syndrome. Mol Syndromol* 2011 ;2:100-12.
6. Angelman H. "Puppet" children: A report on three cases. *Dev Med Child Neurol* 1965;7:681-3.
7. Williams CA, Frias JL. *The Angelman ("happy puppet") syndrome. Am J Med Genet* 1982;11:453-60.
8. Rougeulle C, Glatt H, Lalonde M. *The Angelman syndrome candidate gene, UBE3A/E6-AP, is imprinted in brain. Nat Genet* 1997;17:14-5.
9. Ottman R, Hirose S, Jain S, Lerche H, Lopes-Cendes I, Noebels JL, et al. *Genetic testing in the epilepsies - Report*

- of the ILAE commission. *Genetics. Epilepsia* 2010 Apr ;51(4):655–70.
10. Dagli AI, Williams CA. Angelman syndrome. In: Pagon RA, Bird TD, Dolan CR, Stephens K, editors. *GeneReviews*. Seattle: University of Washington; 1993. updated 2011.
  11. Clayton-Smith J, Laan L. Angelman syndrome: A review of the clinical and genetic aspects. *J Med Genet* 2003;40:87-95.
  12. Jiang Y, Lev-Lehman E, Bressler J, Tsai TF, Beudet AL. Genetics of Angelman syndrome. *Am J Hum Genet* 1999 Jul;65(1):1-6.
  13. Robinson WP, Christian SL, Kuchinka BD, Penaherrera MS, Das S, Schuffenhauer S, et al. Somatic segregation errors predominantly contribute to the gain or loss of a paternal chromosome leading to uniparental disomy for chromosome 15. *Clin Genet* 2000 ;57:349-58.
  14. Bale JR JF, Bokowsky JL, Filloux FM, Hedlund GL, Nielsen DM, Larsen PD. *A Color Handbook Pediatric Neurology*; Manson Publishing Ltd 2012. Chapter 17, the dysmorphic child. p 222.
  15. Galvan-Manso M, Campistol J, Monros E et al. Síndrome de Angelman: características físicas y fenotipo conductual en 37 pacientes con diagnóstico genético confirmado. *Rev Neurol* 2002 ;35(5):425-9.
  16. Laan LA, Renier WO, Arts WF, Buntinx IM, vd Burgt IJ, Stroink H, et al. Evolution of epilepsy and EEG findings in Angelman syndrome. *Epilepsia* 1997 Feb;38(2):195-9.
  17. Vendrame M, Loddenkemper T, Zarowski M, Gregas M, Shuhaiber H, Sarco DP, et al. Analysis of EEG patterns and genotypes in patients with Angelman syndrome. *Epilepsy Behav* 2012 Mar;23(3):261-5.
  18. Valente KD, Koiffmann CP, Fridman C, Varella M, Kok F, Andrade JQ, et al. Epilepsy in patients with Angelman syndrome caused by deletion of the chromosome 15q11-13. *Arch Neurol* 2006 ;63:122-8.
  19. Ohtsuka Y, Kobayashi K, Yoshinaga H, Ogino T, Ohmori I, Ogawa K, et al. Relationship between severity of epilepsy and developmental outcome in Angelman syndrome. *Brain Dev* 2005 Mar;27(2):95-100.
  20. Galvan-Manso M, Campistol J, Conill J, Sanmarti FX. Analysis of the characteristics of epilepsy in 37 patients with the molecular diagnosis of Angelman syndrome. *Epileptic Disord* 2005 ;7:19-25.
  21. Matsumoto A, Kumagai T, Miura K, Miyazaki S, Hayakawa C, Yamanaka T. Epilepsy in Angelman syndrome associated with chromosome 15q deletion. *Epilepsia* 1992 ;33:1083-90.
  22. Uemura N, Matsumoto A, Nakamura M, Watanabe K, Negoro T, Kumagai T, et al. Evolution of seizures and electroencephalographical findings in 23 cases of deletion type Angelman syndrome. *Brain Dev* 2005 Aug;27(5):383-8.
  23. Espay AJ, Andrade DM, Wennberg RA, Lang AE. Atypical absences and recurrent absence status in an adult with Angelman syndrome due to the UBE3A mutation. *Epileptic Disord* 2005 ;7:227-30.
  24. Caraballo RH, Cersosimo RO, Espeche A, Arroyo HA, Fejerman N. Myoclonic status in nonprogressive encephalopathies: Study of 29 cases. *Epilepsia* 2007;48:107-13.
  25. Dalla Bernardina B, Fontana E, Darra F. Myoclonic status in nonprogressive encephalopathies. *Adv Neurol* 2005 ;95:59-70.
  26. Rubin DI, Patterson MC, Westmoreland BF, Klass DW. Angelman's syndrome: Clinical and electroencephalographic findings. *Electroencephalogr Clin Neurophysiol* 1997 ;102:299-302.
  27. Ruggieri M, McShane MA. Parental view of epilepsy in Angelman syndrome: A questionnaire study. *Arch Dis Child* 1998 ;79:423-6.
  28. Thibert RL, Conant KD, Braun EK, et al. Epilepsy in Angelman syndrome: A questionnaire-based assessment of the natural history and current treatment options. *Epilepsia* 2009 ;50:2369-76.
  29. Nolt DH, Mott JM, Lopez WL. Assessment of anticonvulsant effectiveness and safety in patients with Angelman's syndrome using an internet questionnaire. *Am J Health Syst Pharm* 2003 ;60: 2583-7.
  30. Evangelidou A, Doulioglou V, Haidopoulou K, Aptouramani M, Spilioti M, Varlamis G. Ketogenic diet in a patient with Angelman syndrome. *Pediatr Int* 2010 ;52:831-4.
  31. Compas – Casello J. Angelman Syndrome. *Orphanet Encyclopedia Sep* 2004. <http://www.orpha.net/data/patho/GB/uk-Angelman.pdf>
  32. Dagli AI, Mueller J, Williams CA. Angelman Syndrome. *NCBI Bookshelf last updated May 14, 2015*. <http://www.ncbi.nlm.nih.gov/books>.