

CASE REPORT

Two cases of skin hyperpigmentation induced by polymyxin B

Dois casos de hiperpigmentação cutânea induzido pela polimixina B

Cássio Alexandre Oliveira Rodrigues¹, Rand Randall Martins², Eduardo Queiroz da Cunha³, Marizaldo de Souto Lima¹, Valdjane Saldanha⁴

¹Multiprofessional Residence Program, Hospital Universitário Onofre Lopes (HUOL) - Natal (RN), Brazil.

²Pharmacy Department, Universidade Federal do Rio Grande do Norte (UFRN) - Natal (RN), Brazil.

³Adult Intensive Care Unit, Hospital Universitário Onofre Lopes (HUOL) - Natal (RN), Brazil.

⁴Clinical Pharmacy Unit, Hospital Universitário Onofre Lopes (HUOL) - Natal (RN), Brasil.

DOI: <https://dx.doi.org/10.7322/abcshs.v44i2.1170>

ABSTRACT

Introduction: The skin hyperpigmentation process involves biochemical and immunological mechanisms that stimulate melanogenesis and although nephrotoxicity consists of the most relevant adverse reaction of polymyxin B, it is also associated with this changes. **Case report:** Case 1: male patient, diagnosed with Hodgkin's Lymphoma, who developed skin hyperpigmentation after starting treatment with meropenem, anidulafungin and polymyxin B due to a septic shock. Case 2: male patient, admitted to the ICU for decreased level of consciousness and suspected STEMI, diagnosed with endocarditis and pericarditis, who also presented skin hyperpigmentation during therapy with amphotericin B and polymyxin B. **Conclusion:** After careful evaluation of chronological order and drugs used by patients, we conclude that polymyxin B caused hyperpigmentation in both patients. Finally, based on the mechanism of this reaction and the scientific findings, clinical studies that may evidence a probable pharmacological effect with the use of H2 antagonists are required.

Keywords: Polymyxin B; Hyperpigmentation; drug-related side effects and adverse reactions.

RESUMO Introdução: O processo de hiperpigmentação cutânea envolve mecanismos bioquímicos e imunológicos que estimulam a melanogênese e apesar da nefrotoxicidade consistir na reação adversa mais relevante da polimixina B, o antimicrobiano também está associado a esta alteração. **Relato do caso:** Caso 1: paciente masculino diagnosticado com Linfoma de Hodgkin, que desenvolveu hiperpigmentação cutânea após iniciar tratamento com meropenem, anidulafungina e polimixina B devido a um quadro de choque séptico. Caso 2: paciente masculino admitido na UTI por rebaixamento do nível de consciência e suspeita de IAMCSST, diagnosticado com endocardite e pericardite, que também apresentou hiperpigmentação cutânea durante terapia com anfotericina B e polimixina B. **Conclusão:** Após criteriosa avaliação da ordem cronológica e medicamentos utilizados pelos pacientes, concluímos que a polimixina B desencadeou a hiperpigmentação em ambos. Por fim, baseado ao mecanismo desta reação e aos achados científicos, estudos clínicos que possam evidenciar um provável efeito farmacológico com o uso de antagonistas H2 são necessários.

Palavras-chave: Polimixina B; Hiperpigmentação; efeitos colaterais e reações adversas relacionados a medicamentos.

Received on: 05/23/2018

Revised on: 11/04/2018

Accepted on: 12/20/2018

Corresponding author: Cássio Alexandre Oliveira Rodrigues - Hospital Universitário Onofre Lopes - Avenida Nilo Peçanha, 620 - CEP: 59012-300 - Petrópolis (RN), Brasil - E-mail: cassioalexandr3@live.com

Conflict of interest: nothing to declare.

INTRODUCTION

Adverse cutaneous reactions represent an important percentage of problems related to the use of drugs in hospital services and may predispose to serious complications, including death¹. Among the possible clinical manifestations, we highlight the alterations in skin color with a significant aesthetic and psychosocial impact², but without major damage to health.

Polymyxins represent a group of antibiotics for the treatment of gram-negative bacterial infections, however, due to their toxicity and the emergence of safer drugs, their use was practically discontinued in the 1970³. Although nephrotoxicity is characterized as the most relevant polymyxin B adverse reaction³, skin hyperpigmentation is possible in patients taking this drug^{2,4-9}. Some reports are described in the literature, but few information about follow-up and clinical management are observed. The process of skin hyperpigmentation involves biochemical and immunological mechanisms, mainly related to histaminergic receptors². Currently, in the face of the emergence of multiresistant bacteria and the scarcity of new antimicrobial research, it is increasingly used in hospital services³.

Therefore, considering the wide use of polymyxin B in hospital services, we report two cases of patients who developed skin hyperpigmentation during treatment with polymyxin B. This report was approved by the Research Ethics Committee of our institution (CAAE n°: 70957917.7.0000.5292) and the consent term was signed by those responsible.

CASE REPORT

Case 1: Male patient, 24 years old, 46 kg, brown skin (phototype IV), with a major complaint of continuous fever for 15 days before hospitalization, weight loss and jaundice, admitted to the Intensive Care Unit (ICU) after lowering the level of consciousness and diagnosed with Hodgkin's Lymphoma after clinical and immunohistopathological evaluation on the second day after admission in ICU.

Using cefepime and showing hemodynamic stability six days after admission, evolved to septic shock with the isolation of an *Acinetobacter baumannii* in tracheal secretion, being initiated intravenous treatment with polymyxin B (500,000 IU, 12/12 hours), Meropenem (2 g, 8/8 hours) and anidulafungin (an attack dose followed by 100 mg, 24/24 hours) to replace cefepime. On the 15th day after admission, the chemotherapy protocol ABVD (doxorubicin, bleomycin, vinblastine and dacarbazine) was administered, excluding doxorubicin due to hyperbilirubinemia. All medications used in the ICU are listed in Table 1.

Subsequently to the antimicrobial treatment for reversal of sepsis, on the seventh day of treatment, progressive hyperpigmentation of the head and neck was observed (Figure 1A). The apex of the pigmentation occurred around the 12th day, with a slight

Table 1: Drugs prescribed and used during ICU stay.

Patients	Hyperpigmentation	
	Before	After
Caso 1	Folic Acid	Amitriptyline
	Allopurinol	Amphotericin B LC
	Amikacin	Bleomycin
	Anidulafungin	Co-Trimoxazole
	Dexamethasone	Dacarbazine
	Fentanyl	Doxorubicin
	Fenoterol	Hydrocortisone
	Filgrastim	Teicoplanin
	Phytomenadione	Tigecycline
	Furosemide	Vinblastine
	Ganciclovir	
	Meropenem	
	Midazolam	
	Norepinephrine	
	Pantoprazole	
	Polymyxin B	
	Vancomycin	
Caso 2	Aspirin	
	Folic Acid	
	Amphotericin B LC	
	Amlodipine	
	Atenolol	
	Colchicine	
	Dexamethasone	
	Domperidone	
	Fluconazole	
	Heparin	
	Hydrocortisone	
	Linezolid	
	Meropenem	
	Pantoprazole	
	Polymyxin B	
	Vitamin B complex	

LC - Lipid Complex.

regression after the end of the antimicrobial treatment. After 10 days of suspension of polymyxin, a new episode of septic shock indicated resumption of therapy, but without aggravation of hyperpigmentation and evolution to death on the 48th day.

Case 2: Male patient, 45 years old, 78 kg, brown (phototype IV), complaining of a continuous febrile syndrome for 60 days and chronic kidney disease on hemodialysis, admitted to the ICU by lowering the level of consciousness and suspected myocardial infarction with ST-segment elevation (STEMI), being submitted to emergency coronary angiography without evidence of obstruction. Initial exams revealed endocarditis with vegetation in the right atrium and pericarditis.

On day four, it presented clinical stability under intravenous treatment with Meropenem (1 g, 12/12 hours) and Linezolid (600 mg, 12/12 hours), however, due to the persistence of the febrile illness, he started on the same day polymyxin B (750,000 IU, 12/12 hours) and amphotericin B lipid complex (200 mg, 24/24

hours). In addition to antimicrobial therapy, the patient used the medications as shown in Table 1.

The progressive darkening of the face started on the 12th day of admission, 8 days after therapy with polymyxin B and amphotericin B (Figure 1B). The antibacterial agents were administered for 14 days, but even after discontinuation and discharge from the ICU, there was no regression of hyperpigmentation. During the entire hospitalization period (four months), pigmentation persisted.

DISCUSSION

Hyperpigmentation caused by medications are reported in the literature and more recently the reaction has been described for polymyxin B⁴, affecting adults^{4,7,8} and pediatric/neonatal patients^{6,7,8,9}, whose percentage varying between 8-15% of the patients who presented the reaction with the use of the drug in two studies^{2,5}.

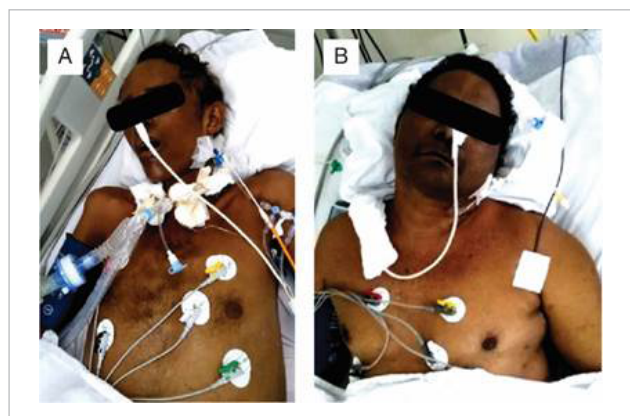


Figure 1: (A) Patient with skin hyperpigmentation after use of polymyxin B (case 1). It is noted increased facial pigmentation in relation to the thorax. (B) Patient with skin hyperpigmentation after use of polymyxin B (case 2). Regarding case #1, hyperpigmentation is more evident.

Men were most affected by this reaction^{2,4-9}, however, skin color seems to have more relevance in this process. In one study only 11.1% of patients with hyperpigmentation were Caucasian, who would be classified among the I-III¹⁰ phototypes on the Fitzpatrick scale, however, this same group represented 78.4% of the patients who did not present skin hyperpigmentation⁵, while most reports describe patients who would be classified from phototype IV (Table 2).

Polymyxin B potentiates the release of histamine in the organism¹¹ and causes morphological changes in human melanocytes from increased of tyrosinase activity, and in addition, histamine generates accumulation of intracellular cAMP and increases the activity of protein kinase A, stimulating melanogenesis in melanocytes^{2,12}. This whole process, therefore, results in increased production of melanin. According to Yoshida *et al.*¹², this process is mediated through H2 receptors which is also present in human melanocytes.

From an *in vivo* study, Yoshida *et al.*¹³ observed that the use of H2 antagonists, famotidine and ranitidine, suppressed melanogenesis in melanocytes. The same author had already obtained similar results in an *in vitro* study that allowed him to highlight a probability of the new therapeutic option for treating hyperpigmentation¹². However, only one study evidenced some action of this class of drugs in the skin¹⁴, the *in vivo* analysis of Yoshida *et al.*¹³ was performed with animals and part of the experiment was done with topical application of the drug. To our knowledge, there are no topical formulations of available H2 antagonists. Furthermore, we realized using proton pump inhibitors (PPIs) in all hyperpigmentation reports which described the use of drugs^{4,7}, which was not different from our report. Thus, we questioned whether the use of ranitidine to replace the PPIs could not have had any pharmacological action as discussed by Yoshida *et al.*¹². But there are still no studies that can prove it.

Hyperpigmentation was observed only in the head and neck region of both patients, where the largest number of melanocytes

Table 2: Characterization of reports regarding hyperpigmentation due to polymyxin B use.

Reference	Number of cases	Age (years)	Sex	Cutaneous phototype *	Polymyxin B dose	Chronic Disease
Kneuppel & Rahimian ⁴	2	46	M	IV	NR	NR
		80	M	IV	NR	CKD; DM
Zavascki <i>et al.</i> ⁷	1	55	M	NR	795,000 UI 48/48 hours**	CKD; SAH
Gothwal <i>et al.</i> ⁶	1	0	NR	NR	25,000-40,000 UI/kg/day	NR
Zavascki <i>et al.</i> ⁹	1	14	F	I-III	1,200,000 UI/day	NR
Lahiry <i>et al.</i> ⁸	1	65	M	IV-V	1,000,000 UI/day	COPD
		44	F	IV	1,500,000 UI/day	NR
Mattos <i>et al.</i> ²	3	50	M	IV	1,500,000 UI/day	NR
		53	M	IV	1,000,000 UI/day	NR
		24	M	IV	1,000,000 UI/day	NR
This study	2	45	M	IV	1,500,000 UI/day	CKD

COPD - Chronic Obstructive Pulmonary Disease; DM - Diabetes Mellitus; CKD - Chronic Kidney Disease; SAH - Systemic Arterial Hypertension; NR - Not Reported; * Fitzpatrick scale was used for classifying the skin phototype. Based on ethnic description of the patients, the classification was based on Torres *et al.*¹⁰
 ** Dose maintained for 10 days and adjusted to 420,000 IU every 12/12 hours.

in the body is concentrated², which may explain the fact that it has not been found in other areas of the body. In addition, the patients were in an environment with artificial and controlled light, without contact with external light.

Applying the Naranjo algorithm, polymyxin B was probably associated with hyperpigmentation in both cases (6 points) and after the application of the Fitzpatrick scale to evaluate the cutaneous phototype in the patients, they were classified as type IV that varied for the VI in the reaction. Regarding the use of drugs, in case 1 only amitriptyline, bleomycin and tigecycline have cases

of alterations in skin pigmentation, however, they were initiated when hyperpigmentation already existed. In case 2, we did not find cases of hyperpigmentation for all drugs used by the patient except for polymyxin B.

We conclude that hyperpigmentation was induced by polymyxin B. Men's and dark-skinned populations are the most affected. Finally, based on the mechanism of this reaction and the findings of Yoshida *et al.*^{12,13}, clinical studies that may evidence a probable pharmacological effect with the use of H2 antagonists are required.

REFERENCES

- Nayak S, Acharya B. Adverse cutaneous drug reaction. *Indian J Dermatol.* 2008;53(1):2-8.
- Mattos KPH, Cintra ML, Gouvêa IR, Ferreira LA, Velho PENF, Moriel P. Skin hyperpigmentation following intravenous polymyxin B treatment associated with melanocyte activation and inflammatory process. *J Clin Pharm Ther.* 2017;42(5):573-8. <http://dx.doi.org/10.1111/jcpt.12543>
- Mendes CAC, Burdman EA. Polimixinas: revisão com ênfase na sua nefrotoxicidade. *Rev Assoc Med Bras.* 2009;55(6):752-9.
- Knueppel RC, Rahimian J. Diffuse cutaneous hyperpigmentation due to tygeciline or polymyxyn B. *Clin Infect Dis.* 2007;45(1):136-8. <http://dx.doi.org/10.1086/518706>
- Mattos KPH, Lloret GR, Cintra ML, Gouvêa IR, Betoni RT, Mazzola PG, *et al.* Acquired skin hyperpigmentation following intravenous polymyxin B treatment: a cohort study. *Pigment Cell Melanoma Res.* 2016;29(3):388-90. <http://dx.doi.org/10.1111/pcmr.12468>
- Gothwal S, Meena K, Sharma SD. Polymyxyn B induced generalized hyperpigmentation in neonates. *Indian J Pediatr.* 2016;83(2):179-80. <http://dx.doi.org/10.1007/s12098-015-1798-z>
- Zavascki AP, Manfro RC, Maciel RA, Falci DR. Head and neck hyperpigmentation probably associated with polymyxin B therapy. *Ann Pharmacother.* 2015;49(10):1171-2. <http://dx.doi.org/10.1177/1060028015595643>
- Lahiry S, Choudhury S, Mukherjee A, Bhunya PK, Bala M. Polymyxin B-induced diffuse cutaneous hyperpigmentation. *J Clin Diagn Res.* 2017;11(2):FD01-2. <http://dx.doi.org/10.7860/JCDR/2017/24278.9213>
- Zavascki AP, Schuster LF, Duquia RP. Histopathological findings of pigmented lesion and recovery of natural skin colour in a patient with polymyxin B-associated diffuse hyperpigmentation. *Int J Antimicrob Agents.* 2016;48(5):579-80. <http://dx.doi.org/10.1016/j.ijantimicag.2016.08.010>
- Torres V, Herane MI, Costa A, Martin JP, Troielli P. Refinando as ideias sobre a pele "étnica". *An Bras Dermatol.* 2017;92(2):221-5.
- Bushby SRM, Green AF. The release of histamine by polymyxin B and polymyxin E. *Br J Pharmacol.* 1955;10(2):215-9.
- Yoshida M, Takahashi Y, Inoue S. Histamine induces melanogenesis and morphologic changes by protein kinase A activation via H2 receptors in human normal melanocytes. *J Invest Dermatol.* 2000;114(2):334-42. <http://dx.doi.org/10.1046/j.1523-1747.2000.00874.x>
- Yoshida M, Hirotsu S, Nakahara M, Uchiwa H, Yasushi T. Histamine is involved in ultravioleta B-induced pigmentation of guinea pig skin. *J Invest Dermatol.* 2002;118(2):255-60.
- Thomas RH, Browne PD, Kirby JD. The influence of ranitidine, alone and in combination with clemastine, on histamine-mediated cutaneous weal and flare reactions in human skin. *Br J Clin Pharmacol.* 1985;20(4):377-82.

