

Word count: Abstract: 243 Text: 2810
Number of refs.: 32
#Figures: 5 #Tables: 3

Treatment of combined aortic regurgitation and systemic hypertension: insights from an animal model study.

Running title: Hypertension and aortic valve regurgitation in rats

Jacques Couet*¹, Martin Gaudreau¹, Dominic Lachance, Eric Plante, Elise Roussel, Marie-Claude Drolet, Marie Arsenault.

Groupe de Recherche en Valvulopathies, Centre de Recherche Hôpital Laval, Institut de cardiologie de Québec, Université Laval, Québec, Canada

¹: These authors have contributed equally to this work.

*Corresponding author:

Jacques Couet PhD

Centre de Recherche Hôpital Laval,

2725, Chemin Sainte-Foy, Sainte-Foy, (Quebec), Canada, G1V 4G5

Phone: 1-418-656-4760; Fax: 1-418-656-4509; Email: jacques.couet@med.ulaval.ca

Canadian Institutes for Health Research (MOP-61818; CIHR), the Heart and Stroke Foundation of Quebec and the Quebec Heart Institute Foundation.

Abstract

Background: Hypertension (HT) and aortic valve regurgitation (AR) often coexist but the specific impacts of AR+HT on the left ventricle (LV) are still unknown. The best treatment strategy for this combination of diseases is also unclear.

Objectives: 1) To evaluate LV function, remodeling and 2) To assess the effects of angiotensin converting enzyme (ACE) inhibitor Captopril (C) in rats with AR±HT (spontaneously hypertensive rats (SHR)).

Methods: Animals were divided as follows: normotensive (NT) Wistar-Kyoto, NT+AR, hypertensive SHR (HT) and HT+AR receiving or not Captopril (150/mg/kg/day). Hearts were evaluated in vivo by echocardiography and harvested for tissue analysis after 6 months of evolution.

Results: HT+AR resulted in the worst LV hypertrophy (LVH), sub-endocardial fibrosis and lowest ejection fraction. Captopril normalized blood pressure in HT and HT+AR, but could not prevent LVH in HT+AR as well as it did in isolated HT. LV ejection fraction remained below normal in HT+AR+captopril compared to HT alone + captopril. Cardiomyocyte hypertrophy remained in HT+AR+captopril but was normalized in HT+captopril. Sub-endocardial fibrosis was reduced by captopril in HT+AR.

Conclusions: AR+HT resulted in the most severe myocardial abnormalities. High dose captopril was effective to slow LVH and preserve normal LV ejection fraction in isolated HT or AR but was less effective when both pathologies were combined. Pro-hypertrophic stimuli clearly remain active in HT+AR despite ACE inhibition. These

results suggest that a very aggressive medical treatment strategy may be required in order to optimize LV protection when AR and HT co-exist.

Introduction

Pressure overload results in concentric left ventricular hypertrophy (LVH) whereas volume overload is associated with eccentric LVH ¹. Current pharmacological treatments are very effective to prevent or even induce regression of concentric LVH associated with pressure overload seen in subjects with systemic hypertension ². Eccentric LVH associated with chronic left-sided valvular regurgitation can also be slowed by vasodilator therapy ^{3;4}. In a significant number of patients, a combination of both hypertension and left sided valvular regurgitation coexist ⁵⁻⁸. It was recently suggested that this combination may have a significant negative impact on LV hypertrophy and remodeling ⁹. The only treatment guidelines addressing the question currently recommend adjusting drug therapy in order to try to normalize systolic blood pressure as much as possible ¹⁰.

Considering this lack of data, the present study was designed to assess the cardiac response to AR and systemic hypertension over a 24 week period by inducing AR in a well-known hypertensive animal model: the spontaneously hypertensive rat (SHR). Considering the proven efficacy of ACE inhibition in both (isolated) diseases in rats, we wished to assess as a secondary objective the effects of ACE inhibition with captopril on LV hypertrophy, function and remodeling in our animals when AR and systemic hypertension coexist.

Methods

Animals: Sixty-six male Wistar-Kyoto (normotensive: NT) or Spontaneously Hypertensive Rats (SHR: HT) of 9-10 weeks of age (Harlan, Indianapolis, IN) were randomly divided in 6 groups (n=10-14/group) as follows: 1) control sham-operated normotensive Wistar-Kyoto (NT), 2) normotensive with AR (NT-AR), 3) untreated sham-operated SHR (HT), 4) untreated HT-AR, 5) HT treated with captopril (HT-C) and 6) HT-AR treated with captopril (HT-AR-C). Captopril (150/mg/kg/day) (Sigma, Oakville Ont. Canada) was given in drinking water¹¹⁻¹³. Drug treatment was started 2 weeks after the surgical procedure and continued for 24 weeks thereafter. This protocol was approved by the Universite Laval's animal protection committee.

Surgical induction of aortic regurgitation (AR): AR was induced and graded in the animals as previously published, under ketamine-xylazine anesthesia, by retrograde puncture of one or two aortic valve leaflets¹⁴⁻¹⁷. Only animals with severe AR by hemodynamic (acute decrease of diastolic pressure >30 mmHg) and echocardiographic criteria (by Color and pulsed-wave Doppler as previously published (see section below)¹⁴⁻¹⁷) were included in the protocol. All animals were evaluated daily for the appearance of signs or symptoms of heart failure. Blood pressure (BP) was monitored measured by the tail-cuff method.

Echocardiography: A complete two-dimensional, M-mode and Doppler echocardiogram was performed in ketamine/xylazine anesthetized animals as previously published at the following time points: preoperatively, immediately postoperatively, at 2 weeks (prior to

drug treatment) and before sacrifice (24 weeks of treatment) using an Philips Sonos 5500 equipped with a 12MHz probe ^{14;15;17}.

Tissue analysis

At the time of sacrifice, the anesthetized rats were exsanguinated. The hearts were quickly removed, freed from connective tissue and the left ventricle dissected and weighed. A piece of the LV was immediately put in RNAGuard (Ambion Inc., Austin, TX) solution and kept at -80°C until total RNA extraction. The remaining LV piece was minced, snap-frozen in liquid nitrogen and then kept at -80°C.

Semi-quantitative RT-PCR of mRNA accumulation:

Reverse transcription-polymerase chain reaction analysis of mRNA accumulation of the different angiotensin II receptors subtypes as collagen I, III, fibronectin and pro-metalloprotease II was performed essentially as previously described. ^{14;15}.

Cardiomyocyte cross-sectional area (CSA) and fibrosis: LV sections stained with Trichrome-Masson from at least 10 animals per group were analyzed as previously described ^{14;15}. Results are expressed as CSA mean \pm SEM in arbitrary units. As for myocardial total and sub-endocardial (inner third of the LV wall) fibrosis, a ratio expressed as percentage of blue staining (collagen fibers) over total staining (red and blue) was estimated for each section using an image analysis software (SigmaScan, Systat Software, Inc. Point Richmond, CA).

Immunohistology: Angiotensin II converting enzyme (ACE) immunolabeling of LV sections was made using a purified anti-ACE mouse monoclonal antibody (MAB3502; Chemicon International, Temecula, CA) at 4µg/ml. Analysis of the labeling was made by a blinded observer for the treatments on four LV sections per group, focusing on the sub-endocardial regions (inner third of the LV wall). Labeling was graded as negative (-), positive (+) or strongly positive (++) for each myocyte in the field. The percentage of each classification of myocyte labeling (-, + or ++) per total myocyte number per field was evaluated and expressed as the mean ± SEM.

Statistical analysis: Results are presented as mean ± SEM unless specified otherwise. One-way analysis of variance was performed to compare serial data. Statistical significance was set at a $p < 0.05$ using post-hoc Tukey's test. Data and statistical analysis were performed using GraphPad Prism version 3.02 for Windows, GraphPad Software, (San Diego CA).

Results

Part 1: Global effects of the combination of 24 weeks of AR and HT on the LV

Hemodynamics (Table 1)

All SHR rats (HT) became severely hypertensive. Severe AR resulted in a significant reduction of diastolic pressure and in an expected increase in pulse pressure in both normotensive (NT) and HT groups. Stroke volume and cardiac output were increased in all NT-AR and HT-AR animals as expected in animals with severe AR.

Left ventricular hypertrophy (LVH) and dilatation (Table 1 and 2)

HT rats developed severe concentric LVH as shown by 1) the increased measured LV weights, 2) smaller intra-cavitary dimensions, 3) thicker LV walls and 4) increased relative wall thickness. NT-AR developed a more eccentric LVH as shown by the increased LV weight, intra-cavitary dimensions and lower RWT. HT-AR developed the most severe LVH compared with isolated AR or HT (Table 1).

LV systolic function (Table 2)

Table 2 summarizes the effects of AR on ejection fraction (EF) at the end of the protocol. EF remained above 50% in all groups. AR caused a significant decrease in EF in both NT and HT animals. LV ejection fraction decreased the most from baseline in HT-AR (fig.3, panel F).

LV filling parameters (Table 3)

Filling parameters were evaluated on mitral inflow pulsed-Doppler recordings. Left atrial dilatation and increased lung weight (indexed for body weight) were considered indirect signs of elevated left filling pressures. E/A wave ratio remained unchanged in all groups. Mitral E wave slope was the steepest in HT-AR animals. NT-AR and HT-AR had increased left atrial dimensions and lung weight in comparison with NT and HT animals without AR.

Cardiomyocyte hypertrophy and LV sub-endocardial fibrosis (Fig 1)

Myocyte cross-sectional area (CSA) was significantly increased in the LV of HT and HT-AR rats compared to NT. AR alone in NT resulted in increased wall thickness (as shown in table 2) but had limited effects on CSA¹⁴. There was a trend towards higher CSA in HT-AR vs. HT alone this did not reach statistical significance. Total (middle panel, fig 1) but mostly sub-endocardial fibrosis (bottom panel, Fig. 1) was increased in the untreated HT-AR compared to HT alone.

Results Part 2: Effects of captopril treatment

Hemodynamics (Table 1):

Captopril treatment reduced significantly both systolic and diastolic pressures in HT and HT-AR rats compared to untreated groups ($p < 0,001$). Pulse pressure remained above normal in HT-AR treated with captopril despite normalization of systolic pressure.

Cardiac output remained increased despite captopril treatment in AR and HT-AR groups.

LV remodeling and function (Table 1, Figures 2 and 3):

Captopril treatment had significant effects on LVH in HT-AR as well as in HT rats. LV mass remained completely normal in HT animals treated by captopril. LVH was partially prevented by captopril treatment in HT-AR but LV mass remained above normal in this group. Captopril completely prevented the concentric remodeling in HT (normal RWT). RWT of treated and untreated HT-AR remained in a normal range. Captopril treatment slowed LV dilatation caused by the combination of AR and HT. Figure 2 shows typical examples of the macroscopic appearance of the LV in each group.

LV ejection fraction was lower in NT-AR and HT-AR groups compared to NT and HT as shown in Figure 3 and the relative decrease in ejection fraction was the most severe in HT-AR. This could not be prevented by captopril.

The increase in indexed lung weight observed in HT-AR rats was normalized by Captopril. There was however no other significant effect of captopril on any of the measured Doppler diastolic parameters nor on left atrial size (table 3).

Myocyte CSA and sub-endocardial fibrosis (Figures 1, 4 and 5)

Captopril treatment significantly reduced myocyte CSA in the HT and HT-AR groups (Fig. 1). Myocyte CSA tended to remain higher than normal in the HT-AR treated with captopril but this result did not reach statistical significance.

In the animals not receiving captopril, the amount of sub-endocardial fibrosis in HT was higher than in NT. Captopril treatment had no significant effect on sub-endocardial

fibrosis in the HT group although a trend for lower levels seemed apparent. Captopril treatment reduced significantly the amount of sub-endocardial fibrosis in HT-AR rats but did not normalize this parameter when compared to controls.

Collagen I, Collagen III and fibronectin mRNA levels were significantly higher in the HT group and their levels were reduced by captopril treatment (Fig. 4). Captopril reduced Collagen 3 and fibronectin expression in HT-AR but not the mRNA levels of Collagen I. On the other hand, LV pro-MMP2 mRNA levels were lower in HT rats compared to NT rats.

Tissue renin-angiotensin system:

As illustrated in Figure 5, LV ACE labeling in HT was increased compared to normal animals but was patchy (i.e. some myocytes labeled more than others) while in HT-AR animals the labeling was uniformly strong. Captopril treatment reduced ACE labeling in HT-AR rats. We did not observe any significant changes in the LV enzymatic ACE activity (not shown) as well as in the expression of angiotensin II receptors AT1a, AT1b and AT2 mRNAs in any of the HT groups (\pm AR, \pm C, results not shown). However, mRNA levels of the AT1a receptor were 45% lower in HT rats compared to NT rats ($p < 0.05$).

Discussion

This study shows that a combination of AR and hypertension results in severe macroscopic and myocardial tissue abnormalities. While ACE inhibition with high doses of captopril was very effective to prevent LVH and preserve normal ejection fraction in hypertensive animals, it was much less effective in the animals with a combination of AR and hypertension despite a complete normalization of their systolic blood pressure.

Captopril was previously proven by others to be effective to prevent and even induce regression of LV hypertrophy and remodeling very effectively in rats with hypertension (SHR) alone ^{2;12-14}. Our team has also recently reported that a dose of 75 mg/kg/day effectively slowed LV dilatation and hypertrophy and preserved LV ejection fraction in animals with AR ¹⁴. Therefore, ACE inhibition has been proven effective for the treatment of AR or hypertension in rats when those pathologies occur separately. ACE inhibitors have also been proven effective in humans with hypertension or aortic valve regurgitation ^{3;10}. In the present study, high doses of captopril (150 mg/kg/day) given to animals with a combination of severe AR and hypertension slowed LV hypertrophy and dilatation but was much less effective in maintaining normal ejection fraction than in animals with isolated AR or HT.

The normalization of systolic BP and the decrease in LVH in the HT-AR group treated with captopril is probably attributable to peripheral and tissue RAS inhibition which resulted in afterload reduction. In animals with HT-AR, strong tissue ACE activation was present. However, hypertrophic stimuli clearly remained active despite ACE inhibition in the HT-AR rats. The mechanical workload induced by volume overload remained

untouched by captopril as shown by the increased stroke volume and cardiac output. Despite ACE inhibition, these ventricles remained exposed to a diastolic mechanical stretch which probably kept acting as a pro-hypertrophic stimulus¹⁸⁻²¹. However, in a previous study in AR rats treated with captopril, we obtained better results on LV function even though the animals remained in a high output state and volume overload. The precise reason for the decreased effectiveness of ACE inhibition when AR and HT are combined remains to be found. Aldosterone escape phenomenon has been reported despite treatment with captopril²². It is possible that such a phenomenon may have occurred in the rats with a combination of hypertension and severe aortic regurgitation and contributed to the decreased effectiveness of captopril against left ventricular hypertrophy and fibrosis in this group. This hypothesis was not tested in our protocol but deserves further investigation.

ECM remodeling was also an important component in our HT-AR rats that developed severe sub-endocardial fibrosis. Although captopril seemed to partly prevent this increase in fibrosis in AR rats, the ECM was still abnormally rearranged^{23;24}. Captopril treatment did not normalize the expression of collagen I in HT-AR animals whereas it had significant effects on collagen III and fibronectin. The reason for this remains unclear but despite this lack of effect on collagen I mRNA expression, captopril did have a significant effect on decreasing total fibrosis in HT-AR animals. This decrease in total fibrosis despite a lack of effect on collagen I mRNA expression could suggest an increased degradation of collagen I. However, pro-MMP2 mRNA expression was generally lower in HT rats suggesting at least, an abnormal degradation and/or turnover of the ECM. Borer et al. have reported in 2002 that fibronectin seems to play a more important role in AR-associated fibrosis than collagen I²⁵. Regulating mechanisms other

than renin-angiotensin system are probably involved in the production of collagen I in LVs submitted to severe overloading.

Experimental studies of models of combined pressure and volume overload of the left ventricle are rare. Most previous publications focused on overt heart failure by combining hypertension and arterio-venous fistulae or aortic banding and AR. These models quickly induce severe LV systolic dysfunction²⁶⁻³⁰ in the animals and are not relevant to the current study. Moreover, in those studies little tissue analysis was performed to assess the effects of combined overloads on the cardiomyocytes and on the ECM. Pharmacological treatment, when given, was mostly limited to a few weeks duration and therefore the long-term effects of treatment have not been assessed²⁸.

While LV remodeling and hypertrophy associated with isolated hypertension or isolated aortic valve regurgitation have been extensively studied, the management of patients with the combination of both LV overloads is not well established¹⁰. Coexistence of hypertension and valvular regurgitation is not an uncommon situation. Based on previous publications, AR can be found in 6-8% of hypertensive patients and roughly half of those patients have at least moderate aortic valve regurgitation. There is very little published data on this subgroup of hypertensive patients. Recent data on a subgroup of patients with hypertension and left sided valvular regurgitation from the LIFE study were published⁹. Compared to subjects with similar levels of hypertension, patients with left sided valvular regurgitation had significantly more macroscopic LV structural and functional changes. Even mild regurgitation had significant impacts in this cohort namely larger LV internal dimensions and higher indexed LV mass⁹. Similar

findings were also described in a cohort of patients from the HyperGEN study ³¹. The results from these two studies suggest that patients with a combination of hypertension and valvular regurgitation may need to be treated very aggressively. There are no specific recommendations for the pharmacologic management of patients with mixed pressure and volume overloads^{3;4;10}. The latest valvular heart disease treatment guidelines only suggest that hypertensive patients with significant aortic valve regurgitation should be treated with the aim of normalizing their blood pressure as much as possible ^{3;4;10;32}.

Study limitations:

Our findings definitely need to be assessed in human clinical trials before any hard conclusions can be drawn. The effects of milder degrees of AR in combination with hypertension remain to be explored as well as the potential effects of other types of medications, alone or in combination. The potential of reversibility of LV hypertrophy and dilatation was not evaluated in our study. Longer follow-up studies as well as morbidity-mortality also need to be performed.

Conclusions:

In our model, the combination of hypertension and AR had important impacts not only on LV function and remodeling but also on myocyte hypertrophy and the ECM which were only partially prevented by ACE inhibition. In this animal model of AR+ HT, reduction of afterload and ACE inhibition was not enough to protect the LV. Normalization of systolic blood pressure was not sufficient to protect the LV of animals with combined overloads. Being well aware of the potential pitfalls of animal models, we do not suggest that the

results of this study be transposed to humans. However, our results bring important insights on the response of the LV to a combination of AR+HT and raise important questions on the optimization of the medical treatment of subjects with this combination of diseases.

References

1. Carabello BA, Zile MR, Tanaka R, Cooper G. Left ventricular hypertrophy due to volume overload versus pressure overload. *Am J Physiol* 1992; 263:H1137-H1144.
2. Pfeffer JM, Pfeffer MA. Angiotensin converting enzyme inhibition and ventricular remodeling in heart failure. *Am J Med* 1988; 84:37-44.
3. Gaasch WH, Sundaram M, Meyer TE. Managing asymptomatic patients with chronic aortic regurgitation. *Chest* 1997; 111:1702-9.
4. Levine HJ, Gaasch WH. Vasoactive drugs in chronic regurgitant lesions of the mitral and aortic valves. *J Am Coll Cardiol* 1996; 28:1083-91.
5. Palmieri V, Bella JN, Arnett DK, Roman MJ, Oberman A, Kitzman DW, Hopkins PN, Paranicas M, Rao DC, Devereux RB. Aortic root dilatation at sinuses of valsalva and aortic regurgitation in hypertensive and normotensive subjects: The Hypertension Genetic Epidemiology Network Study. *Hypertension* 2001; 37:1229-35.
6. Kim M, Roman MJ, Cavallini MC, Schwartz JE, Pickering TG, Devereux RB. Effect of hypertension on aortic root size and prevalence of aortic regurgitation. *Hypertension* 1996; 28:47-52.
7. Lebowitz NE, Bella JN, Roman MJ, Liu JE, Fishman DP, Paranicas M, Lee ET, Fabsitz RR, Welty TK, Howard BV, Devereux RB. Prevalence and correlates of

- aortic regurgitation in American Indians: the Strong Heart Study. *J Am Coll Cardiol* 2000; 36:461-7.
8. Lonati L, Cuspidi C, Sampieri L, Boselli L, Bocciolone M, Leonetti G, Zanchetti A. Prevalence of physiological valvular regurgitation in hypertensive patients: echocardiographic and color Doppler study. *Cardiology* 1992; 81:365-70.
 9. Kontos J, Papademetriou V, Wachtell K, Palmieri V, Liu JE, Gerds E, Boman K, Nieminen MS, Dahlof B, Devereux RB. Impact of valvular regurgitation on left ventricular geometry and function in hypertensive patients with left ventricular hypertrophy: the LIFE study. *J Hum Hypertens* 2004; 18:1-6.
 10. Bonow RO, Carabello B, de Leon AC, Edmunds LH, Jr., Fedderly BJ, Freed MD, Gaasch WH, McKay CR, Nishimura RA, O'Gara PT, O'Rourke RA, Rahimtoola SH, Ritchie JL, Cheitlin MD, Eagle KA, Gardner TJ, Garson A, Jr., Gibbons RJ, Russell RO, Ryan TJ, Smith SC, Jr. ACC/AHA Guidelines for the Management of Patients With Valvular Heart Disease. Executive Summary. A report of the American College of Cardiology/American Heart Association Task Force on Practice Guidelines (Committee on Management of Patients With Valvular Heart Disease). *J Heart Valve Dis* 1998; 7:672-707.
 11. Pfeffer JM, Pfeffer MA, Fletcher PJ, Braunwald E. Ventricular performance in rats with myocardial infarction and failure. *Am J Med* 1984; 76:99-103.

12. Pfeffer JM, Pfeffer MA, Mirsky I, Braunwald E. Prevention of the development of heart failure and the regression of cardiac hypertrophy by captopril in the spontaneously hypertensive rat. *Eur Heart J* 1983; 4 Suppl A:143-8.
13. Pfeffer JM, Pfeffer MA, Mirsky I, Braunwald E. Regression of left ventricular hypertrophy and prevention of left ventricular dysfunction by captopril in the spontaneously hypertensive rat. *Proc Natl Acad Sci U S A* 1982; 79:3310-4.
14. Plante E, Gaudreau M, Lachance D, Drolet MC, Roussel E, Gauthier C, Lapointe E, Arsenault M, Couet J. Angiotensin-converting enzyme inhibitor captopril prevents volume overload cardiomyopathy in experimental chronic aortic valve regurgitation. *Can J Physiol Pharmacol* 2004; 82:191-9.
15. Plante E, Lachance D, Gaudreau M, Drolet MC, Roussel E, Arsenault M, Couet J. Effectiveness of beta-blockade in experimental chronic aortic regurgitation. *Circulation* 2004; 110:1477-83.
16. Arsenault M, Plante E, Drolet MC, Couet J. Experimental aortic regurgitation in rats under echocardiographic guidance. *J Heart Valve Dis* 2002; 11:128-34.
17. Plante E, Couet J, Gaudreau M, Dumas MP, Drolet MC, Arsenault M. Left ventricular response to sustained volume overload from chronic aortic valve regurgitation in rats. *J Card Fail* 2003; 9:128-40.
18. Malhotra R, Sadoshima J, Brosius FC, III, Izumo S. Mechanical stretch and angiotensin II differentially upregulate the renin-angiotensin system in cardiac myocytes In vitro. *Circ Res* 1999; 85:137-46.

19. Pan J, Fukuda K, Saito M, Matsuzaki J, Kodama H, Sano M, Takahashi T, Kato T, Ogawa S. Mechanical stretch activates the JAK/STAT pathway in rat cardiomyocytes. *Circ Res* 1999; 84:1127-36.
20. Shyu KG, Chen JJ, Shih NL, Chang H, Wang DL, Lien WP, Liew CC. Angiotensinogen gene expression is induced by cyclical mechanical stretch in cultured rat cardiomyocytes. *Biochem Biophys Res Commun* 1995; 211:241-8.
21. van Wamel AJ, Ruwhof C, van der Valk-Kokshoom LE, Schrier PI, van der LA. The role of angiotensin II, endothelin-1 and transforming growth factor-beta as autocrine/paracrine mediators of stretch-induced cardiomyocyte hypertrophy. *Mol Cell Biochem* 2001; 218:113-24.
22. Staessen J, Lijnen P, Fagard R, Verschueren LJ, Amery I. Rise in plasma concentration of aldosterone during long term angiotensin II suppression. *J Endocrinol* 1981; 91:457-65
23. Rossi MA, Peres LC. Effect of captopril on the prevention and regression of myocardial cell hypertrophy and interstitial fibrosis in pressure overload cardiac hypertrophy. *Am Heart J* 1992; 124:700-9.
24. Tan LB, Brilla C, Weber KT. Prevention of structural changes in the heart in hypertension by angiotensin converting enzyme inhibition. *J Hypertens Suppl* 1992; 10:S31-S34.

25. Borer JS, Truter S, Herrold EM, Falcone DJ, Pena M, Carter JN, Dumlao TF, Lee JA, Supino PG. Myocardial fibrosis in chronic aortic regurgitation: molecular and cellular responses to volume overload. *Circulation* 2002; 105:1837-42.
26. Leenen FH, Yuan B. Mortality after coronary artery occlusion in different models of cardiac hypertrophy in rats. *Hypertension* 2001; 37:209-15.
27. Friberg P. Diastolic characteristics and cardiac energetics of isolated hearts exposed to volume and pressure overload. *Cardiovasc Res* 1988; 22:329-39.
28. Arnal JF, Philippe M, Laboulandine I, Michel JB. Effect of perindopril in rat cardiac volume overload. *Am Heart J* 1993; 126:776-82.
29. Rohde E, Karasek E, Buske R. Experiments with volume overload in SHR/Frid and WKY/Frid. *Z Versuchstierkd* 1990; 33:128-32.
30. Cicogna AC, Matsubara BB, Matsubara LS, Okoshi K, Gut AL, Padovani CR, Meyer MM, Okoshi MP. Volume overload influence on hypertrophied myocardium function. *Jpn Heart J* 2002; 43:689-95.
31. Palmieri V, Bella JN, Arnett DK, Oberman A, Kitzman DW, Hopkins PN, Rao DC, Roman MJ, Devereux RB. Associations of aortic and mitral regurgitation with body composition and myocardial energy expenditure in adults with hypertension: the Hypertension Genetic Epidemiology Network study. *Am Heart J* 2003; 145:1071-7.
32. Bonow RO. Aortic Regurgitation. *Curr Treat Options Cardiovasc Med* 2000; 2:125-32.

Figure legends:

Figure 1: Left: LV myocyte cross-sectional area (CSA) (top), LV total fibrosis (middle) and sub-endocardial fibrosis (below). Results are expressed in arbitrary units (CSA) or % fibrosis as mean \pm SEM (n=10 animals per group). NT: normotensive, HT: hypertensive, AR: aortic regurgitation, UT: untreated and C: treated with captopril, Sham: sham-operated animals. *: p<0.05 and **: p<0.01 vs. UT sham HT rats and #: p<0.05 and ##: p<0.01 vs. corresponding untreated (UT) group, respectively. Right: Typical views of Trichrome-Masson stained sub-endocardial mid ventricular LV sections. In blue: collagen fibers whereas cardiomyocytes appear in red (magnification 200X).

Figure 2: Typical macroscopic examples of left ventricular hypertrophy and remodeling in specific groups. Representative mid-ventricular sections of the LV stained with Trichrome-Masson are shown. HT: hypertensive; AR: aortic regurgitation; C: captopril treatment.

Figure 3: Effect of captopril (C) treatment on LV dimensions remodeling and systolic function as assessed by echocardiography in SHR hypertensive (HT) animals having (closed bars) or not (open bars) chronic AR. Bar graphs represent variation (Δ) in LV diameters, wall thickness, LV end-diastolic volume and LV ejection fraction from the onset of captopril treatment until the end of protocol. EDD: end-diastolic diameter; ESD: end-systolic diameter; SW: septal wall; PW: posterior wall; EDV: end-diastolic volume; EF: ejection fraction. C: treated with captopril; UT: untreated rats. Results are

expressed mean \pm SEM (n=10-14/group). *: p<0.05, **: p<0.01 and ***: p<0.001 vs. corresponding UT group.

Figure 4: Effect of captopril (C) treatment on the expression of components of the extracellular matrix by semi-quantitative RT-PCR. Collagen type 1 (Col1) (A), collagen Type III (Col3) (B), fibronectin (C) and pro-metalloprotease II (MMP2). Results are expressed mean \pm SEM (n=10/group). *: p<0.05 and **: p<0.01 vs. corresponding group of untreated rats (UT).

Figure 5: Increased LV ACE expression HT-AR animals. Mid-ventricular sections were labeled using an anti-ACE antibody and analysis was made as described in the Methods section. ACE-positive cells are displayed in reddish-brown. Negative control: without primary antibody. Sub-endocardial portions of the LV are illustrated. *:p<0.05 vs. corresponding untreated group and #:p<0.05 vs. NT group.

Table 1: Hemodynamics and LV hypertrophy/remodeling.

Parameters	NT		HT			
	Sham	AR	Sham		AR	
			Untreated	Captopril	Untreated	Captopril
Systolic BP, mmHg	141 ± 11.7	136 ± 7.5	190 ± 8.5	122 ± 6.0**	163 ± 4.8*	133 ± 5.2**#
Diastolic BP, mmHg	90 ± 9.2	53 ± 3.5**	108 ± 5.3	70 ± 6.5**	64 ± 5.7**	57 ± 3.2**
PP, mmHg	50 ± 4.7	83 ± 7.8**	81 ± 5.0	52 ± 5.0**	99 ± 3.8*	77 ± 5.7#
HR, min ⁻¹	215 ± 6,0	225 ± 4,0	218 ± 7.0	210 ± 10.0	230 ± 4.9	234 ± 6.8
CO, ml/min	46.0 ± 2.08	97.1 ± 3.97**	63.4 ± 1.60	46.3 ± 2.92**	96.6 ± 5.42**	104.4 ± 4.48**
RWT	0.37 ± 0.006	0.31 ± 0.010**	0.56 ± 0.009	0.36 ± 0.008**	0.39 ± 0.007**	0.36 ± 0.008**
LV weight index, mg/g	1.9 ± 0.03	2.9 ± 0.12	2.7 ± 0.06	1.5 ± 0.04	3.7 ± 0.08	2.6 ± 0.08

BP: blood pressure; PP: pulse pressure; HR: heart rate; CO: cardiac output; RWT: relative wall thickness (sum of wall posterior and septal wall thickness / LV diastolic diameter); LV: left ventricle; NT: normotensive animals, HT: hypertensive animals (SHR); Sham: sham-operated rats and AR: aortic regurgitation. LV weight obtained at sacrifice is indexed for the animal's body weight.

Values are means ± SEM (n=10-14). *: p<0.05 and **: p<0.01 vs. corresponding Sham group. #: p<0.05 vs. Untreated corresponding group.

Table 2. Echocardiographical findings

Parameters	NT		HT	
	Sham	AR	Sham	AR
EDD, mm	8.7 ± 0.13	11.4 ± 0.29**	7.3 ± 0.18##	10.7 ± 0.13
ΔEDD, mm	0.31 ± 0.211	1.96 ± 0.391**	0.04 ± 0.217	3.92 ± 0.231**
ESD, mm	4.7 ± 0.09	7.4 ± 0.38**	3.2 ± 0.13##	6.7 ± 0.16**
ΔESD, mm	-0.20 ± 0.238	2.08 ± 0.436**	0.07 ± 0.136	3.71 ± 0.221**
SW, mm	1.6 ± 0.04	1.8 ± 0.04	2.0 ± 0.03#	2.0 ± 0.04
PW, mm	1.6 ± 0.03	1.8 ± 0.04	2.2 ± 0.03##	2.0 ± 0.03
EF, %	71 ± 1.5	58 ± 2.4**	80 ± 1.4##	60 ± 1.4**

EDD: end-diastolic diameter; ESD: end-systolic diameter; SW: septal wall thickness; PW: posterior wall thickness; EF: ejection fraction; NT: normotensive; HT: hypertensive (SHR); Sham: sham-operated rats and AR: aortic regurgitation. Δ is for the variation of the parameter through the duration of the protocol. Values are means ± SEM (n=10-14). **: p<0.01 vs. corresponding sham group, ##: p<0.01 vs. NT-Sham.

Table 3. Atrial dimensions, lung weights and Doppler LV filling parameters

Parameters	NT		HT			
	Sham	AR	Sham		AR	
			Untreated	Captopril	Untreated	Captopril
Left atrial diameter, cm	0.39 ± 0.008	0.48 ± 0.031*	0.40 ± 0.012	0.40 ± 0.011	0.46 ± 0.008*	0.44 ± 0.016
Ind. Lung weight, mg/g	3.7 ± 0.20	4.3 ± 0.25*	3.3 ± 0.10	3.5 ± 0.08	3.9 ± 0.14*	3.3 ± 0.11
E/A wave ratio	2.2 ± 0.05	2.4 ± 0.22	2.4 ± 0.11	2.2 ± 0.06	2.3 ± 0.14	2.4 ± 0.22
E wave downslope	1291 ± 45.2	1351 ± 111.4	1406 ± 43.9	1334 ± 50.6	1569 ± 90.6*	1459 ± 70.4

NT: normotensive HT: hypertensive (SHR) Sham: sham-operated rats AR: aortic regurgitation. Ind.: indexed values for animal body weight. E: E wave maximal velocity of pulsed Doppler mitral flow A: A wave maximal velocity of pulsed Doppler mitral flow. Values are means ± SEM (n=10-14). *: p<0.05 vs. corresponding sham group.

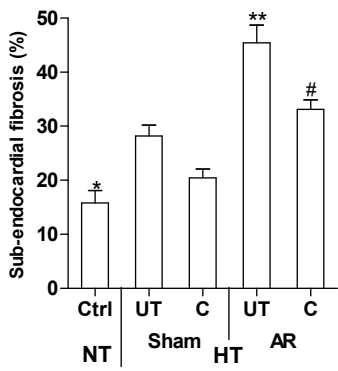
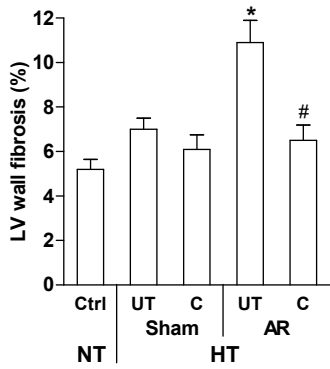
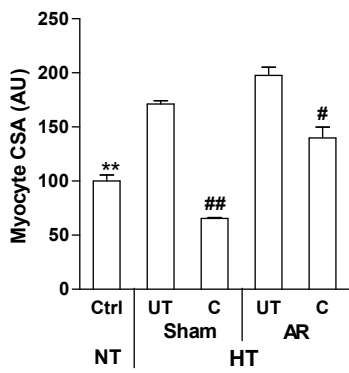


Fig. 1 left
Couet et al.

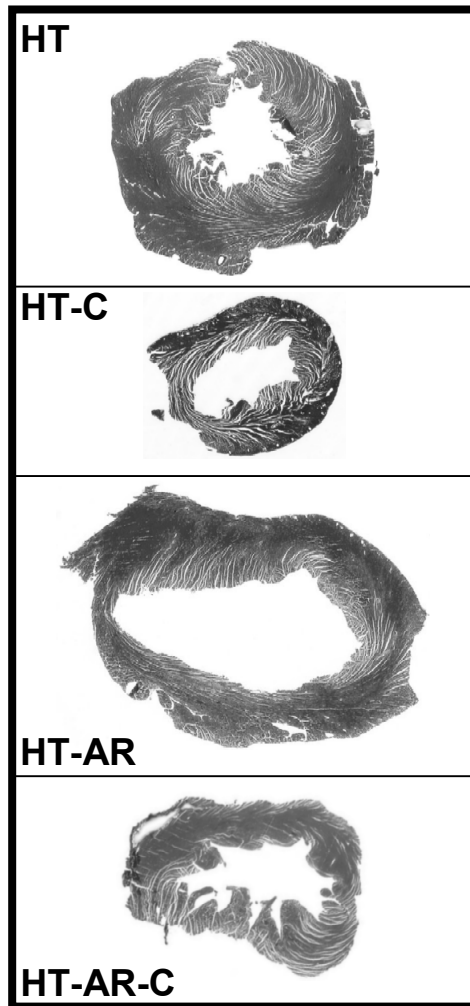


Fig. 2
Couet et al.

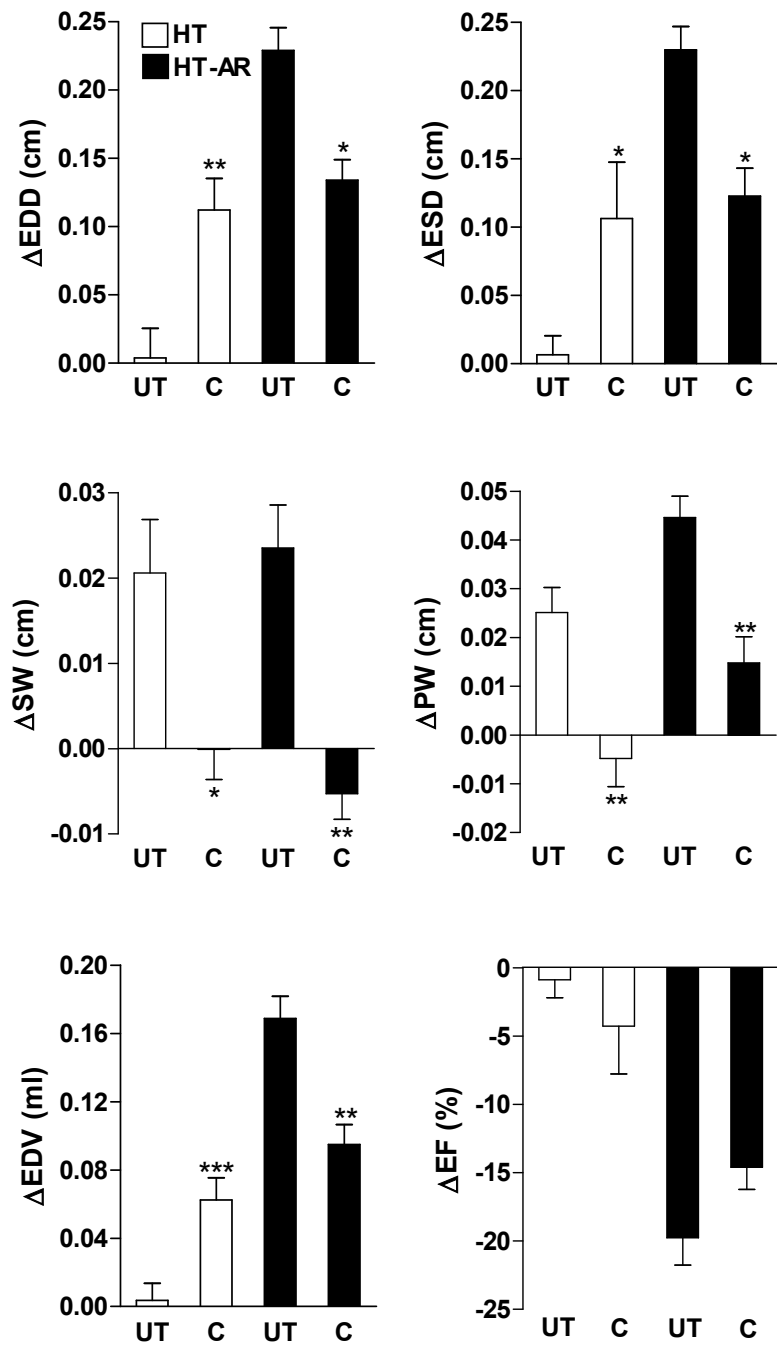


Fig. 3
Couet et al.

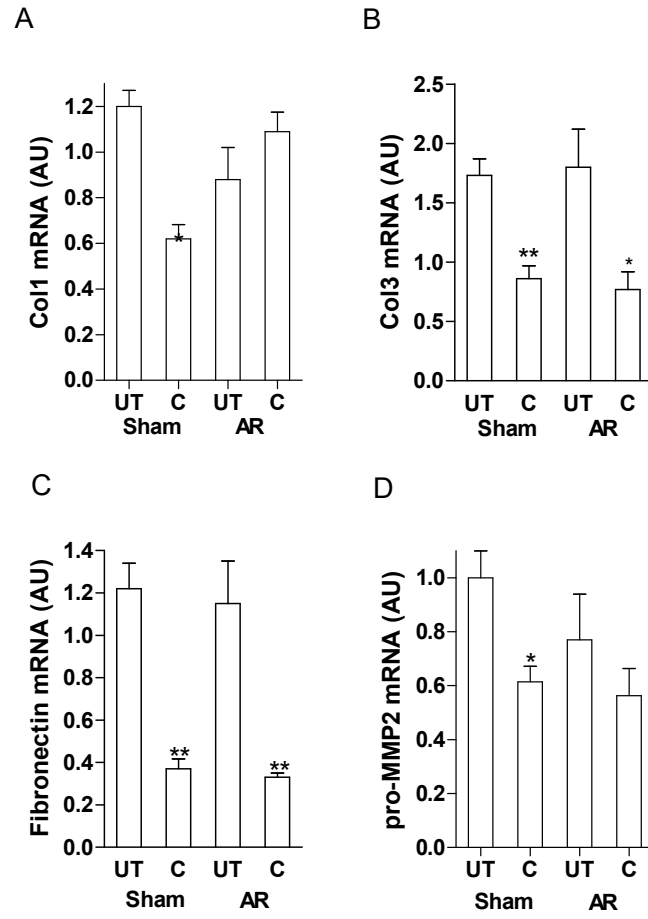


Fig. 4
Couet et al.