



Thomas Jefferson University  
**Jefferson Digital Commons**

Department of Pathology, Anatomy, and Cell  
Biology Faculty Papers

Department of Pathology, Anatomy, and Cell  
Biology

4-1-2021

## Characterization and Clinical Significance of EIF1AX Mutations and Co-Mutations in Cytologically Indeterminate Thyroid Nodules: A 5-Year Retrospective Analysis.

Stacey Gargano


Nitika Badjatia

Yanina Nikolaus

Stephen C Peiper

Zi-Xuan Wang, PhD

Follow this and additional works at: <https://jdc.jefferson.edu/pacbfp>

 Part of the [Medical Anatomy Commons](#), [Medical Cell Biology Commons](#), and the [Medical Pathology Commons](#)

### [Let us know how access to this document benefits you](#)

This Article is brought to you for free and open access by the Jefferson Digital Commons. The Jefferson Digital Commons is a service of Thomas Jefferson University's [Center for Teaching and Learning \(CTL\)](#). The Commons is a showcase for Jefferson books and journals, peer-reviewed scholarly publications, unique historical collections from the University archives, and teaching tools. The Jefferson Digital Commons allows researchers and interested readers anywhere in the world to learn about and keep up to date with Jefferson scholarship. This article has been accepted for inclusion in Department of Pathology, Anatomy, and Cell Biology Faculty Papers by an authorized administrator of the Jefferson Digital Commons. For more information, please contact: [JeffersonDigitalCommons@jefferson.edu](mailto:JeffersonDigitalCommons@jefferson.edu).

## Characterization and Clinical Significance of *EIF1AX* Mutations and Co-Mutations in Cytologically Indeterminate Thyroid Nodules: A 5-Year Retrospective Analysis

Stacey M. Gargano, Nitika Badjatia, Yanina Nikolaus, Stephen C. Peiper, Zi-Xuan Wang

Department of Pathology, Anatomy and Cell Biology, Thomas Jefferson University Hospital, Philadelphia, PA, USA

**Correspondence:** Stacey.Gargano@jefferson.edu; Tel.: + 1 215 955 4404; Fax.: + 1 215 923 1969

**Received:** 3 February 2021; **Accepted:** 8 April 2021

### Abstract

**Objective.** Mutations in the *EIF1AX* gene have been recently detected in a small percentage of benign and malignant thyroid lesions. We sought to investigate the prevalence and clinical significance of *EIF1AX* mutations and co-mutations in cytologically indeterminate thyroid nodules at our institution. **Materials and Methods.** A 5-year retrospective analysis was performed on thyroid nodules with a cytologic diagnosis of Bethesda category III or IV, which had undergone testing by our in-house next generation sequencing panel. Surgically resected nodules with *EIF1AX* mutations were identified, and mutation type and presence of co-mutations were correlated with histopathologic diagnosis. **Results.** 41/904 (4.5%) cases overall and 26/229 (11.4%) surgically resected nodules harbored an *EIF1AX* mutation. The most common histologic diagnoses were follicular thyroid carcinoma and follicular variant of papillary thyroid carcinoma. 11/26 (42.3%) of nodules had isolated *EIF1AX* mutation. Co-mutations were found in *RAS* (12/26; 46.2%), *TERT* (5/26; 19.2%) and *TP53* (2/26; 7.7%). *EIF1AX* mutation alone conferred a 36.4% risk of malignancy (ROM) and 54.5% ROM or noninvasive follicular thyroid neoplasm with papillary-like nuclear features (NIFTP), while the ROM was significantly higher in nodules with concurrent *RAS* (71.4%), *TERT*, *TP53* and *RAS+TERT* (100%) mutations. **Conclusion.** *EIF1AX* mutations occur in benign and malignant follicular thyroid neoplasms. In our cohort, the majority of mutations occurred at the splice acceptor site between exons 5 and 6. Importantly, the coexistence of *EIF1AX* mutations with other driver pathogenic mutations in *RAS*, *TERT* and *TP53* conferred a 100% ROM or NIFTP, indicating that such nodules require surgical removal.

**Key Words:** *EIF1AX* ■ Thyroid Nodule ■ Cytopathology ■ Next-Generation Sequencing.

### Introduction

Up to 30% of biopsied thyroid nodules are classified as either “atypia of undetermined significance (AUS)/follicular lesion of undetermined significance (FLUS)” or “follicular neoplasm (FN)/suspicious for follicular neoplasm (SFN)”, Categories III and IV respectively in The Bethesda System for Reporting Thyroid Cytopathology (TBSRTC) (1). Because these diagnoses are not straightforward benign or malignant, and the reported risks of malignancy are highly variable for these categories, clinicians often struggle with the decision of whether or not to recommend surgical removal of these indeterminate nodules. Molecular analysis, via multi-gene sequencing assays and gene expres-

sion classifiers, has emerged as an important supplemental tool for evaluating thyroid nodules (1, 2). At our institution, thyroid fine needle aspiration (FNA) specimens with an indeterminate cytologic diagnosis are routinely tested via an in-house next generation sequencing (NGS) panel, in order to provide clinicians with more information that may help with risk stratification and guide clinical management.

The most commonly known mutated genes associated with thyroid malignancies are *BRAF* and *RAS*. The majority of *BRAF* mutations are found in classical papillary thyroid carcinoma (PTC), while *RAS* mutations are seen in follicular variant of papillary thyroid carcinoma (FVPTC) and

other malignant and benign follicular-patterned thyroid lesions (3). More recently, mutations in the *EIF1AX* (Eukaryotic translation initiation factor 1A, X-chromosomal) gene have been detected in a small percentage of various types of thyroid cancer as well as benign thyroid nodules. The likelihood of malignancy in an *EIF1AX*-mutated thyroid nodule is thought to correlate with the presence or absence of co-existing mutations and with the position of the mutations within *EIF1AX* (4).

We sought to investigate the prevalence and clinical significance of *EIF1AX* mutations and co-mutations by examining histologic outcomes of a large cohort of cytologically indeterminate thyroid nodules that underwent molecular testing and subsequent surgical resection.

## Materials and Methods

### Case Selection and Histopathologic Correlation

A database search was performed to identify all thyroid nodules with a cytologic diagnosis of Bethesda category III or IV, which had undergone testing by our in-house NGS panel over a 5-year period. Samples with *EIF1AX* mutations were identified, and the electronic medical record was searched to determine which nodules had undergone surgical resection. *EIF1AX* mutation type and presence of co-mutations were correlated with final histopathologic diagnosis.

### Molecular Specimen Information

At the time of the FNA procedure, a separate needle pass was collected in a vial containing methanol/acetic acid (3:1 ratio). Of the 987 clinical FNA specimens, 904 (91.6%) passed sample quality control and obtained molecular results.

### Molecular Analysis

Mutations in *EIF1AX* were identified by NGS with a custom designed Thyroid cancer panel using Illumina's TruSeq Custom Amplicon version 1.5 reagents as previously described (5) or CTL Vari-

antPlex Assay for Illumina Platform (ArcherDx) following the manufacturer's protocol. Besides *EIF1AX* both TruSeq and Archer panels contained primers to amplify targeted regions of interest covering hotspots from additional thyroid cancer-related genes such as *BRAF*, *GNAS*, *HRAS*, *NRAS*, *PIK3CA*, *PTEN*, *RET*, *TERT**pro*, *TP53* and *TSHR*. Libraries were sequenced on the Illumina MiSeq or NextSeq 500 instrument with paired end 150-bp sequencing. Data analysis was performed as previously described (5) for all TruSeq libraries. For all libraries prepared using Archer VariantPlex methodology, fastq files were generated using a custom script and data analyses were performed using the CTL target region file and Archer analysis software version 6.2. Annotated variants were filtered and reported using an in-house, Web-based reporting application ClinMutReporter (Thomas Jefferson University Hospitals, Philadelphia, Pennsylvania).

## Results

### Patients

Among the 904 thyroid FNAs with an indeterminate cytopathologic diagnosis (Bethesda Category III or IV) that were characterized by NGS, 41 cases (4.5%) had mutations in the *EIF1AX* gene. Histopathologic confirmation of the diagnosis was available in a surgical follow up specimen in 26 of the 41 cases (63.4%).

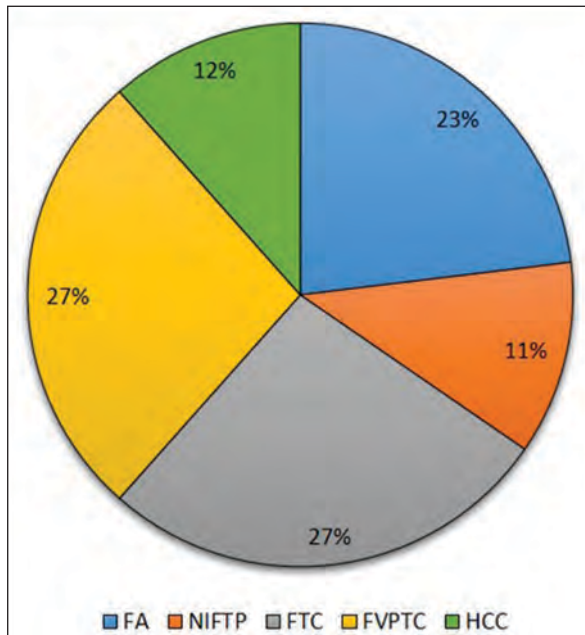
### Clinical & Pathologic Features

The clinical and pathologic features of the 26 patients with full diagnostic characterization are shown in Table 1. The mean patient age was 64 (range: 43-81 years) and with a female preponderance (female:male ratio=3.3). The mean size of the nodules was 2.8 cm (range: 1.1-6.3 cm). The cytopathologic diagnosis was Bethesda Category III (AUS/FLUS) in 12 (46.2%) and Bethesda Category IV (SFN/FN) in 14 (53.8%). As shown in Table 1 and Figure 1, the histopathologic analysis on follow up excisions included 6 neoplasms with a benign diagnosis (follicular adenoma (FA)), 3 with

Table 1. Summary of All *EIF1AX*-Mutated Surgically Removed Nodules

Case	Age (y)	Gender	Nodule size (cm)	Cytologic diagnosis (Bethesda category)	Histopathologic diagnosis	EIF1AX mutation type	Alternate allele frequency (AAF)	EIF1AX mutation location	EIF1AX mutation significance	Co-existing mutation(s), AAF
1	63	F	1.4	3	FA	c.370_371delinsTT; p.G124L	26.6%	Exon 6	Unknown	KRAS p.A59del, 5.6%
2	56	F	4.1	3	FA	c.338-1_338delinsTT; p.?	3.3%	A113_splice site	Pathogenic	-
3	43	F	1.1	3	FA	c.16G>C; p.G6R	9.7%	N terminus	Pathogenic	-
4	75	M	2.7	4	FA	c.338-2A>C; p.?	7.1%	A113_splice site	Pathogenic	-
5	66	F	2.5	4	FA	c.44G>A; p.G15D	9.7%	N terminus	Pathogenic	-
6	63	F	2.6	4 (Hurthle cell type)	FA	c.338-2A>T; p.?	14.1%	A113_splice site	Pathogenic	-
7	76	F	5.2	3	NIFTP	c.338-4_355del; p.?	16.5%	A113_splice site	Pathogenic	-
8	70	F	1.1	4	NIFTP	c.5C>G; p.P2R	4.6%	N terminus	Pathogenic	-
9	59	F	1.5	4	NIFTP	c.210G>C; p.W70C	40.0%	Exon 4	Likely pathogenic	NRAS p.Q61K, 41.9%
10	51	M	1.8	3	FTC	c.338-1G>C; p.?	19.5%	A113_splice site	Pathogenic	KRAS p.Q61R, 8.7%
11	54	F	1.5	3	FTC	c.338-1G>C; p.?	35.2%	A113_splice site	Pathogenic	NRAS p.Q61R, 39.2%; TERT c.-146C>T, 39.7%
12	46	F	2.3	3	FTC	c.3_5dup; p.P2dup	4.2%	N terminus	Likely pathogenic	TERT c.-146C>T, 7.3%
13	69	F	2.2	3	FTC	c.28A>G; p.K10E	31.2%	N terminus	Pathogenic	-
14	71	M	5.5	4	FTC	c.338-2A>G; p.?	40.6%	A113_splice site	Pathogenic	HRAS p.Q61R, 20.3%; TERT c.-124C>T, 11.4%
15	57	F	3	4	FTC	c.338-1G>C; p.?	2.1%	A113_splice site	Pathogenic	NRAS p.Q61K, 2.4%
16	60	F	6.3	4	FTC	c.338-2A>T; p.?	12.7%	A113_splice site	Pathogenic	KRAS p.Q61R, 12.8%; TERT c.-124C>T, 15.1%
17	69	F	3	4 (Hurthle cell type)	HCC	c.338-1G>C; p.?	26.6%	A113_splice site	Pathogenic	-
18	81	M	3.7	4 (Hurthle cell type)	HCC	c.338-1G>A; p.?	19.1%	A113_splice site	Pathogenic	-
19	71	F	3.5	4 (Hurthle cell type)	HCC	c.338-1G>T; p.?	40.3%	A113_splice site	Pathogenic	TP53 p.H179R, 66.4%
20	63	M	3.1	3	EFVPTC	c.429+1G>A; p.?	39.5%	D143_splice site	Likely pathogenic	-
21	59	F	1.8	3	EFVPTC	c.338-1_339delinsACA; p.?	6.7%	A113_splice site	Pathogenic	NRAS p.Q61K, 8.2%
22	68	F	1.3	3	EFVPTC	c.338-2A>T; p.?	4.5%	A113_splice site	Pathogenic	NRAS p.Q61R, 4.3%
23	58	M	4.5	4	EFVPTC	c.338-2A>T; p.?	23.50%	A113_splice site	Pathogenic	HRAS p.Q61R, 12.7%; TP53 p.Q331Rfs*14, 10.1% & p.S240R, 10.9%
24	65	F	2.7	4	EFVPTC	c.26G>T; p.G9V	22.2%	N terminus	Pathogenic	NRAS p.Q61R, 28.9%
25	68	F	2.6	3	IFVPTC	c.338-8_338-1del; p.?	26.3%	A113_splice site	Pathogenic	HRAS p.Q61R, 25.5%; TERT c.-124C>T, 21.6%
26	74	F	1.5	4	IFVPTC	c.338-1G>C; p.?	16.7%	A113_splice site	Pathogenic	YWHAQ-BRAF Fusion

EFVPTC=Encapsulated follicular variant of papillary thyroid carcinoma; F=Female, FA=Follicular adenoma, FTC=Follicular thyroid carcinoma; HCC=Hurthle cell carcinoma; IFVPTC=Infiltrative follicular variant of papillary thyroid carcinoma; M=Male, NIFTP=Noninvasive follicular thyroid neoplasm with papillary-like nuclear features.



FA=Follicular adenoma; FTC=Follicular thyroid carcinoma; FVPTC=Follicular variant of papillary thyroid carcinoma; HCC=Hurthle cell carcinoma; NIFTP=Noninvasive follicular thyroid neoplasm with papillary-like nuclear features.

Figure 1. Prevalence of histopathologic diagnoses in surgically resected EIF1AX-mutated cytologically indeterminate thyroid nodules (N=26).

a noninvasive follicular thyroid neoplasm with papillary-like nuclear features (NIFTP) diagnosis and 17 with a malignant diagnosis.

Malignant neoplasms included follicular thyroid carcinoma (FTC) (N=7), encapsulated follicular variant of papillary thyroid carcinoma (FVPTC) with capsular invasion (N=5), Hurthle cell carcinoma (HCC) (N=3), and infiltrative follicular variant of papillary thyroid carcinoma (IFVPTC) (N=2). The Bethesda Category III and IV cytopathologic diagnoses did not distinguish between benign and malignant thyroid neoplasms, as shown in Table 1.

### Molecular Characterization

These 26 cases were characterized by mutations in the *EIF1AX* gene. Two distinct types of mutations were observed, as shown in Figure 2 and Table 1. A mutation at the 3' end of the exon 6 splice site was observed in 17 cases and missense mutations in the N-terminal of the protein containing basic amino acids was present in 5 cases. In 4 patients the mutations did not fit neatly into this distribution. A duplication of the proline residue encoded by codon 2 was also detected, but it differs from the missense mutations more commonly seen in the N-terminal. In addition, the p.W70C mutation occurs in a "mini-cluster" of mutations that have been seen in non-thyroid malignancies, but have not been reported in thyroid neoplasia in the COSMIC (6) or cBioPortal (7) databases. The p.G124L and c.429+1G>A mutations have not been previously reported in thyroid malignancies. Single mutations in the exon 6 splice site or the basic amino terminal tail occurred in both benign and malignant thyroid neoplasms. In addition to the abnormal *EIF1AX* gene, mutations in significant tumor-associated genes occurred in 15 of the 26 cases, and 13 of the 15 were detected in malignant neoplasms. The additional mutated genes, shown in Table 1, included *NRAS* (N=6), *HRAS* (N=3), *KRAS* (N=3), the common *TERT* promoter mutation (N=5), and *TP53* (N=2). In 4 cases the *TERT* promoter mutation occurred with a *RAS* gene mutation and in one patient a *TP53* mutation occurred with a mutant *RAS* gene. One case also harbored a novel *YWHAG-BRAF* fusion.

*EIF1AX* mutation alone conferred a 36.4% (4/11) risk of malignancy (ROM) and 54.5% (6/11) risk of malignancy or NIFTP, while ROM was significantly higher in nodules with concurrent *RAS* (71.4%; 5/7), *TERT*, *TP53* and *RAS+TERT* (100%) mutations (Table 2).



X-axis shows the number of mutations. Green and black circles denote missense and splice site mutations respectively.

Figure 2. Distribution of EIF1AX mutations in surgically resected thyroid nodules (N=26)

Table 2. Summary of Risk of Malignancy (ROM) for All EIF1AX-Mutated Surgically Removed Nodules

Mutation(s)	Number of cases	Percentage	ROM (%)	ROM or NIFTP (%)
EIF1AX alone	11	42.3	36.4	54.5
EIF1AX + RAS	7	26.9	71.4	85.7
EIF1AX + RAS + TERT	4	15.4	100	100
EIF1AX + RAS + TP53	1	3.8	100	100
EIF1AX + BRAF Fusion	1	3.8	100	100
EIF1AX + TERT	1	3.8	100	100
EIF1AX + TP53	1	3.8	100	100
Overall	26	100	65.4	76.9

ROM=Risk of malignancy; NIFTP=Noninvasive follicular thyroid neoplasm with papillary-like nuclear features.

## Discussion

*EIF1AX* encodes the essential, ubiquitously-expressed eukaryotic translation initiation factor EIF1A with 144 amino acids. As a part of the 43S pre-initiation complex (PIC), it binds to the capped mRNA, aids in localizing the start codon and initiates translation. EIF1A protein contains a core RNA binding domain spanning the residues 32-95 which is flanked on either side by highly charged unstructured N- and C-terminus tails (8). Originally identified in uveal melanomas, *EIF1AX* mutations have now also been detected in a variety of other tumor types, including low-grade gliomas, lung adenocarcinoma, endometrial carcinoma, and various neoplastic and nonneoplastic thyroid lesions (4, 9-11). Missense mutations of the first 2-15 amino acids at the N-terminus of *EIF1AX* have been identified in several cancers (9, 12-14). An additional hotspot splice-site mutation (A113\_splice) in the C-terminus of the protein is thought to be exclusive to thyroid carcinoma (9, 11, 15).

In our study, 4.5% of cytologically indeterminate thyroid nodules (41 out of 904 total cases) and 11.4% (26 out of 229) of those that were surgically resected harbored an *EIF1AX* mutation. Of these cases, the histopathologic diagnoses were benign neoplasm (FA) in 6/26 (23.1%), NIFTP in 3/26 (11.5%) and malignant neoplasm (FTC, HCC or FVPTC) in 17/26 (65.4%) (Table 3A). Karunamurthy et al. (4) found *EIF1AX* mutations in 27/647 (4.2%) of indeterminate cytology samples, of which 5 had surgical follow-up information (1 EFVPTC, 1 hyperplastic nodule (HN), and 3 FA) yielding an estimated ROM of 20%. Our overall ROM is much higher (65.4%), and even in our nodules with *EIF1AX* mutation alone and no other coexisting mutations, the ROM is 36.4% (4/11) and ROM/NIFTP is 54.5% (6/11) (Table 2). All of our nodules were neoplastic, though other studies have found mutations in one case of HN (4). Of note, the estimated ROM calculated in studies such as this one are overestimations of the actual



ROM, due to the impact of selection bias. Nodules that undergo surgical resection are more likely to have suspicious pre-operative clinical findings (e.g. worrisome radiologic features, interval growth), increasing the likelihood of malignancy regardless of the FNA diagnosis and molecular result.

Similar to other studies, the most common type of *EIF1AX* mutation identified in our study was the A113\_splice mutation at the intron 5/exon 6 splice site of *EIF1AX* (17/26), followed by the missense mutations in N-terminus of the protein (5/26). Previous studies have concluded that the A113\_splice mutation, especially with co-existing *RAS* mutation, is more frequently observed in thyroid cancer than isolated *EIF1AX* mutations or mutations at the N-terminus hotspot of the gene (4, 11, 14). In our study, 13/17 (76.5%) surgically resected nodules with the A113\_splice mutation and 3/5 (60%) nodules with an N-terminal missense mutation were malignant. Of the 13 malignant nodules with the A113\_splice mutation, 10 harbored co-mutations (5 harbored one co-mutation and 5 harbored two co-mutations). Of the 3 malignant nodules with N-terminus mutation, 2 harbored co-mutations. Please refer to Table 1 for details.

Four cases harbored *EIF1AX* mutations that did not belong to the 2 common types discussed above. The N-terminal duplication (c.3\_5dup, p.P2dup) was not in the COSMIC database, but is likely similar to the missense mutations in the same region. The *EIF1AX* p.W70C identified in the NIFTP case had a concurrent *RAS* mutation. In the COSMIC database, 4 cases with this mutation and 3 additional missense mutations at this amino acid position had been reported in non-thyroid cancer specimens, which makes the p.W70C mutation likely pathogenic. The mutation p. G124L (c.370\_371delinsTT), detected in a FA, has been reported once in the COSMIC database, in a small cell carcinoma of the lung. Mutations affecting the same amino acid, p.G124\* and p.G124V, were reported in a single thyroid carcinoma specimen (cBioPortal, sample ID TCGA-EM-A3ST-01). Lastly, the mutation c.429+1G>A, exon 6/intron 6 splice site mutation, detected in one of our

EFVPTC cases, has never been reported, but 7 malignant cases with mutations affecting the D143\_splice site were documented in the COSMIC database. This mutation most likely affects splicing and hence the function of the protein.

Other studies have reported *EIF1AX* mutations co-occurring with several other driver mutations. Karunamurthy et al. (4) found co-mutations in 3/11 cases (2 with *NRAS* and 1 with *NRAS*, *TP53* and *TERT*), all of which were malignant neoplasms. The TCGA study found co-mutations (*KRAS* and *BRAF*) in one of their 6 cases of *EIF1AX*-mutated PTC (9). Our study showed that *EIF1AX* mutations can co-occur with mutations in *RAS*, *TP53* and *TERT promoter (TERTp)*, and these co-mutations are associated with a very high ROM. Co-existing *EIF1AX* and a hotspot *RAS* mutation conferred an 85.7% ROM and 100% ROM or NIFTP, compared to *EIF1AX* mutation alone that conferred a 36.4% ROM. Malignancy risk was 100% for nodules containing co-mutations in *TERTp*, *TP53*, *RAS+TERTp*, and *BRAF* fusion. Clinicians must be aware of this and should strongly consider surgical intervention, at least a lobectomy, for patients with multiple such mutations in a thyroid nodule.

Key published studies on the *EIF1AX* mutations in thyroid nodules/cancer specimens are summarized in Table 3. The histopathologic diagnoses and ROM for *EIF1AX* mutation positive specimens identified from FNA with indeterminate cytology (Bethesda III and V), including our current study, are shown in Table 3A. The frequencies of the *EIF1AX* mutations in different categories of thyroid nodules from surgically resected specimens are presented in Table 3B.

While *EIF1AX* mutations were identified in HN, FA, and differentiated thyroid cancer (PTC and FTC), the percentage of specimens containing the *EIF1AX* mutations was enriched in advanced thyroid cancer. By combining the case numbers of the studies listed in Table 3B, there were 11 positive specimens for *EIF1AX* mutations in 97 PDTC (11.3%) and 9 positive in 97 ATC cases (9.3%). Additional co-existing mutations in PDTC and ATC include *RAS*, *RAF*, *TERTp*, *TP53* mutations.

Table 3. Prevalence of EIF1AX Mutations in A) Fine Needle Aspirates (FNA) and B) Surgically Removed Nodules, in Present and Previously Published Studies

## A. Characterization of EIF1AX Mutation-Positive Fine Needle Aspirates (FNA) with Indeterminate Cytology

Study	EIF1AX-mutated FNA	Surgical pathology follow-up of EIF1AX-mutated FNA						
		Total cases	HN	FA	NIFTP	PTC	FTC	HCC
Karunamurthy et al, 2016 (4)	27/647; 4.2%	5/27	1/5; 20%	3/5; 60%	-	1/5; 20%	-	-
Present Study	41/904; 4.5%	26/41	-	6/26; 23.1%	3/26; 11.5%	7/26; 26.9% (FVPTC)	7/26; 26.9%	3/26; 11.5%

## B. Frequency of EIF1AX Mutations in Surgically Removed Nodules

Study	HN	FA	Differentiated TC		Undifferentiated TC		
			PTC	FTC	PDTC	ATC	
TCGA, 2014 (9)	-	-	6/402; 1.5% (5 FVPTC; 1 mix of follicular & classical variant)	-	-	-	-
Kunstman et al, 2015 (16)	-	-	-	-	-	3/22; 13.6%	
Karunamurthy et al, 2016 (4)	1/80; 1.3%	2/27; 7.4%	2/86; 2.3%	0/53; 0%	0/4; 0%	1/4; 25%	
Landa et al, 2016 (11)	-	-	-	-	9/84; 11%	3/33; 9%	
Nicolson et al, 2018 (17)	-	-	-	2/39; 5.1%	-	-	
Pozdeyev et al, 2018 (15)*	-	-	1/89; 1.1%	2/5; 40%	-	2/31; 6.5%	
Simoës-Pereira et al, 2019 (14)†	0/7; 0%	-	1/12; 8.3% (FVPTC)		2/9; 22.2%	0/7; 0%	

ATC=Anaplastic thyroid cancer; FA=follicular adenoma; FTC=Follicular thyroid carcinoma; HCC=Hurthle cell carcinoma; HN=Hyperplastic nodule; NIFTP=Noninvasive follicular thyroid neoplasm with papillary-like nuclear features; PDTC=Poorly differentiated thyroid carcinoma; PTC=Papillary thyroid carcinoma; TC=Thyroid cancer; \*Only those specimens that were sequenced on MSK-IMPACT panels were included in this table since EIF1AX is not tested by the FoundationOne Panels; †9 surgical specimens in this study had distinct histological type and were counted separately based on the histology. Please see the study by Simoës-Pereira et al. (14) for details.

Krishnamoorthy et al. (18) demonstrated *EIF1AX* A113\_splice mutation increases protein synthesis globally and cooperates with *RAS* mutations to increase the stability of c-MYC protein to drive thyroid tumorigenesis.

Among the 26 cases carrying the *EIF1AX* mutations in our cohort, 11 cases had *EIF1AX* mutations alone and 15 had co-existing mutations detected by our NGS panel. Within the 15 co-mutation cases, 13 were in the *RAS*/*RAF* pathway (including 1 case with a non-hotspot *KRAS* mutation, p.A59del with unknown significance), and 2 cases had a mutation either in the *TERT* promoter or the *TP53* gene. When we compared the alternate allele frequencies (AAF) of the *EIF1AX* and other co-existing mutations, the AAFs for the *EIF1AX* mutations were greater than (N=4) or similar to (N=10) that of other driver mutations (Table 1). In the case with a co-existing *TP53* mutation,

the AAF for the *TP53* mutation was 66% and AAF for the *EIF1AX* mutation was 40%. The apparent higher AAF of *TP53* is likely due to a loss of heterozygosity (LOH) event in this case, given the AAF of *TP53* was well over 50%. The high AAFs of *EIF1AX* mutations in comparison to that of co-existing mutations suggests that *EIF1AX* mutations represent an early event, at least in some cases, that promotes initiation of the thyroid tumors and malignant transformation.

## Conclusion

*EIF1AX* mutations can occur in both benign and malignant thyroid neoplasms. The type of *EIF1AX* mutation, and even more importantly, the presence or absence of co-mutations, has an impact on the likelihood of malignancy in an *EIF1AX*-mutat-



ed thyroid nodule. Therefore, in the face of a cytologically indeterminate thyroid nodule with an *EIF1AX* mutation detected upon molecular analysis, a more detailed look at the molecular profile, in conjunction with the clinical and imaging findings, may be helpful in predicting malignancy risk and determining optimal patient care.

#### What Is Already Known on This Topic:

*EIF1AX* mutations occur in wide variety of thyroid lesions, including HN, FA, NIFTP, well differentiated carcinomas (FTC and FVPTC) and poorly differentiated carcinomas (PDTc and ATC). Previous studies examining surgically resected nodules have concluded that the A113<sub>splice</sub> mutation, especially with co-existing RAS mutation, is more frequently observed in thyroid cancer than are isolated *EIF1AX* mutations or mutations at the N-terminus hotspot of the gene. However, there is limited data characterizing *EIF1AX* mutations in cytology samples from indeterminate thyroid nodules.

#### What This Study Adds:

The ROM in an *EIF1AX*-mutated, cytologically indeterminate thyroid nodule may be higher than previously reported, for in our study, 36.4% of thyroid nodules with isolated *EIF1AX* mutation identified in the FNA sample were diagnosed as malignant neoplasms upon surgical removal. Furthermore, our data suggests that the presence of co-mutations, regardless of the position of the *EIF1AX* mutation, has a significant influence on malignancy risk. The coexistence of *EIF1AX* mutations with other pathogenic driver mutations in RAS, TERT and TP53 conferred a 100% ROM or NIFTP in our cohort, indicating that such nodules warrant surgical resection.

**Authors' Contributions:** Conception and design: SG, YN and ZW; Acquisition, analysis and interpretation of data: SG, NB, YN, SP and ZW; Drafting the article: SG, NB and ZW; Revising it critically for important intellectual content: SP and ZW; Approved final version of the manuscript: SG, NB, YN, SP and ZW.

**Conflict of Interest:** The authors declare that they have no conflict of interest.

#### References

1. Rao SN, Bernet V. Indeterminate thyroid nodules in the era of molecular genomics. *Mol Genet Genomic Med*. 2020;8(9):e1288.
2. Kumar N, Gupta R, Gupta S. Molecular testing in diagnosis of indeterminate thyroid cytology: trends and drivers. *Diagn Cytopathol*. 2020 Jun 5. doi: 10.1002/dc.24522. Online ahead of print.
3. Yoo SK, Lee S, Kim SJ, Jee HG, Kim BA, Cho H, et al. Comprehensive analysis of the transcriptional and muta-

tional landscape of follicular and papillary thyroid cancers. *PLoS Genet*. 2016;12(8):e1006239.

4. Karunamurthy A, Panebianco F, Hsiao SJ, Vorhauer J, Nikofoforova MN, Chiosea S, et al. Prevalence and phenotypic correlations of *EIF1AX* mutations in thyroid nodules. *Endocr Relat Cancer*. 2016;23(4):295-301.
5. Simen BB, Yin L, Goswami CP, Davis KO, Bajaj R, Gong JZ, et al. Validation of a next-generation-sequencing cancer panel for use in the clinical laboratory. *Arch Pathol Lab Med*. 2015;139(4):508-17.
6. Catalogue of Somatic Mutations in Cancer [database on the Internet]. v92, released Aug 2020 Aug. [Cited 2021 Jan 29]. Available from: <http://cancer.sanger.ac.uk/cosmic>.
7. cBioPortal for Cancer Genomics [database on the Internet]. [cited 2021 Jan 29]. Available from: <http://cbioportal.org>.
8. Fekete CA, Applefield DJ, Blakely SA, Shirokikh N, Pestova T, Lorsch JR, et al. The eIF1A C-terminal domain promotes initiation complex assembly, scanning and AUG selection in vivo. *EMBO J*. 2005;24(20):3588-601.
9. Cancer Genome Atlas Research Network. Integrated genomic characterization of papillary thyroid carcinoma. *Cell*. 2014;159:676-90.
10. Johnson DB, Roszik J, Shoustari AN, Eroglu Z, Balko JM, Higham C, et al. Comparative analysis of the GNAQ, GNA11, SF3B1, and *EIF1AX* driver mutations in melanoma and across the cancer spectrum. *Pigment Cell Melanoma Res*. 2016;29(4):470-3.
11. Landa I, Ibrahimasic T, Boucai L, Sinha R, Knauf JA, Shah RH, et al. Genomic and transcriptomic hallmarks of poorly differentiated and anaplastic thyroid cancers. *J Clin Invest*. 2016;126(3):1052-66.
12. Martin M, Masshofer L, Temming P, Rahmann S, Metz C, Bornfeld N, et al. Exome sequencing identifies recurrent somatic mutations in *EIF1AX* and *SF3B1* in uveal melanoma with disomy 3. *Nat Genet*. 2013;45:933-6.
13. Etemadmoghadam D, Azar WJ, Lei Y, Moujaber T, Garsed DW, Kennedy CJ, et al. *EIF1AX* and *NRAS* mutations co-occur and cooperate in low-grade serous ovarian carcinomas. *Cancer Res*. 2017;77(16):4268-78.
14. Simoes-Pereira J, Moura MM, Marques IJ, Rito M, Cabreira RA, Leite V, et al. The role of *EIF1AX* in thyroid cancer tumorigenesis and progression. *J Endocrinol Invest*. 2019;42(3):313-8.
15. Pozdnyev N, Gay LM, Sokol ES, Hartmaier R, Deaver KE, Davis S, et al. Genetic analysis of 779 advanced differentiated and anaplastic thyroid cancers. *Clin Cancer Res*. 2018;24(13):3059-68. doi: 10.1158/1078-0432.CCR-18-0373.
16. Kunstman JW, Juhlin CC, Goh G, Brown TC, Stenman A, Healy JM, et al. Characterization of the mutational landscape of anaplastic thyroid cancer via whole-exome sequencing. *Hum Mol Genet*. 2015;24(8):2318-29.

17. Nicolson NG, Murtha TD, Dong W, Paulsson JO, Choi J, Barbieri AL, et al. Comprehensive genetic analysis of follicular thyroid carcinoma predicts prognosis independent of histology. *J Clin Endocrinol Metab.* 2018;103(7):2640-50.
18. Krishnamoorthy GP, Davidson NR, Leach SD, Zhao Z, Lowe SW, Lee G, et al. EIF1AX and RAS mutations cooperate to drive thyroid tumorigenesis through ATF4 and c-MYC. *Cancer Discov.* 2019;9(2):264-81.