



Thomas Jefferson University
Jefferson Digital Commons

Division of Cardiology Faculty Papers

Division of Cardiology

4-21-2021

A Shocking Case of Far-Field Atrial Oversensing in Giant-Cell Myocarditis

Tanuka Datta, MD

S. Melnick, DO

Bharaniabirami Rajaram, MD

Behzad B. Pavri

Follow this and additional works at: <https://jdc.jefferson.edu/cardiologyfp>

 Part of the [Cardiology Commons](#)

[Let us know how access to this document benefits you](#)

This Article is brought to you for free and open access by the Jefferson Digital Commons. The Jefferson Digital Commons is a service of Thomas Jefferson University's [Center for Teaching and Learning \(CTL\)](#). The Commons is a showcase for Jefferson books and journals, peer-reviewed scholarly publications, unique historical collections from the University archives, and teaching tools. The Jefferson Digital Commons allows researchers and interested readers anywhere in the world to learn about and keep up to date with Jefferson scholarship. This article has been accepted for inclusion in Division of Cardiology Faculty Papers by an authorized administrator of the Jefferson Digital Commons. For more information, please contact: JeffersonDigitalCommons@jefferson.edu.

MINI-FOCUS ISSUE: ELECTROPHYSIOLOGY

ADVANCED

CASE REPORT: CLINICAL CASE

A Shocking Case of Far-Field Atrial Oversensing in Giant-Cell Myocarditis



Tanuka Datta, MD, Stephen Melnick, DO, Bharaniabirami Rajaram, MD, Behzad B. Pavri, MD

ABSTRACT

We report a unique case of delivery of inappropriate implantable cardioverter-defibrillator therapies related to a "perfect storm": presence of an integrated lead, insufficient lead slack related to right heart dilation resulting in shock coil misplacement, myocarditis with loss of R waves, and the concomitant occurrence of an incessant atrial tachycardia. (**Level of Difficulty: Advanced.**) (J Am Coll Cardiol Case Rep 2021;3:603-9) © 2021 The Authors. Published by Elsevier on behalf of the American College of Cardiology Foundation. This is an open access article under the CC BY-NC-ND license (<http://creativecommons.org/licenses/by-nc-nd/4.0/>).

HISTORY OF PRESENTATION

A 35-year-old male with a history of nonischemic cardiomyopathy from giant-cell myocarditis (GCM) with a HeartMate 3 left ventricular assist device (Abbott Cardiovascular, Plymouth, Minnesota) and a single-chamber implantable cardioverter-defibrillator (VIGILANT EL ICD D232/254693, Boston Scientific, Marlborough, Massachusetts) presented after receiving a shock. His vital signs showed blood pressure of 110/89 mm Hg, pulse of 69 beats/min, and oxygen saturation of 99% on room air. Echocardiography showed that his left

ventricle, even when fully unloaded by the left ventricular assist device with normal flows, was barely contractile. The right ventricle was also severely dilated and hypokinetic, suggesting single-ventricle physiology with the right ventricle acting as a passive conduit. Telemetry and electrocardiographic review showed an atypical atrial flutter or atrial tachycardia with predominantly 2:1 atrioventricular block (**Figures 1A and 1B**).

DIFFERENTIAL DIAGNOSIS

The differential diagnosis for shock therapy included ventricular tachycardia (VT), ventricular fibrillation (VF), and inappropriate sensing.

INVESTIGATIONS

Interrogation revealed device programming for VVI pacing at 40 beats/min. Tachytherapies were programmed in 2 zones: VT at 200 beats/min (10 s) and VF at 220 beats/min (2.5 s). Therapies for arrhythmias in the VT zone were programmed to 2 rounds of antitachycardia pacing (ATP) followed by 36-J shocks;

LEARNING OBJECTIVES

- To describe clinical scenarios during which atrial oversensing occurs.
- To recognize the scenario of oversensing of far-field atrial signals during atrial tachycardia.
- To identify the mechanism of marked reduction in ventricular sensed amplitudes in the setting of myocarditis.

From the Department of Internal Medicine, Division of Cardiology, Thomas Jefferson University, Philadelphia, Pennsylvania, USA. The authors attest they are in compliance with human studies committees and animal welfare regulations of the authors' institutions and Food and Drug Administration guidelines, including patient consent where appropriate. For more information, visit the [Author Center](#).

Manuscript received November 3, 2020; revised manuscript received January 21, 2021, accepted February 5, 2021.

**ABBREVIATIONS
AND ACRONYMS**

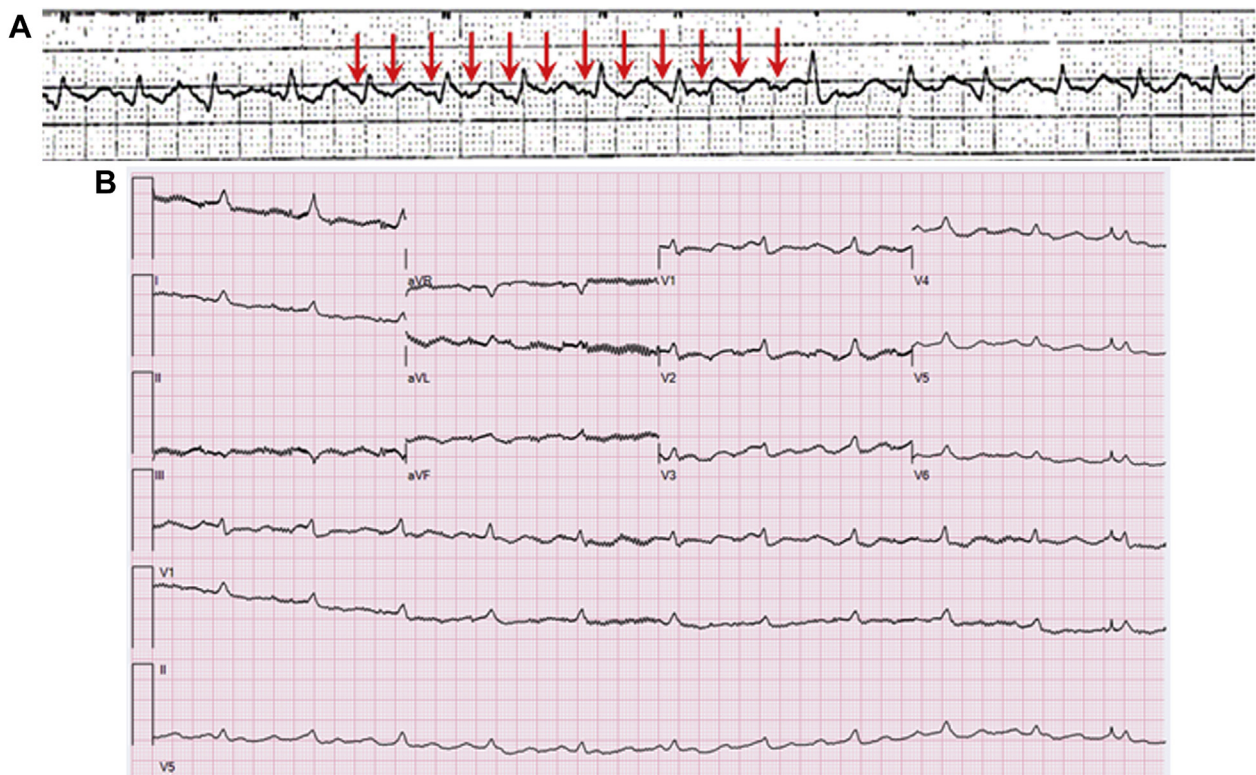
ATP = antitachycardia pacing
GCM = giant-cell myocarditis
RV = right ventricular
VF = ventricular fibrillation
VT = ventricular tachycardia

therapies for arrhythmias in the VF zone were programmed for 1 try of ATP followed by shocks. The device logs showed that the patient had experienced 38 episodes of “VT,” with 22 episodes triggering ATP and 3 episodes resulting in shocks; all treated episodes were declared to have “successful termination” (Figure 2), all occurring over a short

time period. The stored intracardiac trends disclosed that over the preceding 2 months, as his steroids were tapered, the sensed R-wave amplitude had diminished to the point at which the defibrillator was no longer able to sense native R waves even at maximum autogain (Figure 3). However, the far-field atrial electrograms during ongoing atrial tachycardia were sensed by the integrated defibrillator lead, leading to delivery of inappropriate therapies.

MANAGEMENT

In the setting of GCM, the progressive reduction in R-wave amplitudes was likely due to direct involvement of the myocardial tissue in the right ventricle, where his defibrillator lead was located, because of disease progression. Furthermore, Boston Scientific defibrillator leads have an integrated bipolar configuration; right ventricular (RV) dilation and the septal lead position (placed at an outside hospital) likely contributed to the insufficient slack seen on chest radiography, resulting in the proximal end of the shocking coil (used as the anode for sensing) being in the right atrium (Figure 4). The automatic sensing threshold of his defibrillator had dropped down to the lowest level because of small native QRS complexes, which resulted in detection of atrial signals during the ongoing

FIGURE 1 Telemetry and Electrocardiography of Atypical Atrial Flutter

(A) Telemetry showing 2:1 atrial tachycardia. Visible atrial deflections are marked with **arrows**; atrial rate is about 210 to 220 beats/min. **(B)** 12-Lead electrocardiogram showing atypical atrial flutter with 2:1 atrioventricular conduction; atrial rate is approximately 216 beats/min, and ventricular rate is about 108 beats/min. Electrocardiogram is displayed at twice gain with 20-Hz filter applied.

FIGURE 2 Device Interrogation Report Showing Ventricular Episodes

Ventricular Tachy Counters

	Since Last Reset Mar 05, 2020
Ventricular Episode Counters	
Total Episodes	2964
Treated	
VF Therapy	0
⚠️ VT Therapy	25
VT-1 Therapy	0
Commanded Therapy	0
Non-Treated	
No Therapy Programmed	1638
⚠️ NonsustainedV Episodes	1238
Other Untreated Episodes	63
Ventricular Therapy Counters	
ATP Delivered	34
ATP % Successful	76
Shocks Delivered	3
First Shock % Successful	100
Shocks Diverted	4

atrial tachycardia at a rate of approximately 210 beats/min (Figure 5). This arrhythmia was detected as “VT,” resulting in inappropriate ATP followed by a shock, terminating the atrial tachycardia briefly.

We tested for true R-wave sensing at maximum sensitivity of 0.15 mV, but the device continued to sense only atrial signals. In the setting of inability to detect true R waves, and inappropriate shocks due to far-field atrial oversensing during incessant

atrial tachycardia, the device was completely deactivated for both tachycardia and bradycardia therapies.

DISCUSSION

Inappropriate shocks can be the result of oversensing atrial depolarization during an atrial arrhythmia such as flutter or tachycardia (1-3). Clinical scenarios in

FIGURE 3 Progressively Diminishing R-Wave Amplitude Prior to Hospitalization

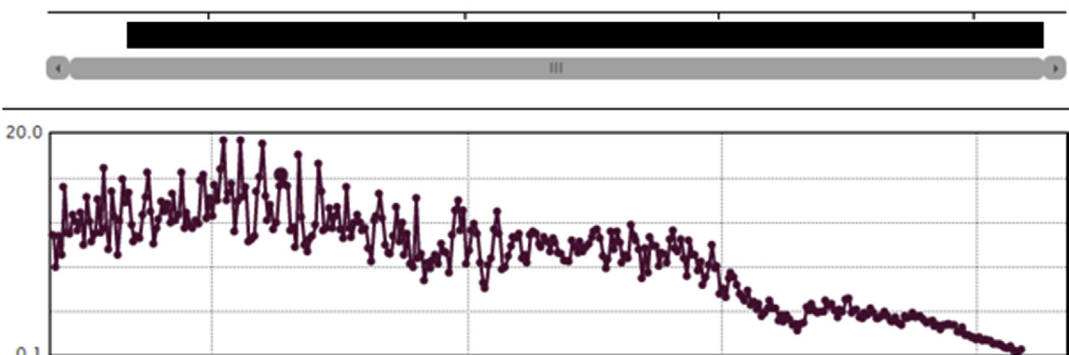
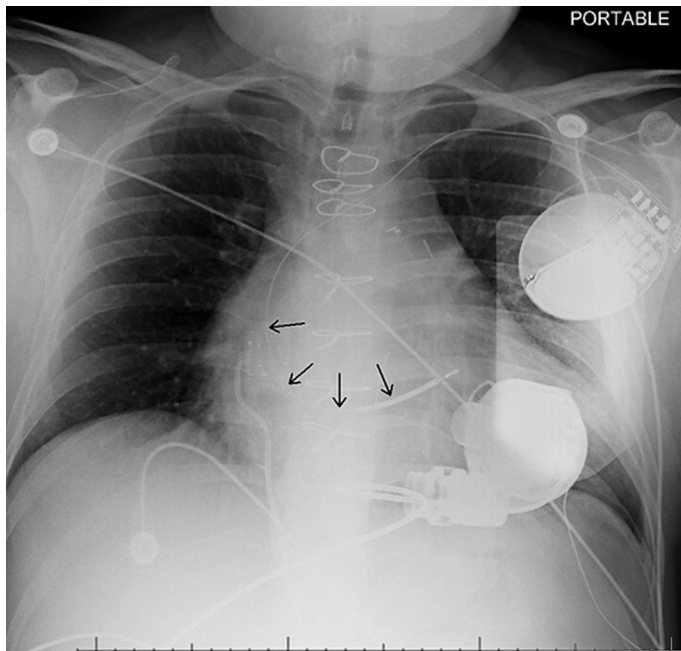


FIGURE 4 Implantable Cardioverter-Defibrillator Lead With Insufficient Slack and Proximal End of Shocking Coil Positioned in the Right Atrium



Arrow denotes proximal end of shocking coil positioned in the right atrium.

which these occur are summarized in [Table 1](#) (4-6). RV lead positioning becomes especially important with integrated bipolar leads; placement in the RV apex with the distal coil lying entirely within the RV cavity will minimize the probability of atrial oversensing (7,8). Remote monitoring has the potential to recognize early changes and potentially prevent such outcomes (9).

FOLLOW-UP

The patient successfully underwent heart transplantation in the following months and is doing well clinically.

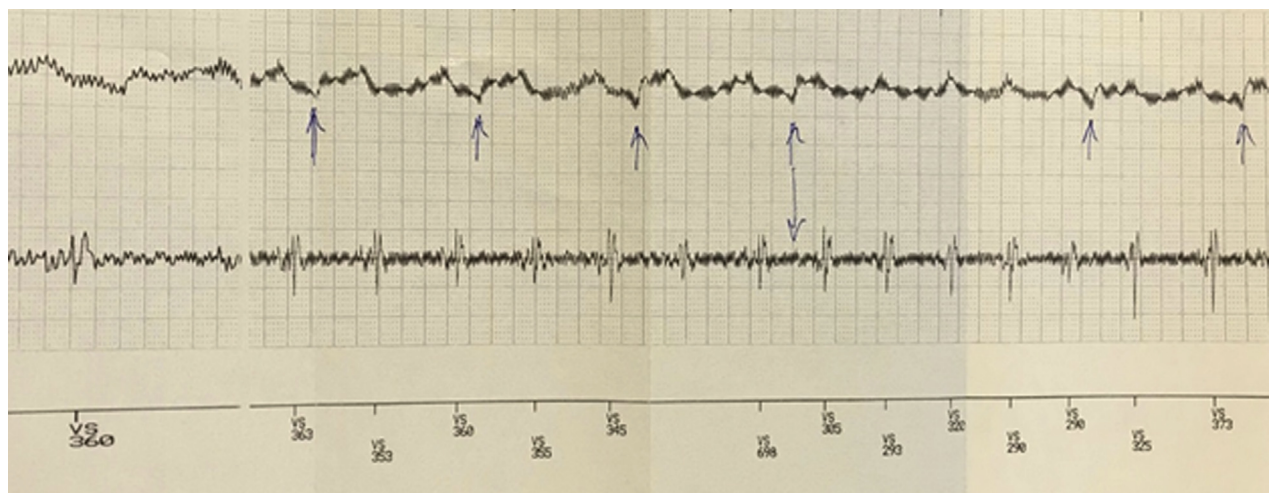
CONCLUSIONS

Inappropriate shocks in the setting of inflammatory cardiomyopathy can be the result of disease progression as well as RV lead factors such as bipolar configurations and lead placement. Cardiologists must be able to distinguish between true VT and inappropriate sensing of atrial arrhythmias in this unique setting.

FUNDING SUPPORT AND AUTHOR DISCLOSURES

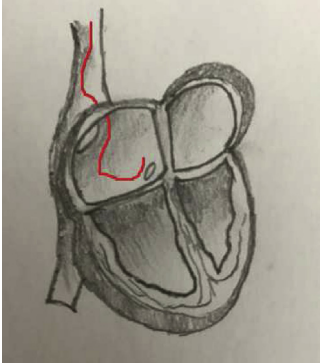
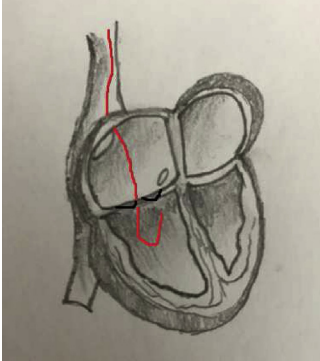
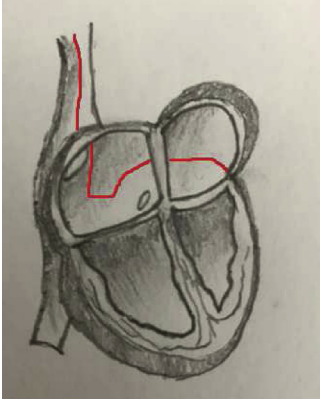
The authors have reported that they have no relationships relevant to the contents of this paper to disclose.

FIGURE 5 Intracardiac Signals From Device Interrogation

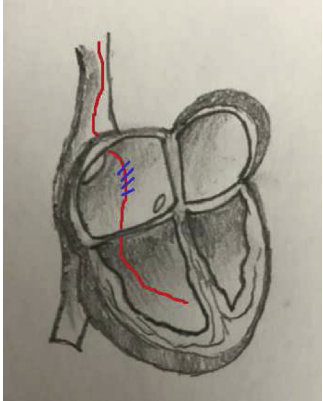
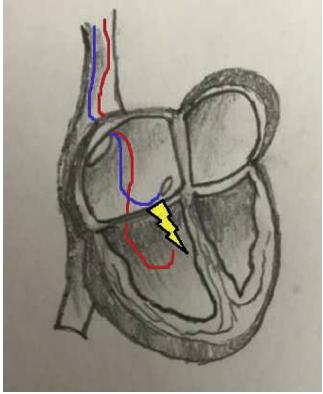


Intracardiac far-field signals (**top trace**) and near-field electrograms from the integrated right ventricular lead (**bottom trace**). No right ventricular signals are visually evident on the near-field electrograms; a small far-field R-wave is intermittently visible (**arrows**).

TABLE 1 Clinical Scenarios During Which Atrial Oversensing Occurs

Cause of Oversensing	Image	First Author (Ref. #)
RV lead-only devices Lead dislodgement to the atrium or atrioventricular junction		Brüggemann et al. (4)
Integrated bipolar lead positioning near tricuspid annulus		Kossaify (5)
Unintentional lead implantation into coronary sinus		Gunderson et al. (6)

Continued on the next page

TABLE 1 Continued		
Cause of Oversensing	Image	First Author (Ref. #)
Insulation defect in atrial portion of the lead causing sensing of atrial activity		Gunderson et al. (6)
Dual-chamber devices Atrial lead to RV lead interaction with the atrial lead contacting the RV lead during atrial systole, thereby producing a signal that is sensed by the RV lead		Gunderson et al. (6)

ADDRESS FOR CORRESPONDENCE: Dr. Tanuka Datta, Jefferson Heart Institute, 925 Chestnut Street,

Mezzanine, Philadelphia, Pennsylvania 19107, USA.
E-mail: tanuka.datta@jefferson.edu.

REFERENCES

- Grimm W, Menz V, Hoffmann J, et al. Complications of third-generation implantable cardioverter defibrillator therapy. *Pacing Clin Electrophysiol* 1999;22:206-11.
- Kowalski M, Ellenbogen KA, Wood MA, Friedman PL. Implantable cardiac defibrillator lead failure or myopotential oversensing? An approach to the diagnosis of noise on lead electrograms. *Europace* 2008;10:914-7.
- Daubert JP, Zareba W, Cannom DS, et al., for the MADIT II Investigators. Inappropriate implantable cardioverter-defibrillator shocks in MADIT II: frequency, mechanisms, predictors, and survival impact. *J Am Coll Cardiol* 2008;51:1357-65.
- Brüggemann T, Dahlke D, Chebbo A, Neumann I. Tachycardia detection in modern implantable cardioverter-defibrillators. *Herzschrittmacherther Elektrophysiol* 2016;27:171-85.
- Kossaify A. Sensing and detection functions in implantable cardioverter defibrillators: the good, the bad and the ugly. *Acta Cardiol Sin* 2020;36:308-17.
- Gunderson BD, Patel AS, Bounds CA, Shepard RK, Wood MA, Ellenbogen KA. An algorithm to predict implantable cardioverter-defibrillator lead failure. *J Am Coll Cardiol* 2004;44:1898-902.

7. Müller D, Hoffman E, Fiek M, Grünwald A, Steinbeck G. Bedeutung der Speicherelektrogramme zur Differenzierung adäquater und inadäquater ICD-Therapien [Stored electrograms to differentiate between adequate and inadequate ICD therapy]. *Herzschrittmacherther Elektrophysiol* 1997;8:39-45.

8. Barold SS, Kucher A. Far-field atrial sensing by the left ventricular channel of a biventricular device. *Pacing Clin Electrophysiol* 2014;37:1624-9.

9. Varma N, Michalski J, Epstein AE, Schweikert R. Automatic remote monitoring of implantable cardioverter-defibrillator lead and generator performance: the Lumos-T Safely Reduces Routine

Office Device Follow-Up (TRUST) trial. *Circ Arrhythm Electrophysiol* 2010;3:428-36.

KEY WORDS cardiac pacemaker, cardiomyopathy, supraventricular arrhythmias, ventricular tachycardia