



Thomas Jefferson University
Jefferson Digital Commons

Department of Orthopaedic Surgery Faculty
Papers

Department of Orthopaedic Surgery

10-14-2020

Osseous changes following reverse total shoulder arthroplasty combined with latissimus dorsi transfer: a case series

Jason S Klein

Peter S Johnston

Benjamin W Sears

Manan S Patel

Armodios M Hatzidakis

See next page for additional authors

Follow this and additional works at: <https://jdc.jefferson.edu/orthofp>

 Part of the [Orthopedics Commons](#), and the [Surgery Commons](#)

[Let us know how access to this document benefits you](#)

This Article is brought to you for free and open access by the Jefferson Digital Commons. The Jefferson Digital Commons is a service of Thomas Jefferson University's [Center for Teaching and Learning \(CTL\)](#). The Commons is a showcase for Jefferson books and journals, peer-reviewed scholarly publications, unique historical collections from the University archives, and teaching tools. The Jefferson Digital Commons allows researchers and interested readers anywhere in the world to learn about and keep up to date with Jefferson scholarship. This article has been accepted for inclusion in Department of Orthopaedic Surgery Faculty Papers by an authorized administrator of the Jefferson Digital Commons. For more information, please contact: JeffersonDigitalCommons@jefferson.edu.

Authors

Jason S Klein, Peter S Johnston, Benjamin W Sears, Manan S Patel, Armodios M Hatzidakis, and Mark D. Lazarus



Osseous changes following reverse total shoulder arthroplasty combined with latissimus dorsi transfer: a case series



Jason S. Klein, MD ^{a,*}, Peter S. Johnston, MD ^b, Benjamin W. Sears, MD ^c,
Manan S. Patel, BA ^d, Armodios M. Hatzidakis, MD ^c, Mark D. Lazarus, MD ^d

^a Division of Shoulder and Elbow Surgery, The Carrell Clinic, Dallas, TX, USA

^b Centers for Advanced Orthopaedics, Southern Maryland Orthopaedics and Sports Medicine Division, Waldorf, MD, USA

^c Division of Shoulder and Elbow Surgery, Western Orthopaedics, Denver, CO, USA

^d Department of Orthopaedic Surgery, The Rothman Institute at Thomas Jefferson University, Philadelphia, PA, USA

ARTICLE INFO

Keywords:

Total shoulder arthroplasty
osteolysis
complications
cuff tear arthropathy
latissimus dorsi transfer
periprosthetic fracture

Level of evidence: Level IV; Case Series;
Treatment Study

Background: This is the first report on the incidence of proximal humerus osseous changes and associated clinical consequences in reverse total shoulder arthroplasty combined with a latissimus dorsi tendon transfer (RTSA+LDT).

Methods: A multicenter, retrospective review identified all patients who had undergone a primary RTSA+LDT and had at least 3-month radiographic follow-up between 2012 and 2017. Data collection included demographics, oral steroid use, repair technique for LDT fixation, radiographic humeral osseous changes, complications, and need for revision surgery.

Results: Twenty-four patients were included with an average age of 70.7 ± 7.9 years and follow-up of 16.3 (3–50) months. Ten patients (41.7%) developed osseous changes at the transfer location. There was no increased risk of developing osseous changes based on the surgical fixation technique ($P = .421$). Average time to earliest radiographic detection of osseous changes was 2.7 ± 1.7 months, with all changes occurring at or before 6 months. Two patients developed proximal humerus fractures, of which 1 had osseous changes through which the fracture occurred.

Discussion: RTSA+LDT may place the proximal humeral cortex at greater risk than previously described. Using a long-stem prosthesis in the setting of RTSA+LDT may limit the consequences of this complication.

© 2020 The Author(s). Published by Elsevier Inc. on behalf of American Shoulder and Elbow Surgeons. This is an open access article under the CC BY-NC-ND license (<http://creativecommons.org/licenses/by-nc-nd/4.0/>).

Massive rotator cuff tears (RCTs) are a significant source of morbidity including weakness, chronic pain, and severe functional impairment.⁸ No consensus exists on the precise definition nor management of massive RCTs.^{2,7,10,15} Patients with irreparable, massive posterosuperior RCTs with stage 3 or 4 fatty infiltration of the infraspinatus and teres minor present with a debilitating decrease in shoulder strength and function often with combined loss of active elevation and external rotation (CLEER).^{3,10,22,23} For these patients, reverse total shoulder arthroplasty (RTSA) is a viable option to restore range of motion, particularly active abduction and forward elevation. However, RTSA may not restore external rotation as effectively.⁴ For select patients, an RTSA combined with a

latissimus dorsi tendon transfer (RTSA+LDT) can help restore ER functional deficit.^{1,9–11,13,14,18}

Gerber et al⁹ studied RTSA+LDT in 12 patients with CLEER and found significant improvements in forward elevation, abduction, external rotation, strength, and functional scores at an average follow-up of 18 months. Puskas et al¹⁸ looked at 32 shoulders with CLEER treated with RTSA+LDT and found significant improvements in functional scores, external rotation, abduction, and forward elevation at a mean follow-up of 53 months. Hartzler et al¹¹ included 10 patients with combined RTSA+LDT and found significant improvements in external rotation, forward elevation, and functional scores, comparable to their patients who only underwent RTSA. Thus these patients with CLEER can achieve similar functional outcomes with an additional LDT as those patients who had better preoperative range of motion and did not require an LDT. Most recently, Popescu et al¹⁷ looked at 13 patients with CLEER treated with RTSA+LDT and found significant improvements in external rotation and forward elevation.

The Office of Human Research at Thomas Jefferson University institutional review board approved this study (IRB no. 18D.274).

* Corresponding author: Jason S. Klein, MD, Division of Shoulder and Elbow Surgery, The Carrell Clinic, Dallas, TX, USA.

E-mail address: jasonskleinmd@gmail.com (J.S. Klein).

<https://doi.org/10.1016/j.jseint.2020.08.018>

2666-6383/© 2020 The Author(s). Published by Elsevier Inc. on behalf of American Shoulder and Elbow Surgeons. This is an open access article under the CC BY-NC-ND license (<http://creativecommons.org/licenses/by-nc-nd/4.0/>).

The cited complication rate for this combined procedure in the literature is between 17.1% and 26%.^{13,18} A systematic review performed by Ortmaier et al¹³ reported a 26% complication rate in the 7 studies that evaluated RTSA+LDT. This included 6% complication rate that was LDT-specific (ie, nerve palsies, subluxation, and partial tear) and 10% complication rate that was RTSA-specific (infections, dislocations, periprosthetic fracture, and 1 aseptic loosening); the rest were unspecified.¹³ To our knowledge, no one has reported specifically on proximal humeral bone changes associated with this combined procedure and their associated consequences.

The purpose of this study is to report the incidence of osseous changes and associated clinical consequences (eg, periprosthetic fracture) in a series of patients who underwent RTSA+LDT for rotator cuff arthropathy in the setting of massive, posterolateral RCTs.

Methods

Patient selection

A multicenter, retrospective review identified all patients who had undergone a primary RTSA+LDT and had at least 3-month radiographic follow-up between 2012 and 2017. Exclusion criteria included patients with less than 3 months of follow-up, revision cases, use of proximal humeral/femoral allograft, and those completed in the setting of infection, which may have compromised proximal humeral bone stock.

Study design

A chart review was performed to collect preoperative, intraoperative and postoperative data. Preoperative data included demographics such as sex, age, comorbidities, and perioperative oral steroid use. Intraoperative data included implant type and company, surgeon, repair technique for LDT fixation (ie, bone tunnel or suture to the pectoralis major), and use of cement. Postoperatively, patients were radiographically assessed for humeral osseous changes using standard anteroposterior and axillary radiographs, any complications, and any need for revision surgery. Each patient was evaluated for osseous change progression from the time of surgery to the final follow-up.

Surgical technique—bone tunnel vs. suture to pectoralis major stump

The latissimus dorsi and teres major tendons were identified and removed from the humerus sharply as 1 unit. For the bone tunnel technique, the tendons were secured with 2 no. 5 nonabsorbable sutures (FiberWire) in a Krackow locking fashion. Before humeral stem implantation, 2 drill holes were made along the lateral aspect of the humerus just lateral to the pectoralis insertion and at the same height as the most proximal position of the pectoralis. A shuttle suture was used to place the no. 5 suture through the transosseous tunnels, and the bone along the lateral margin of the humerus was prepared with light decortication. After humeral stem insertion, the arm was externally rotated to 35°–45° with 25° of elevation and the suture tied over the top of the transosseous tunnels resulting in an onlay repair of the LDT to the lateral humeral cortex. For the repair to the pectoralis major technique, the glenoid and humeral components were implanted in the usual fashion. The tagged tendons were passed posterior to the humerus. The arm was then placed in 35°–45° of external rotation and 25° of abduction after which the tendon was repaired side to side to the upper border of the pectoralis major with a no. 5 nonabsorbable suture (FiberWire). No bone decortication was performed.

Statistical analysis

A Fisher’s exact test was used to evaluate risk factors for the development of bone changes (ie, osseous lesions, heterotopic ossification, fracture, or scapular notching) including gender, surgical fixation technique, cement use, implant company, and steroid use. A Mann-Whitney *U* test was carried out to analyze the effect of age on the development of osseous lesions. To study whether the development of osseous changes differed between the LDT fixation technique, a Kaplan-Meier curve was applied. All statistical analysis was carried out on Statistical Package for the Social Science (SPSS) version 26 (IBM Corp., Armonk, NY, USA). Statistical significance was defined at a *P* value of <.05 for all output.

Results

Our search yielded 28 patients who had been treated for RTSA+LDT. Four patients were excluded: 2 were lost to follow-up (ie, <3 months of radiographic follow-up), 1 for infection, and 1 for use of a proximal humeral allograft. Of the remaining 24 patients, 18 were male and 6 were female, with an average age of 70.7 ± 7.9 years at the time of surgery and an average follow-up of 16.3 (3–50) months. Ten patients were treated with a bone tunnel technique for latissimus dorsi fixation, whereas 14 were treated with suturing to the pectoralis major stump (Table I).

Ten of 24 patients developed osteolytic defects (Fig. 1). Of these 10, 7 were found in the group repaired by suturing to the pectoralis major, and 3 of these were in the bone tunnel group; there was no increased risk of developing osseous changes based on the surgical fixation technique (*P* = .421) (Table I). The average time to earliest radiographic detection of osseous changes was 2.7 ± 1.7 months, with all changes occurring at or before 6 months. Kaplan-Meier analysis is shown in Fig. 2 and was found to be insignificant between groups (*P* = .093) at the final follow-up.

Two patients developed proximal humerus fractures, of whom only 1 had osseous changes through which the fracture occurred. This patient had complete cortical bone loss at the time of fracture and was revised to a long stem with cerclage fixation (Fig. 1). Age, gender, steroid use, implant company, and cement use were not correlated with the development of osseous changes.

Table I

Data organized by overall and surgical technique for latissimus dorsi transfer (bone tunnel or sutured to the pectoralis major)

Patient characteristics	Bone tunnel (n = 10)	Suture (n = 14)	<i>P</i> value
Age (yr), mean ± SD	73.9 ± 6.6	68.5 ± 8.3	.178
Sex (n)			
Male	8	10	
Female	2	4	
Follow-up (mo), mean (range)	22.8 (7–47)	11.6 (3–50)	
Cement, n (%)	3 (30)	3 (21.4)	.633
Bone changes, n (%)			
None	6 (60)	6 (42.9)	
Osseous changes	3 (30)	7 (50)	.421
HO	0 (0)	1 (7.1)	.239
Scapular notching	2 (20)	0 (0)	
Fracture	2 (20)	0 (0)	
Fracture through lysis, n (%)	1 (10)	0 (0)	
Time to radiographic evidence of lysis (mo), mean ± SD	5 ± 1.0	1.7 ± 0.4	
Revision surgery, n (%)	3 (30)	1 (7.1)	.011
Infection, n (%)	0 (0)	1 (7.1)	

SD, standard deviation; HO, heterotopic ossification. *P* values provided when possible, between surgical techniques.

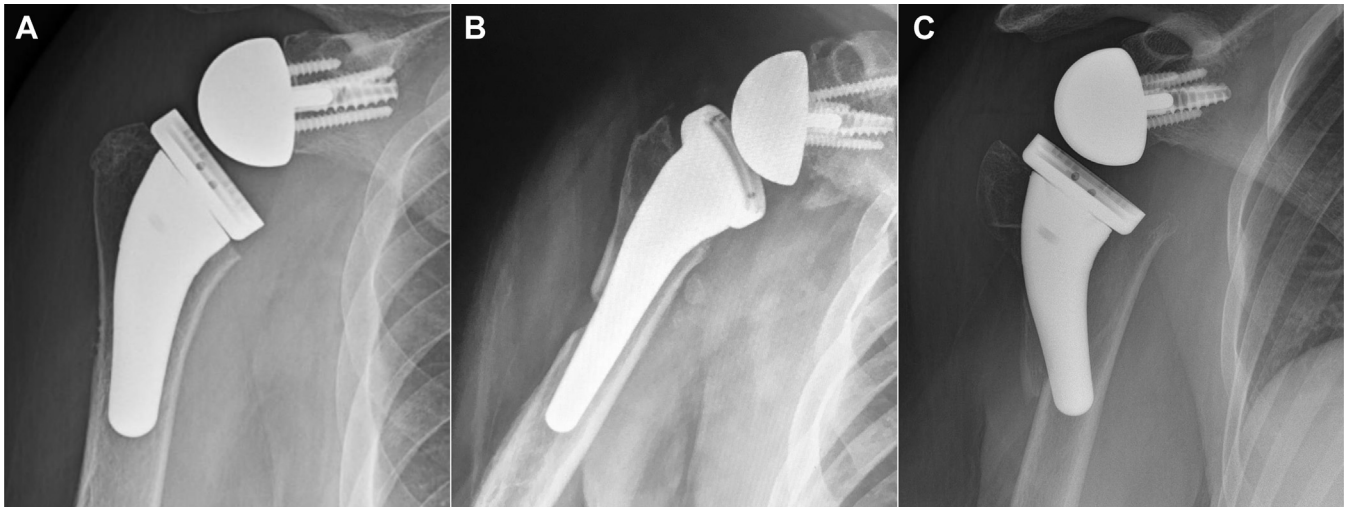

Figure 1 (A, B) Spectrum of cortical bone loss through the lateral cortex. (C) Periprosthetic fracture through the site of osteolysis.

Discussion

In this study, we report a new complication of RTSA+LDT not previously described in the literature. Ten patients in our cohort developed osseous changes on radiographic follow-up. Earliest detection of osseous changes on average was 2.7 ± 1.7 months, with all 10 having osseous changes at or before 6 months after surgery present on standard shoulder films. Thus, the development of bone changes in these patients should be suspected in the first 6 months after surgery.

Two patients suffered fractures secondary to falls, one of which was through the site of osseous changes at the tip of the RTSA humeral stem, near the site of the LDT insertion. The osseous changes may have contributed to a stress riser at that level. Prophylactically using a long-stem humeral component to bypass the area of stress and possible development of osseous changes at that level due to the tendon transfer may limit the risk of periprosthetic

fracture related to the use of an LDT in the future. In the Puskas et al study,¹⁸ 1 patient, treated with RTSA+LDT, suffered a periprosthetic fracture secondary to a fall. However, in this case, the fracture occurred distal to the LDT insertion, at the tip of the humeral stem as well. Further investigation is needed to evaluate stem length as a risk factor for fracture in patients with osseous changes.

Causes for these bone changes are incompletely understood at this time. One possibility is that the fixation technique could influence the development of osseous changes. Although the incidence of osseous changes was greater in the suture to pectoralis major technique relative to bone tunnels in our case series, this finding was not significantly different between the 2 LDT fixation groups (ie, bone tunnel and suture technique to the pectoralis major). This is likely due to the small sample size; studies with larger numbers would be required to elucidate the true difference. Although light decortication was completed in the bone tunnel technique, this cohort had a smaller rate of development of osseous

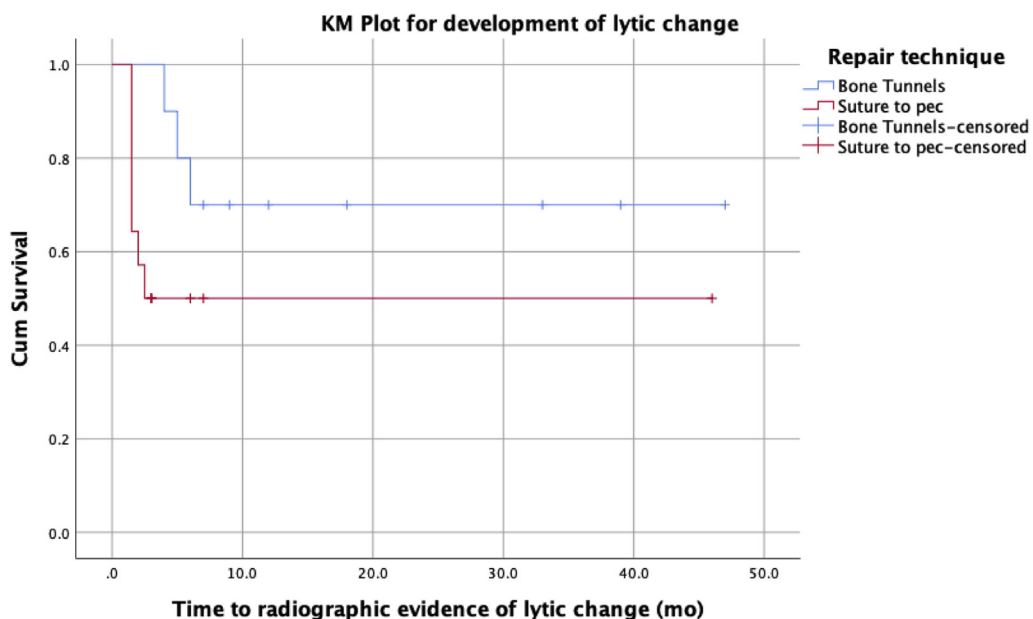


Figure 2 Kaplan-Meier (KM) curve showing the development of osseous changes by tendon fixation (bone tunnels or suturing to the pectoralis major stump). The development of osseous changes between groups was not found to be significantly different.

changes relative to the suture to pectoralis major tendon technique that did not employ decortication. Therefore, decortication of the adjacent bone does not entirely explain this radiographic finding.

For the bone tunnel technique, it is well documented that a hole in the cortex of bone can significantly weaken and create a local stress riser that may lead to fracture.^{5,6,12,21} In the second technique, the suture to pectoralis major LDT transfer technique, the tendon transfer may be placed on greater tension in order to repair it to the pectoralis major tendon origin, thereby limiting internal rotation and possibly causing a wind-shield wiper or periosteal compression effect on the proximal humeral lateral cortex leading to osteolysis. Larger studies and biomechanical evaluation may be necessary to illuminate the causes of this phenomenon further.

An anatomic study by Reeves et al²⁰ showed that the proximal humerus trabecular-canal density is nonuniform. The authors used computed tomography scans of 98 patients to construct a model of the trabecular canal of the proximal humerus. They found the greatest average density of bone within the first 15–20 mm beneath the humeral head resection plane. Thereafter, the density decreased down the canal.²⁰ In another computed tomography study, Razfar et al¹⁹ showed that different stem lengths lead to significantly different proximal humerus stresses, where standard stems lead to a greater reduction in proximal humerus stress due to load transfer along the stem and to the distal tip. A study by Peduzzi et al¹⁶ looked at the bony adaptations with short uncemented stems in 183 patients. They found medial cortical narrowing in 72.6% of cases, lateral metaphysis thinning in 9.8% of cases, and medial metaphysis thinning in 46.4% of cases.¹⁶ Although the authors report that these bony changes are limited phenomena that do not impact functional outcomes at 2 years, in the setting of an RTSA+LDT, these bony adaptations could play a factor in the increased risk of osteolysis or possibly fracture, thus contributing to the findings documented in this study.

Limitations in our study should be taken into account before more definite conclusions can be drawn. Our small sample size makes it difficult to assess for significant differences between the surgical fixation technique as a risk factor, as well as other patient risk factors, for the development of osseous changes. The retrospective nature of our study is another limitation. Being unable to standardize the surgical technique or type of implant used, confounding factors may be at play that influence our results. Finally, with short-term follow-up—mean follow-up of 16.3 (3–50) months—it is challenging to assess the natural history of bone changes such as their timeframe for occurrence, progression of osseous changes, and development of severe sequelae such as periprosthetic fracture in all our patients. However, despite short follow-up, we found evidence of osteolysis in nearly half of our patients, with all developing it before 6 months after operation.

Conclusion

Combined RTSA+LDT may place the proximal humeral cortex at greater risk than previously described. The cause of these bone changes is incompletely understood at this time but should be evaluated in the 6-month postoperative period. One patient advanced to periprosthetic fracture through the area of osteolysis, highlighting a concern for bone loss near the end of the prosthesis resulting in a larger stress riser. In the future, one may consider using a long-stem prosthesis in the setting of RTSA+LDT to limit the risk of fracture associated with this complication. This is the first report in the literature to document osseous changes as a potential complication for RTSA+LDT. Further research is needed to reveal the risk factors and cause of osteolysis identified in this series of patients.

Disclaimer

Peter S. Johnston is the paid consultant for Aevumed; receives IP royalties from Shoulder Innovations; is the unpaid consultant for Tensor Solutions; and is the paid consultant and paid presenter or speaker for and receives research support from Wright Medical Technology, Inc.

Benjamin W. Sears receives research support from Arthrex, Inc. and Tornier; and receives IP royalties from and is the paid consultant for United Orthopedic Corporation.

Armodios M. Hatzidakis is the board or committee member of American Shoulder and Elbow Surgeons; receives research support from Arthrex, Inc. and Exactech, Inc.; is the paid consultant for Medtronic; has stock or stock options in Tornier; and receives IP royalties from, is the paid consultant and paid presenter or speaker for, and receives research support from Wright Medical Technology, Inc.

Mark D. Lazarus receives research support from Tornier; and receives IP royalties from and is the paid presenter or speaker of Wright Medical Technology, Inc.

The other authors, their immediate families, and any research foundations with which they are affiliated have not received any financial payments or other benefits from any commercial entity related to the subject of this article.

References

1. Axe JM. Tendon transfers for irreparable rotator cuff tears: an update. *EFORT Open Rev* 2017;1:18–24. <https://doi.org/10.1302/2058-5241.1.000003>.
2. Boileau P, Baqué F, Valerio L, Ahrens P, Chuinard C, Trojani C. Isolated arthroscopic biceps tenotomy or tenodesis improves symptoms in patients with massive irreparable rotator cuff tears. *J Bone Joint Surg Am* 2007;89:747–57. <https://doi.org/10.2106/JBJS.E.01097>.
3. Boileau P, Rumian AP, Zumstein MA. Reversed shoulder arthroplasty with modified L'Episcopo for combined loss of active elevation and external rotation. *J Shoulder Elbow Surg* 2010;19(Suppl):20–30. <https://doi.org/10.1016/j.jse.2009.12.011>.
4. Boileau P, Watkinson DJ, Hatzidakis AM, Balg F. Grammont reverse prosthesis: design, rationale, and biomechanics. *J Shoulder Elbow Surg* 2005;14(Suppl S): 147S–61S. <https://doi.org/10.1016/j.jse.2004.10.006>.
5. Brooks DB, Burstein AH, Frankel VH. The biomechanics of torsional fractures. The stress concentration effect of a drill hole. *J Bone Joint Surg Am* 1970;52: 507–14.
6. Clark CR, Morgan C, Sonstegard DA, Mathews LS. The effect of biopsy hole shape and size on bone strength. *J Bone Joint Surg Am* 1977;59:213–7.
7. Collin P, Matsumura N, Lädermann A, Denard PJ, Walch G. Relationship between massive chronic rotator cuff tear pattern and loss of active shoulder range of motion. *J Shoulder Elbow Surg* 2014;23:1195–202. <https://doi.org/10.1016/j.jse.2013.11.019>.
8. Gerber C, Fuchs B, Hodler J. The results of repair of massive tears of the rotator cuff. *J Bone Joint Surg Am* 2000;82:505–15.
9. Gerber C, Pennington SD, Lingenfelser EJ, Sukthankar A. Reverse delta-III total shoulder replacement combined with latissimus dorsi transfer: a preliminary report. *J Bone Joint Surg Am* 2007;89:940–7. <https://doi.org/10.2106/JBJS.F.00955>.
10. Goutallier D, Postel J-M, Bernageau J, Lavau L, Voisin M-C. Fatty muscle degeneration in cuff ruptures. *Clin Orthop Relat Res* 1994;304:78–83.
11. Hartzler RU, Steen BM, Hussey MM, Cusick MC, Cottrell BJ, Clark RE, et al. Reverse shoulder arthroplasty for massive rotator cuff tear: risk factors for poor functional improvement. *J Shoulder Elbow Surg* 2015;24:1698–706. <https://doi.org/10.1016/j.jse.2015.04.015>.
12. Johnson BA, Fallat LM. The effect of screw holes on bone strength. *J Foot Ankle Surg* 1997;36:446–51.
13. Ortmaier R, Hitzl W, Matis N, Mattiassich G, Hochreiter J, Resch H. Reverse shoulder arthroplasty combined with latissimus dorsi transfer: a systemic review. *Orthop Traumatol Surg Res* 2017;103:853–9. <https://doi.org/10.1016/j.otsr.2017.03.019>.
14. Ortmaier R, Resch H, Hitzl W, Mayer M, Blocher M, Vasvary I, et al. Reverse shoulder arthroplasty combined with latissimus dorsi transfer using the bone-chip technique. *Int Orthop* 2014;38:553–9. <https://doi.org/10.1007/s00264-013-2139-3>.
15. Patte D. Classification of rotator cuff lesions. *Clin Orthop Relat Res* 1990;254: 81–6.
16. Peduzzi L, Goetzmann T, Wein F, Roche O, Sirveaux F, Mole D, et al. Proximal humeral bony adaptations with a short uncemented stem for shoulder

- arthroplasty: a quantitative analysis. *JSES Open Access* 2019;3:278–86. <https://doi.org/10.1016/j.jses.2019.09.011>.
17. Popescu IA, Bihel T, Henderson D, Martin Becerra J, Agneskirchner J, Lafosse L. Functional improvements in active elevation, external rotation, and internal rotation after reverse total shoulder arthroplasty with isolated latissimus dorsi transfer: surgical technique and midterm follow-up. *J Shoulder Elbow Surg* 2019;28:2356–63. <https://doi.org/10.1016/j.jse.2019.04.039>.
 18. Puskas GJ, Catanzaro S, Gerber C. Clinical outcome of reverse total shoulder arthroplasty combined with latissimus dorsi transfer for the treatment of chronic combined pseudoparesis of elevation and external rotation of the shoulder. *J Shoulder Elbow Surg* 2014;23:49–57. <https://doi.org/10.1016/j.jse.2013.04.008>.
 19. Razfar N, Reeves JM, Langohr DG, Willing R, Athwal GS, Johnson JA. Comparison of proximal humeral bone stresses between stemless, short stem, and standard stem length: a finite element analysis. *J Shoulder Elbow Surg* 2016;25:1076–83. <https://doi.org/10.1016/j.jse.2015.11.011>.
 20. Reeves JM, Athwal GS, Johnson JA. An assessment of proximal humerus density with reference to stemless implants. *J Shoulder Elbow Surg* 2018;27:641–9. <https://doi.org/10.1016/j.jse.2017.09.019>.
 21. Rosson J, Egan J, Shearer J, Monro P. Bone weakness after the removal of plates and screws. Cortical atrophy or screw holes? *J Bone Joint Surg Br* 1991;73:283–6.
 22. Simovitch RW, Helmy N, Z umstein MA, Gerber C. Impact of fatty infiltration of the teres minor muscle on the outcome of reverse total shoulder arthroplasty. *J Bone Joint Surg Am* 2007;89:934–9. <https://doi.org/10.2106/JBJS.F.01075>.
 23. Walch G, Boulahia A, Calderone S, Robinson AHN. The 'dropping' and 'horn-blower's' signs in evaluation of rotator-cuff tears. *J Bone Joint Surg Br* 1998;80:624–8.