

A study of arteriovenous crossing patterns in branch retinal vein occlusion

Nallamasa Rohit Goud,¹ G Badrinarayana,² Raja Ram Reddy,³ Arvind R,³ Ch. Jagan Mohan Rao

¹Postgraduate student, Department of Ophthalmology, ²Professor, Department of Ophthalmology,

³Assistant Professor, Department of Ophthalmology, ⁴Senior resident, Department of Ophthalmology, Prathima Institute of Medical Sciences, Karimnagar, Telangana, India.

Corresponding author: Dr. Nallamasa Rohit Goud, Postgraduate student, Department of Ophthalmology, Prathima Institute of Medical Sciences, Karimnagar, Telangana, India.

Email: drrohitgoud@gmail.com

ABSTRACT

Introduction: Branch retinal vein occlusion (BRVO) almost always occurs at an arteriovenous crossing, where the artery and vein share a common adventitial sheath.

Aim: The study was designed to evaluate the anatomic position of the crossing vessels at the site of occlusion in a case of BRVO.

Materials and Methods: A cross sectional descriptive study was conducted among 20 BRVO patients attending Ophthalmology outpatient department of a tertiary care hospital during the period of September 2013 to August 2014. A semi structured questionnaire was used to evaluate the sociodemographic characters and co-morbidity among the patients. The fundus of the patients were examined with 90D lens under slit lamp and the fundus photographs were taken.

Results: Twenty patients were considered in the study. Eleven were male and nine were female patients. Mean age of the male group was

50.09±4.94 years. Mean age of the female group was 49.33±3.77 years. In all, there were 21 eyes with branch retinal vein occlusion. Out of which 11 were left eyes, eight were right eyes and one patient was having occlusion in both the eyes. In BRVO cases, among 17(80.9%) eyes, the artery was anterior to the vein and in the remaining 4(19.1%) eyes the vein was anterior to the artery. No statistically significant difference was observed regarding the position of artery and vein in BRVO and control eyes (p=0.9). The superiotemporal occlusions were more in number 13 (61.9%) as compared to inferiotemporal occlusions in 8 (38.1%) eyes. A majority 17(85%) of patients were hypertensive.

Conclusion: In the present study the incidence of artery anterior to the vein was higher compare to vein anterior to the artery, the knowledge of which is useful to understand the patho-physiology and management of BRVO.

Key Words: Arteriovenous crossing patterns, Branch retinal vein occlusion.

Please cite this article as: Goud NR, Badrinarayana G, Raja Ram Reddy, Arvind R, Ch. Jagan Mohan Rao. A study of arteriovenous crossing patterns in branch retinal vein occlusion. Perspectives in medical research 2014; 2:15-18

Source of Support: Nil, Conflict of Interest: None Declared.

INTRODUCTION

Branch retinal vein occlusion (BRVO) is a common retinal vascular disorder of older age. Visual loss from a branch retinal vein occlusion is usually due to macular oedema, macular ischemia, or vitreous

haemorrhage. Both the sexes are affected equally, with the usual age of onset between 60 and 70 years.¹ Branch retinal vein occlusion almost always occurs at an arteriovenous crossing, where the artery and vein share a common adventitial sheath. The artery

nearly always lies anterior to the vein.² There are several risk factors documented for BRVO. As per Eye Disease Case Control Study, some of the important risk factors for the development of BRVO are systemic arterial hypertension, cardiovascular disease, increased body mass index (BMI) at 20 years of age and history of glaucoma.³ Histological examination revealed that BRVO is associated with arteriosclerotic changes in the retinal arterioles leading to thickening of artery which may compress the adjacent vein. This process may get aggravated at arteriovenous crossing sites as the two vessels are constrained within a common adventitial sheath. As the compression increases, venous blood flow velocity at the crossing site also gradually increases until local shear stress causes endothelial cell loss, thrombus formation, and vein occlusion. Superotemporal quadrant of the retina is the most common site of a BRVO. This may be due to a higher risk of occlusion in this area, or may be due to increased symptoms of a temporal versus a nasal occlusion. The most common site involved in temporal BRVOs is the superotemporal quadrant

(62%) and inferotemporal quadrant accounted for 38%.⁴ The study was designed to evaluate the anatomic position of the crossing vessels at the site of occlusion in a case of BRVO.

MATERIALS AND METHODS

A cross sectional descriptive study was conducted among 20 BRVO patients attending Ophthalmology outpatient department of a tertiary care hospital during the period of September 2013 to August 2014. The objectives of the study were explained and informed consent was taken from the patient. A semi structured questionnaire was used to evaluate the socio demographic characters and co – morbidity among the patients. Patients were examined for any anterior segment abnormalities with the help of slit lamp. Pupils were examined for reaction, when the pupillary reaction was normal; the eyes of patient were dilated with tropicamide eye drops. After 7 mm of dilatation the fundus of the patients were examined with 90D lens under slit lamp and the fundus photographs were taken.

RESULTS

Table 1 describes the baseline characteristics of the patients. The maximum number of cases of BRVO was seen in 46 – 50 years of age with male being 11 (55%). Mean age of the male group was 50.09±4.94 years and mean age of the female group was 49.33±3.77 years. The left eye was predominantly involved 11(55%) compared with right eye 8 (40%) and both eye involvement was observed in 1 case. Majority of the patients 17 (85%) were hypertensive in the studied sample.

Table 1: Baseline characteristics of the patients

	Variables	Frequency	%
Age	40-45	3	15
	46-50	8	40
	51-55	7	35
	56-60	2	10
Sex	Male	11	55
	Female	9	45
Involvement of eye	Left eye	11	55
	Right eye	8	40
	Both eyes	1	5
Hypertension Status	Hypertension	17	85
	No Hypertension	3	15
Total		20	100

Figure 1: Position of artery and vein at the site of occlusion in BRVO.

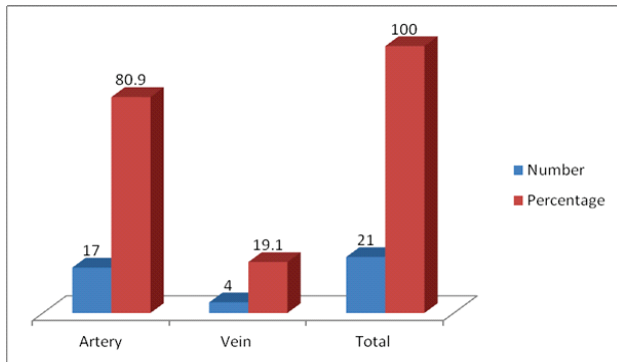
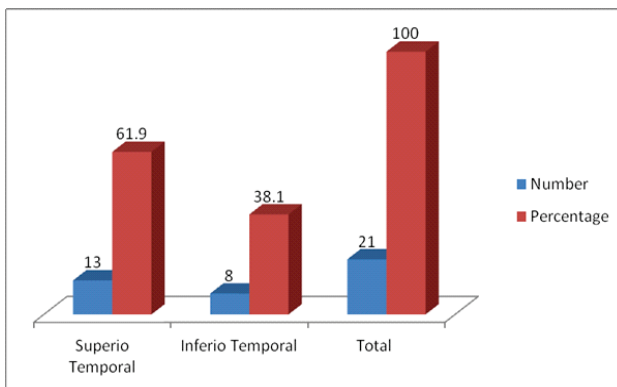


Figure 1 show that in 17 (80.9%) eyes the artery was anterior at the site of occlusion and in remaining 4(19.1%) eyes vein was anterior to the artery.

Figure 2: Quadrant of retina involved in BRVO



The above figure shows that the most common quadrant of retina involved in 21 eyes is superiotemporal, with 13(61.9%) eyes being involved and 8(38.1%) eyes showed inferiotemporal quadrant involvement with BRVO.

Table 2: Position of artery and vein in BRVO and control eye

Variables	Position		Total
	Artery anterior to vein	Vein anterior to artery	
BRVO eye	17	4	21
Control eye	15	4	19
Total	32	8	40

P=0.9

Table 2 revealed the position of artery and vein in BRVO eyes and control eyes (fellow eye). The artery was seen anterior to the vein in 17 cases of BRVO and 15 control eyes at the same site of occlusion, as seen in BRVO cases. Vein was seen anterior to the artery in 4

cases of BRVO and 4 control eyes, at the same site of occlusion as seen in BRVO cases. No statistically significant difference was observed regarding the position of artery and vein in comparison between BRVO eyes and control eyes.

DISCUSSION

The present study deals with the evaluation of arteriovenous crossing patterns in branch retinal vein occlusion among twenty cases attending ophthalmology department of a tertiary care hospital. In the present study the mean age of the male patients was 50.09±4.94 years and that of female group was 49.33±3.77 years. In a study conducted by Hamid et al, the mean age of the male group was 51.5 + 8 years and mean age of the female group was 49.4+ 8.5 years.⁵ Of the total BRVO cases, majority of eyes 17(80.9%) the artery was anterior to the vein. Our findings are consistent with the findings of Hamid et al, who obtained artery anterior to the vein among 96.9% of the cases.⁵ In a study conducted by Sekimoto et al, the arterial overcrossing was involved in 93% of the eyes whereas Zhao et al, observed a very high incidence (99% of eyes with BRVO), of the artery anterior to the vein.^{6,7} The position of vein in between the artery and the retina suggests a possible obstructive pathology in the genesis of BRVO the knowledge of which is useful for the management of BRVO. In the present study 85% of the patients were hypertensive. In a study conducted by Sekimoto et al, systemic hypertension was present in 41 out of total 63 patients.⁶ Hypertension is one of the most important modifiable risk factor for BRVO.

CONCLUSION

In the present study the incidence of artery anterior to the vein was higher compare to vein anterior to the artery, the knowledge of which is useful to understand the patho-physiology and management of BRVO.

REFERENCES

1. Michael G Morley, Jeffrey S. Heier, Myron Yanoff and Jay S Duker Ophthalmology, Third Edition. Elsevier Inc 2009; 601-04.
2. Duker JS, Brown GL. Anterior location of the crossing artery in branch retinal vein occlusion. Arch Ophthalmol 1989;107:429-41.

3. The Eye Disease Case-Control Study Group. Am J Ophthalmol. 1993; 116:286-296.
4. Daniel M Albert, MD, MS, Joan . Miller, MD, Dimitri T Azar, MD and Barbara A Blodi, MD. Albert & Jakobiec's Principles & Practice of Ophthalmology. 3rd Edition.
5. Hamid S, Mirza SA, Shokh I. Anatomic pattern of arteriovenous crossings in branch retinal vein occlusion. J Pak Med Assoc 2008 May;58(5):233-6.
6. Sekimoto M, Hayasaka S, Setogawa T. Type of arteriovenous crossing at site of branch retinal vein occlusion. Jpn J Ophthalmol 1992;36(2):192-6.
7. Zhao J, Sastry SM, Sperduto RD, Chew EY, Remaley NA. Arteriovenous crossing patterns in branch retinal vein occlusion. The Eye Disease Case-Control Study Group. Ophthalmology 1993 Mar;100(3):423-8.