

## Moya Moya disease

G Ashrith goud<sup>1</sup>, C Vikas<sup>2</sup>, T Ramesh<sup>3</sup>

<sup>1</sup>Postgraduate student, <sup>2</sup> Professor, <sup>3</sup>Professor and Head, Department of Radiology, Prathima Institute of Medical Sciences, Karimnagar, Telangana, India.

Address for correspondence: Dr. G.Ashrith goud, Postgraduate student, Department of Radiology, Prathima Institute of Medical Sciences, Karimnagar, Telangana, India.

Email: ashrith9966090545@gmail.com

### ABSTRACT

Moya Moya disease is an entity, which represents chronic idiopathic non-inflammatory progressive occlusion of circle of Willis, which in course of time leads to development of collateral vessels. It is more common in Japanese individuals.

This should be considered as a differential in young stroke. Here we present a case of 8-year-old young female with right hemiparesis and headache with a known history of seizure disorder.

**Keywords:** Moya Moya , puff of smoke, IVY sign

### INTRODUCTION

Moya Moya is a idiopathic, chronic progressive non-atherosclerotic vasoocclusive disease involving circle of Willis arteries predominantly supra clinoid Internal carotid artery with multiple collateral vessels maintaining flow. Moya Moya is a Japanese word representing puffy, hazy appearance, hence the “puff of smoke” appearance<sup>1</sup>. It is first reported in Japanese population in 1957<sup>2</sup>. It has bimodal age distribution: early childhood (two-thirds cases), middle age (one-third cases). Incidence among females is greater than that among males (1.8:1) with Japan having more prevalence than other Asian countries (0.35-2.0 cases per 100000, prevalence 3.16)<sup>3</sup>. 10% of cases showed family history<sup>4</sup>. Moya Moya syndrome has similar appearance to Moya Moya disease but is associated with other conditions like meningitis, head trauma, Neurofibromatosis I, Down syndrome.

### CASE REPORT

A 8 year old female child presented with history of sudden onset of right upper limb weakness with headache and photophobia. No history of fever, vomitings, trauma. She is a known case of seizure disorder. Laboratory investigations like CBP, CUE, homocysteine levels, sickle cell test, antinuclear antibody test shows no abnormality. A non-contrast MRI brain was done on Philips achieva 1.5T scanner. T1, T2, FLAIR, DWI/ADC maps were acquired. The findings included an area of acute infarct in left frontal region ( Fig 1 and Fig 2 ) with adjacent gliotic change.

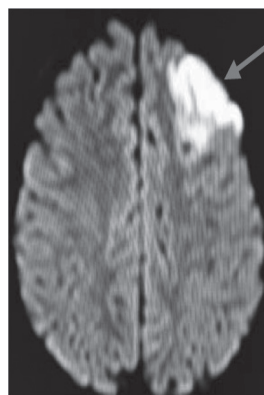


Fig 1. Axial DWI image

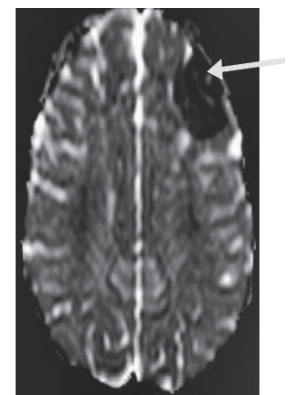


Fig 2. Axial ADC image

Fig 1 and Fig 2 showing area of acute infarct in left frontal region showing diffusion restriction (red arrow) and ADC suppression (yellow arrow)

Then a CT Cerebral angiogram with 128 slice Philips CT scanner was done with administration of 40ml contrast at flow rate of 4ml/sec. Findings included diffusely reduced caliber of bilateral internal carotid arteries with abrupt cut off of distal internal carotid arteries (post supraclinoid segment) with multiple enhancing lenticulostriate and thalamoperforator vascular channels on right side, giving appearance of puff of smoke [Fig 3 and Fig 4], maintaining flow in circle of Willis with one vessel joining left posterior cerebral artery suggesting chronic vasoocclusive changes, a feature of Moya Moya disease stage II.

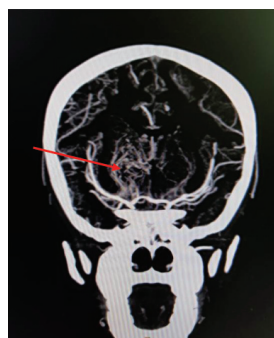

Fig 3. CT angiogram MIP coronal image

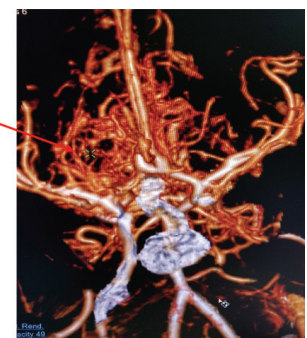
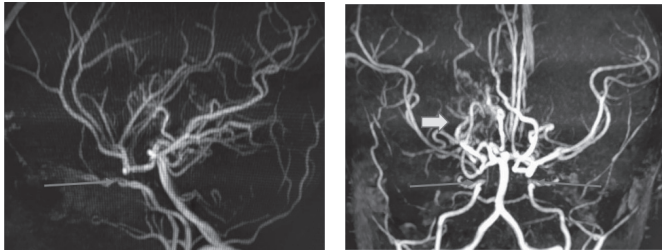


Fig 4. CT angiogram 3D volume rendered image

Fig 3 and 4 showing multiple vascular channels (red arrow) in right basal ganglia region representing lenticulostriate and Thalamoperforator vessels giving characteristic 'puff of smoke' appearance.

An MR angiogram was performed showing similar findings further confirming the diagnosis by clearly depicting the abrupt cut off of internal carotid arteries [Fig 5 and Fig 6].



**Fig 5.** MR angiogram sagittal MIP image

**Fig 6.** MR angiogram coronal MIP image

Fig 5 and 6 showing abrupt cut off of bilateral internal carotid arteries (red arrows) and collateral vessels in right basal ganglia (yellow arrow).

## DISCUSSION

Moya Moya is a non inflammatory chronic progressive occlusion of arteries of circle of Willis leading to the development of collateral vessels seen on cerebral angiography<sup>5</sup>. It has a bimodal age distribution with early childhood and middle age adults representing two-thirds and one-third cases with peaks at 4yrs and 4<sup>th</sup> decade respectively. Clinical presentation may be ischemic (more in children), epileptic or hemorrhagic (more in adults). Behavioral disturbances and cognitive dysfunction are uncommon symptoms and may occur based on the area of insult<sup>6</sup>.

Radiological imaging has an important role in diagnosing Moya Moya disease. CT angiography and MR angiography are good techniques for confirming the diagnosis. It can detect the stenosis or occlusion of internal carotid artery with multiple collateral vessels (pial collaterals, lenticulostriate, thalamoperforators, leptomeningeal vessels) with associated changes in brain like infarction and atrophy. Serpentine sulcal high signal intensity on MRI FLAIR representing IVY sign may be identified.

Conventional angiography is the gold standard to demonstrate Puff Of Smoke appearance.

Staging by Suzuki and Kodama is useful in categorizing the disease into 6 stages:

**Stage I** - "Narrowing of the carotid fork", narrowed ICA bifurcation

**Stage II** - "Initiation of the Moya Moya" - Dilated ACA, MCA and narrowed ICA bifurcation with Moya Moya change

**Stage III** - "Intensification of the Moya Moya" - further increase in Moya Moya change of the ICA bifurcation and narrowed ACA and MCA

**Stage IV** - "Minimization of the Moya Moya" - Moya Moya change reducing with occlusive changes in ICA and Tenuous ACA and MCA

**Stage V** - "Reduction of the Moya Moya" - further decrease in Moya Moya change with occlusion of ICA, ACA and MCA

**Stage VI** - "Disappearance of the Moya Moya" - ICA essentially disappeared with supply of brain from ECA

Early diagnosis and treatment during childhood is essential to prevent disability. Acute medical management includes symptomatic treatment directed towards controlling seizures, increasing cerebral blood flow<sup>7</sup>. Revascularization by bypass grafts from external carotid artery to MCA or superficial temporal artery to MCA is beneficial in ischemic cases<sup>8</sup>.

(ACA: anterior cerebral artery, MCA: middle cerebral artery, ICA: internal carotid artery, MRI: magnetic resonance imaging, CT: computed tomography, MIP: maximum intensity projection)

## REFERENCES

- [1] Suzuki J, Takaku A. Cerebrovascular "moya moya" disease. Disease showing abnormal net-like vessels in base of brain. *Arch Neurol* 1969;20:288-99.
- [2] Takeuchi K, Shimizu K. Hypogenesis of bilateral internal carotid arteries. *No To Shinkei* 1957;9:37-43
- [3] Wetjen NM, Garell PC, Stence NV, et al. Moya moya disease in the mid Western United States. *Neurosurg Focus* 1998; 5:e1.
- [4] Wakai K, Tamakoshi A, Ikezaki K, Fukui M, Kawamura T, Aoki R, et al. Epidemiological features of moya moya disease in Japan: Findings from a nationwide survey. *Clin Neurol Neurosurg* 1997;99 Suppl 2:S1-5.
- [5] Janda PH, Bellew JG, Veerappan V. Moya moya disease: case report and literature review. *J Am Osteopath Assoc* 2009 Oct; 109(10):547-53.
- [6] Eugeniusz Tarasów et al. Moya moya disease: Diagnostic imaging. *Pol J Radiol* 2011 Jan-Mar; 76(1): 73-79.
- [7] Khan N, Schuknecht B, Boltshauser E, et al. Moya moya disease and Moya moya syndrome: experience in Europe; choice of revascularization procedures. *Acta Neurochir (Wien)* 2003;145: 1061-71.
- [8] Smith ER, Scott RM. Surgical management of moyamoya syndrome. *Skull Base* 2005;15:15-26.

**How to cite this article :** Ashrith G, Vikas C, Ramesh T. Moya Moya disease. *Perspectives in Medical Research* 2018; 6(3):82-83.

**Sources of Support:** Nil, Conflict of interest: None declared