

# Coronavirus Disease-2019 Infection in Neonates of an Infected Pregnant Mother with Triplets

Zohreh Farsi<sup>1</sup>, Nima Taheriderakhsh<sup>2</sup>, Mandana Bassirnia<sup>3</sup>, Lida Ahmadi<sup>4</sup>, Mohammadreza Shiva<sup>5</sup>, Sedigheh Yousefzadegan<sup>6</sup>

1. Department of Neonatology, Tehran University of Medical Sciences, Arash Hospital, Tehran, Iran
2. Department of Intensive Care Medicine, Tehran University of Medical Sciences, Arash Hospital, Tehran, Iran
3. Department of Pediatrics, Tehran University of Medical Sciences, Arash Hospital, Tehran, Iran
4. Newborn Expert in Vice Chancellor for Treatment, Tehran University of Medical Sciences, Tehran, Iran
5. Department of Pediatric Nephrology, Tehran University of Medical Sciences, Arash Hospital, Tehran, Iran
6. Department of Pediatric Pulmonary Diseases, Iran University of Medical Sciences, Firoozabadi Hospital, Tehran, Iran

## ABSTRACT

**Background:** Coronavirus disease 2019 (COVID-19) infection is continuing its spread across the world with nearly 13 million people involvement by 11 July 2020. It mainly causes respiratory infection and affects different people in different ways. The COVID-19 infection involves many pregnant women worldwide, and maternal-fetal transmission of viral diseases is a major concern about this virus. However, its vertical transmission has to be proven in further studies.

**Case report:** This study presents a COVID-19-infected woman pregnant with triplets that underwent urgent cesarean section in a tertiary center of gynecology and neonatology. Subsequently, neonatal outcomes will be investigated in this study. All neonates were born with low Apgar scores and transferred to the neonatal intensive care unit (NICU) immediately after birth. Polymerase chain reaction (PCR) test of the second male neonate was positive on days 3 and 6; however, he was finally discharged from the hospital in a good condition. It is worth mentioning that the other two newborns died. All three neonates had white lung with an unfavorable response to treatment.

**Conclusion:** In this case study, we explain and discuss the probable COVID-19 infection in another two offsprings, elaborate on the mother's risk factors predisposing her to get involved with COVID-19 infection, and recommend some suggestions to avoid such complications.

**Keywords:** Covid-19 infection, Neonatal intensive care, Neonatal lung disease, Vertical transmission

## Introduction

Severe acute respiratory syndrome coronavirus 2 (SARS-CoV-2) also named COVID-19 became pandemic according to the World Health Organization announcement in 2020 march 11. The COVID-19 was started in Iran from 15 February up to now (July 11, 2020), affected more than 250000 people, and led to death in approximately 12500 persons (1). This infection mainly causes respiratory symptoms and sometimes leads to respiratory insufficiency and death. People infected with COVID-19 have had a wide range of symptoms ranging from mild ones to severe illness. These symptoms may appear 2-14 days after exposure to the virus (2). There

have been many reports of pregnant women involved with this virus recently from all around the world and Iran. Moreover, the maternal-fetal transmission of viral diseases is regarded as a major concern about this virus; however, its vertical transmission has not been approved yet (3-5).

## Case report

Herein, we present the offsprings of a COVID-19-infected woman pregnant with triplets. This 37-year-old female was fertilized by IVF and had hypothyroidism, gestational hypertension (HTN), and gestational diabetes mellitus (GDM) one

\* Corresponding author: Sedigheh Yousefzadegan, Department of Pediatric Pulmonary Diseases, Iran University of Medical Sciences, Firoozabadi Hospital, Tehran, Iran. Tel: 02151048; Email: dr.yousefzadegan@gmail.com

Please cite this paper as:

Farsi Z, Taheriderakhsh N, Bassirnia M, Ahmadi L, Shiva M, Yousefzadegan S. Coronavirus Disease-2019 Infection in Neonates of an Infected Pregnant Mother with Triplets. 2020 Sep; 11(3). DOI: [10.22038/ijn.2020.49218.1856](https://doi.org/10.22038/ijn.2020.49218.1856)

**Table 1.** Laboratory test results of all three neonates

	Gender	PH	WBC	LYMPH	HB	PLT	CRP	CPK	LDH	BG	PCR1	PCR2	PCR3
Neonate1	Female	7.23	8000	89%	15.1	181000	5	540	1640	B-	NEG	-	-
Neonate2	Male	7.25	8900	86%	15	229000	5.1	700	1970	B-	NEG	POS	POS
Neonate3	Female	7.21	14700	91%	17.5	241000	1	600	2269	O-	NEG	NEG	-

month before admission. Her socioeconomic condition was good, and she was treated with insulin, enoxaparin, and aspirin under the supervision of a gynecologist in Arash Hospital, Tehran, Iran.

She became febrile and myalgic three days before her delivery and had coughs. Her PCR test for COVID-19 was positive; therefore, according to Iran National Protocol for COVID-19 infection (6), she was treated with hydroxychloroquine and oseltamivir. Following that she became afebrile after three days. Eventually, she underwent a cesarean section in the 30<sup>th</sup> week of gestation due to decreased biophysical profile scores in two fetuses and evidence of placental insufficiency.

### The first neonate

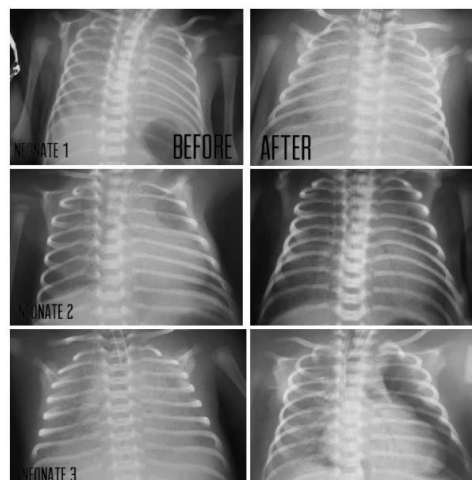
A 1320-gram female born with Apgar 4 (in the 1<sup>st</sup> min) that became 7 in the 5<sup>th</sup> min. Since her condition was deteriorating, she underwent resuscitation and intubation in the operation room, and she was transferred to the NICU immediately. She had white lungs; therefore, she got three doses of surfactant assuming to have respiratory distress syndrome (RDS). Despite the early relative response, her condition got worse, and she died after three days due to respiratory and gastrointestinal bleeding. Her COVID-19 PCR test was negative on day 3.

### The second neonate

A 1600-gram male born with Apgar 5 (in the 1<sup>st</sup> min) that became 7 in the 5<sup>th</sup> min. Immediately after birth, he was intubated and transferred to the NICU after resuscitation. He received two doses of surfactant. His COVID-19 PCR test was negative on day 3 and became positive on day 6. On 23<sup>th</sup> day, he had another positive PCR, and his white lungs responded a little to surfactant therapy. After 30 days of respiratory support and pneumonia treatment, the lungs became clear, and the PCR tests on days 30 and 31 were negative. Therefore, he discharged from the NICU in a good condition after 37 days.

### The third neonate

A 1200-gram female born with Apgar score 6 in the 1<sup>st</sup> min that became 7 in the 5<sup>th</sup> min. She was resuscitated in the operating room and



**Figure 1.** Images of neonates 1, 2, and 3. Left chest x-rays were taken at first and before receiving surfactant. Right chest x-rays were taken after surfactant showing unsatisfying response to therapy

transferred to the NICU. She had white lungs similar to the other two siblings, and she had a modest response to three doses of surfactant. She had generalized edema and anuria, and she died after 16 days as a result of abdominal distension and necrotizing enterocolitis. Her COVID-19 PCR test was negative on days 3 and 6. Table 1 summarizes the laboratory test results of the newborns, and their chest x-rays are depicted in Figure 1. It should be noted that the mother's blood group was B negative, and all PCR tests were performed on a nasopharyngeal swab specimen.

## Discussion

A neonatologist in the operating room resuscitated all the neonates immediately after birth. No neonates had asphyxia, which was confirmed by their primary arterial blood gas tests from their cord blood. Disorders of surfactant metabolism were not considered here since the second neonate remained alive in this study.

Given that the NICU in Arash Hospital affiliated to Tehran University of Medical Sciences, Tehran, Iran, is a tertiary center and neonatal survival rate at the gestational age of  $\geq 30$  weeks is 95% and above, the condition of these neonates was not reasonable for us.

A recent retrospective analysis on adults

showed that the sensitivity of Real-Time PCR is 71% for COVID-19 infection (7). According to the clinical signs of these cases and the lower probability of positive PCR tests in neonates, we concluded that vertical transfer of the virus may be possible and be the reason for severe sickness and white lung disorder in all of them.

Pregnant women with comorbidities may be at increased risk of severe illness (8). Therefore, it seems that the mother's risk factors, such as GDM, HTN, and triplet pregnancy, made her so vulnerable to get infected with the coronavirus.

According to two case series conducted on COVID-19-infected pregnant mothers, it was revealed that perinatal 2019-novel COVID infection might have adverse effects on newborns leading to fetal distress, premature labor, respiratory distress, thrombocytopenia, and even death. However, since the vertical transmission of this virus is not yet known (3, 4) and because of the possibility of vertical transfer to the fetus, it is important to be aware of mothers' condition in pregnancy. Moreover, they should be kept isolated during the epidemic time as much as possible.

## Conclusion

In this case study, we explain and discuss the probable COVID-19 infection in another two offsprings, elaborate on the mother's risk factors predisposing her to get involved with COVID-19 infection, and recommend some suggestions to avoid such complications.

## Acknowledgments

The authors thank all nurses working at the NICU in Arash Hospital, Tehran, Iran, who do their best for all newborns. Special thanks to all health care providers and laboratory experts who do

their best to fight against the novel coronavirus.

## Conflicts of interests

The authors declare that they have no conflict of interest regarding the publication of the study.

## References

1. World Health Organization. Coronavirus disease 2019 (COVID-19). Geneva: World Health Organization; 2020.
2. Jiang F, Deng L, Zhang L, Cai Y, Cheung CW, Xia Z. Review of the clinical characteristics of coronavirus disease 2019 (COVID-19). *J Gen Intern Med.* 2020; 35(5):1545-9.
3. Zhu H, Wang L, Fang C, Peng S, Zhang L, Chang G, et al. Clinical analysis of 10 neonates born to mothers with 2019-nCoV pneumonia. *Transl Pediatr.* 2020; 9(1):51-60.
4. Chen H, Guo J, Wang C, Luo F, Yu X, Zhang W, et al. Clinical characteristics and intrauterine vertical transmission potential of COVID-19 infection in nine pregnant women: a retrospective review of medical records. *Lancet.* 2020; 395(10226):809-15.
5. Schwartz DA. An analysis of 38 pregnant women with COVID-19, their newborn infants, and maternal-fetal transmission of SARS-CoV-2: maternal coronavirus infections and pregnancy outcomes. *Arch Pathol Lab Med.* 2020; 144(7):799-805.
6. Second edition of Iranian National Covid-19 diagnosis and treatment. Iranian Ministry of Health Care and Medical Education. Available at: URL: [http://treatment.sbm.ac.ir/uploads/2-3-covid-19\\_bastari.pdf](http://treatment.sbm.ac.ir/uploads/2-3-covid-19_bastari.pdf); 2020.
7. Fang Y, Zhang H, Xie J, Lin M, Ying L, Pang P, et al. Sensitivity of chest CT for COVID-19: comparison to RT-PCR. *Radiology.* 2020; 296(2):E115-7.
8. Novel coronavirus 2019 (COVID-19). The American College of Obstetricians and Gynecologists (ACOG) practice advisory. Available at: URL: <https://www.acog.org/clinical/clinical-guidance/practice-advisory/articles/2020/03/novel-coronavirus-2019>; 2020.