

Long-term Transcatheter Aortic Valve Durability

Giuliano Costa, Enrico Criscione, Denise Todaro, Corrado Tamburino and Marco Barbanti

Vittorio Emanuele Hospital, University of Catania, Catania, Italy

Abstract

Transcatheter aortic valve implantation (TAVI) has become the standard of care for high-risk and inoperable surgical patients and a valid alternative to surgery for low- and intermediate-risk patients with severe, symptomatic aortic stenosis. It is increasingly being used for younger, lower-risk patients, so it is important to ensure the durability for long-term transcatheter aortic valves. The lack of standard definitions of structural valve degeneration (SVD) had made comparison among studies on prosthetic valve durability problematic. The 2017 standardised definitions of SVD by the European Association of Percutaneous Cardiovascular Intervention, the European Society of Cardiology and the European Association for Cardio-Thoracic Surgery, and the 2018 definitions by the Valve In Valve International Data group, has generated an increased uniformity in evaluations. This article examines the potential mechanisms and rates of SVD of transcatheter bioprostheses and the role of redo TAVI as a treatment option.

Keywords

Bioprosthesis, degeneration, durability, structural valve dysfunction, transcatheter aortic valve implantation

Disclosure: MB is a consultant for Edwards Lifesciences. CT received speaker honoraria from Medtronic, Abbott Vascular, Edwards Lifesciences and Boston Scientific. All other authors have no conflicts of interest to declare.

Received: 27 January 2019 **Accepted:** 29 April 2019 **Citation:** *Interventional Cardiology Review* 2019;14(2):62–9. **DOI:** <https://doi.org/10.15420/icr.2019.4.2>

Correspondence: Marco Barbanti, Division of Cardiology, Policlinico – Vittorio Emanuele Hospital, University of Catania, Via Santa Sofia 78, 95123, Catania, Italy. E: mbarbanti83@gmail.com

Open Access: This work is open access under the CC-BY-NC 4.0 License which allows users to copy, redistribute and make derivative works for non-commercial purposes, provided the original work is cited correctly.

Aortic stenosis (AS) is one of the most common valvular diseases in developed countries and its prevalence is projected to increase over the next decade as the population ages.^{1,2} Transcatheter aortic valve implantation (TAVI) is an established alternative to surgery for treatment of patients with symptomatic, severe AS.³

As the latest multicentre trials have established the role of TAVI alongside surgery for treatment of lower-risk patients, it will be offered to younger people in the upcoming years.^{4,5} In this particular subset, life expectancy is expected to exceed that of the initial high-risk candidates for TAVI, which were older and had multiple, severe comorbidities. This makes it crucial to gather data on the durability of long-term transcatheter valve prosthesis.

The lack of standard definitions of structural valve degeneration (SVD) had made it difficult to compare studies on the durability of surgical or transcatheter bioprostheses due to the high heterogeneity of adopted criteria.^{6–11} Since the release of standardised SVD definitions by the European Association of Percutaneous Cardiovascular Intervention (EAPCI), the European Society of Cardiology (ESC) and the European Association for Cardio-Thoracic Surgery (EACTS), an increasing number of studies have reported encouraging outcomes after TAVI with either balloon- and self-expanding transcatheter aortic valves (TAV) up to 7 and 8 years. In cases of bioprosthesis failure due to SVD, redo TAVI has been shown to be a reliable alternative to redo surgery. This article will examine the emerging issue of TAV degeneration and its management.

Causes and Mechanisms of Bioprosthesis Degeneration

Bioprosthesis degeneration can be related to different aetiologies, including leaflet degeneration, endocarditis, thrombosis and paravalvular leak (*Table 1* and *Figure 1*).

Leaflet Degeneration

The main mechanism behind bioprosthesis degeneration is leaflet degeneration. This happens in a similar way as for the native aortic valve and consists in a step-wise process leading to tissue calcification and consequent valve stenosis or regurgitation.¹² Although TAVs demonstrated to degenerate in a manner comparable to surgical bioprostheses, three key differences between TAV and surgical aortic valve (SAV) degeneration mechanisms have been identified:¹³

- The presence of turbulence in the aortic root due to the combined presence of bulky calcium nodules in the sinuses of Valsalva and the prosthetic aortic valve. This may affect blood flow, resulting in chronic mechanical stresses on the prosthetic valve leaflets, leading to early degeneration.
- The trauma that may occur to prosthetic valve leaflets when loading into a delivery catheter before being established in its anatomical position.
- After deployment, TAVs, particularly the self-expanding ones, often have an oval shape which could affect the normal valvular functioning. Native aortic cusps calcifications, the conformation of the left ventricular outflow tract (usually non-circular) and prosthetic valve oversizing (for reducing paravalvular leakage)

lead TAVs to become non-circular, which could affect long-term durability, although the real impact is not known.¹⁴

Endocarditis

Infective endocarditis has been reported to occur in 0.5–3.4% of cases after TAVI and 1–6% after surgical aortic valve replacement (SAVR).^{13,15} The predominant agents reported to have caused prosthetic valve endocarditis were *Staphylococci* (31.5%), *Enterococci* (20%) and *Streptococci* (14%), based on 29 certain cases of endocarditis from about 4000 TAVI patients of a multicenter registry.¹⁵ Diagnosis of TAV endocarditis can be difficult as older patients may present with subtle and atypical symptoms.¹⁶ Endocarditis is shown with echocardiography as mobile vegetations, aortic root abscess formation, or progressive stenosis/regurgitation (due to prosthetic valve dehiscence). Intraprosthetic regurgitation occurring late after TAVI is suggestive of infective endocarditis, particularly when it is not associated with valve stenosis.¹³

Bioprosthesis Thrombosis

Bioprosthesis thrombosis has been reported in two different forms. First, as a symptomatic obstructive valve thrombosis, resulting in an increase in the transvalvular gradient and reduction in the effective orifice area measured by echocardiography, which is a rare event and reported in about 0.5% of TAVI patients.^{13,17} Second, as asymptomatic subclinical valve thrombosis causing thickening and reduced leaflet motion of bioprosthetic aortic valves detected by CT scan with normal transvalvular gradients at transthoracic ECG. This form is reported to be more frequent in patients treated percutaneously, ranging from 5% to 40% of TAVI patients.¹⁸ The incomplete expansion of a TAV's stent as well as its metallic nature seem to be two of the main factors increasing the risk of subclinical thrombosis.¹³

Paravalvular Leak

Paravalvular leak is mainly caused by the incomplete sealing of the prosthesis to the aortic annulus. Although this is more frequently an early finding, the importance of paravalvular regurgitation may become clinically evident later as it contributes to leaflet degeneration. Treatment mainly consists in re-intervention or percutaneous paravalvular leakage closure. Next-generation TAVs have incorporated additional features with the aim to prevent paravalvular regurgitation, such as the possibility to recapture and reposition the device and the implementation of an external sealing skirt in the inflow portion of the valve.

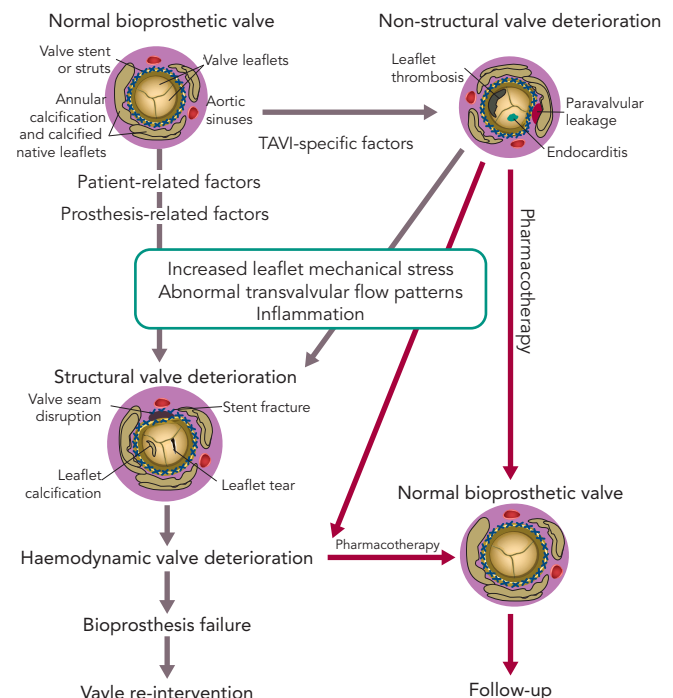
Definitions and Diagnosis of Structural Valve Degeneration

SVD in bioprosthesis has been poorly defined for a long time. Traditionally, it is considered an acquired intrinsic bioprosthetic valve abnormality characterised by the deterioration of the leaflets or supporting structures. One of the causes of SVD is the mechanical stress and the abnormal flow at the surface of the leaflet, which leads to tissue disruption or thickening, collagen fibre disruption and tissue calcification, but the precise mechanism is not known. Risk factors often associated with bioprosthetic SVD are younger age, mitral valve position, end-stage renal disease, higher calcium-phosphorus product, hyperparathyroidism, hypertension and pregnancy.^{19–22} Other clinical valve abnormalities that do not cause deterioration of valve tissue, are not included in the definition of SVD. These include patient-prosthesis mismatch, device malposition, paravalvular regurgitation and abnormal frame expansion in the case of self-

Table 1: Potential Factors in Bioprosthesis Degeneration

TAVI procedure-specific factors	<ul style="list-style-type: none"> • Leaflet injury (crimping/loading/dilatation) • Abnormal trans- and/or paravalvular flow patterns • Non-circular/irregular/incomplete stent deployment
Patient-related factors	<ul style="list-style-type: none"> • Dyslipidaemia, diabetes, metabolic syndrome • Dysregulation of phosphocalcic metabolism • Immune rejection • Hypertension
Bioprosthesis-related factors	<ul style="list-style-type: none"> • Absence of anti-mineralisation treatment • Flaws in bioprosthesis design • Severe prosthesis-patient mismatch • Small prosthesis size

Figure 1: Risk Factors, Mechanisms and Clinical Consequences of Transcatheter Aortic Valve Deterioration



This figure shows the interaction between patient-related, prosthesis-related and TAVI-specific factors in the pathogenesis of structural and non-structural valve deterioration. Red arrows indicate the potentially reversible pathway. Schematic representations of the transcatheter valves with structural or non-structural structural valve degeneration are adapted from Bagur et al.⁵⁵ TAVI = transcatheter aortic valve implantation.

expanding transcatheter bioprostheses.^{10,13,22} Prosthetic valve thrombosis and infective endocarditis are not included in the definition of SVD, but these complications may subsequently lead to SVD, even if treated successfully.^{17,23,24}

The lack of standard definitions for bioprosthesis dysfunction have affected the possibility of a proper comparison of durability studies. Most studies regarding surgical prosthesis have associated SVD with the need for reoperation, but did not provide any specific criteria to define SVD and/or the indication for reoperation. Furthermore, reoperation does not necessary imply presence of SVD as well as SVD does not always lead to reoperation, and older patients are often refused redo surgery because of their high or prohibitive surgical risk profile and their frailty.²⁵ With the worldwide increase in TAVI

Table 2: Current Standardised Definition of Structural Valve Degeneration

Capodanno et al. 2017 ²⁶		Dvir et al. 2018 ²⁷	
Not defined		SVD Stage 0: no significant change from immediate post-implantation	No significant new haemodynamic abnormality (all the following): <ul style="list-style-type: none"> • mean gradient <20 mmHg • intravalvular regurgitation less than moderate (<2+/4+) • no morphological leaflet abnormality, such as leaflet thickening)
Structural valve degeneration	Morphological SVD (any of the following): <ul style="list-style-type: none"> • Leaflet integrity abnormality (i.e. torn or flail causing intra-frame regurgitation) • Leaflet structure abnormality – pathological thickening and/or calcification causing valvular stenosis or central regurgitation • Leaflet function abnormality (i.e. impaired mobility resulting in stenosis and/or central regurgitation) • Strut/frame abnormality (i.e. fracture) 	SVD Stage 1: morphological leaflet abnormality without significant hemodynamic changes	Leaflet calcification, sclerosis, thickening or new leaflet motion disorder. The SVD definition excludes infective endocarditis, valve thrombosis, isolated patient-prosthesis mismatch without deterioration in valve function, isolated paravalvular regurgitation and frame distortion without abnormal leaflet function. Nevertheless, these conditions may account for Stage 1 SVD because these bioprostheses could be prone for early SVD.
	Moderate haemodynamic SVD (any of the following): <ul style="list-style-type: none"> • Mean transprosthetic gradient ≥20 mmHg and <40 mmHg • Mean transprosthetic gradient ≥10 mmHg and <20 mmHg change from baseline • Moderate intra-prosthetic aortic regurgitation, new or worsening (>1+/4+) from baseline 	SVD Stage 2S: moderate stenosis	<ul style="list-style-type: none"> • Mean transprosthetic gradient ≥20 mmHg and <40 mmHg • Mean transprosthetic gradient ≥10 and <20 mmHg change from baseline concomitant with decrease in EOA and DVI. <p>Need to clinically exclude thrombotic leaflet thickening. If reversible with anticoagulation should be considered as valve thrombosis.</p>
		SVD Stage 2R: moderate regurgitation	<ul style="list-style-type: none"> • AR ≥ 2+/4+ <p>If the main component is paravalvular, then it should not be considered as SVD.</p>
	Severe haemodynamic SVD (any of the following): <ul style="list-style-type: none"> • Mean transprosthetic gradient ≥ 40 mmHg • Mean transprosthetic gradient ≥20 mmHg change from baseline • Severe intra-prosthetic aortic regurgitation, new or worsening (>2+/4+) from baseline 	SVD Stage 3: severe stenosis and/or severe regurgitation	<ul style="list-style-type: none"> • Mean transprosthetic gradient ≥40 mmHg • Mean transprosthetic gradient ≥20 mmHg change from baseline • Severe intra-prosthetic aortic regurgitation, new or worsening (>2+/4+) from baseline concomitant with decrease in EOA and DVI.
Bioprosthetic valve failure	<ul style="list-style-type: none"> • Autopsy findings of bioprosthetic valve dysfunction, likely related to the cause of death, or valve-related death (i.e. any death caused by bioprosthetic valve dysfunction or sudden unexplained death following diagnosis of bioprosthetic valve dysfunction) • Repeat intervention (i.e. valve-in-valve TAVI, paravalvular leak closure or SAVR) following confirmed diagnosis of bioprosthetic valve dysfunction • Severe haemodynamic SVD 	Not defined	

AR = aortic regurgitation; DVI = Doppler velocity index; EOA = effective orifice area; SAVR = surgical aortic valve replacement; SVD = structural valve degeneration; TAVI = transcatheter aortic valve implantation.

procedures and the expansion of its indication to include younger, lower-risk patients, a clear definition of TAV durability and comparison with its surgical counterpart is needed.

In 2017, a taskforce of the EAPCI, ESC and EACTS released new standardised definitions of SVD and a new patient-oriented clinical endpoint named bioprosthetic valve failure (BVF), with the aim of

making possible future comparisons between studies on bioprostheses' long-term durability.²⁶ The taskforce characterised structural valve dysfunction as 'haemodynamic SVD' and/or 'morphological SVD'. Haemodynamic SVD is defined as the presence of permanent changes in valve function assessed by echocardiography, even without evidence of morphological SVD. There are two different degrees of haemodynamic SVD. Moderate is defined by the presence of a mean gradient

Table 3: Long-term Durability After Surgical Aortic Valve Replacement

Author	n	Prosthesis Type	Mean Follow-up (years)	SVD Requiring Reintervention, n (%)	Freedom from SVD, Years (%)
Repossini et al. 2016 ³²	565	Freedom SOLO (Sorin Group)	7 ±4	23 (4)	10 (90.8)
Johnston et al. 2015 ⁴⁸	12,569	Carpentier-Edwards PERIMOUNT (Edwards Lifesciences)	6	155 reoperated 268 SVD without reoperation (3.3)	NR
Bourguignon et al. 2015 ⁴⁹	2,758	Carpentier-Edwards PERIMOUNT	6.7 ±4.8	123 reoperated 34 SVD without reoperation	15 (78.6 ± 2.2) 20 (48.5 ± 4.6)
Guenzinger et al. 2015 ⁵⁰	455	Biocor (St Jude Medical)	8 ±6	37 (8.1) 13 were inoperable or refused surgery	5 (97.9 ± 0.8) 10 (92.1 ± 1.7) 15 (84.8 ± 3.0) 20 (67.0 ± 7.3)
Bourguignon et al. 2015 ⁵⁵	373	Carpentier-Edwards PERIMOUNT	9 ±6	78 (20)	10 (86.8 ± 2.5) 15 (66.8 ± 4.2) 20 (37.2 ± 5.4)
Christ et al. 2015 ²⁹	50	Toronto (St Jude Medical)	14 ±6	24 (48)	5 (97.7 ± 2.2) 10 (76.0 ± 6.7) 15 (44.1 ± 8.9)
Bach and Kon 2014 ³¹	725	Freestyle (Medtronic)	8	34 (4.6)	10 (96.4 ± 1.4) 15 (85.1 ± 4.9)
Sénage et al. 2014 ²⁵	617	Mitroflow (Sorin)	3.8 ±2.0	4 (10.3); 35 SVD without reoperation	5 (91.6)
Forcillo et al. 2013 ³⁴	2,405	Carpentier-Edwards	6 ±9	91 (3.7) 2 refused redo surgery	5 (98.0 ± 0.2) 10 (96 ± 1) 20 (67 ± 4)
Mohammadi et al. 2012 ⁵¹	430	Freestyle	9.1 ±4.4	27	<60 years 10 (94) 15 (62.6) ≥60 years 10 (96.3) 15 (88.4)
David et al. 2010 ³³	1,134	Hancock II (Medtronic)	12	87 (7.6) 13 were inoperable	5 (99.7 ± 0.2) 10 (97.6 ± 0.6) 15 (86.6 ± 1.8) 20 (63.4 ± 4.2)
Mykén and Bech-Hansen 2009 ⁵²	1,518	Biocor	6 ±5	77 (5)	20 (61.1 ± 8.5)
Yankah et al. 2008 ⁵³	1513	Mitroflow	4 ±0.12	64 (4.2)	20 (62.3 ± 5.0)
David et al. 2007 ³⁰	357	Toronto	8 ±3	49 (13.7) 4 were inoperable	10 (86 ± 3) 12 (69 ± 4)
Jamieson et al. 2005 ⁵⁴	1823	Carpentier-Edwards SAV	8 ±5	132 (7.2)	15 (74.9 ± 2.3) 18 (64.0 ± 3.6)

SAV = surgical aortic valve; SVD = structural valve degeneration.

≥20 mmHg and <40 mmHg and/or ≥10 mmHg and <20 mmHg change from gradient at baseline (valuated before discharge or within 30 days of valve implantation) and/or the onset of moderate, new or worsening (>1+/4+) of intra-prosthetic valve regurgitation; severe, with mean gradient ≥40 mmHg and/or ≥20 mmHg change from baseline and/or severe, new or worsening (>2+/4+) intra-prosthetic aortic regurgitation. Morphological SVD includes abnormalities in leaflet integrity, structure, function and strut/frame. The diagnosis is based on imaging or autopsy findings. BVF definition integrates severe haemodynamic SVD and its clinical consequences. It is important to stress that BVF could be a consequence of pathophysiological processes unrelated to SVD, such as thrombosis, endocarditis or non-structural valve dysfunction. BVF includes any of the following (Table 2):

- Bioprosthetic valve dysfunction at autopsy, very likely related to the cause of death, or 'valve-related death', defined as any death

caused by bioprosthetic valve dysfunction in the absence of confirmatory autopsy.

- Aortic valve reintervention (i.e. valve-in-valve TAVI, paravalvular leak closure or SAVR).
- Severe hemodynamic SVD.

In 2018, the Valve In Valve International Data (VIVID) group proposed a definition of SVD which emphasises the progressive character of bioprosthetic valve degeneration, similar to that of the native valve, and provided recommendations for timing of clinical and imaging assessment at follow-up.²⁷ The first stage (Stage 1) is defined as early morphological leaflet changes without haemodynamic sequelae, such as leaflet fluttering and leaflet thickening, and limited, delayed or asymmetrical leaflet opening or closure. Valves with definite morphological abnormalities are classified as Stage 1 SVD even if the abnormality is corrected, such as leaflet thickening relieved

Table 4: Long-term Durability After Transcatheter Aortic Valve Implantation Using EAPCI/ESC/EACTS Definitions

Author	n	Prosthesis Type	Mean Follow-up (Years)	Freedom from SVD (%)	Bioprosthetic Valve Failure, n (%)
Deutsch et al. 2018 ³⁸	300	CoreValve (Medtronic) and SAPIEN (Edwards)	7.14	1 year: 90.1 3 years: 83.9 5 years: 82.0 7 years: 77.3	11 4 reoperation
Eltchaninoff et al. 2018 ³⁹	378	Percutaneous Valve Technologies, Cribier-Edwards, SAPIEN and SAPIEN XT	3.1	8 years: 87.2	2 (0.58 8 years, all reoperated)
Barbanti et al. 2018 ⁴⁰	288	Medtronic CoreValve and SAPIEN XT	6.7	8 years: 97.5 (severe SVD)	11 (8 years estimated: 4.51) Two reoperated
Holy et al. 2018 ⁴²	152	CoreValve	6.3 ± 1.0	NR	8 years estimated: 4.5% Five reoperated
Antonazzo et al. 2018 ⁴¹	278	CoreValve	6.8	NR	5 (3.1) + 2 probable bioprosthetic valve failure 3 reoperated
Didier et al. 2018 ⁴³	4,201	CoreValve and SAPIEN and SAPIEN XT	5	<ul style="list-style-type: none"> Moderate SVD: 12.4% between 4 and 5 years Severe SVD: 2.9% between 4 and 5 years 	

SVD = structural valve degeneration.

with anticoagulation, because these leaflets might still be prone to recurrent leaflet thickening or accelerated SVD, requiring more frequent follow-up. Stage 2 SVD refers to morphological abnormalities of valve leaflets associated with haemodynamic dysfunction. This stage is divided into Stage 2S and Stage 2R, depending on the kind of dysfunction, stenosis or regurgitation respectively, because the clinical implications and pace of deterioration are likely to differ between these two failure modes. Stage 2S can be determined by the mandatory presence of an increase of transvalvular gradient (≥ 10 mmHg) and a concomitant decrease in valvular area. In this way, the presence of abnormal leaflet morphology and deterioration in valve haemodynamic must coexist to define SVD. Furthermore, bioprosthetic valves with a combination of moderate stenosis and moderate regurgitation may be considered differently than those with isolated stenosis or regurgitation.²⁸ VIVID definition categorises these mixed moderate stenosis/regurgitation valves at Stage 2RS. Patients in stage 2 could be considered for reintervention in case of symptoms' onset. The most severe stage of SVD is the development of severe stenosis or regurgitation (stage 3). Reintervention is recommended when patients with stage 3 bioprosthesis SVD start to develop symptoms (Table 2).

Bioprostheses Durability Data

Long-term durability is one of the main limitations of surgical bioprostheses, compared with their mechanical counterparts. Several studies have reported encouraging data on valve performance during the first decade after valve implantation, with rates of freedom from SVD >85% at 10 years.²⁹⁻³³ Data on surgical bioprostheses durability at 20 years are limited. Two studies reported results about durability of the Carpentier-Edwards Perimount pericardial bioprostheses (Edwards Lifesciences) at 20 years. Forcillo et al. reported 67% rate of freedom from reoperation at 20 years, whereas Bourguignon et al. reported a rate of freedom from SVD of 48.5%.^{34,35} Unfortunately, the lack of standard definitions for valve dysfunction affects any comparison between different studies (Table 3).

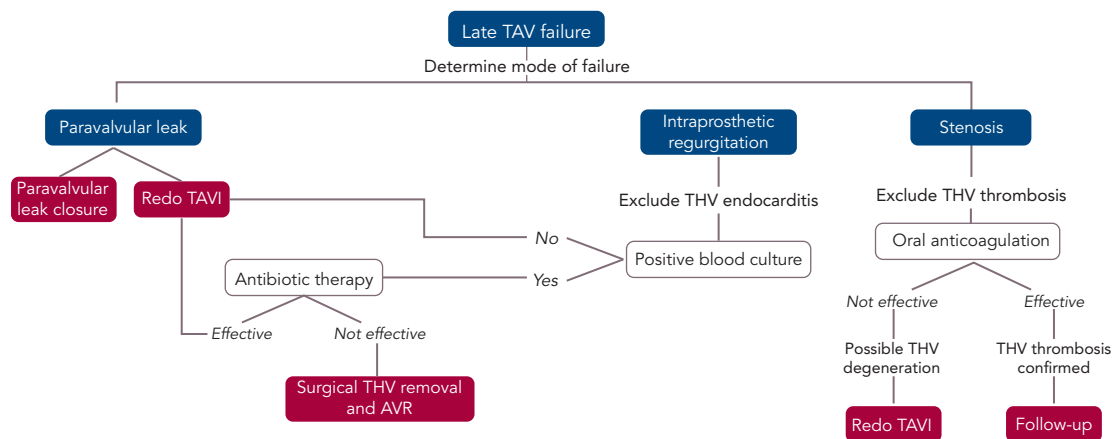
It is well known that transcatheter aortic valves can degenerate in a manner similar to surgical bioprostheses, but durability of TAVs could be shorter than their surgical counterpart because of the possible

trauma that can occur during initial valve preparation and compression, balloon dilatation or as a suboptimal leaflet coaptation, leaflet folding or leaflet-frame contact due to asymmetrical frame expansion.¹⁴

Several limitations prevent robust evaluation of TAV's durability. Firstly, TAVI is a relatively young technology as its wider adoption started when it gained its CE mark in 2007 and US Food and Drug Administration approval in 2011. This means there can be little data on valve durability analysis beyond 10 years. Secondly, current data on long-term outcomes over 5 years refers to the first-generation TAVs, which were implanted by relatively inexperienced operators and suffered from higher valve malpositioning rates and sizing problems. Finally, the major limitation of long-term durability evaluation is the older age of TAVI population, which is affected by multiple comorbidities and usually have high-risk profiles conditioning a limited life expectancy and therefore a paucity of patients (usually <50% of the initial population) available at long-term follow-up.

In the past few years the results of several TAVI studies with more than 5 years of follow-up data have been published. The Placement of AoRTic TraNscatheter Valve Trial (PARTNER-1) trial showed no evidence of SVD at 5-year follow-up.^{8,36} Moreover, the PARTNER-1A substudy demonstrated similar echocardiographic valve performance of TAVs and SAVs, with a mean transvalvular gradient of 10.7 and 10.6 mmHg, and an aortic valve area of 1.6 and 1.5cm², respectively.^{8,37} This evaluation confirmed the satisfactory haemodynamic profile of transcatheter aortic valves up to 5 years post-implantation, even if moderate or severe aortic regurgitation caused by paravalvular regurgitation – which is not included in the SVD definition – was shown to be more common in the TAVI group. Toggweiler et al. showed a 3.4% incidence of SVD at a 5-year follow-up in a cohort of 88 patients who had received a balloon-expandable SAPIEN TAV (Edwards Lifesciences).⁶ Moderate aortic regurgitation, stenosis, or a combination of the two occurred in one patient each, and no patients required reintervention. Our group reported a 5-year experience with the CoreValve system (Medtronic) and found five cases (1.4%) of SVD, with two patients requiring reintervention (valve-in-valve) because symptoms developed 4 and 4.6 years after TAVI.⁷ Furthermore, 10 patients (2.8%) showed late mild stenosis, with a mean transaortic gradient ranging from 20 to 40 mmHg.⁷

Figure 2: Late Transcatheter Aortic Valve Failure Management



AVR = aortic valve replacement; PVL = paravalvular leak; TAVI = transcatheter aortic valve; TAVI = transcatheter aortic valve implantation; THV = transcatheter heart valve.

After the introduction of EAPCI/ESC/EACTS standardised criteria of SVD in 2017, an increasing number of studies have been reporting outcomes after TAVI with either the SAPIEN (Edwards Lifesciences) or CoreValve TAVs up to 7 and 8 years (Table 4).^{38–41} Three single-centre studies demonstrated stable trans-prosthetic gradients over time and a rate of severe TAV dysfunction of 2.4%, 3.2% and 3.6%.^{39–41} Holy et al. analysed long-term outcomes of 152 consecutive patients who had undergone TAVI with the self-expanding CoreValve between 2007 and 2011.⁴² Echocardiographic follow-up was achieved at 6.3 ± 1.0 years (5.0–8.9 years) and was 88% complete (60 of the 68 participants who survived beyond 5 years). No case of SVD was reported and five patients (3.3%) had undergone redo TAVI or surgery due to paravalvular leakage. An analysis by Deutsch et al. showed an overall crude cumulative incidence of SVD of 14.9% at 7 years after TAVI (CoreValve 11.8% versus SAPIEN 22.6%; $p=0.01$).³⁸

Reports from national registries confirm low rates of TAV dysfunction at long-term follow-up. Data from the French Aortic National CoreValve and Edwards (FRANCE-2) registry showed an incidence of severe and moderate/severe SVD of 2.5% and 13.3%, respectively, in surviving patients at 5 years from the procedure, while Blackman et al. reported an incidence of severe and moderate SVD of 0.4% and 8.7% respectively up to 10 years in the UK TAVI Registry.^{43,44} Finally, a recent analysis from the Nordic Aortic Valve Intervention (NOTION) trial reported lower rates of moderate-to-severe SVD after TAVI compared with surgery (24% versus 4.8% for TAVI and SAVR respectively), whereas there was no difference in terms of BVF (6.7% versus 7.5% for TAVI and SAVR respectively).⁴⁵

Structural TAV Dysfunction Management

Management of older people with TAV failure is similar to that of surgical bioprosthesis dysfunction. Any decision about the appropriate approach should be guided by a careful clinical assessment and surgical risk evaluation by a heart team. Management options include medical therapy and reintervention with TAVI or SAVR. Understanding the causal mechanism of TAV degeneration is essential as treatment varies (Figure 2).

Intra-prosthetic regurgitation occurring late after TAVI suggests infective endocarditis, particularly when not associated with stenosis.¹³ In this case, targeted antibiotic therapy represents the first line of treatment. In patients presenting with severe

aortic regurgitation, transcatheter heart valve retrieval and SAVR should be considered. Redo TAVI is an alternative in those patients in which infection has been controlled and blood cultures are negative.¹⁴

In patients with suspected bioprosthesis thrombosis, oral anticoagulation is the treatment of choice both in patients with clear evidence of thrombosis and in those with high transvalvular gradient with evidence of reduced leaflet motion. This therapeutic approach is often sufficient to restore transvalvular gradient and leaflet mobility.¹⁷ Vitamin K antagonists are the most used anticoagulants but novel oral anticoagulation therapy has also been shown to be effective.⁴⁶ In obstructive TAV thrombosis, anticoagulation has been shown to normalise transvalvular gradients in 2–3 months and patients should have lifelong follow up with interval imaging.¹⁷ SAVR should be considered for patients with worsening valve function despite oral anticoagulation therapy. The observation of valve thrombosis has raised the question of treatment necessity with oral anticoagulation for a certain period after TAVI to prevent leaflet thrombosis, but the debate is still ongoing.

Redo TAVI is another option in the management of TAV failure. This strategy has been demonstrated to be safe and it is associated with favourable clinical and echocardiographic outcomes.⁴⁷ When a balloon-expandable TAV fails, implantation of a second same-sized balloon-expandable TAV is the most commonly used approach.⁴⁷ On the other hand, a supra-annular TAV may be preferable in cases of small native annulus due to the possibility of a high residual transvalvular gradient. Redo TAVI strategy has several advantages:

- It is safe, with lower risk of periprocedural complications compared with redo SAVR, which is technically challenging and carries a higher risk of mortality and morbidity than the first valve procedure.¹²
- The presence of the first device represents a fluoroscopic marker for the landing zone, indicating second TAV sizing and facilitating deployment.

Despite its advantages, there are two main concerns associated with redo TAVI: the lack of data on the long-term performance of valve-in-valve implantation; and the access to coronary arteries, especially in the case of a second self-expanding CoreValve device implantation

when a double layer of close cell metallic frame would face the coronary ostia.

When the mechanism of TAV failure is paravalvular regurgitation, there are two possible scenarios: the paravalvular regurgitation is mainly caused by valve implantation that is too high or too low; or it is secondary to incomplete frame expansion or suboptimal sealing because of severe annular calcification. In this latter case, balloon post-dilatation could represent an alternative, although it may cause annular injury when large-diameter balloons are used. However, for either scenario, potential treatments could be represented by a redo TAVI procedure using any TAV type in the proper position (in the case of high or low implant), or a second TAV with higher radial force – SAPIEN or Lotus (Boston Scientific) – if greater expansion and

sealing are required. In addition, paravalvular regurgitation closure with dedicated devices (plugs) has been demonstrated to be a feasible and safe alternative.

Conclusion

With the expansion of TAVI indication to younger, lower-risk patients, SVD up to eight years after TAVI showed very low rates of TAV degeneration, comparing favourably with its surgical counterpart. The release of standardised definitions of SVD represents a fundamental step in allowing data comparison from different centres, with the aim of obtaining a better insight into its real incidence. Evidence suggests that redo TAVI seems to be a feasible and safer alternative to surgery for treatment of bioprostheses failure. ■

- Nkomo VT, Gardin JM, Skelton TN, et al. Burden of valvular heart diseases: a population-based study. *Lancet* 2006;368:1005–11. [https://doi.org/10.1016/S0140-6736\(06\)9208-8](https://doi.org/10.1016/S0140-6736(06)9208-8); PMID: 16980116.
- Otto CM, Prendergast B. Aortic-valve stenosis – from patients at risk to severe valve obstruction. *N Engl J Med* 2014;371:744–56. <https://doi.org/10.1056/NEJMra1313875>; PMID: 25140960.
- Baumgartner H, Falk V, Bax JJ, et al. 2017 ESC/EACTS guidelines for the management of valvular heart disease. *Eur Heart J* 2017;38:2739–86. <https://doi.org/10.1093/eurheartj/ehx391>; PMID: 28886619.
- Popma JJ, Deeb GM, Yakubov SJ, et al. Transcatheter aortic-valve replacement with a self-expanding valve in low-risk patients. *N Engl J Med* 2019; [Epub ahead of print]. <https://doi.org/10.1056/NEJMoa1816885>; PMID: 30883053.
- Mack MJ, Leon MB, Thourani VH, et al. Transcatheter aortic-valve replacement with a balloon-expandable valve in low-risk patients. *N Engl J Med* 2019; [Epub ahead of print]. <https://doi.org/10.1056/NEJMoa1814052>; PMID: 30883058; epub ahead of press.
- Toggweiler S, Humphries KH, Lee M, et al. 5-year outcome after transcatheter aortic valve implantation. *J Am Coll Cardiol* 2013;61:413–9. <https://doi.org/10.1016/j.jacc.2012.11.010>; PMID: 23265333.
- Barbanti M, Petronio AS, Ertori F, et al. 5-Year outcomes after transcatheter aortic valve implantation with corevalve prosthesis. *JACC Cardiovasc Interv* 2015;8:1084–91. <https://doi.org/10.1016/j.jcin.2015.03.024>; PMID: 26117458.
- Mack MJ, Leon MB, Smith CR, et al. 5-year outcomes of transcatheter aortic valve replacement or surgical aortic valve replacement for high surgical risk patients with aortic stenosis (PARTNER 1): a randomised controlled trial. *Lancet* 2015;385:2477–84. [https://doi.org/10.1016/S0140-6736\(15\)60308-7](https://doi.org/10.1016/S0140-6736(15)60308-7); PMID: 25788234.
- Muratori M, Fusini L, Tamborini G, et al. Five-year echocardiographic follow-up after TAVI: structural and functional changes of a balloon-expandable prosthetic aortic valve. *Eur Hear J Cardiovasc Imaging* 2018;19:389–97. <https://doi.org/10.1093/ehjci/jex046>; PMID: 28379513.
- Arsalan M, Walther T. Durability of prostheses for transcatheter aortic valve implantation. *Nat Rev Cardiol* 2016;13:360–7. <https://doi.org/10.1038/nrcardio.2016.43>; PMID: 27053461.
- Del Trigo M, Mu-oz-Garcia AJ, Wijeyesundera HC, et al. Incidence, timing, and predictors of valve hemodynamic deterioration after transcatheter aortic valve replacement. *J Am Coll Cardiol* 2016;67:644–55. <https://doi.org/10.1016/j.jacc.2015.10.097>; PMID: 26868689.
- Dvir D, Barbanti M, Tan J, Webb JG. Transcatheter aortic valve-in-valve implantation for patients with degenerative surgical bioprosthetic valves. *Curr Probl Cardiol* 2014;39:7–27. <https://doi.org/10.1016/j.cpcardiol.2013.10.001>; PMID: 24331437.
- Mylotte D, Andalib A, Theriault-Lauzier P, et al. Transcatheter heart valve failure: a systematic review. *Eur Heart J* 2015;36:1306–27. <https://doi.org/10.1093/eurheartj/ehu388>; PMID: 25265974.
- Barbanti M, Tamburino C. Late degeneration of transcatheter aortic valves: pathogenesis and management. *EuroIntervention* 2016;12:Y33–6. <https://doi.org/10.4244/EUIV12SYA8>; PMID: 27640028.
- Latib A, Naim C, De Bonis M, et al. TAVR-associated prosthetic valve infective endocarditis. *J Am Coll Cardiol* 2014;64:2176–8. <https://doi.org/10.1016/j.jacc.2014.09.021>; PMID: 25457406.
- Habib G, Hoen B, Tornos P, et al. Guidelines on the prevention, diagnosis, and treatment of infective endocarditis (new version 2009): The task force on the prevention, diagnosis, and treatment of infective endocarditis of the European society of cardiology (ESC). *Eur Heart J* 2009;30:2369–413. <https://doi.org/10.1093/eurheartj/ehp285>; PMID: 19713420.
- Latib A, Naganuma T, Abdel-Wahab M, et al. Treatment and clinical outcomes of transcatheter heart valve thrombosis. *Circ Cardiovasc Interv* 2015;8:piv01779. <https://doi.org/10.1161/CIRCINTERVENTIONS.114.001779>; PMID: 25873727.
- Kanjanathai S, Pirelli L, Nalluri N, Klinger CA. Subclinical leaflet thrombosis following transcatheter aortic valve replacement. *J Interv Cardiol* 2018;31:640–7. <https://doi.org/10.1111/joic.12521>; PMID: 29790209.
- Ruel M. Late incidence and determinants of reoperation in patients with prosthetic heart valves. *Eur J Cardio-Thorac Surg* 2004;25:364–70. <https://doi.org/10.1016/j.ejcts.2003.12.013>; PMID: 15019662.
- Mahjoub H, Mathieu P, Larose E, et al. Determinants of aortic bioprosthetic valve calcification assessed by multidetector CT. *Heart* 2015;101:472–7. <https://doi.org/10.1136/heartjnl-2014-306445>; PMID: 25618481.
- Schoen FJ, Levy RJ. Calcification of tissue heart valve substitutes: progress toward understanding and prevention. *Ann Thorac Surg* 2005;79:1072–80. <https://doi.org/10.1016/j.athoracsur.2004.06.033>; PMID: 15734452.
- Demir OM, Ruparella N, Frame A, et al. Management of failing bioprostheses in elderly patients who have undergone transcatheter aortic valve replacement. *Expert Rev Med Devices* 2017;14:763–71. <https://doi.org/10.1080/17434440.2017.1376651>; PMID: 28885112.
- Makkar RR, Fontana G, Jilali H, et al. Possible subclinical leaflet thrombosis in bioprosthetic aortic valves. *N Engl J Med* 2015;373:2015–24. <https://doi.org/10.1056/NEJMoa1509233>; PMID: 26436963.
- Chakravarty T, Sondergaard L, Friedman J, et al. Subclinical leaflet thrombosis in surgical and transcatheter bioprosthetic aortic valves: an observational study. *Lancet* 2017;389:2383–92. [https://doi.org/10.1016/S0140-6736\(17\)30757-2](https://doi.org/10.1016/S0140-6736(17)30757-2); PMID: 28330690.
- Sénage T, Le Tourneau T, Foucher Y, et al. Early structural valve deterioration of mitroflow aortic bioprosthesis. *Circulation* 2014;130:2012–20. <https://doi.org/10.1161/CIRCULATIONAHA.114.010400>; PMID: 25355912.
- Capodanno D, Petronio AS, Prendergast B, et al. Standardized definitions of structural deterioration and valve failure in assessing long-term durability of transcatheter and surgical aortic bioprosthetic valves: a consensus statement from the European Association of Percutaneous Cardiovascular Interventions. *Eur Heart J* 2017;38:3382–90. <https://doi.org/10.1093/eurheartj/ehx303>; PMID: 29020344.
- Dvir D, Bourguignon T, Otto CM, et al. Standardized definition of structural valve degeneration for surgical and transcatheter bioprosthetic aortic valves. *Circulation* 2018;137:388–99. <https://doi.org/10.1161/CIRCULATIONAHA.117.030729>; PMID: 29358344.
- Zilberszac R, Gabriel H, Schemper M, et al. Outcome of combined stenotic and regurgitant aortic valve disease. *J Am Coll Cardiol* 2013;61:1489–95. <https://doi.org/10.1016/j.jacc.2012.11.070>; PMID: 23500223.
- Christ T, Claus B, Borck R, et al. The St. Jude Toronto stentless bioprosthesis: up to 20 years follow-up in younger patients. *Heart Surg Forum* 2015;18:129. <https://doi.org/10.1532/hst.1252>; PMID: 26334847.
- David TE, Feindel CM, Bos J, et al. Aortic valve replacement with Toronto SPV bioprosthesis: optimal patient survival but suboptimal valve durability. *J Thorac Cardiovasc Surg* 2008;135:19–24. <https://doi.org/10.1016/j.jtcvs.2007.04.068>; PMID: 18179912.
- Bach DS, Kon ND. Long-term clinical outcomes 15 years after aortic valve replacement with the freestyle stentless aortic bioprosthesis. *Ann Thorac Surg* 2014;97:544–51. <https://doi.org/10.1016/j.athoracsur.2013.08.047>; PMID: 24140209.
- Repossini A, Fischlein T, Santarpino G, et al. Pericardial stentless valve for aortic valve replacement: long-term results. *Ann Thorac Surg* 2016;102:1956–65. <https://doi.org/10.1016/j.athoracsur.2016.05.080>; PMID: 27544291.
- David TE, Armstrong S, Maganti M. Hancock II bioprosthesis for aortic valve replacement: the gold standard of bioprosthetic valves durability? *Ann Thorac Surg* 2010;90:775–81. <https://doi.org/10.1016/j.athoracsur.2010.05.034>; PMID: 20732495.
- Forcillo J, Pellerin M, Perrault LP, et al. Carpentier-Edwards pericardial valve in the aortic position: 25-years experience. *Ann Thorac Surg* 2013;96:486–93. <https://doi.org/10.1016/j.athoracsur.2013.03.032>; PMID: 23684486.
- Bourguignon T, El Khoury R, Candolfi P, et al. Very long-term outcomes of the Carpentier-Edwards perimount aortic valve in patients aged 60 or younger. *JACC Cardiovasc Imaging* 2015;100:853–9. <https://doi.org/10.1016/j.athoracsur.2015.03.105>; PMID: 26187706.
- Kapadia SR, Leon MB, Makkar RR, et al. 5-year outcomes of transcatheter aortic valve replacement compared with standard treatment for patients with inoperable aortic stenosis (PARTNER 1): a randomised controlled trial. *Lancet* 2015;385:2485–91. [https://doi.org/10.1016/S0140-6736\(15\)60290-2](https://doi.org/10.1016/S0140-6736(15)60290-2); PMID: 25788231.
- Daubert MA, Weissman NJ, Hahn RT, et al. Long-term valve performance of TAVR and SAVR. *JACC Cardiovasc Imaging* 2017;10:15–25. <https://doi.org/10.1016/j.jcmg.2016.11.004>; PMID: 28107714.
- Deutsch M-A, Erlebach M, Burri M, et al. Beyond the five-year horizon: long-term outcome of high-risk and inoperable patients undergoing TAVR with first-generation devices. *EuroIntervention* 2018;14:41–9. <https://doi.org/10.4244/EUI-D-17-00603>; PMID: 29581084.
- Elchaninoff H, Durand E, Avinée G, et al. Assessment of structural valve deterioration of transcatheter aortic bioprosthetic balloon-expandable valves using the new European consensus definition. *EuroIntervention* 2018;14:e264–71. <https://doi.org/10.4244/EUI-D-18-00015>; PMID: 29599103.
- Barbanti M, Costa G, Zappulla P, et al. Incidence of long-term structural valve dysfunction and bioprosthetic valve failure after transcatheter aortic valve replacement. *J Am Heart Assoc* 2018;7:e008440. <https://doi.org/10.1161/JAHA.117.008440>; PMID: 30371244.
- Panico AR, Giannini C, De Carlo M, et al. Long-term results and definitions of the CoreValve transcatheter aortic bioprosthesis: outcomes beyond five years. *EuroIntervention* 2019;14:1639–47. <https://doi.org/10.4244/EUI-D-18-00779>; PMID: 30561369.
- Holy EW, Kebernik J, Abdelghani M, et al. Long-term durability and haemodynamic performance of a self-expanding transcatheter heart valve beyond five years after implantation: a prospective observational study applying the standardised definitions of structural deterioration and valve failure. *EuroIntervention* 2018;14:e390–6. <https://doi.org/10.4244/EUI-D-18-00041>; PMID: 29741488.
- Didier R, Elchaninoff H, Donzeau-Gouge P, et al. Five-year clinical outcome and valve durability after transcatheter aortic valve replacement in high-risk patients. *Circulation* 2018;138:2597–607. <https://doi.org/10.1161/CIRCULATIONAHA.118.003866>; PMID: 30571260.
- Blackman DJ, Saraf S, MacCarthy PA, et al. Long-term durability of transcatheter aortic valve prostheses. *J Am Coll Cardiol* 2019;73:537–45. <https://doi.org/10.1016/j.jacc.2018.10.078>; PMID: 30732706.
- Søndergaard L, Ihlemann N, Capodanno D, et al. Durability of transcatheter and surgical bioprosthetic aortic valves in patients at lower surgical risk. *J Am Coll Cardiol* 2019;73:546–53. <https://doi.org/10.1016/j.jacc.2018.10.083>; PMID: 30732707.
- Ruparella N, Panoulas VF, Frame A, et al. Successful treatment of very early thrombosis of SAPIEN 3 valve with direct oral anticoagulant therapy. *J Heart Valve Dis* 2016;25:211–3. PMID: 27989069.
- Barbanti M, Webb JG, Tamburino C, et al. Outcomes of redo transcatheter aortic valve replacement for the treatment of postprocedural and late occurrence of paravalvular regurgitation and transcatheter valve failure. *Circ Cardiovasc Interv* 2016;9:e003930. <https://doi.org/10.1161/CIRCINTERVENTIONS.116.003930>; PMID: 27578840.
- Johnston DR, Soltesz EG, Vakil N, et al. Long-term durability of bioprosthetic aortic valves: Implications from 12,569 implants. *Ann Thorac Surg* 2015;99:1239–47. <https://doi.org/10.1016/j.athoracsur.2015.09.1239>; PMID: 26187714.

- athoracsur.2014.10.070; PMID: 25662439.
49. Bourguignon T, Bouquiaux-Stablo A-L, Candolfi P, et al. Very long-term outcomes of the Carpentier-Edwards Perimount valve in aortic position. *Ann Thorac Surg* 2015;99:831–7. <https://doi.org/10.1016/j.athoracsur.2014.09.030>; PMID: 25583467.
50. Guenzinger R, Fiegl K, Wottke M, Lange RS. Twenty-seven-year experience with the St Jude Medical biocor bioprosthesis in the aortic position. *Ann Thorac Surg* 2015;100:2220–6. <https://doi.org/10.1016/j.athoracsur.2015.06.027>; PMID: 26421496.
51. Mohammadi S, Tchana-Sato V, Kalavrouziotis D, et al. Long-term clinical and echocardiographic follow-up of the freestyle stentless aortic bioprosthesis. *Circulation* 2012;126:S198–204. <https://doi.org/10.1161/CIRCULATIONAHA.111.084806>; PMID: 22965983.
52. Mykén PSU, Bech-Hansen O. A 20-year experience of 1712 patients with the Biocor porcine bioprosthesis. *J Thorac Cardiovasc Surg* 2009;137:76–81. <https://doi.org/10.1016/j.jtcvs.2008.05.068>; PMID: 19154907.
53. Yankah CA, Pasic M, Musci M, et al. Aortic valve replacement with the Mitroflow pericardial bioprosthesis: Durability results up to 21 years. *J Thorac Cardiovasc Surg* 2008;136:688–96. <https://doi.org/10.1016/j.jtcvs.2008.05.022>; PMID: 18805273.
54. Jamieson WRE, Burr LH, Miyagishima RT, et al. Carpentier-Edwards supra-annular aortic porcine bioprosthesis: Clinical performance over 20 years. *J Thorac Cardiovasc Surg* 2005;130:994–1000. <https://doi.org/10.1016/j.jtcvs.2005.03.040>; PMID: 16214510.
55. Bagur R, Pibarot P, Otto CM. Importance of the valve durability- life expectancy ratio in selection of a prosthetic aortic valve. 2017;103:1756–9. <https://doi.org/10.1136/heartjnl-2017-312348>; PMID: 28903992.