

Determination of echocardiographic parameters in spider monkey (*Ateles spp.*) collectives in captivity sedated with ketamine and midazolam

Determinação dos parâmetros ecocardiográficos em macacos-aranha (*Ateles spp.*) mantidos em cativeiro, sedados com cetamina e midazolam

Daniel de Almeida Balthazar^{1*}, Marcelo dos Santos Vasconcelos², Bárbara Souza Neil Magalhães³, Andressa Kagohara⁴, Fernando Troccoli², Alessandro Galhães², Mário dos Santos Filho⁵ & Jonimar Pereira Paiva^{6†}

¹Veterinarian, DSc. Departamento de Medicina e Cirurgia Veterinária (DMCV), Instituto de Veterinária (IV), Universidade Federal Rural do Rio de Janeiro (UFRRJ), Seropédica, RJ, Brasil

²Veterinarian. Autonomus, Rio de Janeiro, RJ, Brasil

³Veterinarian, MSc. Laboratório de Sanidade Avícola, Universidade Federal Fluminense (UFF), Niterói, RJ, Brasil

⁴Veterinarian. Autonomus, São Paulo, SP, Brasil

⁵Veterinarian, MSc. Programa de Pós-Graduação em Medicina Veterinária –(PPGMV), DMCV, IV, UFRRJ, Seropédica, RJ, Brasil

⁶Veterinarian, Dsc. DMCV, IV, UFRRJ, Seropédica, RJ, Brasil

†deceased in december 2018.

Abstract

Nonhuman primates have long been studied and managed in research centers, zoos, and farms, but there is still a lack of information regarding their illnesses. The present study aimed to establish the echocardiographic parameters of normality among primates of the genus *Ateles* (spider monkey) that are housed at the Zoo of the City of Rio de Janeiro - RIOZOO Foundation. Nine specimens of the same species were used, 5 females and 4 males, that were clinically healthy, young adults, with an approximate captive age of 2 to 3 years, and an average weight of 8.5 kg. The animals were physically restrained with a net and soon after, chemical containment was carried out by means of an association of ketamine hydrochloride at a dose of 8 mg per kg and midazolam at 0.5 mg per kg, intramuscularly. The animals were submitted to chemical restraint to establish the clinical evaluation, blood collection for complete blood count and biochemical measurements, urine collection for urinalysis, chest X-ray in the ventro-dorsal and latero-lateral positions, and electrocardiographic exams, with all the parameters within the normal range, in addition to echocardiographic examination, which became the means by which the study parameters were acquired. During this examination, the following values were evaluated: cardiac output, ejection fraction, final cardiac volume, heart rate, left atrial diameter, aorta diameter, ratio between the diameters of the left atrium and aorta artery, thickness of the interventricular septum in diastole, diameter of the left ventricle in diastole, thickness of the free wall of the left ventricle in diastole, thickness of the interventricular septum in systole, diameter of the left ventricle in systole, thickness of the free wall of the left ventricle in the systole, left ventricular end systolic volume, left ventricular end diastolic volume, septum bending fraction, fraction of curving of the posterior wall, septal separation, and shortening fraction. With the data obtained, tables were drawn with the echocardiographic values of the species studied under sedation.

Keywords: spider monkey, chemical restraint, echocardiogram, parameters of normality.

Resumo

Há tempos primatas não humanos são estudados e manejados em centros de pesquisa, zoológicos e criatórios, porém há ainda hoje uma carência de informações sobre suas enfermidades. O presente estudo teve o objetivo de estabelecer os parâmetros ecocardiográficos de normalidade, de primatas do gênero *Ateles* (macaco-aranha) alojados no Jardim Zoológico da Cidade do Rio de Janeiro - Fundação RIOZOO. Foram utilizados 9 exemplares da espécie, clinicamente saudáveis, sendo 5 fêmeas e 4 machos, adultos jovens, com idade de cativeiro aproximada de 2 a 3 anos, e peso médio de 8.5 kg. Os animais foram contidos



How to cite: Balthazar, D. A., Vasconcelos, M. S., Magalhães, B. S. N., Kagohara, A., Troccoli, F., Galhães, A., Santos Filho, M., & Paiva, J. P. (2020). Determination of echocardiographic parameters in spider monkey (*Ateles spp.*) collectives in captivity sedated with ketamine and midazolam. *Brazilian Journal of Veterinary Medicine*, 42, e107120. <https://doi.org/10.29374/2527-2179.bjvm107120>

Financial support: None.

Conflict of interests: No conflict of interests declared concerning the publication of this article.

Received: August 01, 2019.

Accepted: August 27, 2020.

The study was carried out at Zoo of the city of Rio de Janeiro - Fundação RIOZOO - Rio de Janeiro, RJ, Brasil.

*Correspondence

Daniel de Almeida Balthazar
Departamento de Medicina e Cirurgia Veterinária, Universidade Federal Rural do Rio de Janeiro - UFRRJ
Campus Seropédica
Bairro Zona Rural, Campus Seropédica
CEP 23851-790 - Seropédica (RJ), Brasil
E-mail: danielbalthazar@yahoo.com.br

Copyright Balthazar et al. This is an Open Access article distributed under the terms of the Creative Commons Attribution Non-Commercial License which permits unrestricted non-commercial use, distribution, and reproduction in any medium provided the original work is properly cited.

fisicamente com puçá de rede e logo após foi realizada a contenção química por meio de uma associação de cloridrato de cetamina na dose de 8 mg por kg e midazolam a 0.5 mg por kg, por via intramuscular. Os indivíduos foram submetidos à contenção química para estabelecimento de avaliação clínica, coleta de sangue para hemograma e dosagens bioquímicas, coleta de urina para urinálise, radiografia de tórax nas posições ventro-dorsal e latero-lateral, exames eletrocardiográficos, estando todos os parâmetros dentro da faixa de normalidade, além do exame ecocardiográfico, que veio a ser o meio pelo qual foram adquiridos os parâmetros do estudo. Durante este exame foram avaliados os seguintes valores: débito cardíaco, fração de ejeção, volume final cardíaco, frequência cardíaca, diâmetro do átrio esquerdo, diâmetro da aorta, relação entre os diâmetros do átrio esquerdo e da artéria aorta, espessura do septo interventricular na diástole, diâmetro do ventrículo esquerdo na diástole, espessura da parede livre do ventrículo esquerdo na diástole, espessura do septo interventricular na sístole, diâmetro do ventrículo esquerdo na sístole, espessura da parede livre do ventrículo esquerdo na sístole, volume sistólico final do ventrículo esquerdo, volume diastólico final do ventrículo esquerdo, fração de encurvamento de septo, fração de encurvamento da parede posterior, separação septal e fração de encurtamento. Com os dados obtidos foram elaboradas tabelas com os valores ecocardiográficos da espécie estudada, sob sedação.

Palavras-chave: macaco-aranha, contenção química, ecocardiograma, parâmetros de normalidade.

Introduction

The spider monkey (*Ateles spp.*) is a neotropical primate managed in several zoos, and its presence in such institutions helps in the environmental education of visitors as it is a means of conservation of this genus, whose species are under some degree of threat of extinction (International Union for Conservation of Nature and Natural Resources, 2020). Thus, their presence in zoos is of great importance, as is the maintenance of their health. This genus is also used as an experimental model to test drugs for human use due to its morphophysiological similarity with humans (Verona & Pissinatti, 2007).

There are few records in the literature regarding cardiovascular diseases in neotropical primates and these are increasingly common in specimens that live in captivity due to their increased longevity in these circumstances (Verona & Pissinatti, 2007). Currently, the use of echocardiography in veterinary medicine has been of great value as a complementary exam in the diagnosis of heart diseases and also as an instrument for the prevention and monitoring of such diseases. The electrocardiogram detects electrical disturbances that alter the heart rhythm and may indicate morphological changes. It also provides accurate information with structural measurement of the heart and hemodynamic assessment throughout life, which complements the diagnosis (Fuentes, 2016; Tilley & Smith Junior, 2016).

However, information on the etiology and pathophysiology of heart disease requires comparative reference values for its diagnosis, as is the case with echocardiography. This study aimed to evaluate the echocardiographic parameters in spider monkeys (*Ateles spp.*) sedated with ketamine and midazolam and to establish values for comparison in the diagnosis of cardiovascular diseases in this genus.

Material and methods

The present study was conducted with the purpose of elucidating the occurrences of cardiac disorders in primates at RioZOO after the description of dilated cardiomyopathy in a specimen of spider monkey, reported by Chaves et al. (2019). Thus, the investigation and evaluation of 9 specimens of spider monkeys kept in captivity at the Zoo of the City of Rio de Janeiro - Fundação RioZoo was carried out to evaluate possible cardiac changes.

The monkeys were housed in an enclosure of approximately 50 m² and received food based on fruits and vegetables and water ad libitum. The group consisted of 5 females and 4 males, weighing an average of 8.5 kg, and with an average captivity time of 2 years.

An 8-hour fast was recommended, and the animals were restrained individually, without the rest being able to witness the containment method, and the procedure itself lasted approximately 1 hour, until the animals were allocated for anesthetic recovery. The containment was carried out initially with the aid of a capture nets and then, the chemical containment was performed by dissociative anesthesia with ketamine hydrochloride (Cetamin®) at a dose of 8 mg/kg, associated with 0.5 mg/kg midazolam (Dormonid®), intramuscularly, in a single dose.

The animals were sent to the veterinary hospital of the RIOZOO Foundation, where they underwent several health monitoring tests since the maximum number of procedures is recommended in a single chemical containment. In this way, general physical evaluation, electrocardiographic, echocardiographic exams, blood count, biochemistry, radiography, and urinalysis were performed.

In the echocardiographic examination, an echocardiogram device (Sonosite®) was used, where the convex transducer with ideal frequency between 2 and 5 Mhz and a sectoral transducer (or microconvex) with similar frequency was positioned in the region of the fourth left intercostal space (Figure 1), at the elbow in flexion, with the animals in the left lateral decubitus position. As suggested by Boon (2011), echocardiographic sections (Figure 2), such as parasternal, apical, suprasternal, and subcostal, were obtained with later compilation and recording of data in an electronic spreadsheet. A descriptive statistical analysis (mean, standard deviation, and coefficient of variation) was performed with 95% significance, as well as minimum, average, and maximum values for the parameters: cardiac output (CO), ejection fraction (EF), final cardiac volume (FCV), heart rate (HR), left atrial diameter (LA), aorta diameter (Ao), ratio between the diameters of the left atrium and aorta artery (LA/Ao), thickness of the interventricular septum in diastole (TIVSD), diameter of the left ventricle in diastole (DLVD), thickness of the left ventricular free wall in diastole (TLVFW), thickness of the interventricular septum in systole (TISS), diameter of the left ventricle in systole (DLVS), thickness of the left ventricle free wall in the systole (TLVFW), left ventricular end-systolic volume (LVESV), left ventricular end-diastolic volume (LVEDV), shortening fraction of ventricular septum (SFVS), posterior wall curving fraction (PWCF), left ventricular shortening fraction (LVSF), and shortening fraction (SF). Mean and standard deviation and weight variation coefficient were also determined in kilograms (kg).

After the examinations, the animals were sent to the observation room until full anesthetic recovery. Thus, the data were compiled and evaluated using the aforementioned descriptive statistics in order to assess the echocardiographic findings for future studies in this species.

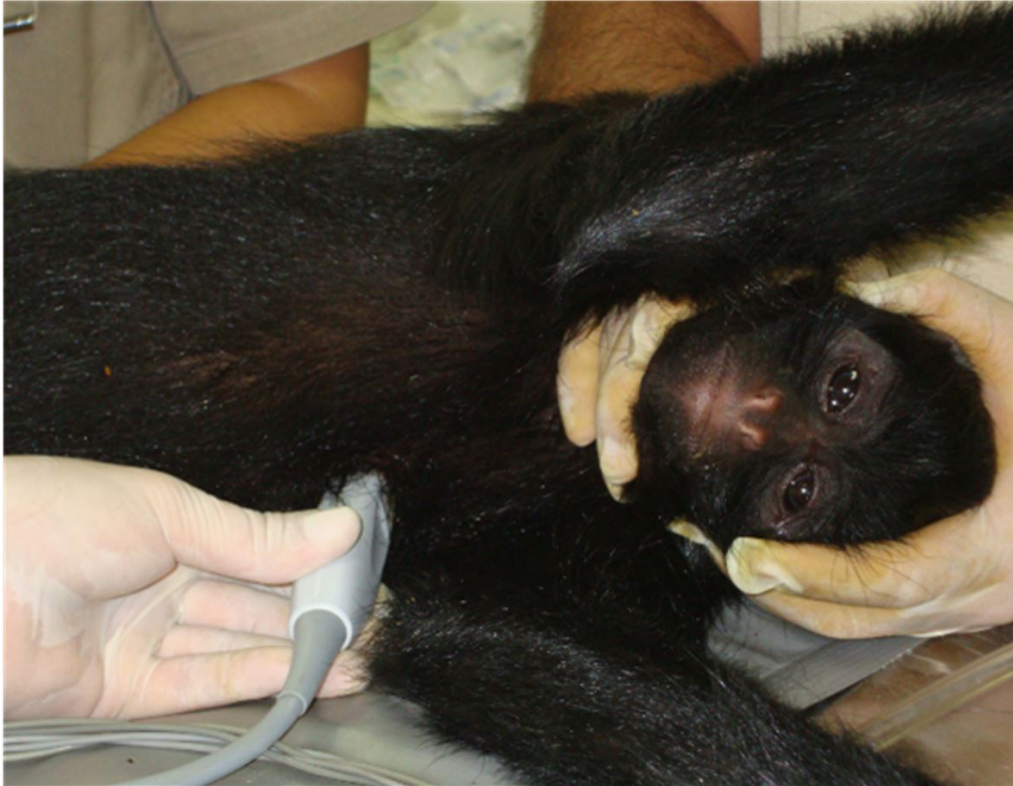

Figure 1. Echocardiographic examination in a specimen of the *Ateles* genus. Patient sedated in the left lateral decubitus. showing the positioning of the transducer in the region of the fourth left intercostal space. at the elbow. to obtain the anatomical echosonographic cuts. Source: RIOZOO.

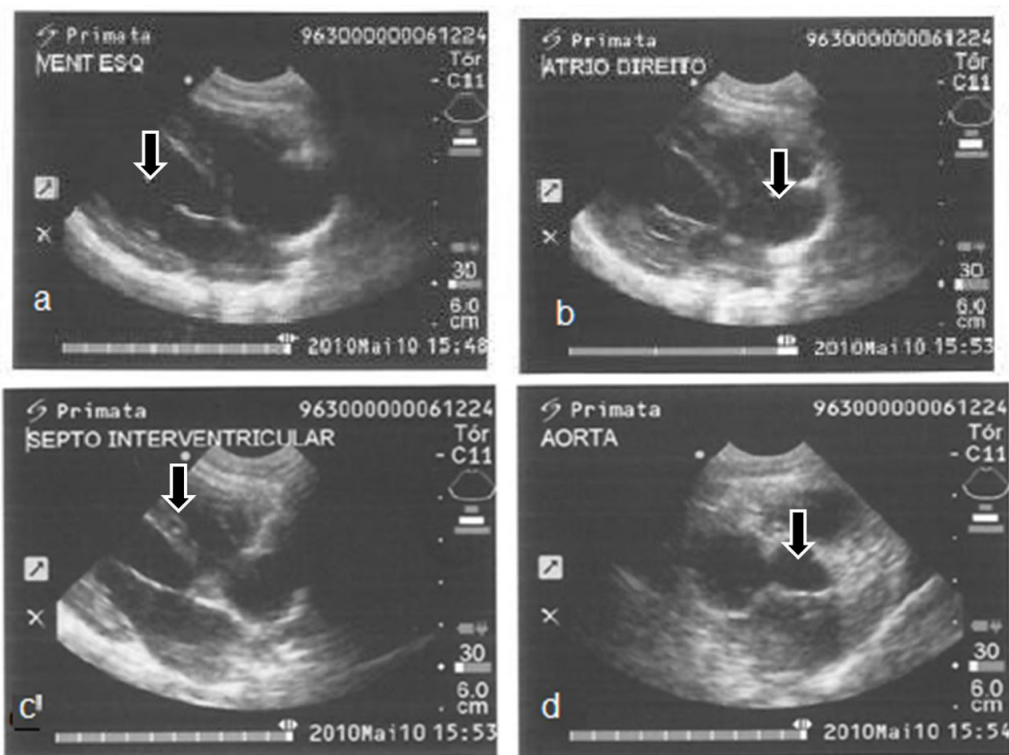


Figure 2. Echocardiographic examination in B mode. (a) Left ventricle; (b) Right atrium; (c) Interventricular septum; (d) Aorta (filled arrows). Source: Alessandro Galhões.

Results

No clinical changes were observed during the physical examination, with the exception of one animal, which had an abdominal mass in the pubic region, suggestive of uterine neoplasia. However, because this animal did not undergo cardiac alterations, it was kept in the study and its parameters were compiled. The protocol used in the chemical restraint was satisfactory, taking into account the relaxation and sedation for the exams, without complications during sedation, and with full recovery of the individuals after the period of pharmacological effect. Tables 1 and 2 list the results of the echocardiographic examinations submitted for descriptive statistical analysis.

Discussion

The use of dissociative anesthesia for chemical containment of neotropical primates is indicated for non-invasive and short-term procedures (Fortman et al., 2018) because it minimizes the stress caused by manipulation and increases the safety of the procedure, thereby preventing accidents (Blanchard & Russell-Lodrigue, 2012), in addition to promoting immobilization and relaxation of the animal, which is desired in various procedures, such as echocardiography.

The use of ketamine associated with midazolam is described in some species of neotropical primates as a satisfactory (sedation and relaxation) and safe protocol since they do not cause significant hemodynamic effects (Furtado et al., 2010; Ølberg & Sinclair, 2014; Raposo et al., 2015; Alfonso et al., 2020). Therefore, since it does not promote hemodynamic changes, this protocol can be indicated in echocardiographic exams in these species.

To perform the echocardiographic examination, the fourth left intercostal space was used to position the transducer since spider monkeys have a thoracic morphology similar to that of canids (Verona & Pissinatti, 2014). The exams showed a regular pattern of parameters (based on the variation coefficient). This indicates that in addition to the technique used for the echocardiographic examination to be effective, the chemical containment protocol with ketamine and midazolam was also satisfactory, since the latter did not promote systemic changes that reflected negatively on the results of the examination.

Table 1. Echocardiographic results of spider monkeys from the RioZOO Foundation (specimens between 7-11 kg), distributed by gender for the following parameters: CO, EF, FCV, HR, LA, Ao, LA/Ao, TIVSD, DLVD and TLVFW.

Animal	Gnd.	Wt. (kg)	CO (l/m)	EF (%)	FCV (ml)	HR (bpm)	LA (cm)	Ao (cm)	LA/Ao	TIVSD (cm)	DLVD (cm)	TLVFW (cm)
1	F	7.50	1.2	59	10.4	115	1.85	0.9	2.03	0.48	2.28	0.46
2	F	7.05	1.2	66	9.8	120	1.32	0.9	1.50	0.48	2.12	0.45
3	F	7.40	1.2	75	10.5	110	1.69	1.0	1.67	0.40	2.07	0.41
4	M	8.10	1.5	62	11.2	132	1.71	1.0	1.73	0.54	2.30	0.51
5	F	8.70	1.3	83	9.4	140	1.52	1.0	1.46	0.40	1.90	0.49
6	F	10.70	1.4	57	10.9	130	1.96	1.1	1.85	0.62	2.35	0.68
7	M	10.30	1.6	74	13.3	120	1.92	1.2	1.59	0.54	2.30	0.53
8	M	8.04	2.1	84	18.4	115	1.71	1.0	1.68	0.66	2.48	0.58
9	M	7.80	1.1	60	11.9	90	1.77	1.4	1.26	0.69	2.38	0.54
Mean		8.51	1.4	69	11.8	119	1.72	1.1	1.64	0.53	2.24	0.52
SD		0.14	0.31	10	2.75	14.50	0.20	0.20	0.22	0.11	0.18	0.08
CV		0.016	0.22	0.14	0.23	0.12	0	0.18	0.12	0.19	0.08	0.16
Min.		7.05	1.16	61.33	9.69	107.88	1.57	0.95	1.47	0.45	2.10	0.45
Max.		1070	1.62	76.10	13.75	129.29	1.86	1.24	1.80	0.61	2.37	0.57

Subtitle: Gnd.: Gender; Wt.: Weight; SD: Standard Deviation; CV: Coefficient of Variation; Min.: indicates the minimum parameter of the confidence interval; Max.: indicates the maximum value of the confidence interval; CO: Cardiac Output; EF: Ejection Fraction; FCV: Final Cardiac Volume; HR: Heart Rate; LA: diameter of the Left Atrium; Ao: diameter of the Aorta; LA/Ao: relationship between the diameters of the Left Atrium and the Aortic artery; TIVSD: Thickness of the Interventricular Septum in Diastole; DLVD: Diameter of the Left Ventricle in Diastole; TLVFW: Thickness of the Left Ventricular Free Wall in Diastole.

Table 2. Echocardiographic results of spider monkeys from the RioZOO Foundation (specimens between 7 and 11 kg), distributed by sex for the following parameters: TISS, DLVS, TLVFWs, LVESV, LVEDV, SFVS, PWCF, LVSF and SF.

Animal	TISS (cm)	DLVS (cm)	TLVFWs (cm)	LVESV (ml)	LVEDV (ml)	SFVS (%)	PWCF (%)	LVSF (%)	SF (%)
1	0.65	1.61	0.75	7.29	17.70	35.40	29.40	63.00	29.39
2	0.73	1.39	0.88	4.60	14.80	52.10	34.40	95.60	34.43
3	0.62	1.21	0.77	3.44	13.90	55.00	41.50	81.80	41.55
4	0.83	1.58	0.88	6.14	18.10	53.70	31.30	72.50	31.30
5	0.80	0.96	0.83	1.84	11.20	100.00	49.50	69.40	49.47
6	0.79	1.69	0.88	8.26	19.10	27.40	28.10	29.40	28.09
7	0.83	1.37	0.75	4.77	18.10	53.70	40.40	41.50	40.43
8	1.09	1.22	0.88	3.51	21.90	65.20	50.80	51.70	50.81
9	0.89	1.66	0.89	7.89	19.70	29.00	30.30	64.80	30.25
Mean	0.80	1.41	0.834	5.304	17.17	52.39	37.30	63.30	37.30
SD	0.14	0.25	0.06	2.22	3.29	22.08	8.650	20.21	8.66
CV	0.17	0.17	0.07	0.42	0.19	0.42	0.23	0.32	0.23
Min.	0.70	1.23	0.79	3.73	14.84	36.71	31.16	48.95	31.15
Max.	0.90	1.58	0.88	6.88	19.50	68.07	43.44	77.65	43.45

Subtitle: SD: Standard Deviation; CV: Coefficient of Variation; Min.: indicates the minimum parameter of the confidence interval; Max.: indicates the maximum value of the confidence interval. Minimum indicates the minimum parameter of the confidence interval. Maximum indicates the maximum value of the confidence interval; TISS: Thickness of the Interventricular Septum in Systole; DLVS: Diameter of the Left Ventricle in Systole; TLVFWs: Thickness of the Left Ventricular Free Wall in Systole; LVESV: Left Ventricular End-Systolic Volume; LVEDV: Left Ventricular End-Diastolic Volume; SFVS: Shortening Fraction of Ventricular Septum; PWCF: Posterior Wall Curving Fraction; LVSF: Left Ventricular Shortening Fraction; SF: Shortening Fraction.

In addition, it was observed that parameters such as diameter and volume of the heart can be directly related to the sex and weight of the animals, presenting higher values in male and heavier individuals. This finding corroborates the description by Paciulli (2017), who reported that primate species present as sexual dimorphism, which is the increase in the size of some internal organs, such as the heart and brain, and increase in body size and mass.

Conclusion

The echocardiographic parameters obtained by the sampling were within the standard average and still within the range of values obtained through the statistical normality test, which can serve as reference values for cardiac morphofunctional evaluation of patients of the present species in captivity.

Acknowledgements

RioZOO.

References

- Alfonso, J., Lescano, J., Quevedo, M., & Fernández, V. (2020). Comparison of three reversible injectable chemical restraint protocols in Spix's Owl monkeys (*Aotus vociferans*) using ketamine, xylazine and midazolam. *Journal of Medical Primatology*, 49(3), 136-143. <http://dx.doi.org/10.1111/jmp.12462>. PMID:32048309.
- Blanchard, J. L., & Russell-Lodrigue, K. E. (2012). Biosafety in laboratories using nonhuman primates. In C. R. Abee, K. Mansfield, S. Tardif & T. Morris (Eds.), *Nonhuman primates in biomedical research: biology and management* (2nd ed., Vol. 1, pp. 437-492). Waltham: Academic Press.
- Boon, J. A. (2011). Myocardial diseases. In J. A. Boon (Ed.), *Veterinary echocardiography* (2nd ed., pp. 359-410). Hoboken: Wiley-Blackwell.
- Chaves, H. H. C. C., Magalhães, B. S. N., Kagohara, A., Troccoli, F., Galhães, A. O., Santos, M., Balthazar, D. A., & Paiva, J. P. (2019). Dilated cardiomyopathy in spider-monkey (*Ateles chamek*, Humboldt, 1812): case report. *Brazilian Journal of Veterinary Medicine*, 41, e098219. <http://dx.doi.org/10.29374/2527-2179.bjvm098219>.
- Fortman, J. D., Hewett, T. A., & Lisa, C. H. (2018). Veterinary care: anesthesia and analgesia. In J. D. Fortman, T. A. Hewett & C. H. Lisa (Eds.), *The laboratory nonhuman primate* (2nd ed., pp. 205-222). Boca Raton: CRC Press.
- Fuentes, V. L. (2016). Echocardiography and Doppler Ultrassound. In F. Smith Junior, L. Tilley, M. Oyama & M. Sleeper (Eds.), *Manual of canine and feline cardiology* (5th ed., pp. 77-92). St. Louis: Elsevier.
- Furtado, M. M., Nunes, A. L. V., Intelizano, T. R., Teixeira, R. H. F., & Cortopassi, S. R. G. (2010). Comparison of racemic ketamine versus (S+) ketamine when combined with midazolam for anesthesia of *Callithrix jacchus* and *Callithrix penicillata*. *Journal of Zoo and Wildlife Medicine*, 41(3), 389-394. <http://dx.doi.org/10.1638/2008-0016.1>. PMID:20945634.
- Ølberg, R. A., & Sinclair, M. (2014). Monkeys and gibbons. In: G. West, D. Heard & N. Caulkett (Eds.), *Zoo animal and wildlife immobilization and anesthesia* (2nd ed., pp. 561-571). Iowa: Wiley-Blackwell. . <http://dx.doi.org/10.1002/9781118792919.ch38>.
- Paciulli, L. M. (2017). Sexual dimorphism (nonhuman primates). In A. Fuentes (Ed.), *The International Encyclopedia of Primatology* (pp. 1-5). Chichester: John Wiley & Sons. . <http://dx.doi.org/10.1002/9781119179313.wbprim0486>.
- Raposo, A. C. S., Ofri, R., Schaffer, D. P. H., Gomes Júnior, D. C., Libório, F. A., Martins Filho, E. F., & Oriá, A. P. (2015). Evaluation of ophthalmic and hemodynamic parameters in capuchin monkeys (*Sapajus sp.*) submitted to dissociative anesthetic protocols. *Journal of Medical Primatology*, 44(6), 381-389. <http://dx.doi.org/10.1111/jmp.12200>. PMID:26457384.
- Tilley, L. P., & Smith Junior, F. W. K. (2016). Electrocardiograph. In F. Smith Junior, L. Tilley, M. Oyama & M. Sleeper (Eds.), *Manual of canine and feline cardiology* (5th ed., pp. 49-76). St. Louis: Elsevier.
- International Union for Conservation of Nature and Natural Resources - IUCN. (2020). *IUCN Red List: Ateles*. Cambridge. Retrieved in 2020, May 20, from <https://www.iucnredlist.org/search?query=ateles&searchType=species>
- Verona, C. E. S., & Pissinatti, A. (2007). Primates: primatas do novo mundo (sagui, macaco-prego, macaco-aranha e bugio). In Z. S. Cubas, J. C. R. Silva & J. L. Catão-Dias (Eds.), *Tratado de animais selvagens* (1. ed., pp. 358-378). São Paulo: Roca.
- Verona, C. E. S., & Pissinatti, A. (2014). Primates: primatas do novo mundo (sagui, macaco-prego, macaco-aranha, bugio e muriqui). In Z. S. Cubas, J. C. R. Silva & J. L. Catão-Dias (Eds.), *Tratado de animais selvagens* (2. ed., pp. 723-743). São Paulo: Roca.