

THE RETROSPECTIVE ANALYSIS RESULTS OF THE ENDOMETRIAL TISSUE PATHOLOGICAL CONDITIONS DEVELOPMENT

<http://dx.doi.org/10.18370/2309-4117.2020.55.48-52>



V.V. ARTYOMENKO

MD, professor, Obstetrics and Gynecology Department No. 2, Odesa National Medical University, Odesa
ORCID: 0000-0003-2490-375X

Z.V. CHUMAK

PhD, assistant, Obstetrics and Gynecology Department No. 2, Odesa National Medical University, City Center for Climacteric Problems, Odesa
ORCID: 0000-0002-7487-1410

M.V. SHAPOVAL

MD, professor, Obstetrics and Gynecology Department No. 2, Odesa National Medical University, Odesa
ORCID: 0000-0002-1087-2609

Contacts:

Volodymyr V. Artyomenko
Odesa National Medical University,
Obstetrics and Gynecology
Department No. 2
Valihovsky alley 2, 65082, Odesa,
Ukraine
Tel.: +38 (050) 316 44 87
email: vartyomenko2017@gmail.com

INTRODUCTION

Endometrial hyperplastic processes (EHP) are one of the most common pathologies of the uterine mucous membrane and characterized by diffuse or local proliferative changes of the stromal and glandular components [1, 2, 3]. These pathological changes are studied and investigated by researchers from various fields of science and practical medicine, due to the increasing frequency of this pathology [4, 5], the ability to both self-healing and malignancy [2, 6, 7] and early manifestations [7, 8, 9].

Proliferation is considered a factor that contributes to the development of genetic damage, often not taking into account that in cells of rapid division, genetic damage can occur more often, but they are more often eliminated [6, 10, 11]. There are works that indicate the leading factors of the mutation process that must be sought within a living organism and a living cell [7, 12, 13].

Endometrial cancer (EC) occupies a leading position in the structure of oncogynecological pathology in economically developed countries, which involves the study of various etiopathogenetic mechanisms of endometrial pathology neoplasia [2, 12, 14], as well as the search for basic mechanisms, that at different levels of cellular regulation processes, can contribute to the acquisition of characteristic properties for further neoplastic growth [15, 16, 17].

Endometrium is a complex multicomponent system of mesenchymal origin, which in the peri- and postmenopausal periods against the background of gradual atrophy of the functional layer, in the basal layer retains memory, plasticity and regenerative properties by preserving its hormonal receptors, enzymatic apparatus and regenerative potential, capable, in the presence of starting mechanisms, to proliferative processes [3, 6, 18]. Endometrial autonomy is characterized by a dense vascular network, presence of the enzymatic apparatus, immune system, ability to local steroidogenesis (synthesis of estrogen, prostaglandins, prolactin, androgens), insulin-like growth factor 1 and 2 types, epidermal growth factor, vascular endothelial growth factor, transforming growth factor 1 α , 1 β [8, 9, 19].

According to various publications, EHP is rated from 15% to 50% among gynecological diseases in general with no tendency to decrease [6, 7, 20]. This variability of indicators depends on age,

environmental, medical and social health problems in different countries, factors that provoke the development of cancer, especially endocrine regulation and iatrogenic factors [12, 21, 22]. There is an increase in the occurrence of atypical EHP and EC in the reproductive period, which encourages researchers to carry out a program of cancer prevention and development of early diagnostic markers, treatment measures on the background of various morphological aspects [13, 20, 23]. Proliferative processes of the endometrium can mimic the periodic cycle normalization with prospect of recurrence and malignancy, and in some cases regression of pathology; such multifactorial processes depend on the manifestation of pathohistological changes and general characteristics of the body as a whole, and requires further study of etiopathogenetic mechanisms nature and possible early markers of development prospects search [2, 24, 25].

The purpose of the research: to study the detection frequency of endometrium proliferative changes states in comparison with the women age.

MATERIALS AND METHODS

We analyzed medical documentation archival data from the Odesa Regional Pathological Bureau of Pediatric and Gynecological Pathological Department for the periods of 2016–2019 years. We analyzed 2196 pathomorphological findings of endometrial tissue samples in women with clinical manifestations requiring surgery: including 1404 hyperplastic conditions, 688 endometrial polyps, 104 condition of the endometrium during operations of total and/or subtotal uterus removal for leiomyoma. The processed results were distributed as follows: endometrial hyperplasia (EH), which included simple and complex atypical hyperplasia, with atypical hyperplasia (AH) – simple and complex atypical hyperplasia, adenocarcinomas (AC) – high-, moderate-, low-differentiated, atrophic states (Atr.S.) and noninformative conclusions (N/inf.), with the endometrium corresponding to the phases of the menstrual cycle (NE) as well as proliferation phase (PP), secretion phase (SP). Histological conditions were distributed according to the age categories of patients with an interval of 5 years.

Results are processed by variation statistics methods with estimation of reliability by Student's criterion with use of standard computer systems.

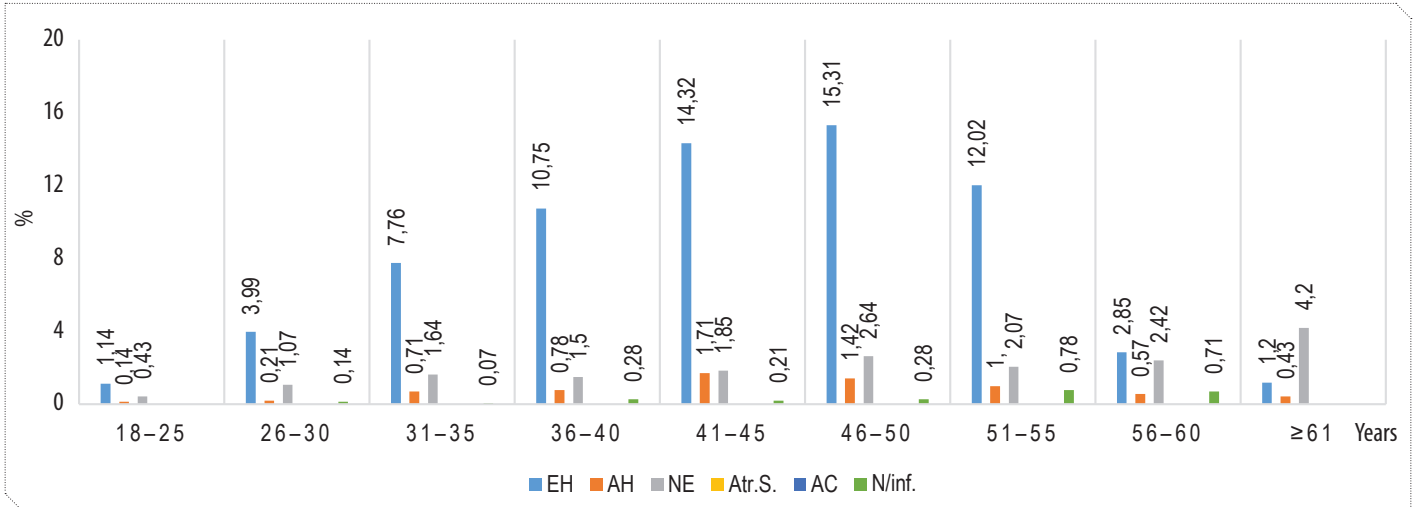


Figure 1. Endometrium morphological types distribution according to age (%)

STUDY RESULTS AND DISCUSSION

It was found that the optimal age of the pathological process falls on the perimenopausal period (Fig. 1), which is one of the most threatening factors in the development of changes in epithelial and stromal components of the endometrium, including due to dyshormonal conditions that may contribute to the triggering mechanisms of pathological manifestations.

The age distribution of EH morphological detection has the maximum value in women aged 46–50 years, which is $15.31 \pm 0.96\%$ of all endometrial conditions and a gradual decrease in the percentage of detection at age to the lowest levels in 18–25 years and more than 61 years ($1.14 \pm 0.28\%$ and $1.2 \pm 0.28\%$, respectively).

AH has a similar type of distribution with a maximum detection rate of 41–45 years ($1.71 \pm 0.35\%$) and 46–50 years ($1.42 \pm 0.32\%$) and a minimum of 18–25 years ($0.14 \pm 0.28\%$) and over 61 years ($0.48 \pm 0.17\%$). Thus, the study of mechanisms of development of endometrium proliferative conditions has both theoretical and purely clinical significance. The fact of menopause development in the Odesa region at the age of 47.6 years (according to the City Center for Menopause, 2005) coincides with the maximum period of detection of hyperplastic and atypical forms of endometrium proliferative states. It has been established that simple and complex atypical hyperplasia are results of relative or absolute estrogen hyper-secretion, and atypical forms are progressive monoclonal muta-

tional damage with hormone-independent local growth [3, 22, 25].

Morphological findings of adenocarcinoma were first detected in the age range of 46–50 years ($0.43 \pm 0.17\%$), then 51–55 years and 56–60 years ($0.71 \pm 0.22\%$), and in the age category of 61 years and older ($1.42 \pm 0.32\%$), which indicates the growth of this pathology with age, the onset of the manifestation is the menopausal period. It is interesting that results of this study established AH in all age groups, starting from 18 years, with different frequency of manifestation. Atypical forms of hyperplasia are malignant from 8% to 44% [3, 25] and are relevant for development of solutions for cancer prevention from a morphological point of view. No malignancy was found in the age group up to 46 years, possibly due to the influence of certain protection factors.

Results of the study of age dynamics and degree of differentiation of adenocarcinoma (Fig. 2) revealed an increase in highly differentiated adenocarcinoma (HDAC) from 46–50 years ($6.52 \pm 3.64\%$) up to 61 years ($19.57 \pm 5.85\%$); moderately differentiated adenocarcinoma (MDAC) – $4.35 \pm 3.0\%$ to $6.52 \pm 3.64\%$, respectively, and low differentiated adenocarcinoma (LDAC) – $2.17 \pm 2.15\%$ to $17.39 \pm 5.59\%$, respectively, which confirms the increase in both frequency and malignancy aggressiveness with age.

Similar results were obtained when analyzing the condition of endometrium after polyps removal (Fig. 3) and total or subtotal leiomyoma hysterectomies (Fig. 4). At polypectomies the maximum values of EH were found in the age category of 41–45 years ($14.68 \pm 1.35\%$), has a dynamics of change with minimum values in 18–25 years ($1.6 \pm 0.48\%$) and more

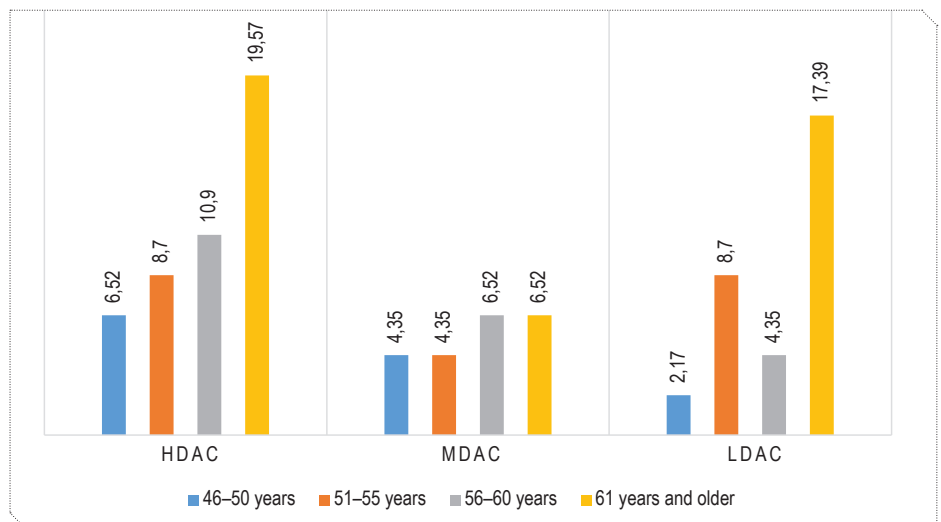


Figure 2. Adenocarcinoma morphological types distribution according to age (%)

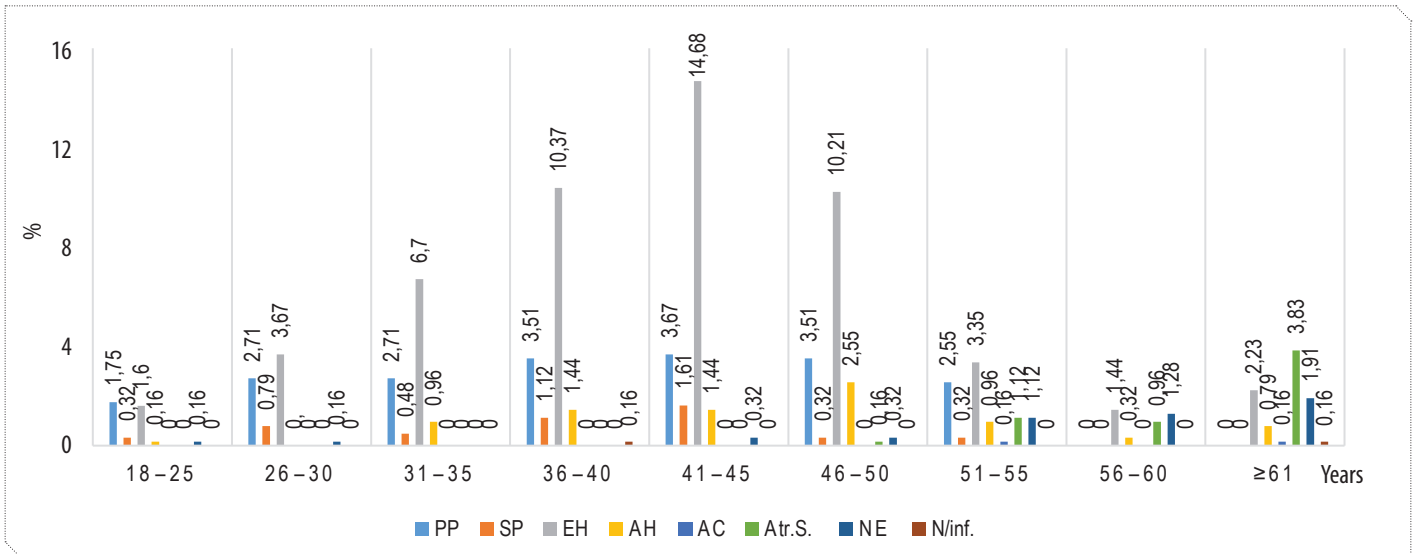


Figure 3. Endometrial state after polypectomies (%)

than 61 years ($2.23 \pm 0.57\%$). Hyperplastic processes with atypical manifestations were maximally diagnosed at the age of 46–50 years – $2.55 \pm 0.6\%$, adenocarcinoma was detected in 51–55 years – $0.16 \pm 0.14\%$. Peak of EH after a total or subtotal hysterectomy was detected at the age of 46–50 years ($23.08 \pm 4.13\%$), AH was detected also at the age of 46–50 years ($2.88 \pm 1.64\%$), AC – in the age after 61 years ($2.88 \pm 1.64\%$).

Results of our study do not contradict the existing hypotheses that the HPE development formation processes coincide with the estrogenic effect in a prolonged dyshormonal state, especially at the age of 45–49 years. This period is considered the “perimenopausal estrogen window”, or the period of “uncovered” estrogenic effects on the endometrium. It is from this age that the fact of increasing the frequency of adenocarcinoma begins [1, 12, 23, 25].

Researches of pathomorphological conditions of endometrial tissue in the postmenopausal period confirm the results of researchers who claim that the endometrium is a complex multicomponent system of mesenchymal origin, which in menopause on the background of gradual atrophy of the functional layer, retains «memory» in the basal layer properties due to preservation of hormonal receptors, the enzymatic complex and regenerative qualities and so in a post-menopause. Confirmation of this position is the results of studies: the establishment of proliferative processes in this age group as HE, AH, especially the

growth of adenocarcinoma with age.

According to the authors [9, 20], in malignancy cell division predominates over elimination, due to activation of proliferation processes, or inhibition of programmed cell death or their combined disorders, forming a clone of cells capable of subsequently showing autonomy and immortalization. The nature of proliferation and apoptosis association is influenced by both state of hormonal homeostasis in general and state of local changes in cellular metabolism at the tissue level, as well as cell senescence.

Cell senescence is a genetically programmed process that should eventually lead to apoptosis [9, 12], manifested by irreversible blockade of the division cycle, cessation of cell response to pro-

liferation stimuli, and growth factors in the presence of critically shortened telomeres and unrepaired DNA damage [7], as the accumulation of genetic heterogeneity is the main property of malignant tumors, the protection against malignancy is sending to apoptosis cells with the expression of mutant genes [9, 10].

In the process of ageing the tissues’ accumulation of ageing cells resistant to apoptosis, which may be a mechanism for the development of malignancy with age.

It is known that in physiological conditions, as a result of apoptosis, only damaged cells are released, which is leading in the process of protecting the body from malignancy [3, 9]. It has been hypothesized that cell ageing is a

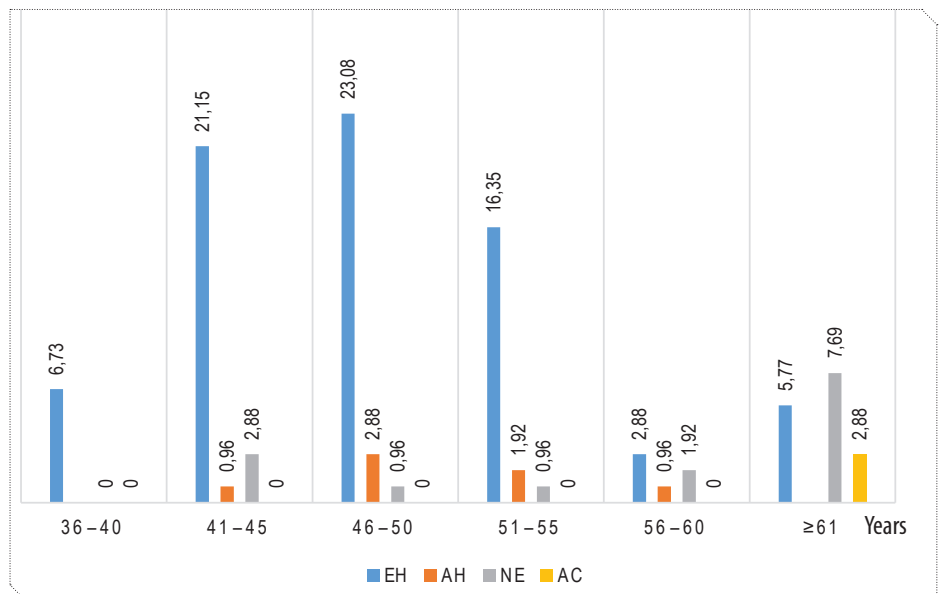


Figure 4. Endometrium condition after surgery for leiomyoma (%)

manifestation of protection against the division of genetically damaged cells and the transition to neoplasia [6, 25]. Stopping mitosis in cells that have reached the Hayflick limit causes activation of p53 [9, 10], p53 protein is expressed in all cell types as an inactive latent transcription factor, only during stress exposure – DNA damage, oxidative stress, telomere shortening, oncogenes activation p53 activation occurs and apoptosis as a consequence [8, 9, 13]. Thus, cell senescence is a universal process that develops as a response to damage of a certain level, including damage to the telomere [13, 21]. The types of damage that trigger the cell to progress to ageing are quite similar to those that stimulate apoptosis [9, 23, 25]. From the evolutionary theory of cell senescence, the process is complex because apoptosis is mandatory for the body, and there is evidence that a cell dies with unreparable DNA damage that is not inherited by descendants, so the provisions on the parallel existence of apoptosis and senescence are not clarified.

Elucidation of the somatic mutations and DNA reparations significance in the mechanisms of senescence leaves open the question of their direct connection with the processes of apoptosis, differentiation, malignancy and malignant growth [3, 6, 13]. The choice of the body specific tactics for cell damage also depends on the type of cells, their location, microenvironment,

the nature of the damage, and the damaging factor. It is safer to start the genetically damaged cells removal mechanisms for the organism survival than the presence of cells' clusters with uncontrolled autonomic growth [9, 10, 20, 25].

CONCLUSIONS

As a result of retrospective analysis of histopathological examinations it was found that the main factor in detecting pathological conditions of the endometrium is a woman's age of perimenopausal period, which can be considered as an early marker of diagnosis, leading to treatment prospects and general therapeutic tactics, for the future diagnostics and detection of others immunohistochemical and molecular genetic markers in women with hyperplastic processes in endometrial tissue. Perimenopausal period (46–50 years) manifests itself as an activator of hyperplastic conditions, hyperplasia with atypia and the onset of adenocarcinoma development, which may be due to changes in health factors, in the reproductive system pathological conditions development. It is mandatory to monitor the patient's condition in perimenopausal age, with the exception of the most pathogenic factors. These indicators allow the use of therapeutic measures to improve treatment tactics and maintain the patients' quality of life.

REFERENCES/ЛІТЕРАТУРА

1. Vovk, I.B., Gorban, N.E., Borysiuk, O.Y. "Endometrial hyperplasia (Clinical lecture)." *Woman's Health* 5.111 (2016): 10–8.
Вовк, І.Б. Гіперплазія ендометрія (Клінічна лекція) / І.Б. Вовк, Н.Е. Горбань, О.Ю. Борисюк // *Здоров'я жінки*. – 2016. – №5 (111). – С. 10–18.
2. World Health Organization. *Cancer. Fact sheet*. Geneva. WHO (2017).
3. Tatarchuk, T.F., Kalugina, L.B., Tutchenko, T.N. "Hyperplastic processes of endometrium: what's new?" *Reproductive Endocrinology* 5.25 (2015): 7–13.
Татарчук, Т.Ф. Гіперпластическі процеси ендометрія: що нового? / Т.Ф. Татарчук, Л.В. Калугіна, Т.Н. Тутченко // *Репродуктивна ендокринологія*. – 2015. – №5 (25). – С. 7–13.
4. Doddamani, U.G., Doddamani, G.B., Katageri, G. "Clinicopathological Correlation of Endometrium in Abnormal Uterine Bleeding." *Sch J App Med Sci* 2.1A (2014): 46–9.
5. Grygorenko, A.N., Gordiychuk, A.B. "Endometrial hyperplasia: There are more questions than answer." *Reproductive Endocrinology* 3.35 (2017): 31–43.
Григоренко, А.Н. Гіперплазія ендометрія: Вопросов больше, чем ответов / А.Н. Григоренко, А.Б. Гордийчук // *Репродуктивна ендокринологія*. – 2017. – №3 (35). – С. 31–43.
6. Orazov, M.R. "Debating points of endometrium hyperplasia case management." *Obstetrics and Gynecology. News, opinions, training* 3 (2016): 46–58.
Оразов, М.Р. Дискуссионные вопросы ведения пациенток с гиперплазией эндометрия / М.Р. Оразов // *Акушерство и гинекология. Новости, мнения, обучение*. – 2016. – №3. – С. 46–58.
7. Makhina, E.V., Pichigina, A.K., Koldysheva, E.V., et al. "Diagnostic and prognostic value of endometrial cell proliferative activity in hyperplastic and neoplastic processes." *Fundamental Researches* 10 (2014): 420–7.
Махина, Е.В. Диагностическая и прогностическая значимость оценки пролиферативной активности клеточных популяций эндометрия при гиперпластических и неопластических процессах / Е.В. Махина, А.К. Пичигина, Е.В. Колдышева и др. // *Фундаментальные исследования*. – 2014. – №10. – С. 420–427.
8. Demakova, N.A., Altukhova, O.B., Pakhomov, S.P., et al. "Molecular genetic mechanisms of the endometrial hyperplastic processes." *Scientific reports* 4.175 Issue 25 (2014): 177–82.
Демакова, Н.А. Молекулярно-генетические механизмы развития гиперпластических процессов эндометрия / Н.А. Демакова, О.Б. Алтухова, С.П. Пахомов и др. // *Научные ведомости*. – 2014. – №4 (175), Вып. 25. – С. 177–182.
9. Davydov, M.I., Gantsev, S.K. *Oncology: textbook*. Moscow. GEOTAR-Media (2019): 920 p.
Давыдов, М.И. Онкология: учебник / М.И. Давыдов, Ш.Х. Ганцев. – М.: ГЕОТАР-Медиа, 2010. – 920 с.
10. Bednarek, M., Constantinou, M., et al. "Evolution of genomic imbalance in endometrial hyperplasia and carcinoma." *Gynecol Pol* 85.11 (2014): 828–32.
11. Chumak, Z.V., Zelinsky, O.O., Shapoval, M.V. "Immune Histochemical and Molecular-genetic Markers of Hyperplastic and Neoplastic Endometrium." *Reports of Morphology* 2 (2015): 547–51.
Чумак, З.В. Иммуногистохимические и молекулярно-генетические маркеры гиперплазированного и неоплазированного эндометрия / З.В. Чумак, А.А. Зелинский, Н.В. Шаповал // *Вісник морфології*. – 2015. – №2, Т. 21. – С. 547–552.
12. Chernukha, G.E., Asaturova, A.V., Ivanov, I.A., et al. "Endometrial lesion's pattern in different age groups." *Obstetrics and Gynecology* 4 (2009): 11–5.
Чернуха, Г.Е. Гіперплазія ендометрія: перспективи розвитку проблеми / Г.Е. Чернуха, А.В. Асатурова, І.А. Іванов і др. // *Акушерство и гинекология*. – 2009. – №4. – С. 11–15.
13. Lehner, R., et al. "Quantitative Analysis of Telomerase hTERT mRNA and Telomerase Activity in Endometrioid Adenocarcinoma and in Normal Endometrium." *Gynecologic Oncology* 84 (2002): 120–5.
14. Litta, P., Bartolucci, C., Saccardi, C., et al. "Atypical endometrial lesions: hysteroscopic resection as an alternative to hysterectomy." *Eur J Gynaecol Oncol* 34.1 (2013): 51–3.
15. Clark, T.J., Mann, C.H., Shah, N., et al. "Accuracy of outpatient endometrial biopsy in the diagnosis of endometrial hyperplasia." *Acta Obstet Gynecol Scand* 80 (2001): 784–93.
16. Gallos, I.D., Krishan, P., Shehmar, M., et al. "Relapse of endometrial hyperplasia after conservative treatment: a cohort study with long-term follow-up." *Hum Reprod* 28 (2013): 1231–6.
17. Amalinei, C., Cianga, C., Balan, R., et al. "Immunohistochemical analysis of steroid receptors, proliferation markers, apoptotic related molecules, and gelatinases in non-neoplastic and neoplastic endometrium." *Ann Anat* 193.1 (2011): 43–5.
18. Jarboe, E.A., Mutter, G.L. "Endometrial intraepithelial neoplasia." *Semin Diagn Pathol* 27.4 (2010): 215–25.
19. Jianying, X.U., et al. "Expression of Survivin Gene among Human Normal Endometrium, Atypical Hyperplasia of Endometrium and Endometrial Carcinoma." *Journal of Reproduction and Contraception* 21.3 (2010): 129–35.
20. Reed, S.D., Newton, K.M., Garcia, R.L., et al. "Complex hyperplasia with and without atypia: clinical outcomes and implications of progestin therapy." *Obstet Gynecol* 116 (2010): 365–73.
21. Monaghan, P. "Organismal stress, telomeres and life histories." *The Journal of Experimental Biology* 217 (2014): 57–66.
22. Ozdegirmenci, O., Kayikcioglu, F., Bozkurt, U., et al. "Comparison of the efficacy of three progestins in the treatment of simple endometrial hyperplasia without atypia." *Gynecol Obstet Invest* 72 (2011): 10–4.
23. Park, J.Y., Lee, S.H., Seong, S.J., et al. "Progestin retreatment in patients with recurrent endometrial adenocarcinoma after successful fertility sparing management using progestin." *Gynecol Oncol* 129 (2013): 7–11.
24. Kotdawala, P., Kotdawala, S., Nagar, N. "Evaluation of endometrium in perimenopausal abnormal uterine bleeding." *J Midlife Health* 4.1 (2013): 16–21.
25. Orbo, A., Ames's, M., Myreng, L., et al. "HE4 is a novel tissue marker for therapy response and progestin resistance in medium- and low-risk endometrial hyperplasia." *British Journal of Cancer* 115.9 (2016). DOI: 10.1038/bjc.2016.330

THE RETROSPECTIVE ANALYSIS RESULTS OF THE ENDOMETRIAL TISSUE PATHOLOGICAL CONDITIONS DEVELOPMENT

V.V. Artyomenko, MD, professor, Obstetrics and Gynecology Department No. 2, Odesa National Medical University, Odesa

Z.V. Chumak, PhD, assistant, Obstetrics and Gynecology Department No. 2, Odesa National Medical University, City Center for Climacteric Problems, Odesa

M.V. Shapoval, MD, professor, Obstetrics and Gynecology Department No. 2, Odesa National Medical University, Odesa

Hyperplastic processes of endometrium are one of the most common pathologies of the uterus mucosa, an interest in its study is due to an increase in the frequency of occurrence, the ability to both self-healing and malignancy.

Purpose of the study: to investigate the detection rate of endometrial proliferative changes depending on the age of woman.

Materials and methods. A retrospective medical documentation analysis of the Department of Pathology was conducted. 2196 pathologic findings of endometrial tissue samples were investigated. 1404 specimen were hyperplastic states, 688 were endometrial polyps, and 104 others were endometrial states after total or subtotal uterine removal after surgery. Histological conditions were distributed according to patients' age categories. Results of the study were processed statistically using variation statistics with Student's criterion, using standard computer systems.

Results. The analysis shows an increase in frequency of endometrial proliferative changes in perimenopausal patients on the background of endometrial pathological changes detection in all age categories. Atypical forms of simple and complex hyperplasia of the endometrium can be traced in all age categories, with a maximum frequency of manifestation in similar age-related periods – 41–45 years and 46–50 years. Morphological signs of endometrial tissue malignancy were first established in the age group of 46–50 years, which coincides with the age of the onset of menopause in the Odesa region, with subsequent relative increase in the frequency and aggressiveness of the process with age. These age groups focus doctors to be more careful about pathological manifestations.

Conclusion. As a result of retrospective analysis of histopathological examinations it was found that the main factor in detecting pathological conditions of the endometrium is a woman's age of perimenopausal period, which can be considered as an early marker of diagnosis, leading to treatment prospects and general therapeutic tactics, for the future diagnostics and detection of others immunohistochemical and molecular genetic markers in women with hyperplastic processes in endometrial tissue.

Keywords: endometrial hyperplasia, atypical endometrial hyperplasia, malignancy.

РЕТРОСПЕКТИВНИЙ АНАЛІЗ РОЗВИТКУ ПАТОЛОГІЧНИХ СТАНІВ ЕНДОМЕТРІАЛЬНОЇ ТКАНИНИ

V.V. Артьоменко, д. мед. н., професор кафедри акушерства та гінекології №2 ОНМедУ, м. Одеса

Z.V. Чумак, к. мед. н., асистент кафедри акушерства і гінекології №2 ОНМедУ, лікар «Міського центру з проблем клімактерію», м. Одеса

M.V. Шаповал, д. мед. н., професор кафедри акушерства та гінекології №2 ОНМедУ, м. Одеса

В різних галузях медицини увага дослідників приділяється вивченню гіперпластичних процесів ендометрія з метою встановлення в розвитку цих патологічних змін тенденцій до малігнізації тканини та профілактики рецидивування.

Мета дослідження: вивчити частоту виявлення проліферативних змін ендометрія залежно від віку жінки.

Матеріали та методи. В результаті ретроспективного аналізу архівних даних медичної документації було проаналізовано 2196 патоморфологічних висновків щодо зразків ендометріальної тканини, з яких 1404 – гіперпластичні стани ендометрія, 688 – поліпи ендометрія, 104 – стан ендометріальної тканини після проведення оперативних втручань. Гістологічні результати були зіставлені з віковими категоріями та проаналізовані з використанням варіаційної статистики за критерієм Ст'юдента.

Результати. Проведений аналіз свідчить про зростання частоти проліферативних змін ендометрія в пацієнок перименопаузального віку на фоні проявів патологічних змін ендометрія в усіх вікових категоріях. При цьому пік гіперплазій ендометрія, в тому числі атипових, і поява аденокарцином припадає на вік 41–45 та 46–50 років, коли ризик переходу в малігнізацію і рецидивування є найвищими. Морфологічні ознаки малігнізації тканин ендометрія вперше були визначені у віковій групі 46–50 років, що збігається з віком настання менопаузи у мешканок Одеської області, з подальшим відносним збільшенням частоти та агресивності процесу з віком. Даний віковий проміжок вимагає від лікарів практичної медицини бути достатньо настороженими в діагностиці та спостереженні за характером перебігу патологічного стану.

Висновок. В результаті ретроспективного аналізу гістопатологічних досліджень було встановлено, що головним фактором виявлення патологічних станів ендометрія є вік жінки в періоді перименопаузи, який можна розглядати як ранній маркер діагнозу. Це обумовлює перспективи лікування та загальну терапевтичну тактику для подальшої діагностики та виявлення інших імуногістохімічних та молекулярно-генетичних маркерів у жінок із гіперпластичними процесами в ендометріальній тканині.

Ключові слова: гіперплазія ендометрія, атипова гіперплазія ендометрія, малігнізація.

РЕТРОСПЕКТИВНИЙ АНАЛІЗ РАЗВИТИЯ ПАТОЛОГИЧЕСКИХ СОСТОЯНИЙ ТКАНИ ЭНДОМЕТРИЯ

V.V. Артѐменко, д. мед. н., профессор кафедры акушерства и гинекологии №2 ОНМедУ, г. Одесса

Z.V. Чумак, к. мед. н., ассистент кафедры акушерства и гинекологии №2 ОНМедУ, врач «Городского центра по проблемам климактерия», г. Одесса

M.V. Шаповал, д. мед. н., профессор кафедры акушерства и гинекологии №2 ОНМедУ, г. Одесса

В различных сферах медицины внимание исследователей уделяется изучению гиперпластических процессов эндометрия с целью определения в развитии этих патологических изменений тенденций к малигнизации ткани и профилактики рецидивирования.

Цель исследования: изучить частоту выявления пролиферативных изменений эндометрия в зависимости от возраста женщины.

Материалы и методы. В результате ретроспективного анализа архивных данных медицинской документации было проанализировано 2196 патоморфологических заключений по образцам эндометриальной ткани, из которых 1404 – гиперпластические состояния эндометрия, 688 – полипы эндометрия, 104 – состояние ткани эндометрия после проведения оперативных вмешательств. Гистологические результаты были сопоставлены с возрастными категориями и проанализированы с использованием вариационной статистики по критерию Стьюдента.

Результаты. Проведенный анализ свидетельствует о росте частоты пролиферативных изменений эндометрия у пациенток перименопаузального возраста на фоне проявления патологических изменений эндометрия во всех возрастных категориях. При этом пик гиперплазий эндометрия, в том числе атипичных, и появление аденокарцином приходится на возраст 41–45 и 46–50 лет, когда риск перехода в малигнизацию и рецидивирование являются наивысшими. Морфологические признаки злокачественности тканей эндометрия впервые были обнаружены в возрастной группе 46–50 лет, что совпадает с возрастом наступления климакса у жительниц Одесской области, с последующим относительным увеличением частоты и агрессивности процесса с возрастом. Данный возрастной промежуток требует от врачей практической медицины быть достаточно настороженными в диагностике и наблюдении за характером течения патологического процесса.

Выводы. В результате ретроспективного анализа гистопатологических исследований было установлено, что основным фактором выявления патологических состояний эндометрия является возраст женщины в перименопаузальном периоде, который можно рассматривать как ранний маркер диагноза. Это обуславливает перспективы лечения и общую терапевтическую тактику для последующей диагностики и выявления других иммуногистохимических и молекулярно-генетических маркеров у женщин с гиперпластическими процессами в ткани эндометрия.

Ключевые слова: гиперплазия эндометрия, атипичная гиперплазия эндометрия, малигнизация.