

## Инфекционный эндокардит искусственного трансплантата после реконструкции левого желудочка (процедура Dor)

Чернов И. И.<sup>1</sup>, Энгиноев С. Т.<sup>1,2</sup>, Козьмин Д. Ю.<sup>1</sup>, Тарасов Д. Г.<sup>1,2</sup>

В течение последних 30 лет инфекционный эндокардит (ИЭ) становится все более серьезной проблемой в кардиологии и кардиохирургии. Несмотря на заметный прогресс, достигнутый в диагностике и лечении ИЭ, прогноз данного состояния все еще остается плохим, а уровень смертности достигает 15-30% [1, 2]. Риск развития ИЭ особенно высок у пациентов с искусственными материалами в сердце (искусственные клапаны, разнотипные протезы, имплантируемые антиаритмические устройства). В настоящей статье представлен редкий клинический случай ИЭ искусственного трансплантата, возникший после реконструкции левого желудочка (процедура Dor).

Российский кардиологический журнал. 2019;24(8):104–106  
<http://dx.doi.org/10.15829/1560-4071-2019-8-104-106>

**Ключевые слова:** процедура Dor, эндокардит трансплантата.

**Конфликт интересов:** не заявлен.

**Благодарность:** мы благодарим профессора Владимира Алекси-Месхишвили за помощь в написании данной работы.

<sup>1</sup>Федеральный центр сердечно-сосудистой хирургии, Астрахань; <sup>2</sup>Астраханский государственный медицинский университет, Астрахань, Россия.

Chernov I. I. — Ph.D., Deputy Chief Physician for Surgery, Department of cardiac surgery № 3, ORCID: 0000-0002-9924-5125, Enginoev S. T.\* — cardiovascular surgeon, Department of cardiac surgery № 3, ORCID: 0000-0002-8376-3104, Kozmin D. Y. — Head of the Cardiac Surgery Department № 3, ORCID: 0000-0002-6999-9671, Tarasov D. G. — Ph.D., Chief doctor, Department of cardiac surgery № 3, ORCID: 0000-0002-0866-3939.

\*Автор, ответственный за переписку (Corresponding author):  
 Soslan.Enginoev@gmail.com

CABG — coronary artery bypass grafting, LV — left ventricle, ECG — electrocardiography, TTE — transthoracic echocardiography, CT — computed tomography, CA — coronary angiography, CPB — cardiopulmonary bypass.

Рукопись получена 26.06.2019  
 Рецензия получена 15.07.2019  
 Принята к публикации 16.07.2019



## The infective endocarditis of synthetic patch after left ventricle reconstruction (Dor procedure)

Chernov I. I.<sup>1</sup>, Enginoev S. T.<sup>1,2</sup>, Kozmin D. Y.<sup>1</sup>, Tarasov D. G.<sup>1,2</sup>

Infective endocarditis (IE) has become an increasingly significant problem in cardiology and cardiac surgery over the past 30 years. Despite the noticeable progress made in the diagnosis and treatment of IE, the prognosis for this condition is still poor and the mortality rate reaches 15-30% [1, 2]. The risk of developing IE is especially high in patients with “intracardiac” artificial materials (artificial valves, prostheses of any type, implantable antiarrhythmic devices). This article presents a rare clinical case of IE of a synthetic patch after left ventricle reconstruction (Dor procedure).

Russian Journal of Cardiology. 2019;24(8):104–106  
<http://dx.doi.org/10.15829/1560-4071-2019-8-104-106>

**Key words:** Dor procedure, patch endocarditis.

**Conflicts of interest:** nothing to declare.

**Acknowledgment:** we thank Prof. Vladimir Alexi-Meskishvili for assistance with this article.

<sup>1</sup>Federal Center for Cardiovascular Surgery, Astrakhan; <sup>2</sup>Astrakhan State Medical University, Astrakhan, Russia.

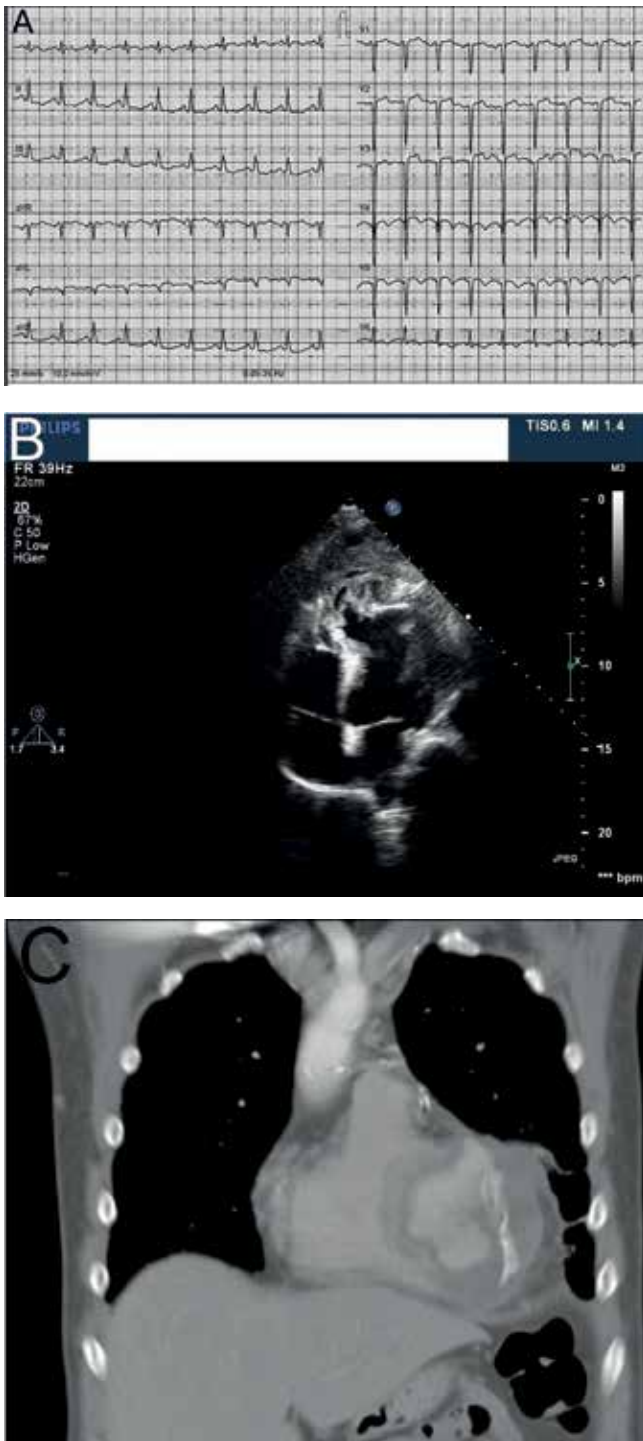Chernov I. I. ORCID: 0000-0002-9924-5125, Enginoev S. T. ORCID: 0000-0002-8376-3104, Kozmin D. Y. ORCID: 0000-0002-6999-9671, Tarasov D. G. ORCID: 0000-0002-0866-3939.

**Received:** 26.06.2019 **Revision Received:** 15.07.2019 **Accepted:** 16.07.2019

Infective endocarditis (IE) has become an increasingly significant problem in cardiology and cardiac surgery over past 30 years. Despite noticeable progress made in the diagnosis and treatment of IE, prognosis for this condition is still poor and mortality rate reaches 15-30% [1, 2]. The risk of developing IE is especially high in patients with “intracardiac” artificial materials (artificial valves, prostheses of any type, implantable antiarrhythmic devices). This article presents a rare clinical case of secondary IE on a synthetic patch after left ventricular (LV) reconstruction surgery by Dor procedure.

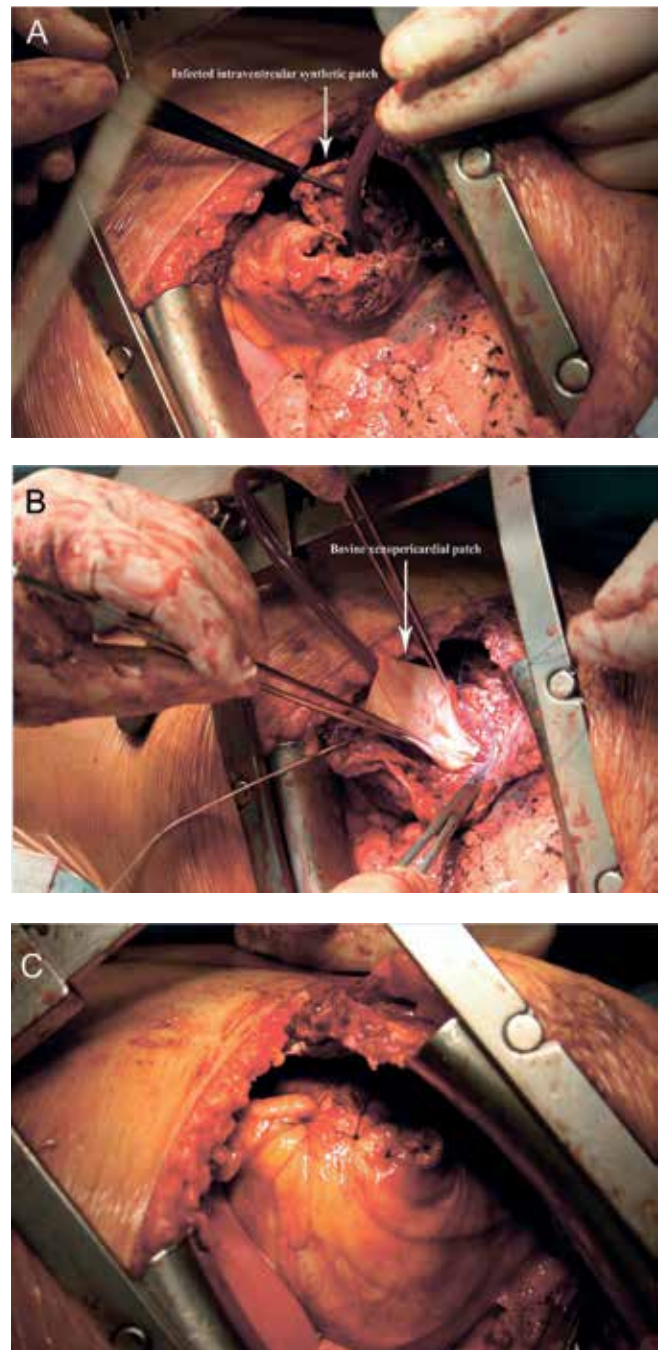
### Case report

A 49-year-old male patient presented with severe weakness, constant chest pain, significant shortness of breath on minimal exertion, chills and fever up to 39.2 C. From the history of the present illness: in January 2011 he suffered anterior ST-segment elevation myocardial infarction. In May 2011, he underwent CABG, Dor’s procedure and LV thrombectomy through a median sternotomy in another institute. Since October 2011, he began to notice an increase in body temperature up to 39.2 C. The patient did not undergo any other procedure



**Figure 1.** (A) ECG images show a cicatricial changes of the LV myocardium. (B) TTE images show a floating structure was located in the apical area (patch), with pseudoaneurysm formation about 30 cm<sup>2</sup>, filled with heterogeneous, loose, hypoechoic thrombotic masses and floating in the LV cavity vegetations. (C) Chest contrast CT images show a thrombotic masses in the LV cavity, detachment of the synthetic patch with the formation of a false aneurysm.

or operation. During an examination in November 2011, according to the cardiac echo, vegetations were found on the IVS, and therapy with antibiotics was started. In December, increased body temperature began to be



**Figure 2.** (A, B and C) Intraoperative photographs showing infected synthetic patch of previous LV plasty was detached by 2/3 of the perimeter, then the plasty of the defect of the LV wall was performed with a Bovine xenopericardial patch and the final look.

recorded again and in blood cultures — *Staphylococcus aureus* was present. ECG revealed a sinus tachycardia with the heart rate 120 min, cicatricial changes of the LV myocardium (Fig.1A). TTE revealed ejection fraction of LV 40%, and a floating structure was located in the apical area (patch), with pseudoaneurysm formation about 30 cm<sup>2</sup>, filled with heterogeneous loose hypoechoic thrombotic masses and floating in the LV cavity

vegetations, (Fig.1B). Chest contrast CT revealed a thrombotic masses in the LV cavity, detachment of the synthetic patch with the formation of a false aneurysm. (Fig.1C). CA demonstrated an occlusion of the left anterior descending artery and 75% stenosis of the circumflex artery. Functioning grafts after CABG. Operation was performed through left anterolateral thoracotomy in 4th intercostal space after cannulation of groin vessels and on normothermic CPB on beating heart. The revision revealed that the walls of the false LV aneurysm were adjunct to the inner surface of the chest, the diaphragm and the lower lobe of the left lung as a solid inflamed fibrous conglomerate. The pseudoaneurysm was separated from the surrounding tissues in a sharp and blunt way. During dissection the edge of the lower lobe of the left lung which was intimately involved in the inflammatory process was damaged. An atypical resection of the lower lobe segment was performed. The cavity of the aneurysm was opened and thrombotic masses and vegetation were removed as well from the cavity of the LV and taken to bacteriological investigation, which showed later the presence of *Staphylococcus aureus*. Appropriate antibiotics (Linezolid, Meropenem) were administered postoperatively. The synthetic patch of the previous LV-plasty was detached by 2/3 of the perimeter, cut off and removed. Mitral valve leaflets with no restriction of motion, nor inflammatory changes. The plasty of the LV wall defect was performed with a Bovine xenopericardial patch (Fig. 2A, B and C).

#### Outcome and follow up:

The postoperative period was complicated with renal and cardiovascular failure. The patient was sent home on the 14th day. The period of postoperative follow-up was 7 years, during which no complications or relapse of infective endocarditis recorded.

#### Discussion

The polymorphism of the clinical picture of IE, associated both with the participation of microorganisms

participating in the infectious process, and with the initial somatic condition of the patient, makes his diagnosis difficult and requires a multidisciplinary approach, involving participation in the competition of specialists of different profiles. In clinical practice, there is often a link between the syndrome of infection and the recent involvement of the endocardium.

In 1976, Looser KG, et al. first described the case of an infection of a cardiac suture line after ventricular aneurysmectomy [3]. McHenry MC, et al. in 1988 conducted an extensive review of such patients, left ventricular false aneurysms were identified in 15 of the 25 patients, in the etiology of *Staphylococci* and gram-negative bacilli were the most frequent [4]. In literature, the only case of IE was described after the Dor procedure. Bartczak-Rutkowska A, et al. [5] described the case of *Staphylococcus aureus* IE of intraventricular patch after the Dor procedure, which developed 30 years after the initial operation. In this case surgical intervention was done. In our patient, left anterolateral thoracotomy gave a wide and direct access to the LV, and we believe that this approach is preferred to redo sternotomy. In the present case, the diagnosis was presented based on two main criteria (positive blood culture and vegetation based on TTE data) and one secondary criteria (fever). Active surgical approach in combination with the antibiotic regimens allowed for effective treatment of our patient with stable long-term results.

#### Conclusion

The presented clinical case emphasizes that intracardiac artificial materials (in this case, a synthetic patch) can become a substrate for development and maintenance of a systemic infection. The occurrence of fever in patients undergoing cardiac surgery should always alert and force attending physician to rule out IE.

**Acknowledgment.** We thank Prof. Vladimir Alexi-Meskhishvili for assistance with this article.

**Conflicts of Interest:** none declared.

#### Литература/References

1. Leone S, Ravasio V, Durante-Mangoni E, et al. Epidemiology, characteristics, and outcome of infective endocarditis in Italy: the Italian Study on Endocarditis. *Infection*. 2012;40:527-35. doi:10.1007/s15010-012-0285-y.
2. Delahaye F, Alla F, Beguinot I, et al. In-hospital mortality of infective endocarditis: prognostic factors and evolution over an 8-year period. *Scand. J. Infect.* 2007;39:849-57. doi:10.1080/00365540701393088.
3. Looser KG, Allmendinger PD, Takata H, et al. Infection of cardiac suture line after ventricular aneurysmectomy. Report of two cases. *J Thorac Cardiovasc Surg* 1976;72:280-1.
4. McHenry MC, Longworth LD, Rehm JS, et al. Infections of the Cardiac Suture Line after Left Ventricular Surgery. *The American Journal of Medicine*. 1988;85:292-300.
5. Bartczak-Rutkowska A, Oko-Sarnowska Z, Rajewska J, et al. *Pol Arch Intern Med*. 2018;128(7-8):480-1. doi:10.20452/pamw.4279.