

MULTIPLE CAVITARY LUNG LESIONS WITH AIR-FLUID LEVEL – CLINICAL DIAGNOSIS TRAPS – CASES PRESENTATION

Simona-Stefania Dobre^{1,2}, Simin-Aysen Florescu^{1,2}, Petre Iacob Calistru^{1,2}, Maria Nica^{1,2}, Alma Kosa¹

¹Hospital for Infectious and Tropical Diseases „Dr. Victor Babes“, Bucharest

²University of Medicine and Pharmacy „Carol Davila“, Bucharest

ABSTRACT

Cavitary lung lesions may pose complex problems in terms of differential diagnosis as their etiological spectrum includes:

– Necrotizing infections (pneumonia, pulmonary tuberculosis, fungi and parasites abscesses)
– Non-infectious diseases: (lung cancer with necrosis, infected cavitating pulmonary infarction, vasculitides, collagenoses with lung cavity by immunological mechanism, the suction of a foreign body intrabronchially, congenital lung malformations, pneumoconiosis excavated etc).

We present three clinical cases with similar radiological images or multiple formations lung cavity fluid level but with different diagnoses and etiologies: Staphylococcus aureus strain MRSA sepsis, echinococcosis with multiple sites and pulmonary tuberculosis secondary caseous-cavitary form. Selected all three cases, standard chest radiography was the basic investigation lung disease diagnosis, but accurate diagnosis requires performing other investigative methods.

Keywords: pneumatocele, pulmonary echinococcosis, secondary pulmonary tuberculosis

INTRODUCTION

Cavitary lung lesions may pose complex problems in terms of differential diagnosis as their etiological spectrum includes:

- Necrotizing infections (pneumonia, pulmonary tuberculosis, fungi and parasites abscesses)
- Non-infectious diseases: (lung cancer with necrosis, infected cavitating pulmonary infarction, vasculitides, collagenoses with lung cavity by immunological mechanism, the suction of a foreign body intrabronchially, congenital lung malformations, pneumoconiosis excavated etc).

CASE PRESENTATIONS

Patient 1

The first case is that of a 43 years old, male, smoker (35 PA), consumer of injectable drugs from

the age of 14 (heroin and ethnobotanical), presented for fever, chest pain and progressive weakness. From anamnesis, we retain thoracic jungle, located at the level of the right hemodialysis, with posterior irradiation, without antalgic position, and which increases during movement and physical exercise, started about 6 months before admission and with progressive accentuation; physical asthenia, one week before admission, with progressive aggravation, to severe muscle weakness, motor deficit, inability to move; and the last three days before admission the patient has fever, chills and progressive dyspnea.

From the personal pathological history, we note chronic hepatitis with hepatitis virus C, diagnosed about one and a half years ago after a laboratory test, and multiple dental abscesses last year, self-medicated by the patient with Augmentin.

Corresponding author:

Simona-Stefania Dobre, Hospital for Infectious and Tropical Diseases „Dr. Victor Babes“, Infectious Diseases Department, 281 Mihai Bravu Av., Bucharest

E-mail: simonabucsa@yahoo.com

The patient is a social case: homeless and without occupation.

Physical examination on admission revealed an underweight patient (W = 49 Kg, H = 170 cm, BMI = 17.5) with the altered state of consciousness, paleness, febrile (T = 38.7°C), pulmonary stethoscopic presence of rheumatic and subcrepant bronchial rheumatism bilaterals, predominantly on the right, O₂ = 96% was in the air, AV = 96/min, TA = 100/70 mmHg.

The investigations carried out on admission showed: important leukocytosis with neutrophilia (L = 18,400/ml, neutrophil = 91.8%), thrombocytopenia (platelets = 88,700/ml), inflammatory syndrome (ESR = 75 mm/h, CRP = 15.6 mg/dL, a positive procalcitonin = 10 mg/dl), hyponatremia with hypokalemia (Na = 121 mmol/L, K = 3.2 mmol/L); virological balance showed negative HBsAg, HCV Ab positive, HIV negative.

Blood cultures were taken which were positive in 2 days after admission for *Staphylococcus aureus*, strain MRSA positive with the DSTresult.

Standard pulmonary radiography highlights: multiple alveolar opacities, some homogeneous, others with hydroaeric levels (pneumatocele) bilaterally diffused, laterotoracic, diameters 1-5 cm, suggestive of pulmonary staphylococcus (Fig. 1).

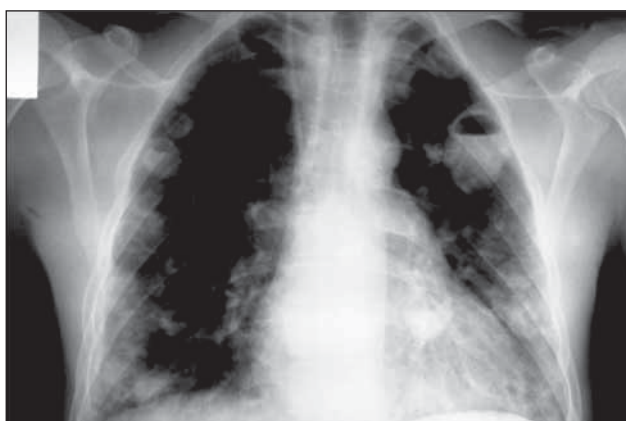

FIGURE 1. Chest X-ray patient 1 – Pneumatocele

Given the laboratory results and radiological examination, the investigational balance was filled with other imaging investigations.

Transthoracic echocardiography describes mobile formations of 8 to 17 mm in the aortic valve, with the appearance of vegetation, normal VS cavity with normal global and segmental systolic function.

The thoraco-abdominal CT scan of the contrast agent showed: multiple round-oval, well-defined, cystic, lesions with a circumferentially thick discrete wall and fluid content with gaseous inclusions, some of which appeared completely evacuated, containing air at the level of both lungs, the

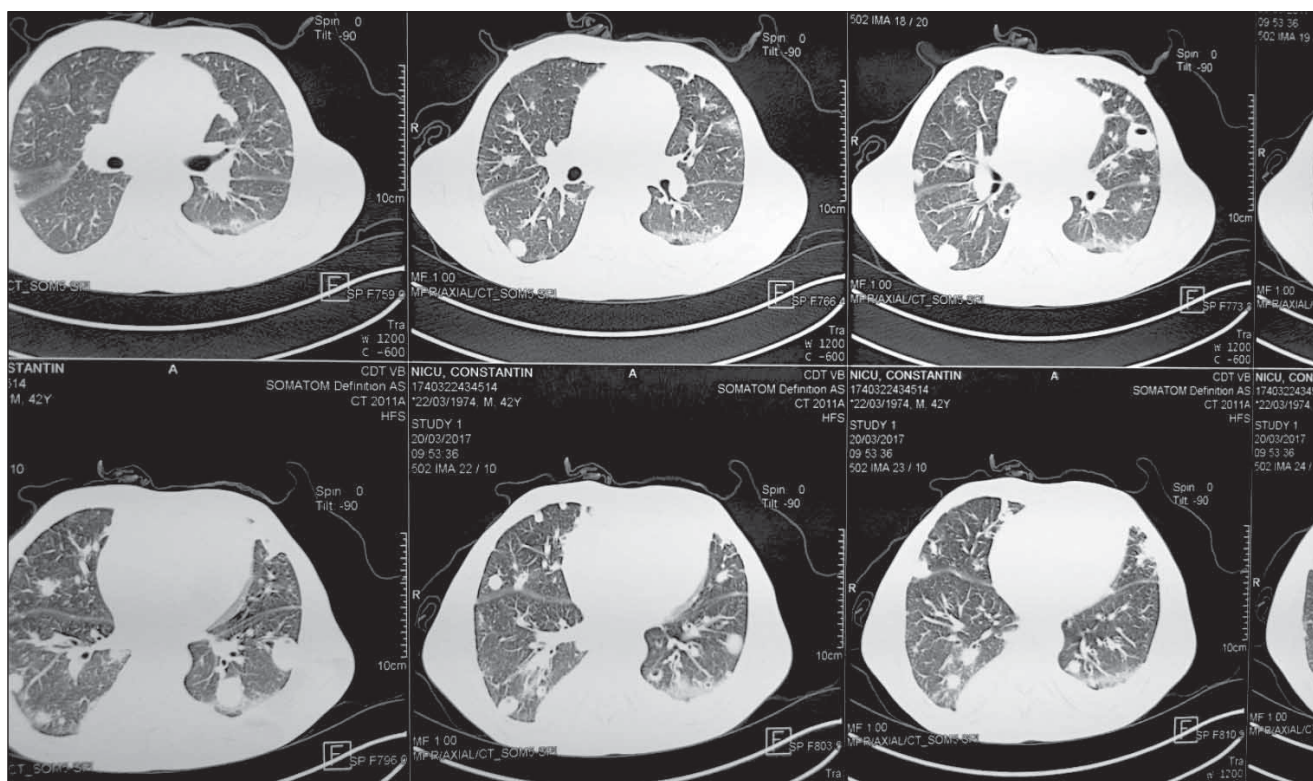


FIGURE 2. Thoracic CT scan, patient 1 – Pneumatocele. Bilateral pleural effusion.

largest being 22 mm on the right and 55 mm on the left; pouring liquid free and partially cloazionate at the level of both pleural cavities having a maximum thickness of 26 mm to the right and 28 mm to the left (Fig. 2).

On the basis of anamnesis, clinical, paraclinical and imaging data, the positive sepsis diagnosis with *Staphylococcus aureus* strain MRSA, infectious endocarditis with MRSA with pulmonary septic determinations in a patient with hepatitis C chronic hepatitis C, ethnobotanic toxicomania.

Patient 2

The second case is that of a 47-year-old, from rural, housewife, known with mildly persistent bronchial asthma following intermittent treatment with inhaled corticosteroids and beta 2 long-acting inhaled agonist, presented to our clinic for a two month dry cough with the appearance of seromucous expectoration in the last week.

The general clinical examination does not reveal anything pathological in the respiratory system.

The present pulmonary X-ray shows more nodular opacities in both pulmonary fields, predominantly in the right pulmonary field, two of them having a air-fluid level (Fig. 3).

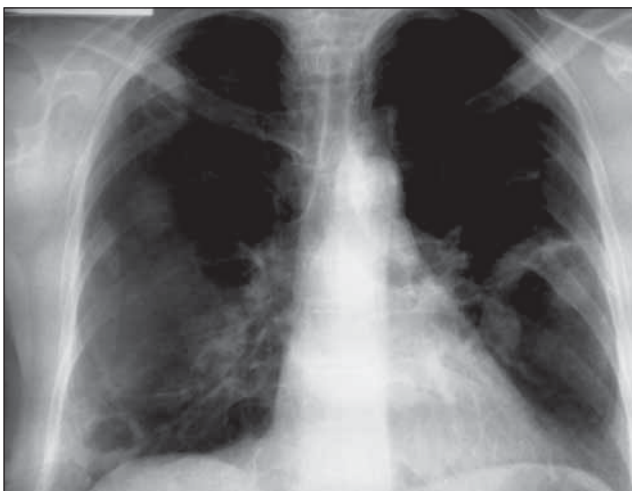

FIGURE 3. Chest X ray patient 2. Air-fluid images disseminated in both lung fields predominant right – pulmonary hydatidosis

Bronchoscopy is performed, which does not reveal bronchial endoluminal changes in the studied territory, and the performed bronchial-alveolar lavage shows a cellularity with predominance of eosinophils without malignant cells. Ziehl-Neelsen

staining from lavaging is negative for alcohol-resistant bacilli; the culture for BK from the bronchial aspiration on the liquid medium (MB/BacT-Alert method) is seeded with a negative result.

The laboratory data points marked leukocytosis with eosinophilia (WBC = 14.300/ml, eosinophils = 9.337/ml = 15,3%), inflammatory biological syndrome (ESR = 68 mm/h, CRP = 2,35 mg/dl, fibrinogen = 572 mg/dl), negative blood cultures and positive serology for *Echinococcus granulosus*; in this context, abandoning the transthoracic biopsy, which could have been performed for differential diagnosis and which would have had unfavorable implications (anaphylactic shock, secondary hydatidosis).

Positive diagnosis was of multiple pulmonary hidatid cysts.

Further investigations are necessary to detect other visceral locations. Abdominal ultrasound reveal three transonic formations, round-oval, with maximum diameters of 1,4 cm, 2.5 cm and 5 cm, irregular shape, the fine septa on the inside, located in the liver sections IV and VI, suggestive of hepatic echinococcosis.

The final diagnosis was echinococcosis with multiple synchronous, hepato-pulmonary localizations.

Patient 3

It is a 58 years old patient, heavy smoker (PA = 40), which is addressed to the specialty ambulatory for the first two months of symptomatology, dry cough, marked asthenia and a week before cough presentation with mucopurulent expectoration, intermittent hemoptotic and subfebrile condition.

At presentation, underweight patient, afebrile, pale skin and mucous membranes, lung auscultation perceive right ronflante rales, SaO₂ = 97% in room air.

Biologically, mild leukocytosis is discovered (WBC = 11,200/ml), mild anemia, hypochromic (Hb = 10.3 g/dl), hyperglycemia (blood glucose = 168 mg/dl).

In standard pulmonary radiograph, two round-ovate, irregularly-shaped cavity images are embedded in an area of infiltrative and fibrous lesions, occupying the upper right lobe (Fig. 4).

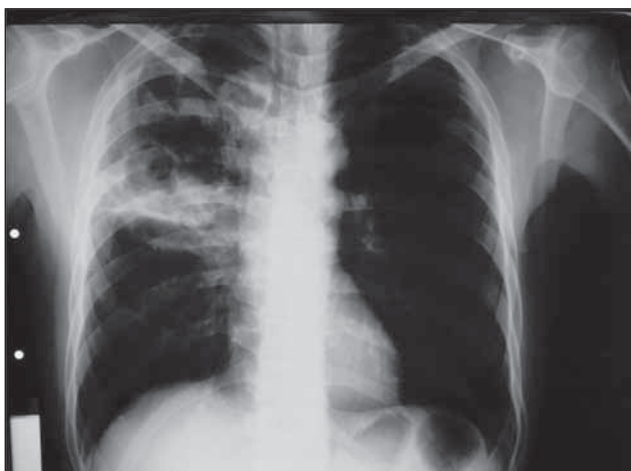

FIGURE 4. Postero-anterior radiography of the patient 3. Apical cavitory fibrocaceous tuberculosis

There is a clinical-radiological suspicion of pulmonary tuberculosis being performed a sputum examination; the rapid GeneXpert method that detected RMP sensitive *Mycobacterium tuberculosis* DNA. The positive diagnosis was secondary pulmonary tuberculosis, fibrocaceous-cavitory form.

DISCUSSIONS

The cases presented are of interest in the etiological diagnosis problem; early diagnosis is of great practical importance, because allow timely treatment can stop the evolution of the pathological process.

Hydatid cyst (CH) is a parasitic disease caused by *Echinococcus granulosus* *Taenia*, common in our country (1). The index of morbidity in Romania, varied in the years 1953-1963 between 5 and 7 per 100,000. In the period 1991-1995 there have reported about 1,000 new cases per year and the mortality index fluctuated between 5 and 7%. The incidence of cases in Romania is higher in Dobrogea and in the central area (1).

In Romania, echinococcosis is endemic. The most frequent localization is the liver (60%), followed by the lungs. Multivariate echinococcosis is defined as the concomitant or sequential presence of hydatidosis in more than one organ (2). It was noted that the number of cases of multiple hydatid cysts and pluriviscerale locations has increased in recent years (3). In literature, the incidence of hydatid cyst with multiple localizations varies between 0.2 and 2% depending on the different authors and the endemic area (4). Currently, worldwide, it is considered that, on average, out of

100 cases of human hydatidosis, 5.1 cases ends with death, 18.8 cases require repeated surgery and 76.1 patients are medically treated for years (5).

The pulmonary hydatid cyst, partially evacuated and over-infected, may evolve with equivocal radiological images for this diagnosis.

The differential diagnosis of pulmonary suppuration after vomiting and the discovery of hydroaeric imaging should exclude pleuropulmonary cavities of another nature (tuberculous cavern, excavated cancer, air cyst, bronchiectasis, interlobar emphysema, fistulised bronchus), which differ from antecedents, evolution, clinical context and complementary investigation data.

Among infectious bacterial causes in staphylococcal pneumonia, the most characteristic lesions is multiple cavity images with air-fluid level (pulmonary pneumatocele).

Pulmonary tuberculosis can be complicated by pleuro-pulmonary staphylococci, increasing the difficulty and complexity of the etiologic diagnosis, modulating the therapeutic attitude. Examination of staphylococcal etiology through appropriate bacteriological examinations resolves the diagnostic problem, but does not rule out the possibility of coexisting disease with other prior pulmonary disease superinfected with staphylococcus.

Pulmonary tuberculosis is another pathological entity that can have pulmonary cavity imaging with or without fluid and air leakage level. Romania is the EU country with the highest incidence of tuberculosis (4 times above the EU average), in recent years, good progress was made in controlling the disease; the overall incidence decreased by 49.8% (from 142.2% in 2002 to 71.7% in 2016) (6).

Based on the radiological examination, suspicion of pulmonary Tb was raised. The diagnosis of certainty was established on the basis of the bacteriological examination, using linear hybridization methods recommended by current WHO guidelines (7,8,9).

In the case presented, the Xpert MTB/RIF test, a rapid diagnosis test, which allows less than 2 hours simultaneously detects *Mycobacterium tuberculosis* complex (MTBC) and resistance to rifampin (RIF), allowing the doctor to determine the correct therapeutic decision and in minimal time.

The Xpert MTB/RIF test for use with the Cepheid GeneXpert® System is a semi-quantitative

nested real-time PCR in-vitro diagnostic test for: 1) the detection of *Mycobacterium tuberculosis* complex DNA in sputum samples or concentrated sediments prepared from induced sputa and 2) the detection of rifampinresistance associated mutations of the *rpoB* gene (10).

As a principle, the GeneXpert Dx System integrates and automates sample processing, nucleic acid amplification, and detection of the target sequences in simple or complex samples using real-time PCR and reverse transcriptase PCR. The system requires the use of single-use disposable GeneXpert cartridges that hold the PCR reagents and host the PCR process. Because the cartridges are self-contained, cross-contamination between samples is eliminated (10).

Xpert MTB/RIF includes reagents for the detection of tuberculosis and RIF resistance as well as a sample processing control (SPC) to control for adequate processing of the target bacteria and to mon-

itor the presence of inhibitor(s) in the PCR reaction (10).

CONCLUSIONS

The common feature of all the cases presented is the monomorphic radiological aspect that contrasts with the etiological polymorphism.

Differential diagnosis of cavitory lung formations is often laborious, requiring many procedures: imaging (conventional radiology, contrast – enhanced CT) scan, bronchoscopy with bronchoalveolar lavage, transbronchial biopsy, transthoracic needle biopsy, serological and immunological lab tests, microbiological investigations.

The conventional chest radiography remains one of the basic methods in the diagnosis of lung diseases, but sometime requires supplementation with other methods of investigation with accuracy higher to guide for correct diagnosis.

REFERENCES

1. **Burlui D., Roșca Monica** Tratatamentul chirurgical al chistului hidatic hepatic, Ed. Medicală, 1977: 8-9, 19-24
2. **Grozavu C.** Echinococoză pluriviscerală. Chirurgia localizărilor toracoabdominale. București: Editura Universitară Carol Davila, 2008.
3. **Niculescu D., Ene D., Negru D., Crumpei Felicia.** Hidatidoza primitivă cu localizări multiple sincrone
4. **Akal M., Kara M.** Primary hydatid cyst of the posterior cervical triangle, Department of Thoracic Surgery, *J Laryngol Otol.* 2002 Feb;116(2): 153-155
5. Echinococoză/hidatidoza umană în RM – studiu retrospectiv, Materialele congresului VI al igieniştilor, epidemiologilor și microbiologilor din RM, 23-24 octombrie 2008
6. <http://gov.ro/ro/sedinte-guvern/Strategia-nationala-de-control-a-tuberculozei-in-Romania-2015-2020>
7. **Tănăsescu Mihaela, Didilescu Cristian, Marica Constantin** Prezent și perspective în diagnosticul rapid molecular al tuberculozei și al MDR-TB
8. **Babady N. Esther, Wengenack Nancy L.** Clinical Laboratory Diagnostics for *Mycobacterium tuberculosis* (2012), Understanding Tuberculosis – Global Experiences and Innovative Approaches to the Diagnosis, Dr. Pere-Joan Cardona (Ed).
9. **Moisoiu A.** Old and new methods for the laboratory diagnosis of tuberculosis and for the detection of resistant strains to anti-tuberculosis drugs. rjid.com.ro/articles/2014.1/Infectio_Nr-1_2014_Art-7.pdf
10. GeneXpert Dx System Operator Manual 301-0045 Rev. C, June 2012