

# ACUTE UPPER AIRWAY OBSTRUCTION IN RHEUMATOID ARTHRITIS: CASE REPORT AND LITERATURE REVIEW

Iulia Szabo<sup>1</sup>, Cristina Tiple<sup>2</sup>, Magdalena Chirila<sup>2,3</sup>, Simona Rednic<sup>1,4</sup>

<sup>1</sup>Rheumatology Department, Emergency Clinical County Hospital, Cluj-Napoca

<sup>2</sup>ENT Department, Emergency County Hospital, Cluj-Napoca

<sup>3</sup>ENT Department, Iuliu Hatieganu University of Medicine and Pharmacy, Cluj-Napoca

<sup>4</sup>Rheumatology Department, Iuliu Hatieganu University of Medicine and Pharmacy, Cluj-Napoca

## Abstract

**Introduction.** Cricoarytenoid arthritis in rheumatoid arthritis (RA) is not infrequent and symptoms can range from mild, nonspecific laryngeal complaints to acute upper airway obstruction.

**Case report.** We report a case of bilateral vocal cord palsy due to cricoarytenoid joint (CAJ) involvement in a RA patient presenting with respiratory distress and stridor. The diagnosis was confirmed by flexible laryngoscopy. The patient responded well to systemic corticosteroids and did not require tracheostomy. There was no recurrence of the symptoms after corticosteroid dose tapering and the patient was discharged after 2 weeks.

**Conclusion.** Cricoarytenoid arthritis should be suspected in RA patients presenting with acute airway compromise. Prompt recognition of this condition and appropriate management can be life-saving.

**Keywords:** cricoarytenoid arthritis, rheumatoid arthritis, airway obstruction

## INTRODUCTION

Rheumatoid arthritis (RA) is an autoimmune disease characterized by symmetric polyarthritis mainly of the diarthrodial joints leading to bone erosions and joint destruction (1). Cricoarytenoid joint (CAJ) involvement is not uncommon (17% to 70% of patients with RA) but it rarely evolves to bilateral vocal cord palsy and laryngeal stenosis (2). Cricoarytenoid arthritis may be asymptomatic or may present with nonspecific symptoms, such as hoarseness, dysphagia, odynophagia, foreign body sensation in the throat, especially when swallowing or speaking, and reflex otalgia (3). Bilateral acute inflammation or ankylosis of the CAJ can progress to dyspnea, inspiratory stridor and peripheral cyanosis due to fixation of the vocal cords in adduction and subsequent airway obstruction (4). In this setting urgent tracheostomy is often required (5).

The purpose of this case report is to raise awareness of this potential life-threatening complication in RA and discuss potential therapeutic interventions.

## CASE REPORT

A 74-year-old woman with a 3 year history of stage IV seropositive RA and severe osteoporosis with vertebral collapse presented to the emergency ENT ward with signs of acute upper airway obstruction: shortness of breath and stridor (see Fig. 1). Inflammatory symmetric polyarthritis of the hands, feet and joint deformities appeared 5 years prior to the first medical visit. At the time of diagnosis the patient had already severe articular compromise. The patient reported hoarseness, sense of fullness in the throat and progressive inspiratory dyspnea over the past month. She also described sore throat, reflex ear pain and painful speech a few days prior to hospitalization. She was currently treated with methotrexate (MTX) 20 mg/week and alendronate 70 mg/week. Physical examination revealed ulnar deviation of the hands, cocking-up deformities and subluxation of the metatarsophalangeal joints, restricted range of motion in both elbows, tachypnea, inspiratory stridor in the upper airways on chest auscultation.

Correspondence address:

Iulia Szabo, Liviu Rebreanu Street, No. 17A, Ap. 6, Cluj-Napoca

E-mail: iulia\_szabo90@yahoo.com

tion and a 94% peripheral oxygen saturation in room air.

No pulmonary consolidations or pleural effusions were detected on chest radiography. Laryngeal endoscopy was performed demonstrating paramedian fixation of the right vocal fold and impairment of the left vocal fold in abduction with the anterior plunging of both arytenoids and decreased airway opening. The concave appearance of the right vocal fold suggested an older mobility disorder because of the tendency to atrophy of the thyroid-arytenoid muscle (Fig. 2). These findings were consistent with bilateral vocal fold paralysis in adduction – Gerhardt Syndrome – due to cricoarytenoid arthritis. Laboratory studies identified high levels of CRP 6.62 mg/dl and

rheumatoid factor 61.7 UI/ml with no alterations of the complete blood count.

Systemic corticosteroids (methylprednisolone 250 mg) and nebulized dexamethasone were administered immediately with resolution of dyspnea and stridor in the following hours. Intravenous methylprednisolone 250 mg was continued for 4 days, with dose tapering to 43.75 mg for another 2 days. Follow-up laryngoscopy after one week revealed persistent paralysis of the right vocal cord, improved mobility of the left vocal fold and significant widening of the glottis opening (Fig. 3).

The patient was transferred to the rheumatology department for further assessment of rheumatoid arthritis disease activity, presence of other potential

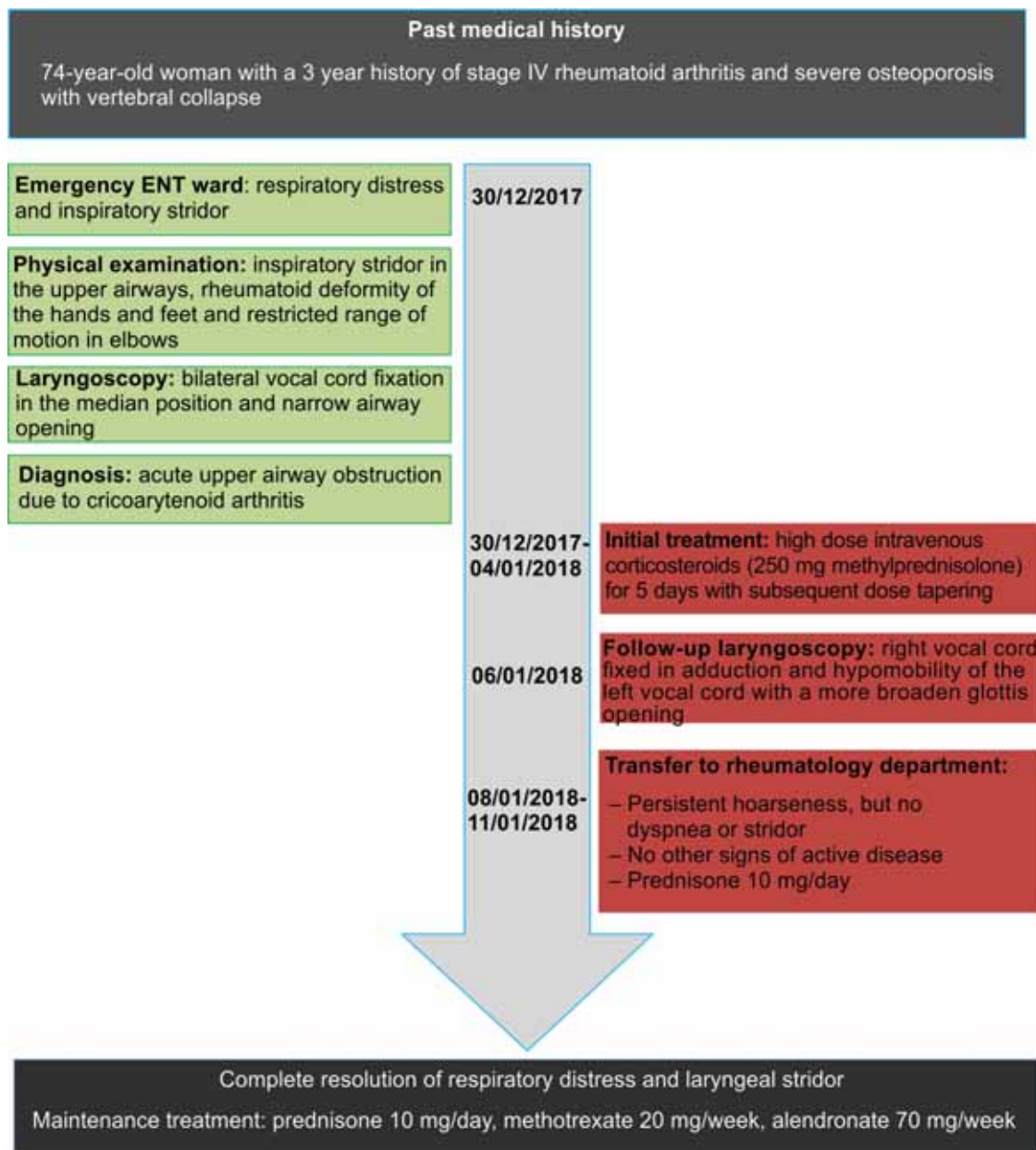
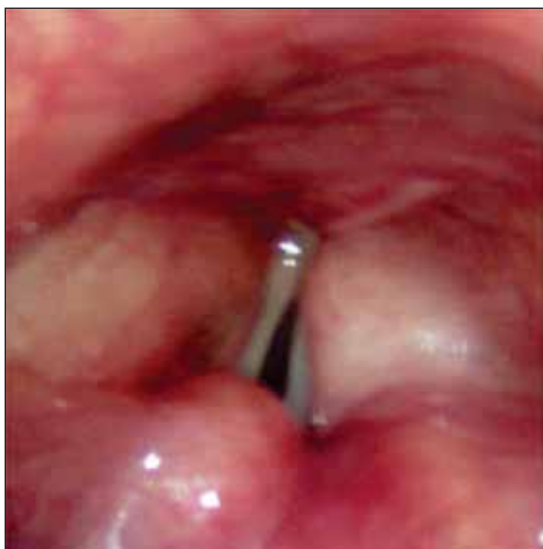
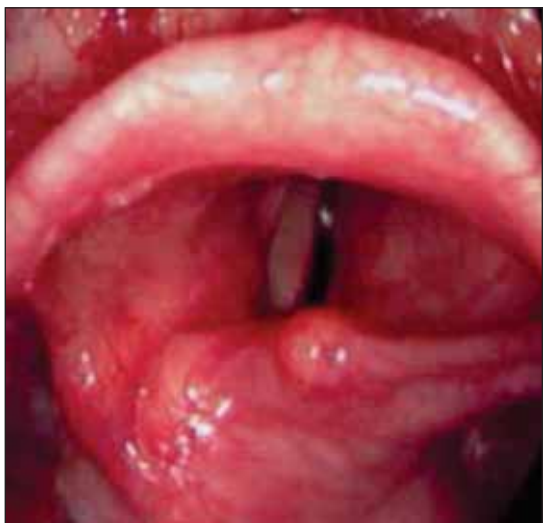
FIGURE 1. Patient Timeline



**FIGURE 2.** Endoscopic view of the larynx – 1st day: the arytenoids are plugged anteriorly and the vocal folds are immobilized in paramedian position. The right vocal fold has a concave aspect.



**FIGURE 3.** Endoscopic view of the larynx – day 7: right vocal fold paralysis with anterior plunging of the right arytenoid

complications and treatment adjustment. Differential diagnosis with other causes of bilateral vocal cord palsy in rheumatoid arthritis was carried out. Absence of skin ulcerations, purpura, ocular involvement, neurologic deficit and normal complement titers ruled out rheumatoid vasculitis. Cervical spine involvement was excluded by normal cervical radiography.

The patient was switched to oral prednisone 10 mg/day, maintaining the same dose of MTX 20 mg/week. During hospitalization she had persistent hoarseness but no other signs of laryngeal obstruction. After a week she was discharged free of upper airway symptoms.

The changes in the vocal cords and arytenoids on laryngoscopy were compatible with the chronic form of cricoarytenoid arthritis. The patient reported hoarseness and a feeling of fullness in the throat, long before the onset of acute symptoms. During the cold season, upper respiratory tract infection in an immunosuppressed patient with no signs of increased disease activity, best explains the cricoarytenoid flare-up.

## DISCUSSION

Prevalence of CAJ arthritis in RA varies between studies, with most reports stating frequent CAJ involvement in 26% to 86% of cases (2,5) often presenting with mild symptoms, whereas bilateral CAJ arthritis is involved in merely 13% to 33% of RA patients (2). Studies suggest that severe RA is a risk factor of CAJ arthritis (5,7) and that severity of laryngeal symptoms do not always correlate with disease activity (4). CAJ is a diarthrodial joint composed by articulation of the cricoid and arytenoid cartilages at the upper lateral aspect of the cricoid cartilage (4). It is a true synovial joint consisting of a ligamentous capsule lined by a synovial membrane and filled with synovial fluid (3). The joint, along with the intrinsic laryngeal muscles, controls the abduction and adduction of the vocal folds therefore playing an important role in assisting respiration, protecting the airways and facilitating sound production (4,5).

Chronic inflammatory changes of the CAJ result in ankylosis and decreased mobility of one or both vocal folds.

Bilateral vocal fold paralysis, an infrequent but life threatening complication of RA, should be considered by clinicians in those with RA and inspiratory dyspnea associated with painful speech or swallowing.

Cricoarytenoid arthritis is not only an RA manifestation, also being encountered in other rheumatic diseases (gout, systemic lupus erythematosus, systemic sclerosis), tumors of the larynx or vocal cords, trauma, infections of the upper respiratory tract and neurologic conditions involving recurrent laryngeal and vagus nerves palsy (4,5). Vocal cord compromise in RA is not only the consequence of cricoarytenoid arthritis. Cervical spine involvement can lead to cervicomedullary compression responsible of vocal fold palsy and other potential neurological deficits (3,8). Radiological assessment is required and

appropriate surgical interventions are needed in this setting (9). Another rare, but potential cause of laryngeal symptoms in RA is ischemic neuropathy of the cranial nerves controlling the movement of the vocal cords due to rheumatoid vasculitis (3,8). There are also reports of laryngeal amyloidosis leading to nonspecific symptoms or even more serious complications, such as exertional dyspnea and stridor (3,8).

The clinical presentation of acute and chronic cricoarytenoid arthritis depends upon the unilateral or bilateral involvement of the CAJ and the position in which the vocal folds remain fixed (3). Laryngeal manipulation, trauma and infection are recognized causes of decompensation of chronic arthritis (7). In anesthesiology, assessing for laryngeal lesions is necessary for optimal perioperative management (5). Use of smaller endotracheal tubes is advised in the case of minimal articular involvement (5,7). If severe joint damage is present, oral intubation should be avoided and other airway management techniques should be considered (5). Maximal attention and close monitoring is recommended after extubation as this is when acute airway obstruction occurs (7). Flexible laryngoscopy is the “gold standard” and confirms the diagnosis and differentiates between acute and chronic forms. In acute cricoarytenoid arthritis, endoscopy displays erythema and swelling of the arytenoids with intact vocal cords and bowing of the vocal folds during inspiration (5). In chronic arthritis the arytenoid mucosa may be thickened and coarse with decreased glottis opening. Also, arytenoid asymmetry, focal vocal cord lesions or diminished vocal fold mobility can be observed during laryngoscopy (6).

In the absence of life-threatening symptoms pulmonary function tests can be performed, showing flow-volume loops suggestive of fixed or variable patterns of extrathoracic upper airway obstruction (7,9). Other diagnostic approaches include anteroposterior low-voltage radiographs of the neck exhibiting the “steeple sign”. This sign demonstrates subglottic tracheal narrowing with an inverted V appearance, denoting tracheal edema and pointing to the presence of CAJ arthritis (8). Another complementary technique in the diagnosis of cricoarytenoid arthritis is computed tomography (CT) (2). CT imaging can detect CAJ prominence (46.6%), CAJ

density and volume changes (46.6%) and CAJ subluxation (39.9%) as demonstrated by Bayar et al (10). To a lesser extent soft tissue swelling around CAJ (20%) and narrowing of the piriform sinus (33.3%) may be revealed (10).

Treatment strategies vary according to clinical presentation and imply appropriate airway management and control of the systemic disease. Mild symptoms, with a more insidious onset and mild exertional dyspnea can benefit from systemic or locally injected steroids (2,6). In severe airway compromise or progressive airway obstruction despite medical treatment, tracheostomy is the preferred approach (6). Intubation may be attempted, but is often difficult and unsuccessful (3). Surgery is required in some situations of chronic bilateral fixation in the median position. Unilateral arytenoidectomy or suturing of the ipsilateral vocal fold in abduction is some of the recommended techniques (6,11).

Our patient ignored symptoms of speech difficulties which started a few months prior to presentation. Likely that was the debut of the right vocal fold paralysis with the appearance of bitonal voice. Acute additional involvement of the left cricoarytenoid joint has led to the occurrence of bilateral paralysis with respiratory distress.

Usually respiratory problems are particularly severe and require urgent tracheostomy. Our patient responded well to intravenous corticosteroids, most likely because the paralysis of the vocal folds did not occur simultaneously and the patient had time to adapt to the new respiratory status. Acute left cricoarytenoid arthritis responded to corticotherapy widening the glottis opening.

## CONCLUSION

CAJ arthritis in RA is a well described entity, often overlooked because of nonspecific laryngeal symptoms. Endotracheal manipulation and upper respiratory tract infection are recognized triggers of acute airway deterioration. Bilateral vocal cord fixation in the adducted position is less frequent and usually severe, requiring high dose intravenous corticosteroids and urgent tracheostomy in more dramatic situations. Flexible laryngoscopy is paramount in confirming the diagnosis and should not be delayed.

## REFERENCES

1. **Pradeep P., Abhishek B., Venkatachalam V.P.** Bilateral cricoarytenoid arthritis: a cause of recurrent upper airway obstruction in rheumatoid arthritis. *Malays J Med Sci.* 2016 May; 23(3):89-91.
2. **Greco A., Fusconi M., Macri G.F. et al.** Cricoarytenoid joint involvement in rheumatoid arthritis: radiologic evaluation. *Am J Otolaryngol.* 2012 Nov-Dec; 33(6):753-5.
3. **Peters J.E., Burke C.J., Morris V.H.** Three cases of rheumatoid arthritis with laryngeal stridor. *Clin Rheumatol.* 2011 May; 30(5):723-7
4. **Stojanović S.P., Zivić L., Stojanović J., Belić B.** Total fixation of cricoarytenoid joint of a patient with rheumatoid arthritis and Hashimoto thyroiditis. *Srp Arh Celok Lek.* 2010 Mar-Apr; 138(3-4):230-2.
5. **Kolman J., Morris I.** Cricoarytenoid arthritis: a cause of acute upper airway obstruction in rheumatoid arthritis. *Can J Anaesth.* 2002 Aug-Sep;49(7):729-32.
6. **Joseph J. Chen, Barton F. Branstetter I.V. et al.** Cricoarytenoid Rheumatoid Arthritis: An Important Consideration in Aggressive Lesions of the Larynx. *AJNR Am J Neuroradiol.* 2005 April; 26:970-972.
7. **Bradley P. Segebarth, Thomas J. Limbird.** Perioperative acute upper airway obstruction secondary to severe rheumatoid arthritis. *J Arthroplasty.* 2007;doi:10.1016/j.arth.2006.06.013
8. **Abe K., Mitsuka T., Yamaoka A., Yamashita K. et al.** Sudden glottic stenosis caused by cricoarytenoid joint involvement due to rheumatoid arthritis. *Intern Med.* 2013; 52(21):2469-72.
9. **Gleason J.B., Hadeh A.** Vocal Hoarseness in Rheumatoid Arthritis: Early Recognition is Critical. *J Clin Diagn Res.* 2017 Apr; 11(4):OJ03.
10. **Bayar N., Kara S.A. et al.** Cricoarytenoiditis in rheumatoid arthritis: radiologic and clinical study. *J Otolaryngol* 2003; 32:373-8.
11. **Whicker J.H., Devine K.D.** Long-term results of Thornell arytenoidectomy in the surgical treatment of bilateral vocal cord paralysis. *Laryngoscope* 1982; 11:361-364.