

MANAGEMENT OF A PATIENT WHO INJECT DRUGS, PRESENTING WITH RIGHT-SIDED INFECTIVE ENDOCARDITIS

Student Cosmina Gabriela Tanase¹, student Mihnea Casian¹,
student Daniela Elena Caldararu¹, student Ana Maria Radulescu¹,
student Mirela Georgiana Tene¹, Univ. Assist. Violeta Melinte^{1,2}, MD, PhD

¹“Carol Davila” University of Medicine and Pharmacy, Bucharest, Romania

²“Dr. Victor Babeş” Clinical Hospital of Infectious and Tropical Diseases, Bucharest,
Romania

ABSTRACT

Background. Right-sided infective endocarditis (RSIE) benefits from a special reference in the latest European Society of Cardiology (ESC) guidelines for the management infectious endocarditis, due to its epidemiology, prognosis, complications, medical and surgical management and presentation particularities (1). The main risk factor for RSIE is the use of intravenous drugs, a behavior that also explains the growing incidence of RSIE in developed countries, especially among the young population (2,6).

Material and methods. We present the case of a young intravenous drug user (IDU) admitted to our hospital for fatigue, fever and generalized arthralgias, which developed shortly after self-administration of iv. heroin. The clinical presentation suggestive for sepsis, together with the high suspicion for RSIE guided the subsequent paraclinical investigations and empirical antibiotic therapy.

Results. The positive diagnosis of sepsis was made once the first blood culture confirmed the presence of methicillin-sensitive *Staphylococcus aureus* (MSSA), in addition to a SOFA score of 4. Confirmation of RSIE came with the echocardiographic description of vegetations on the tricuspid valve, summing up 1 major and 3 minor modified Duke criteria. The patient had a slow, but favorable evolution, however, he developed severe tricuspid insufficiency, the infection persisted under antibiotic therapy with an increased risk of septic embolization, all of which qualified the patient for cardiac surgery to remove the infectious focus and restore the functionality of the tricuspid valve.

Conclusions. In this case, the same behavior that generated the pathology, iv. drug use, also determined deferral of the surgery, under conditions of hemodynamic stability, until a long-term withdrawal of heroin was attained. The patient was discharged upon request before the end of the antibiotic treatment, thus reiterating the need to routinely approach RSIE in IDU in a multidisciplinary “endocarditis team”. The main goal of this approach is to increase adherence to treatment, as well as to decrease morbidity and mortality of all causes, the risk of RSIE recurrence and IDU resumption.

Keywords: right-sided infective endocarditis (RSIE), tricuspid valve, Duke criterion, methicillin-sensitive *Staphylococcus aureus* (MSSA), intravenous drug user (IDU), heroin

INTRODUCTION

Patients with IDU-induced RSIE are often young, with a history of infectious diseases such as hepatitis B, hepatitis C or HIV infection and psychiatric pathologies associated with substance abuse, all of which often complicated by lack of social and family support. The complex care of such a patient requires a multidisciplinary approach within a team composed of different specialists: in-

fectious diseases specialists, cardiologists, cardiovascular surgeons, psychologists, psychiatrists, and support groups. The unidisciplinary health care team approach diminishes the impact of each specialist (9). RSIE treatment consists of intravenous antibiotic therapy, together with surgical intervention. Initially, the surgical success rate is similar in the general population and the IDU population. In the long term, the prognosis is worse for the latter,

Corresponding author:

Student Cosmina Tanase, “Carol Davila” University of Medicine and Pharmacy, Bucharest, Romania
E-mail: cosmina.tanase@yahoo.com

mainly due to the high recurrence rate of drug use and the risk of RSIE of prosthetic valves (2-5). The current addiction management uses an integrative approach, combining both pharmacological and non-pharmacological strategies.

EPIDEMIOLOGY

Among IDU, more than 85% of IE occur on the right side of the heart, involving the tricuspid valve in over 90% of cases (3). The microorganisms involved in the etiology of RSIE in IDU are:

- *Staphylococcus aureus* – the most common etiologic agent, Gram +, aerobic, non-capsulated; it can multiply at the level of the skin and mucous membranes (especially in the hairy areas and at the level of the nasal vestibule); 20% of healthy people are carriers of *S. aureus*; Depending on the sensitivity to methicillin, it is divided into methicillin-sensitive *Staphylococcus aureus* (MSSA) and methicillin-resistant *Staphylococcus aureus* (MRSA).
- Group A, C or G- streptococci (beta-hemolytic streptococci) induce a form of IE are similar to that caused by *S. aureus*, with suppurative complications and a mortality rate of 30-70%;
- Enterococci – in most cases determine subacute endocarditis; the sources are the gastrointestinal or genitourinary tract;
- Gram-negative germs – much less involved – *P. aeruginosa* and the HACEK group.

In Romania, the first data on IDU has been reported in 1995 and showed that 2.7% of young people had tried drugs at least once; two years later the percentage reached 10% (6). Heroin has been released on the market in 1898 by the German company Bayer – as an alternative to morphine – and has been available for 12 years in the treatment of irritant cough in children due to its antitussive properties (6). In Romania, it appeared only a few years after the fall of communism as an option to the local *Aurolac* (trade name of a dye containing solvents with hallucinogenic effects upon inhalation). The morphine-like structure determines most of the short-term effects (from the German word “heroisch” – heroic, the consumer feels euphoric, invincible, presents with analgesia, skin flushing,

pruritus, bradypnea, hypotension, nausea, xerostomia, etc.) and long-term effects (tolerance and dependence sometimes from the first dose, impaired cognitive function). Intravenous heroin use entails the risk of contracting infections with parenteral transmission and developing complications such as: RSIE, sepsis, abscesses, phlebitis at the injection site, etc. (7). According to the country report on drugs for Romania, 3.9% of young people between the ages of 15 and 34 have used drugs at least once in 2016, and heroin is the second most used drug (6).

CASE REPORT

A 25-year-old patient from the urban area presented to the Clinical Hospital for Infectious and Tropical Diseases “Dr. Victor Babes”, Bucharest, with marked fatigue, fever (38 °C before home administration of antipyretics) and generalized arthralgias, developed 4 days before presentation, shortly after the most recent self-administration of intravenous heroin in the left femoral vein. The patient’s history is positive for pathological behaviors such as current use of intravenous heroin - for 8 mo., occasional Cannabis smoking – for 6 y., short-term use of intravenous ethnobotanics, 10 y. ago, single-use of LSD (lysergic acid diethylamide), tobacco use – 10 pack-years, denies alcohol consumption. The patient presented with an altered general state, conscious, cooperative, tachycardic (110 beats/min), hypotensive (100/65 mmHg), tachypneic (24 breaths/min), with a body temperature of 37.6 °C measured axillary. The clinical examination revealed numerous tattoos, scars at the venous puncture sites, partial edentation, and an overall normal physical examination except for the only pathological element: bilateral, symmetrical lung crackles, with normal cardiac and carotid sounds, no murmurs or bruits.

The clinical presentation was suggestive for pulmonary sepsis (qSOFA score of 2), together with a high suspicion for RSIE (2 minor Duke criteria-IDU, fever) guided broad-spectrum empirical antibiotic therapy with Vancomycin 1g q 12 h iv. and Meronem 1g q 8 h iv., together with pathogenic and symptomatic treatment for heroin withdrawal syndrome. The two presumptive diagnoses were confirmed once the first hemoculture for MSSA was

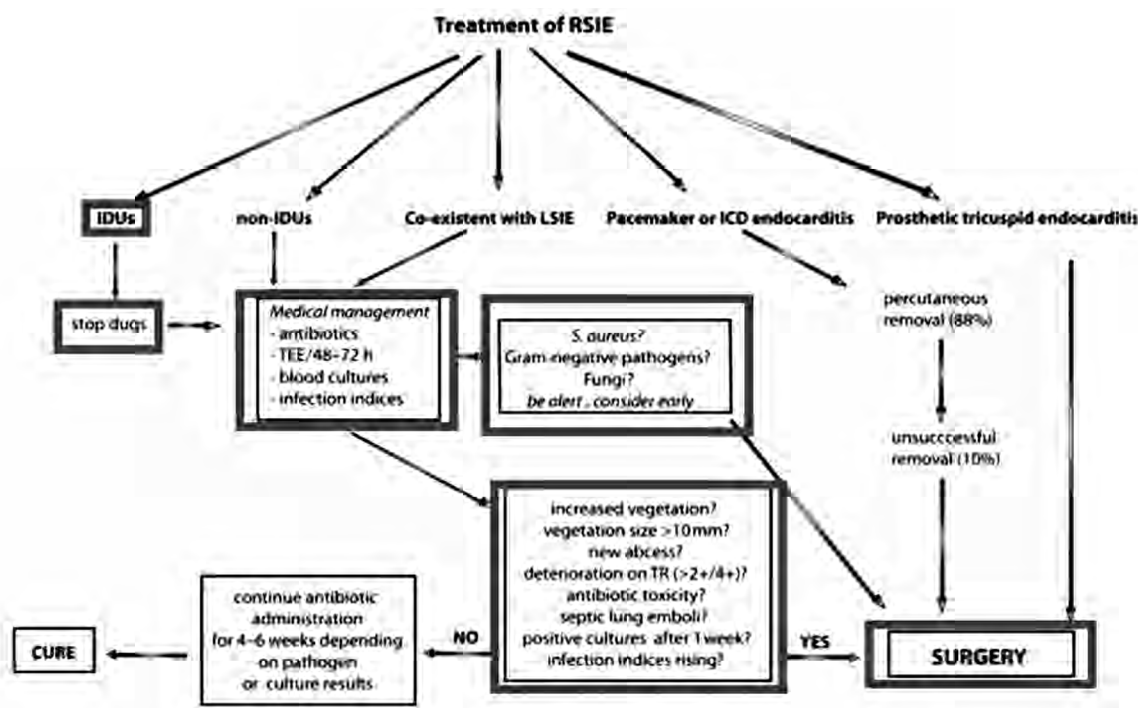


FIGURE 1. Management of RSIE. Akinosoglou et al. (5)

positive, in addition to a SOFA score of 4- sepsis, respectively the echocardiographic description of 3 vegetations on the anterior tricuspid valve, initially summing up 1 major and 3 minor Duke criteria-RSIE. Laboratory samples revealed leukocytosis with neutrophilia, microcytic, hypochromic anemia, severe thrombocytopenia, C-reactive protein (CRP) and procalcitonin with values more than 50 times higher than the normal upper limit. Serial thoracic X-rays revealed signs compatible with bilateral bronchopneumonia and bilateral pleural effusions, at which point a causal link between the aspect and dimensions of the valvular vegetation and the pulmonary imaging aspect is considered, with the suspicion of multiple septic pulmonary infarctions. Serology for HIV1 / 2, HBV, HCV was negative.

The patient stated he has benefited from the national program of free distribution of single-use syringes for IDU, as part of the strategy aimed to prevent the transmission of parenteral infections. This might have contributed to him not being infected to HIV1 / 2, HBV or HCV. In Romania, more than 1.4 million syringes/year are distributed at a national level (6).

Microcytic, hypochromic anemia (min Hb 7 g/dl) and a low serum iron level, established the diagno-

sis of iron deficiency anemia, probably due to a deficiency of intake which was intensified in the context of infection, so that the patient received 2 units of packed red blood cells (PRBCs). The role of IDU in the pathogenesis of anemia is worth mentioning, on the one hand, because of the effect of heroin on the central nervous system – lack of appetite, nausea – and, on the other hand, because we are facing an unemployed young man, with no current incomes, who spends most of his income on heroin and tobacco at the expense of proper nutrition.

Despite administration of broad-spectrum antibiotics, the patient oscillated between periods of normothermia and febrile outbreaks and maintained the level of leukocytes and CRP at high levels, in a plateau, during the 42 days of hospitalization. Additional serological samples were collected - IgM for both *Coxiella burnetii* and IgM *Chlamydia pneumoniae* returned negative. Additional blood cultures, to a total of 5, were drawn and 3 of them came back positive for MSSA (sensitive to Chloramphenicol, Gentamicin, Oxacillin, Penicillin G, Tetracycline, Linezolid). The last negative blood culture was recorded 15 days before discharge. Persistence of infection in these conditions led to an escalation of antibiotic therapy by adding Bisepitol

480 mg every 12 h PO and doxycycline 100 mg q 12 h PO and replacing Meronem with Tazocin 4.5 g every 8 h iv.

The first transesophageal echocardiography performed revealed 3 giant vegetations attached to the tricuspid valve - maximum size 29/12 mm, moderate tricuspid regurgitation, right cavities with no dilatation, left ventricular ejection fraction and overall systolic function preserved. Transthoracic echocardiography revealed a progressive decrease in the vegetation size, in parallel with the worsening of the radiological aspect and the progressive increase of the dimensions of pulmonary opacities, reinforcing the suspicion that their mechanism of production is by septic pulmonary infarction. According to the management recommendations for RSIE (fig. 1), following the cardiovascular surgery examination, the indication for surgery was established based on the persistence of the infection under antibiotic therapy, the pulmonary embolism, the remaining risk of embolization and the severe valvular dysfunction.

The intervention was postponed until a long-term withdrawal of heroin was attained. The patient was discharged on request, after 42 days of hospitalization and 7 days of normal body temperature, with CRP and leukocytes at a stationary level of 9 mg/dl, respectively 13,000/ μ l and persistent, mobile vegetations with maximum sizes 8.6/9.2 mm, mild to severe tricuspid regurgitation, potentially complicated with anterior cusp prolapse.

DISCUSSIONS

RSIE accounts for 5-10% of all cases of IE and is found predominantly among IDU patients. In general, the prognosis of RSIE is favorable compared with that of the left-sided IE (LSIE), as such, the therapeutic approach of this pathology can be systematized as follows: conservative management in 70-80% of cases and surgical management in 20% of cases. As a result of the small number of patients enlisted in a meta-analysis, there are currently no clear guidelines regarding the optimal timing of the surgical intervention, as compared to

the management of LSIE. Most of the current studies indicate the following criteria:

- heart failure following severe tricuspid insufficiency;
- persistent infection under antibiotic therapy, pulmonary septic emboli, septic shock;
- embolic risk - the persistence of vegetation with dimensions greater than 1 cm on the tricuspid valve, under antibiotic therapy.

Infection with MSSA or MRSA requires consideration of surgery in early stages, in addition to antibiotic therapy, because it is associated with the existence of large vegetations, severe valvulopathy, and increased mortality (6). A recent meta-analysis found that conservative treatment in presence of *S. aureus* infection was associated with significantly increased mortality – 51% compared to conservative and surgical treatment – 31% (8).

CONCLUSIONS

The management of our IDU patient with RSIE is characterized by surgical risks related to IDU itself. Although the patient met the criteria for the surgical intervention, it was never performed, because of the risks, such as reduced adherence to the post-surgical medical treatment, especially anticoagulants, high risk of recurrent IE in the context of continuous IDU, with an indication of surgical re-intervention and poor prognosis. Considering that the patient was hemodynamically stable and had a rather slow evolution from RSIE to heart failure, it was possible to delay the surgical intervention to provide psychological counseling for IDU withdrawal, an essential element for the favorable evolution of the patient. During this time, the patient must follow the recommendations to complete the antibiotic treatment (4 weeks from the last negative blood culture) and to prevent transient bacteremia (eg by dental maneuvers).

Our patient with RSIE still requires an integrative approach of a multidisciplinary team if therapeutic success is to be expected. Thus the idea of implementing the ESC concept of Endocarditis Team in Romania (9) is raised, especially among IDU patients.

REFERENCES

1. ESC Guidelines for the management of infective endocarditis: The Task Force for the Management of Infective Endocarditis of the European Society of Cardiology (ESC). Endorsed by: European Association for Cardio-Thoracic Surgery (EACTS), the European Association of Nuclear Medicine (EANM), European Heart Journal, Volume 36, Issue 44, 21 November 2015, Pages 3075–3128, <https://doi.org/10.1093/eurheartj/ehv319>.
2. Yanagawa B, Bahji A, Lamba W, Tan DH, Cheema A, Syed I, Verma S. Endocarditis in the setting of IDU: Multidisciplinary management. *Curr Opin Cardiol*. 2018 Mar; 33(2):140-147. doi: 10.1097/HCO.0000000000000493.
3. Kim JB, Ejiófor JI, Yammine M et al. Surgical outcomes of infective endocarditis among intravenous drug users. *J Thorac Cardiovasc Surg* 2016; 152:832–841.e1.
4. Shetty N, Naggal D, Koivu S, Mrkobrada M. Surgical and medical management of isolated tricuspid valve infective endocarditis in intravenous drug users. *J Card Surg* 2016; 31:83–88.
5. Karolina Akinosoglou, Efstratios Apostolakis, Nikolaos Koutsogiannis, Vassilios Leivaditis, Charalambos A. Gogos. Right-sided infective endocarditis: surgical management. *European Journal of Cardio-Thoracic Surgery*, Volume 42, Issue 3, September 2012, Pages 470–479, <https://doi.org/10.1093/ejcts/ezs084>.
6. Observatorul European pentru Droguri și Toxicomanie. Raportul european privind drogurile 2017: Tendințe și evoluții. Oficiul pentru Publicații al Uniunii Europene, Luxemburg.
7. Rook EJ, van Ree JM, van den Brink W, Hillebrand MJ, Huitema AD, Hendriks VM, Beijnen JH Pharmacokinetics and pharmacodynamics of high doses of pharmaceutically prepared heroin, by intravenous or by inhalation route in opioid-dependent patients. *Basic Clin. Pharmacol. Toxicol*. 2006, 98 (1): 86–96.
8. Daniel J Sexton, Vivian H Chu. Infective endocarditis in injection drug users. UpToDate. Retrieved April, 24, 2019, from <https://www.uptodate.com/contents/infective-endocarditis-in-injection-drug-users>.
9. Habib G. State of the Art: The endocarditis team – a new paradigm. Retrieved April 24, 2019, from <https://esc365.escardio.org/Congress/ESC-CONGRESS-2017/Demystifying-endocarditis/155528-state-of-the-art-the-endocarditis-team-a-new-paradigm>.