



## A first description of benign metastasizing leiomyoma of the lung from madagascar: A brief review of the literature

Razafimanjato Narindra Njarasoa Mihaja<sup>1</sup>, Ralaivao Andrianina Rindra<sup>2</sup>, Nomenjanahary Lalaina<sup>2</sup>, Raharisolo Vololonantenaina Clarette<sup>2</sup>, Randrianjafisamindrakotroka Nantenaina Soa<sup>2</sup>, Rakotovao Hanitrana Jean Louis<sup>1</sup>

<sup>1</sup>Thoracic Surgeon, University Hospital of Joseph Ravoahangy Andrianavalona, Department of Surgery & Division of Thoracic Surgery. Faculty of Medicine, University of Antananarivo. Madagascar

<sup>2</sup> Pathologist, University Hospital of Joseph Ravoahangy Andrianavalona, Department of Fundamental science & Division of Pathology & Laboratory Medicine. Faculty of Medicine, University of Antananarivo. Madagascar

### ARTICLE INFO

*Article type:*  
Case reports

*Article history:*  
Received: 10 April 2021  
Revised: 20 May 2021  
Accepted: 06 June 2021

*Keywords:*  
Benign Metastasizing  
Leiomyoma  
Lung Metastasis  
Leiomyoma Pulmonary  
Nodules

### ABSTRACT

Benign metastatic leiomyoma (BML) spreading in the lung is rare entities predominantly in a young woman. To our knowledge, our observation is the first description of benign metastasizing leiomyoma of the lung from Madagascar. We describe a case of 44-year-old of Malagasy origin, asymptomatic, non-smoking woman who had a history of hysterectomy for myoma three years earlier. Chest computed tomography (CT) revealed multiple well defined nodular shadows in the lung. One tumor of the middle lobe was resected by lateral thoracotomy. The resected lesion consisted of benign spindle cells and was diagnosed as BML. Through this clinical case, we present the first case report of a BML patient from Madagascar. The aim of this article is to take stock of the knowledge relating to this rare affection, and to propose management in accordance with the current literature.

► Razafimanjato, N., Ralaivao, R., Nomenjanahary, L., Raharisolo Vololonantenaina, C., Randrianjafisamindrakotroka, N., Rakotovao, H. A first description of benign metastasizing leiomyoma of the lung from madagascar: A brief review of the literature. *J Cardiothorac Med.* 2021; 9(2): 824-828

### Introduction

The leiomyoma, from the Greek *leios*: smooth and *muôn*: muscle, is a benign tumour consisting of the smooth muscle cell proliferation. The most common leiomyoma is the uterine leiomyoma,

often referred to as myoma, or erroneously, fibroma. Benign Metastasizing Leiomyoma (BML) of the lung is an extremely rare disease characterized by the proliferation of smooth muscle tumours, usually multiple

\*Corresponding author: Razafimanjato Narindra Njarasoa Mihaja, University Hospital of Joseph Ravoahangy Andrianavalona, Department of Surgery & Division of Thoracic Surgery. Faculty of medicine, University of Antananarivo. Madagascar, India.

Tel+261.34.93.687.20, E-mail: [razafesteban@yahoo.fr](mailto:razafesteban@yahoo.fr)

© 2016 mums.ac.ir All rights reserved.

This is an Open Access article distributed under the terms of the Creative Commons Attribution License (<http://creativecommons.org/licenses/by/3.0>), which permits unrestricted use, distribution, and reproduction in any medium, provided the original work is properly cited.

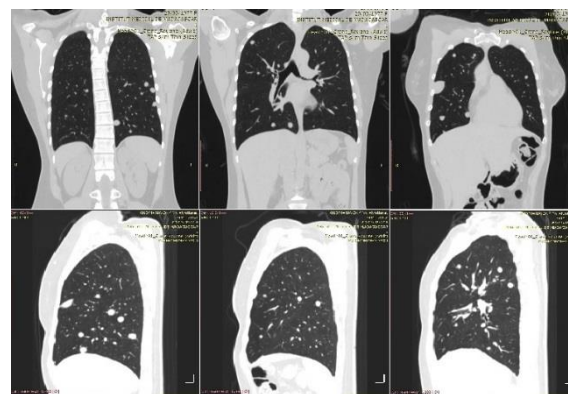
but histologically benign (1). Sekine et al. recorded that leiomyomas constituted 0.085% of all benign lung tumour cases (2). The authors described a case of a 44-year-old woman of Malagasy origin, who had a history of hysterectomy for myoma, seven years earlier. To our knowledge, our observation is the first description of benign metastasizing leiomyoma of the lung from Madagascar. Through this clinical case, the aim of this article is to take stock of the knowledge relating to this rare affection, and to propose management in accordance with the current literature.

### Case Presentation

The patient was a 44-year-old, married female, non-smoking, asymptomatic, who had undergone a hysterectomy with right salpingo-oophorectomy for myoma of the uterus, seven years ago. She was referred to our unit for further evaluation after incidental finding on the pre-operative imaging (chest X-ray) of multiple round solid nodules on both sides of the lungs. In her medical history, she had not previously been affected by any lung disease, including pulmonary tuberculosis. On physical examination, our patient was in a good general condition and no chest symptoms. Thoracic computed tomography (CT) (Figure 1) showed multiple well-defined nodular shadows in both lung fields. She underwent a bronchoscopy with non-contributive of systematic biopsy of tracheobronchial airways. Blood tests data were unremarkable, and tumour markers values were all within normal limits (Table 1).

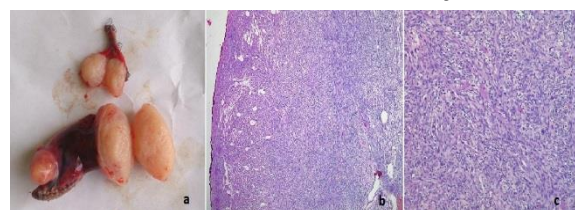
Test (Serum)	Result	Reference Values
CEA	0,97	< 5 ng/ml
CA15-3	10,9	< 31 U/ml
CA-125	165	160-320 U/ml
NSE	13,1	< or =15 ng/mL
CYFRA 21-1	1,0	<3.0 ng/mL

CEA: Carcino-Embryonic Antigen  
 CA 15-3: Carbohydrate Antigen 15 -3  
 NSE: Neuron Specific Enolase  
 CA 125: Cancer Antigen 125



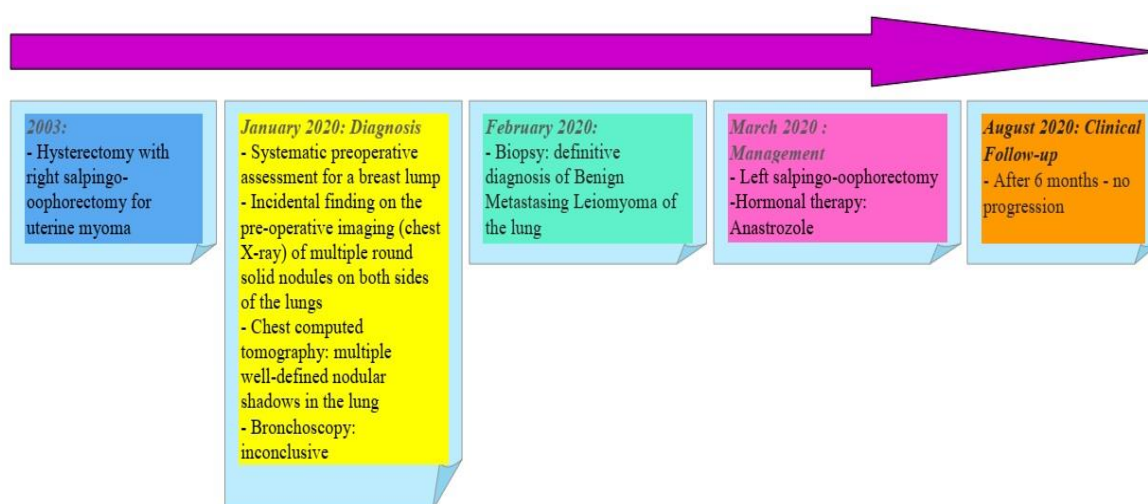
**Figure 1:** Computed tomography demonstrates a diffuse distribution of multiple well-defined non-calcified pulmonary nodules.

Subsequently, the patient underwent a lateral thoracotomy with atypical resection from the right middle lobe of lung (Figure 2.a). The definitive pathology finding revealed a well-differentiated spindle cell proliferation with little nuclear and cellular variability regarding size and shape. There was no evidence of atypical mitosis or necrosis (Figure 2.b,c). In the pathology report, the disease was described as leiomyoma.



**Figure 2:** (a) Pulmonary nodule removed; (b and c) H&E: Low-grade spindle cell proliferation in the excised lesions.

Immunohistochemical examinations confirmed the final pathological interpretation of benign metastasizing leiomyoma of the lung based on morphology and immunohistochemical staining. Hormone suppression consisting of left salpingo-oophorectomy followed by Anastrozole was offered to the patient. No sign of disease progression was noted after a six-month follow-up (Figure 3). The patient is currently being treated on an ambulatory with hormonal therapy.



**Figure 3:** Timeline of the patient

## Discussion

BML is an unusual disease first described in the medical literature by Steiner in 1939 as multiple lung metastases in a 36-year-old woman subsequent to a benign uterine leiomyoma (1, 3). Using the keyword "benign metastasizing leiomyoma" on PubMed, only 231 cases have been reported in the literature from 1977 to date. In our country, only a peritoneal location in a Malagasy woman was described by Ravelosoa E et al in 2003 (4). By reviewing the scientific literature, there is, up to now, no case description of pulmonary metastatic of BML in a Malagasy woman. Similarly to our case, the majority of cases are diagnosed in apparently healthy premenopausal women who have undergone hysterectomy for benign tumours of the uterus (3).

BML is a most unusual aetiology of multiple pulmonary nodules that typically occur in women of reproductive age or older, 36-64 years, with an average 44, with a history of uterine leiomyoma (5). To date, the youngest patient with pulmonary MBL has been 23 years old (6).

The average length of time between leiomyoma surgery and the development of lung nodules is about 15 years with extremes 3 months and 20 years after surgery (1, 7). The pathogenicity of the BML is still under discussion and has not yet been fully elucidated.

The enigmatic question focused on the propagation mechanism and the process of metastasis. Assuming that history of uterine leiomyomas is found in almost all patients with BML, some authors attribute these pulmonary locations to haematogenous cell migration during surgery (myomectomy or hysterectomy) resulting metastasize and embolization to distant organs (1, 3, 5). Others scientists, such as Paley et al. (8), reject the benign nature of these metastatic lesions and attribute them to a low-grade leiomyosarcoma (9). Another hypothesis suggests that smooth muscle neoplasms may arise de novo in the lung as a part of a more generalized systemic leiomyomatosis (3). Fernando Matos et al described a rare presentation of BML in a woman with no medical history of uterine intervention (10). On the one hand, the hormone-dependent process of metastasis growth is justified by its manifestation predominantly in women during their reproductive age, particularly premenopausal because of excessive production of female reproductive hormones (1) and on the other hand, to the regression and stabilization of tumours under antihormonal treatments, during pregnancy (11) after menopause or after oophorectomy (3, 5). These findings are evocative of role promoters of oestrogen and progesterone in the growth of metastatic pulmonary nodules. In our observation, BML is described in a woman with a surgical history of uterine leiomyomas similar to the

majority of reported cases in the literature. Usually, this disorder is symptom-free and incidentally diagnosed (3, 5). If present, symptoms typically include cough, shortness of breath, and chest pain (5). Miyazaki et al (12) reported a case of life-threatening haemoptysis following pulmonary BML. In our case, the disease was discovered incidentally after a systematic preoperative assessment for a breast adenofibroma. It is characterized by well-circumscribed, multiple bilateral nodules ranging from several millimetres to many centimetres, and not calcified in CT imaging similar to the description in literature (3, 13). A few rare cases have been reported with a miliary pattern, cavitory lung nodules, interstitial lung disease and multiloculated liquid-containing cystic lesions (1). In cases observed in the advanced countries, PET/CT takes advantage of the positron decay of F-18 to identify those malignant tissues with a significantly higher uptake of 18-FDG (3, 14). While the anamnesis and clinico-radiological pattern of BML is suggestive, only a histological examination can confirm the diagnosis and identify key features that will lead to establish the differential diagnosis (3, 15). The most helpful pathologic features that characterize BML are the low mitotic index and the absence of coagulative necrosis and atypia (5). However, it could be extremely difficult to identify its malignant potential, because mitotic activity in uterine leiomyomas is not static but may change according to the menstrual cycles (3). Desmin and muscle-specific actin, are used as immunohistochemical markers to confirm the mesenchymal derivation of BML with smooth muscle differentiation. Negativity of Human melanoma black (HMB-45) is suggestive for BML as opposed to lymphangioliomyomatosis (16). Furthermore, the presence of oestrogen and progesterone receptors indicates that these tumours originate from the uterus (1). Fluorescent in situ hybridization confirmed the presence of a 19q 22q terminal deletion, which is pathognomonic for BML (9). No definite treatment strategy of BML has been defined due to low morbidity and rarity of these tumours. Careful observation is acceptable for the indolent and asymptomatic disease (1). As a general rule, for the

symptomatic patient and multiple lesions not amenable to removal, as in our case, hysterectomy, bilateral oophorectomy and long term hormonal therapy based on the oestrogen and progesterone receptor identified on immunohistochemical staining and GnRH agonists are the standard of care for BML control (1, 3, 5). Not all patients respond to hormone therapy, however, and side effects such as flushes, fatigue and nausea can be bothersome to the patient. Surgical palliation could be considered for single and large lesions of BML but is rarely reported. In the literature review, only Ottlakan A et al. reported 87 nodules removed by cautery resection (n=83; 95%) and wedge resection (n=4; 5%), in seven procedures during a 41-month interval with satisfactory functional respiratory outcome (9). As in our case, a combined approach of medical and surgical treatments would benefit from synergistic effects and should be considered in the management of progressive and symptomatic lesions. The majority of BML reports describe a favourable outcome despite the chronicity of the disease. Although, some malignant transformation has been reported (17) and Bachman and Wolff reported a case of death related to acute respiratory distress syndrome (18).

### Conclusion

Multiple lung nodules are not necessarily the result of malignant disease, as multiple benign entities like BML and considered in the differential diagnosis of multiple lung nodules. BML should be in the mind of clinicians and suspected in patients who present an anamnesis of uterine leiomyoma presented multiple pulmonary nodules on CT scan, especially with a history of uterine leiomyoma. However, definitive diagnosis requires biopsy and the immunohistochemistry assay can help avoid the clinicians to confirm the diagnosis of BML lesions. Long-term monitoring of these diseases is required to adapt treatment depending on the patient's symptomatology.



## Conflicts of interest

The authors have declared no conflict of interest.

## References

1. Wei WT, Chen PC. Benign metastasizing leiomyoma of the lung: A case report and literature review. *Oncology letters*. 2015 Jul 1;10(1):307-12.
2. Sekine I, Kodama T, Yokose T, Nishiwaki Y, Suzuki K, Goto K, Nagai K, Kuriyama T. Rare pulmonary tumors—a review of 32 cases. *Oncology*. 1998;55 (5):431-4.
3. Lazzari G, Perri F, Scarpati GD, Pisconti S, Silvano G. Benign leiomyoma metastasizing to the lung: a case report and a brief review of the literature. *Journal of Unexplored Medical Data*. 2017 Jun 14;2:34-8.
4. Ravelosoa E, Cr RV, Randahoarison PG, Rakotosalama D, Heriniaina S, Rasolofondraibe A. Première description de léiomyomatose péritonéale disséminée à Madagascar. *Les Archives de l'Institut Pasteur de Madagascar*. 2003.
5. Taftaf R, Starnes S, Wang J, Shipley R, Namad T, Khaled R, Karim NA. Benign metastasizing leiomyoma: a rare type of lung metastases-two case reports and review of the literature. *Case Rep Oncol Med*. 2014; 2014: 842801.
6. Goyle KK, Moore Jr DF, Garrett C, Goyle V. Benign metastasizing leiomyomatosis: case report and review. *American journal of clinical oncology*. 2003 Oct 1;26(5):473-6..
7. Kayser K, Zink S, schneider T, Dienemann H, André S, kaltner H, et al. Benign metastasizing leiomyoma of the uterus: documentation of clinical, immunohistochemical and lectin-histochemical data of ten cases. *Virchows Arch*. 2000;437:284-92.
8. Paley D, Fornasier VL. Leiomyomatosis metastasizing to the spine. *JBJS*. 1984 Apr 1;66(4):630.
9. Otlakan A, Borda B, Lazar G, Tizslavicz L, Furak J. Treatment decision based on the biological behavior of pulmonary benign metastasizing leiomyoma. *Journal of thoracic disease*. 2016 Aug;8(8):E672.
10. Matos F, Santiago C, Silva D. Multisystemic benign metastasizing leiomyoma: an unusual condition with an atypical clinical presentation. *Case reports in radiology*. 2019 Apr 10;2019.
11. Scuderi R, Giovannini M, Villani V, Canino T, Antonaci D. Differential diagnosis of leiomyoma in pregnancy: rapid growth, rapid regression and progestogenic effects. *Ultrasound in Obstetrics & Gynecology*. 2016 Feb;47(2):241-2.
12. Miyazaki M, Nakayama A, Noda D, Maehara Y, Tsushima Y. Difficulty in complete transarterial embolization for pulmonary benign metastasizing leiomyoma with massive hemoptysis. *Japanese journal of radiology*. 2014 Jan 1;32(1):53-7.
13. Sousa I, Campos P, Távora I. Imaging features of pulmonary leiomyomatosis. *European Congress of Radiology-ECR* 2013.
14. Joseph V, Chacko G, Raghuram L, Rajshekhar V. Benign metastasizing leiomyoma causing spinal cord compression. *Surgical neurology*. 2003 Dec 1;60 (6):575-7.
15. Lewis EI, Chason RJ, DeCherney AH, Armstrong A, Elkas J, Venkatesan AM. Novel hormone treatment of benign metastasizing leiomyoma: an analysis of five cases and literature review. *Fertility and Sterility*. 2013 Jun 1;99 (7):2017-24.
16. Ki EY, Hwang SJ, Lee KH, Park JS, Hur SY. Benign metastasizing leiomyoma of the lung. *World Journal of Surgical Oncology*. 2013 Dec;11 (1):1-7.
17. Song KS, Keum DY, Hwang IS. Malignant transformation of pulmonary benign metastasizing leiomyoma. *The Korean journal of thoracic and cardiovascular surgery*. 2017 Feb;50 (1):59.
18. Bachman DO, Wolff MA. Pulmonary metastases from benign-appearing smooth muscle tumors of the uterus. *American Journal of Roentgenology*. 1976 Sep 1;127(3):441-6.