

Single Case – General Neurology

A Case of Miller-Fisher Syndrome with Syndrome of Inappropriate Secretion of Antidiuretic Hormone

Shunya Fujiwara^a Yasuhiro Manabe^a Yumiko Nakano^a Yoshio Omote^a
Hisashi Narai^a Koji Abe^b

^aDepartment of Neurology, National Hospital Organization Okayama Medical Center, Okayama, Japan; ^bDepartment of Neurology, Graduate School of Medicine, Dentistry and Pharmaceutical Sciences, Okayama University, Okayama, Japan

Keywords

Miller-Fisher syndrome · Syndrome of inappropriate secretion of antidiuretic hormone · Hyponatremia

Abstract

We report a 72-year-old woman with Miller-Fisher syndrome (MFS) with syndrome of inappropriate secretion of antidiuretic hormone (SIADH). She developed diplopia and unsteady gait a week after an upper respiratory infection. Neurologic examination revealed ophthalmoplegia, ataxia, symmetrical weakness, numbness, and areflexia. She underwent intravenous immunoglobulin therapy. Her serum sodium concentration decreased to 119 mEq/L on day 12. She had low plasma osmolality (254 mosm/kg), high urine osmolality (457 mosm/kg), and high urine sodium level (73 mEq/L), while the blood level of antidiuretic hormone was normal. Anti-GD1b immunoglobulin G (IgG), -GQ1b IgG, -GT1a IgG, and -Gal-C IgM antibodies were positive. We diagnosed her with MFS overlapping with SIADH. Four weeks after onset, her symptoms recovered. The elevation of anti-GD1b, -GQ1b, and -GT1a antibodies that recognize disialosyl residue may be pathologically related to SIADH.

© 2021 The Author(s).

Published by S. Karger AG, Basel

Introduction

Miller-Fisher syndrome (MFS) is characterized by the acute onset of external ophthalmoplegia, ataxia of cerebellar type, and the loss of tendon reflexes [1]. It is considered a variant of Guillain-Barré syndrome (GBS). GBS is associated with the syndrome of inappropriate secretion of antidiuretic hormone (SIADH) [2–6]; however, the association between MFS and SIADH has not been fully studied. We herein present a case of MFS with SIADH.

Correspondence to:
Yasuhiro Manabe, manabe.yasuhiro.cw@mail.hosp.go.jp

Case Report

A 77-year-old woman developed muscle weakness in both upper and lower limbs (day 1) a week after an upper respiratory infection. She felt numbness in both upper limbs and pain in both upper and lower limbs on day 5. She was admitted to our hospital due to unsteady gait on day 8. She had diabetes mellitus type 2 and hypertension. She had no familial history of neurological disorders. General physical examination was normal. Neurological examination revealed ophthalmoplegia and muscle weakness of grade 3/5 affecting both proximal upper and lower limbs and grade 4/5 affecting both distal upper and lower limbs. All deep tendon reflexes were absent. Babinski and Chaddock signs were negative. Her gait was ataxic. Mann's test was positive, and tandem walking was impossible. She had numbness in both distal fingers. Her autoimmune system was intact. Findings from routine serum studies revealed an elevation of blood glucose level of 196 mg/dL and hemoglobin A1c of 7.7%. Cerebrospinal fluid analysis showed a cell count of 3/mL (100% mononuclear cells), an increased protein concentration of 91 mg/dL, glucose level of 120 mg/dL, and immunoglobulin G (IgG) and albumin ratios of 0.57 (normal range <0.7). Antinuclear antibody and antineutrophilic cytoplasmic antibody were negative, and antiviral antibodies showed an existing pattern of infection. Magnetic resonance imaging of the brain and cervical spine showed both were intact. Nerve conduction studies showed low amplitude in median, ulnar, tibial, and peroneal nerves consistent with a mixed sensorimotor polyneuropathy. We diagnosed as MFS and started intravenous immunoglobulin (IVIg) therapy from day 9 to 13. The serum sodium concentration decreased from 131 to 119 mEq/L on day 12. Serum osmolality and urine osmolality were 254 and 457 mosm/kg H₂O, respectively. Urine sodium concentration was 73 mEq/L. Antidiuretic hormone was 1.8 pg/mL (normal range <2.8 pg/mL). Creatinine was 0.39 mg/dL. Morning fasting cortisol was 18.4 µg/dL. She was diagnosed as SIADH and treated with intravenous 0.9% NaCl and fluid restriction. Her serum sodium concentration was 137 mEq/L on day 27. Anti-ganglioside antibody assays were performed on serum obtained on day 8. Anti-GD1b IgG (+++), -GQ1b IgG (+++), -GT1a IgG (+++), and -Gal-C IgM (+) antibodies were positive. She was able to walk after rehabilitation and was discharged on day 38 (Fig. 1).

Discussion

We report a case of MFS with SIADH. An association of SIADH with GBS has been documented in the previous reports [2–6]; however, MFS with SIADH is extremely rare [7, 8]. SIADH is a widely recognized complication of several central nervous system disorders such as meningitis, brain tumors, head injuries, stroke, and encephalitis [2–6]. Although the mechanism of SIADH in patients with GBS is unknown, it has been speculated that the plasma concentration of ADH secondary rose due to a disturbance of the peripheral volume receptors [3, 4], and renal tubular sensitivity for ADH increased [5, 6].

Pseudohyponatremia has been reported in patients with GBS treated with IVIg [9]. Intravenous infusion of immune globulin increased the protein-containing nonaqueous phase of plasma, with a consequent relative decrease in plasma water volume. Since sodium was present only in the aqueous phase, each unit volume of plasma measured had less sodium-containing water, and this was interpreted as hyponatremia [9]. True hyponatremia was also seen due to movement of intracellular water to the extracellular compartment caused by the sucrose in the IVIg solution [9]. Thus, we diagnosed SIADH in our patient based on the elevated urine osmoles in the setting of decreased serum osmoles.

There were elevations of the anti-gangliosides anti-GD1b, -GQ1b, and -GT1a in the IgG subclass that recognizes disialosyl residue in our patient, although anti-Gal-C IgM antibody

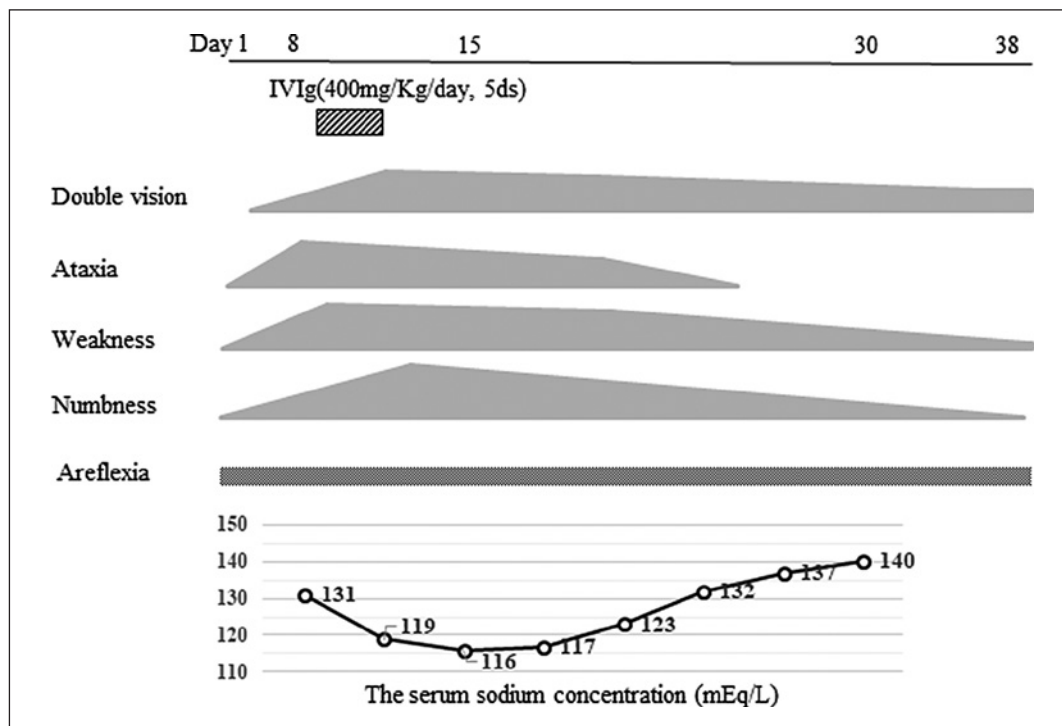


Fig. 1. Clinical course of the patient. IVIg, intravenous immunoglobulin therapy.

did not recognize disialosyl residue. After treatment of melanomas with anti-GD2 monoclonal antibody (MAB) that recognized disialosyl residue, some patients developed sensorimotor demyelinating polyneuropathy with SIADH. Anti-GD2 monoclonal antibody reacted with the myelin sheaths in the peripheral nerves as well as with the pituicyte cytoplasm in the posterior lobe of the pituitary gland [10, 11]. Iorio et al. [12] reported a patient who developed SIADH during the first relapse chronic ataxic neuropathy with ophthalmoplegia, IgM paraprotein, cold agglutinins, and disialosyl antibodies. The dysregulation of osmolarity receptors may be consequent to binding of some anti-disialosyl antibodies to specific hypothalamic epitopes [12]. The elevation of anti-GD1b, -GQ1b, and -GT1a antibodies may be pathologically related to SIADH. Further studies are needed to clarify this issue.

Acknowledgement

We thank Dr. Susumu Kusunoki (Department of Neurology, Kinki University School of Medicine) for measuring anti-ganglioside antibodies.

Statement of Ethics

The authors hereby declare that all work was conducted in accordance with the Declaration of Helsinki (1964), and the submission of this manuscript for publication has been approved by National Hospital Organization Okayama Medical Center. Written informed consent was obtained from the patient for publication of this case report and any accompanying images.

Conflict of Interest Statement

The authors state that they have no conflicts of interest.

Funding Sources

The authors have nothing to disclose.

Author Contributions

Shunya Fujiwara and Yasuhiro Manabe designed the case report and wrote the manuscript. Shunya Fujiwara, Yasuhiro Manabe, Yumiko Nakano, Yoshio Omote, and Hisashi Narai contributed to the diagnosis, physical examination, and testing of the patient. Susumu Kusunoki performed anti-ganglioside antibody assays. Koji Abe supervised this case report and clinical practice. All the authors read and approved the final manuscript.

References

- 1 Fisher M. An unusual variant of acute idiopathic polyneuritis: syndrome of ophthalmoplegia, ataxia, and areflexia. *N Engl J Med*. 1956;255:57–65.
- 2 Posner JB, Ertel NH, Kossmann RJ, Scheinberg LC. Hyponatremia in acute polyneuropathy. Four cases with the syndrome of inappropriate secretion of antidiuretic hormone. *Arch Neurol*. 1967;17:530–41.
- 3 Penney MD, Murphy D, Walters G. Resetting of osmoreceptor response as cause of hyponatraemia in acute idiopathic polyneuritis. *Br Med J*. 1979;2:1474–6.
- 4 Cooke CR, Latif KA, Huch KM, Wall BM. Inappropriate antidiuresis and hyponatremia with suppressible vasopressin in Guillain-Barré syndrome. *Am J Nephrol*. 1998;18:71–6.
- 5 Hoffmann O, Reuter U, Schielke E, Weber JR. SIADH as the first symptom of Guillain-Barré syndrome. *Neurology*. 1999;53:1365.
- 6 Colis BM. Guillain-Barré syndrome and hyponatremia. *Intern Med J*. 2004;33:5–9.
- 7 Ramaprasad ST, Poretzky L. Life-threatening hyponatremia due to the syndrome of inappropriate secretion of antidiuretic hormone (SIADH) in a patient with the Miller Fisher syndrome. *Endocr Pract*. 1995;1:163–5.
- 8 Murakami T, Yoshihara A, Kikuchi S, Yasuda M, Hoshi A, Ugawa Y. [A patient with Fisher syndrome and pharyngeal-cervical-brachial variant of Guillain-Barré syndrome having a complication of SIADH]. *Rinsho Shinkeigaku*. 2013;53:299–303.
- 9 Lawn N, Wijdicks EF, Burritt MF. Intravenous immune globulin and pseudohyponatremia. *N Engl J Med*. 1998;339:632.
- 10 Seleh M, Khazaeli MB, Wheeler RH, Dropcho E, Liu T, Urist M, et al. Phase I trial of the murine monoclonal anti-GD2 antibody 14G2a in metastatic melanoma. *Cancer Res*. 1992;52:4342–7.
- 11 Yuki N, Yamada M, Tagawa Y, Takahashi H, Handa S. Pathogenesis of the neurotoxicity caused by anti-GD2 antibody therapy. *J Neurol Sci*. 1997;149:127–30.
- 12 Iorio R, Capone F, Iannaccone E, Willison HJ, Modoni A, Tonali PA, et al. SIADH in a patient with sensory ataxic neuropathy with anti-disialosyl antibodies (CANOMAD). *J Neurol*. 2009;256:1177–9.