

Screening for Ocular Surface Squamous Neoplasia (OSSN) by Slit-lamp Assisted Visual Inspection (SAVI) following a short course of mild topical steroid-test qualities

E Katsekera*, L Tanyanyiwa*, V Chikwasha† and R Masanganise††

< drmasanganise@gmail.com >

*, †† *Department of Ophthalmology, University of Zimbabwe College of Health Sciences, PO Box A178, Avondale, Zimbabwe*

† *Department of Community Medicine, University of Zimbabwe College of Health Sciences, PO Box A178, Avondale, Zimbabwe*

Received 24 October 2013; revised version accepted 17 March 2014

Abstract

Introduction: Ocular surface squamous neoplasia (OSSN) is currently the commonest ocular malignancy affecting people of child bearing age and is associated with high morbidity and mortality rates in Zimbabwe. Early surgical intervention has been shown to mitigate the effects of OSSN amongst its victims, however this is hampered by limited histopathological services which should guide the extent of surgical excisions of these tumours.

Purpose: The purpose of this study was to determine the accuracy of Slit-lamp Assisted Visual Inspection (SAVI) in diagnosing ocular surface squamous neoplasia with the hope of recommending a fall back tool that ophthalmologists / medical practitioners / ophthalmic nurses or optometrists can use in resource limited situations without readily accessible histopathological services when surgical intervention is contemplated.

Method: This was part of a study which

screened one hundred and nineteen (119) patients with conjunctival growths and recruited sixty seven (67) patients with ocular surface squamous neoplasia by visual inspection over a period of six months. All patients received a week's course of topical fluorometholone 0.1% and had the lesions excised either completely or partially depending on size of tumour and histology performed on the tissues. The histology results were compared with the results by visual inspection to determine diagnostic accuracy. Outcome measures were specificity, sensitivity and predictive values.

Results: Total number of patients with conjunctival growths screened by visual inspection was 119, with median age of 42 years and a range of 18 to 90 years and gender ratio of 1:1.9 in favour of females. There was no significant age difference between confirmed OSSN patients and non-OSSN (pterygia) and the *p*-value was 0.617. Sensitivity and specificity of visual inspection in diagnosing OSSN when compared to histology were 94.3% and 74.2% respectively, with a positive predictive

*RGN, Diploma in Ophthalmic Nursing

†Biostatistician

††Professor, MBChB(UZ) FRCOphthalmol(UK)

value of 74.6%. Histology reports indicated that 24.5% of OSSN specimens seen actually arose from pterygia.

Conclusions: Slit lamp assisted visual inspection (SAVI) is an accurate method of clinically diagnosing OSSN and can be

recommended for use in resource limited settings with hard to access histopathological services. (S Afr Optom 2014 73(1) 16-20)

Key Words: ocular surface squamous neoplasia, visual inspection, histology, tumour diagnosis, conjunctival growth, pterygium.

Introduction

Ocular surface squamous neoplasia (OSSN) is the commonest ocular malignancy seen in Zimbabwe since the onset of the HIV/AIDs epidemic^{1,2}. Although its aetiology remains purely speculative, local studies have proved that OSSN is strongly associated with HIV in Zimbabwe^{3,4} and this has been confirmed elsewhere in Africa⁵. OSSN is associated with high morbidity and mortality rates in Zimbabwe and studies have shown that it is responsible for escalating exenteration and enucleation rates at the National Tertiary Eye Unit^{6,7}. Early surgical intervention has been shown to mitigate the untoward effects of OSSN⁸⁻¹⁰.

Data from the Zimbabwe National Cancer Registry suggest that patients with OSSN come from all over the country with no particular region being more favoured. This wide spread distribution of place of origin contributes negatively to when patients present first with the problem, with patients from remote districts presenting late with advanced tumours when compared to locals. Poor medical services in remote areas hinder the much desired prompt surgical intervention when dealing with OSSN in HIV infected patients. Researchers have tried various methods of predicting whether a conjunctival growth is due to OSSN by using methylene blue dye¹¹ and OCT¹² with varying accuracies. The search for a cheaper and more accurate OSSN screening method is of essence as part of an emergency national response to the OSSN epidemic.

Objective of the study

The objective of this study was to evaluate the accuracy of using Slit-lamp Assisted Visual Inspection (SAVI) in screening for ocular surface squamous neoplasia among patients with conjunctival growths

following a one week course of mild topical steroid drops (Fluorometholone suspension 0.1%) to treat the conjunctival growth.

Methodology

This was part of a prospective pilot study being conducted at Sekuru Kaguvi Hospital Eye Unit (SKHEU) to investigate the aetiology of HIV associated OSSN in Zimbabwe. The study was conducted over a six months period from 1st October 2011 to 31st March 2012. Study subjects were identified and recruited into the study after visual inspection during routine eye clinics in the out-patients department.

All patients with an irritating conjunctival growth were put on a short course of mild topical steroid of fluorometholone suspension 0.1% (FML) three times a day for seven days. The patients were re-evaluated seven days later on slit-lamp and a provisional diagnosis given to the conjunctival growth (OSSN or non-OSSN). Patients were booked for excision of lesions and specimens were submitted for histological evaluation.

Diagnosis of OSSN by slit-lamp assisted visual inspection for this study comprised a history of persistently irritating / painful growth on the conjunctiva, highly vascularised lesion with a rough granulated surface and the over-laying conjunctiva having lost its lustre following a week's course of FML 0.1%. Diagnosis of non-OSSN lesions by slit-lamp assisted visual inspection comprised unresolved non-irritating, non-inflamed conjunctival growths with normal surface lustra following a week's course of FML 0.1%.

All registrars working at SKEU during the time of the study were involved in patient selection but masked to the study since they were doing their usual eye outpatient clinics and the research ophthalmic nurse recruited the patients for the study. Inclusion criteria for the study were all patients aged eighteen

years and above presenting at SKEU for the first time during the study period, with unresolved conjunctival growths following one week course of FML 0.1% drops who consented to participate in the study. Exclusion criteria for the study included all non-consenting patients with unresolved conjunctival growths following a short course of FML 0.1%, all patients below the age of eighteen with conjunctival growths, all patients previously diagnosed as OSSN and all patients with advanced lesions invading lids and orbit ulcerated and fungating.

On recruitment all study subjects had blood tests done for HIV and T-cell profile. The subjects were prepared for either excisional or incisional biopsy of the lesions under local anaesthetic in the usual manner. Excisions were performed under microscopy to ensure complete surgical removal of the tumour

with a 2 mm tumour free margin surrounding excised tissues. Excised tissue was taken and divided into two parts and one part was sent for histology at the local Public Health Laboratory and the other part was stored in RNALater for molecular studies being conducted elsewhere as part of the main study.

Results

One hundred and nineteen (119) patients with conjunctival growths were screened for OSSN using Slit-lamp Assisted Visual Inspection (SAVI). The gender ratio for the patients was 1:1.9 in favour of females (65.5%) and the median age of the 119 patients was 42 years with a range of 18 to 90 years. The contingency table below summarises the findings between the screening test by "Slit-lamp Assisted Visual Inspection" and the standard "Histology".

Table 1: Comparative analysis of OSSN results screened by SAVI against histology.

SCREENING TEST (SAVI)	Confirmed OSSN by Histology	Confirmed non-OSSN by Histology	Total
OSSN by visual inspection	(a) 50	(b) 17	67
Non-OSSN by visual Inspection	(c) 3	(d) 49	52
Total	53	66	119

The following were determined:

- i) Sensitivity of screening method: $a/(a+c) = 94.3\%$, 95% CI (83.4-98.5)
- ii) Specificity of screening method: $d/(b+d) = 74.2\%$, 95% CI (61.8-83.9)
- iii) Positive predictive value of screening method: $a/(a+b) = 74.6\%$, 95% CI (62.3-84.1)
- iv) Negative predictive value of screening method: $d/(c+d) = 94.2\%$, 95% CI (83.1-98.5)

Comparative analysis of age and gender ratios between confirmed OSSN and non-OSSN was statistically insignificant and are shown in the table below:

Table 2: Comparative analysis of gender and age distribution between confirmed OSSN and non-OSSN groups.

Group	Age	Gender distribution
Confirmed OSSN	Median age: 40 years Range: 18 to 67 years	1:1.68 in favour of females
Non-OSSN (Pterygium)	Median age: 45 years Range: 24 to 90 years	1:2.25 in favour of females
<i>p</i> -value	0.617	0.394

Of the 53 histologically diagnosed OSSN specimens 24.5% were reported as arising in a pterygium. Of the 66 histologically diagnosed non-OSSN specimens one was a pyogenic granuloma and the rest were pterygia. Below is a summary of the different types of OSSN identified by histology.

DISTRIBUTION OF OSSN BY TYPE

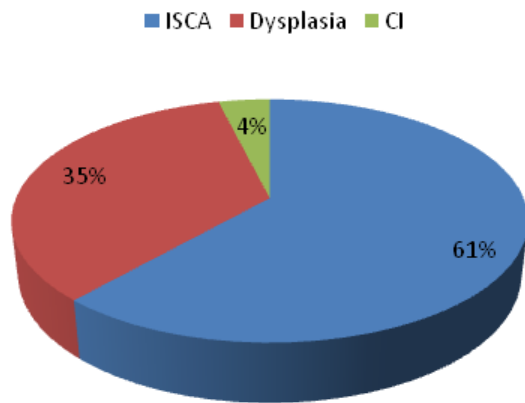


Figure 1. Distribution of OSSN by histological type.

Key: ISCA-Invasive squamous cell carcinoma of conjunctiva, Dysplasia-(Mild, moderate or severe) and CI-Carcinoma *in situ*.

Discussion

OSSN lesions tend to present as irritating or painful conjunctival growths which are well circumscribed, gelatin-like, sessile, papillomatous with leukoplakia of varying extent and located on the interpalpebral region adjacent to the limbus^{5, 13}. Lesions on the nasal limbus are easily mistaken for pterygia or inflamed pingueculae.

The management of HIV associated OSSN differs from that of non-OSSN lesions in terms of timing of surgical intervention, extent of surgical excision, use of adjunctive therapy and follow-up. OSSN calls for a very aggressive approach to save life and reduce morbidity when compared to non-OSSN tumours and surgery is the recommended standard management of OSSN lesions^{9, 10, 14-15}.

The confusion between OSSN and benign conjunctival tumours experienced by clinicians impacts negatively on the speed at which surgical intervention is offered to OSSN patients in Zimbabwe. Use of a mild short course of steroid drops (FML 0.1%) is known to resolve symptoms of inflammatory benign conjunctival tumours namely discomfort and redness but does not reduce the size of degenerative

tumours.

The use of slit-lamp assisted visual inspection to screen for OSSN on patients whose conjunctival growths had received a short course of FML 0.1% had encouraging test qualities in terms of sensitivity, specificity and predictive values rates when compared with standard histology reports (see Table 1 above). SAVI sensitivity of 94.3% and specificity of 74.2% were even better than those found when *in vivo* confocal microscopy (IVCM) where sensitivity of 38.5% and specificity of 66.7% were found between OSSN and benign lesions¹³. In view of these finding the authors advocate that clinicians in resource-limited settings where histopathological services are hard to access use this screening tool to augment clinical judgement when deciding surgical intervention. This approach would expedite service delivery and ameliorate untoward effects of OSSN among HIV infected patients in remote areas.

Although patients with OSSN appeared relatively younger than those with non-OSSN tumours (see Table 2 above) the difference was not statistically significant and all OSSN patients were HIV positive. These observations have been made in other studies conducted in Africa¹⁵. Thus, age and HIV status are other parameters that may be considered as part of clinical judgement in suspect case of OSSN. Gender distribution was not statistically different between OSSN and non-OSSN groups.

The association of 24.5% of OSSN lesions with pterygia was a new observation which to our knowledge has not been well documented. The association between OSSN and pterygia noted in this study could have been purely coincidental although solar radiation has been implicated as possible aetiological factor for both conditions^{17, 18}. The pie chart in Figure 1 above is a summary of the different types of OSSN as confirmed by histology. Further studies in this area would add value to our understanding of aetiology of these conditions.

Conclusion

Slit-lamp Assisted Visual Inspection (SAVI) on patients with conjunctival growths who had a short course of mild topical steroid is an accurate method of clinically screening for OSSN with a high sensitivity (94.3%) and a relatively good specificity (74.2%)

and can be recommended for use in resource limited settings to expedite surgical intervention.

Acknowledgements

This was part of a research supported by the UC San Diego CFAR (NIH grant P30 AI036214). Permission to conduct the study was granted by the Research Council of Zimbabwe, Medical Research Council of Zimbabwe and Joint Research and Ethics Committee (UZCHS).

References

- Masanganise R, Rusakaniko S, Makunike R, Hove M, Chokunonga E, Borock MZ, Mauchaza BG, Chirenje MZ, Masanganise VN, Magure T. A historical perspective of registered cases of malignant ocular tumours in Zimbabwe (1990 to 1999). Is HIV infection a factor? *Cent Afr J Med* 2008 **54** 28-32.
- Pola E, Masanganise R, Rusakaniko S. The trend of ocular surface squamous neoplasia among ocular surface tumour biopsies submitted from Sekuru Kaguvi Eye Unit-Harare between 1996 and year 2000. *Cent Afr J Med* 2003 **49** 1-4.
- Chinogurei TS, Masanganise R, Rusakaniko S, Sibanda E. Ocular surface squamous neoplasia (OSSN) and Human Immunodeficiency Virus at Sekuru Kaguvi Eye Unit in Zimbabwe. *Cent Afr J Med* 2006 **52** 56-58.
- Masanganise R, Mukome A, Dari J, Makunike-Mutasa R. Bilateral HIV related ocular surface squamous neoplasia: a paradigm shift? *Cent Afr J Med* 2010 **56** 23-26.
- Gichuhi S, Sagoo MS, Weiss HA, Burton M. Epidemiology of ocular surface squamous neoplasia in Africa. *J Trop Med Int Health* 2013 **18**(12) 1424-1443.
- Masanganise R, Magava A. Orbital exenterations and squamous cell carcinoma of the conjunctiva at Sekuru Kaguvi Eye Unit Zimbabwe. *Cent Afr J Med* 2001 **47** 196-199.
- Eppe E, Masanganise R. The rate and indications for enucleations at Sekuru Kaguvi Eye Unit in Harare: A comparative analysis. *Cent Afr J Med* 2003 **49** 13-15.
- Masanganise R, Mukome A. Five-year recurrency of surgically excised ocular surface squamous neoplasias at Sekuru Kaguvi Hospital Eye Unit, Zimbabwe. *SA Ophthalmology Journal* 2010 autumn 22-26.
- Maudgil A, Patel T, Rundle P, Rennie IG, Mudhar HS. Ocular surface squamous neoplasia: analysis of 78 cases from a UK ocular oncology centre. *Br J Ophthalmol* 2013 **97**(12) 1520-1524.
- Galor A, Karp CL, Oellers P, Kao AA, Abdelaziz A, Feuer W, Dubovy SR. Predictors of ocular surface squamous neoplasia recurrence after excisional surgery. *Ophthalmology* 2012 **119**(10) 1974-1981.
- Steffen J, Rice J, Lecuona K, Carrara H. Identification of ocular surface squamous neoplasia by in vivo staining with methylene blue. *Br J Ophthalmol* 2014 **98**(1) 13-5.
- Kieval J.Z., Karp C.L., AbouShousha M., Galor A., Hoffman R.A., Dubovy S.R. Ultra-high resolution optical coherence tomography for differentiation of ocular surface squamous neoplasia and pterygia. *Ophthalmology* 2012 **119**(3) 481-486.
- Nguena MB, van den Tweel JG, Makupa W, Hu VH, Weiss HA, Gichuhi S, Burton MJ. Diagnosing Ocular Surface Squamous Neoplasia in East Africa: Case-Control Study of Clinical and In Vivo Confocal Microscopy Assessment. *Ophthalmology* 2014 **121**(2) 484-491.
- Adler E, Turner JR, Stone DU. Ocular surface squamous neoplasia: a survey of changes in the standard of care from 2003 to 2012. *Cornea* 2013 **32**(12) 1558-1561.
- Nagaiah G, Stotler C, Orem J, Mwanda WO, Remick SC. Ocular surface squamous neoplasia in patients with HIV infection in sub-Saharan Africa. *Curr Opin Oncol* 2010 **22**(5) 437-442.
- Makupa II, Swai B, Makupa WU, White VA, Lewallen S. Clinical factors associated with malignancy and HIV status in patients with ocular surface squamous neoplasia at Kilimanjaro Christian Medical Centre, Tanzania. *Br J Ophthalmol* 2012 **96**(4) 482-484.
- Ruchi Mittal, Suryasnata Rath, and Geeta Kashyap Vemuganti. Ocular surface squamous neoplasia - Review of etio-pathogenesis and an update on clinico-pathological diagnosis. *Saudi J Ophthalmol* 2013 **27**(3) 177-186.
- Yam JC, Kwok AK. Ultraviolet light and ocular diseases. *Int Ophthalmol* 2013 [doi: 10.1007/s10792-013-9791-x]

