

Paediatric Neuroimaging

Presentation

A three and a half year-old male child was referred for neuroimaging under general anaesthesia for intractable seizures. These are selected MR images.

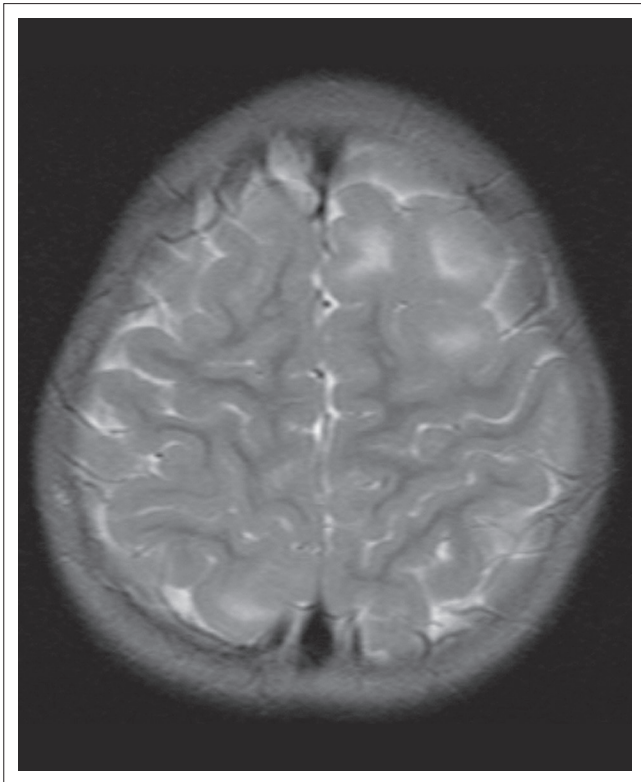


FIGURE 1: Axial T2-weighted MR image.

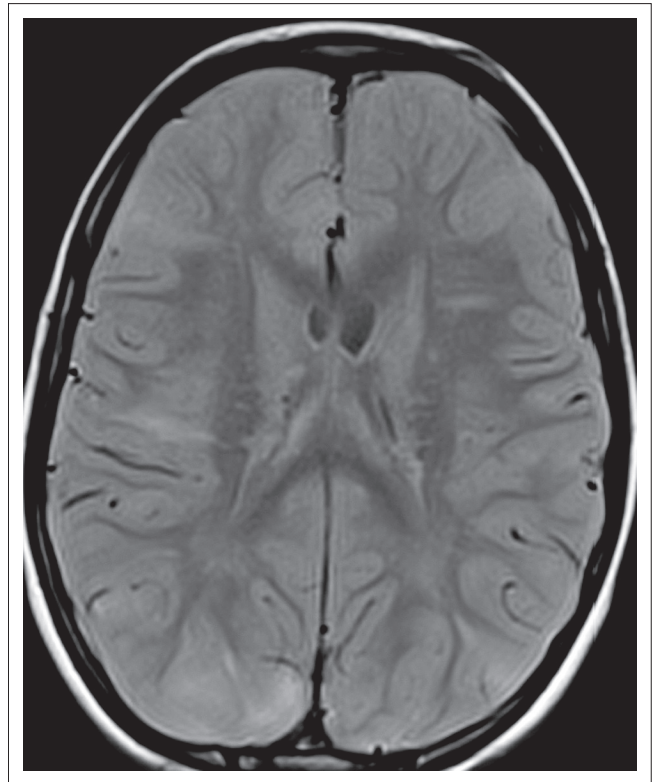


FIGURE 2: Axial FLAIR MR image.

Read online:



Scan this QR code with your smart phone or mobile device to read online.

Author: Shalendra K. Misser¹

Affiliation: ¹Lake Smit and Partners Inc, Durban, South Africa

Correspondence to: Shalendra Misser

Email: misser@lakesmit.co.za

Postal address: Private Bag X08, Overport 4067, Durban, South Africa

How to cite this article: Misser, SK. Paediatric Neuroimaging Quiz Case. S Afr J Rad. 2015;19(2); Art. #873, 3 pages. <http://dx.doi.org/10.4102/sajr.v19i2.873>

Copyright: © 2015. The Authors. Licensee: AOSIS OpenJournals. This work is licensed under the Creative Commons Attribution License.

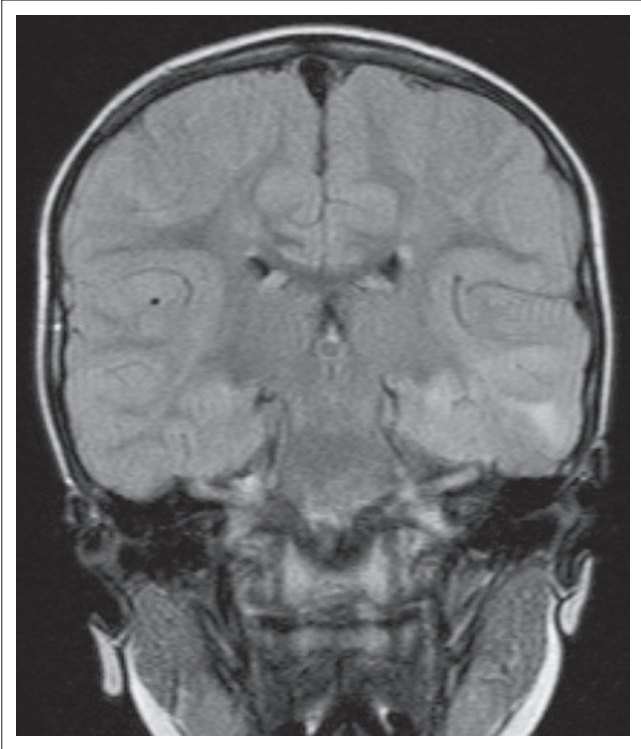


FIGURE 3: Coronal FLAIR MR image.

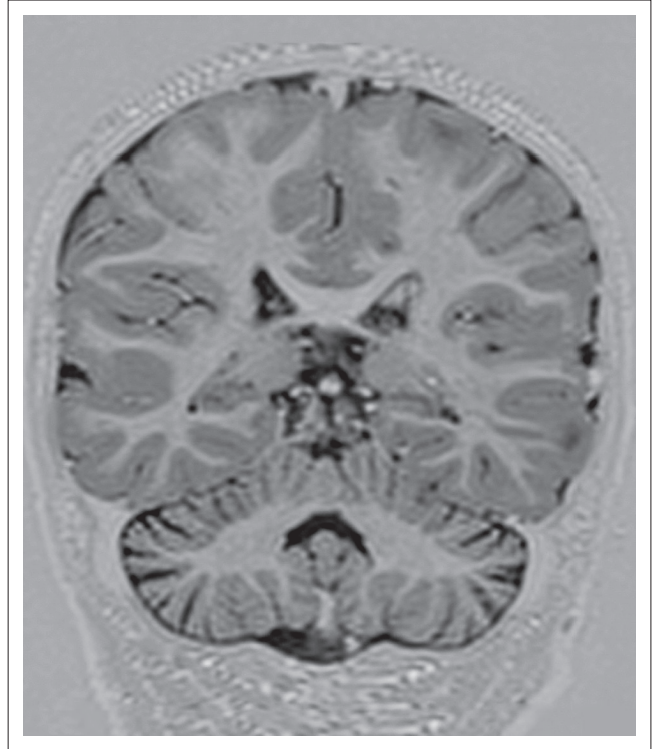


FIGURE 4: Coronal T1-Inversion Recovery MR image.

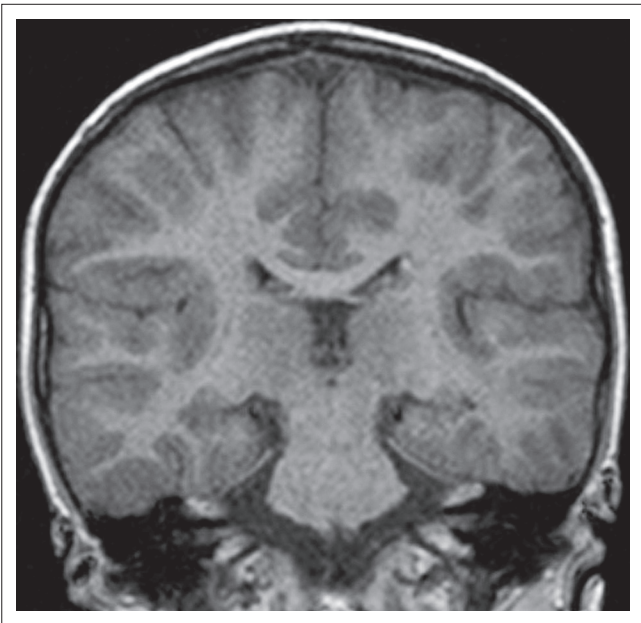


FIGURE 5: Coronal T1-weighted MR image.

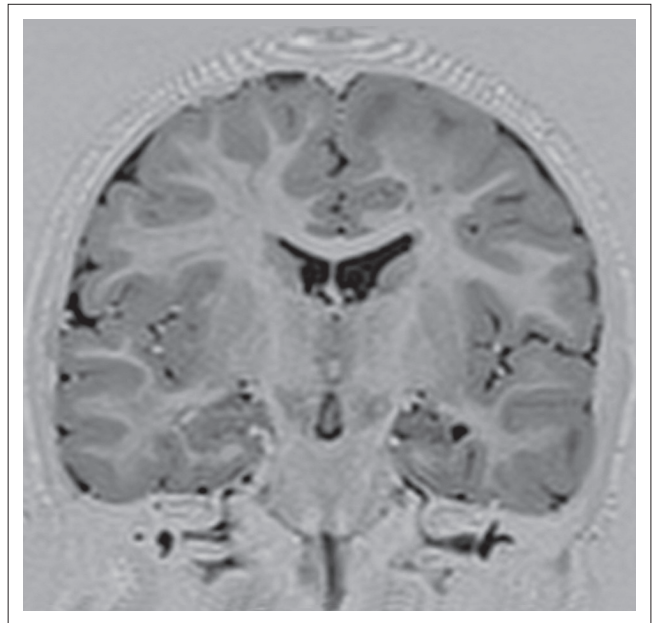


FIGURE 6: Coronal T1 Inversion Recovery MR image.

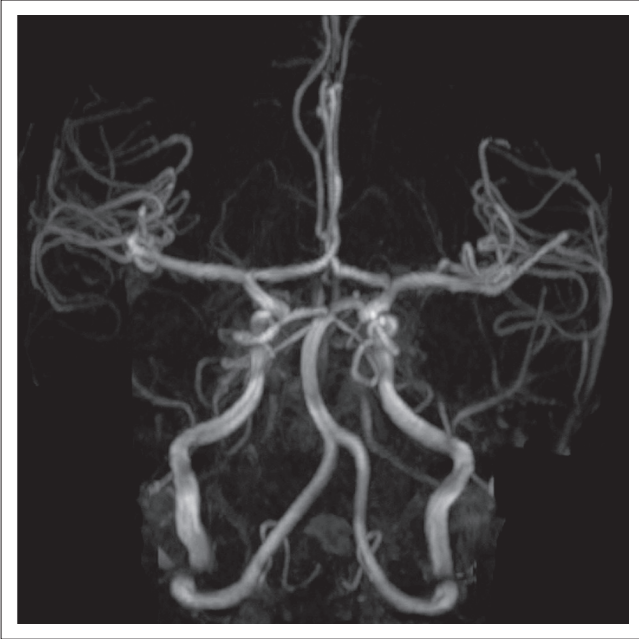


FIGURE 7: MR Angiography image of the circle of willis.

Describe the relevant imaging findings and formulate the most appropriate clinical diagnosis. Please submit your response to missier@lakesmit.co.za not later than 30 November 2015. The winning respondent will receive a R1000 award from the RSSA. A detailed diagnosis and discussion will be presented in the next issue of the SAJR.