



THE UNIVERSITY *of* EDINBURGH

## Edinburgh Research Explorer

# Successful treatment of a multi-drug resistant *Pseudomonas aeruginosa* infection following a digit amputation in a Belgian Blue calf

### Citation for published version:

Tomlinson, M, Crilly, J, Corbishley, A & Hopker, A 2016, 'Successful treatment of a multi-drug resistant *Pseudomonas aeruginosa* infection following a digit amputation in a Belgian Blue calf' *Veterinary Record Case Reports*. DOI: 10.1136/vetreccr-2016-000324

### Digital Object Identifier (DOI):

[10.1136/vetreccr-2016-000324](https://doi.org/10.1136/vetreccr-2016-000324)

### Link:

[Link to publication record in Edinburgh Research Explorer](#)

### Document Version:

Peer reviewed version

### Published In:

*Veterinary Record Case Reports*

### Publisher Rights Statement:

This is the final peer-reviewed manuscript as accepted for publication The BMJ submission template was used by the authors.

### General rights

Copyright for the publications made accessible via the Edinburgh Research Explorer is retained by the author(s) and / or other copyright owners and it is a condition of accessing these publications that users recognise and abide by the legal requirements associated with these rights.

### Take down policy

The University of Edinburgh has made every reasonable effort to ensure that Edinburgh Research Explorer content complies with UK legislation. If you believe that the public display of this file breaches copyright please contact [openaccess@ed.ac.uk](mailto:openaccess@ed.ac.uk) providing details, and we will remove access to the work immediately and investigate your claim.





**Successful treatment of a multi-drug resistant *Pseudomonas aeruginosa* infection following a digit amputation in a Belgian Blue calf.**

Journal:	<i>Veterinary Record Case Reports</i>
Manuscript ID	vetreccr-2016-000324.R1
Manuscript Type:	Food/farmed animals
Species:	Cattle
Date Submitted by the Author:	11-May-2016
Complete List of Authors:	Tomlinson, Martin; R(D)SVS, Farm Animal Practice Crilly, James Patrick; FarmVets SouthWest, Corbishley, Alexander; R(D)SVS, Farm Animal Practice Hopker, Andy; R(D)SVS, Farm Animal Practice
Keywords:	Cattle, Orthopaedics, Resistance, Antimicrobials, Pseudomonas, Diagnostics
Topics:	Diagnostics, Economics, Foot conditions, Imaging, Orthopaedics, Pseudomonas
Abstract:	Digit amputation is a commonly performed surgery in cattle practice. The most common reason for digit amputation is septic pedal arthritis, but other indications include severe trauma, pedal osteitis, non-healing sole, wall or toe ulcers, osteomyelitis of P2, septic tenosynovitis of the distal digital flexor tendons and other infectious processes of the deep digital structures (Blowey, 2011). The procedure is considered a salvage procedure, but good rates of success are reported. The size of the patient is one of the key determinants of prognosis, with reported success rates varying between bulls, cows and calves. Reported complications include haemorrhage, avascular necrosis of the phalangeal fragments, wound infection and fracture of the partner claw (Heppelmann, 2009). In this case report we describe digit amputation under regional and general anaesthesia for the treatment of proximal interphalangeal septic arthritis and the subsequent wound management in the face of a multi-drug resistant <i>Pseudomonas aeruginosa</i> infection.

# Veterinary Record casereports

## Submission template for full cases

All case reports MUST be submitted online using this Word template. Please refer to the [Hints and Tips template](#) so you know what to include in each section

- <http://mc.manuscriptcentral.com/vetreccr>
- You will be asked for more detailed information on submission where you can also upload images, multimedia files, etc
- Further details are available in the [Instructions for authors](#)

For studies using client-owned animals the article must demonstrate a high standard (best practice) of veterinary care and have informed client consent

You, your practice or institution must be a subscriber to Veterinary Record Case Reports in order to submit. Subscribers can submit as many cases as they like, access all the published material, and re-use any published material for personal use and teaching without further permission.

- For more information on rates and how to purchase your subscription visit <http://vetrecordcasereports.bmj.com/site/about/Subslanding.xhtml>
- Contact your librarian, head of department or practice owner to see if your institution already has a subscription

### **TITLE OF CASE** *Do not include "a case report"*

Successful treatment of a multi-drug resistant *Pseudomonas aeruginosa* infection following a digit amputation in a Belgian Blue calf.

### **SUMMARY** *Up to 150 words summarising the case presentation and outcome (this will be freely available online)*

Digit amputation is a commonly performed surgery in cattle practice. The most frequent reason for digit amputation is septic pedal arthritis, but other indications include severe trauma, pedal osteitis, non-healing sole, wall or toe ulcers, osteomyelitis of P2, septic tenosynovitis of the distal digital flexor tendons and other infectious processes of the deep digital structures (Blowey, 2011). The procedure is considered a salvage procedure, but good rates of success are reported. The size of the patient is one of the key determinants of prognosis, with reported success rates varying between bulls, cows and calves. Reported complications include haemorrhage, avascular necrosis of the phalangeal fragments, wound infection and fracture of the partner claw (Heppelmann, 2009).

In this case report we describe digit amputation under regional and general anaesthesia for the treatment of proximal interphalangeal septic arthritis and the subsequent wound management in the face of a multi-drug resistant *Pseudomonas aeruginosa* infection.

### **BACKGROUND** *Why you think this case is important – why did you write it up?*

This case report highlights the benefits of targeted diagnostics (radiography and bacterial culture and sensitivity) in the treatment of refractory or complex orthopaedic cases in cattle and the use of non-pharmacological therapies (hydrogen peroxide and honey dressings) in the treatment of antibiotic resistant pathogens.

**CASE PRESENTATION** *Presenting features, clinical and environmental history*

1 An 8 month-old, male, Belgian Blue calf presented to the Royal (Dick) School of Veterinary  
2 Studies with a month long history of right forelimb lameness and swelling proximal to the  
3 coronary band. The farmer reported they had first noticed the calf to be severely lame 1  
4 week following return from an agricultural show. After an initial telephone consultation with  
5 the referring veterinarian, a two week course of daily intramuscular injection with penicillin  
6 at 8 mg/kg and dihydrostreptomycin at 10 mg/kg (Pen & Strep, Norbrook) was initiated. This  
7 was extended to 1 month without veterinary consultation.  
8

9 On admission, the calf was well grown, in good body condition and showed no signs of  
10 systemic illness. It was 4/5 lame on the right forelimb, which was moderately swollen from  
11 the coronary band to the level of the fetlock, more noticeably on the medial digit. There were  
12 two areas of granulation tissue over the medial pastern, one on the dorsal aspect (3 cm  
13 diameter) and one over the medial aspect (1.5 cm diameter); the latter had a discharging  
14 sinus.  
15

**INVESTIGATIONS** *If relevant*

16  
17  
18 The calf was sedated with intramuscular xylazine at 0.1 mg/kg (Rompun 2%, Bayer Plc) and  
19 cast using Reuff's method. Lateral and dorsopalmar radiographs of the lower limb (pastern)  
20 were then taken using a portable X-ray machine (Orange 1060HF, BCF Technology). The  
21 radiographs revealed complete destruction of the medial proximal interphalangeal joint  
22 (PIPj) with lysis and bony proliferation of the proximal aspect of the proximal phalanx (P1)  
23 (Figure 1). Due to the location, chronicity and severity of the infection, digit amputation by a  
24 high approach through phalanx I (P1) was indicated.  
25  
26

27 The calf was starved overnight and sedated with intramuscular xylazine at 0.2 mg/kg. Once  
28 in sternal recumbency, general anaesthesia was induced by the intravenous administration  
29 of ketamine (Ketamidor, Chanelle UK) at 2 mg/kg. The animal was placed in right lateral  
30 recumbency. Local anaesthesia was achieved by intravenous regional anaesthesia (IVRA). A  
31 tourniquet was applied to the leg immediately distal to the carpus and 10 ml of procaine and  
32 adrenaline (Adrenacaine, Norbrook) was administered intravenously into the radial vein  
33 (Anderson, 2008). The leg distal to the fetlock was surgically prepared. The interdigital skin  
34 was incised and the interdigital tissue divided to the level of distal P1. Pus issued from an  
35 interdigital abscess. Gigli wire was placed in the incision and the medial digit amputated with  
36 the cut being made perpendicular to the long axis of the limb (Anderson, 2008). The  
37 discharging sinus draining tract, the abscess capsule and any obviously necrotic bone on the  
38 cut surface were excised. A pressure bandage was then applied to the limb. Antibiosis with  
39 daily intramuscular administration of amoxicillin-clavulanate at 8.75 mg/kg (Synulox RTU,  
40 Zoetis) was instigated. Analgesia was provided with subcutaneous meloxicam at 0.5 mg/kg  
41 (Metacam 20 mg/ml, Boeringher Ingleheim).  
42

43 Two days later the calf was noted to still remain non-weight bearing on the affected limb and  
44 had not been observed suckling from its mother. The animal was placed in a crush, IVRA  
45 repeated and the pressure bandage removed. The cut end of P1 was observed to have a  
46 degree of devitalised tissue that was necrotic in appearance. This devitalised material was  
47 removed using a spoon curette to aid the process of granulation. An appositional protective  
48 Melolin (Smith&Nephew) dressing was applied.  
49

50 Due to the necrotic nature of the wound the bandage was removed after a further two days  
51 following xylazine sedation and casting as described above. The pastern was again  
52 radiographed and radiographic findings used to guide further curettage of any devitalised  
53 tissue under IVRA (Figure 2). The wound was swabbed for bacteriological culture and  
54 sensitivity due to the poor rate of healing, the infected appearance of the developing  
55 granulation tissue and the unpleasant smell and greenish discharge associated with the  
56 wound (Figure 3).  
57

**DIFFERENTIAL DIAGNOSIS** *If relevant*

--

- 1
- 2
- 3
- 4
- 5
- 6
- 7
- 8
- 9
- 10
- 11
- 12
- 13
- 14
- 15
- 16
- 17
- 18
- 19
- 20
- 21
- 22
- 23
- 24
- 25
- 26
- 27
- 28
- 29
- 30
- 31
- 32
- 33
- 34
- 35
- 36
- 37
- 38
- 39
- 40
- 41
- 42
- 43
- 44
- 45
- 46
- 47
- 48
- 49
- 50
- 51
- 52
- 53
- 54
- 55
- 56
- 57
- 58
- 59
- 60

**TREATMENT *If relevant***

Bacterial culture revealed that the wound was contaminated with *Pseudomonas aeruginosa*, which was resistant to: amikacin, ceftazidime, gentamicin, ampicillin, potentiated amoxicillin, cephalexin, cefovecin, tetracycline, tobramycin, potentiated sulphonamides, enrofloxacin and marbofloxacin. Antibiotic administration was therefore discontinued and the treatment regime changed to focus on topical wound management. The wound was lavaged daily with 3% hydrogen peroxide applied under pressure using a 30ml syringe and 16 gauge needle. Ordinary table honey was applied with a clean dressing daily. The size and temperament of the animal necessitated xylazine sedation at 0.05 mg/kg to facilitate this procedure. This was continued for one week, after which time the wound bed was filled with healthy granulation tissue (Figure 4), discharge was only seen on wound dressings and the degree of lameness was markedly improved. Wound dressing was then halted. The wound was covered in silver sulphadiazine cream and left open. The animal was discharged 3 days later.

**OUTCOME AND FOLLOW-UP**

The animal made a full recovery, but the farmer was warned of the increased risk (and poorer prognosis) of lameness in the remaining claw. The farmer reported the animal to be sound in all 4 limbs, in good body condition and thriving until movement onto a fattening unit.

Economic costs in practice could be a limiting factor in the aftercare and treatment plans of such cases and potentially impact the long-term prognosis. Economics alone should not impact animal welfare, and swift clinical interpretation and judgement can help limit the impact on animal health and welfare as well as reducing financial costs to the client by modifying treatment plans accordingly. The treatment costs surrounding this case have been explained in Table 1, with four different outcome scenarios.

	Scenario 1	Scenario 2	Scenario 3	Scenario 4
	Immediate euthanasia	Failure of treatment	Successful treatment: sale at 8 months	Successful treatment: finish to slaughter.
Sunk costs of weaned calf production.	-£450	-£450	-£450	-£450
Treatments previous to veterinary intervention (in this case).	-£72	-£72	-£72	-£72
Intervention costs in this case (drugs, diagnostics, bandaging material; excludes vet time and hospitalisation).			-£322	-£322
Intervention costs with failure of treatment (drugs and bandaging material for 14 days and extended antibiotics; excludes vet time).		-£360		
Approximate cost of euthanasia	-£40	-£40		£0
Approximate cost of animal disposal	-£100	-£100		£0
Value of weaned 8 month BB steer			£500	
Feed costs to finishing: £3 per day 240-300 days	£0	£0		-£720 to -£900
Value of finished animal: 500kg deadweight at 350p/kg	£0	£0		£1,750
Net gain/loss	-£662	-£1,022	-£344	£186 to £6

1 Table 1: Outline of possible treatment costs in this case, using four different outcome  
2 scenarios.  
3

4 Bacterial culture and sensitivity in this instance cost £30. In total the further diagnostics  
5 (radiography and culture and sensitivity) saved the farmer £40 in overall treatment costs  
6 (regardless of success) given that extended, inappropriate antibiotics would have been  
7 performed without these diagnostics. Vet time and hospitalisation costs have not been included  
8 in these costings given their variation in price in practice. When incorporating such figures,  
9 considerations to minimise the farmer's overall loss must be made. Given the estimated cost  
10 difference between immediate euthanasia and the successful treatment scenarios are between  
11 £300 and £700, this would allow for a generous amount of professional time to be charged and  
12 the case progression in this instance still remain economically viable.  
13

14 The incidence of *P. aeruginosa* in septic pedal arthritis in cattle and treatment success rates  
15 are unknown. Therefore when considering the potential cure rate of the procedure, the clinical  
16 judgement and interpretation of the clinician are the only tools available to help predict an  
17 economically successful outcome with benefits to both animal and farmer. Given the cost  
18 benefit of a successful outcome in this case is at least twice that of immediate euthanasia, if  
19 the clinician considers the prognostic outcome of a successful recovery to be around 50%, then  
20 further investigation of complicated septic pedal arthritis would be warranted on economic  
21 grounds alone.  
22

### 23 **DISCUSSION** *Include a very brief review of similar published cases*

24 Radiography of the bovine foot is not commonly performed, but in this case produced valuable  
25 information regarding the location of the infectious process and the severity of the lesion which  
26 was used to select the appropriate level of excision. It also guided curettage of the  
27 osteomyelitic bone allowing better removal of compromised tissue which would otherwise have  
28 acted as an impediment to healing. Ultrasonography can also be used in general practice in the  
29 assessment of pathological disease of bone, joints and surrounding soft tissues (Kofler, 1996).  
30 Whilst not necessarily as accurate as radiography in the assessment of bony structures, it  
31 may be more accessible to the general bovine practitioner in the assessment of such cases.  
32

33 Best practice for the responsible use of antimicrobials involves the use of culture and  
34 sensitivity to identify the organism(s) in question and select an appropriate antibiotic. This is  
35 not always practical when administering 'first line' treatments in farm animal medicine, but  
36 should always be considered when using antibiotic classes of critical importance to human  
37 medicine such as cephalosporins or fluoroquinolones. In this case, the suppurative nature of the  
38 wound after surgery warranted immediate antibiotics. Given that meat withdrawal was not of  
39 primary concern in a suckler calf at 8 months of age, a course of amoxicillin and clavulanic acid  
40 was initiated. All antibiotic therapy was immediately terminated following the identification of a  
41 multi-drug resistant wound infection. The use of bacterial culture and sensitivity not only  
42 reduced irresponsible antibiotics, but also saved the farmer money overall. This case highlights  
43 the need for prudent use of further diagnostics in complicated cases.  
44

45 *P. aeruginosa* is a facultative anaerobic Gram negative bacillus with reported resistance to  
46 certain beta-lactam and fluoroquinolone antibiotics of up to 30% in human medicine (Lister  
47 2009). It is an environmental contaminant, being commonly found in standing water. *P.*  
48 *aeruginosa* infection of wounds is not frequently reported in farm animal medicine, but when it  
49 does occur, resistance can be acquired rapidly through the acquisition of resistance genes on  
50 mobile genetic elements (e.g. plasmids) or through mutations that alter the expression and/or  
51 function of chromosomally encoded genes, making treatment difficult (Lister, 2009). *P.*  
52 *aeruginosa* wound infection has been reported more commonly in reptiles causing necrotic  
53 stomatitis/lesions and in dogs and cats causing pyoderma and otitis externa. The more  
54 common manifestation of *P. aeruginosa* in cattle produces either metritis or mastitis. It has  
55 been suggested that prolonged antibiotics favours the development of *P. aeruginosa* infection  
56 (Markey, 2013). Although it cannot be proven, the extended antibiotic therapy given to this  
57 animal before referral and diagnosis may have played a role in the development of a multi-  
58 drug resistant *P. aeruginosa* infection. The wound in this case was treated with silver  
59 sulfadiazine upon cessation of bandaging as successful treatment with silver sulfadiazine of  
60 deep-seated wound infections caused by *P. aeruginosa* has been reported in dogs (Hillier,

2012).

Honey has traditionally been included as a topical remedy in wound dressings. Its antimicrobial properties appear to relate partially to the high concentration of sugar being osmotically challenging to bacteria but also a high concentration of hydrogen peroxide within certain honey types. Further understanding of wound care relating to specific bacterial infections and the antimicrobial compounds of specific honeys is only now being investigated further (Roberts, 2012). Table honey was chosen in this instance compared to Manuka honey or medical-grade honey on economic grounds and its ready availability.

The cost of treatment in this case was greatly increased by the need to sedate the animal for each wound inspection and treatment. This was due to the affected limb being a forelimb and the size and temperament of the animal making restraint within a crush difficult. There are no known risks from repeated xylazine sedation in cattle. The withdrawal period of meat for human consumption for the product used is 24 h, hence the likelihood of residue build-up of xylazine at the dosing intervals described is negligible. In keeping with UK legislation, a 28 day withhold was applied, however at the end of these 28 days, the animal was still within its 42 day withdrawal period due to the use of potentiated amoxicillin earlier in the management of this case.

**LEARNING POINTS/TAKE HOME MESSAGES 3 to 5 bullet points – this is a required field**

- Diagnostic imaging can be a useful tool in guiding decision making in orthopaedic procedures in cattle.
- Culture and sensitivity of causative organisms should always be considered as part of responsible use of antimicrobials, particularly when poor treatment responses occur.
- Alternative therapies and wound care can produce excellent results.
- A considered approach to diagnostics and case management are vital to maintain animal welfare and minimise economic losses.

**REFERENCES *Harvard style***

**Anderson, D.E., Miesner, M.D., 2008. Local and regional anaesthesia in cattle. In: Veterinary Clinics of North America: Food Animal Practice, Field surgery of cattle, Part 1, Vol. 24, (2), p.223-224. Saunders 2008 Philadelphia.**

**Anderson, D.E., Miesner, M.D., 2008. Surgical diseases and techniques of the digit. In: Veterinary Clinics of North America: Food Animal Practice, Field surgery of cattle, Part 2, Vol. 24, (3), p.538-540. Saunders 2008 Philadelphia.**

**Blowey, R., 2011. Changing indications for digit amputation in cattle. Veterinary Record, Vol.169 (9), p.236.**

**Heppelmann, M., Kofler, J., Meyer, H., Rehage, J., Starke, A., 2009. Advances in surgical treatment of septic arthritis of the distal interphalangeal joint in cattle: A review. The Veterinary Journal, Vol.182, Issue 2, p.162–175.**

**Kofler, J., 1996. Arthrosonography-the use of diagnostic ultrasound in septic and traumatic arthritis in cattle-a retrospective study of 25 patients. British Veterinary Journal. Vol. 152, issue 6, p. 683-98.**

**Lister, P.D., Wolter, D.J., Hanson, N.D., 2009. Antibacterial-Resistant *Pseudomonas aeruginosa*: Clinical Impact and Complex Regulation of Chromosomally Encoded Resistance Mechanisms. CLINICAL MICROBIOLOGY REVIEWS, Vol. 22, No. 4, p. 582–610.**

**Roberts, A.E.L., Maddocks, S.E., Cooper, R.A., 2012. Manuka honey is bactericidal against *Pseudomonas aeruginosa* and results in differential expression of *oprF* and *algD*. Microbiology, Vol.158, p.3005–3013.**



Hillier, A., Alcorn, J.R., Cole, L.K., Kowalski, J.J., 2006. Pyoderma caused by *Pseudomonas aeruginosa* infection in dogs: 20 cases. *Vet Dermatology*, Vol.17, (6), p.432-9.

Markey, B., Leonard, F., Archambault, M., Cullinane, A., Maguire, D., 2013. *Pseudomonas*, *Burkholderia* and *Stenotrophomonas* species. In: *Clinical Veterinary Microbiology*, Section 2: bacteriology, chapter 18, p. 275-288. Mosby Elsevier 2013, Oxford UK.

#### FIGURE/VIDEO CAPTIONS *figures should NOT be embedded in this document*

**Figure 1: Lateral radiograph of the right forelimb on admission, with arrow indicating destruction of the medial proximal interphalangeal joint (PIPj) with lysis and bony proliferation of the proximal aspect of the proximal phalanx (P1).**

**Figure 2: Repeat radiograph of right forelimb 2 weeks following digit amputation. Osteomyelitis and necrosis of the distal proximal phalanx (P1) can be seen.**

**Figure 3: Photograph of digit amputation site 2 weeks following surgery. Poor healing and necrotic granulation tissue associated with the wound is visible.**

**Figure 4: Photograph of digit amputation site 3 weeks following surgery. Healthy granulation tissue after lavage with hydrogen peroxide and 3 days of honey impregnated bandaging.**

#### OWNER'S PERSPECTIVE *Optional*

#### Copyright Statement

I, [Martin Tomlinson], The Corresponding Author, has the right to assign on behalf of all authors and does assign on behalf of all authors, a full assignment of all intellectual property rights for all content within the submitted case report (other than as agreed with the BMJ Publishing Group Ltd and the British Veterinary Association) ("BMJ" and "BVA") in any media known now or created in the future, and permits this case report (if accepted) to be published on Veterinary Record Case Reports and to be fully exploited within the remit of the assignment as set out in the assignment which has been read <http://journals.bmj.com/site/misc/vetreccrcopyright.pdf>

**Date: Martin Tomlinson May 2016**

#### PLEASE SAVE YOUR TEMPLATE WITH THE FOLLOWING FORMAT:

Corresponding author's last name and date of submission, eg,

Smith\_June\_2013.doc

1  
2  
3  
4  
5  
6  
7  
8  
9  
10  
11  
12  
13  
14  
15  
16  
17  
18  
19  
20  
21  
22  
23  
24  
25  
26  
27  
28  
29  
30  
31  
32  
33  
34  
35  
36  
37  
38  
39  
40  
41  
42  
43  
44  
45  
46  
47  
48  
49  
50  
51  
52  
53  
54  
55  
56  
57  
58  
59  
60

# Veterinary Record casereports

## Submission template for full cases

All case reports MUST be submitted online using this Word template. Please refer to the [Hints and Tips template](#) so you know what to include in each section

- <http://mc.manuscriptcentral.com/vetreccr>
- You will be asked for more detailed information on submission where you can also upload images, multimedia files, etc
- Further details are available in the [Instructions for authors](#)

For studies using client-owned animals the article must demonstrate a high standard (best practice) of veterinary care and have informed client consent

You, your practice or institution must be a subscriber to Veterinary Record Case Reports in order to submit. Subscribers can submit as many cases as they like, access all the published material, and re-use any published material for personal use and teaching without further permission.

- For more information on rates and how to purchase your subscription visit <http://vetrecordcasereports.bmj.com/site/about/Subslanding.xhtml>
- Contact your librarian, head of department or practice owner to see if your institution already has a subscription

### **TITLE OF CASE** *Do not include "a case report"*

Successful treatment of a multi-drug resistant *Pseudomonas aeruginosa* infection following a digit amputation in a Belgian Blue calf.

### **SUMMARY** *Up to 150 words summarising the case presentation and outcome (this will be freely available online)*

Digit amputation is a commonly performed surgery in cattle practice. The most frequent reason for digit amputation is septic pedal arthritis, but other indications include severe trauma, pedal osteitis, non-healing sole, wall or toe ulcers, osteomyelitis of P2, septic tenosynovitis of the distal digital flexor tendons and other infectious processes of the deep digital structures (Blowey, 2011). The procedure is considered a salvage procedure, but good rates of success are reported. The size of the patient is one of the key determinants of prognosis, with reported success rates varying between bulls, cows and calves. Reported complications include haemorrhage, avascular necrosis of the phalangeal fragments, wound infection and fracture of the partner claw (Heppelmann, 2009).

In this case report we describe digit amputation under regional and general anaesthesia for the treatment of proximal interphalangeal septic arthritis and the subsequent wound management in the face of a multi-drug resistant *Pseudomonas aeruginosa* infection.

### **BACKGROUND** *Why you think this case is important – why did you write it up?*

This case report highlights the benefits of targeted diagnostics (radiography and bacterial culture and sensitivity) in the treatment of refractory or complex orthopaedic cases in cattle and the use of non-pharmacological therapies (hydrogen peroxide and honey dressings) in the treatment of antibiotic resistant pathogens.

**CASE PRESENTATION** *Presenting features, clinical and environmental history*

1 An 8 month-old, male, Belgian Blue calf presented to the Royal (Dick) School of Veterinary  
2 Studies with a month long history of right forelimb lameness and swelling proximal to the  
3 coronary band. The farmer reported they had first noticed the calf to be severely lame 1  
4 week following return from an agricultural show. After an initial telephone consultation with  
5 the referring veterinarian a two week course of daily intramuscular injection with penicillin at  
6 8mg/kg & dihydrostreptomycin at 10mg/kg (Pen & Strep, Norbrook) was initiated by the  
7 farmer, this was extended to 1 month without veterinary consultation as the farmer noted  
8 minor improvements in the degree of inflammation however no improvement in the degree  
9 of lameness had been observed.

10  
11 On admission, the calf was well grown, in good body condition and showed no signs of  
12 systemic illness. It was 4/5 lame on the right forelimb, which was moderately swollen from  
13 the coronary band to the level of the fetlock, more noticeably on the medial digit. There were  
14 two areas of granulation tissue over the medial pastern, one on the dorsal aspect (3 cm  
15 diameter) and one over the medial aspect (1.5 cm diameter); the latter had a discharging  
16 sinus.

**INVESTIGATIONS** *If relevant*

17  
18  
19  
20  
21 The calf was sedated with intramuscular xylazine at 0.1mg/kg (Rompun 2%, Bayer Plc) and  
22 cast using Reuff's method. Lateral and dorsopalmar radiographs of the lower limb (pastern)  
23 were then taken using a portable X-ray machine (Orange 1060HF, BCF Technology). The  
24 radiographs revealed complete destruction of the medial proximal interphalangeal joint  
25 (PIPj) with lysis and bony proliferation of the proximal aspect of the proximal phalanx (P1)  
26 (Figure 1). Due to the location, chronicity and severity of the infection, digit amputation by  
27 a high approach through phalanx I (P1) was indicated.

28  
29 The calf was starved overnight and sedated with intramuscular xylazine at 0.2mg/kg. Once  
30 in sternal recumbency, general anaesthesia was induced by the intravenous administration  
31 of ketamine (Ketamidor, Chanelle UK) at 2mg/kg. The animal was placed in right lateral  
32 recumbency. Local anaesthesia was achieved by intravenous regional anaesthesia (IVRA). A  
33 tourniquet was applied to the leg immediately distal to the carpus and 10 ml of procaine and  
34 adrenaline (Adrenacaine, Norbrook) was administered intravenously into the radial vein  
35 (Anderson, 2008). The leg distal to the fetlock was surgically prepared. The interdigital skin  
36 was incised and the interdigital tissue divided to the level of distal P1. Pus issued from an  
37 interdigital abscess. Gigli wire was placed in the incision and the medial digit amputated with  
38 the cut being made perpendicular to the long axis of the limb (Anderson, 2008). The  
39 discharging sinus draining tract, the abscess capsule and any obviously necrotic bone on the  
40 cut surface were excised. A pressure bandage was then applied to the limb. Antibiosis with  
41 daily intramuscular administration of amoxicillin-clavulanate at 8.75mg/kg (Synulox RTU,  
42 Zoetis) was instigated. Analgesia was provided with subcutaneous meloxicam at 0.5mg/kg  
43 (Metacam 20mg/ml, Boeringher Ingleheim).

44  
45 Two days later the calf was noted to still remain non-weight bearing on the affected limb and  
46 had not been observed suckling from its mother. The animal was placed in a crush, IVRA  
47 repeated and the pressure bandage removed. The cut end of P1 was observed to have a  
48 degree of devitalised tissue that was necrotic in appearance. This devitalised material was  
49 removed using a spoon curette to aid the process of granulation. An appositional protective  
50 Melolin (Smith&Nephew) dressing was applied.

51  
52 Due to the necrotic nature of the wound the bandage was removed after a further two days  
53 following xylazine sedation and casting as described above. The pastern was again  
54 radiographed and radiographic findings used to guide further curettage of any devitalised  
55 tissue under IVRA (Figure 2). The wound was swabbed for bacteriological culture and  
56 sensitivity due to the poor rate of healing, the infected appearance of the developing  
57 granulation tissue and the unpleasant smell and greenish discharge associated with the  
58 wound (Figure 3).

<b>DIFFERENTIAL DIAGNOSIS <i>If relevant</i></b>

- 1
- 2
- 3
- 4
- 5
- 6
- 7
- 8
- 9
- 10
- 11
- 12
- 13
- 14
- 15
- 16
- 17
- 18
- 19
- 20
- 21
- 22
- 23
- 24
- 25
- 26
- 27
- 28
- 29
- 30
- 31
- 32
- 33
- 34
- 35
- 36
- 37
- 38
- 39
- 40
- 41
- 42
- 43
- 44
- 45
- 46
- 47
- 48
- 49
- 50
- 51
- 52
- 53
- 54
- 55
- 56
- 57
- 58
- 59
- 60

**TREATMENT *If relevant***

Bacterial culture revealed that the wound was contaminated with *Pseudomonas aeruginosa* which was resistant to, Amikacin, Ceftazidime, Gentamicin, Ampicillin, Potentiated Amoxicillin, Cephalexin, Cefovecin, Tetracycline, Tobramycin, Potentiated Sulphonamides, Enrofloxacin and Marbofloxacin. Antibiotic administration was therefore discontinued and the treatment regime changed to focus on topical wound management. The wound was lavaged daily with 3% Hydrogen Peroxide applied under pressure using a 30ml syringe and 16 gauge needle. Ordinary table honey was applied with a clean dressing daily. The size and temperament of the animal necessitated xylazine sedation at 0.05mg/kg to facilitate this procedure. This was continued for one week, after which time the wound bed was filled with healthy granulation tissue (Figure 4), only discharge was seen on wound dressings and the degree of lameness was markedly improved. Wound dressing was then halted. The wound was covered in silver sulphadiazine cream and left open. The animal was discharged 3 days later.

**OUTCOME AND FOLLOW-UP**

The animal made a full recovery but the farmer was warned of the increased risk (and poorer prognosis) of lameness in the remaining claw. The farmer reported the animal to be sound in all 4 limbs, in good body condition and thriving until movement onto a fattening unit.

Economic costs in practice could be a limiting factor in the aftercare and treatment plans of such cases and potentially impact the long-term prognosis. Economics alone should not impact animal welfare, and swift clinical interpretation and judgement can help limit the impact on animal health and welfare as well as reducing financial costs to the client by modifying treatment plans accordingly. The treatment costs surrounding this case have been explained in Table 1, with four different outcome scenarios.

	Scenario 1	Scenario 2	Scenario 3	Scenario 4
	Immediate euthanasia	Failure of treatment	Successful treatment: sale at 8 months	Successful treatment: finish to slaughter.
Sunk costs of weaned calf production.	-£450	-£450	-£450	-£450
Treatments previous to veterinary intervention. (In this case)	-£72	-£72	-£72	-£72
Intervention costs in this case: (Drugs, diagnostics, bandaging material; excludes vet time and hospitalisation.)			-£322	-£322
Intervention costs with failure of treatment: (Drugs and bandaging material for 14 days and extended antibiotics; excludes vet time.)		-£360		
Approximate cost of euthanasia	-£40	-£40		£0
Approximate cost of animal disposal	-£100	-£100		£0
Value of weaned 8 month BBx steer			£500	
Feed costs to finishing: £3 per day 240-300 days	£0	£0		(-)£720 - £900
Value of finished animal: 500kg deadweight at 350p/kg	£0	£0		£1,750
Net gain/loss	-£662	-£1,022	-£344	£186 -£6

1 Table 1: Outline of possible treatment costs in this case, using four different outcome  
2 scenarios.  
3

4  
5 Further diagnostics (radiography and culture and sensitivity) in this case saved the farmer £40  
6 in overall treatment costs (regardless of success) given that extended, inappropriate antibiotics  
7 would have been performed without these diagnostics. Vet time and hospitalisation costs have  
8 not been included in these costings given their variation in price in practice. When  
9 incorporating such figures, considerations to minimise the farmer's overall loss must be made.  
10 Given the estimated cost difference between immediate euthanasia and the successful  
11 treatment scenarios are between £300 and £700, this would allow for a generous amount of  
12 professional time to be charged and the case progression in this instance still remain  
13 economically viable.  
14

15 The incidence of *P. aeruginosa* in septic pedal arthritis in cattle and treatment success rates  
16 are unknown. Therefore when considering the potential cure rate of the procedure, the clinical  
17 judgement and interpretation of the clinician are the only tools available to help predict an  
18 economically successful outcome with benefits to both animal and farmer. Given the cost  
19 benefit of a successful outcome in this case is at least twice that of immediate euthanasia, if  
20 the clinician considers the prognostic outcome of a successful recovery to be around 50%, then  
21 further investigation of complicated septic pedal arthritis would be warranted on economic  
22 grounds alone.  
23

#### 24 **DISCUSSION** *Include a very brief review of similar published cases*

25 Radiography of the bovine foot is not commonly performed, but in this case produced valuable  
26 information regarding the location of the infectious process and the severity of the lesion which  
27 was used to select the appropriate level of excision. It also guided curettage of the  
28 osteomyelitic bone allowing better removal of compromised tissue which would otherwise have  
29 acted as an impediment to healing. Ultrasonography can also be used in general practice in the  
30 assessment of pathological disease of bone, joints and surrounding soft tissues (Kofler,  
31 1996). While not necessarily as accurate as radiography in the assessment of bony  
32 structures and perhaps dependent upon user skill, it may be more accessible to the general  
33 bovine practitioner in the assessment of such complex cases.  
34

35 Best practice for responsible use of antimicrobials is to be guided with culture and sensitivity of  
36 the organisms in question. This is not always practical when administering 'first line'  
37 treatments in farm animal medicine but should always be considered when using antibiotic  
38 classes of critical importance to human medicine such as cephalosporins or fluoroquinolones. In  
39 this case the suppurative nature of the wound after surgical correction warranted immediate  
40 antibiotics. Given meat withdrawal was not of primary concern in a suckler calf at 8 months of  
41 age a clinical course of amoxicillin and clavulanic acid was initiated. All antibiotic therapy was  
42 immediately terminated upon lack of bacterial susceptibility on culture and sensitivity. The use  
43 of bacterial culture and sensitivity not only reduced irresponsible antibiotics but also saved the  
44 farmer money overall. This case highlights the need for prudent use of further diagnostics in  
45 complicated cases.  
46

47 *P. aeruginosa* is a facultative anaerobic Gram negative bacillus with reported resistance to  
48 certain beta-lactam and fluoroquinolone antibiotics of up to 30% in human medicine (Lister  
49 2009). It is an environmental contaminant, being commonly found in standing water. *P.*  
50 *aeruginosa* infection of wounds is not frequently reported in farm animal medicine, but when it  
51 does occur, resistance can be acquired rapidly through the acquisition of resistance genes on  
52 mobile genetic elements (e.g. plasmids) or through mutational processes that alter the  
53 expression and/or function of chromosomally encoded mechanisms, making treatment difficult  
54 (Lister, 2009). *P. aeruginosa* wound infection has been reported more commonly in reptiles  
55 causing necrotic stomatitis/lesions and in dogs and cats causing pyoderma and otitis externa.  
56 The more common manifestation of *P. aeruginosa* in cattle produces either metritis or mastitis.  
57 It has been suggested that prolonged antibiotics favours the development of *P. aeruginosa*  
58 infection (Markey, 2013). Although it cannot be proven the extended antibiotic therapy given  
59 to this animal before referral and diagnosis may have played a role in the development of a  
60 multi-drug resistant *Pseudomonas*. The wound in this case was treated with silver sulfadiazine

upon cessation of bandaging. Successful treatment of deep-seated wound infections caused by *P. aeruginosa* with silver sulfadiazine has also been reported in dogs (Hillier, 2012).

Honey has traditionally been included as a topical remedy in wound dressings. Its antimicrobial properties appear to relate partially to the high concentration of sugar being osmotically challenging to bacteria but also a high concentration of hydrogen peroxide within certain honey types. Further understanding of wound care relating to specific bacterial infections and the antimicrobial compounds of specific honeys is only now being investigated further (Roberts, 2012). Table honey was chosen in this instance compared to Manuka honey or medical-grade honey on economic grounds and its readable availability.

The cost of treatment in this case was greatly increased by the need to sedate the animal for each wound inspection and treatment. This was due to the affected limb being a forelimb and the size and temperament of the animal making restraint within a crush difficult. There are no known risks from repeated xylazine sedation in cattle. The withdrawal period of meat for human consumption for the product used is 24 h, hence the likelihood of residue build-up of xylazine at the dosing intervals described is negligible. In keeping with UK legislation, a 28 day withhold was applied, however at the end of these 28 days, the animal was still within its 42 day withdrawal period due to the use of potentiated amoxicillin earlier in the management of this case.

#### **LEARNING POINTS/TAKE HOME MESSAGES 3 to 5 bullet points – this is a required field**

- Diagnostic imaging can be a useful tool in guiding decision making in orthopaedic procedures in cattle.
- Culture and sensitivity of causative organisms should always be considered as part of responsible use of antimicrobials, particularly when poor treatment responses occur.
- Alternative therapies and wound care can produce excellent results.
- A considered approach to diagnostics and case management are vital to maintain animal welfare and minimise economic losses.

#### **REFERENCES *Harvard style***

- Anderson, D.E., Miesner, M.D., 2008. Local and regional anaesthesia in cattle. In: Veterinary Clinics of North America: Food Animal Practice, Field surgery of cattle, Part 1, Vol. 24, (2), p.223-224. Saunders 2008 Philadelphia.**
- Anderson, D.E., Miesner, M.D., 2008. Surgical diseases and techniques of the digit. In: Veterinary Clinics of North America: Food Animal Practice, Field surgery of cattle, Part 2, Vol. 24, (3), p.538-540. Saunders 2008 Philadelphia.**
- Blowey, R., 2011. Changing indications for digit amputation in cattle. Veterinary Record, Vol.169 (9), p.236.**
- Heppelmann, M., Kofler, J., Meyer, H., Rehage, J., Starke, A., 2009. Advances in surgical treatment of septic arthritis of the distal interphalangeal joint in cattle: A review. The Veterinary Journal, Vol.182, Issue 2, p.162–175.**
- Kofler, J., 1996. Arthrosonography-the use of diagnostic ultrasound in septic and traumatic arthritis in cattle-a retrospective study of 25 patients. British Veterinary Journal. Vol. 152, issue 6, p. 683-98.**
- Lister, P.D., Wolter, D.J., Hanson, N.D., 2009. Antibacterial-Resistant *Pseudomonas aeruginosa*: Clinical Impact and Complex Regulation of Chromosomally Encoded Resistance Mechanisms. CLINICAL MICROBIOLOGY REVIEWS, Vol. 22, No. 4, p. 582–610.**
- Roberts, A.E.L., Maddocks, S.E., Cooper, R.A., 2012. Manuka honey is bactericidal against *Pseudomonas aeruginosa* and results in differential expression of *oprF* and**



algD. Microbiology, Vol.158, p.3005–3013.

Hillier, A., Alcorn, J.R., Cole, L.K., Kowalski, J.J., 2006. Pyoderma caused by *Pseudomonas aeruginosa* infection in dogs: 20 cases. *Vet Dermatology*, Vol.17, (6), p.432-9.

Markey, B., Leonard, F., Archambault, M., Cullinane, A., Maguire, D., 2013. *Pseudomonas*, *Burkholderia* and *Stenotrophomonas* species. In: *Clinical Veterinary Microbiology*, Section 2: bacteriology, chapter 18, p. 275-288. Mosby Elsivar 2013, Oxford UK.

**FIGURE/VIDEO CAPTIONS** *figures should NOT be embedded in this document*

**Figure 1: Lateral radiograph of the right forelimb on admission, with arrow indicating destruction of the medial proximal interphalangeal joint (PIPj) with lysis and bony proliferation of the proximal aspect of the proximal phalanx (P1).**

**Figure 2: Repeat radiograph of right forelimb 2 weeks following digit amputation. Osteomyelitis and necrosis of the distal proximal phalanx (P1) can be seen.**

**Figure 3: Photograph of digit amputation site 2 weeks following surgery. Poor healing and necrotic granulation tissue associated with the wound prior to bacteriology is evidenced.**

**Figure 4: Photograph of digit amputation site 3 weeks following surgery. Healthy granulation tissue after lavage with Hydrogen Peroxide and 3 days of honey impregnated bandaging.**

**OWNER'S PERSPECTIVE** *Optional*

**Copyright Statement**

I, [Martin Tomlinson], The Corresponding Author, has the right to assign on behalf of all authors and does assign on behalf of all authors, a full assignment of all intellectual property rights for all content within the submitted case report (other than as agreed with the BMJ Publishing Group Ltd and the British Veterinary Association) ("BMJ" and "BVA") in any media known now or created in the future, and permits this case report (if accepted) to be published on Veterinary Record Case Reports and to be fully exploited within the remit of the assignment as set out in the assignment which has been read <http://journals.bmj.com/site/misc/vetreccrcopyright.pdf>

**Date: Martin Tomlinson March 2016**

**PLEASE SAVE YOUR TEMPLATE WITH THE FOLLOWING FORMAT:**

Corresponding author's last name and date of submission, eg,

Smith\_June\_2013.doc

1  
2  
3  
4  
5  
6  
7  
8  
9  
10  
11  
12  
13  
14  
15  
16  
17  
18  
19  
20  
21  
22  
23  
24  
25  
26  
27  
28  
29  
30  
31  
32  
33  
34  
35  
36  
37  
38  
39  
40  
41  
42  
43  
44  
45  
46  
47  
48  
49  
50  
51  
52  
53  
54  
55  
56  
57  
58  
59  
60

1  
2  
3  
4  
5  
6  
7  
8  
9  
10  
11  
12  
13  
14  
15  
16  
17  
18  
19  
20  
21  
22  
23  
24  
25  
26  
27  
28  
29  
30  
31  
32  
33  
34  
35  
36  
37  
38  
39  
40  
41  
42  
43  
44  
45  
46  
47  
48  
49  
50  
51  
52  
53  
54  
55  
56  
57  
58  
59  
60

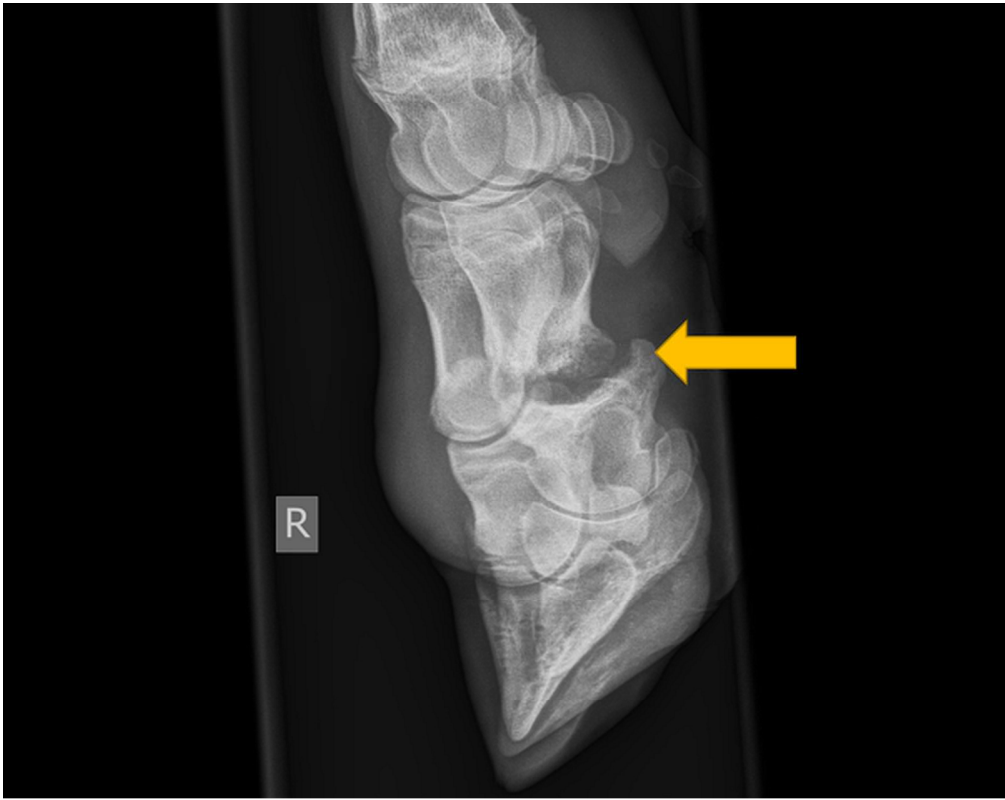
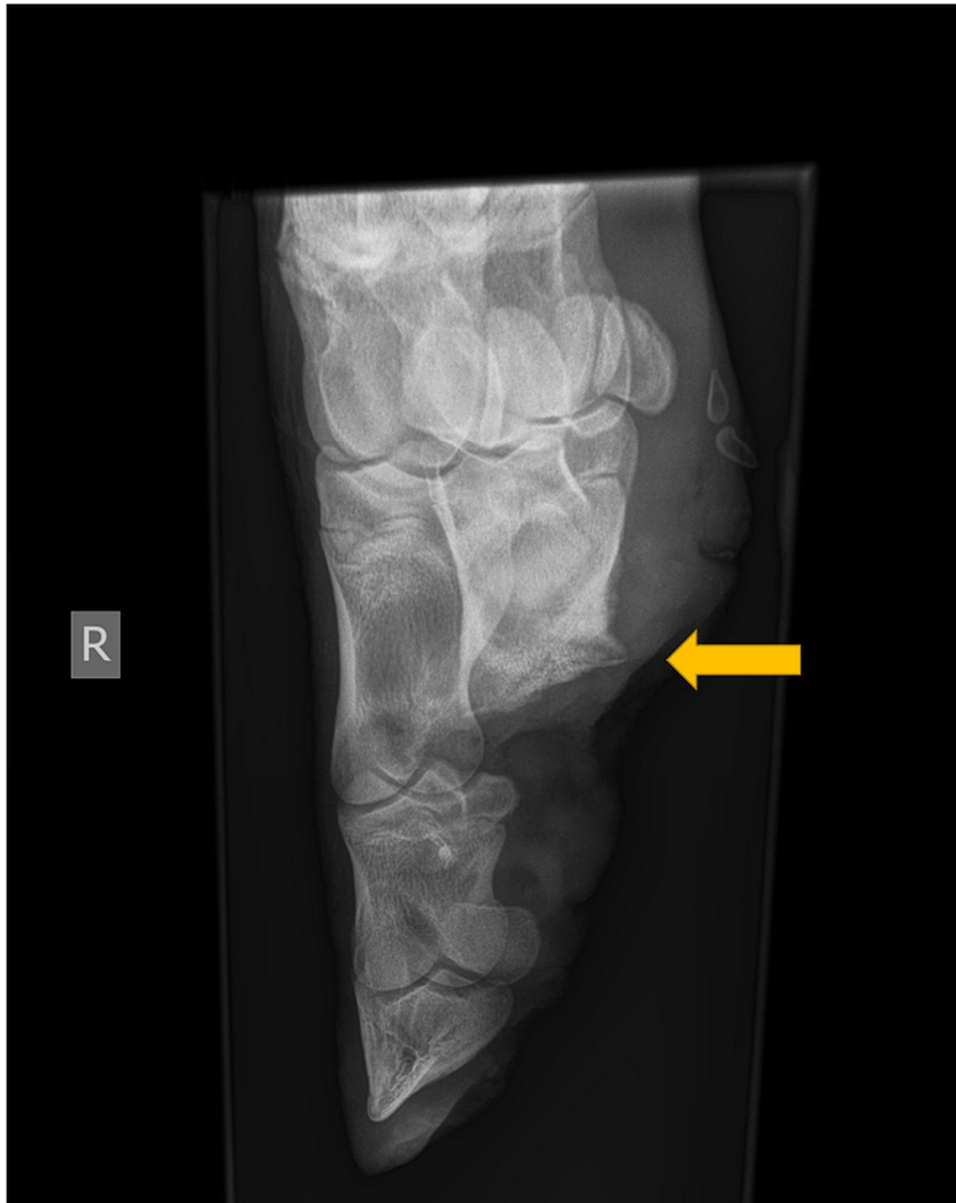


Figure 1: Lateral radiograph of the right forelimb on admission, with arrow indicating destruction of the medial proximal interphalangeal joint (PIPj) with lysis and bony proliferation of the proximal aspect of the proximal phalanx (P1).



46  
47  
48  
49  
50  
51  
52  
53  
54  
55  
56  
57  
58  
59  
60

Figure 2: Repeat radiograph of right forelimb 2 weeks following digit amputation. Osteomyelitis and necrosis of the distal proximal phalanx (P1) can be seen.

1  
2  
3  
4  
5  
6  
7  
8  
9  
10  
11  
12  
13  
14  
15  
16  
17  
18  
19  
20  
21  
22  
23  
24  
25  
26  
27  
28  
29  
30  
31  
32  
33  
34  
35  
36  
37  
38  
39  
40  
41  
42  
43  
44  
45  
46  
47  
48  
49  
50  
51  
52  
53  
54  
55  
56  
57  
58  
59  
60

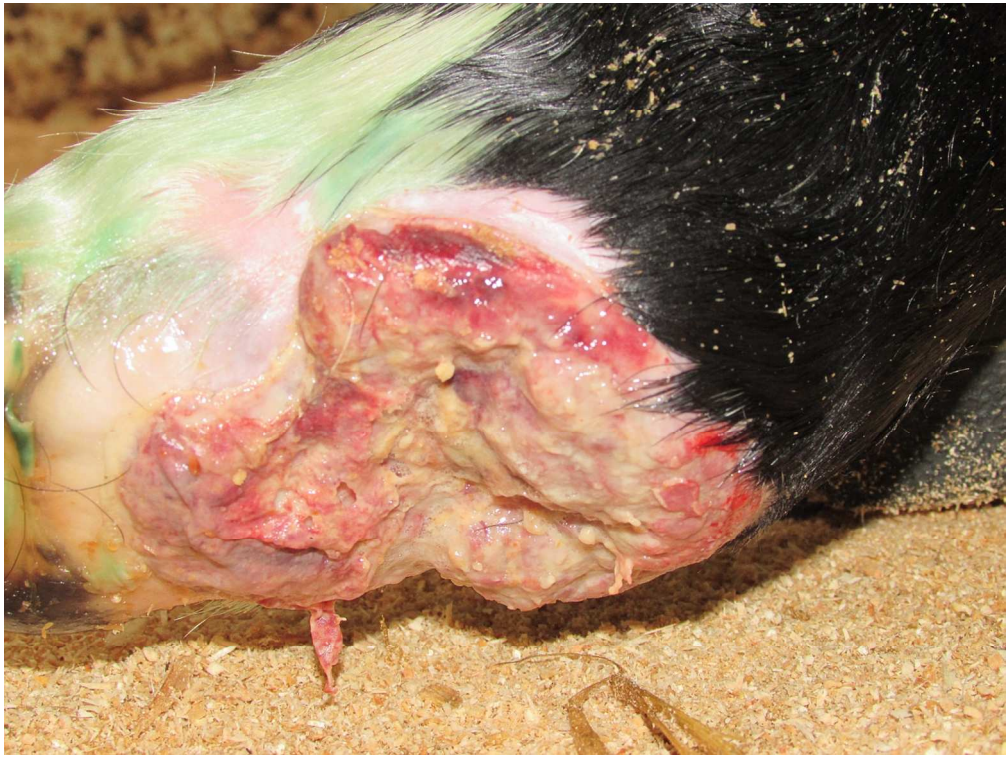

Figure 3: Photograph of digit amputation site 2 weeks following surgery. Poor healing and necrotic granulation tissue is visible.  
119x90mm (300 x 300 DPI)

1  
2  
3  
4  
5  
6  
7  
8  
9  
10  
11  
12  
13  
14  
15  
16  
17  
18  
19  
20  
21  
22  
23  
24  
25  
26  
27  
28  
29  
30  
31  
32  
33  
34  
35  
36  
37  
38  
39  
40  
41  
42  
43  
44  
45  
46  
47  
48  
49  
50  
51  
52  
53  
54  
55  
56  
57  
58  
59  
60

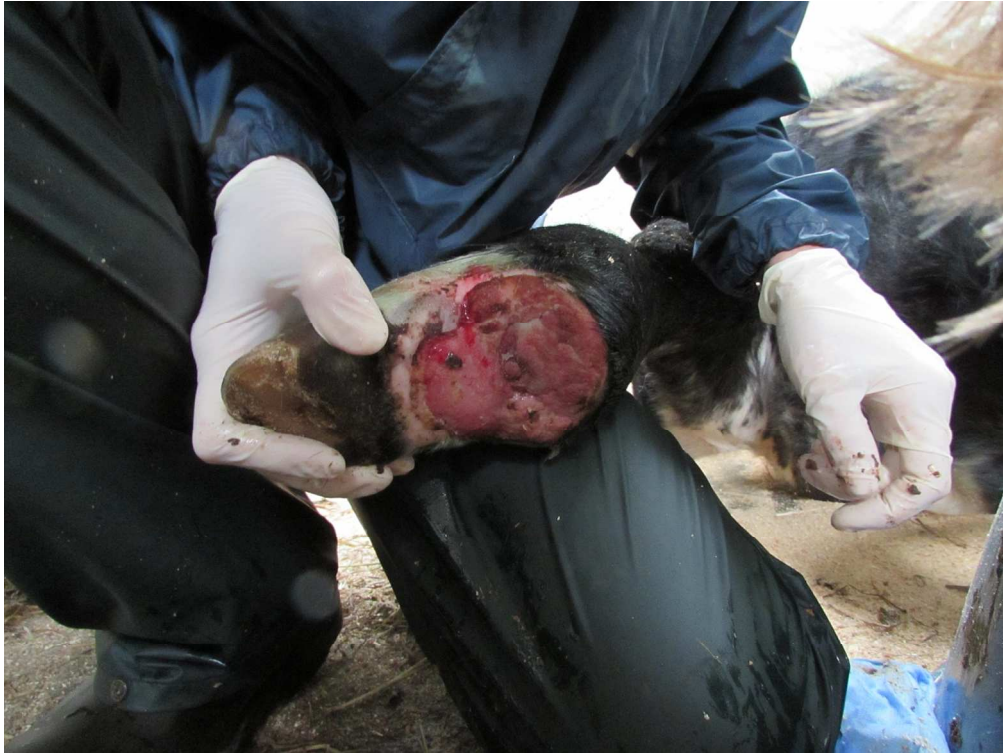

Figure 4: Photograph of digit amputation site 3 weeks following surgery. Healthy granulation tissue after lavage with hydrogen peroxide and 3 days of honey impregnated bandaging.  
119x90mm (300 x 300 DPI)