



THE UNIVERSITY *of* EDINBURGH

Edinburgh Research Explorer

How normal is this brain? Development and testing of a new MR template for voxel-based brain ranking.

Citation for published version:

Dickie, DA, Job, D, Rodriguez Gonzalez, D, Shenkin, S & Wardlaw, J 2013, 'How normal is this brain? Development and testing of a new MR template for voxel-based brain ranking.' The 19th Annual Meeting of the Organization for Human Brain Mapping, Seattle, United Kingdom, 16/06/13 - 20/06/13, .

Link:

[Link to publication record in Edinburgh Research Explorer](#)

Document Version:

Other version

General rights

Copyright for the publications made accessible via the Edinburgh Research Explorer is retained by the author(s) and / or other copyright owners and it is a condition of accessing these publications that users recognise and abide by the legal requirements associated with these rights.

Take down policy

The University of Edinburgh has made every reasonable effort to ensure that Edinburgh Research Explorer content complies with UK legislation. If you believe that the public display of this file breaches copyright please contact openaccess@ed.ac.uk providing details, and we will remove access to the work immediately and investigate your claim.



How normal is this brain? Development and testing of a new MR template for voxel-based brain ranking

Abstract Submission No:

1774

Authors:

David Alexander Dickie¹, Dominic Job¹, David Rodriguez Gonzalez¹, Susan Shenkin¹, Joanna Wardlaw¹

Institutions:

¹The University of Edinburgh, SINAPSE Collaboration, Edinburgh, United Kingdom

Introduction:

Normal reference magnetic resonance (MR) templates of brain structure may support patient diagnoses. For example, when faced with brain scans from only one time point, they allow clinicians to determine if and where a patient is within a normal range [2]. Based on whole brain ranking, previous templates were developed for visual comparison with patient scans [2]. As there may only be subtle brain structure differences between diseased and healthy subjects [5,6], it may be useful to create a template that, rather than the brain as a whole, ranks each MR voxel relative to a normal range.

Current voxel-based analyses use statistical tests that may be limited by their assumptions, e.g. they require voxel smoothing, and they do not use a normal range to rank subjects [7,3]. A voxel-based ranking template has been developed for younger ages but defined only normal limits (not levels within the limits) [4].

Here we describe a MR template that defines the normal limits and levels (rank order) of brain structure voxel values for older (≥ 60 years) subjects. We then provide results from using the template to rank Alzheimer's disease (AD) and matched control subjects.

Methods:

T1W MR images of the brain from 138 AD and 236 matched normal subjects (age range 60-94, mean ~ 76 years) were acquired from the AD Neuroimaging Initiative (ADNI; AD $n=89$, normal $n=138$) and Open Access Series of Imaging Studies (OASIS; AD $n=49$, normal $n=98$). We extracted brains by registering and applying the Montreal Neurological Institute (MNI) brain mask to each subject, manually correcting errors, e.g. remaining skull. We performed bias field correction and generated grey matter (GM) and white matter (WM) tissue images automatically [8]. In these images, each voxel has a value between 0 and 1, which is the proportion of tissue in that voxel.

Normal templates of GM and WM were created with 98 randomly selected normal subjects ('development group', 49 from ADNI and 49 from OASIS). Each template consisted of the 5th, 25th, 50th, 75th, and 95th percentiles of tissue proportion in each voxel (figure 1). These percentiles were calculated from the rank order of tissue proportions in each voxel in the development group.

Tissue images from remaining subjects (AD $n=138$, control $n=138$, 'testing groups') were registered and quantitatively compared with the templates: in each voxel, testing subject tissue proportion was ranked as the nearest normal percentile, or abnormal, if lower than the template range. Median GM rank images were created for each testing group.

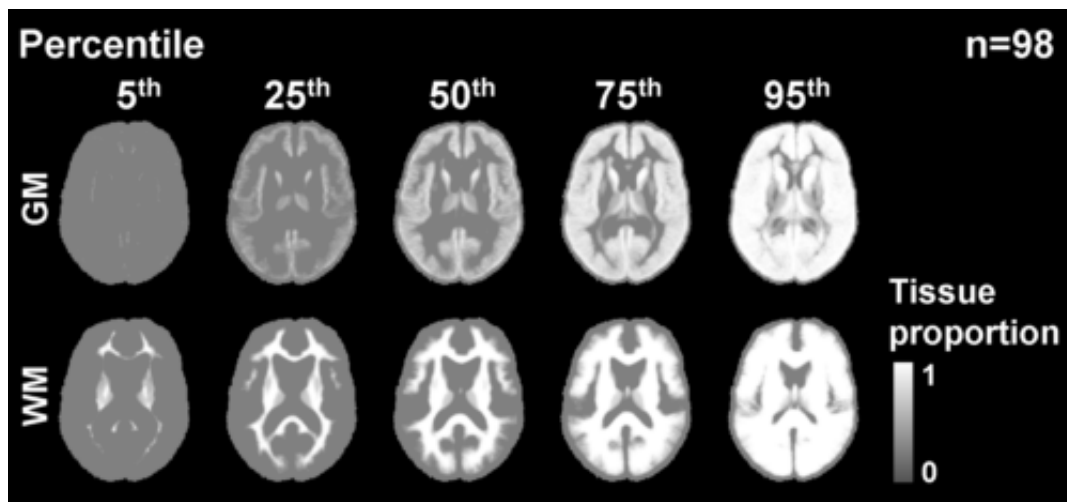


Figure 1. Templates of the normal levels and limits (rank order) of voxel GM and WM proportion. The templates show that in the rank order of tissue proportions in individual voxels, the 5th percentile is often close to zero. GM=grey matter; WM=white matter.

Results:

From comparison with the templates, abnormal GM proportion in the medial temporal lobe (MTL) was found in 86% of AD subjects; WM lesions around the lateral ventricles were also highlighted, e.g. subjects "AD01" and "AD02", respectively in figure 2. AD and control subjects had similar ranks of GM proportion in the upper part of the cortex but AD subjects were ranked lower in the MTL (figure 3). This was found in both (ADNI and OASIS) testing cohorts and is consistent with findings from serial imaging studies [6].

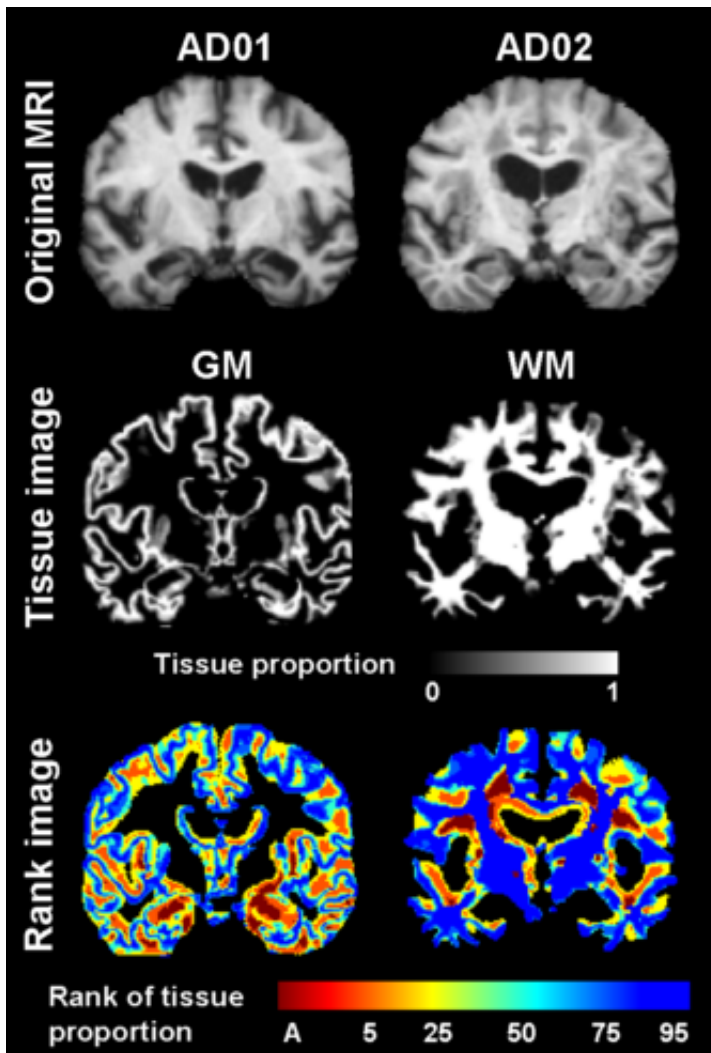


Figure 2. Ranks of voxel tissue proportions in two individual AD subjects ("AD01" and "AD02"), computed by comparison of their tissue images to the normal reference templates. A=abnormal; AD=Alzheimer's disease; GM=grey matter; MRI=magnetic resonance image; WM=white matter.

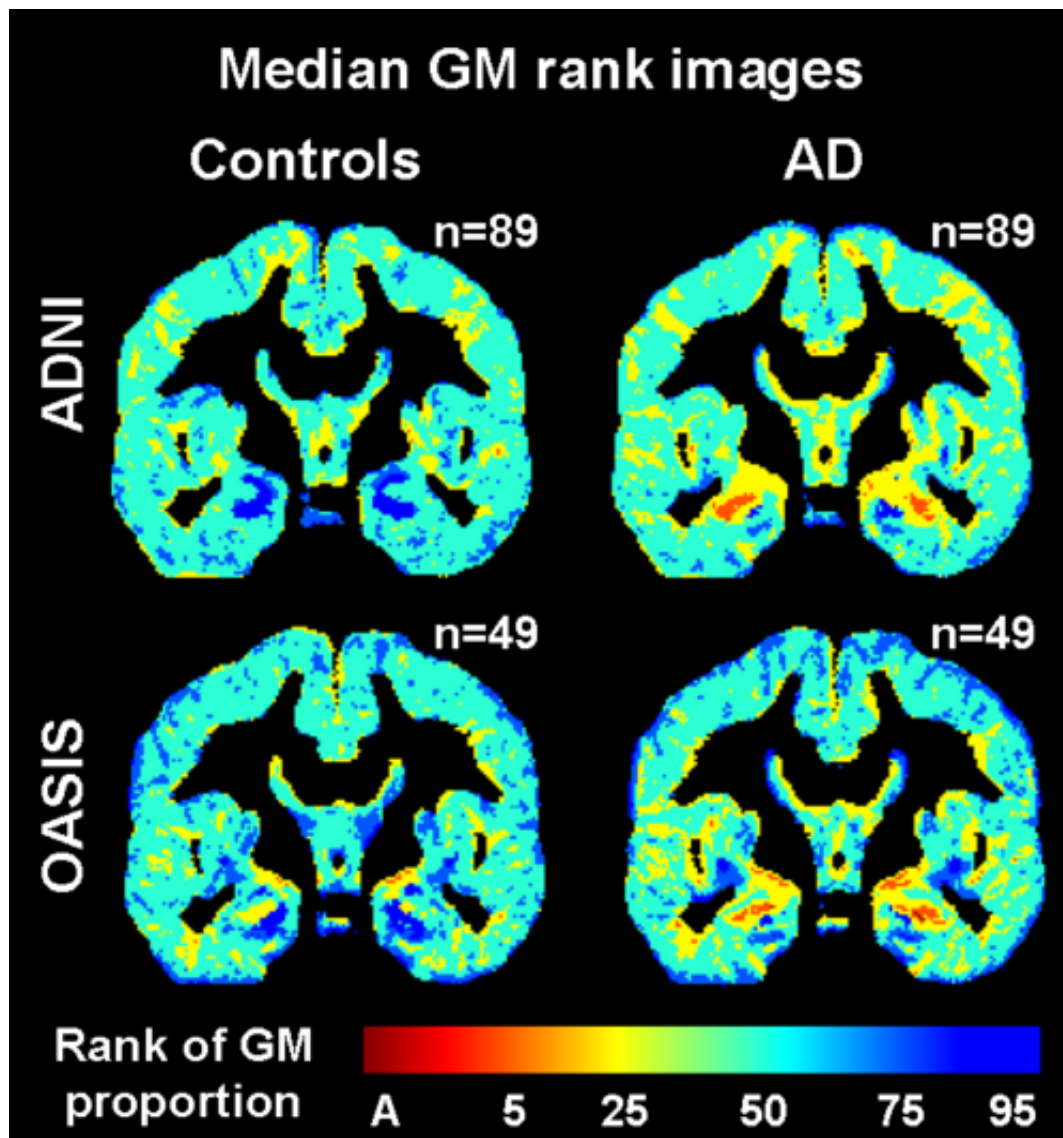


Figure 3. Median GM rank images from the AD and control testing groups. A=abnormal; AD=Alzheimer's disease; ADNI=AD Neuroimaging Initiative; GM=grey matter; OASIS=Open Access Series of Imaging Studies.

Conclusions:

Comparison of AD and control MR brain images to a rank order, voxel-based normal reference template reflected patterns of brain loss found in serial imaging [6]. Therefore, this template has the potential to act as a surrogate for prior MR brain images when, as is common in clinical reporting [2], faced with patient images from only one time point. Further, the template may also be valuable in clinical trials to determine differences between groups and the effects of treatments on rankings. Future work may allow the template to automatically classify patients. However, much more testing and images from diverse populations are required for robust templates. For that purpose, the template software and MR brain images from >1000 normal subjects across the lifespan will soon be available through the Brain Images of Normal Subjects (BRAINS) Bank [1].

Informatics:

Atlases

[1] Brain Research Imaging Centre (2013), 'Brain Images of Normal Subjects (BRAINS) Bank', <http://www.bric.ed.ac.uk/research/brains.asp>

[2] Farrell, C., et al. (2009), 'Development and initial testing of normal reference MR images for the brain at ages 65–70 and 75–80 years', *European Radiology*, vol. 19, no. 1, pp. 177-183.

[3] Good, C. D., et al. (2001), 'A Voxel-Based Morphometric Study of Ageing in 465 Normal Adult Human Brains', *Neuroimage*, vol. 14, no. 1 Pt 1, pp. 21-36.

[4] Pernet, C., et al. (2009), 'Brain classification reveals the right cerebellum as the best

biomarker of dyslexia', BMC Neuroscience, vol. 10, no. 1, pp. 67.

[5] Shenton, M., et al. (2001), 'A review of MRI findings in schizophrenia', Schizophrenia Research, vol. 49, no. 1-2, pp. 1-52.

[6] Thompson, P. M., et al. (2003), 'Dynamics of gray matter loss in Alzheimer's disease', The Journal of Neuroscience, vol. 23, no. 3, pp. 994-1005.

[7] Wright, I., et al. (1995), 'A voxel-based method for the statistical analysis of gray and white matter density applied to schizophrenia', Neuroimage, vol. 2, no. 4, pp. 244-252.

[8] Zhang, Y., et al. (2001), 'Segmentation of brain MR images through a hidden Markov random field model and the expectation-maximization algorithm', IEEE Transactions on Medical Imaging, vol. 20, no. 1, pp. 45-57.