



# THE UNIVERSITY *of* EDINBURGH

## Edinburgh Research Explorer

### Maxillary canine tooth growth in babirusa (genus *Babyrousa*)

**Citation for published version:**

Macdonald, A, Leus, K & Hoare, H 2016, 'Maxillary canine tooth growth in babirusa (genus *Babyrousa*)' *Journal of Zoo and Aquarium Research*, vol. 4, no. 1.

**Link:**

[Link to publication record in Edinburgh Research Explorer](#)

**Document Version:**

Publisher's PDF, also known as Version of record

**Published In:**

*Journal of Zoo and Aquarium Research*

**General rights**

Copyright for the publications made accessible via the Edinburgh Research Explorer is retained by the author(s) and / or other copyright owners and it is a condition of accessing these publications that users recognise and abide by the legal requirements associated with these rights.

**Take down policy**

The University of Edinburgh has made every reasonable effort to ensure that Edinburgh Research Explorer content complies with UK legislation. If you believe that the public display of this file breaches copyright please contact [openaccess@ed.ac.uk](mailto:openaccess@ed.ac.uk) providing details, and we will remove access to the work immediately and investigate your claim.



Research article

## Maxillary canine tooth growth in babirusa (genus *Babyrusa*)

Alastair A. Macdonald<sup>1,2</sup>, Kristin Leus<sup>3,4</sup> and Henry Hoare<sup>1</sup>

<sup>1</sup>Royal (Dick) School of Veterinary Studies, The University of Edinburgh, UK

<sup>2</sup>Royal Zoological Society of Scotland, Edinburgh, UK

<sup>3</sup>Centre for Research and Conservation, Royal Zoological Society of Antwerp, Antwerp, Belgium

<sup>4</sup>Copenhagen Zoo, Denmark

Correspondence: Alastair Macdonald, Royal (Dick) School of Veterinary Studies, The University of Edinburgh, Easter Bush, Midlothian EH25 9RG, Scotland; Alastair.Macdonald@ed.ac.uk

**Keywords:**

dentition, wild pig, ontogeny

**Article history:**

Received: 16 May 2015

Accepted: 15 January 2016

Published online: 31 January 2016

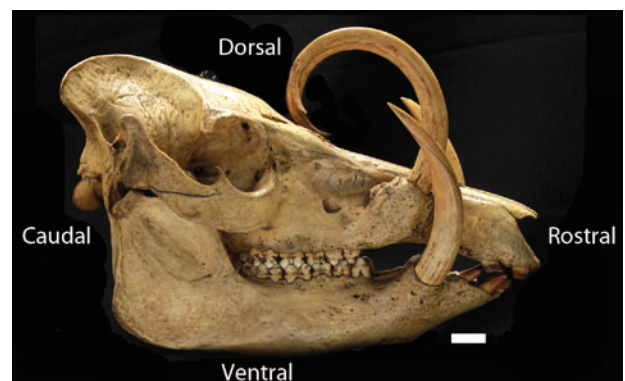
**Abstract**

Babirusa (genus *Babyrusa*), wild pigs from the Indonesian island of Sulawesi and neighbouring small islands, most obviously differ from other wild pigs in that the maxillary (upper) canine teeth of the males pierce through the skin of the nose and curl over the forehead. The females sometimes show small teeth piercing through the nasal skin. The process of anatomical growth of these maxillary canine teeth and the remodelling of the alveolar processes (tooth sockets) within which they grow is here illustrated and explained for the first time. Forty-four skulls in museum and private collections were studied. They represented all ages, from neonates to adult animals. The deciduous maxillary canine teeth of both sexes begin life by pointing rostrally and slightly ventrally into the oral cavity and then appear to be rotated dorsally and medially. The permanent teeth continue this process, rotating through approximately 90 degrees, from pointing rostrally to pointing dorsally through the nasal skin. The structure of the alveolar process is in the meantime modified and develops a bony flange caudally. We hypothesise that some form of connective tissue, stretching from the flange to the subcutaneous tissues of the forehead, exerts a caudally orientated pulling force that results in the gradual rotation of the alveolar process. The contributory role in this pulling force of bone growth at the facial sutures is also highlighted.

**Introduction**

The earliest written indication of the existence of pigs with strange teeth in South-east Asia came in draft reports, dated about 1544, from the Portuguese sea captain Galvao who wrote that in 'the islands of Maluko ... there are many large wild swine, some of them with horns [sic]' (Jacobs 1971). The first description of the teeth of babirusa (genus *Babyrusa*) may be found in a letter written in 1582 by Fr. Bernardino Ferrari describing the wildlife on the Indonesian island of Buru 'amongst which [animals] there are some resembling pigs, but white. The two tusks which pigs use to fight with, these animals have straight, in such a way as to pierce the snout of the said animal, sticking out on top like two great nails' (Jacobs 1980).

That the maxillary canine teeth of the male babirusa grow up through the skin of the snout and elongate to curl over the forehead of the animal has been noted for many years (Figure 1). The earliest known illustration of them can be found on the



**Figure 1.** Right lateral view of the same skull of a male babirusa (AAM0474) from Buru that was first depicted by Seba in 1734. The positional anatomical terms, rostral, dorsal, ventral and caudal are depicted. (British Museum (Natural History) 67.4.12.223). Scale bar = 20mm.

**Table 1.** A summary list of all the specimens of *Babyrousa* skeletal material examined in this study together with the new international identification number for *Babyrousa* (AAM number), the museum name (or private collection), the registered specimen number, age group, sex (M = male; F = female), origin (B = Buru; NS = North Sulawesi; S = Sula islands; S or B = Sula islands or Buru; SE = South-east Sulawesi; T = Togeian islands; Z = Zoo) and provenance.

AAM number	Museum or private collection	Registered number	Age	Sex	Origin	Provenance
AAM0041	Zoological Museum Amsterdam	16574	Sub-adult	M	NS	Museum record
AAM0054	Naturhistorisches Museum Basel	C.2877	Sub-adult	M	NS	Collector's record
AAM0055	Naturhistorisches Museum Basel	C.2878	Sub-adult	M	NS	Collector's record
AAM0058,	Naturhistorisches Museum Basel	C.2881	Sub-adult	M	NS	Collector's record
AAM0061	Naturhistorisches Museum Basel	C.2885	Adult	F	NS	Collector's record
AAM0065	Naturhistorisches Museum Basel	C.3036	Neonate	F	NS	Collector's record
AAM0125	Cambridge University Museum of Zoology	H.13000	Adult	F	NS	Collector's record
AAM0149	Museum Zoologicum Bogoriense, Cibinong	6898	Adult	F	T	Collector's record
AAM0223	Staatliches Museum für Tierkunde, Dresden	3452	Adult	F	NS	Collector's record
AAM0244	National Museum of Scotland, Edinburgh	1993.159.001	Adult	F	T	Studbook record
AAM0247	National Museum of Scotland, Edinburgh	1993.159.004	Sub-adult	M	Z	Studbook record
AAM0265	National Museum of Scotland, Edinburgh	2004.94.002	Adult	F	Z	Studbook record
AAM0268	National Museum of Scotland, Edinburgh	2004.225.003	Juvenile	M	Z	Studbook record
AAM0269	National Museum of Scotland, Edinburgh	2004.224.002	Neonate	M	Z	Studbook record
AAM0291	Naturmuseum Senckenberg, Frankfurt am Main	2471	Adult	F	NS	Studbook record
AAM0310	Göteborgs naturhistoriska museum	4.730	Neonate	M	NS	Collector's record
AAM0316	Göteborgs naturhistoriska museum	17.937	Sub-adult	M	NS	Collector's record
AAM0344	Göteborgs naturhistoriska museum	17.965	Sub-adult	M	NS	Collector's record
AAM0345	Göteborgs naturhistoriska museum	17.966	Adult	F	NS	Collector's record
AAM0349	Göteborgs naturhistoriska museum	17.970	Juvenile	M	NS	Collector's record
AAM0368	Göteborgs naturhistoriska museum	17.989	Sub-adult	M	SE	Collector's record
AAM0392	Naturalis Leiden	28798	Neonate	M	NS	Collector's record
AAM0393	Naturalis Leiden	28799	Neonate	M	NS	Collector's record
AAM0399	Naturalis Leiden	28810	Sub-adult	M	B	Collector's record
AAM0400	Naturalis Leiden	28811	Sub-adult	M	B	Collector's record
AAM0401	Naturalis Leiden	28812	Sub-adult	M	B	Collector's record
AAM0405	Naturalis Leiden	28816	Sub-adult	M	B	Collector's record
AAM0414	Naturalis Leiden	89b	Sub-adult	M	B	Collector's record
AAM0425	Naturalis Leiden	28796	Juvenile	F	NS	Collector's record
AAM0453	British Museum (Natural History), London	19.11.23.6	Sub-adult	M	S	Collector's record
AAM0454	British Museum (Natural History), London	19.11.23.7	Sub-adult	M	S	Collector's record
AAM0533	American Natural History Museum, New York	152857	Juvenile	F	NS	Collector's record
AAM0544	American Natural History Museum, New York	153409	Adult	F	T	Collector's record
AAM0595	Naturhistoriska Riksmuseet Stockholm	A60 5924	Adult	F	NS	Collector's record
AAM0598	Kebun Binatang Surabaya	598	Adult	F	Z	Zoo record
AAM0630	Smithsonian National Museum of Natural History, Washington	A 12191	Sub-adult	M	S or B	'No history'
AAM0640	Smithsonian National Museum of Natural History, Washington	199883	Sub-adult	F	NS	Collector's record
AAM0651	Smithsonian National Museum of Natural History, Washington	199892	Adult	F	NS	Collector's record
AAM0655	Smithsonian National Museum of Natural History, Washington	199896	Sub-adult	M	NS	Collector's record
AAM0738	Muséum National d'Histoire Naturelle, Paris	MNHN-ZM-AC 1951-251	Adult	F	Z	'unknown'
AAM0774	Private collection Indonesia	774	Sub-adult	M	SE	Collector's record
AAM0775	Private collection Indonesia	775	Juvenile	M	SE	Collector's record
AAM0776	Private collection Indonesia	776	Juvenile	M	SE	Collector's record
AAM0778	Private collection Indonesia	778	Adult	F	SE	Collector's record

wall of a cave in South Sulawesi (van Heekeren 1966, 1972). This has recently been dated, using uranium-series dating of coralloid speleothems, to 35.4 thousand years ago, and may indeed be the earliest dated figurative depiction worldwide (Aubert et al. 2014). In more modern times the maxillary canine teeth were illustrated by Piso (1658) and described in more detail by Seba (1734), Bergen

(1753) and Stehlin (1899). The earliest photograph of an adult male babirusa skull was by Rousseau and Devéria (1853).

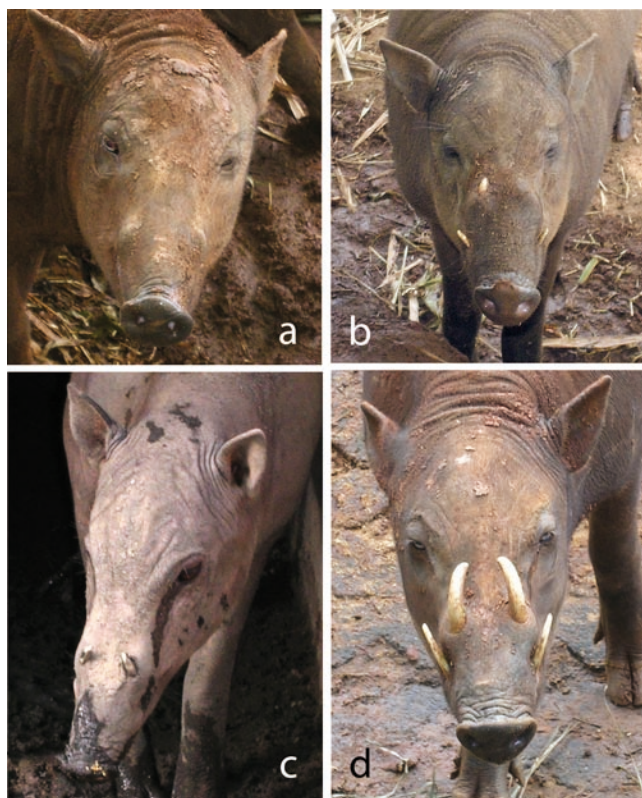Many zoo staff and members of the visiting public have observed the changes in the appearance of the face of young male babirusa during the first three years of life (Figure 2). However, the modifications that take place under the surface of the skin

during this period have remained a hidden mystery. In addition, the scanty amount of information available about female babirusa indicated to reviewers of the literature that females seldom had obvious maxillary canine teeth, and that when observed they appeared as small teeth just penetrating the skin of the nose (Meyer 1896; Mohr 1958).

In this paper we seek to illustrate the process of anatomical growth of the maxillary canine tooth and the remodelling of the alveolar process (tooth socket) within which it grows. We present data for young male babirusa, and in addition, demonstrate what takes place in the female.

## Methods

The specimens studied are listed in Table 1. This shows the new international reference number for *Babyrusa* skulls (AAM number), the museum or private collection, the registered museum specimen number, the age category, the sex, the geographic origin of the specimen and its provenance. In the text below the specimens have been grouped geographically to accommodate the distribution clustering found in museum collections.



**Figure 2.** Four rostro-dorsal photographs of sub-adult male babirusa heads illustrating maxillary tooth growth. (a) Approximately 18 months of age. Maxillary canine teeth have protruded from their alveolar processes, but have not yet penetrated the skin of the snout; (b) Approximately 24 months of age. The right maxillary canine has grown sufficiently to penetrate the skin of the snout, but the left tooth remains below the epidermal surface; (c) Approximately 26 months of age. Both maxillary canine teeth have penetrated the skin of the snout. Note the absence of inflammation around the wound; (d) Approximately three years of age. Both maxillary canines have grown through the skin and there is evidence of enlargement of their bony alveolar processes and subcutaneous tissue growth.

## Male babirusa

We studied 26 skulls of neonatal, juvenile and sub adult male babirusa. One series of nine skulls represented development of north Sulawesi babirusa (AAM0041, AAM0054, AAM0055, AAM0058, AAM0310, AAM0316, AAM0344, AAM0349, AAM0655). These skulls had good provenance data. The origin of an additional two skulls has been identified, on cranial morphological grounds (Deninger, 1909), as probably originating from North Sulawesi (AAM0392, AAM0393). A second series of six skulls, also with good provenance data, represented development of south-east Sulawesi babirusa (AAM0247, AAM0268, AAM0368, AAM0774, AAM0775, AAM0776) with an additional skull probably originating from south-east Sulawesi (AAM0269). The third series of six skulls, also with good provenance data, represented development of Buru or the Sula Islands' babirusa (AAM0399, AAM0400, AAM0401, AAM0405, AAM0453, AAM0454), with an additional two skulls, based on cranial morphological grounds (Linnaeus, 1758; Deninger, 1909), probably originating from these islands (AAM0414, AAM0630). This skeletal material came from museums in Amsterdam, Basel, Edinburgh, Göteborg, Leiden, London, Paris, Washington, and from private collections in Indonesia (Table 1).

## Female babirusa

We studied 18 skulls of neonatal, juvenile, sub adult and adult female babirusa showing evidence of maxillary canine teeth. Eleven represented north Sulawesi (AAM0061, AAM0065, AAM0125, AAM0223, AAM0291, AAM0345, AAM0425, AAM0533, AAM0595, AAM0640, AAM0651). One represented south-east Sulawesi (AAM0778). Three represented the Togian islands (AAM0149, AAM0244, AAM0544). The geographical origins of three other skulls (AAM0265, AAM0598, AAM0738) were unknown. This skeletal material came from museums in Basel, Cambridge, Cibinong, Dresden, Edinburgh, Frankfurt am Main, Göteborg, Leiden, New York, Paris, Stockholm, Surabaya, Washington and from private collections in Indonesia (Table 1). Skulls from a further 34 female babirusa in museum collections were examined and found to have no evidence of maxillary canine teeth or of supporting alveolar processes (unpublished observations).

## Results

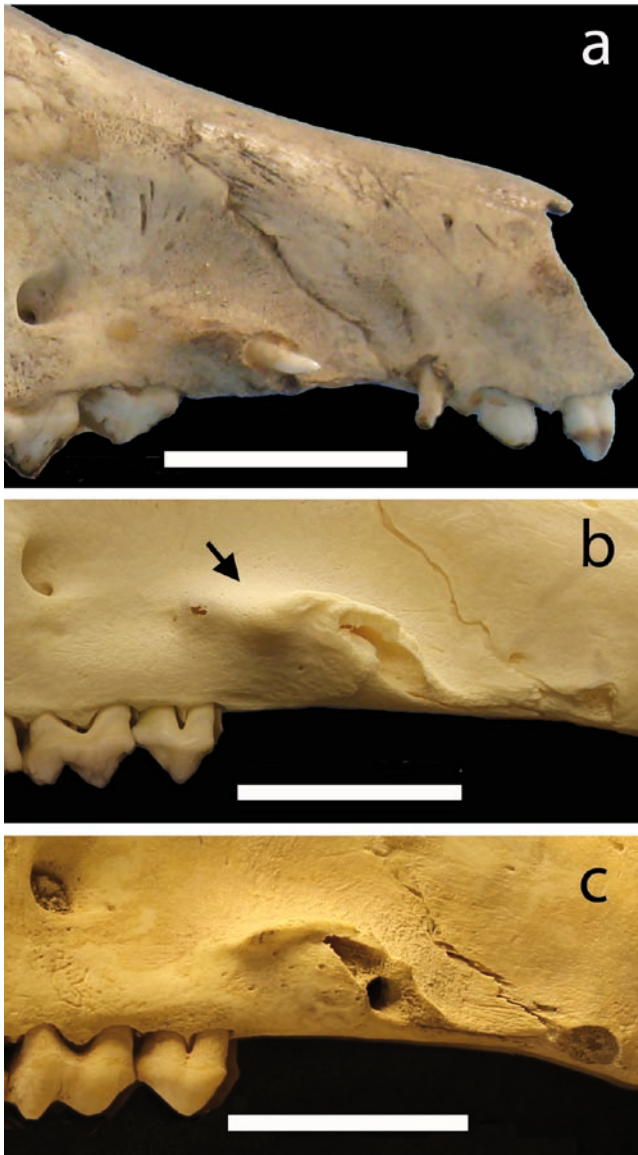
### Male babirusa

In the two youngest skulls (AAM0392, AAM0393) the orientation of the rod-like deciduous maxillary canine tooth was approximately 15 degrees ventral to the palate and about 37 degrees lateral to the midline. The tooth was pointed (Figure 3a).

In two slightly older neonates (AAM0269, AAM0310), the bony support for the permanent maxillary canine tooth (maxillary alveolar process) was found ventral to that of the deciduous tooth (Figures 3b,c). In each skull the teeth had been lost sometime during skull preparation and conservation. However, the orientation of the alveolar process was approximately 9 degrees ventral of the palate and about 15 degrees lateral of the midline. A small bony thickening (arrow) was apparent on the caudo-dorsal side of the alveolar process (Figure 3b), and rostral to the infra-orbital foramen, the landmark hole into the skull on the left side of the images.

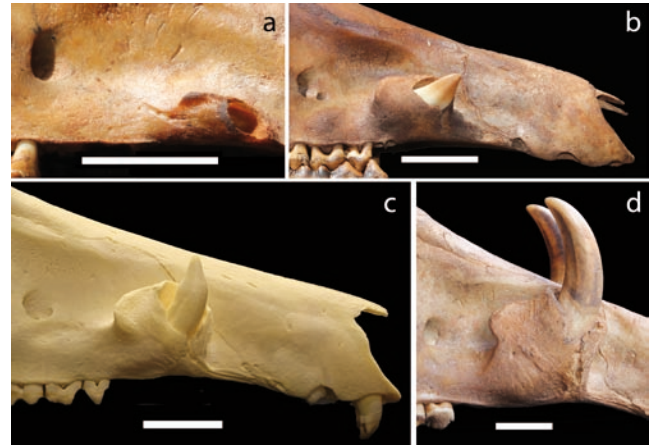
The tubular alveolar processes of the maxillary canines of a somewhat older juvenile (AAM0776) were orientated to lie parallel to the palate (Figure 4a) and at approximately 5 degrees lateral of the midline. The left alveolar process was 16.6 mm rostro-caudally long, 5.35 mm dorso-ventrally deep, and approximately 4.8 mm latero-medially wide (the medial edge was not clearly defined). The oval opening, out of which the tooth had projected, was 7.2 mm x 3.4 mm in size. The right alveolar process was 16.6 mm rostro-caudally long, 6.6 mm dorso-ventrally deep, and about





**Figure 3.** The rostral portion of three neonatal male babirusa skulls showing right maxillary alveolar development. (a) Alveolar process with rod-like deciduous tooth pointing slightly ventrally and laterally (AAM0392); (b) Alveolar process, having defoliated its deciduous tooth, with ventral to it the alveolar cavity of the permanent tooth (AAM0269). Bony development on the caudo-dorsal aspect of alveolar process (arrow); (c) Alveolar cavity of exfoliated deciduous tooth and ventral to it that of the permanent tooth (AAM0310). Scale bar = 20mm.

5.1 mm latero-medially wide. The oval opening was 12.3 mm x 3.9 mm. Both alveolar processes showed irregular bone growth rostral and ventral to the opening. However, the internal surfaces of the alveolar processes seemed straight and smooth. The bony thickening on the caudo-lateral side of the alveolar process was formed into a small (0.8–1.0 mm) vertical flange caudally. A shallow groove was present between the developing alveolar process and the facial surface of the maxilla. The left tooth was rod-shaped with a blunt point; the right tooth was missing. Progressively the maxillary alveolar process increased in volume to become a bulbous bony structure (Figure 4b). Its attachment to the maxilla ventro-medially created a short channel dorsally along each side of the nose. The caudally facing bony flange increased in size. The rostral border of the alveolar process was eroded to such an extent that a split ran dorso-ventrally through its structure. The



**Figure 4.** The rostral portion of four young babirusa skulls showing right maxillary alveolar development. (a) Alveolar process orientated parallel to the palate and with its opening pointing rostrally. The canine tooth was lost in skull collection or preparation (AAM0776). (b) Alveolar process enlarged and pointing rostrally and slightly dorsally (AAM0775); (c) Alveolar process enlarged and remodelled, pointing more dorsally (AAM0268); (d) Alveolar process showing extensive remodelling with the tooth curving dorso-caudally (AAM0774). Scale bar = 20mm.

bony edges of the split were rough in texture, as was the edge of the oval opening. Each maxillary canine tooth of AAM0775 had a broad base ventrally and was curved such that its point was orientated approximately 40–75 degrees dorsally with respect to the palate. Two other skulls (AAM0349 and AAM0247) showed similar features. The left alveolar process of AAM0775 was 20.5 mm rostro-caudally long, 14.1mm dorso-ventrally deep and 3.9 mm latero-medially wide caudally and 6.9mm latero-medially wide rostrally. The oval opening from the alveolar process was 9.6 mm x 8.1 mm in size. The right alveolar process was 20.7 mm rostro-caudally long, 13.5 mm dorso-ventrally deep, and 4.7 mm latero-medially wide caudally and 6.8 mm latero-medially wide rostrally. The oval opening from the alveolar process was 10.2 mm x 7.7 mm in size. In an older juvenile skull (AAM0268) each maxillary canine alveolar process had increased in dorso-ventral size (depth) and had an enlarged opening for the tooth (Figure 4c). The lateral and rostral bony support for the tooth had eroded further. The bony caudal flange was enlarged, had a roughened edge and was pitted superficially. The tooth was orientated more dorso-ventrally with respect to the palate. It was positioned approximately 5 degrees lateral to the midline.

The extensive remodelling of the alveolar process, and its continued rotation towards a right angle with respect to the palate, was achieved by growth in its dorso-ventral size such that the opening reached just below the level of the nasal bone (Figure 4d). Erosion of the rostro-lateral border of the bony socket of AAM0774 was demonstrated by a ragged dorso-ventral split in the bony collar round the tooth. The tooth had elongated and curved first rostro-dorsally and then dorso-caudally with respect to the palate. The caudally projecting flange of the alveolar process, situated slightly below the opening for the tooth, was now higher up the side of the elongated alveolar process. The left alveolar process had the following dimensions: 45.4 mm dorso-ventral depth, 29.7 mm rostro-caudal breadth, and 12.5 mm latero-medial width. The relatively flat flange was 18.5 mm long and had a maximum depth of 6.6 mm. The outer oval was 25.6 mm x 17 mm in size. The right alveolar process had the following dimensions: 43.6mm dorso-ventral depth, 29.1 mm rostro-caudal

breadth, and 17.2 mm latero-medial width. The flange was 19.4 mm long and had a maximum depth of 8.2 mm. The outer oval was 26.9 mm x 16.2 mm.

In the skulls of sub-adult babirusa the maxillary tooth continued to show curvilinear growth, but to a lesser extent. The apparent rotation of the alveolar process seemed to stop at or about the time that the oval opening from the alveolar process approached the dorsal level of the nasal bone. It was also at about this time that the split in the rostral wall of the alveolar process was closed.

### Female babirusa

Although the deciduous maxillary canine teeth of the only female neonatal skull (AAM0065) had defoliated, the alveolar processes demonstrated that their projection was ventral to the palate and lateral to the midline. In one group of seven adult skulls, small (4–6mm diameter), pointed, rod-like maxillary canine teeth (or their alveolar processes) were observed. The orientation of these canine teeth with respect to the palate varied, ranging from pointing approximately 45 degrees rostrally and ventrally (Figure 5b), through to being parallel to the palate (Figure 5a,d). One tooth appeared to be encased in its bony alveolar process (Figure 5c). Each of the alveolar processes had a ridge-like dorsal edge (Figure 5a–d).

In the second group, of 10 sub-adult and adult female skulls, permanent maxillary canines (or their alveolar processes) were present. The rostral orientation of these ranged from approximately parallel with the palate, to being rotated round to 110 degrees

dorsal to the palate (Figure 5f). The teeth were generally blunt-ended (Figure 5f), although in six instances they were pointed. These teeth were about 6–9mm in diameter. Generally, the maxillary alveolar processes had a somewhat flattened caudal aspect, thereby creating a ridge-like dorsal edge (Figure 5f).

Four of the female babirusa had only a left maxillary canine tooth (Figure 5e,f) and one had a maxillary canine tooth on the right only. Thirty-four additional adult female skulls in museum collections had no maxillary canine teeth or alveolar processes.

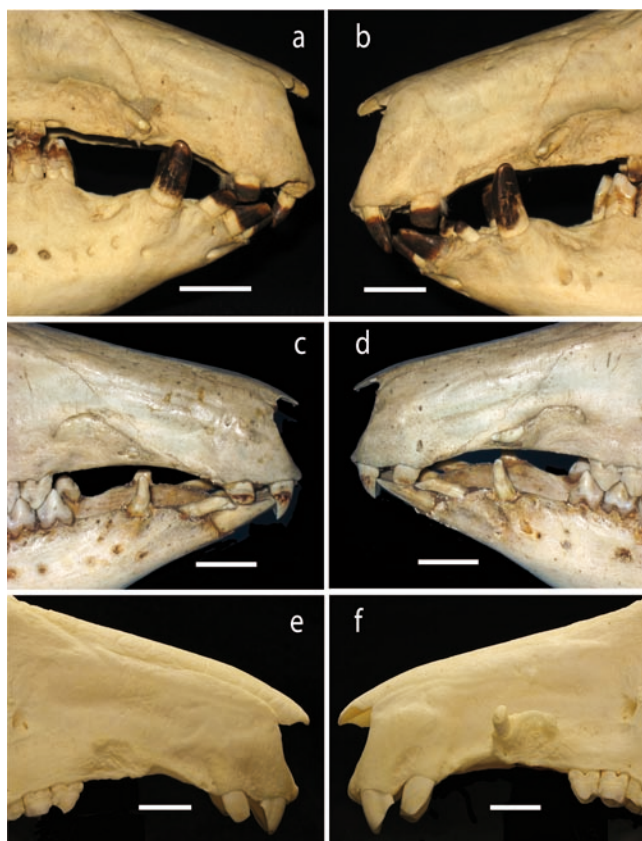
### Discussion

This is the first detailed analysis of maxillary canine tooth growth in either male or female babirusa, and draws on the evidence contained in skeletal tissues gathered, stored and curated in museum collections around the world. These skulls have illustrated the pattern of this growth in the male until the time of penetration of the tooth through the skin of the nose. They have also shown for the first time a number of ways in which the maxillary canine tooth of the female can be orientated in the jaw, with or without penetration of the skin.

The initial, somewhat ventral and lateral, orientation of both the deciduous and permanent teeth of the babirusa bears some general similarity to that found in *Phacochoerus africanus*, the common warthog (Stehlin 1900; Child et al. 1965), as well as in *Sus scrofa*, the Eurasian wild pig and the domestic pig (Stehlin 1900; Weaver et al. 1969; Briedermann 2009). However, there are differences in detail. The deciduous teeth of both male and female babirusa differ from these in shape; in babirusa they are round, rod-like structures. These teeth appear to be consistently shed and replaced by permanent teeth in the male babirusa. In the female, however, it would seem that they might be shed, or alternatively they might be retained into adult life. There was also evidence that if the deciduous teeth were shed they might be replaced by small permanent teeth, or, as in most cases, not replaced by permanent maxillary canine teeth at all. About two thirds of the 52 female skulls seen in museum collections had no permanent maxillary canine teeth.

The deciduous maxillary canine teeth of both sexes began life by pointing rostrally and slightly ventrally. They then appear to be rotated dorsally and medially to align themselves approximately parallel to the mid-line. It was clear from the skulls of both sexes that the alveolar process was being structurally remodelled to accommodate/facilitate this change in the orientation of the tooth (Figures 3c, 5c). It was also clear that in the male animals the remodelled alveolar process was to accommodate the permanent tooth. It has been reported that the volume as well as the shape of the alveolar process is determined by the form of the tooth, its axis of eruption and eventual inclination (Schroeder 1986). However, the extent to which the tooth regulates growth of its supporting alveolar process or vice-versa is not known (Kjær 2014). Likewise, the functional relationship between the tooth and the adjacent alveolar bone remains largely unknown (Marks and Schroeder 1996; Popowics et al. 2009; Kjær 2014). However, it would seem reasonable to surmise that some form of genetic regulation of tooth and alveolar bone growth is underpinning the complexity of the process observed.

In the male babirusa the alveolar process supporting the maxillary canine tooth showed evidence of a considerable degree of remodelling during the first three years of the animal's life (Figure 4). Its rotation through approximately 90 degrees, from pointing rostrally to pointing dorsally, was the most striking aspect of this. This rotation appeared to provide structural support for the dorsally orientated curvilinear growth of the canine tooth. The split along the rostro-lateral face of the alveolar process could be interpreted as providing a means by which growth (in the



**Figure 5.** (a,b) Adult female North Sulawesi babirusa (AAM0595), skull, right and left sides respectively, illustrating the maxillary alveolar process and teeth pointing rostrally and ventrally. (c,d) Sub-adult female North Sulawesi babirusa skull (AAM0425) with (c) maxillary canine tooth encased in right alveolar process and (c) the left maxillary canine tooth projecting rostrally. (e,f) Adult female Togian babirusa skull (AAM0244) with (e) no maxillary canine on the right side and (f) a small, blunt maxillary canine projecting dorsally and slightly laterally on the left side. Scale bar = 20mm.

diameter of the opening) could take place to accommodate the growing tooth. It is highly probable that the opening was bridged with hyaline cartilage. This material gives both structural support as well as providing the substrate for endochondral bone growth. It is also likely that the dorsal edge of the alveolar opening carried a layer of hyaline cartilage, the interfacing edge of which would have provided the region of bone growth to take place.

In the female babirusa the observed failure to replace the fenestrated deciduous canine tooth with a permanent tooth led to a substantial reduction in the alveolar ridge (Figure 5e), and in most cases its disappearance altogether. Experiments on three-month old pigs show that alveolar ridge reduction occurs after tooth extraction due to three major alterations: convergence of the buccal and lingual gingival crests, loss of apposition on the lingual bundle bone, and decelerated growth along the entire buccal surface (Sun et al. 2013). Alveolar bone resorption occurs reliably after tooth extraction in pigs (Sun et al. 2013), adult humans (Van der Weijden et al. 2009) and dogs (Araujo et al. 2005). The inherent absence of mechanical changes in the babirusa male due to tongue pressure or under-loading from mastication suggests that alternative mechanical forces were applied to the maxillary canine by the connective tissues overlying the permanent tooth. This suggestion would seem to be supported by the nature of the growth and development of the alveolar process when the canine tooth was present (Figure 5f). The composition of the subcutaneous tissue environment dorsal to and surrounding the male babirusa's growing maxillary canine teeth, implied by the elevation of the skin in that region (Figure 2), remains to be investigated.

Periosteal activity is important for the growth of the skull. The flat dermal bones of the craniofacial skeleton enlarge by membranous apposition. Studies on rapidly growing piglets demonstrated that cranial periosteum was stratified into a fibrous outer layer and an inner layer (Ochareon and Herring 2011). The former contained dense collagen fibres, usually orientated parallel to the bone surface, whereas the inner periosteal layer showed a more delicate network with many fibrils pointing toward the bone surface. Regions of appositional bone growth contained large numbers of osteogenic cells and were highly vascular. It is likely that these mechanisms are at work on the lateral, caudal and medial sides of the babirusa's maxillary canine alveolar process, but in addition it seems likely that hyaline cartilage-based osteogenic activity may be present on the rostral and dorsal aspects of the structure. We made no systematic attempt to examine the microscopic structure of the alveolar process. Yeh and Popowics (2011a,b) demonstrated in minipigs that the alveolar cancellous bone surrounding the first mandibular molar tooth showed a tendency to change from dense fibro-lamellar into a more plate-like lamellar structure.

The development of a flange on the caudal edge of the alveolar process suggests that it has a function. The male pigs of the genera *Potamochoerus* and *Sus* use the lateral aspects of the snout in agonistic behaviour (Frädrich 1967; Plesner-Jensen 2008). The hypothesis has been put forward that in those species the supra-canine bony flange and associated thickening of the skin acts as protection for the muscles and tendons of the rhinarium (Kingdon 1979). The adult male babirusa has different agonistic behaviour (Macdonald et al. 1993; Patry et al. 1995), which climaxes in 'boxing'. This involves two adult males raising their forelimbs off the ground until each is standing on his hind limbs facing the other, paddling and pushing with his forelimbs against the chest and shoulders of his opponent. The snouts are held as high as possible and in almost all cases are kept free of one another; the snouts are not used to strike the head of the other babirusa (Macdonald et al. 1993). Thus a protective role for the supra-canine bony flange in relation to male agonistic behaviour would not appear to be paramount in babirusa. However, it does

not exclude the possibility that it may reflect such a requirement in a much earlier time. There is, as yet, very little fossil evidence of *Babyrousa* (Hooijer, 1948). However, the babirusa fetus does exhibit close anatomical similarities to other pigs with respect to placental and cardiovascular structures (Macdonald 1994).

Alternatively, the way in which the flange on the caudal edge of the alveolar process was positioned with respect to the 'tubular' structure that supported it, the pitted surface and leading edge of the flange, and the manner in which the 'tube' was progressively remodelled such that the flange remained near the top of the 'tooth-supporting tube', all suggest that it provides an anchorage for some kind of structure. We hypothesise that some form of connective tissue is attached to the flange in order to exert a caudally orientated pulling force, resulting in the gradual rotation of the alveolar process. The *Musculus platysma*, originating from the fascia over the neck, does not reach as far rostrally as the zygomatic arch and so cannot play a role (Herring 1972; Kneepkens and Macdonald 2010). The *Musculi levator labii superioris* and *M. depressor labii superioris* are not responsible, as the course of their tendons passes medial and dorsal to the alveolar process of the maxillary canine tooth, and inserts on the snout (Herring 1972; Kneepkens and Macdonald 2010; Hamacher 2011). The orientation of the *M. levator nasolabialis* in the babirusa fetus, covering the rostral part of the snout, suggests that this muscle could not play a role at this stage of development (Herring 1972). However, in the adult male, a part of this muscle was found to originate from the lateral side of the alveolar bone of the maxillary canine and insert into the subcutaneous tissues of the forehead dorsal to the *M. orbicularis oris* and the *M. levator labii superioris* tendon and rostral to the eye (Kneepkens and Macdonald 2010). Although no studies have been made of this muscle in juvenile or sub-adult males, it appears to indicate an appropriate alignment in the adult. It might also be expected that the orientation of the *M. levator nasolabialis* develops after birth in such a way as to normally not impede the growth of the maxillary canine tooth through the skin.

The 'pulling force' applied to the alveolar process might have less to do with muscular tissue per se and more to do with the associated fascia. The shape of the babirusa skull changes during the period from birth to adolescence, from a rounded to a more elongate structure (Stehlin 1899, 1900). The sutures of the skull are major sites of bone expansion during postnatal craniofacial growth (Rafferty and Herring 2000; Opperman 2000). This was demonstrated in growing pigs when rigid microplates were attached bilaterally across the frontonasomaxillary and zygomaxillary sutures (Holten et al. 2010). It is likely that bony growth at these sutures in the babirusa contribute to the pulling force applied to the alveolar process of the permanent maxillary canine tooth in both males and females. The attachment of fascia associated with the *M. levator nasolabialis* to the lateral side of the alveolar process in the male babirusa might also contribute to the maintenance of the rostro-lateral split through the bone of the alveolar process. The growth in diameter of the canine tooth must also put pressure on the inside volume of the tubular collar, which will also contribute to the pressure to maintain the split. Whether this opening is bridged by hyaline cartilage, and whether it is performing a bone growth function comparable to that found in the epiphyseal plates of long bones, remains to be investigated. Growth in the diameter of the alveolar process to accommodate the increased size of the maxillary tooth would also be expected to necessitate remodelling of the diameter and length of this structure. Whether micro-cracking of the alveolar cancellous bone results from the curvilinear tooth growth of the male maxillary tooth and/or contributes to the remodelling is also unknown, but it is recognised as a phenomenon leading to bone remodelling (Verna et al. 2004).



It used to be thought that babirusa were the only mammals that had maxillary canine teeth that penetrated the upper lip (Macdonald 1993). Recent research has revealed that a distant Cetartiodactyla relative of the babirusa, the narwhal (*Monodon monoceros*), also exhibits this anatomical character (Nweeia et al. 2012). The male narwhal usually exhibits one maxillary canine tooth, on the left side, which erupts through the upper lip, and projects rostrally; less commonly, two tusks may be expressed. Female narwhal usually have two canine teeth that remain embedded in the skull with neither erupting, although occasionally one or both teeth may erupt (Nweeia et al. 2012). As with babirusa, there is no ancestral condition to account for this expression, nor any evident functional significance. The most likely explanation suggested was as an epigenetic by-product of selection.

The function of the curved maxillary canine teeth of the adult male babirusa remains unknown and has stimulated speculation. Mackinnon (1981) put forward the hypothesis that the canines were used in fighting. However, subsequent studies of agonistic behaviour showed that this was not the case (Macdonald et al. 1993). The canine teeth of the adult male were never used directly against another male. Indeed the relative structural fragility of the maxillary canine tooth and the relative shallowness of this tooth's alveolar process preclude the 'wrestling matches' proposed by Mackinnon (1981). The tooth wear pattern reported on the lateral side of maxillary canine teeth was either due to scent-marking behaviour, involving the rubbing of eye-gland secretions onto saplings or other structures in the environment (Macdonald et al. 1996), or more rarely, if the growth of an upper canine tooth brings it into contact with the skin of the forehead (Macdonald, unpublished).

## Conclusions

This survey of skeletal material that had been accumulated over the last three hundred years, and been curated in museum collections, offered an opportunity to study the nature of the growth of maxillary canine teeth in both male and female babirusa. The deciduous maxillary canine teeth of both sexes begin life by pointing rostrally and slightly ventrally and then seem to be rotated dorsally and medially. The permanent teeth continue this process, rotating through approximately 90 degrees, from pointing rostrally to pointing dorsally. The structure of the supporting alveolar process is in the meantime modified and develops a bony flange caudally. The hypothesis is proposed that some form of connective tissue stretches between this flange and the subcutaneous tissues of the forehead that exerts a caudally orientated pulling force resulting in the gradual rotation of the alveolar process. The elongation of the growing face and the contributory role of bone growth at facial sutures in this process is highlighted.

## Acknowledgements

We would like to thank the directors, curators and staff of the following zoological collections for giving us close access to their animals: Royal Zoological Society of Antwerp, Berlin zoo, Royal Zoological Society of Scotland, Gembiraloka zoo, Marwell zoo, Ragunan zoo, Rotterdam zoo, Singapore zoo, Surabaya zoo, Taman Safari Indonesia. We would also like to thank the curators and staff of the following museums for access to the skeletal babirusa material listed in Table 1 which forms part of their collections: Zoological Museum Amsterdam, The Netherlands; Naturhistorisches Museum Basel, Switzerland; Cambridge University Museum of Zoology, England; Museum Zoologicum Bogoriense, Cibinong, Indonesia; Staatliches Museum für Tierkunde Dresden, Germany; National Museum of Scotland: Naturmuseum Senckenberg, Frankfurt am

Main, Germany; Göteborgs naturhistoriska museum, Sweden; Naturalis Leiden, The Netherlands; (British Museum (Natural History), England; American Natural History Museum, New York, USA; Naturhistoriska Riksmuseet Stockholm, Sweden; Kebun Binatang Surabaya, Indonesia; Smithsonian National Museum of Natural History, Washington, USA; Muséum National d'Histoire Naturelle, Paris, France and private collections in Indonesia.

We are grateful to Thomas Kauffels and Jörg Beckmann for babirusa studbook data. Our thanks too to Darren Shaw for database support. We are grateful to the University of Edinburgh and the Balloch Trust for their financial support. The Centre for Research and Conservation of the Royal Zoological Society of Antwerp gratefully acknowledges the structural support of the Flemish government.

## References

- Araujo M.G., Lindhe J. (2005) Dimensional ridge alterations following tooth extraction. An experimental study in the dog. *Journal of Clinical Periodontology* 32: 212–218.
- Aubert M., Brumm A., Ramli M., Sutikna T., Saptomo E.W., Hakim B., Morwood M.J., van den Bergh G.D., Kinsley L., Dosseto A. (2014) Pleistocene cave art from Sulawesi, Indonesia. *Nature* 514: 223–227.
- Bergen C.A. (1753) Nachricht vom Kopfe des Babyroussa. *Hamburgisches Magazin, oder gesammelte Schriften, aus der Naturforschung und der angenehmen Wissenschaften überhaupt* 11: 188–199.
- Briedermann L. (2009) *Schwarzwild*. Stuttgart, Germany: Franckh-Kosmos.
- Child G., Sowls L., Mitchell B.L. (1965) Variations in the dentition, ageing criteria and growth patterns in wart hog. *Arnoldia* 38: 1–23.
- Deninger K. 1909. Über Babirusa. *Berichte der Naturforschenden Gesellschaft zu Freiburg* 17(3): 179–200.
- Ferrari B. (1582) Letter to Fr. Everard Mercurian dated March 21, 1582 (Letter D 34). In: Jacobs H. (ed.). *Documenta Malucensia, 2 (1577–1606)*. Rome, Italy: Jesuit Historical Institute, 114.
- Frädrih H. (1967) Das Verhalten der Schweine (Suidae, Tayassuidae) und Flußpferde (Hippopotamidae). In: *Handbuch der Zoologie* 10 (26): 1–14.
- Hamacher L. (2011) *Nasus externus und Cavum nasi beim männlichen adulten Hirscheber (Babyrousa sp.)*. Diplomarbeit. Vienna, Austria: Veterinärmedizinischen Universität Wien.
- Herring S.W. (1972) The facial musculature of the Suoidea. *Journal of Morphology* 137: 49–62.
- Holton N.E., Franciscus R.G., Nieves M.A., Marshall S.D., Reimer S.B., Southard T.E., Keller J.C., Maddux S.D. (2010) Sutural growth restriction and modern human facial evolution: an experimental study in a pig model. *Journal of Anatomy* 216: 48–61.
- Jacobs H.T.T.M. (ed.) (1971) *A Treatise on the Moluccas (c. 1544) Probably the Preliminary Version of Antonio Galvao's lost Historia das Molucas, Edited, Annotated, and Translated into English from the Portuguese Manuscript in the Archivo General de Indias, Seville*. [Á muitos porcos montezes e grandes, e deles com cornos]. Rome, Italy: Jesuit Historical Institute and St Louis, USA: St. Louis University, 60–61.
- Jacobs H. [T.T.M.] (ed.) (1980) D34. Fr Bernardino Ferrari, Superior to Fr. Everard Mercurian, General, Tidore, March 21, 1582. [È l'isola del Burro molto fertile de victovaglie di queste parti, habundante de molti animali sylvestri, come de porci et altri animali di queste parti. Fra quali vi sono uni semeglianti al porco ma bianchi. E li due denti grandi, con i quali i porci combatteno, questi animali le tengono diretti di modo che furan oil musso del detto animali, e uscindo sopra appariscono come due chiodi grandi.] In: *Missiones Orientales Documenta Malucensia, II (1577–1606)*. *Monumenta Historica Societatis Iesu* 119: 112–115.
- Kingdon J. 1979. East African mammals. An atlas of evolution in Africa. In: Kingdon J. (ed.). *East African Mammals – An Atlas of Evolution in Africa*. London: Academic Press, 184–249.
- Kjær I. (2014) Mechanism of human tooth eruption: review article including a new theory for future studies on the eruption process. *Scientifica*. doi:10.1155/2014/341905.
- Kneepkens A.F.L.M., Macdonald A.A. (2010). Vertebral column, rib and sternal muscles of Sulawesi babirusa (*Babyrousa celebensis*). *Anatomia, Histologia, Embryologia* 40: 149–161.
- Linnaeus C. (1758) *Systema Naturæ Per Regna Tria Naturæ, Secundum Classes, Ordines, Genera, Species, Cum Characteribus, Differentiis, Synonymis, Locis, Volume 1*, 10<sup>th</sup> edn. Holmiae: Laurentii Salvii, 49–50.



- Macdonald A.A. (1993) The babirusa (*Babyrousa babyrussa*). In: Oliver W.L.R. (ed.). *Status Survey and Conservation Action Plan: Pigs, Peccaries and Hippos*. Gland, Switzerland: IUCN, 161-171.
- Macdonald A.A. (1994) The placenta and cardiac foramen ovale of the babirusa (*Babyrousa babyrussa*). *Anatomy and Embryology* 190: 489-494.
- Macdonald A.A., Bowles D., Bell J., Leus K. (1993) Agonistic behaviour in captive babirusa (*Babyrousa babyrussa*). *Zeitschrift für Säugetierkunde* 58: 18-30.
- Macdonald A.A., Leus K., Florence A., Clare J., Patry M. (1996) Notes on the behaviour of Sulawesi warty pigs (*Sus celebensis*) in North Sulawesi, Indonesia. *Malaysian Nature Journal* 50: 47-53.
- MacKinnon J. (1981) The structure and function of the tusks of babirusa. *Mammal Review* 11: 37-40.
- Marks S.C., Schroeder H.E. (1996) Tooth eruption: theories and facts. *The Anatomical Record* 245: 374-393.
- Meyer A.B. (1896) Säugethiere von Celebes- und Philippinen- Achipel. *Abhandlungen und Berichte des Königlichen Zoologischen und Anthropologisch-Ethnographischen Museums zu Dresden* 6 (I-VIII): 1-36.
- Mohr E. (1958) Zur Kenntnis des Hirschebers, *Babirussa babyrussa* Linne 1758. *Der Zoologische Garten* 25: 50-69.
- Nweeia M.T., Eichmiller F.C., Hauschka P.V., Tyler E., Mead J.G., Potter C.W., Angnatsiak D.P., Richard P.R., Orr J.R., Black S.R. (2012) Vestigial tooth anatomy and tusk nomenclature for *Monodon monoceros*. *The Anatomical Record* 295: 1006-1016.
- Ochareon P., Herring S.W. (2011) Cell replication in craniofacial periosteum: appositional vs. resorptive sites. *Journal of Anatomy* 218: 285-297.
- Opperman L.A. (2000) Cranial sutures as intramembranous bone growth sites. *Developmental Dynamics* 219: 472-485.
- Patry M., Leus K., Macdonald A.A. (1995) Group structure and behaviour of babirusa (*Babyrousa babyrussa*) in Northern Sulawesi. *Australian Journal of Zoology* 43: 643-655.
- Piso G. (1658) Appendix: De Baby-Roussa. In: Bondt J. (ed.). *Historiae Naturalis & Medicae Indiae Orientalis*. Amstelaedami: Ludovicum et Danielem Elzevirios, 5: 61-62.
- Plesner-Jensen S. (2008) Das Verhalten der wilden Schweine. In: Macdonald A.A., Gansloser U. (eds.) *Wilde Schweine und Füsspferde*. Erlangen: Filander Verlag, 67-110.
- Popowics T., Yeh K., Rafferty K., Herring S. (2009) Functional cues in the development of osseous tooth support in the pig, *Sus scrofa*. *Journal of Biomechanics* 42: 1961-1966.
- Rafferty K.L., Herring S.W. (2000) Craniofacial sutures: morphology, growth, and in vivo masticatory strains. *Journal of Morphology* 242: 167-179.
- Rousseau L., Deveria J.J.M.A. (1853-1855) *Photographie Zoologique, ou Représentation des Animaux Rares des Collections du Muséum d'Histoire Naturelle*. Paris: L. R. et A. De V. and London, England: Procédés de Lemerrier et Bisson Frères, and Masson & E. Gambart.
- Seba A. (1734) *Locupletissimi rerum naturalium thesauri accurata descriptio – Naaukeurige beschryving van het schatryke kabinet der voornaamste seldzaamheden der natuur, 80, Taf 50, 2, 3*. *Aper indicus orientalis (Babi roesa) ex Buru*. Amstelaedami: apud J. Wetstenium, & Gul. Smith, & Janssonio-Waesbergios.
- Schroeder H.E. (1986) *The Peridontium. Handbook of microscopic anatomy, 5/5*. Berlin: Springer.
- Stehlin H.G. (1899) Über die Geschichte des Suiden Gebisses. Erster Teil. *Abhandlungen der Schweizerischen Palaontologischen Gesellschaft* 26: 1-336.
- Stehlin H.G. (1900) Über die Geschichte des Suiden Gebisses. Zweiter Teil. *Abhandlungen der Schweizerischen Palaontologischen Gesellschaft* 27: 337-527.
- Sun Z., Herring S.W., Tee B.C., Gales J. (2013) Alveolar ridge reduction after tooth extraction in adolescents: an animal study. *Archives in Oral Biology* 58: 813-825.
- van der Weijden F., Dell'Acqua F., Slot D.E. (2009) Alveolar bone dimensional changes of post-extraction sockets in humans: a systematic review. *Journal of Clinical Periodontology* 36: 1048-1058.
- van Heekeren H.R. (1966) Handen aan de wand. *Verre naasten naderbij* 1: 2-8.
- van Heekeren, H.R. (1972) The stone age of Indonesia. *Verhandelingen van het Koninklijke Instituut voor Taal-, Land-, en Volkenkunde* 61: 69-71, 116-122.
- Verna C., Dalstra M., Lee T.C., Cattaneo P.M., Melsen B. (2004) Microcracks in the alveolar bone following orthodontic tooth movement: a morphological and morphometric study. *European Journal of Orthodontics* 26: 459-467.
- Weaver M.E., Jump E.B., McKean C.F. (1969) The eruption pattern of permanent teeth in miniature swine. *Archives of Oral Biology* 14: 323-331.
- Yeh K-D., Popowics T.E. (2011a) The impact of occlusal function on structural adaptation in alveolar bone of the growing pig, *Sus scrofa*. *Archives of Oral Biology* 56: 79-89.
- Yeh K-D., Popowics T.E. (2011b) Molecular and structural assessment of alveolar bone during tooth eruption and function in the miniature pig, *Sus scrofa*. *Anatomia, Histologia Embryologia* 40: 283-291.