



THE UNIVERSITY *of* EDINBURGH

Edinburgh Research Explorer

The Use of Recombinant Tissue Plasminogen Activator (rTPA) in The Treatment of Fibrinous Pleuropneumonia in Horses: 25 Cases (2007-2012)

Citation for published version:

Tomlinson, JE, Byrne, E, Pusterla, N, Magdesian, KG, Hilton, HG, McGorum, B, Davis, E, Schoster, A, Arroyo, L, Dunkel, B, Carslake, H, Boston, RC & Johnson, AL 2015, 'The Use of Recombinant Tissue Plasminogen Activator (rTPA) in The Treatment of Fibrinous Pleuropneumonia in Horses: 25 Cases (2007-2012)' *Journal of Veterinary Internal Medicine*, vol. 29, no. 5, pp. 1403-1409. DOI: 10.1111/jvim.13594

Digital Object Identifier (DOI):

[10.1111/jvim.13594](https://doi.org/10.1111/jvim.13594)

Link:

[Link to publication record in Edinburgh Research Explorer](#)

Document Version:

Publisher's PDF, also known as Version of record

Published In:

Journal of Veterinary Internal Medicine

Publisher Rights Statement:

Copyright © 2015 The Authors. *Journal of Veterinary Internal Medicine* published by Wiley Periodicals, Inc. on behalf of the American College of Veterinary Internal Medicine.

This is an open access article under the terms of the Creative Commons Attribution-NonCommercial License, which permits use, distribution and reproduction in any medium, provided the original work is properly cited and is not used for commercial purposes.

General rights

Copyright for the publications made accessible via the Edinburgh Research Explorer is retained by the author(s) and / or other copyright owners and it is a condition of accessing these publications that users recognise and abide by the legal requirements associated with these rights.

Take down policy

The University of Edinburgh has made every reasonable effort to ensure that Edinburgh Research Explorer content complies with UK legislation. If you believe that the public display of this file breaches copyright please contact openaccess@ed.ac.uk providing details, and we will remove access to the work immediately and investigate your claim.



The Use of Recombinant Tissue Plasminogen Activator (rTPA) in The Treatment of Fibrinous Pleuropneumonia in Horses: 25 Cases (2007–2012)

J.E. Tomlinson, E. Byrne, N. Pusterla, K. Gary Magdesian, H.G. Hilton, B. McGorum, E. Davis, A. Schoster, L. Arroyo, B. Dunkel, H. Carslake, R.C. Boston, and A.L. Johnson

Background: Information about treatment protocols, adverse effects and outcomes with intrapleural recombinant tissue plasminogen activator (rTPA) use in horses with fibrinous pleuropneumonia is limited.

Hypothesis/Objectives: Describe factors that contribute to clinical response and survival of horses treated with rTPA intrapleurally.

Animals: Horses with bacterial pneumonia and fibrinous pleural effusion diagnosed by ultrasonography, that were treated with rTPA intrapleurally.

Methods: Retrospective multicenter case series from 2007–2012. Signalment, history, clinical and laboratory evaluation, treatment, and outcome obtained from medical records. Regression analysis used to identify associations between treatments and outcomes.

Results: Thirty three hemithoraces were treated in 25 horses, with 55 separate treatments. Recombinant tissue plasminogen activator (375–20,000 µg/hemithorax) was administered 1–4 times. Sonographically visible reduction in fibrin mat thickness, loculations, fluid depth, or some combination of these was seen in 32/49 (65%) treatments. Response to at least 1 treatment was seen in 17/20 (85%) horses with sonographic follow-up evaluation after every treatment. Earlier onset of rTPA treatment associated with increased survival odds. No association was found between cumulative rTPA dose or number of rTPA doses and survival, development of complications, duration of hospitalization or total charges. Clinical evidence of hypocoagulability or bleeding was not observed. Eighteen horses (72%) survived to discharge.

Conclusions and clinical importance: Treatment with rTPA appeared safe and resulted in variable changes in fibrin quantity and organization within the pleural space. Recombinant tissue plasminogen activator could be a useful adjunct to standard treatment of fibrinous pleuropneumonia, but optimal case selection and dosing regimen remain to be elucidated.

Key words: intrapleural; fibrinolysis; alteplase; pleuritis.

Pleural fibrin deposition is a common occurrence in parapneumonic effusions in horses. In a recent ret-

From the Department of Clinical Studies, New Bolton Center, University of Pennsylvania School of Veterinary Medicine, Kennett Square, PA (Tomlinson, Boston, Johnson); Alamo Pintado Equine Medical Center, Los Olivos, CA (Byrne); Department of Medicine and Epidemiology, School of Veterinary Medicine, University of California, Davis, CA (Pusterla, Magdesian); Departments of Structural Biology and Microbiology & Immunology, Stanford University School of Medicine, Stanford, CA (Hilton); Royal (Dick) School of Veterinary Studies and Roslin Institute, University of Edinburgh, Easter Bush, Midlothian UK (McGorum); Department of Clinical Sciences, College of Veterinary Medicine, Kansas State University, Manhattan, KS (Davis); Department of Clinical Studies, Ontario Veterinary College, University of Guelph, Guelph, Canada (Schoster, Arroyo); Department of Clinical Science and Services, The Royal Veterinary College, North Mymms, Herts UK (Dunkel); Philip Leverhulme Equine Hospital, University of Liverpool, Wirral, UK (Carslake).

Dr. Tomlinson's current association is the Department of Clinical Sciences, Cornell University, Ithaca, NY

Dr. Schoster's current association is the Equine Department, University of Zurich, Zurich, Switzerland

Corresponding author: J. Tomlinson, Department of Clinical Sciences, College of Veterinary Medicine, Cornell University, Ithaca NY, 14853. e-mail: jet37@cornell.edu.

Submitted November 24, 2014; Revised May 6, 2015; Accepted July 8, 2015.

Copyright © 2015 The Authors. Journal of Veterinary Internal Medicine published by Wiley Periodicals, Inc. on behalf of the American College of Veterinary Internal Medicine.

This is an open access article under the terms of the Creative Commons Attribution-NonCommercial License, which permits use, distribution and reproduction in any medium, provided the original work is properly cited and is not used for commercial purposes.

DOI: 10.1111/jvim.13594

Abbreviations:

rTPA	recombinant tissue plasminogen activator
IPFT	intrapleural fibrinolytic treatment
FA	facultatively anaerobic

rospective study, it affected 85% of horses with bacterial pleuropneumonia, and was associated with decreased survival.¹ Fibrin loculations create separated fluid pockets that inhibit thorough drainage of the pleural cavity and likely impair antimicrobial penetration.^{2–4} Repeated drainage and monitoring of pleural effusions are major causes of morbidity and expense in the treatment of pleuropneumonia in horses and can affect duration of hospitalization. Consequently, there is a strong interest in developing methods to prevent, decrease or remove fibrin deposits. Thoracoscopy has been advocated as a procedure to break down fibrinous loculations early in the disease process,⁵ but it has not gained widespread use. This likely is because of the limited field of view obtained, the surgical and anesthetic expertise required, potential complications, and the likelihood of reformation of fibrinous adhesions after the procedure.⁵ Standing thoracotomy is another option for removal of pleural fibrin, and it has been reported to result in a high survival rate of 88%.⁶ This procedure, however, often is reserved for end-stage disease, after pleural abscess formation, so that the abscess capsule prevents development of iatrogenic pneumothorax. The procedure also is associated with a high rate of complications (50%), surgical pain, and a prolonged recovery time with a median of 2.5 months for incisional heal-

ing.⁶ In search of a less invasive procedure, there has been increasing interest in intrapleural fibrinolytic treatment (IPFT) to break down fibrin loculations and improve drainage. The goals of IPFT are decreased hospitalization time because of faster resolution of pleural effusion, decreased incidence of complications such as pleural abscesses, decreased need for surgical intervention, and improved survival rate. We report the use of IPFT in 25 horses with fibrinous bacterial pleuropneumonia and investigate treatment factors that might affect outcome.

Materials and methods

Participating institutions were identified by contacting diplomates of the American College of Veterinary Internal Medicine and the European College of Equine Internal Medicine who specialize in large animal medicine using the listserve. Inclusion criteria were diagnosis of bacterial pleuropneumonia by clinical examination and culture, fibrinous pleural effusion on thoracic sonography, and treatment with intrapleural recombinant tissue plasminogen activator (rTPA) at least once. Investigators contributed all such cases treated at their respective hospitals over the study period.

Historical information collected from the medical records included age, sex, breed, and duration of clinical signs before hospitalization. Details obtained regarding clinical examination at admission were the presence or absence of fever, cough, nasal discharge, malodorous breath or nasal discharge, tachypnea, pleurodynia, abnormal mucous membranes, and thoracic auscultation findings. Admission peripheral blood leukocyte and platelet counts and plasma fibrinogen concentration were recorded. Additional information included duration of hospitalization, total inpatient charges, cost of rTPA, bacterial isolates from tracheal fluid, pleural fluid, or both, medications used, adjunctive therapies, complications, and outcome.

Details specific to pleural fluid drainage and rTPA administration were collected separately for each hemithorax and included number of drains placed, initial volume drained, fluid nucleated cell count, fluid protein concentration, odor of fluid obtained, duration of drainage, timing and number of treatments, dose of rTPA used, and sonographic appearance before and after each rTPA treatment. The sonographic response to treatment was subjectively described by each attending clinician and categorized as improved, mildly improved, not improved/worsened. The mildly improved description was thought to be more open to bias because treatment was not blinded and therefore this category was combined with the not improved/worsened category for analysis to provide the most conservative estimate of the results of treatment. To be categorized as improved, at least 1 of the following was present: clear reduction in maximal fluid height, breakdown of loculations, or reduction in total amount of fibrin.

Statistical analysis

Data were summarized using descriptive statistics. The median and range were reported.

Factors that could affect survival were investigated using logistic regression. The primary exposures of interest were the cumulative dosage of rTPA, total number of rTPA treatments, and the day of hospitalization on which the first rTPA treatment was administered. For this purpose, the day of treatment was natural log transformed to decrease the effect of right skew. The following confounders were considered: which hemithorax was treated, bacteriologic agents, anaerobic infection, malodorous breath or pleural fluid, epistaxis, use of hyperbaric oxygen treatment, age, total volume of pleural fluid drained at first thoracocentesis, peripheral

blood leukocyte counts and fibrinogen concentrations at admission, and duration of clinical disease before admission.

Exposures that could affect the change in sonographic appearance after rTPA administration were investigated using logistic regression. Exposures included the variables described above as well as the dose number (1st–4th dose), day of hospitalization on which rTPA was administered, individual dose of rTPA, and duration that drains were clamped after rTPA administration. For this purpose, sonographic outcome was collapsed into 2 categories: improved, or mild improvement/no change/deterioration.

Robust regression analysis was used to determine the association of cumulative dosage of rTPA and number of treatments with rTPA with the following outcomes: number of indwelling thoracic drains used, duration of thoracic drainage, occurrence of complications, occurrence of pleural abscessation, treatment with thoracotomy, duration of hospitalization, and total charges.

Fisher's exact test was used to compare survival and complication rates from this study with those reported for horses with fibrinous pleuropneumonia that were not treated with IPFT.¹

Commercial statistical software was used^a and significance was set at $P < 0.05$.

Results

Records of 25 horses from 8 clinics were obtained for analysis. One of these cases was included in a previous publication.⁷ They included 13 (52%) females, 5 (20%) intact males, and 7 (28%) geldings. The median age was 3 years (range, 14 days–19 years). The breeds were 12 (48%) Thoroughbred, 4 (16%) Quarter Horse, 4 (16%) Warmblood, 2 (8%) Irish Sport Horse, and 1 (4%) each Standardbred, Thoroughbred cross and Paint Horse.

The median duration of clinical signs before presentation was 4.5 days (range, 0 h [developed in hospital]–21 days).

Clinical signs at presentation included fever ($n = 11$), cough (13), nasal discharge (13) that was sanguineous in 5 horses and malodorous in 10, tachypnea (18), pleurodynia (12), and abnormal mucous membranes (9). Lung sounds were decreased ventrally in 20 horses, and 5 horses had crackles, wheezes, pleural friction rubs, or some combination of these. Median peripheral blood leukocyte count at admission was 9.63×10^9 cells/L (range, $2.7\text{--}34.2 \times 10^9$ cells/L). Median fibrinogen concentration at admission was 6 g/L (range, 2.95–10.84 g/L). Median blood platelet count was 150×10^9 /L (range, $94\text{--}300 \times 10^9$ /L).

Aerobic infection was confirmed in 23 horses; anaerobic in 13 and combined aerobic and anaerobic infection in 12 (Table 1). Of 19 tracheal aspirates, 18 were positive on aerobic and 10 were positive on anaerobic culture. Of 22 pleural fluid samples, 18 were positive on aerobic and 10 were positive on anaerobic culture. Polymicrobial infections were common, with only 4 horses having only a single bacterial species cultured. The most common isolate was *Streptococcus equi* subsp. *zooepidemicus* (19). The 2 most common anaerobic isolates were *Fusobacterium necrophorum* (6), and *Prevotella* spp. (6). A single neonate had blood and nasal swab cultures instead of transtracheal aspirate culture because of its small size. These cultures yielded a coagulase negative *Staphylococcus* and

Table 1. Combined culture results for tracheal aspirates and pleural fluid from 24 horses with fibrinous pleuropneumonia that were subsequently treated with intrapleural fibrinolytic treatment. FA, facultatively anaerobic

Aerobic and FA isolates (n = 38)	No. horses from which isolate was cultured (%)	Obligate anaerobic isolates (n = 26)	No. horses from which isolate was cultured (%)
Gram + cocci		Gram + cocci	
<i>Streptococcus equi</i> sbsp <i>zooepidemicus</i>	19 (76)	<i>Peptostreptococcus</i> spp.	3 (12)
<i>Staphylococcus aureus</i>	1 (4)		
Group C beta hemolytic <i>Streptococcus</i> , not speciated	1 (4)	Gram + bacilli unidentified	1 (4)
<i>Enterococcus</i> spp.	1 (4)		
<i>Rhodococcus equi</i>	1 (4)		
Gram - bacilli		Gram - bacilli	
<i>Escherichia coli</i>	6 (24)	<i>Fusobacterium necrophorum</i>	6 (24)
<i>Actinobacillus equuli</i>	3 (12)	<i>Prevotella</i> spp.	6 (24)
<i>Pasteurella</i> spp.	2 (8)	<i>Porphyromonas</i> spp.	4 (16)
<i>Enterobacter</i> spp.	2 (8)	<i>Bacteroides</i> spp.	4 (16)
<i>Morganella morganii</i>	1 (4)	unidentified	2 (8)
<i>Klebsiella</i> spp.	1 (4)		
Total no. horses with aerobic/FA isolates	23 (92)	Total no. horses with anaerobic isolates	13 (52)

Bordetella bronchiseptica, respectively. In all cases, the isolated bacteria were sensitive to the antimicrobials being utilized for treatment.

Horses received treatment at the clinicians' discretion (Table 2). Antimicrobials were used in combination and frequently were changed from the IV to PO route of administration during hospitalization.

Initial treatment consisted of placement of indwelling thoracic drains in 1 or both hemithoraces or intermittent drainage with a teat cannula. The median initial volume of pleural fluid drained from each side was 2 liters (range, 0–32 L). A median of 2 drains were placed per horse during hospitalization, 1 drain per hemithorax (range, 0–17 drains) for a median duration of drainage of 10 days (range, 0–150 days). The reasons for removing or replacing drains included blockage of the drain, insertion site cellulitis, or resolution of effusion.

Primary reasons cited for treatment with rTPA were to decrease loculations that were perceived to impede drainage of pleural fluid, lysis of adhesions, and to prevent pleural abscessation. Repeated obstruction of the indwelling drains with fibrin was not cited as a reason for IPFT. The financial resources of the owner often were a deciding factor in whether to implement IPFT. Recombinant tissue plasminogen activator treatment rarely was initiated on the first day of treatment

Table 2. Treatments administered to 25 horses with fibrinous pleuropneumonia that were also administered intrapleural fibrinolytic treatment

Antimicrobial treatment	No. horses treated (%)	Adjunctive treatment	No. horses treated (%)
Aminoglycoside		NSAID	24 (96)
Gentamicin	22 (88)	Flunixin meglumine	23 (92)
Amikacin	1 (4)	Phenylbutazone	6 (24)
		Meloxicam	2 (8)
Beta lactam		Aspirin	2 (8)
Penicillin	12 (48)	Diclofenac 2% topical cream	2 (8)
Ampicillin	3 (12)		
Ceftiofur	9 (36)	Gastrointestinal health support	12 (48)
Cefquinome	2 (8)	Probiotic bacteria	10 (40)
		Biosponge	9 (36)
Metronidazole	17 (68)	Omeprazole	8 (32)
		Ranitidine	3 (12)
Potentiated sulfa	9 (36)	Bismuth subsalicylate	2 (8)
		Sucralfate	2 (8)
Fluoroquinolone			
Enrofloxacin	4 (16)	Other analgesia	8 (32)
		Dipyrrone	4 (16)
Macrolide		Gabapentin	2 (8)
Clarithromycin	2 (8)	Morphine	2 (8)
Azithromycin	1 (4)	Butorphanol	2 (8)
		Fentanyl	1 (4)
Tetracycline		Lidocaine CRI	1 (4)
Doxycycline	1 (4)		
		Other anti-inflammatory/anti-endotoxic	
		Pentoxifylline	8 (32)
		J5 hyperimmune plasma	2 (8)
		Polymixin B	2 (8)
		Dexamethasone	2 (8)
		Vitamin E	1 (4)
		DMSO	1 (4)
		Other	
		Hyperbaric oxygen treatment	8 (32)
		Intravenous fluids	7 (28)
		Bronchodilators	3 (12)
		Heparin	2 (8)
		Diphenhydramine	1 (4)
		Stanozolol	1 (4)
		<i>R. equi</i> hyperimmune plasma	1 (4)
		Fenbendazole	1 (4)
		Glutathione	1 (4)
		Intranasal oxygen	1 (4)
		Hetastarch	1 (4)
		Furosemide	1 (4)

(median, day 4; range, day 1–76) and never on the first day of clinical signs (median, day 9.5; range, day 4–77).

All horses received alteplase and none received a DNase. The median number of rTPA doses per horse

was 2 (range, 1–8 doses), and per hemithorax was 1 (range, 1–4 doses) for a total of 55 doses among 25 horses. Seventeen horses received rTPA treatment in 1 hemithorax (12 on the right and 5 on the left) and the remaining 8 horses received treatments in both hemithoraces. The dose of rTPA used per hemithorax was highly variable with a median of 3750 μg (range, 375–20,000 μg). Recombinant tissue plasminogen activator was diluted in 10 mL–2 L of polyionic solution for administration and was infused through the existing thoracic drains or through a teat cannula into a specific fibrin loculation, which the clinician desired to break down. Indwelling tubes were clamped for a median of 24 h (range, 0.5–36 h) to prevent medication from draining out. Fifteen of 25 horses had the chest lavaged with 1–20 L polyionic fluids before administration of rTPA. Two horses received intrapleural amikacin in combination with rTPA, and 5 horses were treated with intrapleurally administered antimicrobials (potassium penicillin, gentamicin, metronidazole, amikacin) at other times.

Thoracic sonography was performed before rTPA administration for all doses and within 24 h of unclamping the tubes after 49 of 55 doses. Thirty two of 49 (65%) treatments with follow-up sonographic evaluation resulted in notable improvement. The volume of drainage immediately upon unclamping the tubes after rTPA administration was not routinely recorded, but for the 15 doses for which it was recorded, the median amount drained was 1.5 L (range, 0–6 L). All horses had sonographic follow-up evaluation after at least 1 dose, but only 20 horses had sonographic follow-up for all doses. Seventeen (17/20, 85%) of those showed notable decreases in fibrin loculations, fibrin mat thickness, fluid depth, or some combination of these within 24 h of at least 1 rTPA treatment.

Complications secondary to pleuropneumonia were seen in 20 horses (Table 3). Of 3 horses that developed a pleural abscess, 1 required prolonged drainage (42 days), another required thoracotomy, and 1 was

Table 3. The development of and survival with complications in 25 horses with bacterial pleuropneumonia that received intrapleural fibrinolytic treatment. The overall survival rate was 18/25 (72%). Most horses (80%) developed at least 1 complication. No bleeding complication was observed

Complication	No. horses	No. survived
No complication	5	5
Any complication	20	13
Pulmonary abscess	11	9
Laminitis	3	0
Pleural abscess	3	2
Bronchopleural fistula	3	2
Cranial mediastinal abscess	2	0
Jugular vein thrombosis	2	2
Suspected re-inflation pulmonary edema	1	1

euthanized. Although 2 horses developed jugular vein thrombosis, no evidence of hemorrhagic coagulopathy was seen.

Eighteen (72%) horses survived and 7 were euthanized. Reasons for euthanasia were severity of disease and poor response to treatment (4), development of laminitis (3), and financial considerations (3). Excluding horses euthanized for financial reasons, 82% survived. Ten survivors were racehorses (8 Thoroughbred, 1 Quarter Horse, 1 Standardbred), 4 of which returned to racing, with 2 winning at least once. Both winners had a bronchopleural fistula. Five racehorses were retired without attempt to retrain for racing. Two of the 5 became riding horses and the other 3 were retired to be broodmares. One racehorse did not race again but was otherwise lost to follow-up. Of the remaining 8 non-racehorse survivors, 1 broodmare foaled successfully, 1 competitive western riding horse was retired to pleasure riding without an attempt to return to previous performance level, 1 was euthanized 8 months after discharge because of orthopedic injury, and 5 were lost to follow-up.

The median duration of hospitalization was 19 days (range, 8–210 days) with median hospital charges of \$9800 USD (range, \$3743–\$30,000). The median total cost per horse for rTPA was \$605 USD (range: \$176–\$1201) which represented 1–15% of each horse's total hospital charges. The cost per mg of rTPA varied widely (median \$88, range \$8–370 USD/mg).

Foul odor of breath, pleural fluid, or both (OR = 0.052, CI = 0.007–0.38, $P = 0.004$) but not anaerobic infection was highly associated with no sonographic improvement after IPFT. Infection with enterobacteriaceae was associated with an 83% lower odds of sonographic response to rTPA treatment (OR = 0.17, CI = 0.027–0.99, $P = 0.05$) whereas infection with *Escherichia coli* was associated with an 86% lower odds of sonographic response to rTPA treatment (OR = 0.14, CI = 0.019–1.07, $P = 0.058$).

Earlier onset of rTPA treatment during hospitalization was associated with increased odds of survival (OR for $\ln[\text{day of first rTPA dose}] = 0.22$, $P = 0.034$, Fig. 1). There was no association between cumulative rTPA dosage or number of rTPA doses and any outcome. There was no association between any other variable tested and survival. The survival rate for horses treated with IPFT in this study (72%) was not statistically different from the survival of horses with fibrinous pleural effusion that did not receive IPFT (62%).¹ Horses treated with IPFT had nonsignificantly lower rates of pleural abscessation (12%) and surgical intervention (4%) compared to 19% and 7.9%, respectively, in horses with fibrinous pleural effusion that were not treated with IPFT.¹

Discussion

Intrapleural fibrinolytic treatment has been used for over 60 years in people with variable success. Several reviews have concluded that IPFT appears to decrease the requirement for surgical interventions but does not

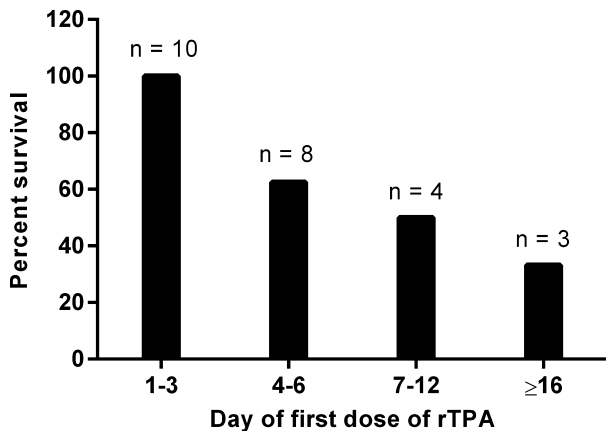


Fig. 1. The survival rate by the day of hospitalization that rTPA treatment was started for 25 horses with bacterial pleuropneumonia and fibrinous pleural effusion that were treated with an intraleural fibrinolytic agent, rTPA. Treatment was initiated between day 1 and 76 of hospitalization. By logistic regression, the odds of survival was higher with earlier onset of treatment ($P = 0.034$).

decrease mortality in adults.^{8,9} Although early studies in people identified improved survival after IPFT,^{10–12} 2 of the largest randomized, placebo-controlled studies in adults failed to show a positive effect with IPFT without concurrent intraleural administration of DNase.^{13,14} This discrepancy has been attributed to wide variation in patient selection, dosage regimens, and type of fibrinolytic agent used (including urokinase, streptokinase, alphasimase, and rTPA). Unlike in adults, in pediatric medicine, the use of IPFT is well accepted and efficacious.¹⁵ These findings are similar to the findings in our study. We found an improved odds of survival with early rTPA treatment, and a suggestion that surgical intervention might be decreased, although statistical power was low in this study and the apparent reduction in the need for surgical intervention was not statistically significant. Although most horses develop pleuropneumonia as adults, the disease process in many ways resembles human pediatric cases more than human adult cases because, in contrast to adults, horse and children generally are presented without other comorbidities.^{13,16–18}

The information provided in this study is primarily descriptive. Conclusions based on the statistical analysis provided must be considered in the context of the limitations of the study. An appropriate control population was not available, which means efficacy of treatment could not be evaluated directly, both in terms of sonographic improvement and survival after IPFT. In particular, the sonographic improvement noted after 65% of IPFT treatments is difficult to interpret because no appropriate control for the likelihood of sonographic improvement after 24 h of standard treatment was available. Sonographic evaluation also is largely subjective and lacks standardized criteria to determine improvement. Wide variation in the dosage and timing of treatment limited the power of comparisons of outcome by dose. Four major causes of bias in case

selection and dosing were identified. First, because IPFT still is regarded as an experimental treatment, for many clinicians it was reserved only for severely affected horses that were perceived to have a poor prognosis or high risk of complications. This suggests a bias toward a higher mortality rate, which could mask a true benefit of rTPA treatment and account for the lack of statistical difference between survival and complication rates of horses in this study and the companion study.¹ However, this effect could have been offset by having a second concurrent bias toward a population of owners with sufficient funds to invest in optimal care and longer treatment courses. Third, some of the clinicians used larger dosages based on a single early case report describing the use of alteplase in a horse.⁷ Because the single case contributors generally were using IPFT in severely affected horses, there might have been some bias for higher mortality and complication rates in horses receiving higher doses. Fourth, due to the cost of treatment, most clinicians used the fewest number of doses possible. Therefore, additional doses were more likely to be given if there was an incomplete or no response or more severe disease.

Investigation of IPFT has been hampered by a lack of fundamental studies examining appropriate dosage regimens both in people and horses. In this study, no association between dosage of rTPA and outcome could be identified either in the short term (sonographic improvement) or long term (complication rate, survival). Although this observation could reflect a true lack of effect of treatment at any dosage, this surprising finding is likely to be a factor of small sample size, number of contributing clinicians, and highly variable treatment regimens. In humans, doses from 2–100 mg of alteplase have been used with variable success.¹¹ Dwell times have varied from 1 to 24 hours and frequency of administration from 1 to 3 times daily.^{10,11,14,19} For rTPA to be effective, endogenous plasminogen must be available for conversion into plasmin. It is unknown whether or not larger or more frequent doses are futile because the natural supply of plasminogen is exhausted. In human and preclinical rodent studies, 1 of the few consistent aspects of dosing is the use of repeated administrations, with once or twice daily administration for 3 days being the most common approach.^{9–11,14,19,20} If a standard 3 day dosing regimen were adopted for horses, results might be better, but several contributing clinicians reported that their ability to use a higher dose or to repeat dosing was limited by the owner's financial commitment to treatment.

The half-life of rTPA in human plasma is only about 6 minutes¹¹, but its half-life in parapneumonic pleural fluid is unknown. The short plasma half-life, however, suggests that long dwell times are likely not helpful. In this study, no association between dwell time and likelihood of sonographic improvement was found after IPFT. However, in 1 case, a horse had thoracic sonography performed after 2 h of dwell time, at which time no appreciable changes were present, but repeated evaluation at 4 h identified decreased fibrin loculations.

This observation suggests either ongoing rTPA activity, or a posttreatment effect because of the action of activated plasmin. Because the rTPA-plasminogen complex generally must be bound to fibrin, earlier opening of the drains might not result in loss of active plasmin or efficacy. Some balance must be achieved between adequate dwell time and early enough opening of the drains that maximal fluid drainage is achieved before loculations reform. Based on the findings of this study and results from human medicine, a dwell time of 4 h is tentatively recommended until additional investigations have been completed.

Earlier administration of the first rTPA dose was associated with improved survival in this study. This observation does not necessarily imply that starting treatment on the day of admission would be best, as only 3 horses were treated on the day of admission. There is some evidence to suggest that rTPA is only beneficial in the subset of human patients that did not have resolution of pleural effusion after 24 h of conventional tube drainage. In a series of prospective trials in people, all patients with purulent or septic pleural fluid were treated beginning on the day of admission and no difference in outcome was seen with IPFT versus placebo.¹⁴ Conversely, in studies in which IPFT was limited to patients that still had pleural effusion after 24 h of chest drainage, a positive effect was observed.^{10,11} A prospective trial using IPFT in horses that have incomplete resolution of pleural effusion after 24 h of tube drainage would be beneficial but is not likely to be feasible given the high costs and relatively low disease incidence involved.

Despite the apparent survival benefit of early onset of treatment, the timing of an individual dose relative to admission to the hospital was not associated with likelihood of sonographic improvement. Information regarding the timing of treatments relative to the development of loculations was not available and is probably the most relevant information because some horses do not have fibrin or loculations on admission to the hospital.¹

No evidence of rTPA-associated hemorrhagic coagulopathy such as petechiation, hemoptysis, or bleeding at venipuncture or chest drain sites was reported. Coagulation profiles were not performed and subclinical prolongations could have been present. In humans, bleeding complications occur in approximately 7% of patients treated with IPFT, but patients who had bleeding complications more often were receiving concurrent anticoagulation treatment or intrapleural DNase treatment.^{11,14,20}

Pleural fibrin deposition in parapneumonic effusions has been shown to be caused primarily by increased expression of plasminogen activator inhibitor-1 (PAI-1), which causes an imbalance between procoagulant and fibrinolytic pathways.²¹ A newer type of rTPA called tenecteplase was designed to be more resistant to inhibition by PAI-1 to overcome the high level of inhibition.²² This product has been used in a single horse in combination with a DNase with a successful outcome.²³

One possible cause of failure of IPFT with TPA alone in a previous study¹⁴ was that the viscosity of

highly cellular pleural fluids prevented adequate drainage even if TPA successfully decreased intrapleural loculations. Intrapleural DNase administration has been used to enzymatically digest cellular DNA, thereby decreasing the viscosity of the empyemic fluid. In the previous study, the combination of TPA with a DNase resulted in 77% fewer referrals for surgical intervention and a shorter hospitalization time, but also a nonsignificant increase in bleeding complications.¹⁴ It is unclear whether this requirement for DNase treatment is applicable to horses. Chest drains used in horses generally are larger than those used in human patients (15 Fr or less), which might decrease the effect of viscosity on ability to drain the effusion.

In conclusion, there could be a place for IPFT in the treatment of fibrinous parapneumonic effusions in horses. No complications associated with rTPA administration were detected in this study, and it appears to be safe to use in horses. In this study, the cost of rTPA treatment was a small percentage of the entire hospital charges, suggesting it should not be considered cost prohibitive. A blinded, randomized, placebo-controlled study would be ideal but is probably unrealistic based on low case numbers. Therefore, a tentative treatment protocol is proposed: consider administration of IPFT if the pleural effusion remains above the level of the drain or is trapped in fibrin loculations 24 h after the placement of indwelling chest drains. Tenecteplase could be used in preference to alteplase, based on better theoretical performance in septic effusions.²² If using alteplase, 2–10 mg per dose q12–24 h for 3 days, with a dwell-time of approximately 4 h is a recommended treatment course.

Footnote

^a StataCorp. 2011. *Stata Statistical Software: Release 12*. College Station, TX: StataCorp LP. And Rstudio. 2014. *RStudio: Integrated development environment for R* (Version 0.98.1056) [Computer software]. Boston, MA. Retrieved September 15, 2014.

Acknowledgments

None.

Previous publication: 2014 ACVIM Forum research abstract oral presentation. VCRS oral presentation October 2014.

Conflict of Interest Declaration: Authors disclose no conflict of interest.

Off-label Antimicrobial Declaration: Authors declare no off-label use of antimicrobials.

References

1. Tomlinson J, Reef V, Boston R, Johnson A. The Association of Fibrinous Pleural Effusion with Survival and Complications in Horses with Pleuropneumonia (2002–2012): 74 Cases. *JVIM* (in press).

2. Himelman RB, Callen PW. The prognostic value of localizations in parapneumonic pleural effusions. *Chest* 1986;90:852–856.
3. Raidal SL. Equine Pleuropneumonia. *Br Vet J* 1995;151:233–262.
4. Chaffin MK, Carter GK, Byars TD. Equine bacterial pleuropneumonia. Part III. Treatment, sequelae, and prognosis. *Compend Contin Educ Vet* 1994;16:1585–1594.
5. Vachon AM, Fischer AT. Thoracoscopy in the horse: diagnostic and therapeutic indications in 28 cases. *Equine Vet J* 1998;30:467–475.
6. Hilton H, Aleman M, Madigan J, Nieto J. Standing lateral thoracotomy in horses: indications, complications, and outcomes. *Vet Surg* 2010;39:847–855.
7. Hilton H, Pusterla N. Intrapleural fibrinolytic therapy in the management of septic pleuropneumonia in a horse. *Vet Rec* 2009;164:558–559.
8. Cameron R, Davies HR. Intra-pleural fibrinolytic therapy versus conservative management in the treatment of adult parapneumonic effusions and empyema. *Cochrane Database Syst Rev* 2008;(2):CD002312.
9. Janda S, Swiston J. Intrapleural fibrinolytic therapy for treatment of adult parapneumonic effusions and empyemas: a systematic review and meta-analysis. *Chest* 2012;142:401–411.
10. Levinson GM, Pennington DW. Intrapleural fibrinolytics combined with image-guided chest tube drainage for pleural infection. *Mayo Clin Proc* 2007;82:407–413.
11. Hamblin SE, Furmanek DL. Intrapleural tissue plasminogen activator for the treatment of parapneumonic effusion. *Pharmacotherapy* 2010;30:855–862.
12. Bouros D, Tzouvelekis A, Antoniou KM, Heffner JE. Intrapleural fibrinolytic therapy for pleural infection. *Pulm Pharmacol Ther* 2007;20:616–626.
13. Maskell NA, Davies CW, Nunn AJ, et al. U.K. Controlled trial of intrapleural streptokinase for pleural infection. *N Engl J Med* 2005;352:865–874.
14. Rahman NM, Maskell NA, West A, et al. Intrapleural use of tissue plasminogen activator and DNase in pleural infection. *N Engl J Med* 2011;365:518–526.
15. Paraskakis E, Vergadi E, Chatzimichael A, Bouros D. Current evidence for the management of paediatric parapneumonic effusions. *Curr Med Res Opin* 2012;28:1179–1192.
16. Thommi G, Shehan JC, Robison KL, et al. A double blind randomized cross over trial comparing rate of decortication and efficacy of intrapleural instillation of alteplase vs placebo in patients with empyemas and complicated parapneumonic effusions. *Respir Med* 2012;106:716–723.
17. Picard E, Joseph L, Goldberg S, et al. Predictive factors of morbidity in childhood parapneumonic effusion-associated pneumonia: a retrospective study. *Pediatr Infect Dis J* 2010;29:840–843.
18. Corcoran JP, Hallifax R, Rahman NM. New therapeutic approaches to pleural infection. *Curr Opin Infect Dis* 2013;26:196–202.
19. Zhu Z, Hawthorne ML, Guo Y, et al. Tissue plasminogen activator combined with human recombinant deoxyribonuclease is effective therapy for empyema in a rabbit model. *Chest* 2006;129:1577–1583.
20. Abu-Daff S, Maziak DE, Alshehab D, et al. Intrapleural Fibrinolytic Therapy (IPFT) in loculated pleural effusions—analysis of predictors for failure of therapy and bleeding: a cohort study. *BMJ Open* 2013;3: doi: 10.1136/bmjopen-2012-001887.
21. Idell S, Girard W, Koenig KB, et al. Abnormalities of pathways of fibrin turnover in the human pleural space. *Am Rev Respir Dis* 1991;144:187–194.
22. Keyt BA, Paoni NF, Refino CJ, et al. A faster-acting and more potent form of tissue plasminogen activator. *Proc Natl Acad Sci USA* 1994;91:3670–3674.
23. Rendle DI, Armstrong SK, Hughes KJ. Combination fibrinolytic therapy in the treatment of chronic septic pleuropneumonia in a thoroughbred gelding. *Aust Vet J* 2012;90:358–362.