



THE UNIVERSITY *of* EDINBURGH

## Edinburgh Research Explorer

# A case of variably protease-sensitive prionopathy treated with doxycyclin

### Citation for published version:

Assar, H, Topakian, R, Weis, S, Rahimi, J, Trenkler, J, Höftberger, R, Aboulenein-Djamshidian, F, Ströbel, T, Budka, H, Yull, H, Head, MW, Ironside, JW & Kovacs, GG 2015, 'A case of variably protease-sensitive prionopathy treated with doxycyclin' *Journal of Neurology, Neurosurgery & Psychiatry*, vol. 86, no. 7, pp. 816-818. DOI: 10.1136/jnnp-2014-309871

### Digital Object Identifier (DOI):

[10.1136/jnnp-2014-309871](https://doi.org/10.1136/jnnp-2014-309871)

### Link:

[Link to publication record in Edinburgh Research Explorer](#)

### Document Version:

Peer reviewed version

### Published In:

*Journal of Neurology, Neurosurgery & Psychiatry*

### General rights

Copyright for the publications made accessible via the Edinburgh Research Explorer is retained by the author(s) and / or other copyright owners and it is a condition of accessing these publications that users recognise and abide by the legal requirements associated with these rights.

### Take down policy

The University of Edinburgh has made every reasonable effort to ensure that Edinburgh Research Explorer content complies with UK legislation. If you believe that the public display of this file breaches copyright please contact [openaccess@ed.ac.uk](mailto:openaccess@ed.ac.uk) providing details, and we will remove access to the work immediately and investigate your claim.



## ONLINE SUPPLEMENTAL FILE-1

---

### **A case of variably protease-sensitive prionopathy treated with doxycyclin**

Hamid Assar MD<sup>1</sup>, Raffi Topakian MD<sup>2</sup>, Serge Weis MD PhD<sup>3</sup>, Jasmin Rahimi MD<sup>4</sup>, Johannes Trenkler MD<sup>5</sup>, Romana Höftberger MD<sup>4</sup>, Fahmy Aboulenein-Djamshidian MD<sup>6</sup>, Thomas Ströbel PhD<sup>4</sup>, Herbert Budka MD<sup>7</sup>, Helen Yull MSc<sup>8</sup>, Mark W. Head PhD<sup>8</sup>, James W. Ironside FRCPATH FMedSci<sup>8</sup>, Gabor G. Kovacs MD PhD<sup>4</sup>

1: Neuromedizinische Ambulanzzentrum, State Neuropsychiatric Hospital Wagner-Jauregg, Linz, Medical School, Johannes Kepler University, Linz, Austria;

2: Department of Neurology, Klinikum Wels-Grieskirchen, Wels, Austria;

3: Laboratory of Neuropathology, Department of Pathology and Neuropathology, State Neuropsychiatric Hospital Wagner-Jauregg, Medical School, Johannes Kepler University Linz, Austria;

4: Institute of Neurology, Medical University of Vienna and Austrian Reference Centre for Human Prion Diseases Vienna, Austria;

5: Institute of Radiology, State Neuropsychiatric Hospital Wagner-Jauregg, Linz, Medical School, Johannes Kepler University, Linz, Austria;

6: Karl Landsteiner Institute for Neuroimmunological and Neurodegenerative Disorders, Department of Neurology, SMZ-Ost Donauespital, Vienna, Austria

7: Institute of Neuropathology, University Hospital Zürich, Zürich, Switzerland

8: National CJD Research & Surveillance Unit, University of Edinburgh, Edinburgh, United Kingdom;

---

### **Material and Methods**

Neuropathological examination was performed using paraffin-embedded tissue blocks of various cortical regions, basal ganglia, thalamus, hippocampus, brainstem and cerebellum using standard and published methods and various anti-PrP antibodies.<sup>1</sup> The study was approved by the Ethical Committee of the Medical University of Vienna (Nr. 396/2011). Frozen tissues from selected brain regions from this case were available for biochemical analysis. Tissues were analyzed for the presence of protease resistant PrP (PrP<sup>res</sup>) as previously described.<sup>2</sup> Selected UK cases of sporadic and variant Creutzfeldt-Jakob disease (vCJD) were used as reference standards for the Western blot analysis. They were obtained from the CJD Brain and Tissue Bank (part of Edinburgh Brain and Tissue Banks); the use of these tissues is covered by ethics approval 11/ES/0022, Edinburgh Brain Bank.

### **Clinical observations**

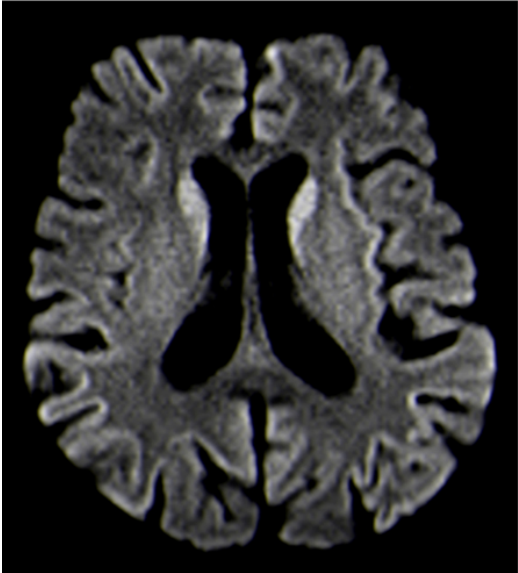
Based on clinical scales, the change in MMSE was noteworthy (22/30 in September 2007, 13/30 in January 2008, and 0/30 from August 2008 on; Barthel index was 100/100 in June, 2007, 95/100 in September, 2007, 60/100 in January, 2008, 30/100 in August, 2008 and 0/100 in December, 2008).

Diffusion restriction had resolved 3.5 years after baseline imaging and a marked atrophy had evolved (**Suppl. Figure 1A, B**) with progression on CT after 4.5 years (**Suppl. Figure 1 C, D**).

Suppl. Figure 1. DWI (A, B) and cranial CT (C, D).

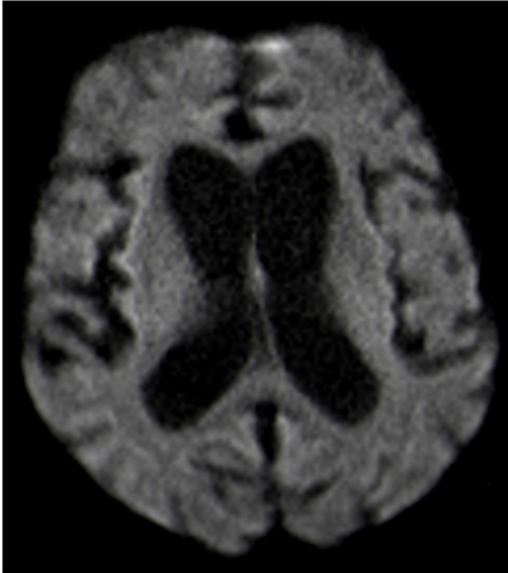
A

Baseline DWI

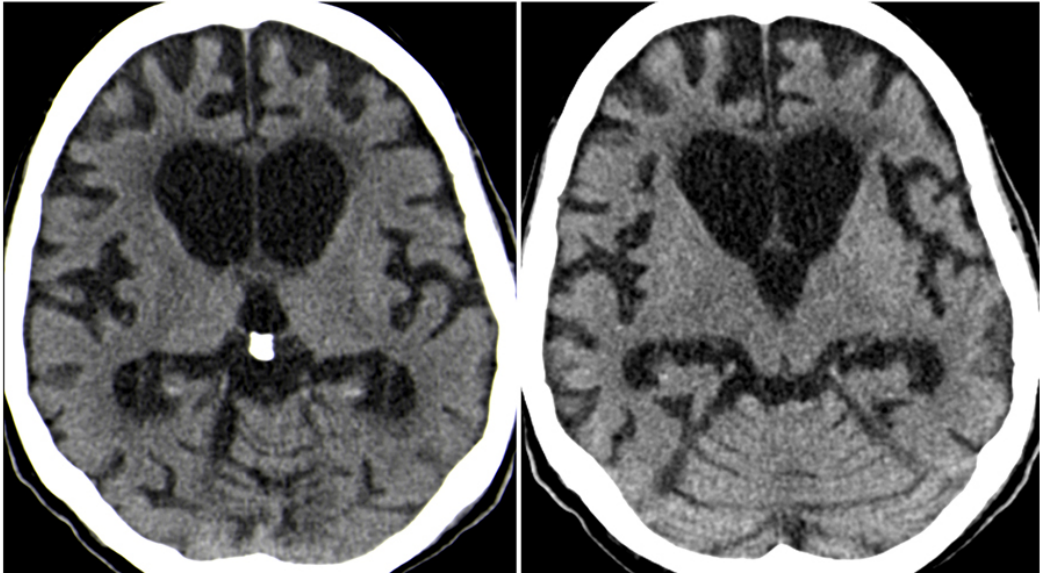


B

DWI 3.5 years after baseline imaging



CT 4.5 years after baseline imaging



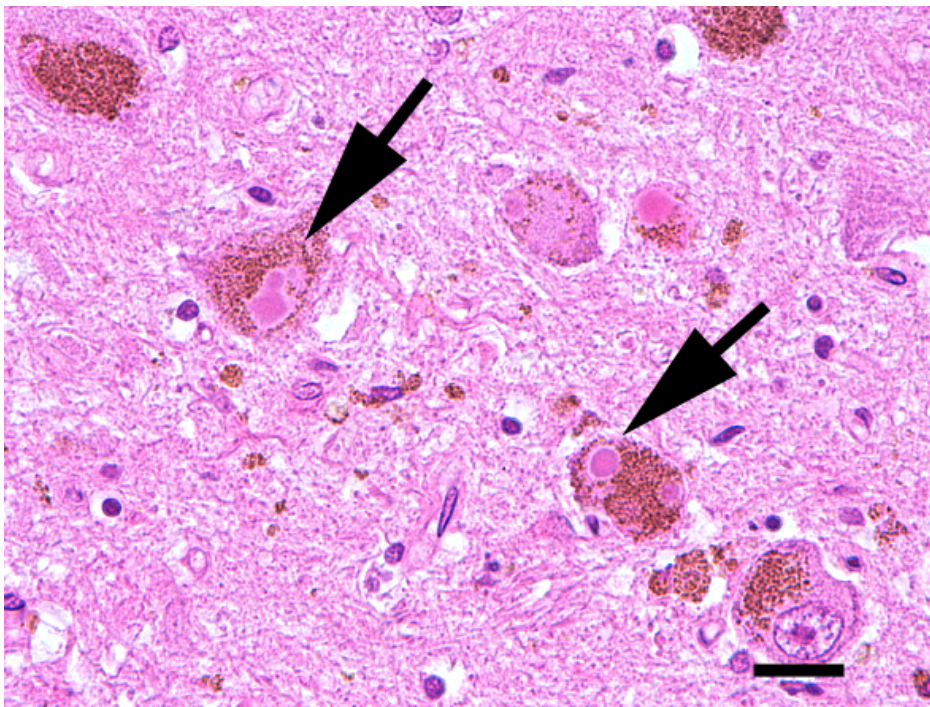
C

D

### Neuropathological observations

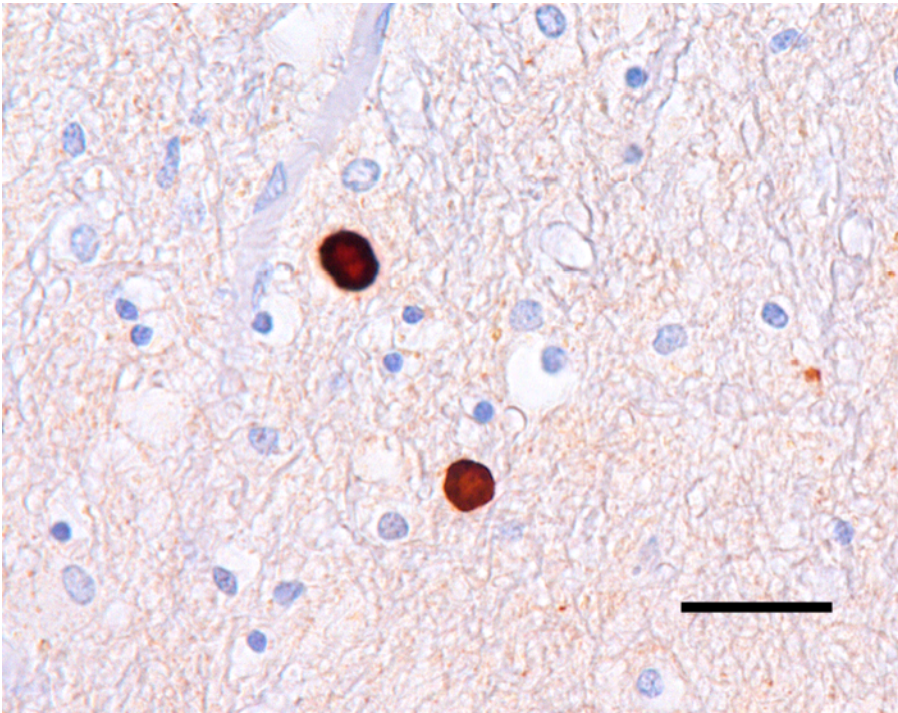
Macroscopic evaluation revealed cortical atrophy and enlargement of the ventricles. A moderate degree of spongiform change and gliosis was seen in the frontal, temporal, parietal and occipital cortices and nucleus accumbens, while mild or focal spongiform change was noted in the striatum, thalamus, hippocampal subregions and cerebellar cortex. Reactive gliosis was prominent in the striatum and amygdala. Neurons in the cortical areas, hippocampus, and cerebellum were relatively well preserved. In the brainstem the locus coeruleus and substantia nigra showed moderate neuronal loss and eosinophilic Lewy bodies (**Suppl. Figure 2**).

**Suppl. Figure 2.** Lewy bodies (arrows) in the substantia nigra (Bar: 25  $\mu\text{m}$ ).



Immunostaining for PrP showed a diffuse synaptic pattern with loose clusters of granular deposits in the cortex and small droplets (8-12  $\mu\text{m}$ ) in the white matter (**Suppl. Figure 3**). These did not resemble the dystrophic neurites that are immunostained for PrP<sup>C</sup> in the cortex in Alzheimer disease samples.

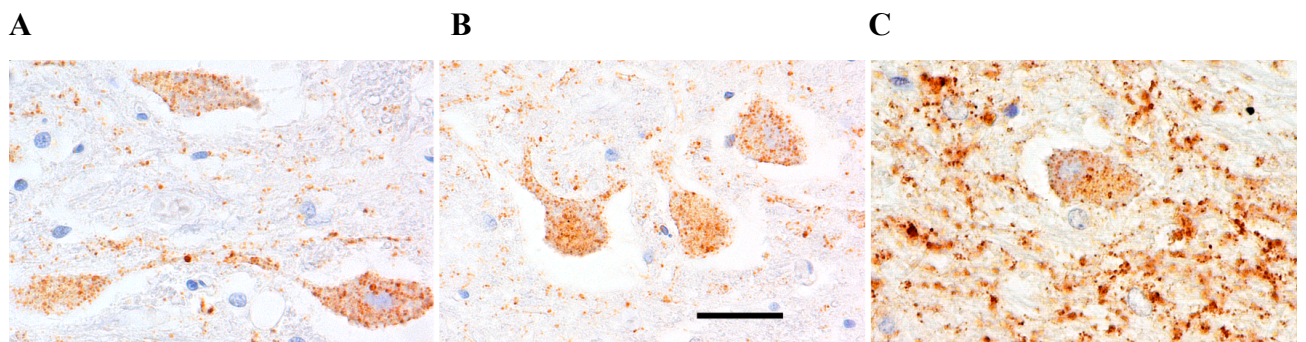
**Suppl. Figure 3.** PrP immunoreactive droplets in the parietal white matter (bar: 25  $\mu$ m).



Intraneuronal dots and somatosynaptic type of PrP immunoreactivity were noted in the anterior horn motor neurons of the cervical spinal cord (**Suppl. Figure 4 A, B**). This corresponds to the somato-synaptic and intraneuronal fine dot-like pattern seen mostly in VV and MV type 2 sporadic CJD cases mostly in the brainstem/thalamus (**Suppl. Figure 4 C**).

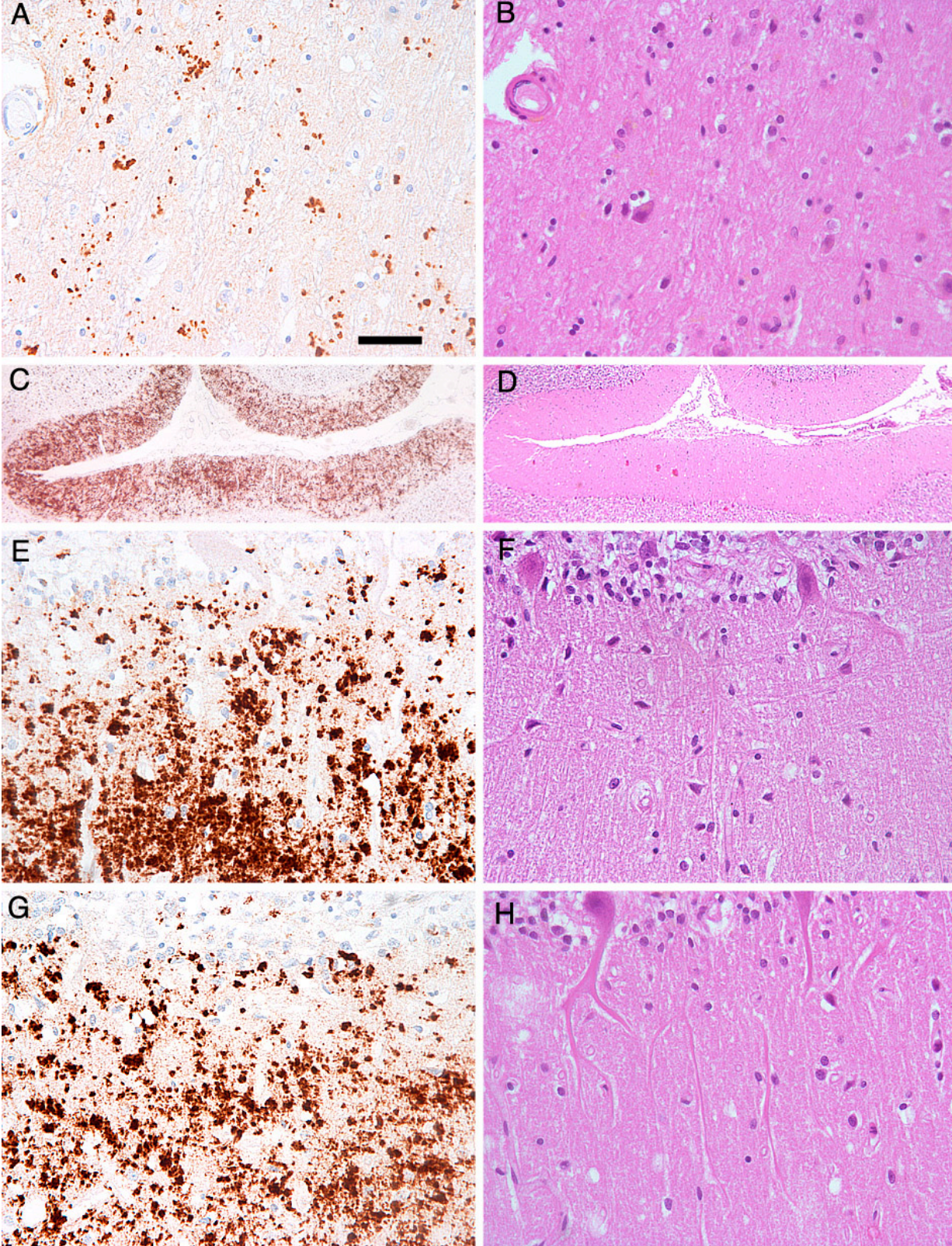
**Suppl. Figure 4.** PrP immunoreactivity in the lower motor neurons (cervical spinal cord).

A and B is the present case, C is a sporadic CJD VV type 2 case used as control (pons base shown here). Bar in B: 25  $\mu$ m.



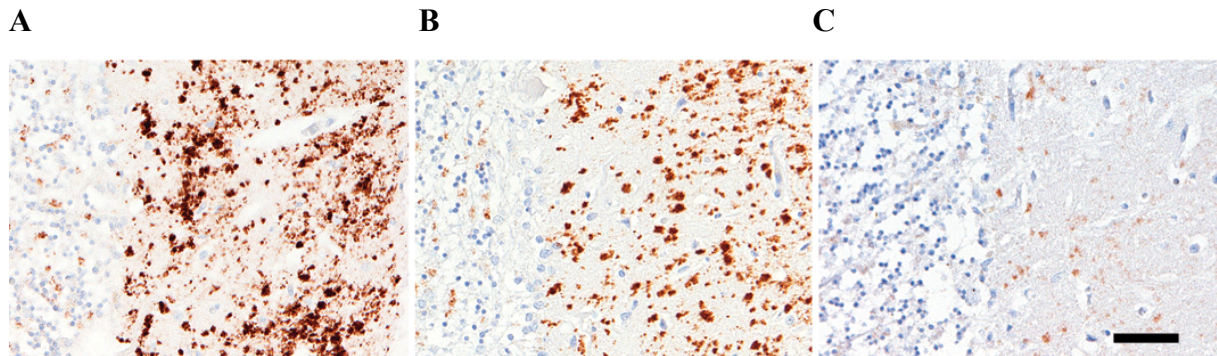
In the thalamus and cerebellar cortex mostly the granular- and microplaque-like PrP immunoreactivity was seen (**Suppl. Figure 5 A-H**). Microplaques were not seen unequivocally in adjacent section stained for Haematoxylin and eosin.

**Suppl. Figure 5.** PrP immunoreactivity in the thalamus (A) and cerebellum (C, E, G) shows microplaque-like immunoreactivity. However, these are not detected unequivocally in the Haematoxylin and Eosin stained sections of the thalamus (B) and cerebellum (D, F, H). Bar in A represents 50  $\mu\text{m}$  for A, B and E-H and 150  $\mu\text{m}$  for C and D.



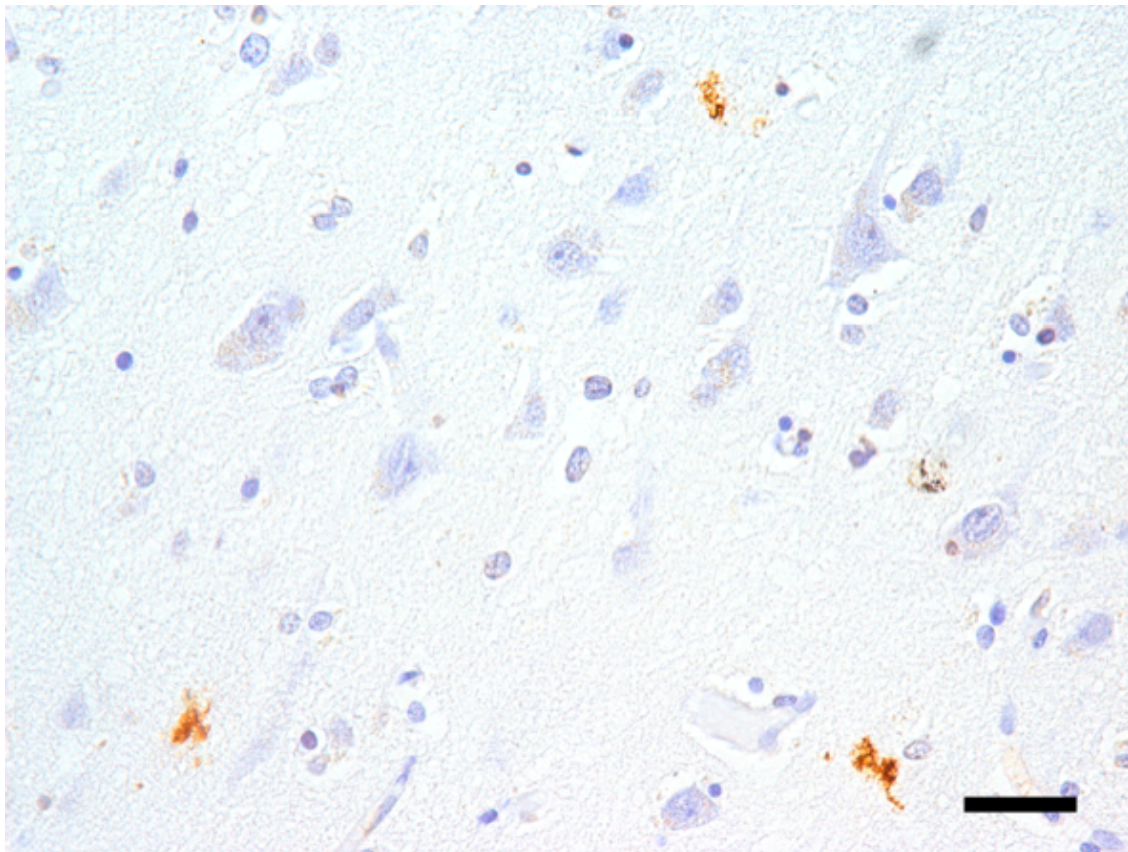
The most prominent degree of PrP immunoreactivity was seen in the parietal and occipital cortices, thalamus and cerebellum. Comparison of different anti-PrP antibodies revealed that 3F4 (**Suppl. Figure 6A**), KG9, L42 and 12F10 (**Suppl. Figure 6B**) were the most effective to detect the immunoreactivities, while 6H4 (**Suppl. Figure 6C**) showed only weak results.

**Suppl. Figure 6.** Comparison of PrP immunoreactivity in the cerebellum as visualized by antibody 3F4 (**J**), 12F10 (**K**) and 6H4 (**L**). Bar in C represents 50  $\mu$ m.



Immunostaining for phospho-tau (AT8) revealed small neuritic profiles (**Suppl. Figure 7**) as seen also in sporadic CJD brains.

**Suppl. Figure 7.** Phospho-tau (AT8) immunoreactivity in the frontal cortex (bar: 25  $\mu$ m).



## Comments

The neuropathological features together with the Western blot profile of this case, including poorly protease-resistant PrP, an approximately 8kDa band, and additional 19kDa and 23kDa bands in the cerebellum, are consistent with VPSPr.<sup>2-4</sup> Moreover the *PRNP* codon 129 genotype of the patient (VV) is the one in which VPSPr most commonly occurs.<sup>3,4</sup>

In the striatum mostly gliosis was observed, while in the neocortex gliosis and spongiform alterations were noted. The severity of these histopathological features overlapped with the areas in DWI showing high signal and also with the atrophy seen in the CT.

Interestingly, pentosan-polysulphate therapy in vCJD seems to be associated with prolonged survival, but prominent tissue damage of the brain.<sup>5</sup> *In vitro* and *in vivo* studies have shown that doxycycline renders PrP<sup>Sc</sup> protease sensitive, reduces the infectivity titer in prion-contaminated material, and prolongs the survival of experimentally prion-infected animals, but had no apparent effect on disease characteristics or duration in a randomized, double-blind placebo-controlled trial in patients with sporadic and genetic forms of CJD.<sup>6</sup>

Detection of VPSPr in a cognitively normal 93-year-old individual suggests that PrP production in VPSPr might in itself be less neurotoxic.<sup>7</sup>

Of note, restricted diffusion was widespread in the baseline imaging of the basal ganglia and cerebral cortex, but declined over the years. We are not aware of any characteristic MRI feature of VPSPr but it is of note that the first MRI images were similar to that seen in sporadic CJD.

Lewy body pathology<sup>8</sup> as well as lack of microplaques detectable in H&E<sup>2</sup> has been also reported in VPSPr. Neuronal loss in the pigmented brainstem nuclei correlated with the presence of Lewy bodies.



## References

1. Kovacs GG, Peden A, Weis S, et al. Rapidly progressive dementia with thalamic degeneration and peculiar cortical prion protein immunoreactivity, but absence of proteinase K resistant PrP: a new disease entity? *Acta Neuropathol Commun* 2013;**1**:72.
2. Head MW, Yull HM, Ritchie DL, et al. Variably protease-sensitive prionopathy in the UK: a retrospective review 1991-2008. *Brain* 2013;**136**:1102-15.
3. Gambetti P, Dong Z, Yuan J, et al. A novel human disease with abnormal prion protein sensitive to protease. *Ann Neurol* 2008;**63**:697-708.
4. Zou WQ, Puoti G, Xiao X, et al. Variably protease-sensitive prionopathy: a new sporadic disease of the prion protein. *Ann Neurol* 2010;**68**:162-72.
5. Newman PK, Todd NV, Scoones D, et al. Postmortem findings in a case of variant Creutzfeldt-Jakob disease treated with intraventricular pentosan polysulfate. *J Neurol Neurosurg Psychiatry* 2014;**85**:921-4.
6. Haik S, Marcon G, Mallet A, et al. Doxycycline in Creutzfeldt-Jakob disease: a phase 2, randomised, double-blind, placebo-controlled trial. *Lancet Neurol* 2014;**13**:150-8.
7. Ghoshal N, Perry A, McKeel D, et al. Variably Protease-sensitive Prionopathy in an Apparent Cognitively Normal 93-Year-Old. *Alzheimer Dis Assoc Disord* 2014;10.1097/WAD.0000000000000049.
8. Head MW, Lowrie S, Chohan G, Knight R, Scoones DJ, Ironside JW. Variably protease-sensitive prionopathy in a PRNP codon 129 heterozygous UK patient with co-existing tau, alpha synuclein and Abeta pathology. *Acta Neuropathol* 2010;**120**:821-3.