Innovations in femoral tunnel positioning for anatomical ACL reconstruction

Joan Luites

Innovations in femoral tunnel positioning for anatomic ACL reconstruction

Proefschrift

ter verkrijging van de graad van doctor
aan de Radboud Universiteit Nijmegen
op gezag van de rector magnificus,
volgens besluit van het college van decanen
in het openbaar te verdedigen op vrijdag 22 april 2016
om 10.30 uur precies

door

Joanna Wilhelmina Henrica Luites

geboren op 24 september 1968
te Dreumel

Promotor
Prof. dr. ir. N.J.J. Verdonschot

Copromotor
Dr. A.B. Wymenga (Sint Maartenskliniek, Nijmegen)

Manuscriptcommissie
Prof. dr. C.J.H.M. van Laarhoven (voorzitter)
Prof. dr. R.L. Diercks (UMCG)
Prof. dr. ir. C.H. Slump (UT)

Paranimfen
Gemma Cornelissen
Marianne Braam

Het lijkt altijd onmogelijk, totdat het is gedaan
(Nelson Mandela)

Voor 's pap en 's mam
Raffi en Ezi

Reference Luites, J.W.H.
Innovations in femoral tunnel positioning for anatomic ACL reconstruction.
Thesis Radboud University Nijmegen, The Netherlands
With summary in Dutch- 244 p.

ISBN/EAN 978-94-6295-478-6
NUR-code 954-Biomedische technologie

Cover design Ezi, Raffi en Joan Luites
Layout Joan Luites (advies Seña Ontwerpers)
Printing Uitgeverij BOXPress || Proefschriftmaken.nl

The work presented in this thesis was carried out within the St. Maartenskliniek and the Radboud Institute for Health Sciences (*Orthopaedic Research Laboratory*) and partly funded by the OA Foundation.

The thesis was financially supported by
Stichting OrthoResearch, Nijmegen
Sint Maartenskliniek, Nijmegen
RMS Foundation, Switzerland
Annafonds|NOREF, Leiden
All sponsors are greatly acknowledged.

Electronic version https://nl.linkedin.com/in/joanluites

Innovations in femoral tunnel positioning for anatomical ACL reconstruction

Joan Luites

Contents

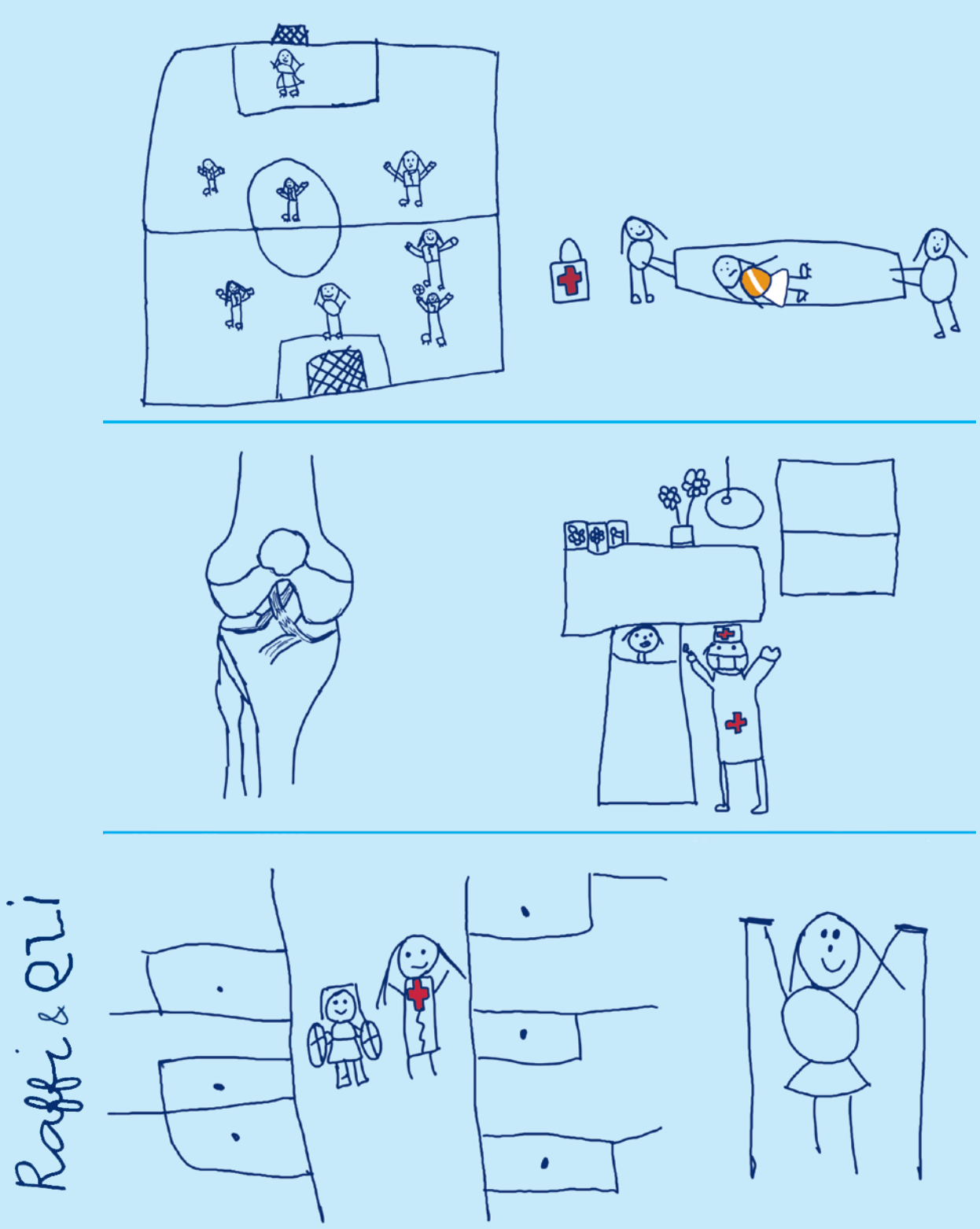
Raffi & Eli

CHAPTER 1

General introduction

General introduction

Considering the total published volume about the anterior cruciate ligament (ACL), one would think that all the secrets about this small structure in the knee have been revealed. However, frequently new studies are published with new information about an aspect of the ACL anatomy and its biomechanical functioning. These new data often stem from the evolution of new measurement and imaging techniques and the deepening of concepts of ACL reconstruction. This thesis is an additional contribution to enhance our knowledge about the anterior cruciate ligament.

In this chapter an extensive historical overview is provided of the various developments and stages that are associated with ACL reconstruction. In that historical context the research questions have been formulated which are presented at the end of this chapter.

BACKGROUND

History of ACL

The earliest texts about the cruciate ligaments date back to old Egyptian times when the structures were described in medical papyrus rolls, the Papyrus Smith (3000 BC) and Papyrus Ebers (1550 BC). Around 400 BC, Hippocrates (460–370 BC) described the results of ligament pathology, mentioning the subluxation of the knee joint [109]. A Greek physician in the Roman Empire, Claudius Galen (129-199 AD) was responsible for the naming, calling the structures "ligament genu cruciata". He developed the concept of the ligaments stabilizing the knee [82]. In 1836, the Weber brothers (an anatomist and a physicist) described in their "Mechanik der menschlichen Gehwerkzeuge" the different bundles and tension patterns of the cruciate ligaments after an anatomical and biomechanical transection study, animated with clear anatomical drawings (Figure 1) [264].

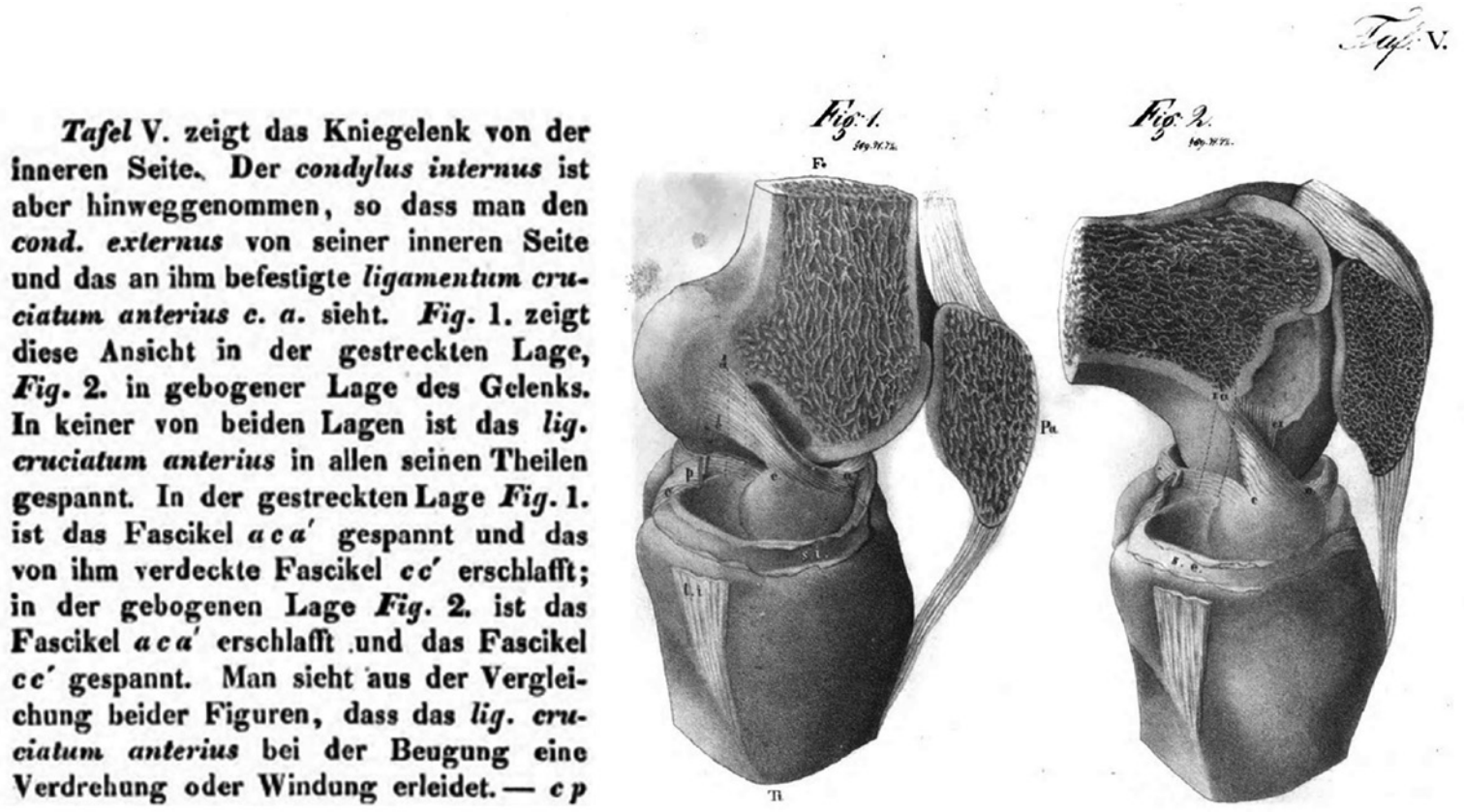

Tafel **V. zeigt das Kniegelenk von der inneren Seite. Der *condylus internus* ist aber hinweggenommen, so dass man den *cond. externus* von seiner inneren Seite und das an ihm befestigte *ligamentum cruciatum anterius c. a.* sieht. *Fig.* 1. zeigt diese Ansicht in der gestreckten Lage, *Fig.* 2. in gebogener Lage des Gelenks. In keiner von beiden Lagen ist das *lig. cruciatum anterius* in allen seinen Theilen gespannt. In der gestreckten Lage *Fig.* 1. ist das Fascikel *a c a′* gespannt und das von ihm verdeckte Fascikel *c c′* erschlafft; in der gebogenen Lage *Fig.* 2. ist das Fascikel *a c a′* erschlafft und das Fascikel *c c′* gespannt. Man sieht aus der Vergleichung beider Figuren, dass das *lig. cruciatum anterius* bei der Beugung eine Verdrehung oder Windung erleidet. — *c p***

Figure 1. Anatomical drawings and description of the anterior cruciate ligament from the Weber brothers. (From E&W Weber, 1836) [264]

Anatomy

The ACL is a ligament inside the knee joint consisting of multiple fascicles primarily made of collagen. The ligament is covered by a synovial fold, placing the intra-articular ligament extrasynovial [15]. As already described by the Weber brothers in 1837, the ACL consists of two functional bundles, which are named after their insertion area, with anteromedial (AM) and posterolateral (PL) fibers [15, 87]. The AM fibers run from the deep high insertion part at the femur to the anteromedial intercondylar area at the tibia. The fibers of the PL originate from the shallow low part of the femoral attachment area and insert posterolateral at the tibia (Figure 2). The AM fibers are mostly tightened in flexion, however, remain tensed throughout the whole range of knee motion, acting more or less isometrical; The fibers of the PL tighten at the lower flexion angles, near extension [10, 87, 234].

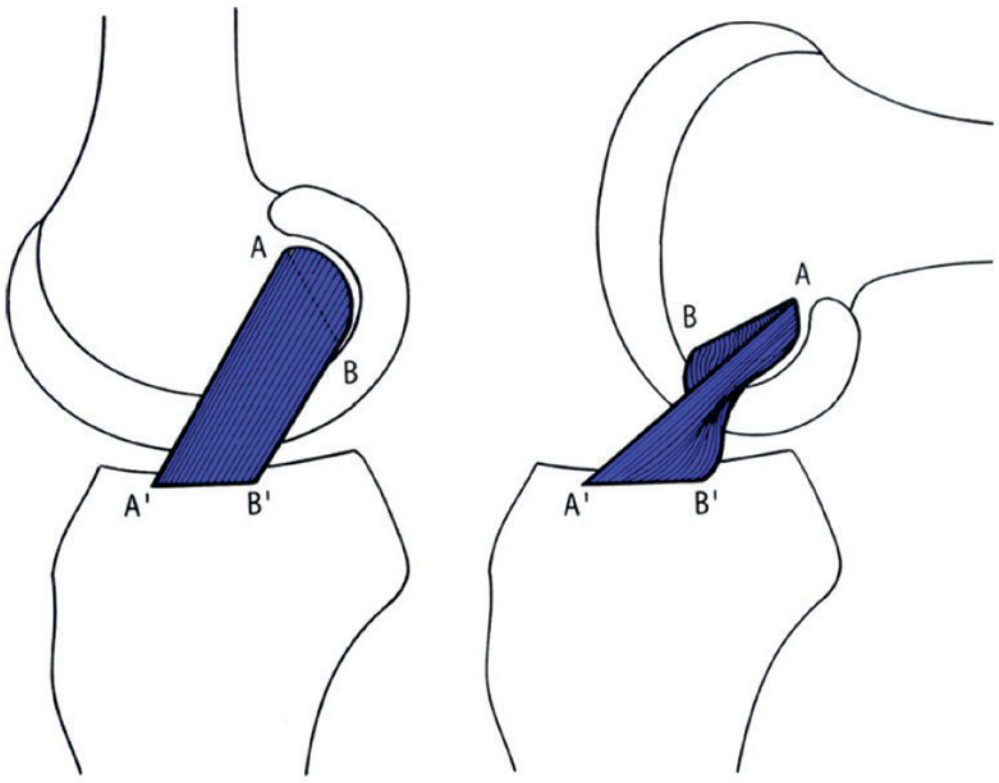

Figure 2. Schematic drawing of the two functional bundles of the ACL, with the AM fibers running from A-A', tensed in flexion, and the PL fibers from B-B', tensed in extension. (From Girgis, 1975) [87]

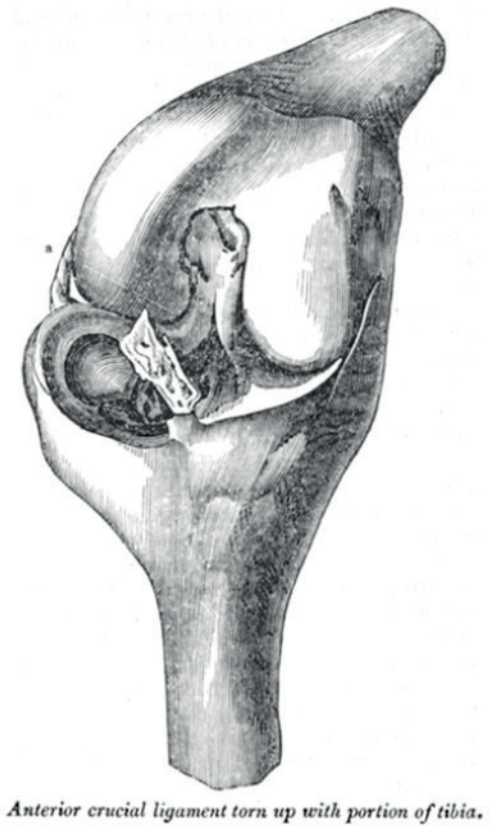

Figure 3. Drawing of an avulsion fracture of the cruciate ligament, observed by Adams in 1837. (From Adams, 1847) [1]

Biomechanics

The ACL is the primary stabilisator of the anterior displacement of the tibia and guides the screw-home mechanism associated with knee extension. The AM bundle is the major constraint for anterior tibial displacement of the flexed knee [109]. The PL bundle restrains anterior displacement near extension and prevents the tibia from rotating externally [160]. Together with the collateral ligaments of the knee, the ACL acts secondarily to prevent the knee from bending in varus or valgus, particularly in extension. The stabilizing role of the ACL is important in sports with cutting and turning movements and heavy physical loads.

Injury

In 1837, Adams described the first clinical case of ACL rupture (Figure 3) [1]. Bonnet published his findings about knee ligament injuries and its mechanism observed in cadaveric studies in 1845 [24]. The first author to mention several important clinical signs such as, giving-way, subluxation and audible snapping was Stark in 1850, reporting his findings on two clinical cases of ACL-ruptures [155].

Etiology

The ACL can rupture after impinging against de intercondylar notch roof through direct traumatic subluxation of the tibia, when the knee is forced into hyperextension beyond its normal limits [50]. In contact sports, the foot is usually planted and the impact causes knee hyperextension. However, 70% of the ACL ruptures, arises in non contact sports situations. The person is usually changing direction quickly, making a sudden stop or landing from a jump. The injured knee hyperextends and pivots at the same time, stressing the ACL and causing it to stretch and tear. High-risk sports include football, basketball, soccer and skiing. The use of cleats, shoes with studs like soccer boots, also increases the risk of an ACL injury.

Epidemiology

The ACL is one of the most commonly injured ligaments of the knee. Injuries occur predominantly in a young and sports-active population. Women are at higher risk of sustaining an ACL injury than men.[136] The number of ACL ruptures in the United States was estimated at 200,000 in 2006 [111]. The number of ACL reconstructions in the United States rose from 86,687 in 1994 to 129,836 in 2006, an increase of the incidence from 32.9 per 100,000 person-years to 43.5 per 100,000 person-years [106]. A decrease of inpatient settings, which amounted ca. 30% in 1997, and consequential an increase of outpatient treatment till ca 95% in 2006, was reported [104]. A Swedish database demonstrated an incidence of ACL injury of 78 per 100,000 persons, but showed that only 36% of these cases undergo ACL reconstruction [124]. A study from New Zealand demonstrated an incidence of ACL reconstruction of 36.9 per 100,000 person-years [57]. The exact number of ACL injuries in The Netherlands is not available, but an estimation around 8000-9000 ACL reconstructions has been published in 2012 [41].

Effects

The cruciate ligaments have negligible intrinsic healing capacity, caused by the synovial membrane that covers the ligaments. After a rupture the membrane closes around the ends of the ruptured ligament, which retract. Injury leads to instability and abnormal kinematics of the knee. Subluxation episodes occur, creating abnormal shear forces on the meniscus and articular cartilage. The incidence of subsequent meniscal injury is increased significantly [81]. Associated with this meniscal pathology is an increased incidence of osteoarthritis in knees with ACL tears [158].

Treatment

Conservative

ACL-deficient knees can be treated conservatively. In 1850, Stark reported the treatment of two patients with ligament injuries immobilizing the knee for 3 months with casts, followed by a 10 months use of a semi-rigid brace. However, neither patient regained entirely normal knee function [155]. Fisher (1933) was a promotor of conservative management to compensate the knee instability after ACL-injury [46]. He advized the combination of functional training, increasing the strength of leg and thigh muscles, with immobilization through an accurately fitting mechanical support. In his view, operations should be preserved for cases who suffer grave functional disability, despite active conservative treatment.

During the second half of the twentieth century, the surgical techniques evolved. Due to relatively high failure rates of conservative therapy and the rising expectations of patients, reconstructive surgical treatment gained more popularity. In 1983, Noyes published his 'rule of thirds' in an article about patients treated conservatively. He concluded that ''one-third of the patients with this injury will compensate adequately and be able to pursue recreational activities, one-third will be able to compensate but will have to give up significant activities, and the remaining one-third will do poorly and will probably require future reconstructive surgery" [125].

Repair

In 1895, Mayo Robson performed the first surgery to repair both cruciate ligaments of the knee in a 41-year-old mine worker after the diagnosis of ruptured ligaments through avulsion from their femoral attachments [114]. Since he published it only in 1903, it was not the first ACL repair reported. Battle published the successful results of a single case of open ACL repair with a silk suture in 1900, performed two years earlier during treatment for dislocation of the knee [18]. In 1913, Goetjes who studied ruptures of the cruciate ligaments in cadavers, advocated repair for the acute injury and conservative treatment for chronic cases after ACL ruptures [59]. Jones remarked in 1916 that stitching the ligaments is absolutely futile [84]. Jones' early observation was confirmed 60 years later by Feagin and Curl [43].

Although banned for a long time because of unsuccessful outcomes, ACL repair seems to have a new future nowadays, due to improved biological techniques as reported in studies using bio-enhanced ACL repair [137], tissue engineering [123] and techniques with cell source and growth factors [97].

Reconstruction

The third option besides conservative therapy or ACL repair is reconstruction of the ligament, with two options: placement of material outside the joint, extra-articular; or replacing material inside the joint, intra-articular.

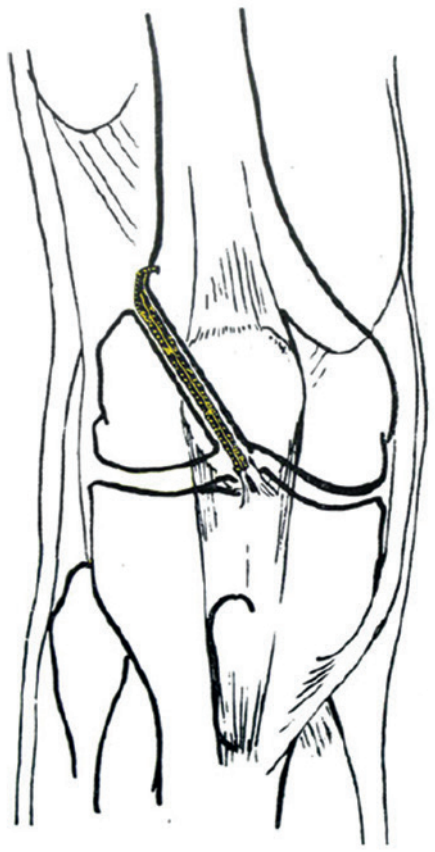

Figure 4. An extra-articular technique with silk structures placed trans-femorally to stabilize the knee with a torn ACL. (From Lange 1947) [95]

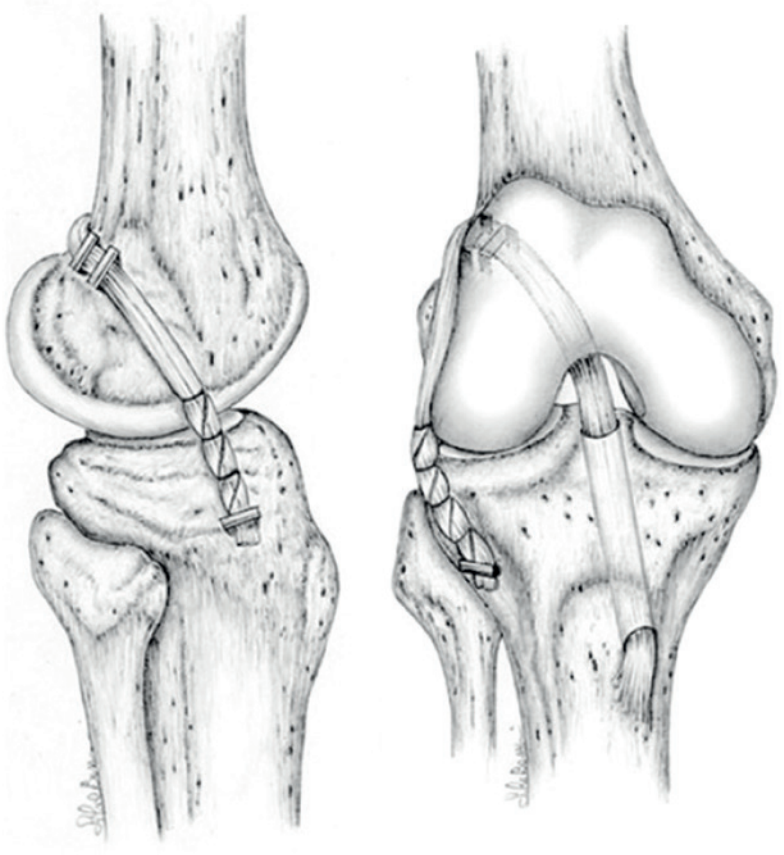

Figure 5. A combination of extra- and intra-articular reconstruction with double-strand hamstring graft. (From Marcacci 1998) [108]

Extra-articular

An ACL-insufficient, unstable knee can be stabilized without opening the joint by utilizing materials outside the knee joint. Fritz Lange was in 1907 the first to publish such an extra-articular procedure. He placed silk sutures across the joint space to treat knee instabilities (Figure 4) [95]. After Lange's publication, many different extra-articular techniques have been developed and tested. Most additional extra-articular procedures had vanished by the end of 1990s, however some surgeons still use an extra-articular reconstruction, mostly in combination with an intra-articular technique (Figure 5) [108, 149, 168]. The extra-articular lateral plasty is placed with the aim of achieving an optimal control of translational and rotational knee laxity, protecting overloads on the new ACL graft and improve outcomes.

Intra-articular

In an intra-articular ACL reconstruction, a torn ACL is replaced by a substitution, a graft fixated in tibial and/or femoral tunnels during a reconstruction. The first cruciate ligaments reconstruction was performed in 1913 by the Russian surgeon Grekow in St Petersburg and published by Hesse, his surgical assistant [69]. He reconstructed both ruptured cruciate ligaments with free grafts from fascia latae tissue which was dissected from its anatomic position and routed through femoral drill holes, stitched against the ligament remnants on the tibia. In 1917, Hey Groves published the first complete ACL reconstruction. He detached a strip of fascia lata from its tibial insertion, leaving the proximal ending attached to the muscle belly to maintain blood supply and nutrition and directed it through tunnels in femur and tibia (Figure 6) [71]. Later, he modified his technique by leaving the graft attached to the tibia and detaching it superiorly (Figure 7) [72]. Many methods, techniques and concepts have passed in ACL history, which spans more than a century.

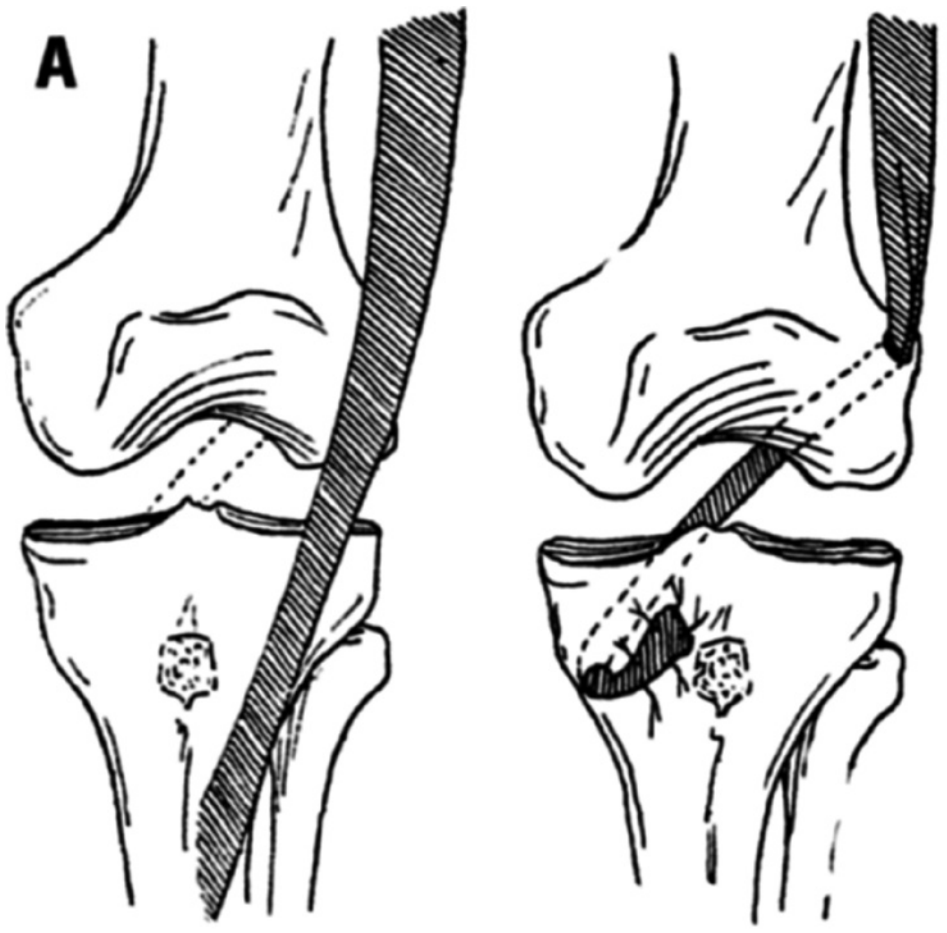

Figure 6. Original Hey Groves ACL reconstruction technique with detached and rerouted tibial insertion of the fascia lata. (From Hey Groves 1917) [71]

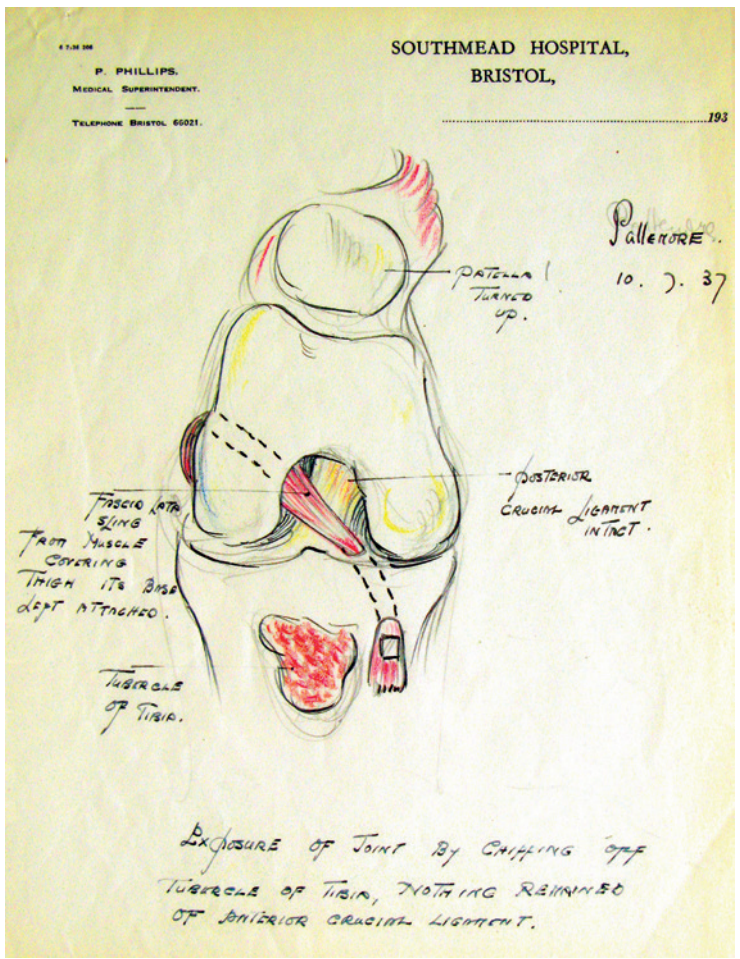

Figure 7. Original drawing by Hey Groves (1937) showing the revised technique of using proximally detached pedicled fascia lata. (From Schindler 2012) [147]

Arthroscopic reconstruction

During the first 80 years of ACL surgery, the knee joint was usually opened with a large incision along the knee joint, an open arthrotomy, to get full access to the intercondylar notch. However, the evolution of arthroscopic techniques started from the beginning of the twentieth century. The first physician to use an endoscope to take a look inside the knee joint was Nordentoft who presented his findings in 1912 at the 41st Congress of the German Surgical Society in Berlin [87]. He called the procedure an arthroscopy; Arthro means joint and scope to view from the Greek root. In 1918, Takagi, 'father of arthroscopy', performed his first arthroscopy [129]. Later, in 1931, he created 12 different arthroscopes, with varying angles of view, along with operative instruments small enough to perform rudimentary surgery, such as biopsy within the knee joint. Bircher published the first articles regarding clinical arthroscopy of the knee in 1921, referring to this technique as arthroendoscopy (Figure 8) [88].

Figure 8. A knee surgery performed with an arthroscopy by Dr. Bircher in 1917 with the joint filled up with gas. (From: Kieser 2003)

In 1931, Michael Burman performed the first arthroscopic procedures. He used an arthroscopic instrument, built by Wappler (New York), to directly visualize joints of cadaveric specimens. He was the first to publish colored pictures of arthroscopic findings of joints in a medical journal (artist: Frieda Erfurt, Dresden Institute) [29].

During the 50s some studies, Zappala in 1953, König in 1955 and Li in 1958, reported ACL reconstructions without opening of the knee joint [147]. The ACL was reconstructed with a trans-articular reconstruction, positioned either relying on anatomical landmarks or on radiographic control and guidance for tibial and femoral tunnel positioning (Figure 9).

In 1959, Watanabe, protégé of Takagi, established himself as the 'father of modern arthroscopy'. He developed sophisticated instruments using electronics and optics, his 'No. 21 arthroscope' became a model for production (Figure 10). In 1962, he performed the first arthroscopic partial meniscectomy [129].

The development of fiber optics and the use of television technology in the 70s gave a boost to the surgical arthroscopy. Fiber optic light cables improved visibility and the television monitor

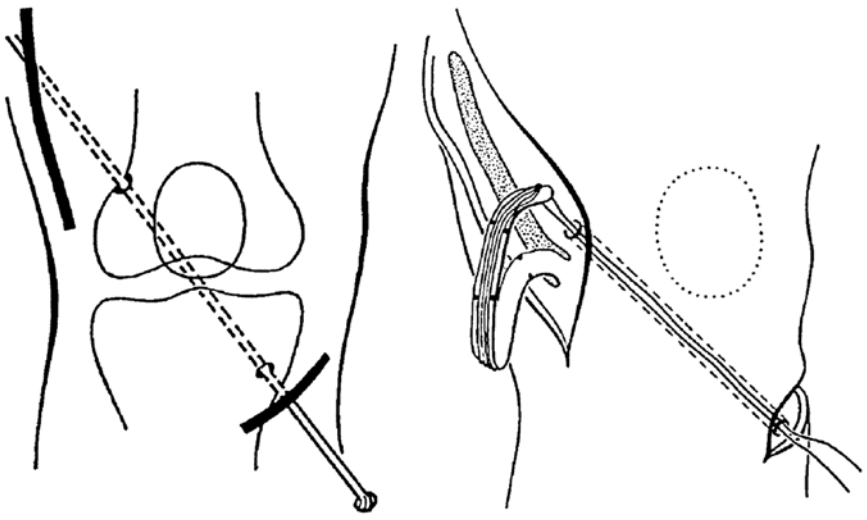

Figure 9. A transarticular ACL reconstruction without femoral joint arthrotomy as devised by König in 1955. (From Schindler 2012) [147]



Figure 10. The 'No 21 arthroscope' developed by Watanabe. (From Paessler 2012) [129]

allowed surgeons to view the image on a screen. These developments facilitated procedures as ligament reconstruction with minimally invasive techniques. In 1980, Dandy performed the first arthroscopically assisted ACL reconstruction [38]. As arthroscopic technology advanced, this 'keyhole surgical technique' became within reach for all surgeons. The benefits of the arthroscopic techniques over open techniques are expressed in reduced post-operative morbidity, improved cosmetics, increased speed of recovery and enhanced range of motion [25]. During the 90s, arthroscopic ACL reconstruction became the preferred method of surgical treatment over conventional, 'old-fashioned' procedures.

Initially, two incisions were made during the procedure. Through the first incision, the graft is harvested and the tibial tunnel prepared [67]. With the second incision the femoral tunnel could be drilled from outside-in using a 'rear-entry guide' [2]. Later, new devices were introduced, allowing the femoral tunnel to be drilled from inside-out through the tibial tunnel, making a second incision unnecessary [14, 107, 116]. During the nineties, single-incision endoscopic ACL reconstruction became the standard [66].

Graft

Besides the surgery technique, the most important aspects for ACL reconstruction concern the graft: selection, fixation and positioning.

Graft selection

Various tissues and materials have been used to serve as replacement of the anterior cruciate ligament. Four main choices for graft tissue can be made: allograft, autograft, xenograft or synthetic material.

Allograft

In allograft ligament reconstructions, autologous tissue from the patient is used as graft material. In the first reconstructions, the fascia latae (ilio-tibial band) and menisci have been used as graft material. Grekow used free grafts [69], where Hey Groves detached only one ending, rerouting it [71]. In 1917, Zur Verth replaced the ACL with the torn lateral meniscus, which he left attached distally, and sutured against the ligament remnants proximally [75]. Knowledge of the role of the meniscus in the force transmission across the joint, abandoned it as grafting material in the same period. Reconstructions with the ilio-tibial band technique are rarely used in the contemporary ACL reconstruction, the last bulk of published surgery with this graft dates from the 1980s [78].

In 1928, Ernst Gold, used a distally based strip of extensor retinaculum and patellar tendon to reconstruct the ACL of a 27 year old lady, which was torn during skiing [60]. Jones introduced in 1963 a technique using the central third of the patellar tendon, with proximal a triangular bone block of the superficial one-half of the patella [82]. At the distal end, the tendon remained attached, the proximal end was pulled into the femoral drill hole, until it was fixated tightly in the canal (Figure 11). Jones's technique gained widespread popularity, particularly in the United States and reconstruction of the ACL with patellar tendon graft became known as the 'Jones procedure'. Because of the insufficient length of the pedicled patellar tendon graft, Jones moved the attachment of the graft forward within the roof of the intercondylar notch. This resulted in an non-anatomical, vertical graft position.

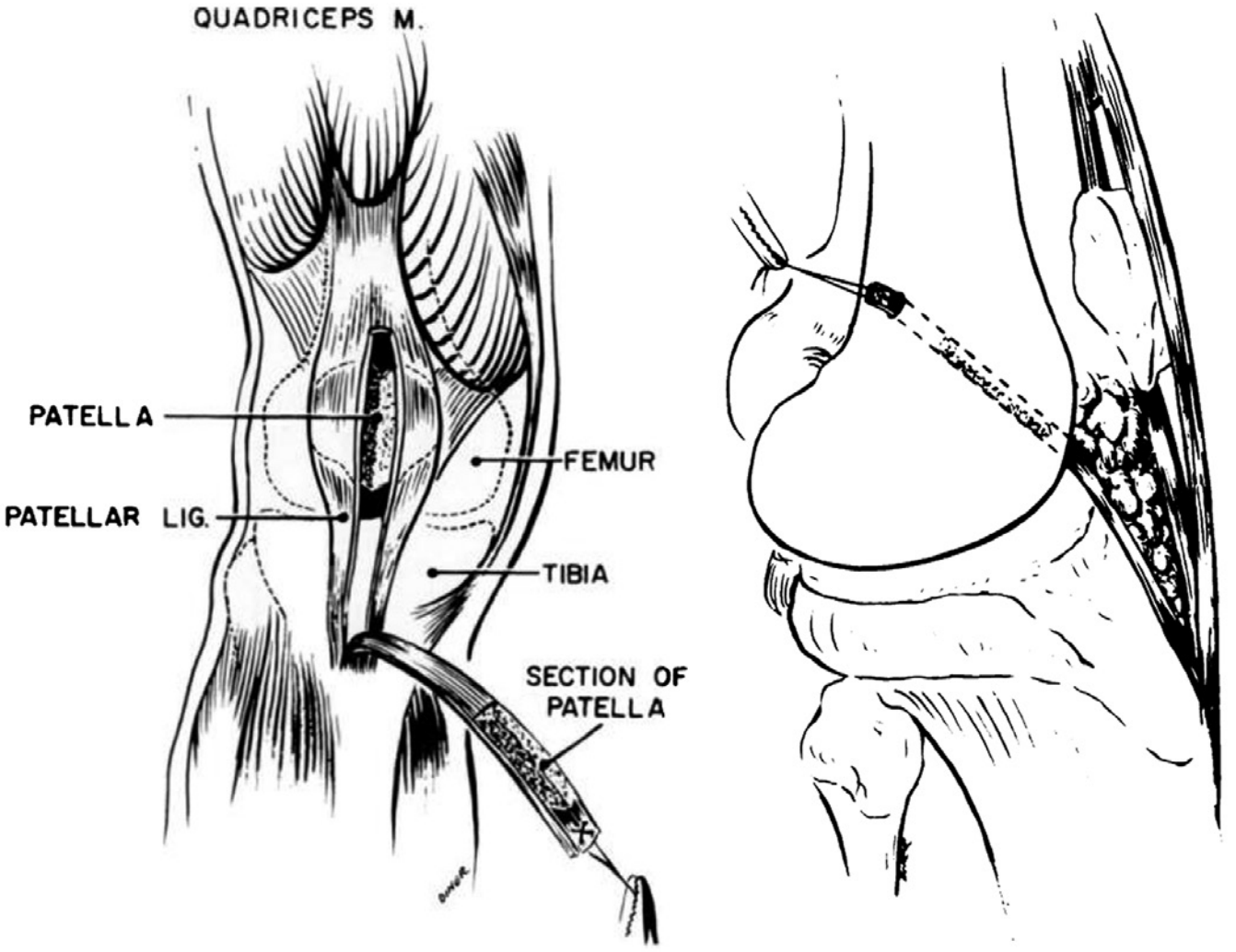

Figure 11. Left: The middle one third of the patellar tendon is detached proximally with the patellar bone. Right: The new ligament is pulled through the drill hole, locating the patellar bone in the femoral tunnel. (From Jones 1963) [82]

Brückner adapted Jones' technique with the patellar tendon. However, he rerouted the distal part through a tibial tunnel, resulting in more length to reach the anatomical position on the femur [27]. As an alternative technique Brückner recommended the use of a free central strip of bone-patellar tendon-bone graft (B-PT-B). This technique was later reported by Artmann and Wirth and in the 1980s by Clancy [13, 32]. By the end of the 1990s the patellar tendon had become the most popular graft source in ACL surgery.

Some surgeons started to experiment with alternative sources, due to the potential morbidity associated with harvesting the patellar tendon. The Quadriceps tendon was first used in the seventies by England and Marshall [42, 110], but despite the publications of Blauth and Staübli [23, 156], it did not became as popular as the patellar tendon and hamstrings.

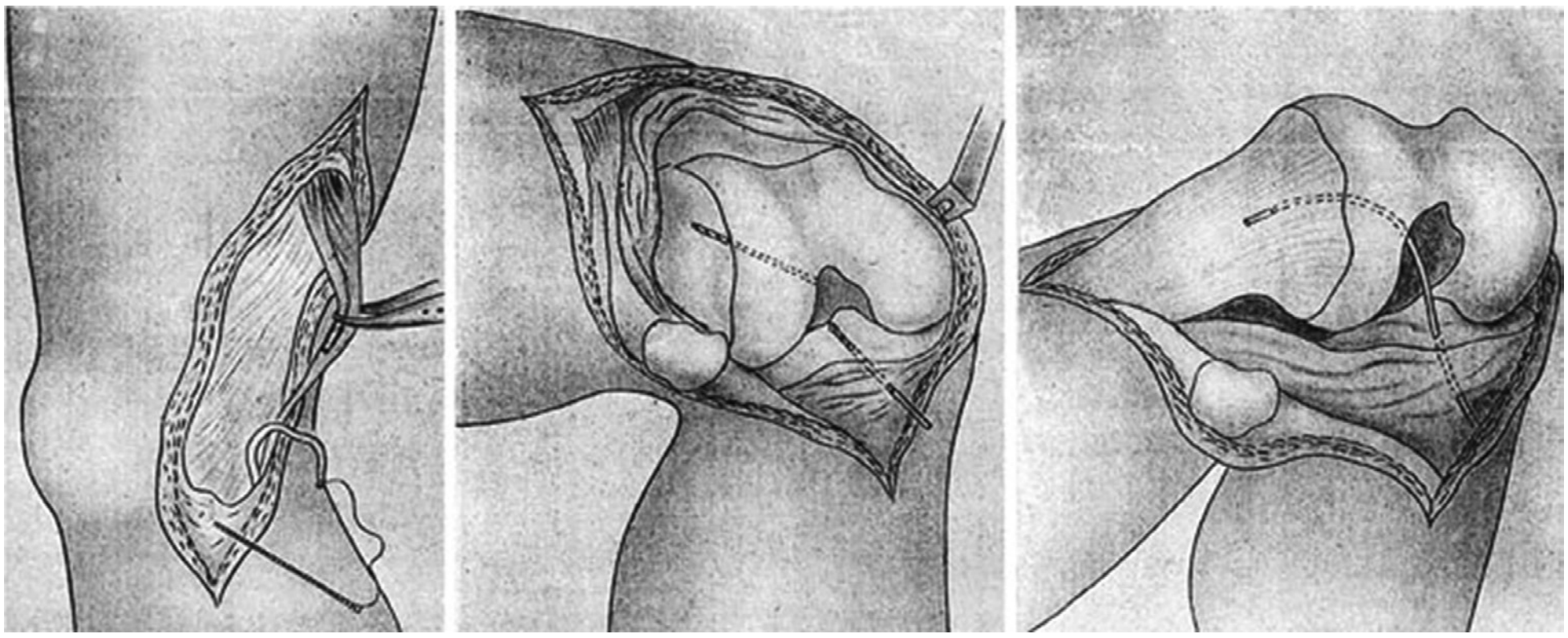

Figure 12. The original drawings of Galeazzi showing the reconstruction of the ACL with the use of the semitendinosus tendon. (From Schindler, 2012) [147]

Galeazzi (1934) was the first to us the hamstrings as a graft in his anatomical ACL reconstruction with the semitendinosus tendon being left attached distally at the pes anserinus (Figure 12) [44]. In the late eighties, Friedman reported a technique with the four-strand hamstring reconstruction, which became the standard for ACL reconstruction with hamstrings in the next 25 years [49].

Allograft

Besides autologous material, tissue from other humans, homogenous tendon tissue, has been used for ACL reconstruction. The use of allografts avoids the need of graft harvest and associated donor site morbidity and prevents weakening of external ligament and tendon structures which contribute to overall joint stability. In 1986, Shino published as one of the first, the clinical results of 31 patients who had received allogenic reconstruction of the ACL utilizing mainly anterior tibial and calcaneal tendon grafts [151]. The increased risk of viral disease transmission (e.g. HIV, Hepatitis C) associated with allografts in the 1990s created a significant setback for this technology.

Xenograft

In 1929, Eugene Bircher, also known for his pioneering work on arthroscopy, used kangaroo tendon as an augment as well as a sole graft. Kangaroo tendon, like other xenografts, never gained any real popularity [88].

Synthetics

From the early days of ACL reconstruction, surgeons experimented with synthetic materials to replace injured ligaments. The extra–articularly placed reconstructions from Lange (1907) intended to stabilize ‘wobbly knees’, were made of silk, augmented with hamstrings tendons [95]. Various materials are used after that, from silver wire (Figure 13) [36] to products as Teflon® made of carbon in the 1970s, followed by LAD®, Dacron and Gore-Tex® in the 80s and 90s [96]. The enthusiasm about the artificial ligaments was initiated by positive effects as lack of harvest site pathology, their abundant supply and significant strength, the technically easier surgical technique and the shorter rehabilitation period. However, some synthetic fibers failed to survive the experimental studies due to their unsuitable mechanical properties, others were used as a biological ACL graft substitute but presented serious drawbacks: cross-infections, immunological responses, breakage, debris dispersion, leading to synovitis, chronic effusions, recurrent instability and knee osteoarthritis [96]. Research in the field of artificial ligaments resulted in the conclusion that these materials should combine biocompatibility with mechanical characteristics, which mimic the natural ligament. This means a substitute material providing a functional and biologically valid ACL, able to promote a continuous tissue remodeling. A concept which touches the current new tissue engineering techniques trying to repair a torn ACL [123].

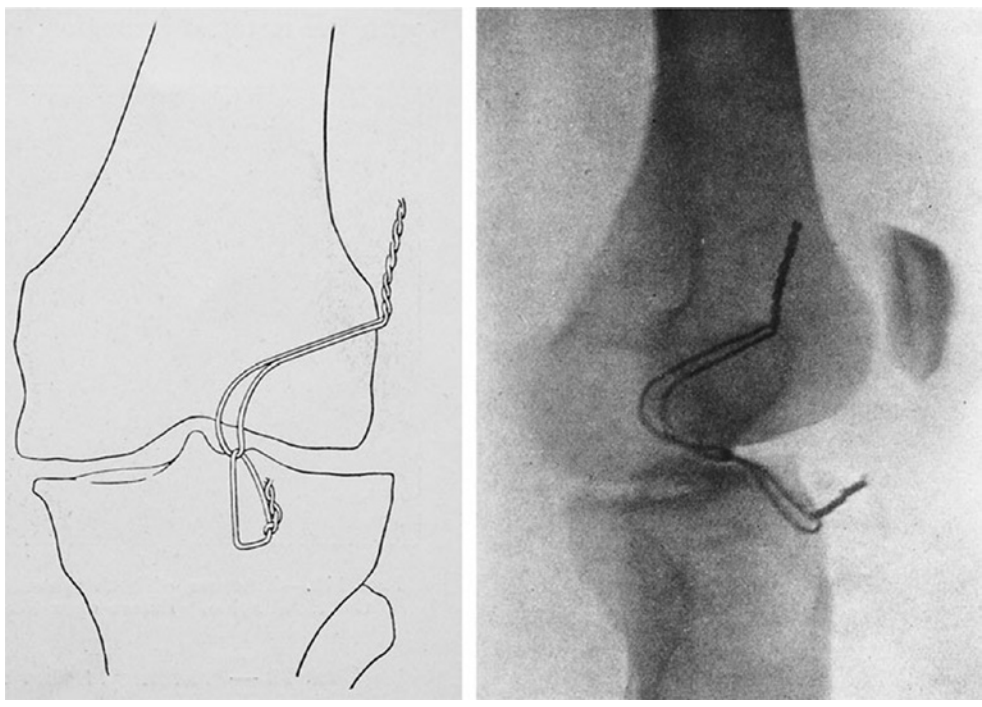

Figure 13. The knee with ACL replaced by an artificial Silk wire graft. (From Corner, 1914) [36]

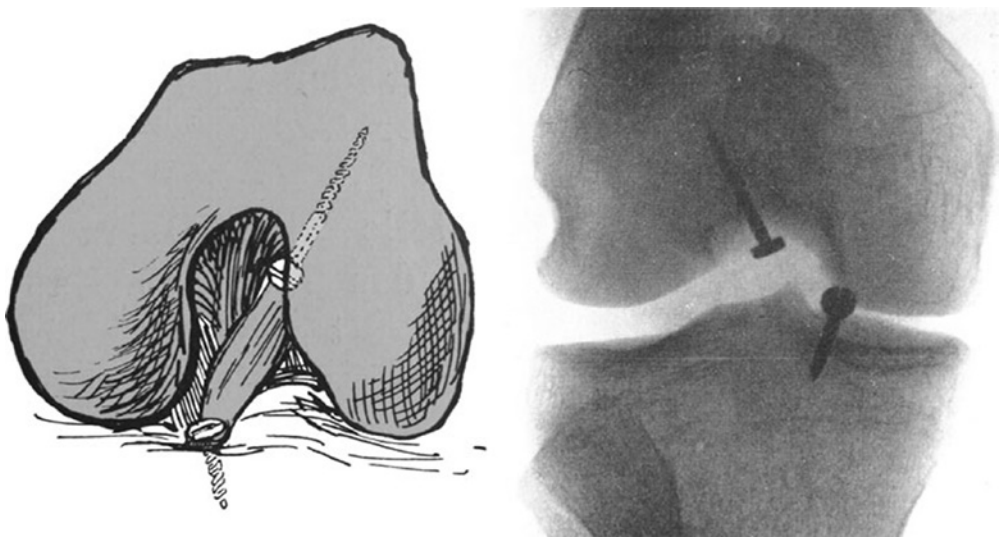

Figure 14. Screw fixation of a meniscal ACL graft. (From Wittek, 1927) [164]

Graft fixation

Various methods to fixate the graft material have been proposed. In the beginning of the ACL reconstructions the protruding parts of the graft were simple sutured to the periosteum at the tunnel exits. In 1927, Wittek replaced the ACL with a torn medial meniscus, fixating it with intra-articular screws (Figure 14) [164].

Albee (1943) suggested a more secure fixation of free fascia grafts with small bone wedges harvested from the anterior tibia and driven alongside the tendon into the tunnel (Figure 15) [5]. The combination of sutures and a bone block was applied by Jones in his technique using the mid third of the patellar tendon including the proximal bone block as a graft [82]. Distally, the tendon remained attached to the bone; the proximal portion with chromic sutures was pulled into the femoral drill hole, where the wedged bone block fixated the graft. The sutures, mentioned as 'probably unnecessary', were secured through the periosteum (Figure 11). Although Jones noticed that supplementary fixation to secure the bone graft in the tunnel was not really necessary, he adapted this fixating technique, by drilling a Kirschner wire across the femoral tunnel into the opposite femoral condyle (Figure 16) [83].

Bruckner (1966), who adapted the method of Jones, used bone blocks proximally and distally in the femoral and tibial tunnel, the bone-patellar tendon-bone (BPB, Figure 17) [27]. In 1983, Lambert published another modification of the Bruckner method, twisting the graft 180° and fixating the bone blocks with 30 mm A-O cancellous screws producing 'an interference fit whereby it actually engages both the side of the bone block and the screw hole in a more or less cogwheel fashion' (Figure 18) [94].

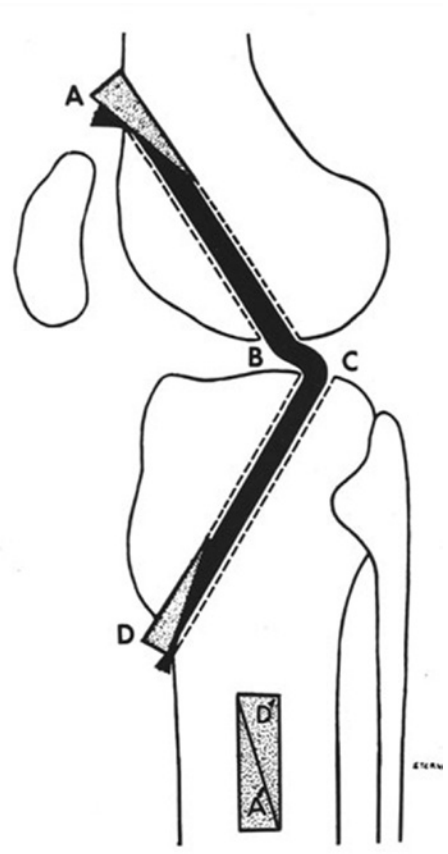

Figure 15. Fixation of the ACL graft with bone wedges from the tibia. (From Albee, 1943) [5]

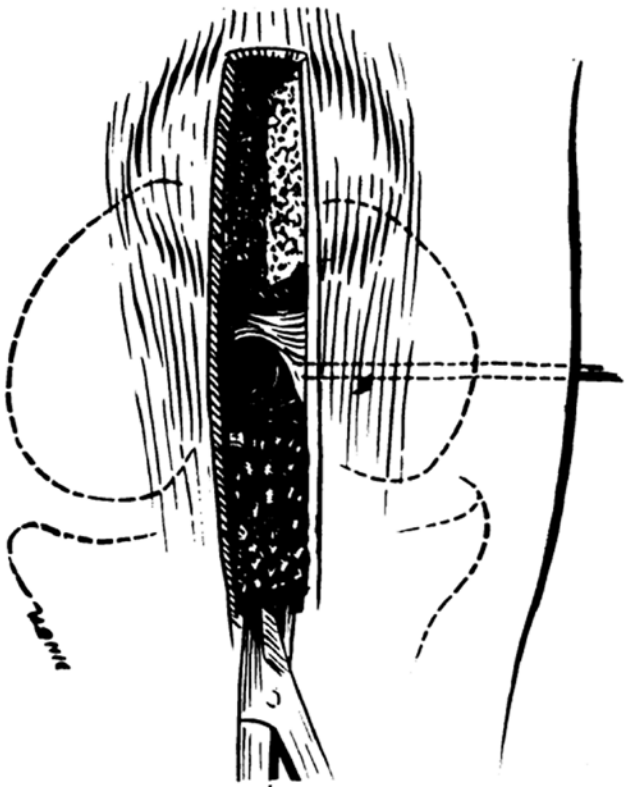

Figure 16. Supplementary fixation with a Kirschner wire. (From Jones 1970) [83]

The interference screws were initially made of metal and later of biodegradable materials [154]. These screws were not only used in grafts with bone blocks, but also with hamstring tendon grafts. Various other methods have been developed to fixate Hamstrings grafts, like staples, endobuttons, cross-pin fixation and washers (Figure 19) [112]. Bone staples, already used in orthopedic surgery since 1906, compress the tendons against the tibial bone [15, 56]. The Endobutton®, a titanium button to which the graft is connected through sutures, was originally developed for hamstring grafts in 1994 by Graf and colleagues [61], but later re-adapted to accommodate other graft materials. The idea of Jones (1970) with a cross-pin fixation was elaborated by Wolf introducing the Transfix® device for hamstring grafts [166, 167] Washers have a large number of short and a few long spikes penetrating the soft tissue graft in multiple locations. A cancellous screw is used to compress the washer against the soft tissue graft and tibial bone [105, 113].

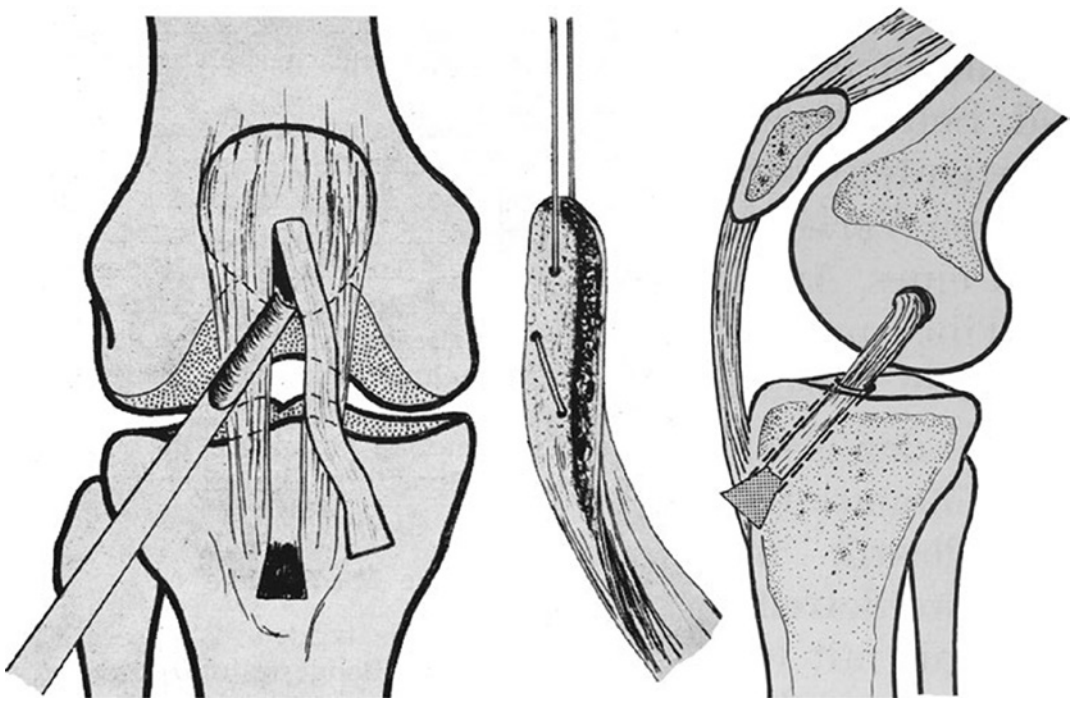

Figure 17. Press fit technique of the BPB at the tibial site and sutures at the femoral site. (From Brückner 1966) [27]

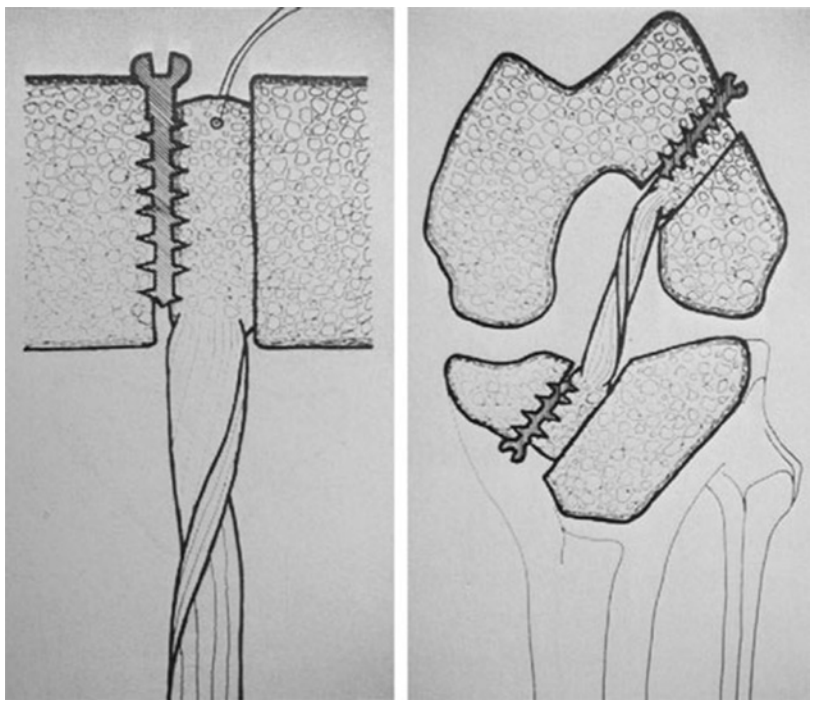

Figure 18. The BPB is twisted 180° and the bone blocks are fixated with cancellous screws. (From Lambert, 1983) [94]

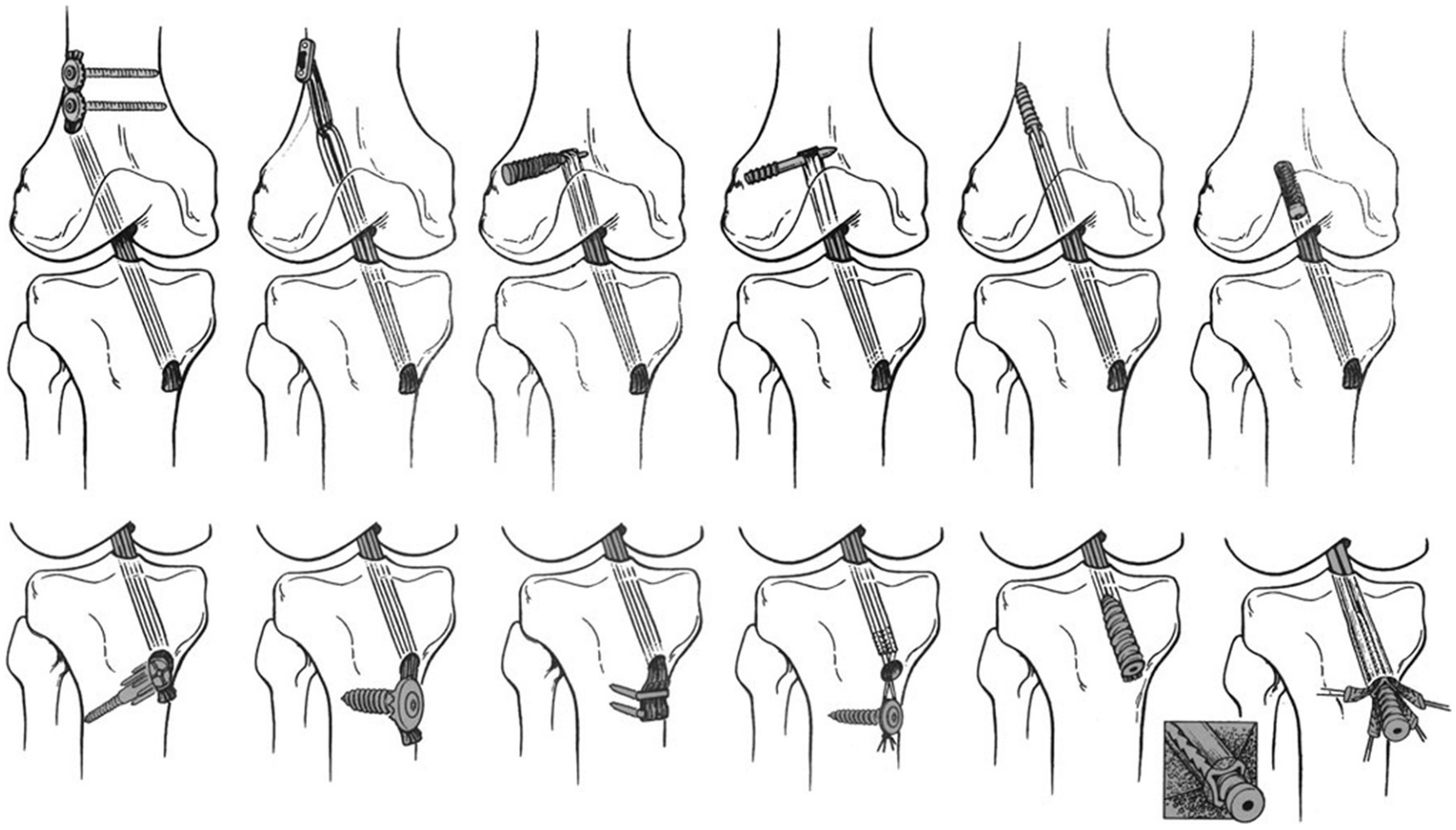

Figure 19. Upper row, femoral graft fixation methods for Hamstring grafts from left to right: (A) Two 13.5 mm x 4.0 mm AO plastic spiked washers. (B) EndoButton (Smith and Nephew Inc, Andover, MA). (C) TransFix (Arthrex Corp, Naples, FL). (D) Crosspin (Semifix, Arthrex, Naples, FL). (E) LinX HT polymer fastener. (F) Interference screw.
Lower row, tibial fixation methods for Hamstring grafts from left to right:(A) Two 13.5 mm x 4.0 mm AO plastic spiked washers. (B) Washerloc. (C) Seventeen-millimeter plastic spiked ligament washer with 9mm x 25mmunicortical fixation screw. (D) Two barbed ligament staples. (E) Sutures tied around a 9mm x 25mm unicortical fixation post and metal washer. (F) Nine millimeter x 28 mm biointerference screw. (G) Intrafix device. (From Martin 2002) [112]

Graft positions

Already in the beginning of the history of the ACL reconstruction, Hey Groves was aware that proper knee joint function could only be re-established if the reconstructed ligament graft would be placed in the exact anatomic position of the original ACL [72]. Surgeons who used his technique, like Palmer in the 1930s [130], tried to place the graft material at the original attachment sites. Some reconstruction techniques, however, like Jones' procedure with the central third of the patellar tendon, resulted in non-anatomic graft placement [82]. On the other hand, the concept of 'isometry' (as little length change of the graft as possible during the whole range of motion), has been present from the beginning of the ACL reconstruction surgery.

Isometrical reconstruction

In 1911, Rudolf Fick described the tension pattern of the two ACL bundles, with the 'upper medial bundle' being tightest in extension and the 'lower lateral bundle' tightest in flexion. He also noticed that some ACL fibers are tensioned over the complete range of motion [45].
Cowan reported in 1963 that it would be difficult to produce a new ligament with the complexity of the normal anatomical arrangement of the ACL [37]. A single tubular graft composed of parallel fibers could not reproduce both ACL bundles and their tension patterns. He described some modification of the Jones technique (1963) placing the femoral drill hole so that the substitute ligament remains firm throughout the full range of flexion and extension and does not limit this range (Figure 20). In 1968, Lam repeated this criterion, mentioning that Cowan used a dental scaler to determine the point in the intercondylar notch which remained equidistant from the tibial tuberosity in all positions of the knee, during knee movement over the full

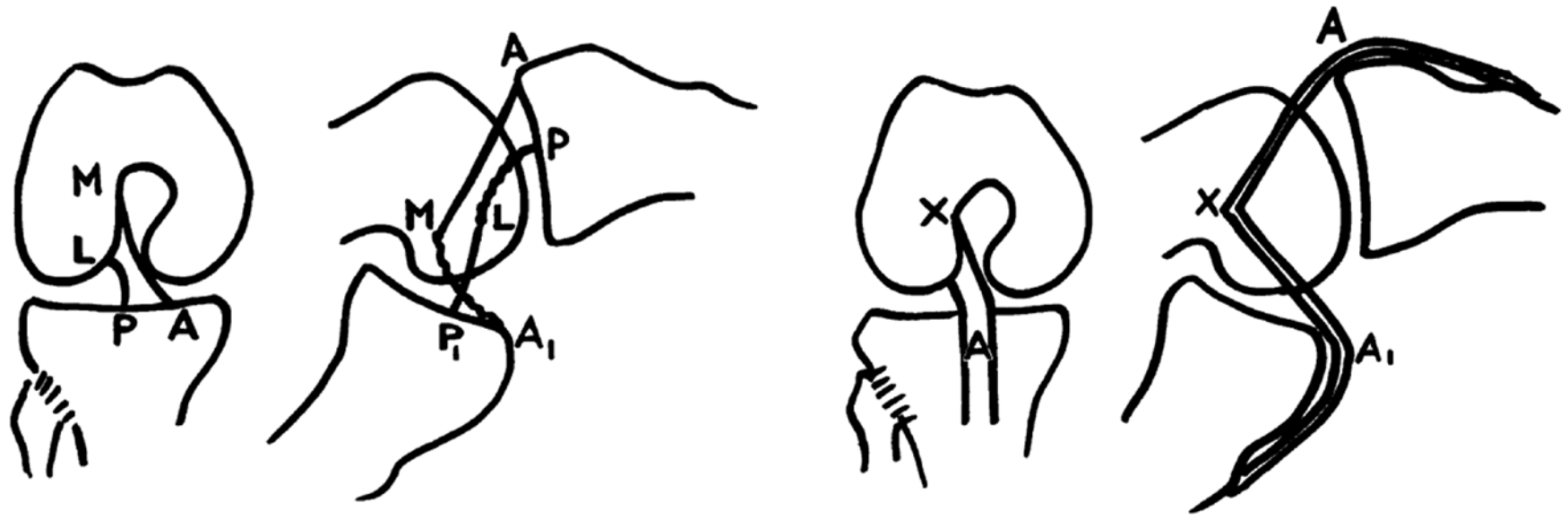

Figure 20. Left: The normal arrangement of the fibers of the ACL, A-M anteromedial fibers and P-L posterolateral fibers. Right: The ACL reconstruction, with the middle third of the patella ligament replacing the more isometric behaving AM fibers of the ACL (A1-X), X is the drill hole in the lateral femoral condyle. (From Cowan 1963) [37]

range of motion [93]. He recommended outside-in drilling with a special drill guide preventing damage to the femoral articular cartilage.

In 1974, Artmann and Wirth performed an experimental study, defining isometric points within the femoral ACL attachment [13]. The posterior-superior part of the anatomic footprint, close to the 'over-the-top' position, showed no change in distance between the femoral and tibial attachment. They stated that the 'antero-tibial cruciate fibers are particularly suited for the replacement, since they remain constant under tension'. Constructions at different positions will have variable tensioning patterns, producing graft loosening or tightening and resulting in remaining knee instability or new graft rupture (Figure 21).

Hewson (1983) noticed that accurate determination of the location of the femoral tunnel is a major factor in the success or failure of the ACL substitute [70]. He advocated the isometric position, 'posterior, superior and medial', as the ideal location at which the length and tension in the substitute were constant through the full range of motion resulting in nearly uniform tension (Figure 22).

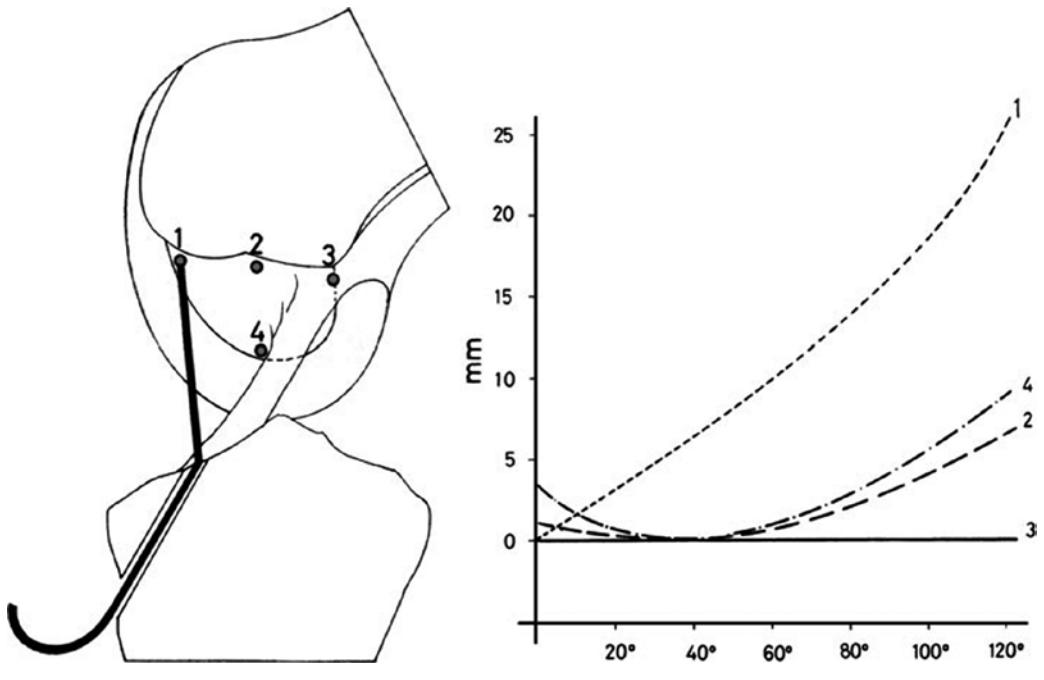

Figure 21. Left: The graft has been fixated at various positions in the notch. Right: The diagram shows the displacement of the grafts during movement over the full range of motion (0° represents full extension). Position 3, at the posterior-superior part of the anatomic footprint, results in isometric behavior of the graft. (From Artmann and Wirth, 1974) [13]

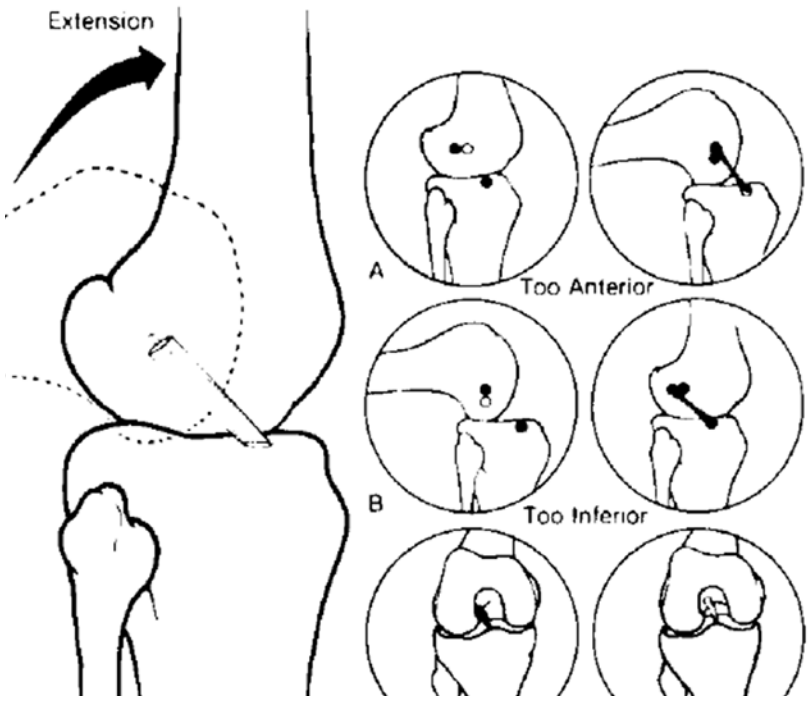

Figure 22. The ideal location of the femoral tunnel is the isometric position. A, too anterior results in limited flexion. B: too inferior results in limited extension. C, too lateral results in impingement of lateral femoral condyle. D, Ideal location is posterior, superior and medial. (From Hewson, 1983) [70]

The importance of the concept of isometricity was confirmed by Odensten en Gillquist (1985) [126]; They found that the distance between the central points of the normal attachment areas of the ACL was isometric during flexion and extension.

Through studies like these [70, 126, 131], isometric placement of the graft became a new goal in ACL reconstruction at the end of the 1980s. Studies reported the larger influence on isometry from femoral tunnel placement variations than tibial tunnel positions [35]. From then onwards, the quest to determine the femoral isometric position(s) intensified. Although Hewson and Odensten & Gillquist reported the centers of the anatomical insertions as the isometric position [70, 127], other studies determined various isometric points and zones [22, 30, 48, 68, 152].

In the proceedings of the 1993 ESSKA Scientific Workshop on Reconstruction of the Anterior and Posterior Cruciate Ligaments [6], composed by various leading European surgeons, the isometric spot in the intact knee was defined as situated at the anteroproximal corner of the ACL femoral attachment, close to the junction of the wall and roof of the intercondylar notch at the 'over the top' position. In this region the fibers of the AM bundle attach. The guidelines recommended the graft to be positioned posterior and distal, but still covering the most isometric area. The preferred location of the graft was within the normal anatomical insertion of the ACL.

The development of the arthroscopic ACL reconstruction technique in that period contributed to isometric graft placement. Since the arthroscopic view is limited, technical restrictions determined the tunnel placement concept. This resulted in positioning tunnels at sites with as little change of the graft as possible during the whole range of motion, without blow-out of the posterior notch wall. Various surgical devices have been developed to facilitate isometric femoral tunnel placement, like arthroscopic drill [127] and off-set guides [107, 116] and tension isometers [141]. These devices supported isometric placement, although McGuire claims that his off-set guide results in anatomical placement. The endoscopic femoral aimer drill guides allowed for femoral tunnel preparation through the tibial tunnel (transtibial) making a second incision unnecessary, thereby decreasing the morbidity. During the nineties this surgical technique was adopted as the golden standard.

Anatomical reconstruction

Hey Groves' intention in the beginning of the 20th century with his reconstruction technique was obviously a replacement at the anatomical insertions sites [71]. Palmer emphasized in 1938, the importance of precise graft placement at the native attachment site, developing his own drill guide to achieve accurate anatomical placement during the open surgical technique [130]. During the evolution of arthroscopically techniques, the anatomical concept has been overwhelmed by the isometric concept, which came at full glory during the nineties, influenced by what was technically achievable.

However, some surgeons remained advocating the concept of anatomical graft placement [32, 33] and was vivid [8, 9, 21]. At the turn of the century, the revival of anatomical tunnel placement became clear [20, 52].

Double-bundle reconstruction

Already in 1927, Ludloff reported that ''reconstitution of relatively normal function would require the new cruciate ligament to consist of two separate bundles'' [103]. Palmer performed

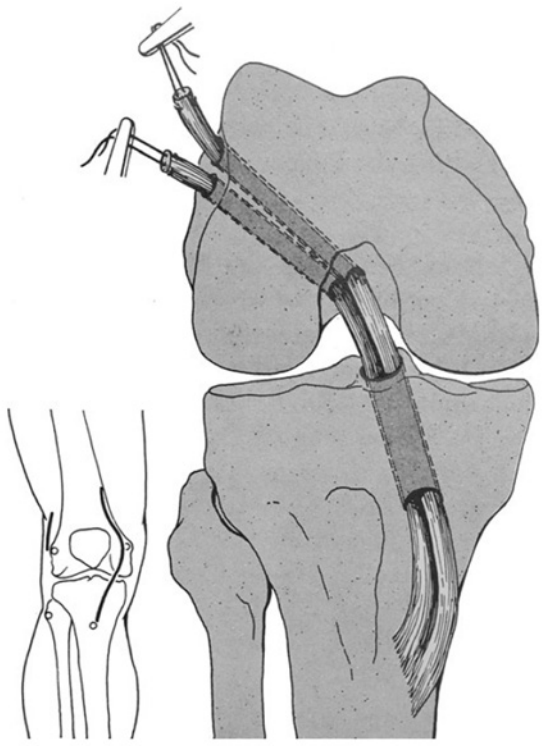

Figure 23. The double-bundle technique according to Viernstein & Keyl. (From Vierstein and Keyl, 1973) [162]

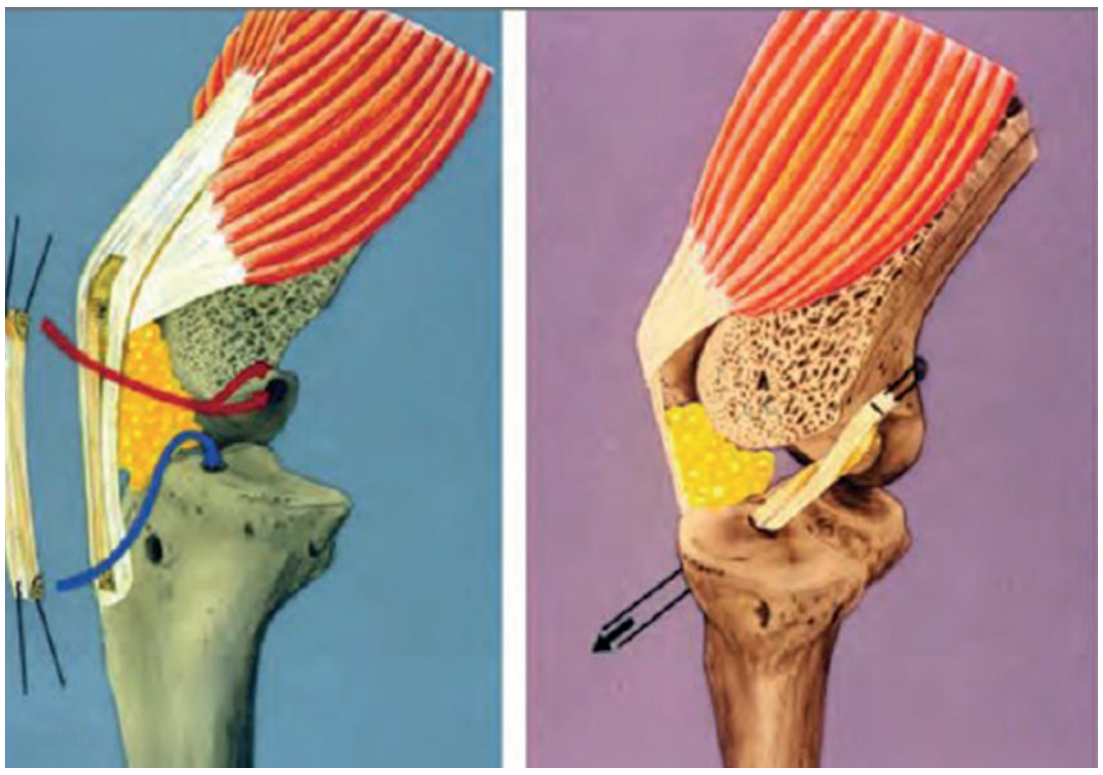

Figure 24. Two bundle anatomometric graft according to Müller [119], combining the isometrical principle with anatomical placement. (From Schindler, 2012) [148]

double-bundle ACL repairs in the 30s, but his concept had no followers [147]. In 1973, Viernstein en Keyl experimented with double-bundle ACL reconstruction using proximally detached semidendinosus and gracilis graft [162]. The tendons were routed through a single tibial tunnel into two separate femoral tunnels and sutured against each other at the exit (Figure 23). The femoral tunnels were placed close to the anatomic foot prints of the native ACL bundles, mimicking the natural twisting between the two graft bundles during flexion.

From 1978 onwards, Mott started with his STAR procedure in patients, often referred to as the ‘‘semitendinosus anatomic reconstruction’’ [118]. He placed a free semitendinosus graft through double tunnels in tibia an femur during an arthrotomy. In the eighties, Müller developed his ‘anatomometric’ double-bundle procedure with a split patellar tendon passed through one tibial tunnel, one leg of the graft passing through a femoral tunnel and the other one leading over the top (Figure 24), combining anatomical placement with the isometric principle [119]. Blauth followed this concept using a split quadriceps tendon (Figure 25) [23]. In the early eighties, Zaricznyj placed double-bundle grafts, using doubled tendon of the semitendinosus

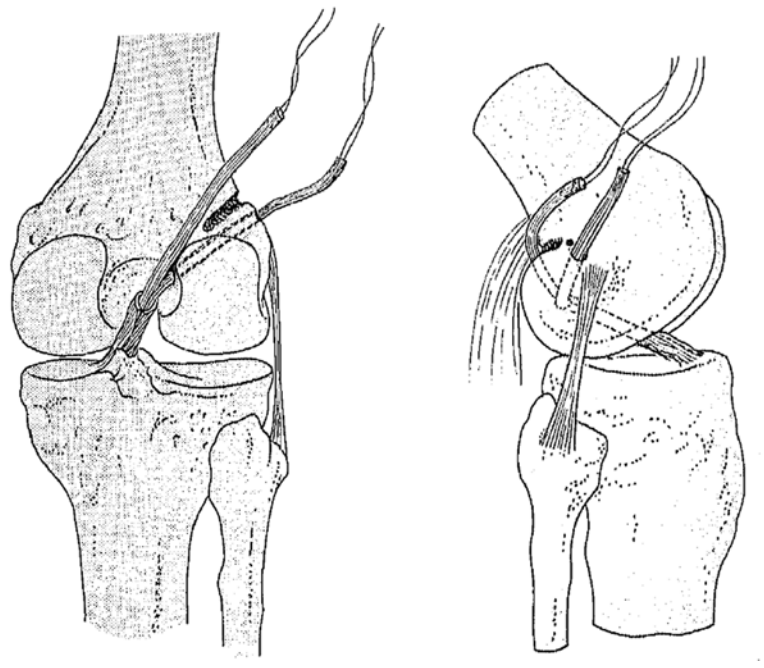

Figure 25. A double-bundle graft with a split patellar tendon, left attached at the tibia and detached proximally, routing it one part through a femoral tunnel and one part over the top. (From Blauth, 1984) [23]

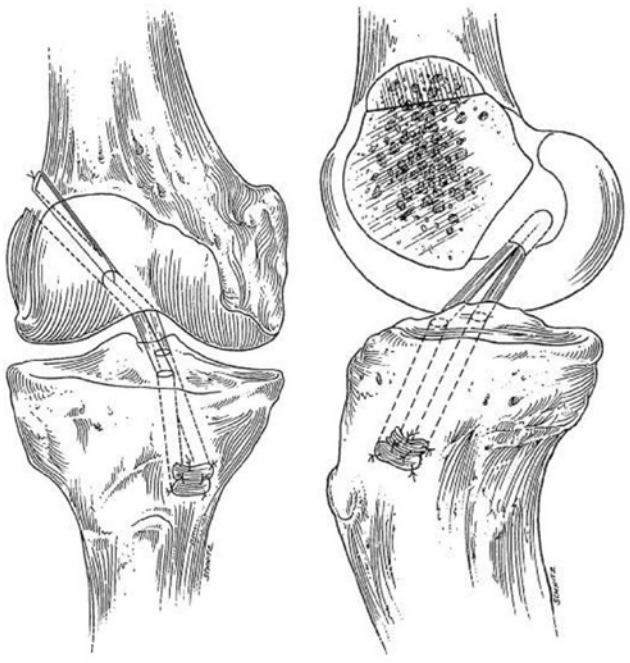

Figure 26. Doubled semitendinosus tendon, passed through two tibial tunnels and fixated in one femoral tunnel, with sutures through two canals to the outside of the lateral femoral condyle. (From Zaricznyj, 1987) [170]

muscle, in 14 patients using two tibial tunnels and one femoral hole (Figure 26) [170].

These double-bundle reconstructions all aimed at additional rotational and anterior stability in the lower flexion angles repairing the posterolateral bundle, while maintaining the anteromedial bundle, which restores the anterior-posterior stability. Radford and Amis demonstrated this concept in a biomechanical cadaver experiment [138]. In 1994, Rosenberg performed an arthroscopically assisted technique for double-bundle reconstruction, with a single tibial and double femoral tunnels [143]. Around the turn of the century several patient studies with various arthroscopic double-bundle techniques were published [63, 65, 100, 121]. In the same period several studies identified tunnel locations as an important factor related to a successful clinical outcome [3, 86, 153].

Positioning and placement of femoral tunnels

The locations of femoral tunnels has two aspects: the positioning concept and the actual placement. The positioning concept of the tunnels means the decision where the tunnels have to be placed. This decision depends on the reconstruction concept which is followed with choices about anatomic versus isometric concept, single or double bundle grafts, grafts with bony parts or tendons etcetera. The challenge is how to place the tunnel(s) at the location predetermined according to the chosen concept: the actual tunnel placement. Accurate tunnel placement appears to be difficult. Misplacement between 25% and 65% of the tibial and femoral tunnels is reported [19, 92, 159].

Instruments and methods to achieve precise tunnel placement, regardless of the reconstruction concept, have been developed since the early days of ACL reconstruction. Besides anatomical descriptions, many other methods have been developed: Descriptions using various imaging techniques like radiography and CT; Computer-assisted surgery (CAS) using fluoroscopic overlays and real time navigation; and, originating from the beginning of the ACL reconstruction history, the development of femoral drill guides and aiming devices for accurate tunnel placement and guided drilling.

HISTORICAL PERSPECTIVE OF THIS THESIS

Anatomical studies

Numerous studies reported the anatomical insertion geometry, starting with the description of the Weber brothers in 1837. The article of Girgis et al. has become a standard work in the history of ACL anatomy articles [58]. However, the descriptions in this paper were less suitable for the determination of the tunnel location at the centers of the native anatomical insertion during an arthroscopic anatomical tunnel placement procedure. During the nineties, an anatomical description from the surgeons perspective at the two-dimensional (2D) monitor view was not available. We wanted to fill this gap and performed an anatomical study addressing the 3D insertion geometry of the ACL and its two functional bundles, described relative to landmarks available during arthroscopic surgery (Chapter 2).

Radiographic descriptions

Besides anatomical studies, radiographic descriptions became available during the nineties. Two approaches have been published. The 'clock method' describes the anatomical insertion from the frontal view at coronal radiographs [6]. This method has been criticized since the anatomical notch is not circular and a 2D clock is inaccurate to align in a three–dimensional (3D) structure [6, 40, 51]. Furthermore, a lack of a unified definition applying the clock, results in subjective placement with a diverse range of alignment and centering the clock [12, 64] providing the method a poor intra-observer and inter-observer agreement [165]. Other methods used the lateral view on sagittal images to describe the positions of the femoral attachment site of the ACL [4, 6, 62, 67, 91, 99]. The most well-known and utilized method is the quadrant method of Bernard et al. [20]. We applied this method at 36 dissected cadaveric femora to determine the positions of the AM and PL centers and presented the guideline in 2000 at the 9th ESSKA congress in London.

In 2012, Piefer collected the data of eight different studies [34, 47, 62, 79, 134, 157, 161, 169] reporting the radiographic positions of the centers of the ACL and its functional bundles and published a new, averaged guideline using various data sources [133]. However, these data sources were rather variable and averaging of these various data sources did not seem to be the most reliable manner to define a new standard for ACL reconstruction. To address this issue, we calculated the difference in accuracy of the average guideline of Piefer and compared that to our previous results (Chapter 3).

CT

The quadrant method has also been applied at computed tomographic (CT)-scans [47, 85, 98, 101, 122]. Computed tomography (CT) is an imaging technique that uses x-rays to create three-dimensional (3D) representations of an object. This technique allows 3D surface modelling, adding an extra dimension to the graphic representation of the femoral notch relative to the 2D methods. Various measurement methods to determine femoral tunnel locations on CT scans have been developed [17, 47, 77, 85, 98, 139]. However, only Kai and colleagues utilize the 3D possibilities of CT-technique [85]. They determined the ACL center positions in two dimensions, relative to the intercondylar notch. For the position in the frontal plane, the clock method was used, which is subjected to comments about unified application and inter-observer agreement [51, 64, 165]. To avoid the clock method, we explored the possibilities to determine the 3D ACL center position relative to other structures instead of the often used intercondylar notch. For this goal, we studied the opportunities determining the 3D femoral position of the centers of the ACL and its bundles using the CT-technique. This resulted in the definition of the 3D anatomical ACL center position relative to the distal femur in 3D models derived from CT-data (Chapter 4).

Computer assisted surgery systems

Computer-assisted surgery (CAS) was developed to locate brain tumors based on stereotactic principles [26]. Since the nineties, CAS is used for orthopedic surgery and in 1995, Desenne introduced CAOS in ACL reconstruction surgery [39]. Computer-assisted orthopedic surgery systems can determine the position for the femoral tunnel and contribute in minimizing variation in graft placement [90]. These systems can be classified as passive or active systems. In active systems the surgery technique, drilling of the tunnel, is performed by a robot, like the CASPAR® system [28, 122, 132]. Furthermore, two methods to determine the correct tunnel position can be distinguished: systems that make use of images and image-free systems using real time navigation. The images that have been used are preoperative lateral radiographs [146] and CT-scans [132] or intraoperative fluoroscopic computer overlay techniques [74, 91, 117, 128]. With these images the center of the anatomical insertion is determined using a 2D concept, like the quadrant method of Bernard et al. [20]. The other method is image-free and uses real-time navigation, with which structures can be digitized during surgery [39, 80, 120, 135, 145, 146]. With this method, the actual 3D anatomical data of the patient's knee is used to find the preferred graft position. This method is mostly used to find positions in which notch impingement is avoided and to locate the most isometric zone for isometric single-bundle ACL reconstruction [145]. That means the positions at which the graft has the least elongation during knee movement over the full range of motion. However, this is not sufficient to position the tunnels for anatomic double bundle ACL reconstruction and does not use the full potential of CAS systems. We took the challenge to develop a method to determine the positions of the anatomical centers of the AM and PL bundles using intra-operative real-time digitization. A computer template was developed (Chapter 5) and its accuracy was calculated (Chapter 6). Next, we used the CAS system in an in-vitro experiment to place the anatomical tunnels for the AM- and PL bundle with the developed template (Chapter 7).

Femoral drill guides

In 1938, Palmer, who performed the Hey Groves technique, developed the first specific femoral drill guide, the 'drill adjuster' (Figure 27) [130]. The goal was to assist in positioning the drill tunnels when drilling from outside the joint during open surgery technique for accurate anatomic canal placement, reattaching the torn graft to the normal insertion area of the ACL, resulting in an anatomic reconstruction. Many other drill guides have been developed since, aiding the surgeon in tunnel positioning, placement and drilling. We were interested in the concepts behind the femoral guides and analyzed the literature (Chapter 8).

The most well-known and widely used femoral guide is the endoscopic femoral aimer (EFA) (Figure 28) [66, 115]. However, this guide is designed for transtibial isometric tunnel placement

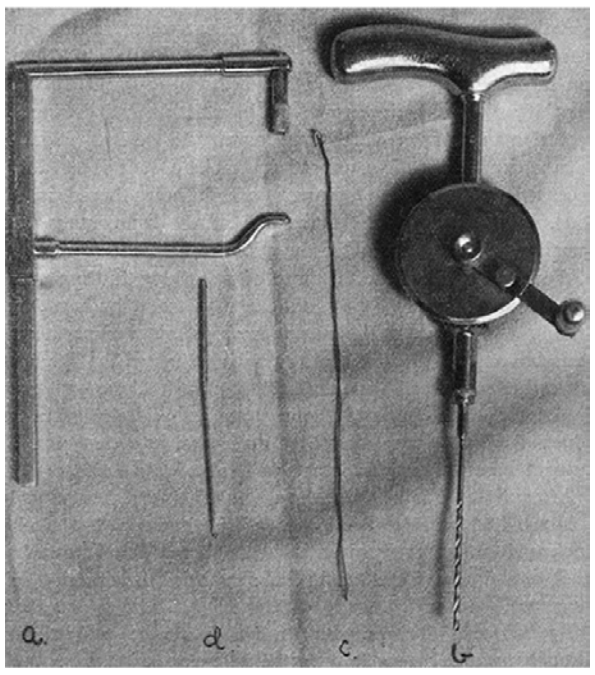

Figure 27. Drill adjuster (a) with drill (b) constructed. (From Palmer 1938) [130]

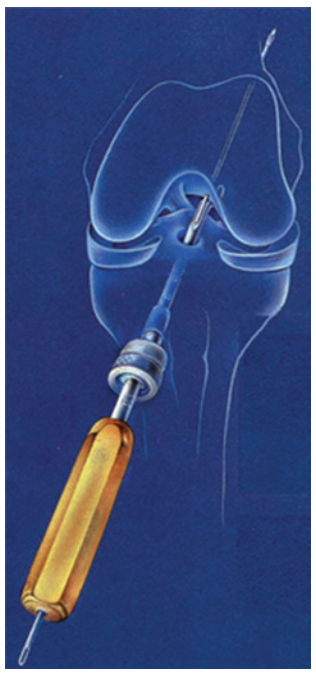

Figure 28. The endoscopic femoral aimer (EFA), placed transtibial behind the cortex at 11 o'clock.

and as Arnold reported [11], transtibial use of the EFA misses the anatomical insertion. Considering the patents found on the world wide web, numerous new, anatomical, guides have been developed. Only a few of these guides have been described in literature, though without accuracy values relative to the anatomical insertion centers [31, 55, 102]. With the results of our anatomical study, we developed a new Guide for Anatomic Femoral Tunnel placement (GAFT). In a validation study, we tested the accuracy of its design and the placement protocol during application from an arthroscopic view by various orthopedic residents, relative to the native ACL insertion centers (Chapter 9).

Patient specific devices

The accuracy of femoral tunnel placement with the aid of an aiming device depends on its design, on the one hand. However on the other hand, the accuracy depends on the surgeon's skill, experience and exactitude in positioning the guide, on the basis of a protocol, at the perfect place. Holding this in mind and the fact that 85% of the ACL-surgeons in the US perform less than 10 ACL reconstructions on an annual basis [54], it seems obvious that the use of an aiming device, which can be positioned freely, is not always a guarantee for accurate tunnel placement. In the quest for a solution decreasing the degrees of freedom in guide placement, we started thinking about the possibilities in personalizing parts of the guide which would be snap-fit on the femur in only one position. These opportunities could be found in stereolithography or 3D layering or 3D printing, a technique developed by Charles Hull in 1986 [76] with which a 3D object can be quickly fabricated on the basis of 3D images. In the nineties, application of stereolithography in medicine started with 3D printing of anatomical models derived from computer images from medical scanners, like X-ray computed tomography (CT) [16, 89]. In the last decade, this rapid prototyping process has been evolved, resulting in the application of this technique for the development of a broad range of new medical applications [142, 150], including surgical instruments [140]. Through these developments, possibilities for application of rapid prototyping in femoral tunnel placement arise, adapting guiding devices to the individual patient.

Transferring the concept to the design of a personalized aiming guide, we used the 3D data CT images of the patients knee (Chapter 9) to manufacture an individual device, printing a 3D mold of part of the femoral intercondylar notch. This idea and the accuracy results regarding anatomical tunnel placement have been elaborated (Chapter 10).

SUMMARIZED OUTLINE AND RESEARCH QUESTIONS

Outline of this thesis

To determine the anatomical positions of the center of the ACL and its two functional bundles, 36 cadaveric knees were dissected and the insertion sites of the AM and PL were identified. Using digitalization, the 3D positions of the centers relative to landmarks visible during the arthroscopic procedure were determined and described in **chapter 2.** The 2D anatomical center positions were also measured on lateral radiographs according to the quadrant method. The guidelines resulting from these measurements were applied to 12 cadaveric femora, as were the guidelines of Piefer [133]. The accuracy of both sets were calculated and causes for differences were explored in **chapter 3**. In **chapter 4**, we calculated the 3D positions of the femoral ACL centers relative to the dimensions of the distal femoral condyle, based on CT-data of 12 cadaveric femora and defined the mean positions.

The results of the 3D digitized center positions of the 36 femora were processed in a computer template, serving as input for intra-operative planning of the anatomic femoral tunnel location with a CAS system. In **chapter 5**, the development of this template is described. The accuracy of the template and the tunnel placement procedure is determined in **chapter 6**. In **chapter 7**, the CAS system with the template was used to place the anatomical tunnels for the AM- and PL bundle in an in vitro experiment in 8 cadaveric knees. The anterior translation of the tibia was tested in intact knees and knees without an ACL. Next, the ACL was reconstructed with a traditional isometrically placed single bundle graft and a computer-assisted anatomically placed double-bundle graft, with the AM tensed in 90° of flexion and the PL in 15° of flexion. The laxity in anterior-posterior direction was tested and the results have been compared.

Since the use of CAS in ACL reconstructions is not within reach for all surgeries, alternative methods to determine the anatomical femoral tunnel positions are developed as well as aids for accurate tunnel placement. In **chapter 8**, the history of femoral guides and concepts in literature utilized in ACL reconstruction is described. Besides the aim of anatomical or isometrical tunnel placement, two concepts can be distinguished: surgeon oriented drill guides and aiming devices. The first guides have to be positioned by the surgeon at the aiming point; This requires a lot of knowledge and skills from the surgeon. Aiming devices support the surgeon in correct positioning, since the design of these guides and the placement protocols guide the surgeon to the preferred point. Surgeons with less experience in ACL reconstruction can benefit this feature. Since no validated aiming guide for anatomical placement of the AM and PL tunnels is on the market, we developed and tested a new Guide for Anatomic Femoral Tunnel placement, the GAFT. The design and accuracy measurements are described in **chapter 9**.

In **chapter 10**, we applied the previous developed method, determining the ACL center positions relative to the distal femur derived from the CT-data to 6 femora. The results, the means of the ACL, AM and PL centers, were applied to 6 other femora to calculate the accuracy. With the 3D surface data of the femoral intercondylar notch and the mean center positions of those 6 femora, a 3D mold was printed. The mold was placed in the intercondylar notch and the incorporated tunnel positions of the ACL, AM and PL were marked in the femora. Finally, the accuracy of the tunnel positions relative to the anatomical centers were calculated.

Research questions

In summary the following research questions were examined in this thesis:

1. What are the 3D positions of the anatomical centers of the ACL, AM and PL bundles in the femoral intercondylar notch from surgical endoscopic perspective? (Chapter 2)
2. How accurate is an averaged guideline for radiological determination of the anatomical centers of the ACL, AM and PL bundles at a lateral radiograph? (Chapter 3)
3. What are the 3D positions of the anatomical centers of the ACL, AM and PL bundles relative to the distal femur derived from CT? (Chapter 4)
4. Can we develop an average computer template to position femoral tunnels using intra-operative real time navigation with CAS? (Chapter 5) How accurate is anatomical femoral tunnel placement using CAS and an incorporated femoral template? (Chapter 6)
5. Is there a difference in anterior tibial stability between isometric single bundle ACL reconstruction and anatomical double bundle ACL reconstruction? (Chapter 7)
6. Which concepts can be found in the history of femoral drill guides and aiming devices for tunnel placement in ACL reconstruction? (Chapter 8)
7. How accurate is anatomical femoral tunnel placement with the newly developed GAFT (Guide for Anatomic Femoral Tunnel placement)? (Chapter 9)
8. How accurate is anatomical femoral tunnel placement with a 3D printed personalized mold with average positions for the anatomical centers of the ACL, AM and PL bundles? (Chapter 10)

References

1. Adams R (1847) Abnormal conditions of the knee joint. In Todd R (ed) (ed) Cyclop Anat Physiol vol III Sherwood Gilbert & Piper, London, pp 48–78.
2. Aglietti P, Buzzi R, D'Andria S, Zaccherotti G (1992) Arthroscopic anterior cruciate ligament reconstruction with patellar tendon. Arthroscopy 8:510–516.
3. Aglietti P, Buzzi R, Giron F, Simeone A, Zaccherotti G (1997) Arthroscopic-assisted anterior cruciate ligament reconstruction with the central third patellar tendon. Knee Surg Sport Traumatol Arthrosc 5:138–144.
4. Aglietti P, Zaccherotti G, Menchetti P (1995) A comparison of clinical and radiological parameters with two arthroscopic techniques for anterior cruciate ligament reconstruction. Knee Surg Sport Traumatol Arthrosc 3:2–8.
5. Albee F (1943) A new operation for the repair of the cruciate ligaments. Am J Surg 3:349–353.
6. Amis AA, Beynnon B, Blankevoort L, Chambat P, Christel P, Durselen L, Friederich N, Grood E, Hertel P, Jakob R, Müller W, O'Brien M, O'Connor J (1994) Proceedings of the ESSKA Scientific Workshop on Reconstruction of the Anterior and Posterior Cruciate Ligaments. Knee Surg Sport Traumatol Arthrosc 2:124–132.
7. Amis AA, Dawkins GP (1991) Functional anatomy of the anterior cruciate ligament. Fibre bundle actions related to ligament replacements and injuries. J Bone Joint Surg Br 73:260–267.
8. Amis AA, Jakob RP (1998) Anterior cruciate ligament graft positioning, tensioning and twisting. Knee Surg Sport Traumatol Arthrosc 6:S2–S12.
9. Amis AA, Zavras T (1995) Isometricity and graft placement during anterior cruciate ligament reconstruction. Knee 2:5–17.
10. Arnoczky SP (1983) Anatomy of the anterior cruciate ligament. Clin Orthop Relat Res 172:19–25.
11. Arnold MP, Kooloos J, Kampen A (2001) Single-incision technique misses the anatomical femoral anterior cruciate ligament insertion: a cadaver study. Knee Surg Sport Traumatol Arthrosc 9:194–199.
12. Arnold MP, Verdonschot N, van Kampen A (2005) ACL graft can replicate the normal ligament's tension curve. Knee Surg Sports Traumatol Arthrosc 13:625–631.
13. Artmann M, Wirth CJ (1974) Untersuchung über den funktionsgerechten Verlauf der vorderen Kreuzbandplastik. [Free transplantation of the upper third of the patellar ligament for replacement of the anterior crucial ligament. A modification of Jones' method]. Monatsschr Unfallheilkd Versicher Versorg Verkehrsmed 77:556–561.
14. Bach BR, Jones GT, Sweet FA, Hager CA (1994) Arthroscopy-assisted Anterior Cruciate Ligament Reconstruction Using Patellar Tendon Substitution. Am J Sports Med 22:758–767.
15. Bargar WL, Sharkey NA, Paul HA, Manske DJ (1988) Efficacy of bone staples for fixation. J Orthop Trauma 1:326–330.
16. Barker TM, Earwaker WJ, Frost N, Wakeley G (1993) Integration of 3-D medical imaging and rapid prototyping to create stereolithographic models. Australas Phys Eng Sci Med 16:79–85.
17. Basdekis G, Christel P, Anne F (2009) Validation of the position of the femoral tunnels in anatomic double-bundle ACL reconstruction with 3-D CT scan. Knee Surg Sport Traumatol Arthrosc 17:1089–1094.
18. Battle W (1900) A case after open section of the knee-joint for irreducible traumatic dislocation. Trans Clin Soc L 232–233.
19. Behrend H, Stutz G, Kessler MA, Rukavina A, Giesinger K, Kuster MS (2006) Tunnel placement in anterior cruciate ligament (ACL) reconstruction: quality control in a teaching hospital. Knee Surg Sports Traumatol Arthrosc 14:1159–1165.
20. Bernard M, Hertel P, Hornung H, Cierpinski T (1997) Femoral insertion of the ACL. Radiographic quadrant method. Am J Knee Surg 10:14–21.
21. Blankevoort L, Huiskes R, Kampen A Van (1991) ACL reconstruction: simply a matter of isometry? Passiv motion Charact Hum knee Exp Comput simulations PhD thesis, University of Nijmegen, pp 151–162.
22. Blankevoort L, Huiskes R, de Lange A (1991) Recruitment of knee joint ligaments. J Biomech Eng 113:94–103.

23. Blauth W (1984) Die zweizügelige Ersatzplastik des vorderen Kreuzband der Quadricepssehne. [2-strip substitution-plasty ofthe anterior cruciate ligament with the quadriceps tendon]. Unfallheilkunde 87:45–51.
24. Bonnet A (1845) Traité des maladies des articulations [Treatise on joint diseases]. Baillière, Paris.
25. Bray RC, Dandy DJ (1987) Comparison of Artliroscopic and Open Techniques in Carbon Fibre Reconstruction of the Anterior Cruciate Ligament : Long-Term Follow-up After 5 Years. Arthroscopy 3:106–110.
26. Brown R a (1979) A computerized tomography-computer graphics approach to stereotaxic localization. J Neurosurg 50:715–720.
27. Brückner H (1966) Eine neue Methode der Kreuzbandplastik. [A new method for plastic surgery of cruciate ligaments]. Chirurg 413–414.
28. Burkart A, Debski RE, McMahon PJ, Rudy T, Fu FH, Musahl V, van Scyoc A, Woo SL (2001) Precision of ACL tunnel placement using traditional and robotic techniques. Comput Aided Surg 6:270–278.
29. Burman MS (1931) Arthroscopy or the direct visualization of joints. J Bone Jt Surg Br 669–695.
30. Cazenave A, Laboureau JP (1990) [Reconstruction of the anterior cruciate ligament. Determination of the pre- and peroperative femoral isometric point]. Rev Chir Orthop Reparatrice Appar Mot 76:288–292.
31. Christel P, Sahasrabudhe A, Basdekis G (2008) Anatomic double-bundle anterior cruciate ligament reconstruction with anatomic aimers. Arthroscopy 24:1146–1151.
32. Clancy WG (1985) Intra-articular reconstruction of the anterior cruciate ligament. Orthop Clin North Am 16:181–189.
33. Clancy WG (2015) Anatomic ACL reconstruction: The final answer? Knee Surg Sports Traumatol Arthrosc 23:636–639.
34. Colombet P, Robinson J, Christel P, Franceschi J-P, Djian P, Bellier G, Sbihi A (2006) Morphology of anterior cruciate ligament attachments for anatomic reconstruction: a cadaveric dissection and radiographic study. Arthroscopy 22:984–992.
35. Cooper DE, Urrea L, Small J (1998) Factors Affecting Isometry of Endoscopic Anterior Cruciate and Rotation. 14:164–170.
36. Corner E (1914) Notes of a Case illustrative of an Artificial Anterior Crucial Ligament, demonstrating the Action of that Ligament. Proc R Soc Med 120–121.
37. Cowan D (1963) Reconstruction of the Anterior Cruciate Ligament by the Method of Kenneth Jones (1963). Proc R Soc Med 336–338.
38. Dandy DJ, Flanagan JP, Steenmeyer V (1982) Arthroscopy and the Management of the Ruptured Anterior Cruciate Ligament. Clin Orthop Relat Res 167:43–49.
39. Dessenne V, Lavallée S, Julliard R, Orti R, Martelli S, Cinquin P (1995) Computer-assisted knee anterior cruciate ligament reconstruction: first clinical tests. J Image Guid Surg 1:59–64.
40. Edwards A, Bull AMJ, Amis AA (2007) The attachments of the anteromedial and posterolateral fibre bundles of the anterior cruciate ligament: Part 1: tibial attachment. Knee Surg Sports Traumatol Arthrosc 15:1414–1421.
41. Engelen-van Melick N, Hullegie W, Brooijmans F, Hendriks E, Neeter C, VanTienen T, van Cingel R (2014) KNGF Evidence Statement; Revalidatie na voorste-kruisbandreconstructie.
42. England RL (1976) Repair of the ligaments about the knee. Orthop Clin North Am 7:195–204.
43. Feagin JA, Curl WW (1976) Isolated tear of the anterior cruciate ligament: 5-year follow-up study. Am J Sports Med 4:95–100.
44. Ferretti A (2003) A historical note on anterior cruciate ligament reconstruction. J Bone Joint Surg Am 85-A:970–971.
45. Fick R (1911) Handbuch der Anatomie und Mechanik der Gelenke. 3 Teil: Spezielle Gelenk- und Muskelmechanik. Gustav Fischer, Jena.
46. Fisher A (1933) Internal derangements of the knee-joint. HK Lewis Co, London.
47. Forsythe B, Kopf S, Wong AK, Martins CAQ, Anderst W, Tashman S, Fu FH (2010) The location of femoral and tibi-

al tunnels in anatomic double-bundle anterior cruciate ligament reconstruction analyzed by three-dimensional computed tomography models. J Bone Joint Surg Am 92:1418–1426.

48. Friederich NF, O'Brien WR (1998) Anterior cruciate ligament graft tensioning versus knee stability. Knee Surg Sports Traumatol Arthrosc 6 Suppl 1:S38–S42.
49. Friedman M (1988) Arthroscopic semitendinosus (gracilis) reconstruction for anterior cruciate ligament deficiency. Tech Orthop 74–80.
50. Friedman RL, Feagin JA (1994) Topographical anatomy of the intercondylar roof. A pilot study. Clin Orthop Relat Res 163–170.
51. Fu FH (2008) The clock-face reference: simple but nonanatomic. Arthroscopy 24:1433; author reply 1434.
52. Fu FH, Schulte KR (1996) Anterior Cruciate Ligament Surgery 1996 State of the art? Clin Orthop Relat Res 325:19–24.
53. Galen C (1968) On the usefulness of parts of the body (trans: May MT). Cornell Univ Press New York.
54. Garrett WE, Swiontkowski MF, Weinstein JN, Callaghan J, Rosier RN, Berry DJ, Harrast J, Derosa GP (2006) American Board of Orthopaedic Surgery Practice of the Orthopaedic Surgeon: Part-II, certification examination case mix. J Bone Joint Surg Am 88:660–667.
55. Gelber PE, Erquicia J, Abat F, Torres R, Pelfort X, Rodriguez-Baeza A, Alomar X, Monllau JC (2011) Effectiveness of a footprint guide to establish an anatomic femoral tunnel in anterior cruciate ligament reconstruction: computed tomography evaluation in a cadaveric model. Arthroscopy 27:817–824.
56. Gerich TG, Cassim A, Lattermann C, Lobenhoffer HP, Tscherne H (1998) Ausreisskraft der tibialen Transplantatfixierung fur den Ersatz des vorderen Kreuzbands. Unfallchirurg 101:204–208.
57. Gianotti SM, Marshall SW, Hume PA., Bunt L (2009) Incidence of anterior cruciate ligament injury and other knee ligament injuries: A national population-based study. J Sci Med Sport 12:622–627.
58. Girgis FG, Marshall JL, Monajem A (1975) The cruciate ligaments of the knee joint. Anatomical, functional and experimental analysis. Clin Orthop Relat Res 216–231.
59. Goetjes H (1913) Über Verletzungen der Ligamenta cruciate des Kniegelenks [On injuries of the cruciate ligaments of the knee joint]. Dtsch Z Chir 221–289.
60. Gold E (1928) Vollständiger plastischer Ersatz des vorderen Kreuzbandes und funktionell-anatomische Wiederherstellung desselben [Complete functional/anatomical reconstruction of the anterior cruciate ligament]. Dtsch Z Chir 120–126.
61. Graf BK, Rosenberg TD, Sklar JH, Ferragamo MC (1994) Graft attachment device and method of using same. US Patent 5306301.
62. Guo L, Yang L, Wang A-M, Wang X-Y, Dai G (2009) Roentgenographic measurement study for locating femoral insertion site of anterior cruciate ligament: a cadaveric study with X-Caliper. Int Orthop 33:133–137.
63. Hamada M, Shino K, Horibe S, Mitsuoka T, Miyama T, Shiozaki Y, Mae T (2001) Single- versus bi-socket anterior cruciate ligament reconstruction using autogenous multiple-stranded hamstring tendons with endoButton femoral fixation. Arthrosc J Arthrosc Relat Surg 17:801–807.
64. Han Y, Hart A, Martineau PA (2014) Is the clock face an accurate, precise, and reliable measuring tool for anterior cruciate ligament reconstruction? Arthroscopy 30:849–855.
65. Hara K, Kubo T, Suginoshita T, Shimizu C, Hirasawa Y (2000) Reconstruction of the anterior cruciate ligament using a double bundle. Arthroscopy 16:860–864.
66. Hardin GT, Bach BR, Bush-Joseph CA (2003) Endoscopic Single-Incision Anterior Cruciate Ligament Reconstruction Using Patellar Tendon Autograft Surgical Technique. Am J Knee Surg 16:135–144.
67. Harner CD, Marks PH, Fu FH, Irrgang JJ, Silby MB, Mengato R (1994) Anterior cruciate ligament reconstruction: endoscopic versus two-incision technique. Arthroscopy 10:502–512.
68. Hefzy MS, Grood ES, Noyes FR (1989) Factors affecting the region of most isometric femoral attachments. Part II: The anterior cruciate ligament. Am J Sports Med 17:208–216.

69. Hesse E (1914) Über den Ersatz der Kreuzbänder des Kniegelenkes durch freie Fascientransplantation [On the replacement of the cruciate ligaments with transplanted free fascia grafts]. Verh Dtsch Ges Chir 188–189.
70. Hewson GF (1983) Drill guides for improving accuracy in anterior cruciate ligament repair and reconstruction. Clin Orthop Relat Res 119–124.
71. Hey Groves E (1917) Operation for the repair of crucial ligaments. Lancet 674–675.
72. Hey Groves E (1920) The crucial ligaments of the knee joint: their function, rupture and operative treatment of the same. Br J Surg 505–515.
73. Hippocrates (1928) On wounds in the head. In: the surgery fractures joints (trans: Whittington ET). Loeb Class Libr vol III William Heinemann, London Harvard Univ Press Cambridge, MA.
74. Hiraoka H, Kuribayashi S, Fukuda A, Fukui N, Nakamura K (2006) Endoscopic anterior cruciate ligament reconstruction using a computer-assisted fluoroscopic navigation system. J Orthop Sci 11:159–166.
75. Hölzel W (1917) Fall von Zerreisung beider Kreuzbänder des linken Kniegelenkes, geheilt durch Ersatz aus dem luxierten äußeren Meniskus [Rupture of both cruciate ligaments, cured by replacement with the lateral meniscus]. Munch Med Wschr 928–929.
76. Hull CW (1986) Apparatus for production of three-dimensional objects by stereolithography. US Patent 45753330.
77. Inoue M, Tokuyasu S, Kuwahara S, Yasojima N, Kasahara Y, Kondo E, Onodere S, Yasuda K (2010) Tunnel location in transparent 3-dimensional CT in anatomic double-bundle anterior cruciate ligament reconstruction with the trans-tibial tunnel technique. Knee Surg Sports Traumatol Arthrosc 18:1176–1183.
78. Insall J, Joseph DM, Aglietti P, Campbell RD (1981) Bone-block iliotibial-band transfer for anterior cruciate insufficiency. J Bone Joint Surg Am 63:560–569.
79. Iriuchishima T, Ingham SJM, Tajima G, Horaguchi T, Saito A, Tokuhashi Y, Van Houten AH, Aerts MM, Fu FH (2010) Evaluation of the tunnel placement in the anatomical double-bundle ACL reconstruction: a cadaver study. Knee Surg Sports Traumatol Arthrosc 18:1226–1231.
80. Ishibashi Y, Tsuda E, Fukuda A, Tsukada H, Toh S (2006) Future of double-bundle anterior cruciate ligament (ACL) reconstruction: incorporation of ACL anatomic data into the navigation system. Orthopedics 29:S108–S112.
81. Jones HP, Appleyard RC, Mahajan S, Murrell GAC (2003) Meniscal and Chondral Loss in the Anterior Cruciate Ligament Injured Knee. Sport Med 33:1075–1089.
82. Jones KG (1963) Reconstruction of the anterior cruciate ligament using the central one-third of the patellar ligament. J Bone Joint Surg Am 45:925–932.
83. Jones KG (1970) Reconstruction of the anterior cruciate ligament using the central one-third of the patellar ligament. A follow-up report. J Bone Joint Surg Am 52:1302–138.
84. Jones R (1916) Disabilities of the knee joint. Br Med J 169–173.
85. Kai S, Kondo E, Kitamura N, Kawaguchi Y, Inoue M, Amis AA, Yasuda K (2013) A quantitative technique to create a femoral tunnel at the averaged center of the anteromedial bundle attachment in anatomic double-bundle anterior cruciate ligament reconstruction. BMC Musculoskelet Disord 14:189.
86. Khalfayan EE, Sharkey PF, Alexander AH, Bruckner JD, Bynum EB (1996) The relationship between tunnel placement and clinical results after anterior cruciate ligament reconstruction. Am J Sports Med 24:335–341.
87. Kieser CW, Jackson RW (2001) Severin Nordentoft: The first arthroscopist. Arthroscopy 17:532–535.
88. Kieser CW, Jackson RW (2003) Eugen bircher (1882-1956) the first knee surgeon to use diagnostic arthroscopy. Arthroscopy 19:771–776.
89. Klimek L, Klein HM, Schneider W, Mösges R, Schmelzer B, Voy ED (1993) Stereolithographic modelling for reconstructive head surgery. Acta Otorhinolaryngol Belg 47:329–334.
90. Klos TV, Habets RJ, Banks AZ, Banks SA, Devilee RJ, Cook FF (1998) Computer assistance in arthroscopic anterior cruciate ligament reconstruction. Clin Orthop Relat Res 65–69.
91. Klos TV, Harman MK, Habets RJ, Devilee RJ, Banks SA Locating femoral graft placement from lateral radiographs in anterior cruciate ligament reconstruction: a comparison of 3 methods of measuring radiographic images.

Arthroscopy 16:499–504.

92. Kohn D, Busche T, Carls J (1998) Drill hole position in endoscopic anterior cruciate ligament reconstruction. Results of an advanced arthroscopy course. Knee Surg Sports Traumatol Arthrosc 6 Suppl 1:S13–S15.
93. Lam S (1968) Reconstruction of the Anterior Cruciate Ligament Using the Jones Procedure an Its Guy's Hospital Modification. J Bone Jt Surg Br 50-A:1213–1224.
94. Lambert KL (1983) Vascularized patellar tendon graft with rigid internal fixation for anterior cruciate ligament insufficiency. Clin Orthop Relat Res 85–89.
95. Lange F (1907) Künstliche Gelenkbänder aus Seide [On artificial silk ligaments]. Munch Med Wschr 834–836.
96. Legnani C, Ventura A, Terzaghi C, Borgo E, Albisetti W (2010) Anterior cruciate ligament reconstruction with synthetic grafts. A review of literature. Int Orthop 34:465–471.
97. Leong N, Kabir N, Arshi A, Nazemi A, Wu B, Petrigliano FA, McAllister DR (2015) Evaluation of polycaprolactone scaffold with basic fibroblast growth factor and fibroblasts in an athymic rat model for anterior cruciate ligament reconstruction. Tissue Eng Part A 21:1859–1868.
98. Lertwanich P, Martins CAQ, Asai S, Ingham SJM, Smolinski P, Fu FH (2011) Anterior cruciate ligament tunnel position measurement reliability on 3-dimensional reconstructed computed tomography. Arthroscopy 27:391–398.
99. Lintner DM, Dewitt SE, Moseley JB (1996) Radiographic Evaluation of Native Anterior Cruciate Ligament Attachments and Graft Placement for Reconstruction. Am J Sports Med 24:72–78.
100. Loh JC, Fukuda Y, Tsuda E, Steadman RJ, Fu FH, Woo SLY (2003) Knee stability and graft function following anterior cruciate ligament reconstruction: Comparison between 11 o'clock and 10 o'clock femoral tunnel placement. 2002 Richard O'Connor Award paper. Arthroscopy 19:297–304.
101. Lorenz S, Elser F, Mitterer M, Obst T, Imhoff AB (2009) Radiologic evaluation of the insertion sites of the 2 functional bundles of the anterior cruciate ligament using 3-dimensional computed tomography. Am J Sports Med 37:2368–2376.
102. Lubowitz JH (2009) Anteromedial portal technique for the anterior cruciate ligament femoral socket: pitfalls and solutions. Arthroscopy 25:95–101.
103. Ludloff K (1927) Der operative Ersatz des vorderen Kreuzbandes am Knie [Surgical replacement of the anterior cruciate ligament]. Zentralbl Chir 3162–3166.
104. Lyman S, Koulouvaris P, Sherman S, Do H, Mandl LA, Marx RG (2009) Epidemiology of anterior cruciate ligament reconstruction: trends, readmissions, and subsequent knee surgery. J Bone Joint Surg Am 91:2321–2328.
105. Magen HE, Howell SM, Hull ML (1999) Structural properties of six tibial fixation methods for anterior cruciate ligament soft tissue grafts. Am J Sports Med 27:35–43.
106. Mall NA, Chalmers PN, Moric M, Tanaka MJ, Cole BJ, Bach BR, Paletta GA (2014) Incidence and trends of anterior cruciate ligament reconstruction in the United States. Am J Sports Med 42:2363–2370.
107. Marans H, Hendrix M, Paterson R (1992) A new femoral drill guide for arthroscopically assisted anterior cruciate ligament replacement. Arthroscopy 8:234–238.
108. Marcacci M, Zaffagnini S, Iacono F, Neri MP, Loreti I, Petitto A (1998) Arthroscopic intra- and extra-articular anterior cruciate ligament reconstruction with gracilis and semitendinosus tendons. Knee Surg Sports Traumatol Arthrosc 6:68–75.
109. Marshall JL, Wang JB, Furman W, Girgis FG, Warren R (1975) The anterior drawer sign: what is it? J Sports Med 3:152–158.
110. Marshall JL, Warren RF, Wickiewicz TL, Reider B (1979) The anterior cruciate ligament: a technique of repair and reconstruction. Clin Orthop Relat Res 97–106.
111. Marshall S, Padua D, McGrath M (2007) Incidence of ACL injury. In Hewitt G, Mandelbaum, Schultz (eds) Underst Prev noncontact ACL Inj: Human Kinetics, Campaign, IL.
112. Martin SD, Martin TL, Brown CH (2002) Anterior cruciate ligament graft fixation. Orthop Clin North Am 33:685–696.

113. Matsumoto A, Howell SM (2005) The WasherLoc and Bone Dowel: A Rigid, Slippage-Resistant Tibial Fixation Device for a Soft Tissue Anterior Cruciate Ligament Graft. Tech Orthop 20:278–282.
114. Mayo Robson A (1903) Ruptured crucial ligaments and their repair by operation. Ann Surg 37:716–718.
115. McGuire D, Hendricks S, Grinstead G (1996) Use of an endoscopic aimer for femoral tunnel placement in anterior cruciate ligament reconstruction. Arthroscopy 12:26–31.
116. McGuire D, Paterson R (1996) Femoral guide and methods of precisely forming bone tunnels in cruciate ligament reconstruction of the knee. US Patent 5520693 A.
117. Moloney G, Araujo P, Rabuck S, Carey R, Rincon G, Zhang X, Harner C (2013) Use of a fluoroscopic overlay to assist arthroscopic anterior cruciate ligament reconstruction. Am J Sports Med 41:1794–1800.
118. Mott HW (1983) Semitendinosus Anatomic Reconstruction for Cruciate Ligament Insufficiency. Clin Orthop Relat Res 90–92.
119. Müller W (1992) Treatment of acute Tears. In Jakob R, Staübl H-J (eds) Knee cruciate ligaments Springer Heidelberg, Berlin, Berlin, Heidelberg, pp 279–288.
120. Müller-Alsbach UW, Staubli AE (2004) Computer aided ACL reconstruction. Injury 35 Suppl 1:S–A65–67.
121. Muneta T, Sekiya I, Yagishita K, Ogiuchi T, Yamamoto H, Shinomiya K (1999) Two-bundle reconstruction of the anterior cruciate ligament using semitendinosus tendon with endobuttons: operative technique and preliminary results. Arthroscopy 15:618–624.
122. Musahl V, Burkart A, Debski RE, Van Scyoc A, Fu FH, Woo SLY (2003) Anterior cruciate ligament tunnel placement: Comparison of insertion site anatomy with the guidelines of a computer-assisted surgical system. Arthroscopy 19:154–160.
123. Nau T (2015) Regeneration of the anterior cruciate ligament: Current strategies in tissue engineering. World J Orthop 6:127–136.
124. Nordenvall R, Bahmanyar S, Adami J, Stenros C, Wredmark T, Fellander-Tsai L (2012) A Population-Based Nationwide Study of Cruciate Ligament Injury in Sweden, 2001-2009: Incidence, Treatment, and Sex Differences. Am J Sports Med 40:1808–1813.
125. Noyes FR, Matthews DS, Mooar PA, Grood ES (1983) The symptomatic anterior cruciate-deficient knee. Part II: the results of rehabilitation, activity modification, and counseling on functional disability. J Bone Joint Surg Am 65:163–174.
126. Odensten M, Gillquist J (1985) Functional anatomy of the anterior cruciate ligament and a rationale for reconstruction. J Bone Jt Surg Am 67:257–262.
127. Odensten M, Gillquist J (1986) A modified technique for anterior cruciate ligament (ACL) surgery using a new drill guide system for isometric positioning of the ACL. Clin Orthop Relat Res 213:154–158.
128. Pace A, Fergusson C (2006) Preoperative computerized radiograph measurement of Blumensaat's line as an aid to correct placement of the femoral tunnel in ACL reconstruction. J Knee Surg 19:176–180.
129. Paessler HH, Yang Y (2012) The past and the future of Arthroscopy. Doral MN (ed) Sport Inj Prev Diagnosis, Treat Rehabil Berlin, Heidelberg.
130. Palmer I (1938) Chapter VIII. The therapie of ligamentous injuries. Acta Chir Scand 81:231–267.
131. Penner DA, Daniel DM, Wood P, Mishra D (1988) An in vitro study of anterior cruciate ligament graft placement and isometry. Am J Sports Med 16:238–243.
132. Petermann J, Kober R, Heinze R, Frölich JJ, Heeckt PF, Gotzen L (2000) Computer-assisted planning and robot-assisted surgery in anterior cruciate ligament reconstruction. Oper Tech Orthop 10:50–55.
133. Piefer JW, Pflugner TR, Hwang MD, Lubowitz JH (2012) Anterior cruciate ligament femoral footprint anatomy: systematic review of the 21st century literature. Arthroscopy 28:872–881.
134. Pietrini SD, Ziegler CG, Anderson CJ, Wijdicks CA, Westerhaus BD, Johansen S, Engebretsen L, LaPrade RF (2011) Radiographic landmarks for tunnel positioning in double-bundle ACL reconstructions. Knee Surg Sports Traumatol Arthrosc 19:792–800.

135. Plaweski S, Cazal J, Rosell P, Merloz P (2006) Anterior cruciate ligament reconstruction using navigation: a comparative study on 60 patients. Am J Sports Med 34:542–552.
136. Prodromos CC, Han Y, Rogowski J, Joyce B, Shi K (2007) A meta-analysis of the incidence of anterior cruciate ligament tears as a function of gender, sport, and a knee injury-reduction regimen. J Arthrosc Relat Surg 23:1320–1325.
137. Proffen BL, Sieker JT, Murray MM (2015) Bio-Enhanced Repair of the Anterior Cruciate Ligament. Arthroscopy 31:990–997.
138. Radford WJ, Amis AA (1990) Biomechanics of a double prosthetic ligament in the anterior cruciate deficient knee. J Bone Joint Surg Br 72:1038–1043.
139. Ramme AJ, Wolf BR, Warme BA, Shivanna KH, Willey MC, Britton CL, Magnotta VA, Grosland NM (2012) Surgically oriented measurements for three-dimensional characterization of tunnel placement in anterior cruciate ligament reconstruction. Comput Aided Surg 17:221–231.
140. Rankin TM, Giovinco N a, Cucher DJ, Watts G, Hurwitz B, Armstrong DG (2014) Three-dimensional printing surgical instruments: are we there yet? J Surg Res 189:193–197.
141. Raunest J (1991) Application of a new positioning device for isometric replacement in anterior cruciate ligament repair and reconstruction. J Trauma 31:223–229.
142. Rengier F, Mehndiratta A, von Tengg-Kobligk H, Zechmann CM, Unterhinninghofen R, Kauczor H-U, Giesel FL (2010) 3D printing based on imaging data: review of medical applications. Int J Comput Assist Radiol Surg 5:335–341.
143. Rosenberg TD (1994) Techniques for ACL reconstruction with Multi-Trac drill guide. Accufex Microsurg Inc, Mansf MA.
144. Sakane M, Fox RJ, Woo SLY, Livesay GA, Li G, Fu FH (1997) In situ forces in the anterior cruciate ligament and its bundles in response to anterior tibial loads. J Orthop Res Raven Press Ltd 15:285–293.
145. Sati M, Stäubli H, Bourquin Y, Kunz M, Nolte LP (2002) Real-time computerized in situ guidance system for ACL graft placement. Comput Aided Surg 7:25–40.
146. Sati M, Stäubli HU, Bourquin Y, Kunz M, Käsermann S, Nolte L-P (2000) Clinical integration of computer-assisted technology for arthroscopic anterior cruciate ligament reconstruction. Oper Tech Orthop 10:40–49.
147. Schindler OS (2012) Surgery for anterior cruciate ligament deficiency: A historical perspective. Knee Surg Sport Traumatol Arthrosc 20:5–47.
148. Schindler OS (2012) The story of anterior cruciate ligament reconstruction- part 2. Clin Featur 22:189–196.
149. Schlatterer B, Jund S, Delépine F, Razafindratsiva C, de Peretti F (2006) [Acute anterior cruciate ligament repair with combined intra- and extra-articular reconstruction using an iliotibial band with the modified MacIntosh technique: a five-year follow-up study of 50 pivoting sport athletes]. Rev Chir Orthop Reparatrice Appar Mot 92:778–787.
150. Schubert C, van Langeveld MC, Donoso LA (2014) Innovations in 3D printing: a 3D overview from optics to organs. Br J Ophthalmol 98:159–161.
151. Shino K, Kimura T, Hirose H, Inoue M, Ono K (1986) Reconstruction of the anterior cruciate ligament by allogeneic tendon graft. An operation for chronic ligamentous insufficiency. J Bone Joint Surg Br 68:739–746.
152. Sidles JA, Larson R V, Garbini JL, Downey DJ, Matsen FA (1988) Ligament length relationships in the moving knee. J Orthop Res 6:593–610.
153. Sommer C, Friederich NF, Müller W (2000) Improperly placed anterior cruciate ligament grafts: correlation between radiological parameters and clinical results. Knee Surg Sports Traumatol Arthrosc 8:207–213.
154. Stähelin AC, Weiler A (1997) All-inside anterior cruciate ligament reconstruction using semitendinosus tendon and soft threaded biodegradable interference screw fixation. Arthroscopy 13:773–779.
155. Stark J (1850) Two cases of rupture of the crucial ligament of the knee-joint. Edinb Med Surg 74:267–271.
156. Stäubli HU, Schatzmann L, Brunner P, Rincón L, Nolte LP (1996) Quadriceps tendon and patellar ligament: cryo-

sectional anatomy and structural properties in young adults. Knee Surg Sports Traumatol Arthrosc 4:100–110.

157. Steckel H, Musahl V, Fu FH (2010) The femoral insertions of the anteromedial and posterolateral bundles of the anterior cruciate ligament: a radiographic evaluation. Knee Surg Sports Traumatol Arthrosc 18:52–5.
158. Stein V, Hunter DJ (2012) Pattern of joint damage in persons with knee osteoarthritis and concomitant ACL tears. 32:1197–1208.
159. Topliss C, Webb J (2001) An audit of tunnel position in anterior cruciate ligament reconstruction. Knee 8:59–63.
160. Torg JS, Conrad W, Kalen V (1976) Clinical diagnosis of anterior cruciate ligament instability in the athlete. Am J Sports Med 4:84–93.
161. Tsukada H, Ishibashi Y, Tsuda E, Fukuda A, Toh S (2008) Anatomical analysis of the anterior cruciate ligament femoral and tibial footprints. J Orthop Sci 13:122–129.
162. Viernstein K, Keyl W (1973) Operationen am Kniegelenk. In Breitner B (ed) Chir Oper vol IV/2 Urban & Schwarzenberg, München, München, pp 1–78.
163. Weber W, Weber E (1836) Mechanik der menschlichen Gehwerkzeuge [The mechanics of human locomotion]. Dieterichsche Buchhandlung, Göttingen.
164. Wittek A (1927) Über Verletzungen der Kreuzbänder des Kniegelenkes. Mit 13 Abbildungen [On the injuries to the cruciate ligaments. With 13 illustrations]. Dtsch Z Chir 491–515.
165. Wittstein JR, Garrett WE (2013) Time to Get Rid of the Clock: Intraobserver and Interobserver Reliability in Determination of the O'clock Position of the Femoral Tunnel in ACL Reconstruction. J Knee Surg 1:1–4.
166. Wolf E (1998) Semitendinosis and Gracilis Anterior Cruciate Ligament Reconstruction Using the TransFix Technique. Tech Orthop 13:329.
167. Wolf E, Whelan J (1992) Bio-TransFix ACL Reconstruction. Surgical Technique. Arthrex Inc, Naples, Florida.
168. Zaffagnini S, Signorelli C, Lopomo N, Bonanzinga T, Muccioli GMM, Bignozzi S, Visani A, Marcacci M (2012) Anatomic double-bundle and over-the-top single-bundle with additional extra-articular tenodesis: An in vivo quantitative assessment of knee laxity in two different ACL reconstructions. Knee Surg Sport Traumatol Arthrosc 20:153–159.
169. Zantop T, Diermann N, Schumacher T, Schanz S, Fu FH, Petersen W (2008) Anatomical and nonanatomical double-bundle anterior cruciate ligament reconstruction: importance of femoral tunnel location on knee kinematics. Am J Sports Med 36:678–685.
170. Zaricznyj B (1987) Reconstruction of the anterior cruciate ligament of the knee using a doubled tendon graft. Clin Orthop Relat Res 162–175.

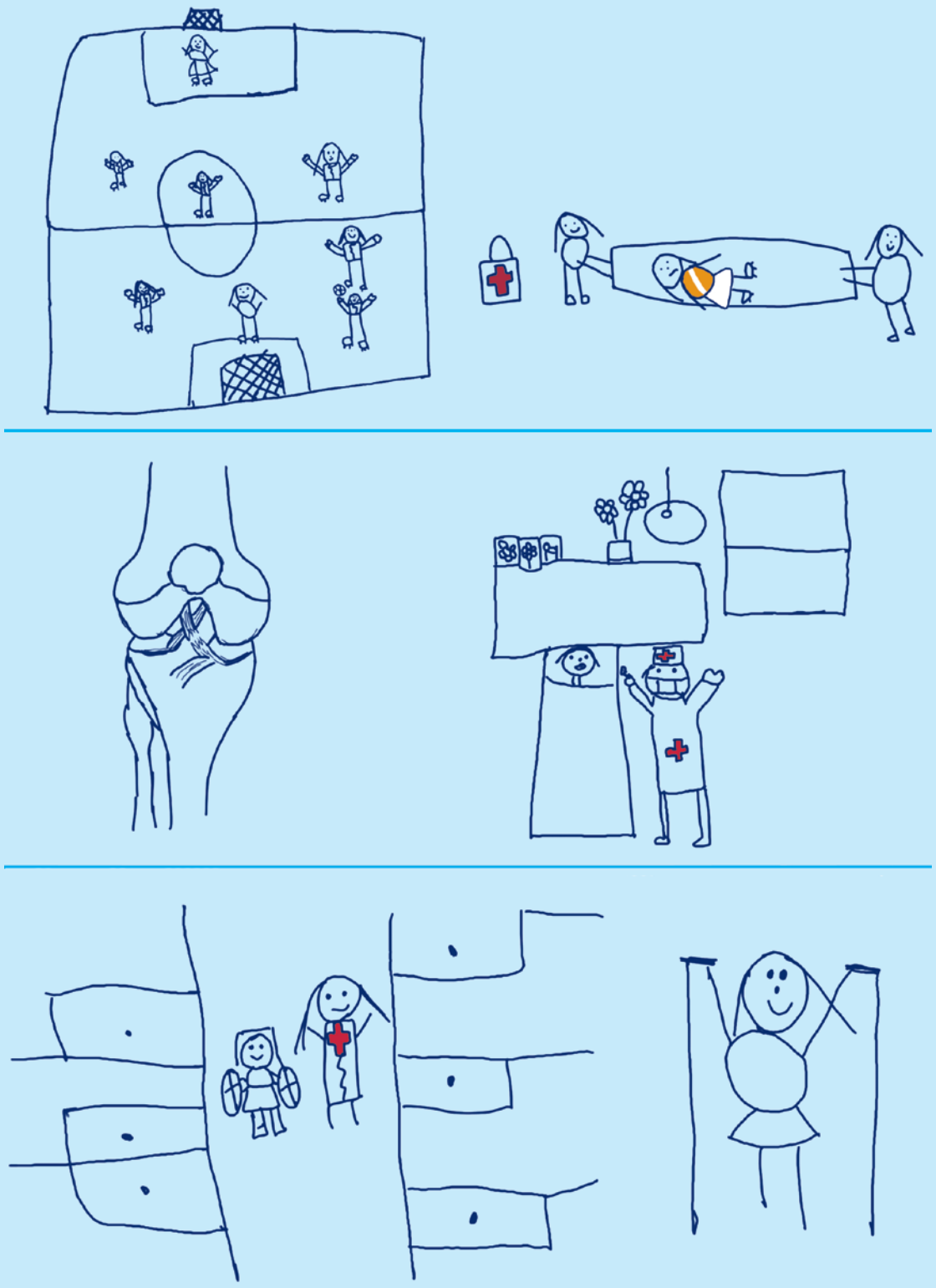

Raffi & Eli

CHAPTER 2

Description of the attachment geometry of the anteromedial and posterolateral bundles of the ACL from arthroscopic perspective for anatomical tunnel placement

Joan W.H. Luites, Ate B. Wymenga, Leendert Blankevoort, Jan G.M. Kooloos

Knee Surgery, Sports Traumatology, Arthroscopy 2007 15:1422–1431

Abstract

The anterior cruciate ligament (ACL) consists of an anteromedial bundle (AMB) and a posterolateral bundle (PLB). A reconstruction restoring the functional two-bundled nature should be able to approximate normal ACL function better than the most commonly used single-bundle reconstructions. Accurate tunnel positioning is important, but difficult. The purpose of this study was to provide a geometric description of the centre of the attachments relative to arthroscopically visible landmarks. The AMB and PLB attachment sites in 35 dissected cadaver knees were measured with a 3D system, as were anatomical landmarks of femur and tibia. At the femur, the mean ACL centre is positioned 7.9 ± 1.4 mm (mean ± 1SD) shallow, along the notch roof, from the most lateral over-the-top position at the posterior edge of the intercondylar notch and from that point 4.0 ± 1.3 mm from the notch roof, low on the surface of the lateral condyle wall. The mean AMB centre is at 7.2 ± 1.8 and 1.4 ± 1.7 mm, and the mean PLB centre at 8.8 ± 1.6 and 6.7 ± 2.0 mm. At the tibia, the mean ACL centre is positioned 5.1 ± 1.7 mm lateral of the medial tibial spine and from that point 9.8 ± 2.1 mm anterior. The mean AMB centre is at 3.0 ± 1.6 and 9.4 ± 2.2 mm, and the mean PLB centre at 7.2 ± 1.8 and 10.1 ± 2.1 mm. The ACL attachment geometry is well defined relative to arthroscopically visible landmarks with respect to the AMB and PLB. With simple guidelines for the surgeon, the attachments centres can be found during arthroscopic single-bundle or double-bundle reconstructions.

Introduction

The anterior cruciate ligament (ACL) consists of two functional bundles [2, 4, 16]. The anteromedial bundle (AMB) originates anteroproximal in the intercondylar notch, close to the over-the-top position at the posterior edge of the notch, from the deep high part of the femoral attachment area and inserts anteromedial on the anterior intercondylar area of the tibia. The posterolateral bundle (PLB) originates more posteriorly and distally in the notch, from the shallow low part of the femoral attachment area and inserts posterolateral on the anterior intercondylar area of the tibia. The ACL reconstruction aims at restoring normal knee function. Most ACL replacements are performed with the isometric single-bundle technique. Isometric positioning of a single-bundle graft results in replacement of the AMB only. Although tensioned over the complete range of motion, the fibres are mostly tight in flexion. The AMB is the major constraint for anterior tibial displacement of the flexed knee [30], but cannot restore normal knee laxity and kinematics near extension [4, 28, 41]. In an effort to improve knee mechanics, double-bundle anatomic ACL reconstructions are now developed with reconstruction of both AMB and PLB [9, 10, 13, 19, 28, 35, 40, 46, 49, 50, 52, 53]. As presented in previous studies, a reconstructed PLB is able to restore stability in knee angles where an isometrically placed graft fails [28, 41, 50]. Additional restraint against anterior displacement in 15° of flexion [48] as well as prevention of the pivot shift is demonstrated [28, 50]. Therefore, a reconstruction with two bundles should be able to approximate normal ACL function over the complete range of motion [39, 41, 51]. Tunnel positioning is an important factor for clinical success of ACL reconstructions. Incorrect tibial [23] and femoral [29, 55] tunnel placements result in abnormal knee mechanics. Anatomical placement restores normal knee function better than isometric placement [36, 55]. However, accurate tunnel placement seems difficult. Misplacement between 25 and 65% of the tibial and femoral tunnels is reported [8, 27, 47]. Double-bundle ACL reconstructions require an anatomical placement of the bone tunnels. It is difficult to identify the ACL remnants in chronic ACL-injured knees. Therefore, detailed information about the approximate native position is essential to determine proper anatomic tunnel placement for the two bundles during arthroscopy [17]. The anatomical position has been the subject of many studies [3, 5, 12, 14–16, 20, 26, 33, 34, 37, 38, 44]. Only a few recent studies have described the anatomic positions of the AM and PL bundles [11, 32, 45, 52]. Due to the two-dimensional and limited view on the arthroscopic monitor, the landmarks and descriptions used in the above-mentioned studies seem not sufficient for correct positioning of the two separate bundles in all planes during arthroscopic surgery. This study is aimed at acquiring quantitative geometric data of the ACL attachments on tibia and femur, such that these data can be used in an arthroscopically guided procedure for reconstruction of the ACL. We hypothesized that reliable guidelines to find the centres of the AMB, PLB and ACL relative to arthroscopically visible landmarks can be established. For the purpose of an anatomically accurate reconstruction of the ACL, the variations should be equal to or less than reported in other studies. As regard to the dimensions of drilled tunnel holes, normally 10 up to 12 mm, 95% (mean ± 2SD) of the attachment centres should be within this range. Therefore the a priori set assumption is that the maximally acceptable SD is 2.5 up to 3 mm.

Methods

Dissection

Thirty-five intact human cadaveric knee joints of elderly donors preserved in formalin, without signs of gross bony deformity, previous fracture or degenerative disease and with intact knee ligaments were dissected. Because of local post-dissection handling procedures, no exact data on gender and age of the donors were available, but they were older than 60 years. The muscles and anterior capsule were removed. The ligaments were left intact in order to preserve controlled motion of the knee. The femur was fixated in a clamp, the tibia was moved, resulting in flexion and extension of the knee joint. During this repeated passive movement, the two functional components of the ACL were identified, based on a visually detectable difference in their tensioning patterns as described by Girgis et al. [16]. In 90° of flexion, an anterior load was manually applied. This caused tension in the fibres of the medial tibial attachment site, the AMB. The fibres of the PLB remained slack. This procedure enabled a separation of the two bundles at the tibial attachment from ventral. The femur was turned in the clamp to enable a posterior approach and the posterior cruciate ligament (PCL) was removed. In this position the initial division of the ACL at the tibial attachment was visible and used to extend the division towards the femoral origin. The tibia was moved towards extension. The PLB-fibres, inserting at the lateral femoral ACL attachment site, tightened, enabling to complete the separation as far as the femoral attachment. The outline contours of both AMB and PLB attachment areas were marked, with a waterproof felt pen.

Anatomical position

To quantify the position of the centres of the attachment sites relative to arthroscopically visible landmarks, three-dimensional (3D) measurements were made with a 3Space Fastrak electromagnetic tracking system (Polhemus Navigation Sciences, Colchester, VT, USA). The x, y and z co-ordinates of each measured point were recorded with an accuracy of 0.35 mm [42]. On the femur and tibia, the attachment sites of the AMB, PLB and the entire ACL were digitized by means of a collection of points placed at equal distances on the marked outlines. The 3D position of the centres of the ACL, AMB and PLB attachments were calculated by the geometric mean of all points on the outlines. The 3D distances between the centres of the two bundles were calculated. On both femur and tibia, an arthroscopically visible landmark was digitized that served as the origin of a local coordinate system. The absolute two-dimensional (2D) positions of the centres relative to these landmarks were calculated. The position in the third dimension was determined by the surface geometry of the femoral condyle and the intercondylar tibial area, respectively. Absolute positions can depend on different knee sizes and the dimensions of the femoral notch and the intercondylar tibial area. To correct for this, the relative centre positions were also calculated. Additional reference points near the attachment area on femur and tibia were digitized. Between these points two reference lines were defined to create a 2D coordinate system. The distances defined the dimensions of the femoral notch and intercondylar tibial area. Absolute centre positions were transformed in positions relative to the reference lines (%) within femur and tibia. To detect whether the absolute position of the attachment centres was actually influenced by knee size, statistical analyses were performed. The relation between absolute position and knee size can be demonstrated with a correlation coefficient. The Pearson's correlations between the distances of the absolute positions and the length of the reference lines, representing knee size, were calculated. Correlations with a Pearson's correlation coefficient r>0.6 and a significance level P<0.05, for a 95% alpha level were considered relevant and confirmed the relation between knee size and absolute centre position.

Femur

In the anatomical nomenclature the femoral ACL attachment uses anterior/posterior and proximal/distal positions, relative to the extended knee [17] (Figure 1a). Since this study aimed at describing the positions of the AMB and PLB of the femoral attachment from an arthroscopic perspective, the arthroscopic nomenclature was used as recommended by the ''ESSKA Scientific Workshops'' in 1998 [4]. The definitions, shallow/deep and high/low, refer to the position along the wall and from the roof of the intercondylar notch in a 90° flexed knee (Figure 1b). The digitized points on the femur are represented in Figure 2. The main femoral landmark was derived from the over-the-top position, located at the posterior edge of the intercondylar notch. The most proximal high deep point (D) on the lateral condyle was found at the 10.30 o'-clock position in the arc of the femoral notch, in a right knee (at 1.30 in a left knee) [17] (Figure 2). The circumferences of the ACL attachments were digitized, as was the additional reference point, the most distal high shallow point (S). This point is positioned on the distal cartilage edge of the lateral condyle in the anterior notch outlet (Figure 2a). The femoral coordinate system was defined with two reference lines (Figure 3). The first-defined femoral reference line (from D to S) divided the notch roof from the notch wall and defined the length of the lateral notch depth (ND). The lowest, dorsal point (L) on the posterior joint cartilage edge was found using a line parallel to the line DS. The second reference line (from L to H) was defined from point L perpendicular to crossing point H, high in the notch at the line DS. It indicated the magnitude of the notch height (NH). After creating this coordinate system, the calculated attachment centres (C) of the ACL, AMB and PLB were projected on the line DS at point P. The absolute centre position (mm) was composed of the distance between the main femoral landmark, the high deep point D and the point P and the distance between the point P and the centre C. The relative (%) position was calculated by dividing the distance DP by DS (notch depth) and distance CP by LH (notch height). Finally the individual results were displayed in a diagram to define the distribution of the centres relative to the means and the advised tunnel position.

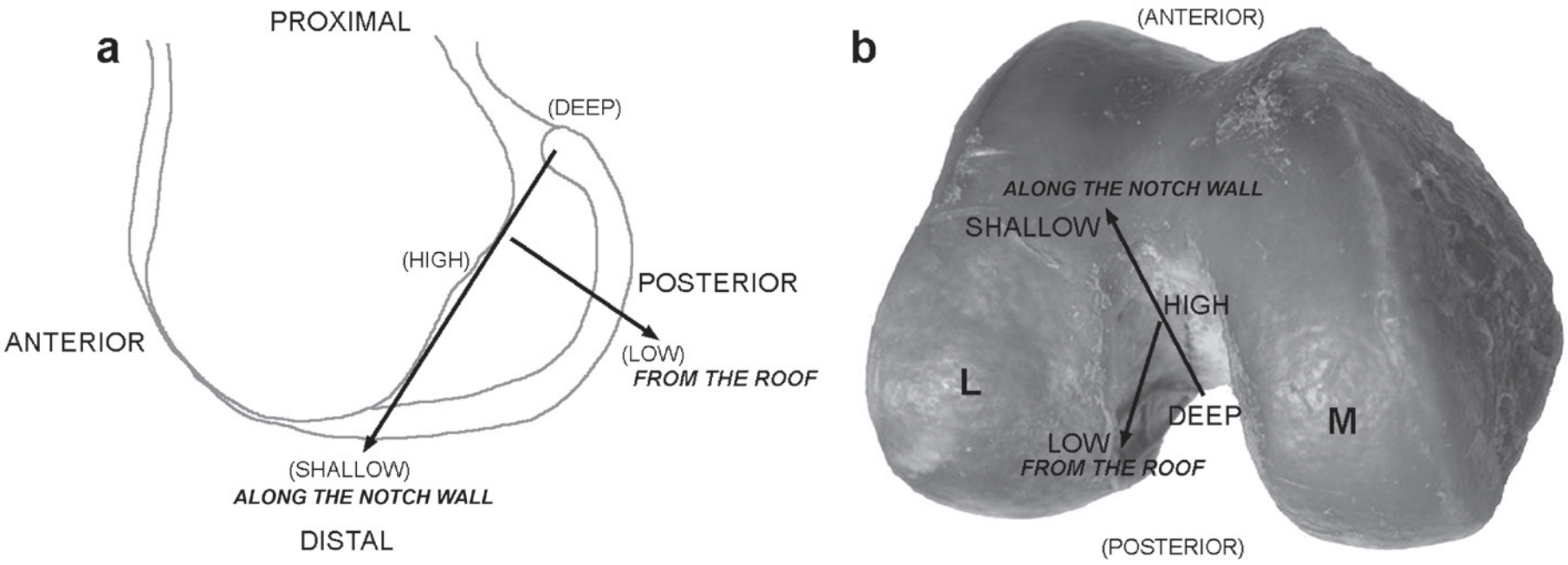

Figure 1. The orientation in the femoral notch, used in this study, is based on the recommendations of the ESKKA 1998 [4]. The notch depth (ND) is directed from shallow to deep in anatomic distal– proximal direction. The notch height (NH) is directed from low to high in anatomic dorsal–ventral direction. The notch wall is located at the medial side of the lateral condyle. The notch roof is the connection between the two condyles.

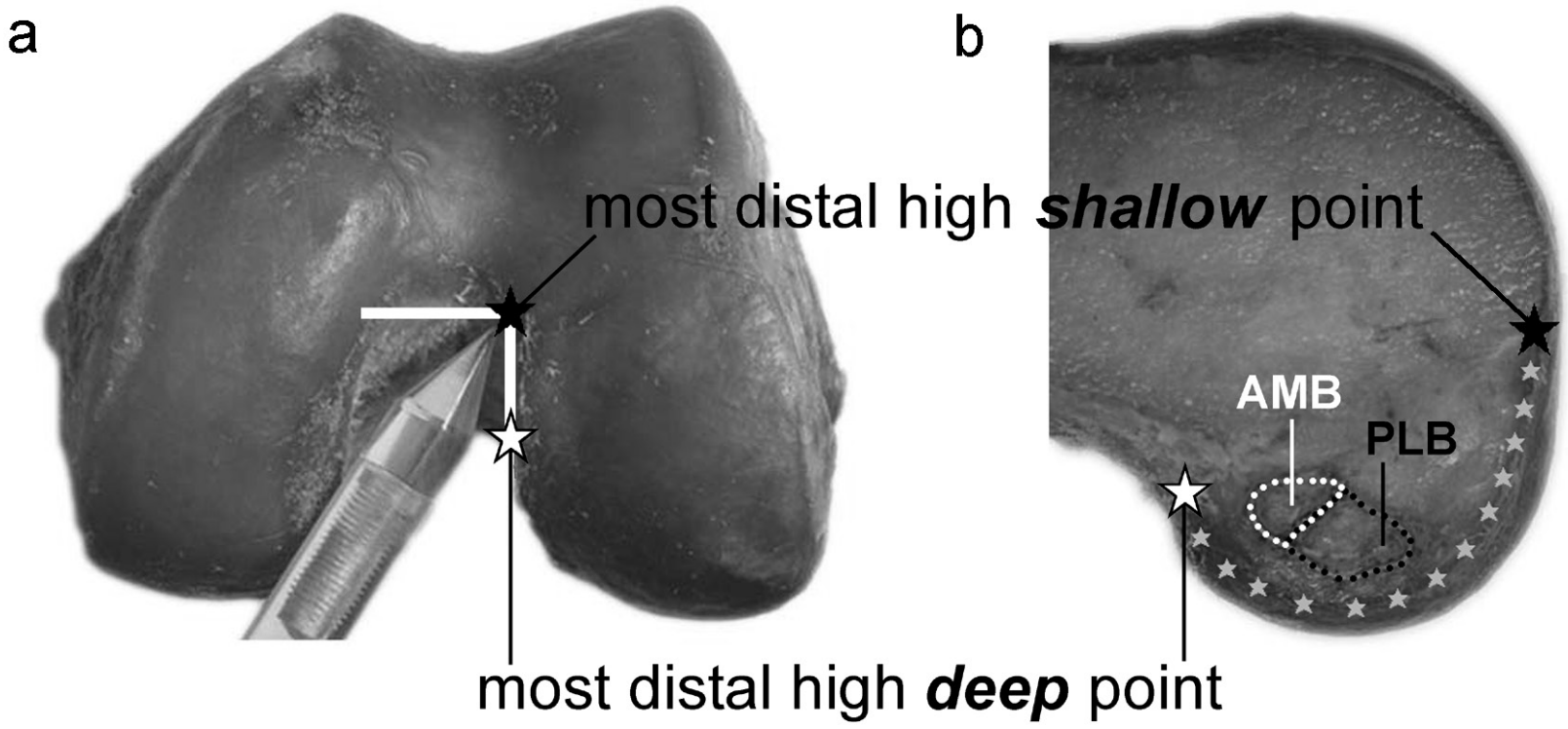

Figure 2. a) Distal view at a left femur. The high shallow and high deep points of the cartilage border were determined by placing the stylus at the point of an imaginary rectangular corner, indicating the separation between wall and roof, this corresponds with the 1.30 o'clock position in a left knee (10.30 o'clock in a right knee). b) View at the medial side of a left lateral femoral condyle. The points that were digitized: AMB (white rounds) and PLB (black rounds) attachments; the cartilage border (grey asterisks), with the most distal, high shallow point (black asterisk) and most proximal, high deep point (white asterisk) indicating the separation between the notch wall on the lateral condyle and the notch roof.

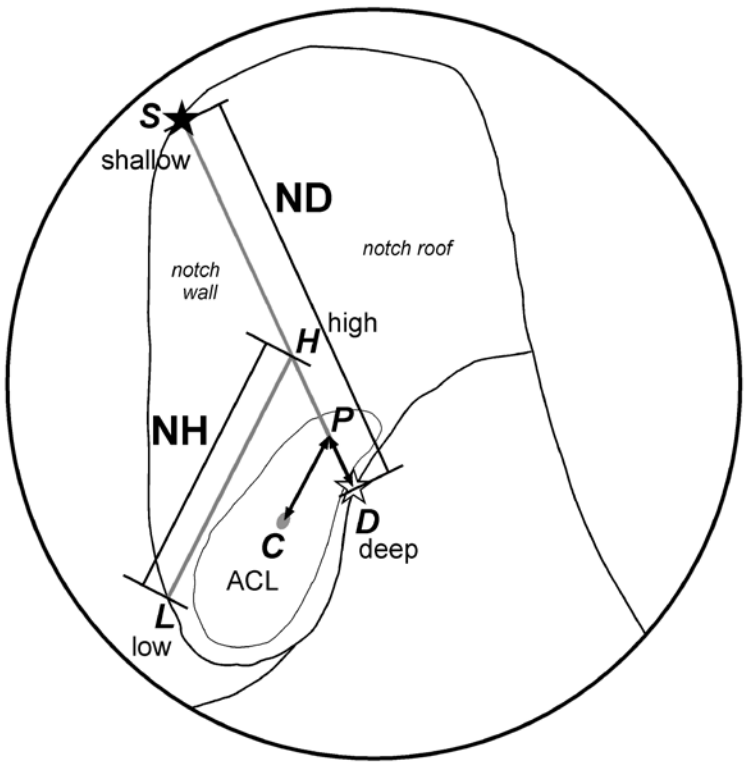

Figure 3. A schematic arthroscopic femoral view through the antero-medial portal. The femoral co-ordinate system is indicated. The first reference line, from the high deep point (D) to the high shallow point (S) on the cartilage edge separated the notch wall on the lateral condyle from the notch roof and defined the notch depth (ND). The second reference line, a perpendicular line, from the lowest point on the posterior cartilage edge (L) to the crossing point on the line DS (H) and defined the notch height (NH). The calculated attachment centre of the ACL (C) was projected on line DS (P). The absolute distances DP and CP were calculated, as were the distances relative to the reference lines (DP/DS and CP/LH). This was also done for the AMB and PLB, for the sake of clearness, only the centre of the entire ACL is depicted.

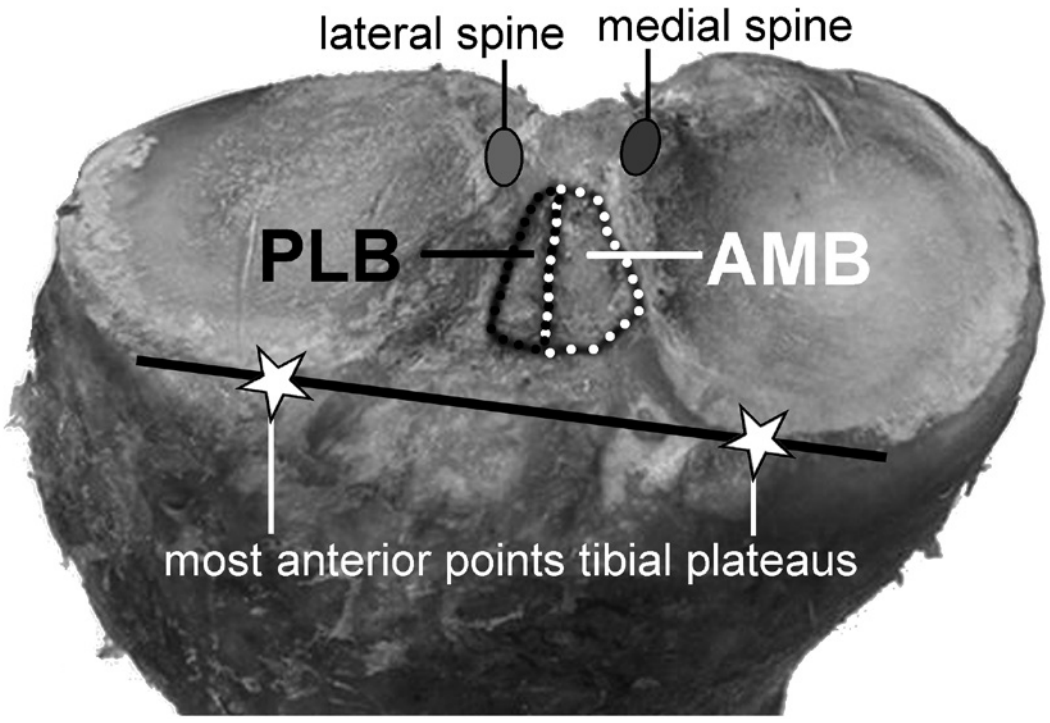

Figure 4. Proximal view at the articular surfaces of the tibial condyles and the anterior intercondylar area. The points that were digitized: AMB (white rounds) and PLB (black rounds) attachments; the lateral tibial spine (light grey oval) and medial tibial spine (dark grey oval) and the most anterior points on the margin of the articular surface of the medial and lateral tibial condyles (white asterisks).

Tibia

The digitized points on the tibia are represented in Figure 4. The medial tibial spine (M) was determined as the main tibial landmark. The circumferences of the ACL attachments were digitized, as were the additional reference points. Those were, besides the lateral tibial spine (L), the most anterior points on the margin of the articular surfaces of the medial tibial condyle (MA) and lateral tibial condyle (LA). The tibial coordinate system was defined as follows (Figure 5). The first tibial reference line (from M to L) was defined between the medial and the lateral tibial spine representing the interspinal distance (ID).

A line connecting the anterior points MA and LA indicated the anterior margin of the articular surface of the medial and lateral condyles of the tibia. The second reference line (from M to Q) connected the medial spine (M) perpendicular with the anterior margin at crossing point Q. The length of the second reference line represents the length of the anterior intercondylar area (AL). After creating this coordinate system, the calculated attachment centres of the ACL, AMB and PLB were projected on the line ML at point P. The absolute centre position (mm) was composed of the distance between the major tibial landmark, the medial tibial spine M and the point P, and the distance between the point P and the centre C. The relative position (%) was calculated by dividing the distance MP by ML (interspinal distance) and distance CP by MQ (anterior length). Finally the individual results were displayed in a diagram to define the distribution of the centres relative to the means and the advised tunnel position.

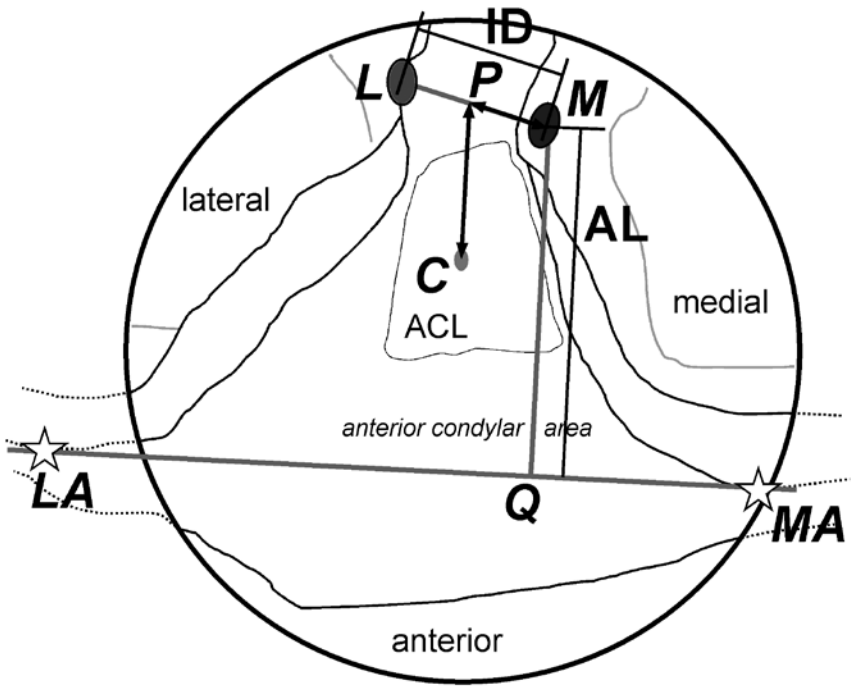

Figure 5. A schematic arthroscopic tibial view. The tibial coordinate system is indicated. The first reference line, from the medial spine (M) to the lateral spine (L), defined the interspinal distance (ID). The second reference line, from the medial spine (M) perpendicular to the crossing point (Q) at the anterior line between the most anterior points on the margin of the articular surface of the medial and lateral tibial condyles defined the anterior intercondylar length (AL). The calculated attachment centre (C) was projected on line ML (P). The absolute distances MP and CP were calculated, as were the distances relative to the reference lines (MP/ML and CP/MQ). This was also done for the AMB and PLB, for the sake of clearness, only the centre of the entire ACL is depicted.

Surface

To determine the surface dimensions of the bony attachment areas, a line was fitted through the digitized points on the outlines of both the AMB and PLB attachments on femur and on the tibia. The enclosed surface of all areas was calculated (in mm^2), with the aid of a Delaunay triangulation based on the Qhull algorithm as provided by Matlab1 (version 7 The MathWorks, Inc., more details provided on www.mathworks.com). The surface of the entire ACL attachment was calculated as the sum of AMB and PLB. Also the percentage of AMB and PLB surfaces was calculated relative to the ACL attachment surface. Statistical analyses to detect differences in size of the attachment surfaces were performed. Femoral AMB and femoral PLB, tibial AMB and tibial PLB and finally femoral ACL and tibial ACL were compared. A 2-tailed Student's t test for paired data was used. Statistical significance was defined as $P<0.05$, for a 95% alpha level.

Results

Femur

The oval-shaped attachment of the anterior cruciate ligament was situated on the medial surface of the lateral femoral condyle. It was positioned deep in the notch, covering most of the proximal half of the wall. The fibres of the deep low border attached to the edge of the joint cartilage, following the contour of this edge posteriorly on the condyle. In only 4 of the 35 specimens, the attachment site was completely limited to the medial wall of the lateral condyle and had no footprint in the notch roof. In 31 femurs, a small part of the deep high AMB attachment extended into the intercondylar notch roof. The notch depth (DS = 31.8 ± 2.6 mm) was the largest distance of the femoral dimensions. On average it was 2¼ times the length of the notch height (LH = 14.3 ± 1.5 mm). In shallow–deep direction measured along the notch, relative to the notch depth, the centres of the two bundles were more close to each other, than in high–low direction measured from the roof, relative to the notch height. The mean position of all AMB centres along the roofline of the notch was 7.2 mm shallow from the high deep corner at ¼ of the ND-line (Table 1; Figure 6). In 9 of the 35 femurs the centre of the AMB was not situated on the condyle wall, but above the transition line on the notch roof. Therefore, the average centre was high in the notch at 1/10 of the NH-line, 1.4 mm from the roof. The centre of the PLB was positioned slightly more shallow at less than 2 mm from the AMB (Table 1; Figure 6).

Table 1. The positions of the ligament centres in the femoral notch

	Absolute distances (mm) mean (SD)		Relative distances (%) mean (SD)	
	DP	CP	DP/DS	CP/LH
AMB	7.2 (1.8)	1.4 (1.7)	23 (6)	10 (12)
PLB	8.8 (1.6)	6.7 (2.0)	28 (6)	47 (13)
ACL	7.9 (1.4)	4.0 (1.3)	25 (5)	28 (9)

DP The absolute distance from the high deep point D until point P, the projection of the mean ligament centre at the DS-line, in the notch depth direction; CP the absolute distance from the mean ligament centre until point P at the LH-line, in notch height direction; DP/DS The relative position of the centre to the notch depth; CP/LH The relative position of the centre to the notch height

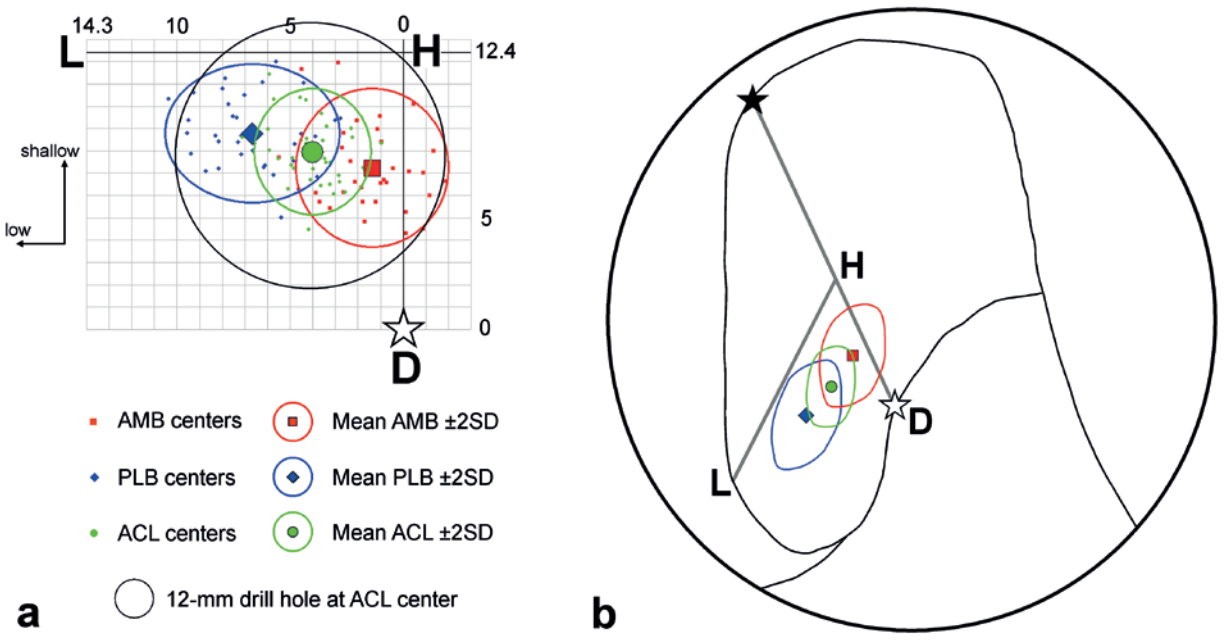

Figure 6. a) A two-dimensional graph of the medial side of a right lateral femoral condyle with the individual centres, and the mean centres with the 95% Confidence Interval of the AMB (red squares), PLB (blue diamonds) and ACL (green dots). The position of a 12 mm drill hole at the ACL centre is also displayed. b) A schematic arthroscopic view through the anteromedial portal with the mean centres and the 95% Confidence Interval areas of the AMB (red square with line), PLB (blue diamond with line) and ACL (green dot with line).

Table 2. The surface dimensions of the ACL and the two bundles at femur and tibia

	Absolute surface area (mm) mean (SD)			Relative surface to total ACL (%) mean (SD)	
	ACL	**AMB**	**PLB**	**AMB**	**PLB**
Femur	184 (52)	81 (27)	103 (39)	45 (11)	55 (11)
Tibia	229 (53)	136 (37)	93 (33)	59 (9)	41 (9)

However, it was situated clearly lower, about 5 mm, on the femoral condyle wall, approximately halfway the notch height. The centre position of the entire ACL was in the middle between the AMB and the PLB at ¼ of both reference lines. Approximately 96% of the mean centres were inside a 12 mm drill hole, if positioned at the mean centre of the ACL attachment. The Pearson's correlation coefficients between the absolute positions and the reference lines were smaller than 0.3 and not significant (P>0.05). The mean centres of the AMB and PLB were situated 6.2 ± 1.2 mm from each other. The AMB attachment area, 45% of the total ACL, was significantly (P = 0.005) smaller than the PLB attachment area (Table 2).

Tibia

The tibial attachment area of the ACL was situated between the medial and lateral tibial condyle covering the medial part of the anterior intercondylar area. It was stretched out from the region between the tibial spines to anterior with various extensions, more or less shaped as a footprint. The fibres of the AMB inserted medially along the cartilage edge of the articular surface of the medial tibial condyle. The PLB covered the lateral side of the attachment area and was bounded by the attachment of the anterior horn of the lateral meniscus. The interspinal distance (ML = 12.9 ± 1.6 mm) between the medial and the lateral spine was on the average half times the length of the anterior intercondylar area (MQ = 24.8 ± 2.7 mm). The average centre of the AMB was situated closest to the medial spine, lateral at ¼ of the ID. The PLB was 4 mm more lateral, approximately halfway between the medial and lateral spine (Table 3; Figure 7).

Table 3. The positions of the ligament centres at the anterior intercondylar tibial area

	Absolute distances (mm) mean (SD)		Relative distances (%) mean (SD)	
	MP	**CP**	**MP/ML**	**CP/MQ**
AMB	3.0 (1.6)	9.4 (2.2)	23 (12)	37 (9)
PLB	7.2 (1.8)	10.1 (2.1)	55 (13)	38 (9)
ACL	5.1 (1.7)	9.8 (2.1)	39 (12)	38 (8)

MP The absolute distance from the medial spine (M) until the point P, the projection of the mean ligament centre at the line ML in lateral direction; CP the absolute distance from the mean ligament centre until point P on the line ML, in anterior direction; MP/ML The relative position of the centre to the interspinal distance; CP/MQ The relative position of the centre to the anterior length

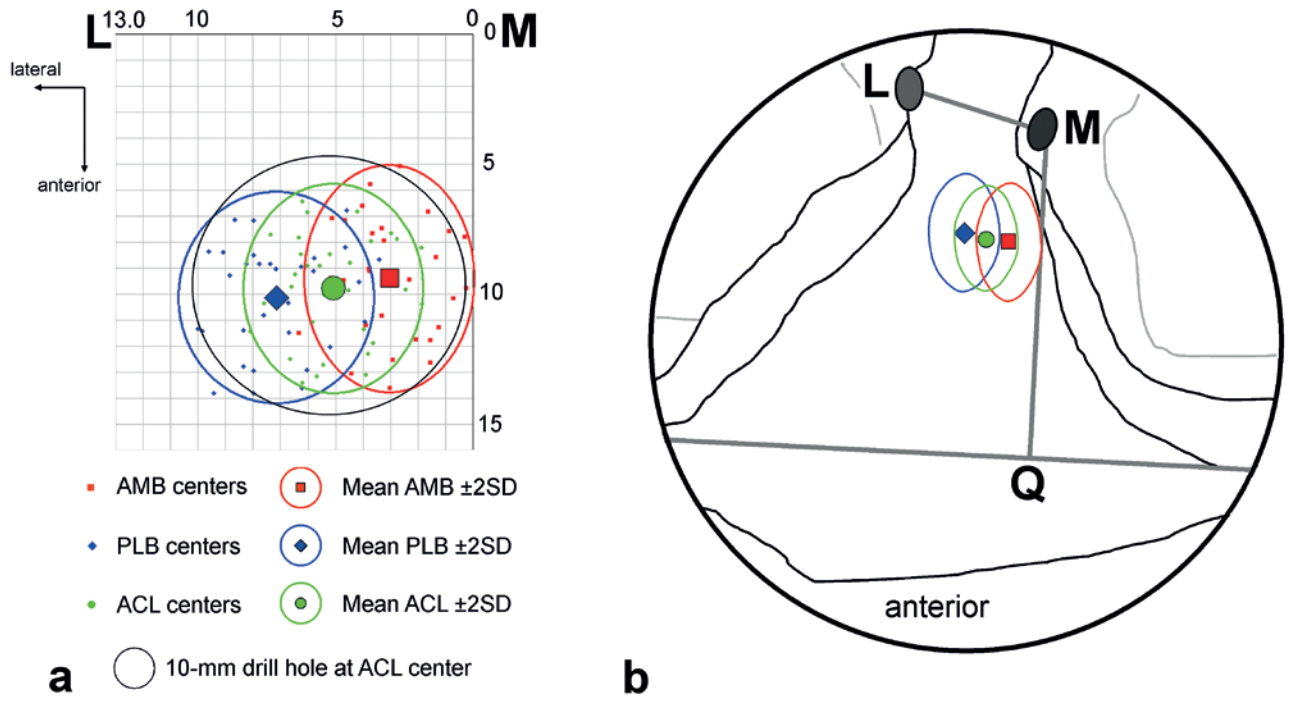

Figure 7. a) A two-dimensional graph of a right anterior intercondylar tibial area with the individual centres, and the mean centres with the 95% Confidence Interval of the AMB (red squares), PLB (blue diamonds) and ACL (green dots). The position of a 10 mm drill hole at the ACL centre is also displayed. b) A schematic arthroscopic view with the mean centres and the 95% Confidence Interval areas of the AMB (red square with line), PLB (blue diamond with line) and ACL (green dot with line)

The ACL was in between at 2/5 of the ID. In anterior direction the AMB, ACL and PLB were close to each other, just over 1/3 of the anterior length. Approximately 94% of the mean centres were inside a 10 mm drill hole, if positioned at the mean centre of the ACL attachment (Table 3; Figure 7). The Pearson's correlations coefficients between the absolute positions and the interspinal distance (reference line ML) were smaller than 0.3 and not significant($P>0.05$). The Pearson's correlations coefficients between the absolute positions and the anterior length (reference line MQ) were significant ($P<0.05$), however smaller than 0.6. The mean centres of the AMB and PLB were situated 4.5 ± 0.1 mm from each other. The tibial AMB attachment area of 59% was significantly larger than the PLB attachment area ($P<0.001$). The tibial attachment area of the ACL and of the AMB was significantly larger than on the femur ($P<0.001$) (Table 2).

Discussion

Incorrect tunnel placement, tibial [22, 25] as well as femoral [43], is seen as one of the most important causes of clinical failure in single-bundle ACL reconstructions [1]. In double-bundle ACL reconstruction, exact anatomic tunnel placement seems to be even more essential. Two bundles must be accurately placed relative to the surrounding structures and relative to each other. Although exact tunnel positioning is important, it seems difficult, even for experienced surgeons [8, 27, 47]. A clear description of the anatomic centres with guidelines to determine the correct tunnel position during arthroscopic procedures can improve the accuracy. The femoral positions of the two distinct bundles found in this study, the AMB deep high and the PLB shallow low in the notch, are broadly in line with literature [11, 20, 32, 45, 52]. Compared to others, the landmarks that are used in the present study are more easy to locate during arthroscopy. Harner et al. [20] quantified the cross-sectional shape and area of the femoral and tibial attachments of both components in 10 knees without describing the positions relative to landmarks. Yasuda et al. [52] limit their study to the femoral attachment, using five specimens. They describe the centre of the PLB 5 to 8 mm anterior to the edge of the joint cartilage, on the vertical line through the contact point between the femoral condyle and the tibial plateau in a 90 flexed knee. Because this point depends on the position of the knee, it can be difficult to locate accurately during an arthroscopic procedure. Colombet et al. [11] examined seven specimens, collecting especially data of the attachment dimensions. The femoral results presented by the studies of Mochizuki et al. [32] and Takahashi et al. [45] are more suitable for practical use during arthroscopy; however, no exactly defined landmarks were used. The tibial results of Takahashi et al. [45] cannot easily be transferred to the arthroscopic situation. Finally, above-mentioned studies did not present the centres of the ACL attachment. Tunnel positioning in the femoral notch is often determined by the 'clock' method [13, 18, 35, 36, 52, 54]. However, this only determines the high–low position from the roof, in the transversal plane along the arc of the femoral notch [17, 54]. The accuracy in the sagittal plane, deep–shallow along the roof of the notch, seems to affect the functional outcome more [17, 21, 29, 55, 56]. This position is often determined with a femoral guide placed behind the posterior edge of the intercondylar notch, at the over-the-top position, not to be confused with the Resident's ridge [24]. This seems sufficiently accurate for determining the AMB centre, when a guide with a 7 mm offset is placed in the 10.30 or 1.30 o'clock position. The 7 mm offset of the guide places the tunnel in the sagittal plane close to the AMB centre position, found in this study, i.e. 7.2 mm shallow along the roof. Although we did not translate the measured distance in a clock position, the 10.30 clock position seems close to the measured position in the transversal plane, 1.4 mm low from the roof on the condyle wall. This corresponds with the results of Mochizuki et al. [32] and Yasuda et al. [52]. However, the clock method is sensitive to subjective interpretation of positioning the face of the clock [7]. It is not sufficient to find the correct position for the PLB, especially in the sagittal plane. Therefore Colombet et al. [11] defined an extra guideline to position the PLB tunnel: 8 mm lower and 'shallower' relative to the AMB centre, found with the clock method. The present study is more precise: 1.3 mm more shallow along the notch and 5.3 mm lower from the roof on the condyle wall, relative to the above-described position of the AMB centre. These positions can best be approached through an anteromedial arthroscopic portal [6]. Various methods can be used to determine the correct drill hole position at the tibia. Some authors prefer placement of the tibial tunnel based on avoiding graft impingement against the roof of the femoral notch with knee extension [22, 34, 44]. Others prefer guides that use the posterior cruciate ligament (PCL) attachment as reference point [31]. Based on these methods, positioning in anteroposterior direction, the sagittal plane, is defined. However, placement of the tunnel in mediolateral direction, the transversal plane, which is also important [26], is not determined. Some studies describe the mediolateral position, relative to the width of the tibial plateau [23, 45]. However, this guideline cannot be used during an arthroscopic procedure. The results of this study can be used for arthroscopic positioning in both directions. The division of the AMB and PLB on the tibia in anteroposterior direction is similar to Harner et al. [20], resulting in a medial AMB and lateral PLB. This deviates only marginally from other definitions, where the division is in an anteromedial and a posterolateral part [3, 16, 38]. The position of the centres in anteroposterior direction correspond with the results of Takahashi et al. [45], who used similar reference points to define the anterior margin of the articular surface of the tibial condyles. The centres of the two bundles were more close to each other on the tibia, than on the femur. The size of the femoral ACL attachment 184 ± 52 mm2 was similar to the result of Odensten and Gillquist (200 mm2) [38]. Other studies found smaller attachment areas, 132 mm2 [45] and 113 mm2 [20]. This difference may be caused by a different measuring method, using the largest projection in a 2D image plane. Our study measured the actual three-dimensional attachment area. The partition of the femoral attachment area was nearly equal with 5%, 55%, respectively, for the AMB and PLB. This was comparable to Harner et al. [20] (AMB = 52%, PLB = 48%) and Takahashi et al. [45] (AMB = 50%, PLB = 50%). The average tibial attachment area found in this study was larger than the femoral attachment. This is in line with the results of Girgis et al. [16] and Fuss et al. [15]. On the other hand, Takahashi et al. [45] found that the femoral attachment was larger than the tibial attachment (132 vs 119 mm2). Harner et al. [20] and Odensten and Gillquist [38] found similar sizes for the tibial and femoral attachment areas. In our study the AMB occupied 59% of the tibial attachment, nearly similar to the 57% of Takahashi et al. [45], slightly more than the 52% Harner et al. [20] found. There was a large variation in knee sizes and dimensions of the reference lines. However, we did not find a correlation between the absolute distance of the attachment centres and the size of the reference lines, i.e. knee size. The absolute positions of the attachment centres were more or less similar for large and small knees. Therefore both absolute as well as relative data can be used as guidelines to find the anatomical positions. At the arthroscopic view, the absolute positions are more useful than the relative positions. As regards to the dimensions of drilled tunnel holes (10–12 mm), the standard deviations of the attachment centres within 3 mm are acceptable. The femoral positions had less variations than the tibial positions. The positions for the entire ACL attachment had less variations than the attachment positions for the separate bundles. The results of this study seem to produce accurate guidelines to find the anatomic tunnel position during arthroscopic reconstruction. However, some limitations must be mentioned. The subdivision of the ACL in AMB and PLB is not based on anatomically distinct fibre bundles surrounded with fibrous issue [5, 15, 33, 38]. Fibres of both bundles are twisted around each other [33]. Division of the ACL in separate bundles is not easy [3]. Therefore utmost care was taken to divide the two functional bundles according to a previously described method [11, 20]. The method, based on observed tension variation during passive flexion–extension movement was reported to be consistent [32]. This is expressed in the standard deviations (SD) of the mean attachment centres. The variation of the population is expressed by the SD of the ACL centre. The SD of the mean PLB and mean AMB centres show this variation combined with the division error. For the tibia the SDs of the PLB and AMB attachment centres are equal to that of the ACL. For the femur the SDs of the two bundle centres are slightly larger. However, these results do not point to large errors in the identification of the two bundles. The variations of attachment centre positions are actually rather small and similar to other studies [11, 45]. The age of the cadaveric knee specimens was more than 60 years. However, only knees without severe arthritic signs were evaluated. It seems likely that the data can be transferred to the, mostly younger, population receiving an ACL reconstruction [3, 11, 34, 44]. Perfusion fixation preserves the outer contours of shapes i.e. ligament bundles, so neither the identification nor the measurements of the various bundles can be assumed to have been hampered by the fixation.

Conclusions

This study was performed because no earlier study described the ACL, AMB and PLB attachment centres relative to arthroscopically visible landmarks. This resulted in quantitative data of the positions of the attachment centres of the ACL and its two bundles, relative to bony landmarks on femur and tibia, visible through an arthroscope. Using these results, the surgeon will be able to determine the anatomical position of the ACL and the two functional bundles during arthroscopy without additional images or fluoroscopic support. The results can be applied for anatomic single-bundle or anatomic double-bundle techniques.

Acknowledgments The authors would like to thank Willem van de Wijdeven, Huub Peeters and Bart Nienhuis for their contributions to this work. This study was funded by grant 99-W14 from the AO Research Fund, Association for Osteosynthesis Foundation, Switzerland.

References

1. Aglietti P, Buzzi R, Giron F, Simeone AJ, Zaccherotti G (1997) Arthroscopic-assisted anterior cruciate ligament reconstruction with the central third patellar tendon. A 5–8-year follow-up. Knee Surg Sports Traumatol Arthrosc 5(3):138–144.
2. Amis AA, Beynnon B, Blankevoort L, Chambat P, Christel P, Durselen L, Friederich N, Grood E, Hertel P, Jakob R (1994) Proceedings of the ESSKA Scientific Workshop on Reconstruction of the Anterior and Posterior Cruciate Ligaments. Knee Surg Sports Traumatol Arthrosc 2(3):124–132.
3. Amis AA, Dawkins GP (1991) Functional anatomy of the anterior cruciate ligament. Fibre bundle actions related to ligament replacements and injuries. J Bone Joint Surg Br 73(2):260–267.
4. Amis AA, Jakob RP (1998) Anterior cruciate ligament graft positioning, tensioning and twisting. Knee Surg Sports Traumatol Arthrosc 6(Suppl 1):S2–S12.
5. Arnoczky SP (1983) Anatomy of the anterior cruciate ligament. Clin Orthop 172:19–25.
6. Arnold MP, Kooloos J, Van Kampen (2001) Single-incision technique misses the anatomical femoral anterior cruciate ligament insertion: a cadaver study. Knee Surg Sports Traumatol Arthrosc 9(4):194–199.
7. Arnold MP, Verdonschot N, Van Kampen (2005) ACL graft can replicate the normal ligament's tension curve. Knee Surg Sports Traumatol Arthrosc 13(8):625–631.
8. Behrend H, Stutz G, Kessler MA, Rukavina A, Giesinger K, Kuster MS (2006) Tunnel placement in anterior cruciate ligament (ACL) reconstruction: quality control in a teaching hospital. Knee Surg Sports Traumatol Arthrosc 14(11):1159–1165.
9. Bellier G, Christel P, Colombet P, Djian P, Franceschi JP, Sbihi A (2004) Double-stranded hamstring graft for anterior cruciate ligament reconstruction. Arthroscopy 20(8):890–894.
10. Buoncristiani AM, Tjoumakaris FP, Starman JS, Ferretti M, Fu FH (2006) Anatomic double-bundle anterior cruciate ligament reconstruction. Arthroscopy 22(9):1000–1006.
11. Colombet P, Robinson J, Christel P, Franceschi JP, Djian P, Bellier G, Sbihi A (2006) Morphology of anterior cruciate ligament attachments for anatomic reconstruction: a cadaveric dissection and radiographic study. Arthroscopy 22(9):984–992.
12. Dodds JA, Arnoczky SP (1994) Anatomy of the anterior cruciate ligament: a blueprint for repair and reconstruction. Arthroscopy 10(2):132–139.
13. Franceschi JP, Sbihi A, Champsaur P (2002) [Arthroscopic reconstruction of the anterior cruciate ligament using double anteromedial and posterolateral bundles]. Rev Chir Orthop Reparatrice Appar Mot 88(7):691–697.
14. Fu FH, Harner CD, Johnson DL, Miller MD, Woo SL (1994) Biomechanics of knee ligaments: basic concepts and clinical application. Instr Course Lect 43:137–148.
15. Fuss FK (1989) Anatomy of the cruciate ligaments and their function in extension and flexion of the human knee joint. Am J Anat 184(2):165–176.
16. Girgis FG, Marshall JL, Monajem A (1975) The cruciate ligaments of the knee joint. Anatomical, functional and experimental analysis. Clin Orthop 106:216–231.
17. Giron F, Cuomo P, Aglietti P, Bull AM, Amis AA (2006) Femoral attachment of the anterior cruciate ligament. Knee Surg Sports Traumatol Arthrosc 14(3):250–256.
18. Hamada M, Shino K, Horibe S, Mitsuoka T, Miyama T, Shiozaki Y, Mae T (2001) Single- versus bi-socket anterior cruciate ligament reconstruction using autogenous multiple-stranded hamstring tendons with endoButton femo-

ral fixation: a prospective study. Arthroscopy 17(8):801–807.
19. Hara K, Kubo T, Suginoshita T, Shimizu C, Hirasawa Y (2000) Reconstruction of the anterior cruciate ligament using a double bundle. Arthroscopy 16(8):860–864.
20. Harner CD, Baek GH, Vogrin TM, Carlin GJ, Kashiwaguchi S, Woo SL (1999) Quantitative analysis of human cruciate ligament insertions. Arthroscopy 15(7):741–749.
21. Hefzy MS, Grood ES, Noyes FR (1989) Factors affecting the region of most isometric femoral attachments. Part II The anterior cruciate ligament. Am J Sports Med 17(2):208–216.
22. Howell SM, Clark JA (1992) Tibial tunnel placement in anterior cruciate ligament reconstructions and graft impingement. Clin Orthop 283:187–195.
23. Howell SM, Wallace MP, Hull ML, Deutsch ML (1999) Evaluation of the single-incision arthroscopic technique for anterior cruciate ligament replacement. A study of tibial tunnel placement, intraoperative graft tension, and stability. Am J Sports Med 27(3):284–293.
24. Hutchinson MR, Ash SA (2003) Resident’s ridge: assessing the cortical thickness of the lateral wall and roof of the intercondylar notch. Arthroscopy 19(9):931–935.
25. Ikeda H, Muneta T, Niga S, Hoshino A, Asahina S, Yamamoto H (1999) The long-term effects of tibial drill hole position on the outcome of anterior cruciate ligament reconstruction. Arthroscopy 15(3):287–291.
26. Jackson DW, Gasser SI (1994) Tibial tunnel placement in ACL reconstruction. Arthroscopy 10(2):124–131.
27. Kohn D, Busche T, Carls J (1998) Drill hole position in endoscopic anterior cruciate ligament reconstruction. Results of an advanced arthroscopy course. Knee Surg Sports Traumatol Arthrosc 6(Suppl 1):S13–S15.
28. Loh JC, Fukuda Y, Tsuda E, Steadman RJ, Fu FH, Woo SL (2003) Knee stability and graft function following anterior cruciate ligament reconstruction: comparison between 11 o’clock and 10 o’clock femoral tunnel placement. Arthroscopy 19(3):297–304.
29. Markolf KL, Hame S, Hunter DM, Oakes DA, Zoric B, Gause P, Finerman GA (2002) Effects of femoral tunnel placement on knee laxity and forces in an anterior cruciate ligament graft. J Orthop Res 20(5):1016–1024.
30. Marshall JL, Wang JB, Furman W, Girgis FG, Warren R (1975) The anterior drawer sign: what is it? J Sports Med 3(4):152–158.
31. McGuire DA, Hendricks SD, Sanders HM (1997) The relationship between anterior cruciate ligament reconstruction tibial tunnel location and the anterior aspect of the posterior cruciate ligament insertion. Arthroscopy 13(4):465–473.
32. Mochizuki T, Muneta T, Nagase T, Shirasawa S, Akita KI, Sekiya I (2006) Cadaveric knee observation study for describing anatomic femoral tunnel placement for two-bundle anterior cruciate ligament reconstruction. Arthroscopy 22(4):356–361.
33. Mommersteeg TJ, Kooloos JG, Blankevoort L, Kauer JM, Huiskes R, Roeling FQ (1995) The fibre bundle anatomy of human cruciate ligaments. J Anat 187(Pt 2):461–471.
34. Morgan CD, Kalman VR, Grawl DM (1995) Definitive landmarks for reproducible tibial tunnel placement in anterior cruciate ligament reconstruction. Arthroscopy 11(3):275–288.
35. Muneta T, Sekiya I, Yagishita K, Ogiuchi T, Yamamoto H, Shinomiya K (1999) Two-bundle reconstruction of the anterior cruciate ligament using semitendinosus tendon with endobuttons: operative technique and preliminary results. Arthroscopy 15(6):618–624.
36. Musahl V, Plakseychuk A, VanScyoc A, Sasaki T, Debski RE, McMahon PJ, Fu FH (2005) Varying femoral tunnels between the anatomical footprint and isometric positions: effect on kinematics of the anterior cruciate ligament-reconstructed knee. Am J Sports Med 33(5):712–718.
37. Norwood LA, Cross MJ (1979) Anterior cruciate ligament: functional anatomy of its bundles in rotatory instabilities. Am J Sports Med 7(1):23–26.
38. Odensten M, Gillquist J (1985) Functional anatomy of the anterior cruciate ligament and a rationale for reconstruction. J Bone Joint Surg Am 67(2):257–262.

39. Papachristou G, Tilentzoglou A, Efstathopoulos N, Khaldi L (1998) Reconstruction of anterior cruciate ligament using the doubled tendon graft technique: an experimental study in rabbits. Knee Surg Sports Traumatol Arthrosc 6(4):246–252.
40. Pederzini L, Adriani E, Botticella C, Tosi M (2000) Technical note: double tibial tunnel using quadriceps tendon in anterior cruciate ligament reconstruction. Arthroscopy 16(5):E9.
41. Radford WJ, Amis AA (1990) Biomechanics of a double prosthetic ligament in the anterior cruciate deficient knee. J Bone Joint Surg Br 72(6):1038–1043.
42. Sidles JA, Larson RV, Garbini JL, Downey DJ, Matsen FA III (1988) Ligament length relationships in the moving knee. J Orthop Res 6(4):593–610.
43. Sommer C, Friederich NF, Muller W (2000) Improperly placed anterior cruciate ligament grafts: correlation between radiological parameters and clinical results. Knee Surg Sports Traumatol Arthrosc 8(4):207–213.
44. Staubli HU, Rauschning W (1994) Tibial attachment area of the anterior cruciate ligament in the extended knee position. Anatomy and cryosections in vitro complemented by magnetic resonance arthrography in vivo. Knee Surg Sports Traumatol Arthrosc 2(3):138–146.
45. Takahashi M, Doi M, Abe M, Suzuki D, Nagano A (2006) Anatomical study of the femoral and tibial insertions of the anteromedial and posterolateral bundles of human anterior cruciate ligament. Am J Sports Med 34(5):787–792.
46. Takeuchi R, Saito T, Mituhashi S, Suzuki E, Yamada I, Koshino T (2002) Double-bundle anatomic anterior cruciate ligament reconstruction using bone-hamstring-bone composite graft. Arthroscopy 18(5):550–555.
47. Topliss C, Webb J (2001) An audit of tunnel position in anterior cruciate ligament reconstruction. Knee 8(1):59–63.
48. Torg JS, Conrad W, Kalen V (1976) Clinical diagnosis of anterior cruciate ligament instability in the athlete. Am J Sports Med 4(2):84–93.
49. Yagi M, Kuroda R, Nagamune K, Yoshiya S, Kurosaka M (2007) Double-bundle ACL reconstruction can improve rotational stability. Clin Orthop Relat Res 454:100–107.
50. Yagi M, Wong EK, Kanamori A, Debski RE, Fu FH, Woo SL (2002) Biomechanical analysis of an anatomic anterior cruciate ligament reconstruction. Am J Sports Med 30(5):660–666.
51. Yamamoto Y, Hsu WH, Woo SL, Van Scyoc AH, Takakura Y, Debski RE (2004) Knee stability and graft function after anterior cruciate ligament reconstruction: a comparison of a lateral and an anatomical femoral tunnel placement. Am J Sports Med 32(8):1825–1832.
52. Yasuda K, Kondo E, Ichiyama H, Kitamura N, Tanabe Y, Tohyama H, Minami A (2004) Anatomic reconstruction of the anteromedial and posterolateral bundles of the anterior cruciate ligament using hamstring tendon grafts. Arthroscopy 20(10):1015–1025.
53. Yasuda K, Kondo E, Ichiyama H, Tanabe Y, Tohyama H (2006) Clinical evaluation of anatomic double-bundle anterior cruciate ligament reconstruction procedure using hamstring tendon grafts: comparisons among 3 different procedures. Arthroscopy 22(3):240–251.
54. Zantop T, Petersen W, Sekiya JK, Musahl V, Fu FH (2006) Anterior cruciate ligament anatomy and function relating to anatomical reconstruction. Knee Surg Sports Traumatol Arthrosc 14(10):982–992.
55. Zavras TD, Race A, Amis AA (2005) The effect of femoral attachment location on anterior cruciate ligament reconstruction: graft tension patterns and restoration of normal anterior–posterior laxity patterns. Knee Surg Sports Traumatol Arthrosc 13(2):92–100.
56. Zavras TD, Race A, Bull AM, Amis AA (2001) A comparative study of ‘isometric’ points for anterior cruciate ligament graft attachment. Knee Surg Sports Traumatol Arthrosc 9(1):28–33.

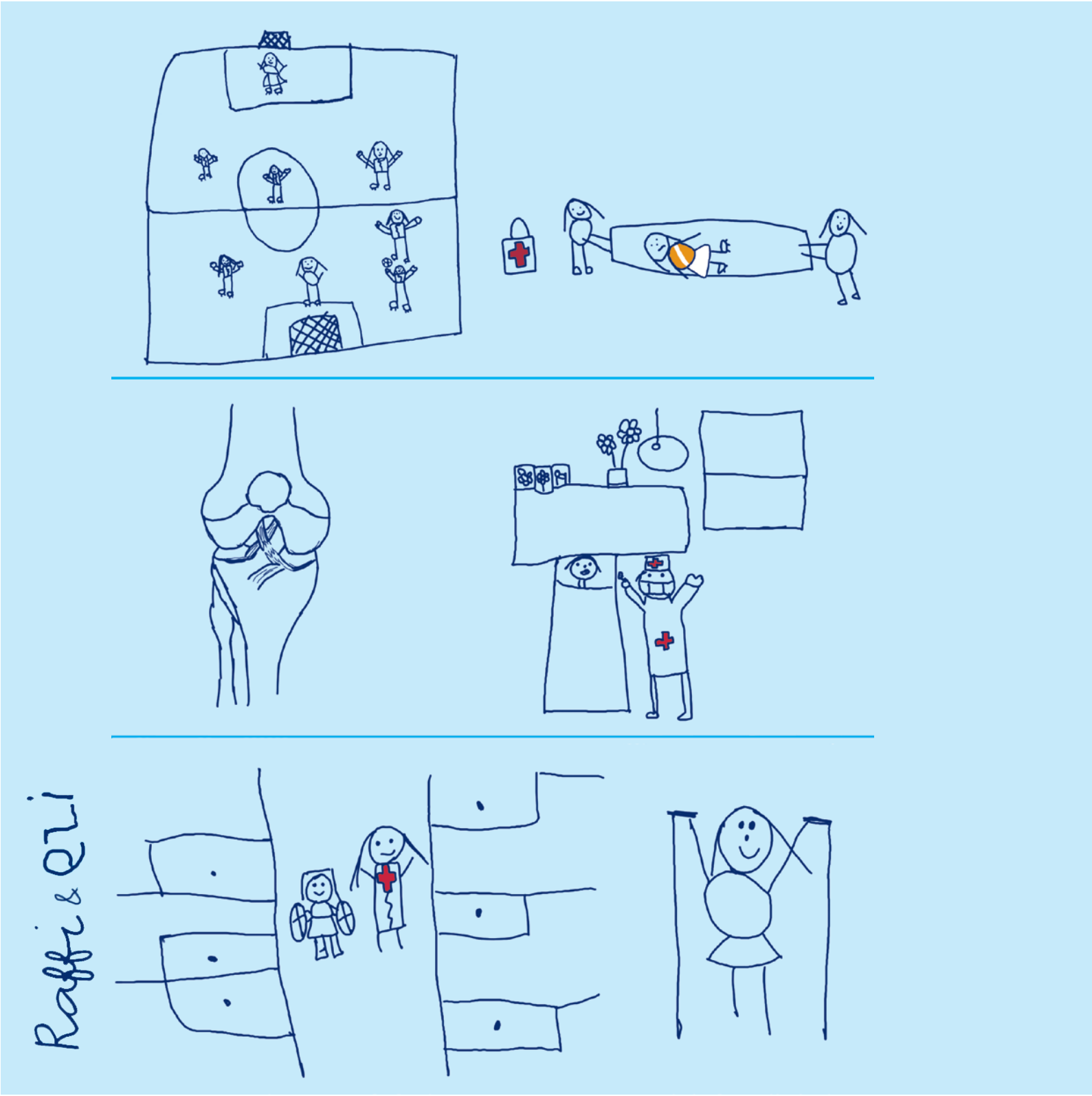

Raffi & Eli

CHAPTER 3

Radiographic positions of femoral ACL, AM and PL centres: accuracy of guidelines based on the lateral quadrant method

Joan W.H. Luites and Nico Verdonschot

Knee Surgery, Sports Traumatology, Arthroscopy epub 2014

Abstract

Purpose

Femoral tunnel positioning is an important factor in anatomical ACL reconstructions. To improve accuracy, lateral radiographic support can be used to determine the correct tunnel location, applying the quadrant method. Piefer et al. (Arthroscopy 28:872–881, 2012) combined various outcomes of eight studies applying this method to one guideline. The studies included in that guideline used various insertion margins, imaging techniques and measurement methods to determine the position of the ACL centres. The question we addressed is whether condensing data from various methods into one guideline, results in a more accurate guideline than the results of one study.

Methods

The accuracy of the Piefer's guideline was determined and compared to a guideline developed by Luites et al. (2000). For both guidelines, we quantified the mean absolute differences in positions of the actual anatomical centres of the ACL, AM and PL measured on the lateral radiographs of twelve femora with the quadrant method and the positions according to the guidelines.

Results

The accuracy of Piefer's guidelines was 2.4 mm (ACL), 2.7 mm (AM) and 4.6 mm (PL), resulting in positions significantly different from the actual anatomical centres. Applying Luites' guidelines for ACL and PL resulted in positions not significantly different from the actual centres. The accuracies were 1.6 mm (ACL) and 2.2 mm (PL and AM), which were significantly different from Piefer for the PL centres, and therefore more accurate.

Conclusions

Condensing the outcomes of multiple studies using various insertion margins, imaging techniques and measurement methods, results in inaccurate guidelines for femoral ACL tunnel positioning at the lateral view.

Clinical relevance

An accurate femoral tunnel positioning for anatomical ACL reconstruction is a key issue. The results of this study demonstrate that averaging of various radiographic guidelines for anatomical femoral ACL tunnel placement in daily practice, can result in inaccurate tunnel positions.

Introduction

The success of ACL reconstructions depends on various aspects. Tunnel placement is one of the most important factors influencing the clinical outcome [11, 40]. Knowledge of the anatomical position of ACL attachments can improve correct positioning and placement of he tunnel and graft. Therefore, many studies have described the anatomical position of the ACL and its functional bundles, the anteromedial (AM) and posterolateral (PL), with various methods in the past decades. Radiographic imaging has been often used to determine the centre positions, resulting in several guidelines. These guidelines can intra-operatively be used for tunnel positioning (determining the preferred position) and placement (drilling the tunnel at the preferred position) and are also frequently used for post-operative tunnel placement evaluation [35]. Two main approaches can be distinguished: either lateral or coronal radiographic imaging. Studies using the frontal approach at the coronal radiographs, describe the attachment site using the so-called clock-method [37, 48], which is also often mentioned in studies using other methods [2, 10, 29, 31, 33]. However, this method has been criticized; the anatomical notch is not circular, and a two-dimensional clock is inaccurate to align in a three-dimensional structure [2, 10, 14]. Lack of a unified definition applying the clock, results in subjective placement with a diverse range of alignment and centering the clock [4, 16], providing the method a poor intra-observer and inter-observer agreement [46]. With the lateral radiographic imaging technique, various methods to describe the positions on the images have been developed [1, 2, 15, 17, 25], of which the most well-known method is the quadrant method of Bernard et al. [5]. In 2000, Luites et al. presented guidelines for AM and PL centre positions according to this lateral method at the 9th ESSKA congress (poster presentation ESSKA 2000 in London; Table 1). Thereafter, in the last decade, the quadrant method has been applied by many other research groups, resulting in various outcomes [6, 13, 15, 18, 24, 27, 28, 35, 39, 43–45, 47 49]. These variations in outcome can have multiple causes. Firstly, the attachments and attachment centres or tunnel centres have been defined in various ways. Secondly, there is a variety used in imaging techniques, such as CT scans, radiographs or digital photographs, and measurement techniques, such as calipers or digital software. Thirdly, there are differences caused by subjective macroscopic dissection of the AM and PL bundles [18]. To condense the many methods from lateral images to one set of guidelines, Piefer et al. [38] combined in 2012 the results of eight different studies [6, 13, 15, 18, 39, 43, 45, 49]. In this way, he has proposed quadrant guidelines for AM, PL and ACL centre positions (Table 1). However, since these data are composed from different studies, using different dissection concepts, it is not possible for surgeons to connect the values of these averaged guidelines to a placement concept they intend to follow. This is in contrast to guidelines from a single study. Besides that, it is questionable whether the combination and subsequent averaging of these inconsistent data sets obtained with different dissection, imaging and measurement techniques result in valid guidelines.

To answer this question, this study was performed, to assess in more detail the effects of the application of the combined guideline as defined by Piefer et al. [38] in terms of the position errors in the individual knee and compared it with a plain set of guidelines. The guidelines were applied according to Luites et al. (2000) and Piefer et al. [38] on new dissected cadaver femora, to determine the accuracy of both guidelines relative to the actual anatomical centres, i.e. the

Table 1. Relative positions of the centres (%) of the ACL, AM and PL according to the guidelines of Luites et al. (2000) and Piefer et al. [43] and the positions of the actual anatomical centres in the current study in deep–shallow (DS) direction at Blumensaat's line (BS) and high–low (HL) direction at condyle depth (CD)

	ACL			**AM**			**PL**		
	Piefer et al. [38]	**Luites et al. (2000)**	**Current study**	**Piefer et al. [38]**	**Luites et al. (2000)**	**Current study**	**Piefer et al. [38]**	**Luites et al. (2000)**	**Current study**
DS % at BS	28.5	23.5 (3.7)	24.9 (2.7)	21.5	21.0 (3.6)	23.2 (2.7)	32.0	26.6 (5.3)	25.2 (2.7)
HL % at CD	35.2	32.3 (7.1)	31.9 (4.8)	23.1	19.2 (10.3)	15.1 (6.0)	48.8	42.2 (9.4)	38.1 (6.6)

gold standard. Our hypothesis was that the mean radiographic guidelines of Luites et al. (2000) are more accurate than the composed guidelines according to Piefer et al. [38], since condensing different inconsistent methods will result in less accurate guidelines.

Materials and methods

Twelve embalmed cadaveric knee specimens from the anatomical laboratory, without gross deformation, were dissected removing skin and muscles. Dorsal knee capsula, collateral ligaments and meniscal structures were kept intact. The synovial structure at the anterior cruciate ligament was removed to improve visibility of the fibres. The ligament showed a narrow midsubstance, with the fibres fanning out towards the femoral and tibial insertion sites, with the femoral fibres attaching to the distal convex lateral surface of the intercondylar notch. During repeated knee movement over the complete range of motion combined with an anterior translation of the tibia in the lower flexion angles, the ACL fibres remaining tightened over the complete range of motion were separated from the fibres tensed in extension and loosening with increasing flexion, with a blunt scalpel. In some specimens, a cleft was discernible between the two bundles. When separation was completed at the mid-ligamental part, the knee joint was dissected till the bone, except for the ACL. Then, separation was continued towards the tibial bone and femoral bone, after which the ligament was split. The complete insertion sites, with the fanning fibre bundles, of the ACL footprints were marked next to the outlines of the fibre attachments with a marker with permanent ink, as was the line separating the ACL into an AM and PL bundle. Then, the fibres were removed from its insertion sites. To make the insertions visible on radiographs, thin radiopaque lead wires were glued at its outlines.

The femora were embedded in a block of poly methyl methacrylate (PMMA) with the use of a mould, in a neutral position in all three planes: frontal, sagittal and transversal. True lateral radiographs were taken, positioning the femora with the medial epicondyle on top of the film including a ruler close to it. This method resulted in very small magnification effects due to roentgen beams spreading being nearly similar in all radiographs (101–102 %) and was therefore neglected. The radiographs were digitized with a Hewlett Packard Scanjet 6100 C/T (150 pixels per inch). Digital measurements of the femoral dimensions and insertion geometry were done with an accuracy of 0.1 mm in Rhinoceros (version 1.0, NURBS Modelling for Windows).

To define the dimensions of the femoral condyle, the most proximal (1) and distal (2) points of the condyle at the intercondylar roof and the most dorsal (3) point of the condyle were marked. The length of Blumensaat's line (BS) was defined between point 1 (deep) and 2 (shallow); the length of the condyle depth (CD) was defined between point 3 (low) and the intersection point from its perpendicular line at BS (high). The gold standard to which the accuracy of the guidelines was calculated, is the actual position of the ACL centres from the used cadaveric knees. To define its positions, the outlines of the ACL footprint and the AM and PL bundles were marked with equally divided points. The points were converted to surfaces, and with the 'mass properties' command, the area centroid was defined. Lines from the centre towards BS and CD were drawn. Finally, the lengths of all lines (mm) were determined to define the positions of the ACL, AM and PL centre, absolutely and relative to BS and CD (Figure 1). The ACL, AM and PL centres obtained will be referred to as 'actual ACL, AM, PL', respectively.

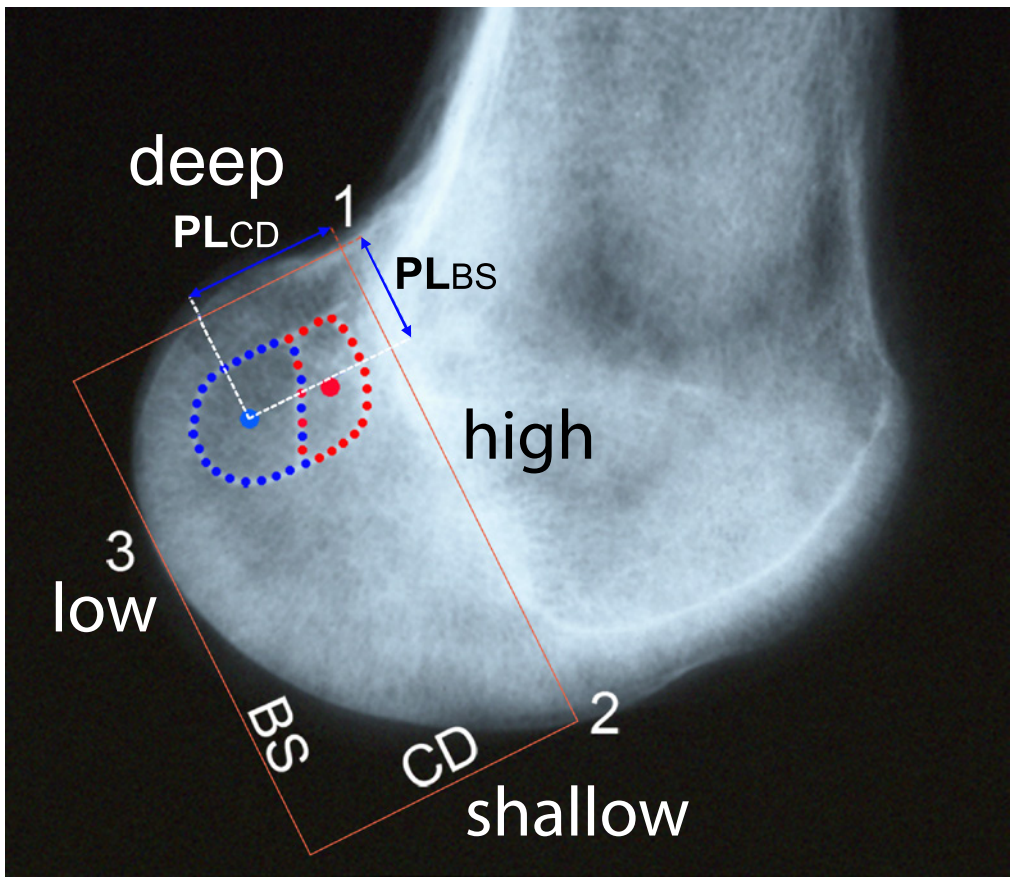

Figure 1. Lateral radiograph with the lines defining the dimensions: Blumensaat's line (BS) between point 1 (deep) and 2 (shallow) and condyle depth (CD) between point 3 (low) and BS (high). The actual centres of the ACL and the AM and PL bundles were defined and its positions relative to BS and CD determined.

Data analysis

To calculate the accuracy of the guidelines from Luites et al. (2000) and Piefer et al. [38], both sets (Table 1) were applied to the 12 knees and compared to the 'actual centres'. This was done in both directions, deep–shallow (BS) and high–low (CD), for the ACL, AM and PL centres. For every knee, the recommended percentages of both guidelines (Table 1) were applied and, using the individual lengths of BS and CD, recalculated into positions expressed in mm. Then, the individual differences in the centre positions according to both guidelines and the gold standard, the actual anatomical centres, were determined calculating the 2D distances between both positions (√BS2 + CD2). The mean absolute difference defines the accuracy (the agreement between the positions) of the guidelines, and the standard deviation (SD) of the absolute differences represents the precision (the repeatability of the procedure). The differences between the femoral centres according to the guidelines and the actual centres were also calculated for both BS and CD directions separately, with the mean differences resulting in the bias or error of the guidelines in both directions.

Statistical analysis

Paired Student's t tests were applied to define whether the positions according to the guidelines differ significantly from the actual anatomical centres and to determine significant differences between the accuracies of both guidelines. P < 0.05 was set as significance level. Using the mean value and standard deviation of the actual anatomical ACL centre in deep–shallow direction (Table 2) and the number of 12 specimens, a post hoc power analysis was performed, resulting in a power of 0.79 detecting a significant difference of 1.2 mm between the actual centres and the centres according to the guidelines.

Table 2 Absolute positions (mm) of the actual anatomical centres of the ACL, AM and PL in the 12 femora of the current study and the positions according to the guidelines of Luites et al. (2000) and Piefer et al. (2012) in deep–shallow (DS) direction at Blumensaat's line and in high–low (HL) direction at condyle depth

	ACL			**AM**			**PL**		
	Piefer et al. [38]	**Luites et al. (2000)**	**Current study**	**Piefer et al. [38]**	**Luites et al. (2000)**	**Current study**	**Piefer et al. [38]**	**Luites et al. (2000)**	**Current study**
DS % at BS	14.0† (1.3)	11.5 (1.1)	12.2 (1.7)	10.5† (1.0)	10.3† (1.0)	11.4 (1.7)	15.7† (1.5)	13.0 (1.2)	12.3 (1.7)
HL % at CD	8.7† (0.5)	8.0 (0.5)	7.9 (1.2)	5.7† (0.3)	4.8† (0.3)	3.8 (1.5)	12.1† (0.7)	10.5 (0.6)	9.5 (1.6)

† *P < 0.05 relative to actual anatomical centres in the current study*

Results

The ACL insertion was found at the proximal half of the medial wall of the lateral condyle, following the cartilage edge, often with a small part of the AM bundle positioned in the notch roof. The line dividing the ACL into an AM and PL part mostly ran parallel to Blumensaat's line. This radiographic line was on average 47.8 ± 3.5 mm, and the condyle depth measured was 24.8 ± 1.5 mm. The dimensions of the femora from the present study did not differ significantly from the dimensions of the femora measured in 2000.

The actual ACL centre was found at an average of 12.2 ± 1.7 mm of Blumensaat's line and at 7.9 ± 1.2 mm of the condyle depth. The actual AM centre was situated at 11.4 ± 1.7 mm (BS) and 3.8 ± 1.5 mm (CD); the actual PL centre was situated at 12.3 ± 1.7 mm (BS) and 9.5 ± 1.6 mm (Table 2; Figure 2). The calculated results applying Piefer et al's guidelines differed significantly at both dimensions for all centres from the actual centres found in this study. The calculated results with Luites et al's guidelines only differed significantly for the AM centre position in both directions from the actual centres (Table 2).

Accuracy

The accuracies of the guidelines for the centres according to Piefer et al. represented by the absolute 2D distances, were 2.4 mm for the ACL centre, 2.7 for the AM centre and 4.6 mm for the PL centre (Table 3; Figure 3). The calculated position of the AM centre was on average the

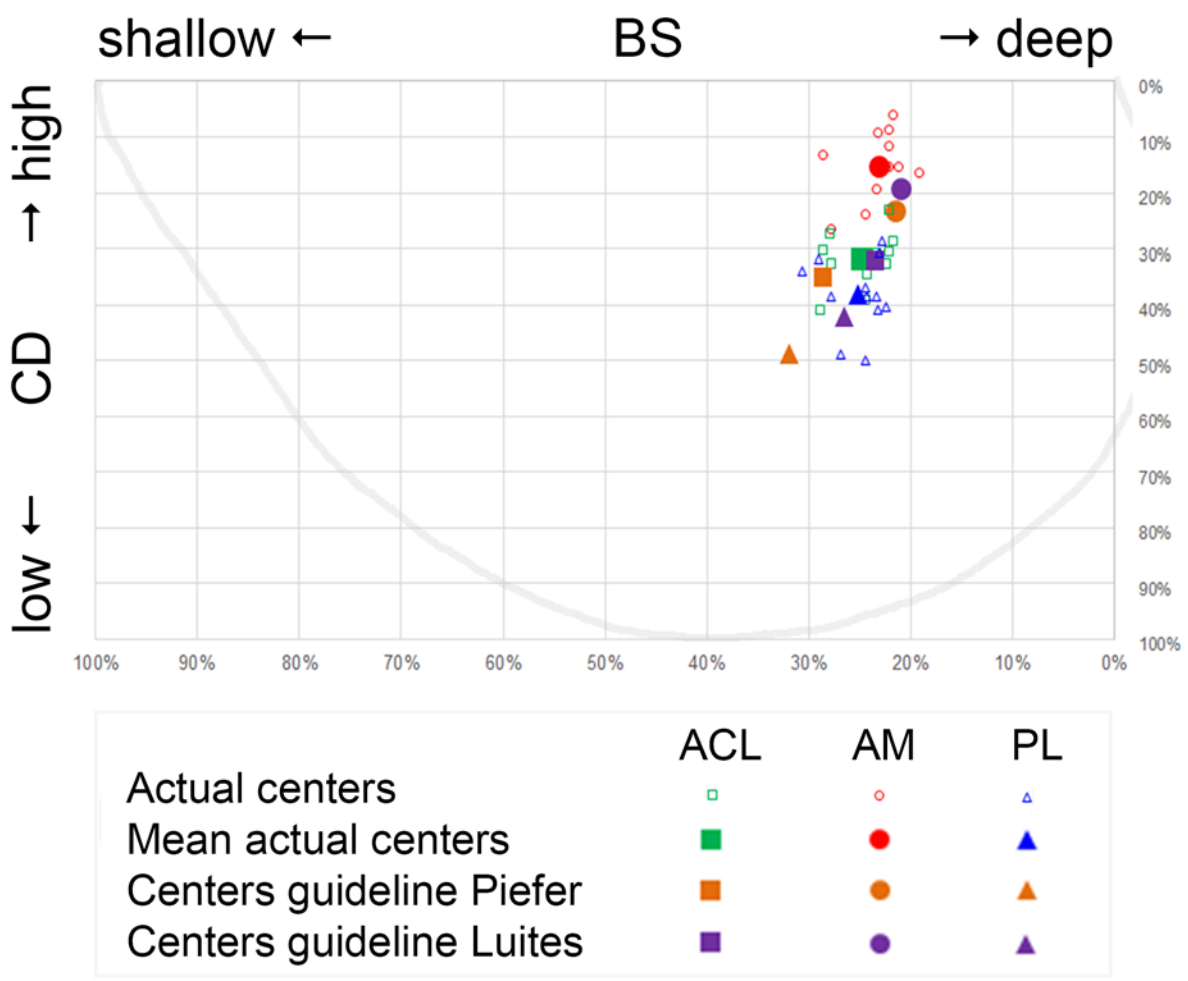

Figure 2. Relative positions of the actual ACL, AM and PL centres in the 12 femora ('gold standard') and their means. The guidelines according to Piefer et al. [38] and Luites et al. (2000) for ACL, AM and PL are also displayed. The grey line represents the average outline of a condyle.

most accurate result in deep–shallow direction (1.1 mm), the ACL in high–low direction (1.2 mm). The results for the PL centres were least accurate (2.7 mm in DS and 3.3 mm in HL), little worse than for the ACL, with the highest accuracy in deep–shallow direction. The worst results for the individual femora ranged between 3.2 mm (ACL in HL) and 6.7 mm (PL 2D). The bias of Piefer et al's guideline showed errors between −0.3 mm for the PL in shallow direction at BS and 0.8 mm for AM in deep direction at BS.

The accuracy of the guidelines for the centres according to Luites et al. (2000) ranged between 1.6 mm for the ACL centre and 2.2 mm for both AM and PL centres regarding the 2D distances (Table 3; Figure 3). The position of ACL centre was most accurate, as well in high–low direction (0.9 mm) as in deep–shallow direction (1.1 mm). The accuracies for AM and PL centres were in both directions similar to each other: in deep–shallow direction 1.2 mm for AM and 1.3 mm for PL and in high–low direction 1.5 mm (AM) and 1.6 mm (PL). The worst individual results ranged between 2.2 mm (PL in DS) and 4.0 mm (AM 2D). The bias for guidelines of Luites et al. (2000) ranged between −1.0 mm for the AM in low direction at CD and 1.1 mm for the AM in deep direction at BS.

The results of the applied guidelines for the centre positions according to Luites et al. (2000) were more accurate than those of Piefer et al. for all measurements, except for the AM positions in deep–shallow direction on Blumensaat's line (Table 3; Figure 3). The differences in outcomes between Piefer et al. and Luites et al. were significant for the PL centre in both directions (1.2 mm in HL and 2.0 mm in DS) and 2D (2.4 mm) and the AM position in high–low direction at the condyle depth (0.7 mm) and 2D (0.5 mm). The differences for the ACL centre, 0.3 mm (HL), 0.7 mm (DS) and 0.8 (2D), were not significant. The deep–shallow AM position according to Piefer et al. was significantly more accurate than that with Luites et al's guidelines, 1.1 versus 1.2 mm, respectively, however, a clinically not relevant difference.

The results for precision and repeatability were nearly similar in both groups ranging from 0.6 to 1.5 mm.

Table 3 Accuracy, precision [between '(..)'], bias and standard deviation [between '(..)'] and range [between '(..)'] in mm of the results applying the guidelines according to Piefer et al. (2012) and Luites et al. (2000) in deep–shallow (DS) direction at Blumensaat's line (BS) and high–low (HL) direction at condyle depth (CD)

	ACL			**AM**			**PL**		
	Piefer et al. [38]	**Luites et al. (2000)**	***P* value†**	**Piefer et al. [38]**	**Luites et al. (2000)**	***P* value†**	**Piefer et al. [38]**	**Luites et al. (2000)**	***P* value†**
DS at BS	1.8 (1.3) -1.8 (1.4) [0.0-3.4]	1.1 (1.0) 0.7 (1.3) [0.0-2.8]	0.285 n.s.	1.1 (1.2) 0.8 (1.3) [0.1-3.5]	1.2 (1.2) 1.1 (1.3) [0.1-3.7]	0.001	3.3 (1.4) -3.3 (1.4) [0.7-5.1]	1.3 (0.6) -0.7 (1.3) [0.2-2.2]	<0.001
HL at CD	1.2 (0.8) -0.8 (1.2) [0.2-3.2]	0.9 (0.8) -0.1 (1.2) [0.1-2.4]	0.285 n.s.	1.1 (1.2) -2.0 (1.4) [0.2-4.2]	1.2 (1.2) -1.0 (1.4) [0.2-4.2]	0.011	2.7 (1.5) -2.7 (1.6) [0.0-5.0]	1.6 (1.0) -1.0 (1.5) [0.2-3.3]	0.010
2D	2.4 (1.1) [0.8-4.6]	1.6 (1.0) [0.4-3.5]	0.128 n.s.	2.7 (1.0) [1.2-4.3]	2.2 (1.1) [1.0-4.0]	0.009	4.6 (1.2) [2.6-6.7]	2.2 (0.8) [1.2-3.8]	<0.001

† P value: paired t test between the absolute differences of Piefer and Luites; n.s. not significant

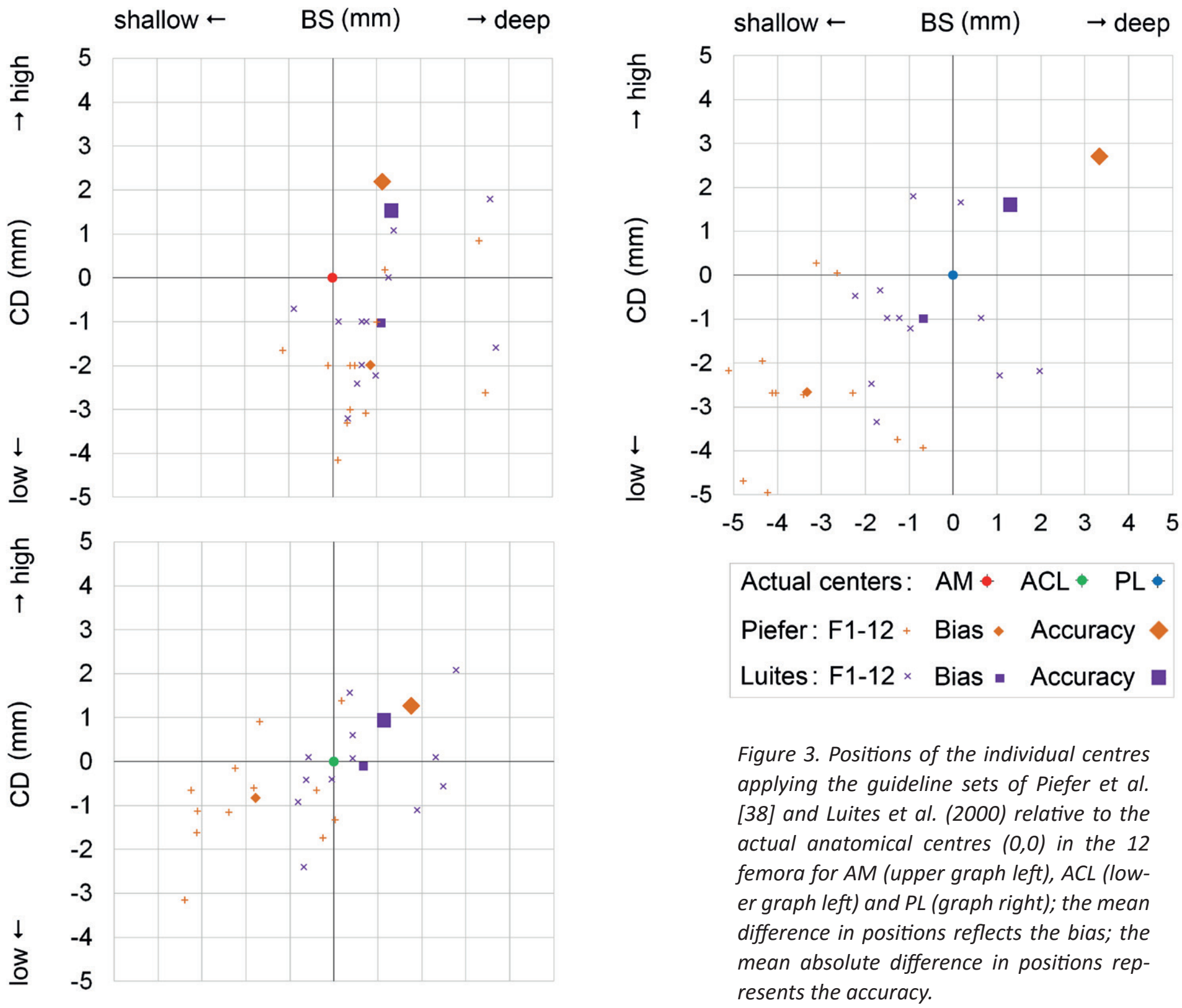

Figure 3. Positions of the individual centres applying the guideline sets of Piefer et al. [38] and Luites et al. (2000) relative to the actual anatomical centres (0,0) in the 12 femora for AM (upper graph left), ACL (lower graph left) and PL (graph right); the mean difference in positions reflects the bias; the mean absolute difference in positions represents the accuracy.

Discussion

Many studies have reported the radiological positions of the anatomical centres of the ACL and its two functional bundles, the AM and PL bundles. This resulted in various guidelines for anatomical tunnel positioning and postoperative tunnel placement evaluation. In this article, we applied two sets of guidelines to get an impression of the variability of the accuracy. The most important finding of the present study was the inaccuracy of the averaged guide- lines reported by Piefer et al. [38], which were composed through a meta-analysis of the data of various studies. The averaged guidelines were less accurate in the specimens used in the current study, compared to the guidelines of Luites et al. (2000), a single study. Piefer et al's guidelines were least accurate for the PL centre, with maximum errors of 5–6.7 mm.

Piefer et al. combined studies with large differences in outcomes in his guideline. These different outcomes in the various included studies, can be the result of the use of different methods and specimens [26]. Some included studies determined the centres of the insertion sites [6, 15, 39, 45, 49]; these were defined as the measured geometrical centre of the marked insertion site [15] (and current study), the 'parallel projection' of the central fibres of the bundle onto its attachment [6], the centre of the oval shape, determined by the software, which approximated the margins of the ACL footprint [45] or the centre chosen by 'vision' [39, 49]. Other studies included by Piefer et al. drilled tunnels and measured the positions of the tunnel centres [13, 18]. The imaging techniques on which the quadrant method was applied, varied from radiographs [15, 39, 49] to CT scans [13] and digital photographs [45]. Although Musahl et al. [35] found no significant difference between measurements on radiographs and CT scans, Jenny et al. [21] addressed different locations of the femoral ACL attachments according to the measurement technique (radiographs or CT scan). The presence of the variations could also be explained by the dissection technique: the separation of the ACL into two bundles and the determination of the attachment margins. All studies included by Piefer et al. report identical separation techniques of the AM and PL bundles based on identified differences in tension pat- terns during the complete range of knee motion. However, the ACL consists of many small fibres, and macroscopically separation is difficult and subjected to human error and bias [18]. The determination of the attachment margins differs in the various studies. As noticed in many anatomical studies, the fibres of the femoral attachment fan out over a broad flattened area [3, 12, 33, 34]. Some studies narrow the insertion to the area of the midsubstance fibres, the direct insertion [6, 24, 33, 44], while others, including the present study, use the entire broad attachment area, the direct and indirect insertion (Figure 4). Recent publications describe this phenomenon [19, 20, 32, 41]. The main reason we chose for the entire attachment area is that the ligament insertion site and the underlying bone are additional parts of the ligament unit which functions as one complex, contributing to the constraining function of the ligament [23]. The ligamentous tissue is mediated by a transitional zone of fibrocartilage and mineralized fibrocartilage to that of rigid bone [3], which cannot be separated macroscopically [20, 41]. In daily practice, surgeons can choose for a different concept when deciding upon the femoral tunnel location. However, when using the averaged guidelines of Piefer et al., it is not clear which concept these values represent. In conclusion, the results of this study show the inaccuracy of the averaging method proposed by Piefer et al. Application of this method for anatomical ACL reconstruction will result in inaccurate femoral tunnel positioning.

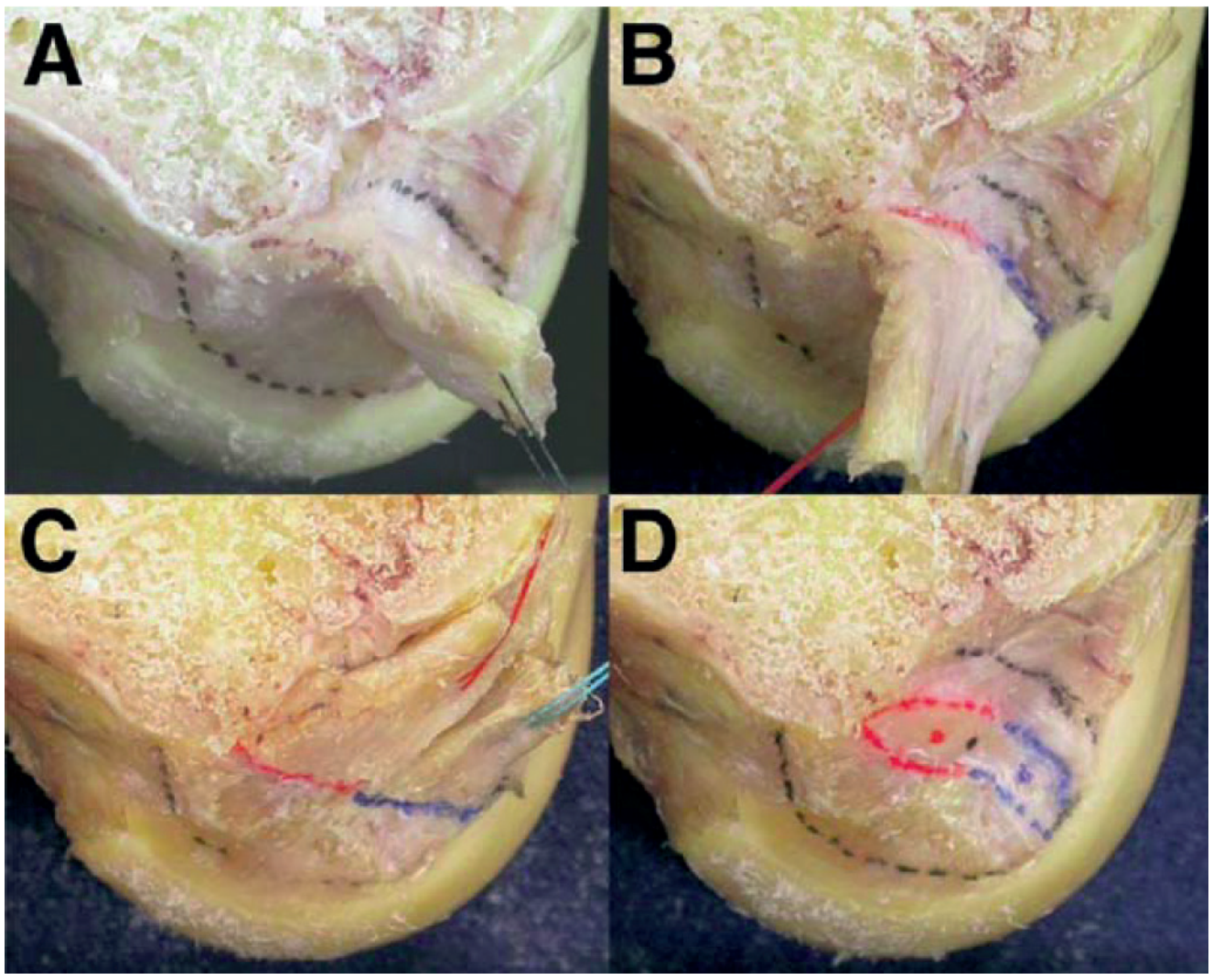

Figure 4. At these pictures from Mochizuki et al. [33], the difference between the direct and indirect insertion is clearly visualized. The direct insertion consists of the midsubstance fibres; the indirect insertion consists of the fibres fanning out into the bone of the intercondylar notch.

Besides the exploration of the causes of the variability of outcomes as stated above, another important question to answer is which magnitude of inaccuracy on tunnel placement has any clinical effect on knee stability. Several studies have shown the influence of different femoral tunnel positions on biomechanical parameters in cadaveric knees [29, 31, 36, 50]. Musahl et al. [36] showed significant different anterior tibial translation values between two tunnel positions, at 25 % × BS/40 % × CD and at 38 % × BS/8 % × CD, with an inter-distance of approximately 9 mm. Zavras et al. [50] demonstrated a large effect on the anterior–posterior (AP) laxity of the knee varying the femoral graft position with 3 mm. This effect was mainly in the positions 3 mm towards posterior (deeper in the notch along the notch roof) and 3 mm towards the 12 o'clock position (higher) from the isometric point, defined as 3 mm distal to the posterior edge of Blumensaat's line at 10:30–11:00 o'clock, which is in the proximal edge of the femoral attachment. Other studies compared tunnels at the 11 o'clock and 10 o'clock positions [29, 31, 42]. Assuming a clock with the 12 o'clock (noon) position defined as the top of the intercondylar notch and the 6 o'clock defined as the bottom of the lateral femoral condyle in the flexion position [33] and a height of circa 20 mm [7], both positions are approximately 3–4 mm located from each other. Markolf et al. [31] tested AP laxity with tunnels at different clock positions, adapting the graft pretension at the same time. He showed that tunnels positioned towards 10 o'clock and 12 o'clock showed no significant different AP laxities of the knee relative to a standard 11 o'clock tunnel, which was located 6–7 mm anterior to the posterior wall. However, a tunnel positioned 5 mm more shallow, anterior along the notch roof in the direction of Blumensaat's line, had significantly different AP laxity in most knee angles compared to the 11 o'clock tunnel. Tunnels positioned 2.5 mm posterior (deeper), showed no significantly different AP laxities. Loh et al. [29] tested the anterior tibial translation with tunnels at 10 and 11 o'clock positioned with a 7-mm offset drill guide, resulting in smaller, not significant, anterior translation in the lower flexion angles for the 10 o'clock tunnel.

Summarizing the results of these biomechanical studies, it can be estimated that a positioning error at the femoral condyle beyond 3–4 mm can result in a different biomechanical behavior, although this is not similar for the entire area and for deviations in each directions. Application of this reasoned threshold of 3 mm, results in the findings of Table 4, showing that in 92 % of the femora the guidelines according to Piefer et al. result in PL tunnel positions deviating more than 3 mm from the PL actual centre. This could possibly result in different biomechanical behaviors in these knees as aimed for regarding the PL tunnel positioning. Furthermore, the table also shows that the guidelines for the PL bundle from Luites et al. (2000) will result in 25 % of the femora with errors beyond the threshold of 3 mm. However, it remains unclear what influence the amount of such an inaccuracy has on the clinical outcome.

Although femoral graft positions in ACL literature are mentioned as an important factor in clinical outcome, various clinical studies could not evidently show differences in post-operative biomechanical tests (Lachman and pivot-shift test) caused by small variations in femoral tunnel positions [22, 42]. Seon et al. [42] showed in a clinical study that the intra-operative internal rotation was significantly better (2°) for the lower 10 o'clock tunnel relative to the higher 11 o'clock tunnel; however, this did not result in a reduction in the residual pivot-shift phenomenon 2 years post-operative, suggesting the found difference was not clinically relevant in terms of functional activities. However, the tunnel positions in this study were not objectively and accurately measured post-operative, a limitation indicated by van Eck et al. about both clinical [9] and cadaveric studies concerning femoral tunnel positions [8]. Besides that, many other factors, not only concerning surgical techniques, play a role in clinical outcome. Hence, the influence of various positions of the femoral tunnel on clinical parameters remains uncertain. Besides that, the final quest for the optimal femoral tunnel position combined with the optimal position technique and measurement method remains.

This study has several limitations. Although the measurements of the ACL centres of the specimens in the current study were performed by another researcher, the dissections were done by the same researcher (JL). This can be judged as a limitation, besides the observation that it could be an explanation for the similarities between the results from the study in 2000 and this study and may emphasize the influence of dissection choice regarding the attachment margins at the geometrical insertion results. The dissection was performed by macroscopic evaluation. Other limitations are related to the specimen: we performed the measurements on a limited number of femora, which were embalmed and probably of older age than patients undergoing ACL reconstruction. However, the used specimen had no osteoarthritic changes. Despite the limitations, the anatomical results [30] and radiological results are in line with the literature [5, 39, 45].

Conclusion

The current study shows that combining the various results of femoral centre positions from different radiographic studies using different concepts and techniques, does not lead to accurate guidelines for individual tunnel positioning.

Acknowledgments We thank Jan Kooloos, Department of Anatomy of the University of Nijmegen, who provided the specimens and John Berns, Department of Radiology, Sint Maartenskliniek, Nijmegen, who assisted in taking the radiographs.

References

1. Aglietti P, Zaccherotti G, Menchetti PP, De Biase BP (1995) A comparison of clinical and radiological parameters with two arthroscopic techniques for anterior cruciate ligament reconstruction. Knee Surg Sports Traumatol Arthrosc 3:2–8.
2. Amis AA, Beynnon B, Blankevoort L, Chambat P, Christel P, Durselen L et al (1994) Proceedings of the ESSKA scientific workshop on reconstruction of the anterior and posterior cruciate ligaments. Knee Surg Sports Traumatol Arthrosc 2:124–132.
3. Arnoczky SP (1983) Anatomy of the anterior cruciate ligament. Clin Orthop Relat Res 172:19–25.
4. Arnold MP, Verdonschot N, van KA (2005) ACL graft can replicate the normal ligament's tension curve. Knee Surg Sports Traumatol Arthrosc 13:625–631.
5. Bernard M, Hertel P, Hornung H, Cierpinski T (1997) Femoral insertion of the ACL. Radiographic quadrant method. Am J Knee Surg 10:14–21.
6. Colombet P, Robinson J, Christel P, Franceschi JP, Djian P, Bellier G et al (2006) Morphology of anterior cruciate ligament attachments for anatomic reconstruction: a cadaveric dissection and radiographic study. Arthroscopy 22:984–992.
7. van Eck CF, Martins CA, Vyas SM, Celentano U, van Dijk CN, Fu FH (2010) Femoral intercondylar notch shape and dimensions in ACL-injured patients. Knee Surg Sports Traumatol Arthrosc 18:1257–1262.
8. van Eck CF, Samuelsson K, Vyas SM, van Dijk CN, Karlsson J, Fu FH (2011) Systematic review on cadaveric studies of anatomic anterior cruciate ligament reconstruction. Knee Surg Sports Traumatol Arthrosc 19(Suppl 1):S101–S108.
9. van Eck CF, Schreiber VM, Mejia HA, Samuelsson K, van Dijk CN, Karlsson J et al (2010) "Anatomic" anterior cruciate ligament reconstruction: a systematic review of surgical techniques and reporting of surgical data. Arthroscopy 26:S2–S12.
10. Edwards A, Bull AM, Amis AA (2007) The attachments of the anteromedial and posterolateral fibre bundles of the anterior cruciate ligament: part 2: femoral attachment. Knee Surg Sports Traumatol Arthrosc 16:29–36.
11. Fernandes TL, Fregni F, Weaver K, Pedrinelli A, Camanho GL, Hernandez AJ (2014) The influence of femoral tunnel position in single-bundle ACL reconstruction on functional outcomes and return to sports. Knee Surg Sports Traumatol Arthrosc 22:97–103.
12. Ferretti M, Ekdahl M, Shen W, Fu FH (2007) Osseous landmarks of the femoral attachment of the anterior cruciate ligament: an anatomic study. Arthroscopy 23:1218–1225.
13. Forsythe B, Kopf S, Wong AK, Martins CA, Anderst W, Tashman S et al (2010) The location of femoral and tibial tunnels in anatomic double-bundle anterior cruciate ligament reconstruction analyzed by three-dimensional computed tomography models. J Bone Joint Surg Am 92:1418–1426.
14. Fu FH (2008) The clock-face reference: simple but nonanatomic. Arthroscopy 24:1433.
15. Guo L, Yang L, Wang A, Wang X, Dai G (2008) Roentgenographic measurement study for locating femoral insertion site of anterior cruciate ligament: a cadaveric study with X-Caliper. Int Orthop 33:133–137.
16. Han Y, Hart A, Martineau PA (2014) Is the clock face an accurate, precise, and reliable measuring tool for anterior cruciate ligament reconstruction? Arthroscopy 30:849–855.
17. Harner CD, Marks PH, Fu FH, Irrgang JJ, Silby MB, Mengato R (1994) Anterior cruciate ligament reconstruction: endoscopic versus two-incision technique. Arthroscopy 10:502–512.
18. Iriuchishima T, Ingham SJ, Tajima G, Horaguchi T, Saito A, Tokuhashi Y et al (2010) Evaluation of the tunnel placement in the anatomical double-bundle ACL reconstruction: a cadaver study. Knee Surg Sports Traumatol Arthrosc 18:1226–1231.
19. Iriuchishima T, Ryu K, Aizawa S, Fu FH (2016) The difference in centre position in the ACL femoral footprint inclusive and exclusive of the fan-like extension fibres. Knee Surg Sports Traumatol Arthrosc 24:254-259.

20. Iwahashi T, Shino K, Nakata K, Otsubo H, Suzuki T, Amano H et al (2010) Direct anterior cruciate ligament insertion to the femur assessed by histology and 3-dimensional volume-rendered computed tomography. Arthroscopy 26:S13–S20.
21. Jenny JY, Ciobanu E, Clavert P, Jaeger JH, Kahn JL, Kempf JF (2011) Anatomic attachment of the ACL. Comparison between radiological and CT analysis. Knee Surg Sports Traumatol Arthrosc 19:806–810.
22. Jepsen CF, Lundberg-Jensen AK, Faunoe P (2007) Does the position of the femoral tunnel affect the laxity or clinical outcome of the anterior cruciate ligament-reconstructed knee? A clinical, prospective, randomized, double-blind study. Arthroscopy 23:1326–1333.
23. Jung H-J, Fisher MB, Woo S (2009) Role of biomechanics in the understanding of normal, injured, and healing ligaments and tendons. Sport Med Arthrosc Rehabil Ther Technol 1:9.
24. Kai S, Kondo E, Kitamura N, Kawaguchi Y, Inoue M, Amis AA et al (2013) A quantitative technique to create a femoral tunnel at the averaged center of the anteromedial bundle attachment in anatomic double-bundle anterior cruciate ligament reconstruction. BMC Musculoskelet Disord 14:189–198.
25. Klos TV, Harman MK, Habets RJ, Devilee RJ, Banks SA (2000) Locating femoral graft placement from lateral radiographs in anterior cruciate ligament reconstruction: a comparison of 3 methods of measuring radiographic images. Arthroscopy 16:499–504.
26. Kopf S, Musahl V, Tashman S, Szczodry M, Shen W, Fu FH (2009) A systematic review of the femoral origin and tibial insertion morphology of the ACL. Knee Surg Sports Traumatol Arthrosc 17:213–219.
27. Lee JK, Lee S, Seong SC, Lee MC (2015) Anatomy of the anterior cruciate ligament insertion sites: comparison of plain radiography and three-dimensional computed tomographic imaging to anatomic dissection. Knee Surg Sports Traumatol Arthrosc 23:2297-2305.
28. Lertwanich P, Martins CA, Asai S, Ingham SJ, Smolinski P, Fu FH (2011) Anterior cruciate ligament tunnel position measurement reliability on 3-dimensional reconstructed computed tomography. Arthroscopy 27:391–398.
29. Loh JC, Fukuda Y, Tsuda E, Steadman RJ, Fu FH, Woo SL (2003) Knee stability and graft function following anterior cruciate ligament reconstruction: comparison between 11 o’clock and 10 o’clock femoral tunnel placement. Arthroscopy 19:297–304.
30. Luites JW, Wymenga AB, Blankevoort L, Kooloos JG (2007) Description of the attachment geometry of the antero-medial and posterolateral bundles of the ACL from arthroscopic perspective for anatomical tunnel placement. Knee Surg Sports Traumatol Arthrosc 15:1422–1431.
31. Markolf KL, Hame S, Hunter DM, Oakes DA, Zoric B, Gause P et al (2002) Effects of femoral tunnel placement on knee laxity and forces in an anterior cruciate ligament graft. J Orthop Res 20:1016–1024.
32. Mochizuki T, Fujishiro H, Nimura A, Mahakkanukrauh P, Yasuda K, Muneta T et al (2014) Anatomic and histologic analysis of the mid-substance and fan-like extension fibres of the anterior cruciate ligament during knee motion, with special reference to the femoral attachment. Knee Surg Sports Traumatol Arthrosc 22:336–344.
33. Mochizuki T, Muneta T, Nagase T, Shirasawa S, Akita KI, Sekiya I (2006) Cadaveric knee observation study for describing anatomic femoral tunnel placement for two-bundle anterior cruciate ligament reconstruction. Arthroscopy 22:356–361.
34. Mommersteeg TJ, Kooloos JG, Blankevoort L, Kauer JM, Huiskes R, Roeling FQ (1995) The fibre bundle anatomy of human cruciate ligaments. J Anat 187(Pt 2):461–471.
35. Musahl V, Burkart A, Debski RE, van SA, Fu FH, Woo SL (2003) Anterior cruciate ligament tunnel placement: comparison of insertion site anatomy with the guidelines of a computer-assisted surgical system. Arthroscopy 19:154–160.
36. Musahl V, Plakseychuk A, VanScyoc A, Sasaki T, Debski RE, McMahon PJ et al (2005) Varying femoral tunnels between the anatomical footprint and isometric positions: effect on kinematics of the anterior cruciate ligament-reconstructed knee. Am J Sports Med 33:712–718.
37. Petersen W, Zantop T (2007) Anatomy of the anterior cruciate ligament with regard to its two bundles. Clin Or-

thop Relat Res 454:35–47.

38. Piefer JW, Pflugner TR, Hwang MD, Lubowitz JH (2012) Anterior cruciate ligament femoral footprint anatomy: systematic review of the 21st century literature. Arthroscopy 28:872–881.
39. Pietrini SD, Ziegler CG, Anderson CJ, Wijdicks CA, Westerhaus BD, Johansen S et al (2011) Radiographic landmarks for tunnel positioning in double-bundle ACL reconstructions. Knee Surg Sports Traumatol Arthrosc 19:792–800.
40. Sadoghi P, Kropfl A, Jansson V, Muller PE, Pietschmann MF, Fischmeister MF (2011) Impact of tibial and femoral tunnel position on clinical results after anterior cruciate ligament reconstruction. Arthroscopy 27:355–364.
41. Sasaki N, Ishibashi Y, Tsuda E, Yamamoto Y, Maeda S, Mizukami H et al (2012) The femoral insertion of the anterior cruciate ligament: discrepancy between macroscopic and histological observations. Arthroscopy 28:1135–1146.
42. Seon JK, Park SJ, Lee KB, Seo HY, Kim MS, Song EK (2011) In vivo stability and clinical comparison of anterior cruciate ligament reconstruction using low or high femoral tunnel positions. Am J Sports Med 39:127–133.
43. Steckel H, Musahl V, Fu FH (2010) The femoral insertions of the anteromedial and posterolateral bundles of the anterior cruciate ligament: a radiographic evaluation. Knee Surg Sports Traumatol Arthrosc 18:52–55.
44. Takahashi M, Doi M, Abe M, Suzuki D, Nagano A (2006) Anatomical study of the femoral and tibial insertions of the antero-medial and posterolateral bundles of human anterior cruciate ligament. Am J Sports Med 34:787–792.
45. Tsukada H, Ishibashi Y, Tsuda E, Fukuda A, Toh S (2008) Anatomical analysis of the anterior cruciate ligament femoral and tibial footprints. J Orthop Sci 13:122–129.
46. Wittstein JR, Garrett WE (2014) Time to get rid of the clock: intraobserver and interobserver reliability in determination of the o’clock position of the femoral tunnel in ACL reconstruction. J Knee Surg 27:89–92.
47. Yamamoto Y, Hsu WH, Woo SL, Van Scyoc AH, Takakura Y, Debski RE (2004) Knee stability and graft function after anterior cruciate ligament reconstruction: a comparison of a lateral and an anatomical femoral tunnel placement. Am J Sports Med 32:1825–1832.
48. Yamazaki J, Muneta T, Koga H, Sekiya I, Ju YJ, Morito T et al (2011) Radiographic description of femoral tunnel placement expressed as intercondylar clock time in double-bundle anterior cruciate ligament reconstruction. Knee Surg Sports Traumatol Arthrosc 19:418–423.
49. Zantop T, Wellmann M, Fu FH, Petersen W (2008) Tunnel positioning of anteromedial and posterolateral bundles in anatomic anterior cruciate ligament reconstruction: anatomic and radiographic findings. Am J Sports Med 36:65–72.
50. Zavras TD, Race A, Amis AA (2005) The effect of femoral attachment location on anterior cruciate ligament reconstruction: graft tension patterns and restoration of normal anterior-posterior laxity patterns. Knee Surg Sports Traumatol Arthrosc 13:92–100.

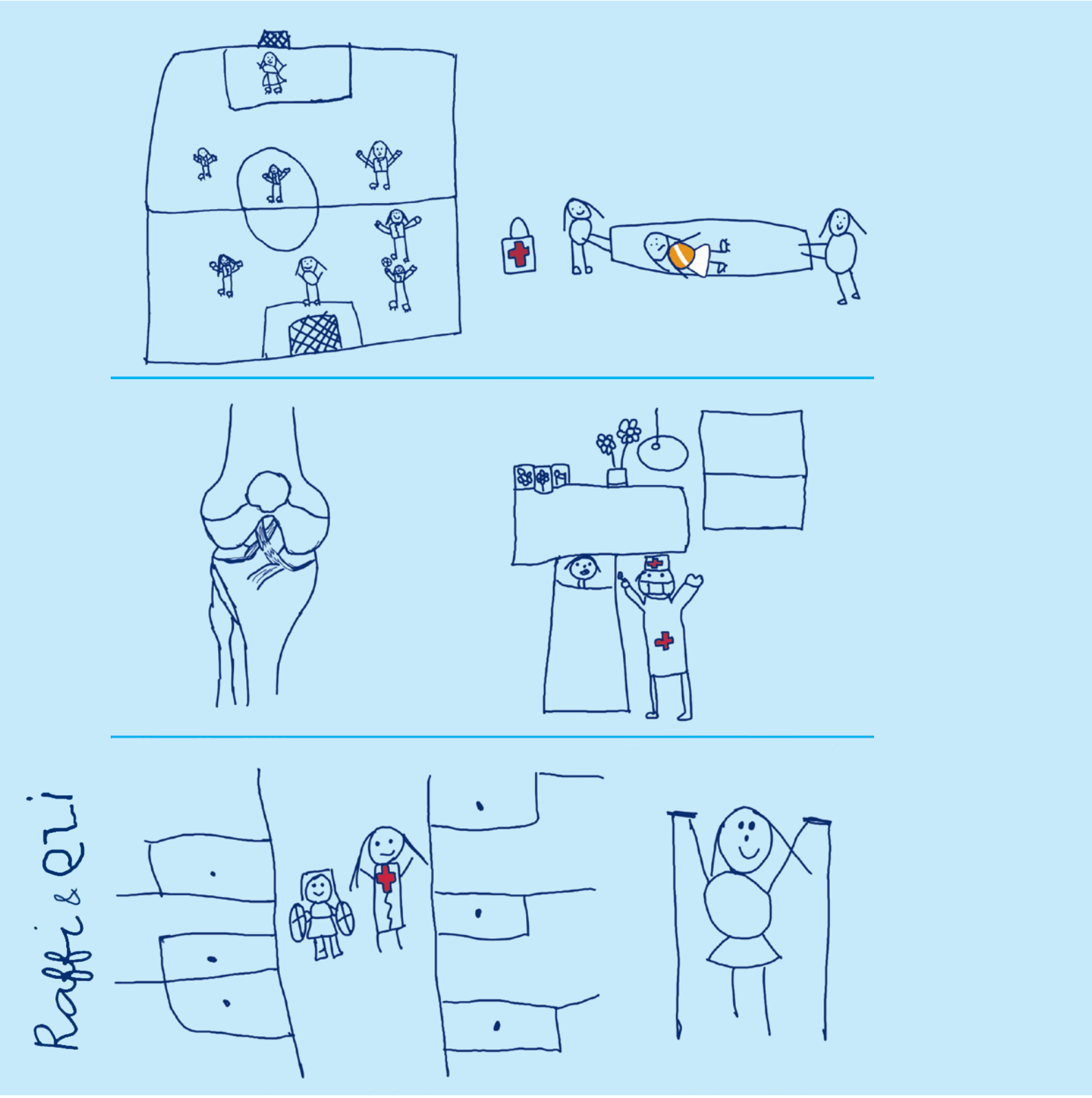
Raffi & Eli

CHAPTER 4

Three-dimensional positions of ACL, AM and PL centers in the distal femur determined from computed tomography scans

Joan W.H. Luites, Pawel K. Tomaszewski, Willy J. Zevenbergen,
Gudo Hoogzaad, Sarthak Misra, Dennis Janssen and
Nico Verdonschot

Abstract

Purpose

The development of an objective femoral alignment method resulting in a reproducible coordinate system, in which the 3-dimensional (3D) center positions of the anterior cruciate ligament (ACL), the anteromedial (AM) and posterolateral (PL) bundles were defined relative to simple detectable femoral structures.

Methods

First, we developed a software program for automated femoral alignment, modifying an existing method. Subsequently, 3D surface models based on CT data of 12 cadaveric femora with marked ACL, AM and PL outlines were created and the center positions were determined. The depth, height and width of the distal femur were calculated, as were the positions of the insertion centers relative to the femoral dimensions in the new coordinate system.

Results

The center positions appeared to be consistent (i.e. scalable) with the femoral dimensions, showing acceptable SDs of 1.3-1.4 mm. The ACL center was positioned at 22.1%, 65.2% and 60.2%, the AM at 26.1%, 69.4% and 57.9%; the PL at 19.2%, 62.3% and 61.5%, relative to the femoral depth, height and width, respectively.

Conclusions

We introduced an automated, reproducible method to objectively define a 3D coordinate system, in which the 3D positions of the ACL, AM and PL centers relative to the distal femoral dimensions have been determined. The methodology and results can be used to improve femoral tunnel positioning in anatomical single bundle or double bundle ACL reconstruction. Furthermore, the technique can be used to develop patient specific instruments for tunnel placement and for pre/intra-operative planning of the 3D femoral tunnel positions with navigation systems.

Introduction

Femoral graft placement is an important factor affecting the outcome after anterior cruciate ligament (ACL) reconstruction, with accurate anatomic placement resulting in superior clinical outcome [9, 33] and malpositioning as the main cause of graft failure [25]. To increase knowledge of femoral ACL insertion geometry and improve accuracy of tunnel placement, various anatomical studies determining the positions of ACL centers have been performed. These studies use a large pallet of ACL imaging methods like planar radiography [4], magnetic resonance imaging (MRI) [34] and computed tomography (CT) [1, 20, 27, 36].

The use of CT in ACL surgery has been introduced in the past century for diagnostic aims [30, 32]. The evolution of the CT technique resulted in high speed, spiral 3D CT scans and is currently being considered as the gold standard to evaluate osseous structures. Besides application in anatomical studies defining the anatomical center positions [1, 20, 27, 36], the CT technique is used for the postoperative evaluation of tunnel widening [37] and, increasingly, tunnel location evaluation [18, 29]. Various measurement methods to determine femoral tunnel locations on CT scans have been developed [3, 10, 14, 17, 19, 31]. Most CT studies report the 2-dimensional (2D) positions of the anatomical center positions [1, 20, 27, 36] or tunnel locations [3, 10, 14, 19] only in the sagittal plane, often relative to Blumensaat's line and the condyle height. However, the CT technique enables 3D evaluation of positions. A 3D evaluation requires a 3D femoral coordinate system. Ramme et al. [31] developed a 3D tunnel measurement method, establishing a surgically oriented coordinate system enabling angular and spatial descriptions of femoral tunnel positions along defined axes. The axes of the coordinate system were defined aligning the bone surfaces to a standardized 3D orientation. After aligning the proximo-distal (PD) axis with the intramedullary canal manually, the mediolateral (ML) axis was defined, rotating the femur around the PD axis to reach a perfect visual overlap of the femoral condyles. This alignment method is subjective and sensitive to inaccuracies. To improve accuracy of measurements avoiding subjectivity, an objective (independent of the CT-scanning coordinate system and individuals defining the axes), automated and reproducible femoral alignment method should be used. Since usually the femur is scanned only in the distal region, the alignment has to be based on the geometry of the distal femur. Miranda et al. [23] proposed a method, fitting a cylinder to the posterior femoral condyle to define the ML axis. However, this approximation does not take into account the medio-lateral asymmetry of the condyles, which is bound to be present [7, 16]. Fitting cylinders to both condyles, could possibly improve the accuracy of the Miranda's method.

This alignment method results in an objective 3D femoral coordinate system, in which the 3D position of the ACL, AM and PL centers can be located. The next step is to define easily detectable reference structures. The positions of the insertion centers are reported to have consistent locations in the intercondylar notch [1, 4, 20, 27, 36]. Moreover, the intercondylar notch width and height correlate with the knee width [26] and the knee width in turns with the condyle height [24] and depth [28]. This suggests that the positions of the ACL insertion centers are related to the width, depth and height of the distal femur, turning it into a suitable reference system. Since CT is the gold standard technique to evaluate osseous structures, the dimensions of the distal femur can be easily measured from CT images.

The purpose of this study was twofold. The first goal was the development and validation of a modified objective alignment method of the distal femur resulting in a reproducible coordinate system. The second goal was to define the 3D positions of the ACL, AM and PL centers in that coordinate system relative to the distal femur width, depth and height.

Methods

Part 1: Development of a distal femoral coordinate system

For the development of the distal femoral coordinate system, a computed tomographic scan of the distal part of one embalmed femur specimen without visible malformations was obtained with a SOMATOM Sensation 64 (Siemens AG, Munich, Germany); Slice thickness was 0.6 mm and slice increment 0.3 mm. The 3D surface model of the distal femur was generated from the CT data in Mimics software v.14.01 (Materialise N.V., Leuven, Belgium). This model was used to define a coordinate system by an in-house MATLAB-based program (Version 2013, The MathWorks, Natick, Massachusetts, USA). To obtain the ML axis, the posterior femoral condyles were isolated using a plane oriented over multiple successive steps, using the principle axes of inertia, center of mass and cross-sectional area, similarly to the method proposed by Miranda et al. [23]. The point clouds representing both condyles, as isolated from the last step, were fitted with a cylinder. Following Miranda et al. [23], the centerline of this cylinder represented the ML-axis of the femur (Figure 1). Afterwards the surface of the posterior femoral condyles was split into a medial and lateral part, using a plane perpendicular to the centerline of the cylinder, positioned at its centroid. Next, the intercondylar notch and epicondylar surfaces of the condyles were excluded to select only the articulating surface of the condyles. Subsequently, the points of the articulating surface of both condyles were each individually fitted with a cylinder. The line connecting the centroids of the cylinders was used as the cylindrical axis.[8, 22] Using this cylindrical axis a new radius was determined for each condyle. The resulting axis formed the newly defined ML-axis of the femoral coordinate system (Figure 2). The anterio-posterior (AP) axis was computed by taking the cross product of the ML-axis and the mid-line of the femoral shaft. This mid-line was determined by the smallest inertial axis of the femoral shaft, congruent to the method proposed by Miranda et al. [23]. Finally, the distal-proximal (DP) axis was set orthogonal to both the AP and ML axes. The origin of the coordinate system was defined as the midpoint of the intersections of the ML-axis with the most medial and most lateral aspect of the femora [8]. The orientation method is bound to a minimal length requirement of the femoral shaft on the images, which should be larger than the diameter of the femoral shaft.

Validation of the method

The robustness of the developed algorithm was tested comparing the results applying the method three times at the 3D surface models of five fresh frozen cadaveric femora. The three outcome results for each femur were completely similar after each calculation.

The same five surface models were used to assess the changes of the cylinder fit and position and orientation of the coordinate system between the currently developed method and Miranda's method. The approximation of the medial and lateral condyles geometry with a

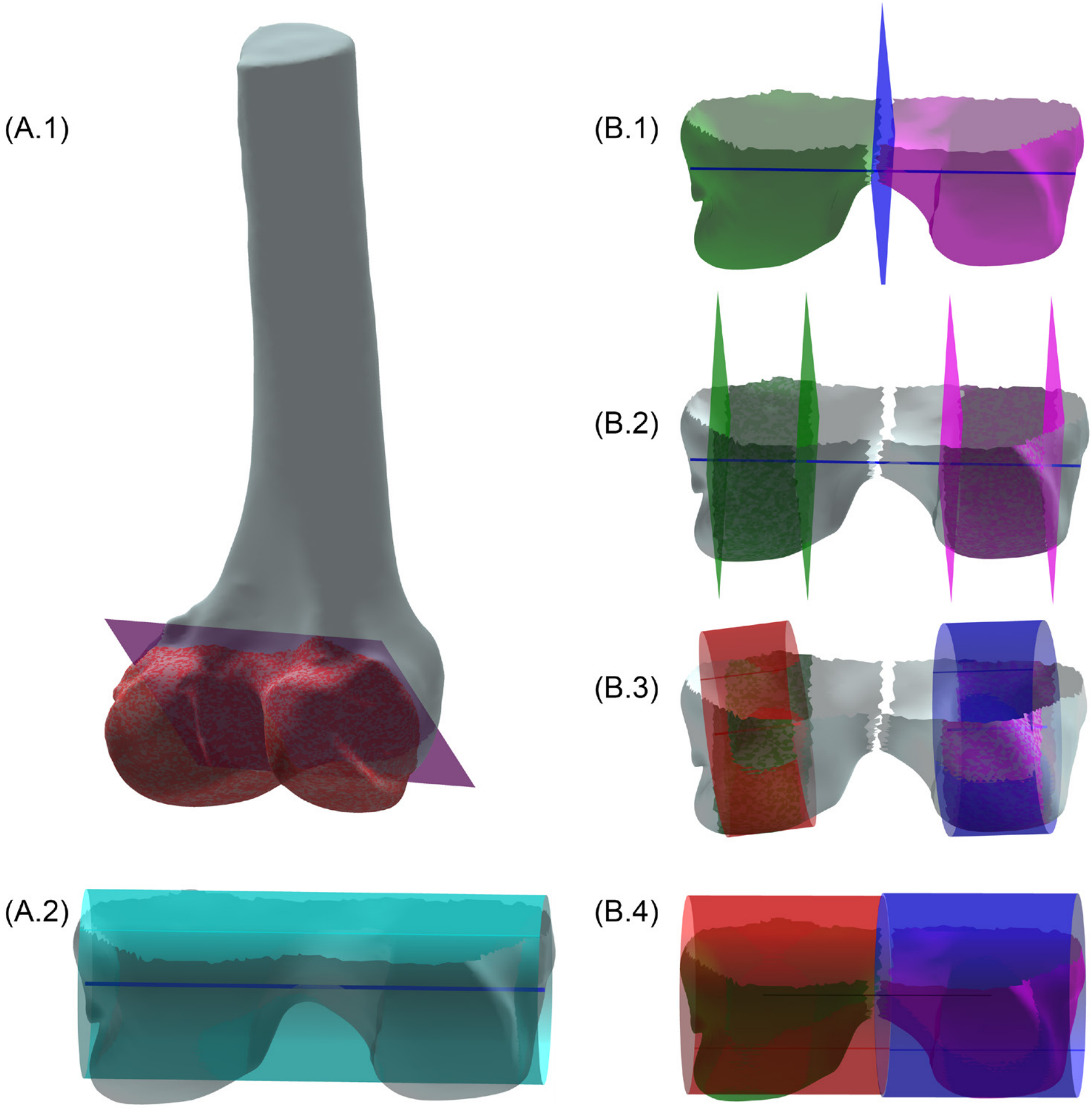

Figure 1. Construction of the ML-axis following Miranda et al. (A-B) and the proposed method (C-F) [23]; A) Isolated condyles using a plane orientated according to Miranda et al. B) The cylinder fitted to the condyles using a Matlab-based Gauss-Newton algorithm (The MathWorks, Natick, Massachusetts, USA). The blue line represents the centerline of the cylinder, which is denoted as the ML-axis of the coordinate system proposed by Miranda et al. (2010). C) Mutual perpendicular planes to this centerline are used to separate the condyles and isolate the articulating surfaces. Frontal view of the plane used to separate the condyles positioned at the center of the cylinder in B. D) Frontal view of the planes used to isolate the articulating surfaces. E) Two cylinders fitted to the medial and lateral articulating surfaces of the condyles using a Gauss-Newton algorithm F) ML-axis of the femur defined by the center points of the constructed cylinders for the lateral and medial femoral condyle.

cylinder, as obtained using both algorithms, was assessed. This was achieved by isolating the articular surface of the condyles corresponding to a flexion range of 20° to 120° and evaluating the root mean squared error (RMSE) of the fit to both cylinders. The RMSEs for the current method was almost twice as small (2.1±0.6 and 2.1±0.5) as the RMSEs found for Miranda's method (4.0±0.6 and 3.9±0.5). The outcomes for both methods differed on average 1.1±0.7 mm (range 0.4-2.8 mm) for the positions of the new origins and 1.9±0.7° (0.7-3.0°) for the orientations of the new coordinate system.

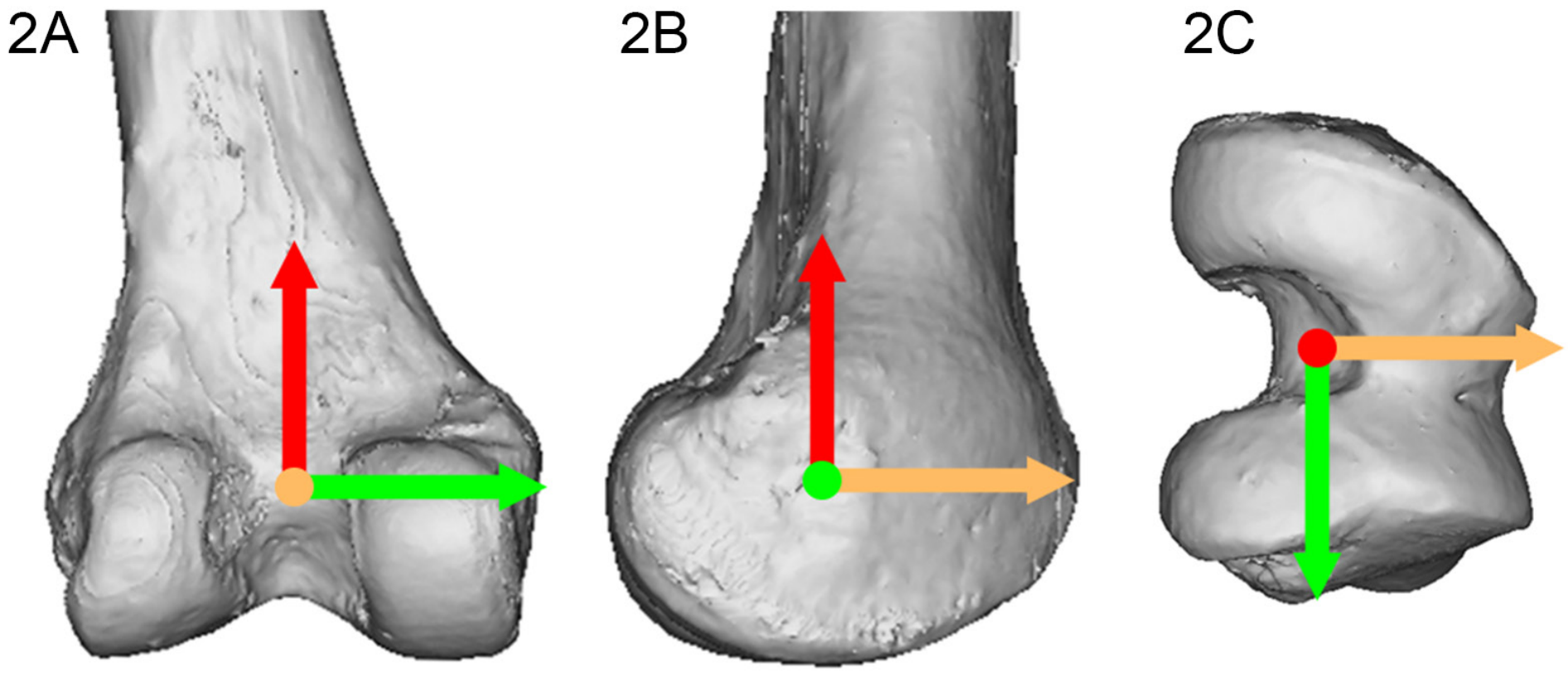

Figure 2. The axes of the new coordinate system in the distal femur. A) Dorsal view with mediolateral (ML, green and distal-proximal (DP, red) axes. B) Lateral view with DP (red) and anteroposterior (AP, orange) axes. C) Distal view with ML (green) and AP (orange) axes.

Part 2: ACL insertion site measurements in the femoral coordinate system

Specimens

Twelve embalmed knee joints of elderly donors (age and sex unknown) preserved in formalin, without signs of gross bony deformity and with intact knee ligaments were prepared, dissecting all tissue from tibia and femur keeping the ligaments and menisci intact. The two functional bundles of the ACL were separated during passive knee movement; the fibers tensed in and near extension, the posterolateral (PL) part, were discerned from the fibers tensed in flexion combined with passive anterior translation, the anteromedial (AM) part. The collateral ligaments, posterior cruciate ligament (PCL) and menisci were dissected, followed by the ACL fibers, marking the outlines of both insertion sites on the bone with a marker. Subsequently, these outlines were marked with leaded wire. CT scans of the femoral bones were made, followed by segmentation of the bone and the ACL outlines in Mimics, thereby ensuring orientation of the femur in the coordinate system as described above.

Femoral dimensions

In Mimics, the dimensions of the twelve distal femora were determined in mm (Figure 3). The height of the femoral condyle from distal to proximal (DP) in the axial plane was measured with the use of the circle method of Amis et al. [2]. In the sagittal plane, a circle was fitted at the dorsal contour of the medial condyle (Figure 3A), at approximately 50% of the medial condyle in mediolateral direction (green line Figure 3B-C). The distance between the first distal slice and the proximal top of the circle defined the condyle height (Figure 3A). The depth was the distance between the first and last slice in the coronal plane from anterior to posterior (AP) (Figure 3D). The femoral width was determined between the first and last slice in the sagittal plane (Figure 3E).

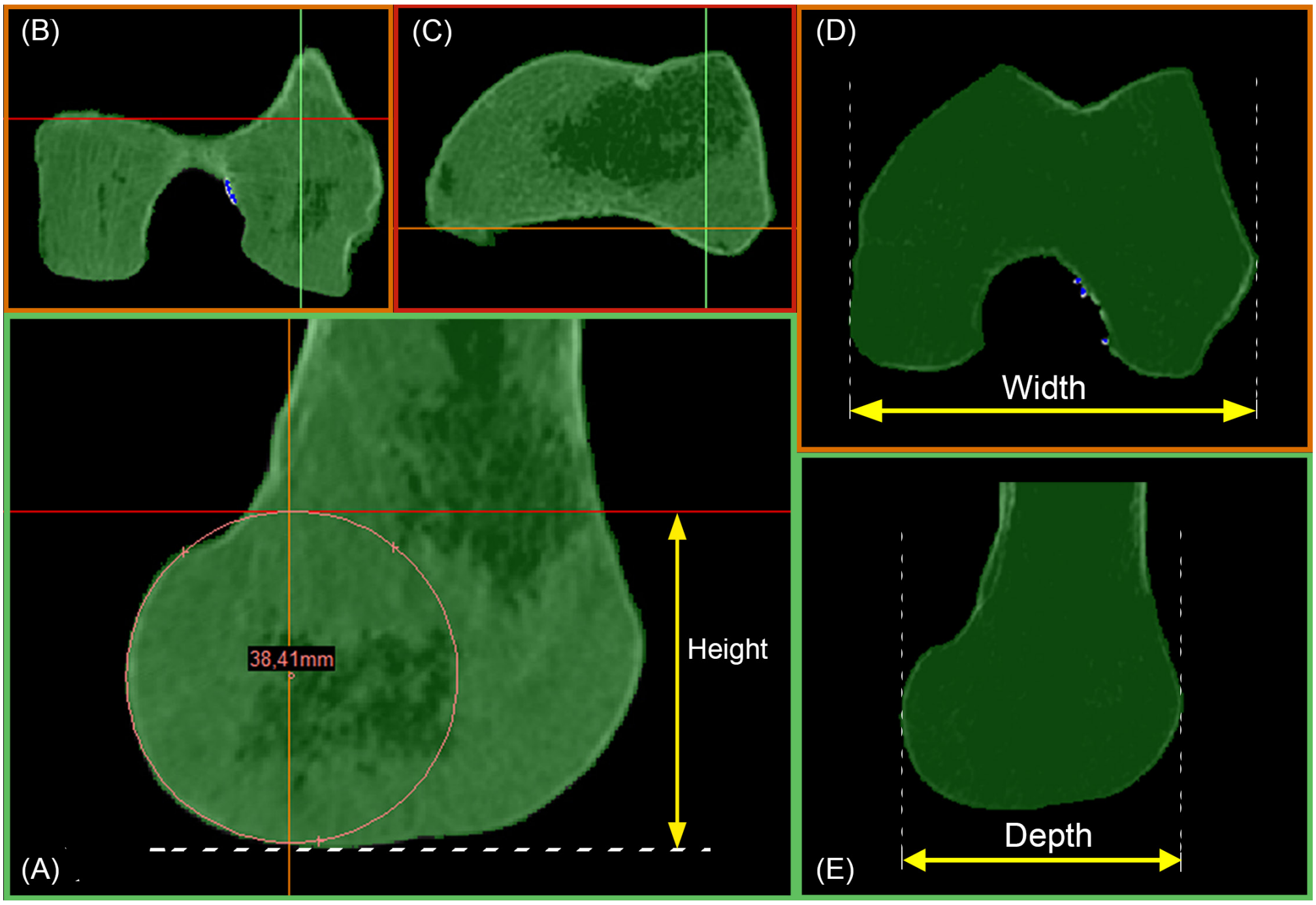

Figure 3. The dimensions of the distal femur. A) The height of the femoral condyle is defined between the distal and proximal end. The proximal end is determined by the top of a circle, fitted through the posterior medial condyle [2] in the sagittal plane (green line and box), at 50% of the medial condyle as displayed in B) the coronal plane (orange line and box) and C) axial plane (red line and box). D) The depth of the femur between the first and last slide in anteroposterior direction. E) The width of the femur between the first and last slide in mediolateral direction.

Center positions

The marked insertion outlines were segmented in Mimics and copied to Rhinoceros software (version 5 2013, McNeel North America, Seattle, USA). In this program, the centers of the ACL, AM and PL insertions were determined as the centroid of the area enclosed by the insertion outlines. Next, the visual information of the center position at the lateral view was applied to position the centers in Mimics (Figure 4). Finally, the coordinates of all centers in the three directions were quantified.

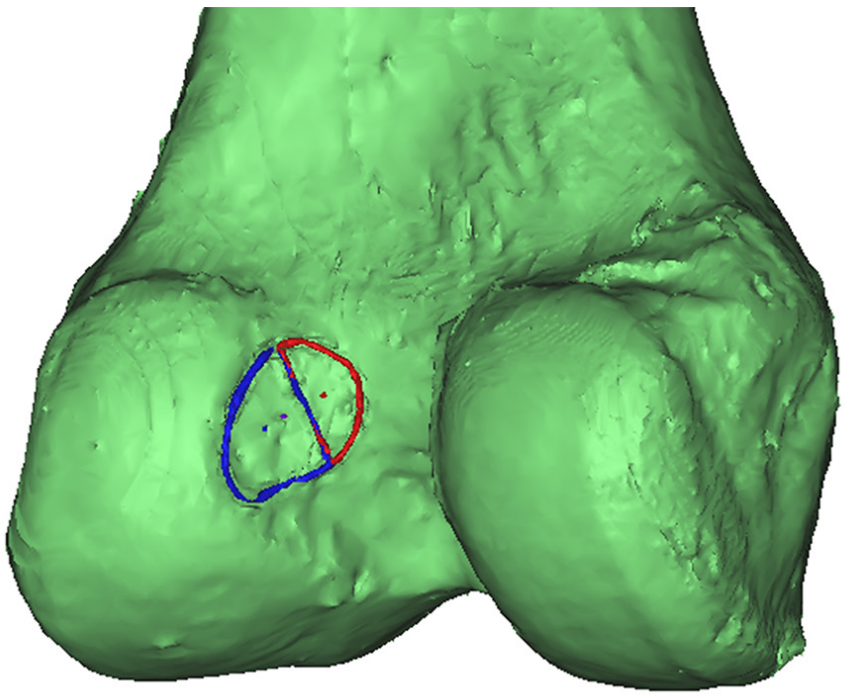

Figure 4. Surface model of the distal femur with the modelled insertion AM (red) and PL (blue) outlines and the ACL (purple), AM (red) and PL (blue) centers.

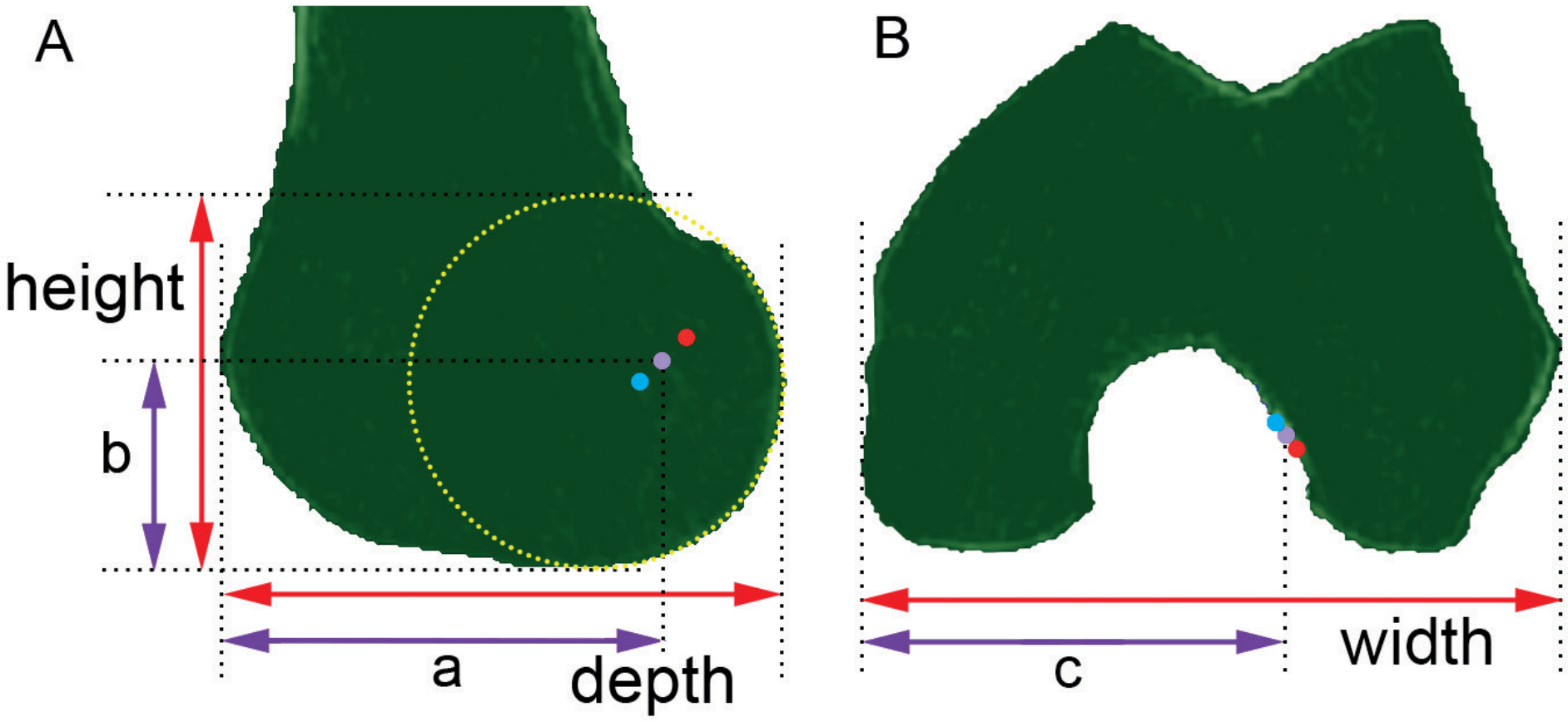

Figure 5. Calculation of the 3D positions of the insertion centers ACL (purple), AM (red) and PL (blue) relative to the dimensions of the distal femur. (A) Lateral view with the positions of the ACL center (purple) relative to femoral depth (a/depth) and height (b/height) and (B) femoral width (c/width).

Statistical analyses

The mean distal femoral dimensions and standard deviations (mm and %) were calculated. To determine the relations between the height, depth and width, correlations between these dimensions were calculated with Pearson correlation coefficient. The 3D coordinates of the ACL, AM and PL insertion centers were converted to relative positions in the distal femur using the determined dimensions (Figure 5). Finally, the mean percentages and standard deviations of these center positions were calculated.

Results

Femoral dimensions

The femoral dimensions are displayed in table 1. Strong correlations between the characteristic femoral dimensions were found. Pearson's correlation coefficients for the width with depth and height were 0.8; height and depth showed a correlation of 0.9.

Table 1. The average dimensions of twelve distal femora (in mm); and relative SD and range (in %)

	Mean (mm)	SD (mm)	SD (%)	Min -max (mm)	Range (mm)	Range (% mean)
Depth (AP)	65.4	4.3	7%	58.3 - 71.4	13.1	20%
Height (DP)	43.0	3.7	9%	37.7 - 49.2	11.5	27%
Width (ML)	82.5	5.5	7%	74.4 - 90.2	15.9	19%

AP=anterior-posterior; DP=distal-proximal; ML=medial-lateral

Table 2. The 3D positions of the ACL, AM and PL centers in twelve femora relative to the distal femoral dimensions (in %); and absolute SD and range (in mm)

	Mean (%)	SD (%)	SD (mm)	Min – max (%)	Range (%)	Range (mm)
ACL						
Depth (AP)	77.9	2.1	1.4	74.7 - 81.6	6.9	4.5
Height (DP)	65.2	3.2	1.4	59.6 - 70.3	10.7	4.6
Width (ML)	60.2	1.6	1.3	57.0 - 62.5	5.5	4.5
AM						
Depth (AP)	73.9	2.1	1.4	70.2 - 77.3	7.1	4.6
Height (DP)	69.4	3.1	1.3	64.2 - 74.1	9.9	4.2
Width (ML)	57.9	1.7	1.4	55.2 - 61.0	5.8	4.8
PL						
Depth (AP)	80.8	2.1	1.4	77.3 - 84.7	7.4	4.8
Height (DP)	62.3	3.1	1.3	56.5 - 66.7	10.2	4.4
Width (ML)	61.5	1.7	1.4	58.4 - 64.3	6.0	4.9

AP=anterior-posterior; DP=distal-proximal; ML=medial-lateral

Center positions

The ACL center was positioned at 22.1%, 65.2% and 60.2%, the AM at 26.1%, 69.4% and 57.9%; and the PL at 19.2%, 62.3% and 61.5%, relative to the femoral depth, height and width, respectively (Table 2). The 3D center positions relative to the distal femoral dimensions varied only slightly for ACL as well as AM and PL in the twelve femora, as indicated by the small SDs of 1.3-1.4 mm in all directions. Since the femoral height is the smallest dimension, the range in position in the proximal distal direction is relatively the largest. The AM and PL centers are on average at approximately equal distance from each other relative to the height (7.1%) and depth (6.8%), and located closest together in medio-lateral direction (3.6%).

Discussion

This study developed and tested with success an automated and objective distal femoral alignment method to define a reproducible coordinate system of the distal femur (Part 1). In this coordinate system, the 3D positions of the ACL centers were determined relatively to the characteristic dimensions of the distal femur, resulting in consistently located average center positions (Part 2), which can be used in femoral tunnel placement and evaluation.

CT data is often used to describe the positions of anatomical femoral ACL centers or tunnels, with most studies reporting the 2D positions in the sagittal plane relative to Blumensaat’s line. This is done either in the 2D coordinate system of the quadrant method [1, 20, 27, 36] or derivatives [19], or in other 2D coordinate systems [10, 14, 17, 36]. Kai et al. [17] included the transversal plane defining the positions with the clock method from the axial view at the distal femoral condyles. Two issues about these methods can be reported. Firstly, methods describing the position of the anatomical center or femoral tunnel in the sagittal plane require a true lateral femoral view [1, 10, 14, 19, 20, 27, 36], since alignment of the limb can cause significant errors in position estimates [6]. In the clock method correct orientation of the clock in the femoral notch is required, as well as controlling the rotation component of the femoral condyles [11]. Thus, accurate determination of the center and tunnel positions with both methods depends on correct projection. Although the CT technique offers the possibility to change orientation after scanning, unlike radiographic methods where femoral alignment has to be done prior to imaging, few CT studies reported the use of objective alignment methods. Secondly, the localization of the line of Blumensaat is exposed to subjectivity. It is a radiographic term and represents the projection of the roof of the femoral intercondylar notch, showing a highly variable shape, often undulating with a starting point which is difficult to define [15, 31]. To improve objective determination of insertion centers or tunnel locations, both issues have been addressed in this study.

In the first part, an objective femoral alignment method has been developed, based on the method of Miranda et al. [23]. We improved this method, developing a system, based on the fitting of two cylinders to both femoral condyles, instead of one cylinder through both femoral condyles. This new method resulted in reproducible positions of the origins and orientations of the coordinate system, slightly different relative to Miranda’s one cylinder method. Since the two cylinder method showed smaller errors in the fitting procedure, the new method proves to be an improved technique for femur alignment. With this automatic defined coordinate system, unique orientation of each distal femur was obtained, avoiding inaccuracies in center and tunnel positions through subjective estimation of the correct alignment.

In the second part of this study, the 3D positions of the ACL centers have been determined relative to easily detectable structures. It has been addressed in previous studies, that the positions of the ACL centers are consistent relative to the dimensions of the intercondylar notch [1, 4, 20, 27, 36]. Since the dimensions of the distal femur correlates with the notch height and width [24, 26, 28], these dimensions could appear to be simple references in the description of the center positions. Therefore, we first measured the femoral width, height and depth. The femoral dimensions found in the current study, as well as the detected correlations between the dimensions, corresponded with the outcomes of other studies [24, 26, 28]. These results confirmed the concept of the use of the femoral dimensions as reference in the description of the center positions. The positions of the ACL centers as measured relative to these landmarks in the current study turned out to be consistent, showing relative small standard deviations (1.3-1.4 mm). These variations are comparable to the standard deviations found with the quadrant method in lateral radiographs varying between 1.2 mm and 1.7 mm [21]. Bernard et al. [4] reported larger standard deviations of 2.2 and 2.5 mm for ACL center positions with the quadrant method.

The absolute results of the center positions of this study are difficult to compare to other studies, due to the new method, referencing the positions to the femoral dimensions. Scanlan et al. [34] presented the side-to-side differences in the location of the femoral ACL graft footprints in a similar coordinate system, defining the ML-axis conform Miranda’s method, measured on MRI. However, they did not present the center positions.

A disadvantage of the presented method is the use of CT scans, which are more expensive and expose the patient to a higher dose of radiation than plain radiographs. However, plain radiography sometimes demonstrates poor visibility of femoral tunnels [5, 12] and measurement accuracy depends on high quality images, for example fluoroscopic radiographs [35] and true lateral radiographs [6]. CT-scans are without these limitations and are identified as the most reliable imaging method for tunnel position evaluation relative to plain radiography [12]. As an alternative for regular CT-scan, cone-beam 3D CT imaging may be used thereby acquiring 3D images with a lower dose radiation [38]. In the current study we utilized dissected cadaveric femora for the anatomical study, whereas in reality the bones are surrounded with soft tissue. However, bony contours can be detected rather easily on CT scans, so measurement of the femoral dimensions should not be different.

Although the orientation method to define the local coordinate system requires a certain minimal length of the femoral shaft length on the image, we consider this requirement as an advantage as many orthopedic imaging studies would require a significant larger portion of the femoral shaft on the scans or even the complete femur. The fact that we only require a very small portion of the femoral shaft therefore facilitates application of our method on clinical CT scans.

We obviously used a relatively small number of specimens, similar to other comparable anatomical CT studies [1, 18, 20, 31, 36]. The specimens were obtained from Caucasian donors and the sex was unknown. The size and dimensions of female and male distal femora vary, also in different ethnicities [13]. It is unknown whether the current results are generalizable to other populations or if separate determination of the position relative to the distal male and female femur dimensions would result in different data.

Conclusion

We introduced an automated, reproducible method to objectively define a 3D coordinate system, requiring only a small part of the distal femur, being therefore highly suitable for clinical application. With this coordinate system, the 3D positions of the ACL, AM and PL centers relative to simple detectable references (i.e. the distal femoral dimensions) can be determined. The methodology and results can be used to improve femoral tunnel positioning in anatomical single bundle or double bundle ACL reconstruction, applying the guidelines in the development of patient specific instruments and pre/intra-operative planning of the femoral tunnel positions in three planes with navigation systems and in postoperative tunnel location evaluation.

References

1. Abreu-E-Silva GM De, Oliveira MHGCN De, Maranhão GS, Deligne LDMC, Pfeilsticker RM, Novais ENV, Nunes TA, Andrade MAP De (2015) Three-dimensional computed tomography evaluation of anterior cruciate ligament footprint for anatomic single-bundle reconstruction. Knee Surg Sport Traumatol Arthrosc 23:770–776.
2. Amis AA, Beynnon B, Blankevoort L, Chambat P, Christel P, Durselen L, Friederich N, Grood E, Hertel P, Jakob R, Müller W, O'Brien M, O'Connor J (1994) Proceedings of the ESSKA Scientific Workshop on Reconstruction of the Anterior and Posterior Cruciate Ligaments. Knee Surg Sport Traumatol Arthrosc 2:124–132.
3. Basdekis G, Christel P, Anne F (2009) Validation of the position of the femoral tunnels in anatomic double-bundle ACL reconstruction with 3-D CT scan. Knee Surg Sport Traumatol Arthrosc 17:1089–1094.
4. Bernard M, Hertel P, Hornung H, Cierpinski T (1997) Femoral insertion of the ACL. Radiographic quadrant method. Am J Knee Surg 10:14–21.
5. Dargel J, Schmidt-Wiethoff R, Fischer S, Mader K, Koebke J, Schneider T (2009) Femoral bone tunnel placement using the transtibial tunnel or the anteromedial portal in ACL reconstruction: a radiographic evaluation. Knee Surg Sport Traumatol Arthrosc 17:220–227.
6. van Eck CF, Wong AK, Irrgang JJ, Fu FH, Tashman S (2012) The effects of limb alignment on anterior cruciate ligament graft tunnel positions estimated from plain radiographs. Knee Surg Sport Traumatol Arthrosc 20:979–985.
7. Eckhoff DG, Bach JM, Spitzer VM, Reinig KD, Bagur MM, Baldini TH, Flannery NM (2005) Three-dimensional mechanics, kinematics, and morphology of the knee viewed in virtual reality. J Bone Joint Surg Am 87 Suppl 2:71–80.
8. von Eisenhart-Rothe R, Bringmann C, Siebert M, Reiser M, Englmeier KH, Eckstein F, Graichen H (2004) Femoro-tibial and menisco-tibial translation patterns in patients with unilateral anterior cruciate ligament deficiency--a potential cause of secondary meniscal tears. J Orthop Res 22:275–282.
9. Fernandes TL, Fregni F, Weaver K, Pedrinelli A, Camanho GL, Hernandez AJ (2014) The influence of femoral tunnel position in single-bundle ACL reconstruction on functional outcomes and return to sports. Knee Surg Sports Traumatol Arthrosc 22:97–103.
10. Forsythe B, Kopf S, Wong AK, Martins CAQ, Anderst W, Tashman S, Fu FH (2010) The location of femoral and tibial tunnels in anatomic double-bundle anterior cruciate ligament reconstruction analyzed by three-dimensional computed tomography models. J Bone Joint Surg Am 92:1418–1426.
11. Han Y, Hart A, Martineau PA (2014) Is the clock face an accurate, precise, and reliable measuring tool for anterior cruciate ligament reconstruction? Arthroscopy 30:849–855.
12. Hoser C, Tecklenburg K, Kuenzel KH, Fink C (2005) Postoperative evaluation of femoral tunnel position in ACL reconstruction: Plain radiography versus computed tomography. Knee Surg Sport Traumatol Arthrosc 13:256–262.
13. Hussain F, Abdul Kadir MR, Zulkifly AH, Sa'at A, Aziz AA, Hossain G, Kamarul T, Syahrom A (2013) Anthropometric measurements of the human distal femur: a study of the adult Malay population. Biomed Res Int 2013:175056.
14. Inoue M, Tokuyasu S, Kuwahara S, Yasojima N, Kasahara Y, Kondo E, Onodere S, Yasuda K (2010) Tunnel location in transparent 3-dimensional CT in anatomic double-bundle anterior cruciate ligament reconstruction with the trans-tibial tunnel technique. Knee Surg Sports Traumatol Arthrosc 18:1176–1183.
15. Iriuchishima T, Ryu K, Aizawa S, Fu FH (2015) Blumensaat's line is not always straight: morphological variations of the lateral wall of the femoral intercondylar notch. Knee Surg Sport Traumatol Arthrosc Epub:10.1007/s00167–015–3579–7.
16. Iwaki H, Pinskerova V, Freeman MA (2000) Tibiofemoral movement 1: the shapes and relative movements of the femur and tibia in the unloaded cadaver knee. J Bone Jt Surg Br 82:1189–1195.
17. Kai S, Kondo E, Kitamura N, Kawaguchi Y, Inoue M, Amis AA, Yasuda K (2013) A quantitative technique to create a femoral tunnel at the averaged center of the anteromedial bundle attachment in anatomic double-bundle anterior cruciate ligament reconstruction. BMC Musculoskelet Disord 14:189.
18. Kopf S, Forsythe B, Wong AK, Tashman S, Anderst W, Irrgang JJ, Fu FH (2010) Nonanatomic tunnel position in

traditional transtibial single-bundle anterior cruciate ligament reconstruction evaluated by three-dimensional computed tomography. J Bone Joint Surg Am 92:1427–1431.

19. Lertwanich P, Martins CAQ, Asai S, Ingham SJM, Smolinski P, Fu FH (2011) Anterior cruciate ligament tunnel position measurement reliability on 3-dimensional reconstructed computed tomography. Arthroscopy 27:391–398.
20. Lorenz S, Elser F, Mitterer M, Obst T, Imhoff AB (2009) Radiologic evaluation of the insertion sites of the 2 functional bundles of the anterior cruciate ligament using 3-dimensional computed tomography. Am J Sports Med 37:2368–2376.
21. Luites JWH, Verdonschot N (2015) Radiographic positions of femoral ACL, AM and PL centres: accuracy of guidelines based on the lateral quadrant method. Knee Surg Sports Traumatol Arthrosc Epub:10.1007/s00167–015–3681–x.
22. McPherson A, Kärrholm J, Pinskerova V, Sosna A, Martelli S (2005) Imaging knee position using MRI, RSA/CT and 3D digitisation. J Biomech 38:263–268.
23. Miranda DL, Rainbow MJ, Leventhal EL, Crisco JJ, Fleming BC (2010) Automatic determination of anatomical coordinate systems for three-dimensional bone models of the isolated human knee. J Biomech 43:1623–1626.
24. Monk AP, Choji K, O'Connor JJ, Goodfellow JW, Murray DW (2014) The shape of the distal femur: a geometrical study using MRI. Bone Jt J 96-B:1623–1630.
25. Morgan JA, Dahm D, Levy B, Stuart MJ (2012) Femoral Tunnel Malposition in ACL Revision Reconstruction. J Knee Surg 25:361–368.
26. Murshed KA, Cicekcibasi AE, Karabacakoglu A, Seker M, Ziylan T (2005) Distal femur morphometry: a gender and bilateral comparative study using magnetic resonance imaging. Surg Radiol Anat 27:108–112.
27. Musahl V, Burkart A, Debski RE, Van Scyoc A, Fu FH, Woo SLY (2003) Anterior cruciate ligament tunnel placement: Comparison of insertion site anatomy with the guidelines of a computer-assisted surgical system. Arthroscopy 19:154–160.
28. Nishikawa M, Owaki H, Kaneshiro S, Fuji T (2014) Preoperative morphometric differences in the distal femur are based on skeletal size in Japanese patients undergoing total knee arthroplasty. Knee Surg Sport Traumatol Arthrosc 22:2962–2968.
29. Park JS, Park JH, Wang JH, Oh CH, Hwang MH, Lee SH, Kim JG (2015) Comparison of femoral tunnel geometry, using in vivo 3-dimensional computed tomography, during transportal and outside-in single-bundle anterior cruciate ligament reconstruction techniques. Arthroscopy 31:83–91.
30. Pavlov H, Freiberger RH, Deck MF, Marshall JL, Morrissey JK (1978) Computer-assisted tomography of the knee. Invest Radiol. 13:57–62.
31. Ramme AJ, Wolf BR, Warme BA, Shivanna KH, Willey MC, Britton CL, Magnotta VA, Grosland NM (2012) Surgically oriented measurements for three-dimensional characterization of tunnel placement in anterior cruciate ligament reconstruction. Comput Aided Surg 17:221–231.
32. Rickards D, Chapman JAA (1984) Computed tomography of the anterior cruciate ligament. Clin Radiol 35:327–329.
33. Sadoghi P, Kröpfl A, Jansson V, Müller PE, Pietschmann MF, Fischmeister MF (2011) Impact of tibial and femoral tunnel position on clinical results after anterior cruciate ligament reconstruction. Arthroscopy 27:355–364.
34. Scanlan SF, Lai J, Donahue JP, Andriacchi TP (2012) Variations in the three-dimensional location and orientation of the ACL in healthy subjects relative to patients after transtibial ACL reconstruction. J Orthop Res 30:910–918.
35. Sullivan JP, Matava MJ, Flanigan DC, Gao Y, Britton CL, Amendola A, Wolf BR (2012) Reliability of tunnel measurements and the quadrant method using fluoroscopic radiographs after anterior cruciate ligament reconstruction. Am J Sports Med 40:2236–2241.
36. Westermann R, Sybrowsky C, Ramme A, Amedola A, Wolf BR (2014) Three-dimensional characterization of the anterior cruciate ligament's femoral footprint. J Knee Surg 27:53–58.
37. Zantop T, Petersen W, Sekiya JK, Musahl V, Fu FH (2006) Anterior cruciate ligament anatomy and function relating

to anatomical reconstruction. Knee Surg Sports Traumatol Arthrosc 14:982–92.

38. Zbijewski W, De Jean P, Prakash P, Ding Y, Stayman JW, Packard N, Senn R, Yang D, Yorkston J, Machado A, Carrino JA, Siewerdsen JH (2011) A dedicated cone-beam CT system for musculoskeletal extremities imaging: Design, optimization, and initial performance characterization. Med Phys 38:4700.


Raffi & Eli

CHAPTER 5

Development of a femoral template for computer-assisted tunnel placement in anatomical double-bundle ACL reconstruction

Joan W.H. Luites, Ate B. Wymenga, Leendert Blankevoort, Jan G.M. Kooloos
and Nico Verdonschot

Computer Aided Surgery January 2011; 16(1): 11–21

Abstract

Femoral graft placement is an important factor in the success of anterior cruciate ligament (ACL) reconstruction. In addition to improving the accuracy of femoral tunnel placement, Computer Assisted Surgery (CAS) can be used to determine the anatomic location. This is achieved by using a 3D femoral template which indicates the position of the anatomical ACL center based on endoscopically measurable landmarks. This study describes the development and application of this method. The template is generated through statistical shape analysis of the ACL insertion, with respect to the anteromedial (AM) and posterolateral (PL) bundles. The ligament insertion data, together with the osteocartilage edge on the lateral notch, were mapped onto a cylinder fitted to the intercondylar notch surface (N = 33). Anatomic variation, in terms of standard variation of the positions of the ligament centers in the template, was within 2.2 mm. The resulting template was programmed in a computer-assisted navigation system for ACL replacement and its accuracy and precision were determined on 31 femora. It was found that with the navigation system the AM and PL tunnels could be positioned with an accuracy of 2.5 mm relative to the anatomic insertion centers; the precision was 2.4 mm. This system consists of a template that can easily be implemented in 3D computer navigation software. Requiring no preoperative images and planning, the system provides adequate accuracy and precision to position the entrance of the femoral tunnels for anatomical single- or double-bundle ACL reconstruction.

Introduction

Anatomical double-bundle reconstructions to restore anterior cruciate ligament (ACL) ruptures have become popular over the last few decades. The aim of the double-bundle technique is to restore the anteromedial (AM) bundle as well as the posterolateral (PL) bundle at their anatomical attachment sites, resulting in the most physiological functioning of the restored ACL. A single-bundle AM reconstruction is able to restore anterior translation, especially in the higher flexion region [1–3]. The additional graft, which reconstructs the PL bundle, provides for a more physiological anterior translation in the lower flexion angles and at full extension [4, 5] and, perhaps more importantly, for rotational stability in that range [6–8]. Therefore, a double-bundle reconstruction is theoretically better able to restore normal knee stabilization and kinematics than a traditional single-bundle reconstruction, particularly with regard to reduction of the pivot shift [9–12].

However, the introduction of an extra bundle into the reconstruction technique also means the introduction of more technical difficulties. Since there are two grafts, two tunnels have to be created, and fixation of the bundles can be more complicated. These issues can lead to additional sources of failure [13]. Exact graft placement is one of the most complicated steps during ACL surgery, and large numbers of misplaced grafts have been reported [14–16]. These misplacements can be attributed in part to the nature of the arthroscopic procedure: The view is restricted to a local part of the ligament attachment site, and only a two-dimensional (2D) view of the three-dimensional (3D) reality can be displayed through the endoscope. Since it is difficult to judge depth from a 2D view, and because the view is so limited, it is difficult to find the correct positions for tunnel placement.

Studies have demonstrated the relationship between graft positioning errors and clinical results [17, 18]. Incorrectly placed grafts lead to unstable knees [4, 19, 20], and these patients are prone to developing early osteoarthritis [21]. In an anatomical reconstruction with two bundles, graft placement becomes even more relevant than in single-bundle reconstructions; grafts must be positioned accurately not only with respect to the surrounding tissues, but also relative to one another. Since the femoral positioning is most important [16] and most difficult to achieve [14], this study is focused on the femoral attachment sites.

Basic anatomical studies have improved the description and understanding of the position of the ACL and its two bundles in the femoral notch [22–29]. Studies to develop improved methods for accurate femoral tunnel positioning and drilling have encompassed radiographic guidelines [16, 30], tensiometers and femoral aiming guides [31, 32], computer-assisted fluoroscopic navigation [33–35], computer-assisted real-time navigation [36–41] and robotic-assisted surgery systems [42, 43]. Passive computer-assisted navigation and active robotic-assisted surgery systems can contribute to minimizing variation in graft placement. The initial reports on the use of these innovative systems in ACL reconstruction have provided clear evidence that more exact bone tunnel placement relative to the preferred position can be achieved with both passive and active systems than with conventional techniques [40, 41, 44–47].

Several tools have been developed to find the position for graft placement with the assistance of navigation using a Computer Assisted Surgery (CAS) system. These are based on two different methods: One method uses images, such as preoperative radiographs [37] and CT

[43] or intraoperative fluoroscopic computer overlay techniques [44]; the other method is image-free and uses real-time navigation, which means that structures can be digitized during surgery. With the latter method, the 3D anatomical data of the patient's knee is used to find the preferred graft position. In current systems, this method is mostly used to find positions in which notch impingement is avoided, and to locate the most isometric zone [38] for isometric single-bundle ACL reconstruction. However, this is not sufficient for anatomical double-bundle reconstruction, in which the two bundles are attached at their original anatomical positions, which do not coincide with the isometric zone.

If computer navigation systems are to be used for exact anatomical double-bundle placement, the question arises as to the location where the two bundles should be attached. This information is currently lacking, with the result that navigation systems are not used to their full potential in double-bundle reconstructions. With CAS, it is common to morph the individual bone to a standardized bone that is stored within the computer. This approach could also be applied to ACL surgery, standardizing the positions of the insertion centers of the AM and PL bundles. In a previous study [23], we determined the insertion centers of the anteromedial and posterolateral bundles of the ACL in cadaver knees. The purpose of the current study was to generate a standardized template, incorporated in a CAS system, by quantifying the femoral insertion centers of the AM and PL bundles in the notch. To this end, we first developed a template and determined whether the anatomical variation of the center locations in the template was within acceptable limits. We then determined the accuracy and precision of the template as incorporated in the CAS system with respect to positioning of the AM and PL tunnels.

Material and methods

Development of a femoral template

In the first part of this study, a template of the femoral notch including the mean positions of the anatomical insertion centers was developed. Thirty-three human cadaver femoral bones were used for this phase. These femora were previously dissected for an anatomical study of the insertion site of the two bundles of the ACL [23]. The bones were preserved in formalin, and no exact data on the gender and age of the donors was available. However, all donors were over 60 years old, and no gross deformation of the bony structures was observed. On each femur, the outlines of the insertion sites of both the AM bundle and the PL bundle were marked with an ink line. The ACL fibers had been divided during passive knee movement: the fibers of the part that was slack in flexion, the PL bundle, were separated with a sharp scalpel from the fibers that were tight with the knee in that position, i.e., the AM bundle.

To enable definition of the insertion sites in the local coordinate system of the femur, the following points (Figure 1) were digitized using an electro-magnetic 3Space Fastrak system (Polhemus Navigation Sciences, Colchester, VT):

I. Ligament outline points: the attachment sites of the ACL and its two separate bundles (AM and PL), by means of points distributed over the outlines of the three insertion areas;

II. Notch surface points (roof points): a mapping of the uncovered part of the surface of the lateral and medial wall and the roof of the intercondylar notch, by means of distributed multiple points;

III. Cartilage line points: the posterior joint cartilage edge at the medial wall in the lateral notch, by means of points distributed on the total osteocartilage transition line.

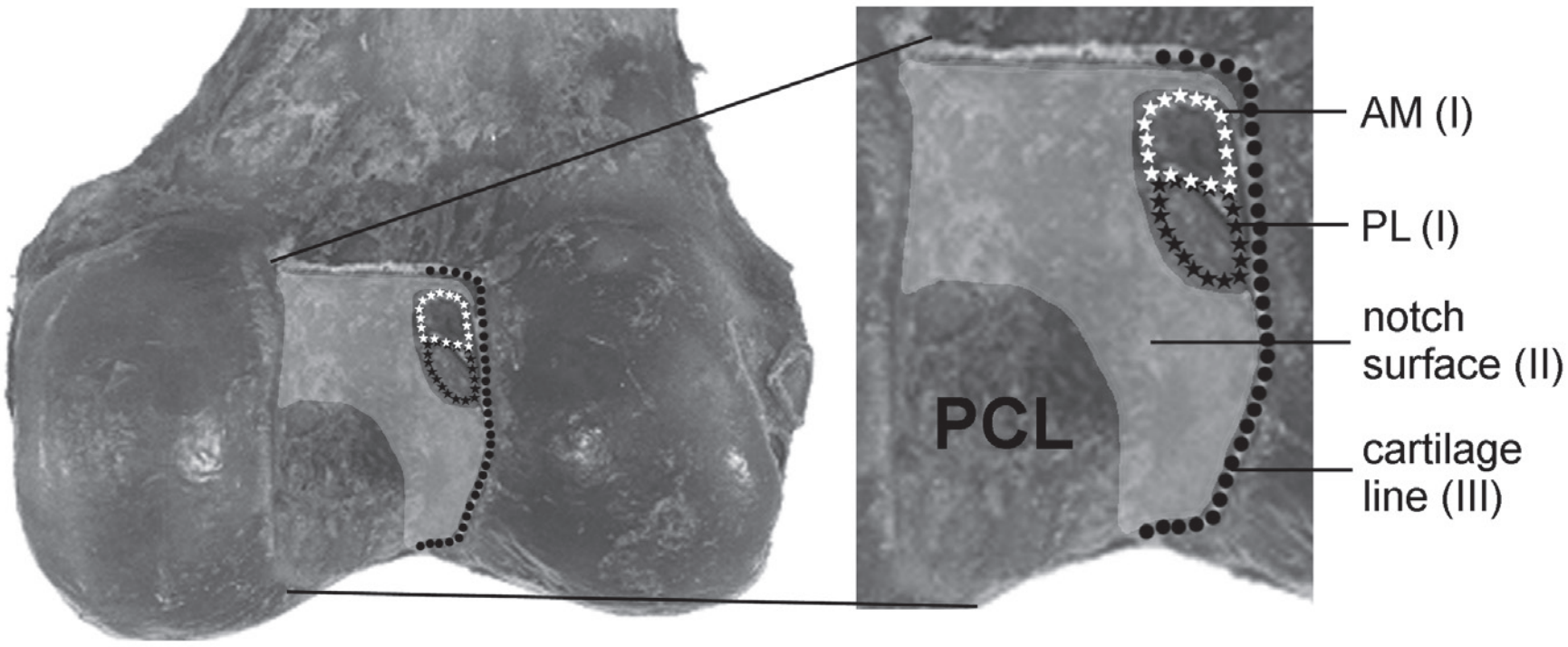

Figure 1. Dorsal view of the femoral intercondylar notch with the areas three-dimensionally digitized by Fastrak: (I) the outlines of the AM (white stars) and PL (black stars) ligament insertion sites; (II) the surface of the lateral notch (including the insertion areas); and (III) the cartilage line of the posterior joint cartilage edge at the medial wall of the lateral condyle (black dots).

The accuracy of the x, y and z coordinates of each point, as digitized with the stylus, was 0.35 mm [48]. Hence, 33 files were acquired, each containing the femoral ACL insertion sites relative to the anatomical distal geometry of a femur. In the next step, the points were used to define a template including the center positions of the ACL, AM bundle and PL bundle. These centers were determined as the geometric mean of all collected points on the outlines (I).

First, the roof points (II) were used to define a 3D model in the notch, fitting a cylinder shape through these points using a least-squares fit. The roof points determined the radius, orientation and position of the cylinder (Figure 2).

Then, the points of the cartilage line (III) were projected perpendicularly on the surface of the cylinder to define them in the cylindrical coordinate system, using a coordinate in the longitudinal direction (Z in mm) and an angle in the transverse plane (φ in rad) (Figure 3).

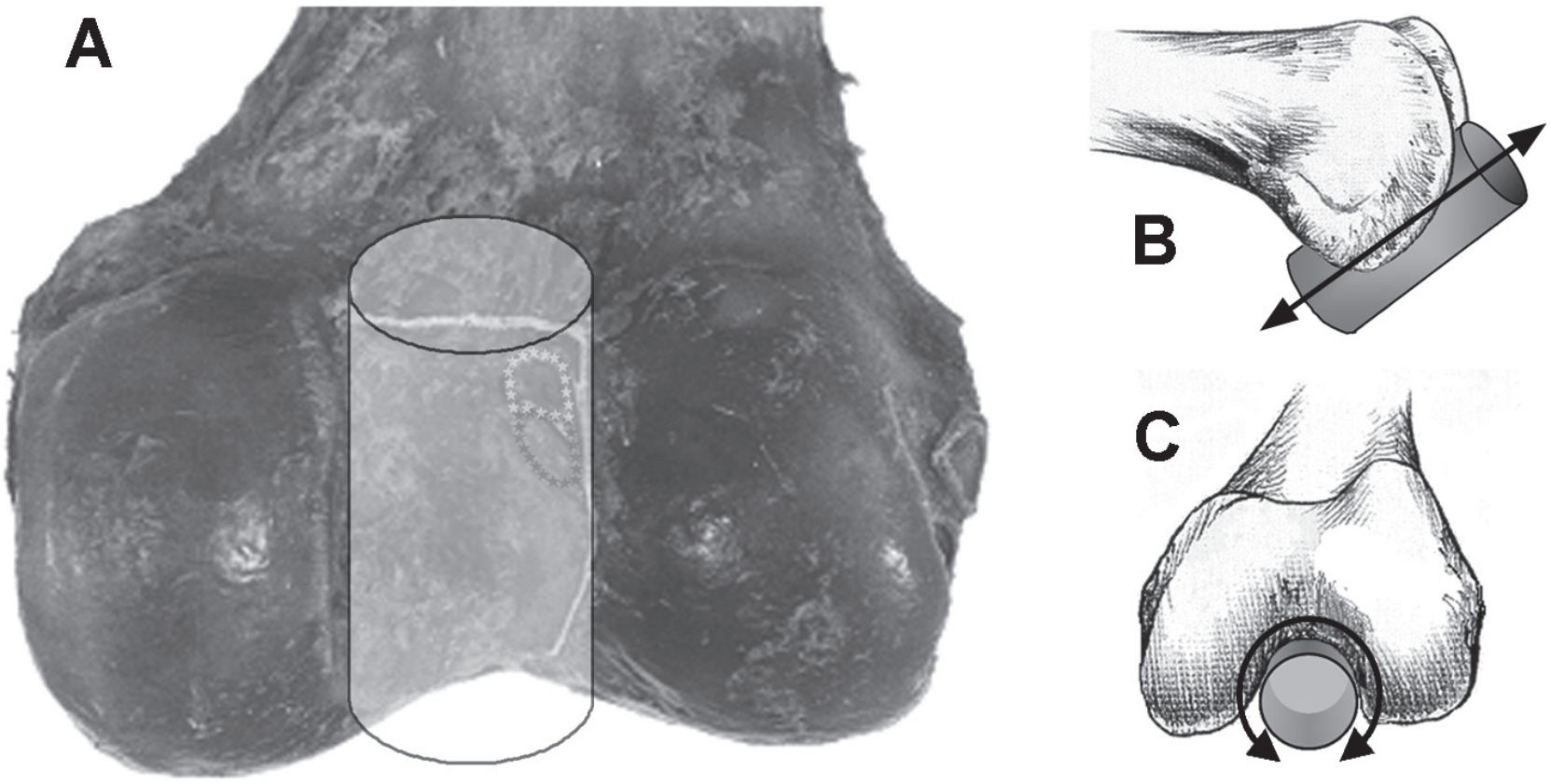

Figure 2. The notch surface in the dorsal view (A), lateral view (B) and notch view (C), which can be approximated by a cylindrical shape. A) The radius, orientation and position of the cylinder are determined by the roof points. B) The cylinder position in the proximal-distal direction and C) the rotation along the longitudinal axis were determined by the origin (0, 0) of the cylindrical coordinate systems (also see Figure 3).

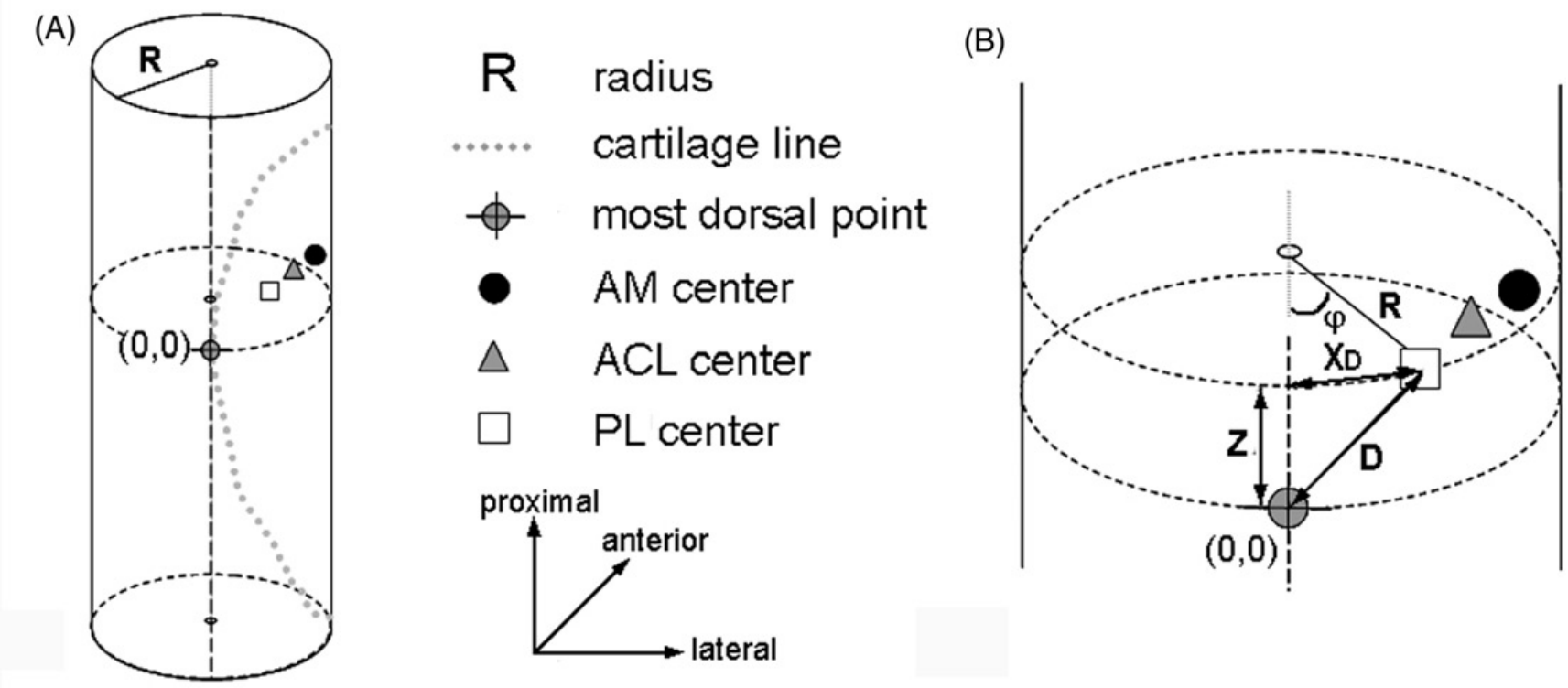

*Figure 3. A) Ventrolateral view of the fitted cylinder with the projected data of the cartilage border and the AM and PL insertion centers. A parabolic curve was fitted through the points of the cartilage border. The top of the parabola was defined as the origin (0, 0) at the cylindrical surface. B) From the mean center points, the distance in the axial direction (Z) in mm and the angle φ were defined. The direct distance (2D vector D) between the centers and the origin was calculated with Pythagoras' theorem, with XD being the result of sin 0.5φ*R*2.*

Subsequently, the most dorsal point, the apex of the curved posterior joint cartilage edge, was found by fitting a second-order polynomial through its cylinder coordinates by a least-squares fit. The top of this parabola was the most dorsal point and was defined as the origin (0, 0) of the cylindrical coordinate system, determining the cylinder position in the proximal-distal direction and the rotation along the longitudinal axis (Figure 3A). To quantify the validity of the chosen curve-fitting method, the mean explained variances (R2) of all fits were calculated. Finally, the points of the ACL, AM and PL centers were projected perpendicularly on the surface of the cylinder. The positions were determined by the Z coordinate and angle φ in the cylindrical coordinate system. The angle φ determined the X coordinate and the value of the 2D vector D, the distance between the origin and the three centers of the ACL, AM bundle and PL bundle (Figure 3B).

To develop an average cylinder-based insertion definition, the 33 individual cylinders were scaled. The mean radius (R) of all cylinders was calculated, and the ratio of the individual radius to the mean radius resulted in the individual scaling factor. With this factor, each cylinder with the projected points on its surface was scaled. In the last stage of the development, the mean positions of the 33 ACL, AM and PL insertion centers relative to the cylindrical origin were calculated, thereby quantifying the distance Z (in mm), the angle φ (in rad) and the 2D vector D.

To address the first research question, the anatomical variation in the positions of the centers in the developed template was quantified by calculating the SD of the vectors (D) between the centers and the apex of the cartilage border. The 95% CI (as 2 x 1.96 SD) was displayed in both directions in a diagram to visualize the size of the area in which 95% of the anatomical centers were positioned.

Femoral template incorporation

To enable the femoral template to be used for anatomical positioning of the tunnels in the individual patient during ACL reconstruction, it was incorporated in the ACL Replacement Module of the SurgiGATE navigation system (Medivision, Oberdorf, Switzerland). This system and the associated software were developed at the M.E. Müller Institute for Biomechanics at the University of Bern for performing intraoperative planning for ACL replacement [37, 38]. The system consists of an opto-electric camera (Optotrak 3020; Northern Digital, Inc., Waterloo, Ontario, Canada), a computer and computer-tracked devices. The Optotrak system has three cameras that track the 3D positions of light-emitting diodes (LEDs). The LEDs are located on the dynamic reference bases (DRBs), which are rigidly fixated to the femur and tibia of the patient. LEDs are also mounted on specially designed surgical instruments to enable navigated surgery. This system allows for real-time tracking of the bones and interactive digitization and labeling of anatomical structures identified under direct visual or endoscopic control. The interface of the SurgiGATE system guides the surgeon through the steps of acquiring the required landmarks for the template alignment. First, the DRB is fixed to the femur so that it can be used to digitize points on the femur. The Optotrak system tracks the LEDs on the DRB and the ACL module displays them on the monitor. Subsequently, the computer-tracked pal- pation hook (Stille hook) and a computer-tracked pedicle awl are calibrated. The axes of the femur (the long axis between the trochanter major femoralis and the mid condyles, and the medial-lateral axis between the femoral epicondyles) are digitized with the Stille hook to provide the system with information about the orientation of the femur. During the following steps the surgeon digitizes femoral points, after which the template is aligned in the femoral notch by the program:

1. The notch surface is digitized as a cloud of points by the surgeon (Figure 4A) and visualized by the program with a 3D surface fitted through the points with a Levenberg-Marquardt algorithm (Figure 4B). The cylinder algorithm starts to fit the cylinder template onto the notch surface points, and the size, position and orientation are determined. Since surgical orientation of the reference base on the femur is arbitrary, the system can give several different starting conditions for both algorithms; it chooses the solution having the smallest residual. Refining the notch surface with additional points can also improve cylinder positioning.

2. The cartilage line is digitized through multiple points on the posterior joint cartilage edge (Figure 5A). After the input of the last point, the system places the template in the notch, positioning the origin of the cylindrical coordinate system at the apex of the curve of the cartilage line (Figure 5B). Rotation about the cylindrical axis and positioning in the proximo-distal direction are determined. The template is visualized as a 3D cylinder to verify proper algorithm convergence. The AM, PL and ACL center points are also projected.

3. The drill-hole location(s) in the notch can be marked with a physical indent of the computer-tracked awl (Figure 6A). The anatomic center, target point for the mark, is visualized on the CAS system monitor, as is the awl (Figure 6B).

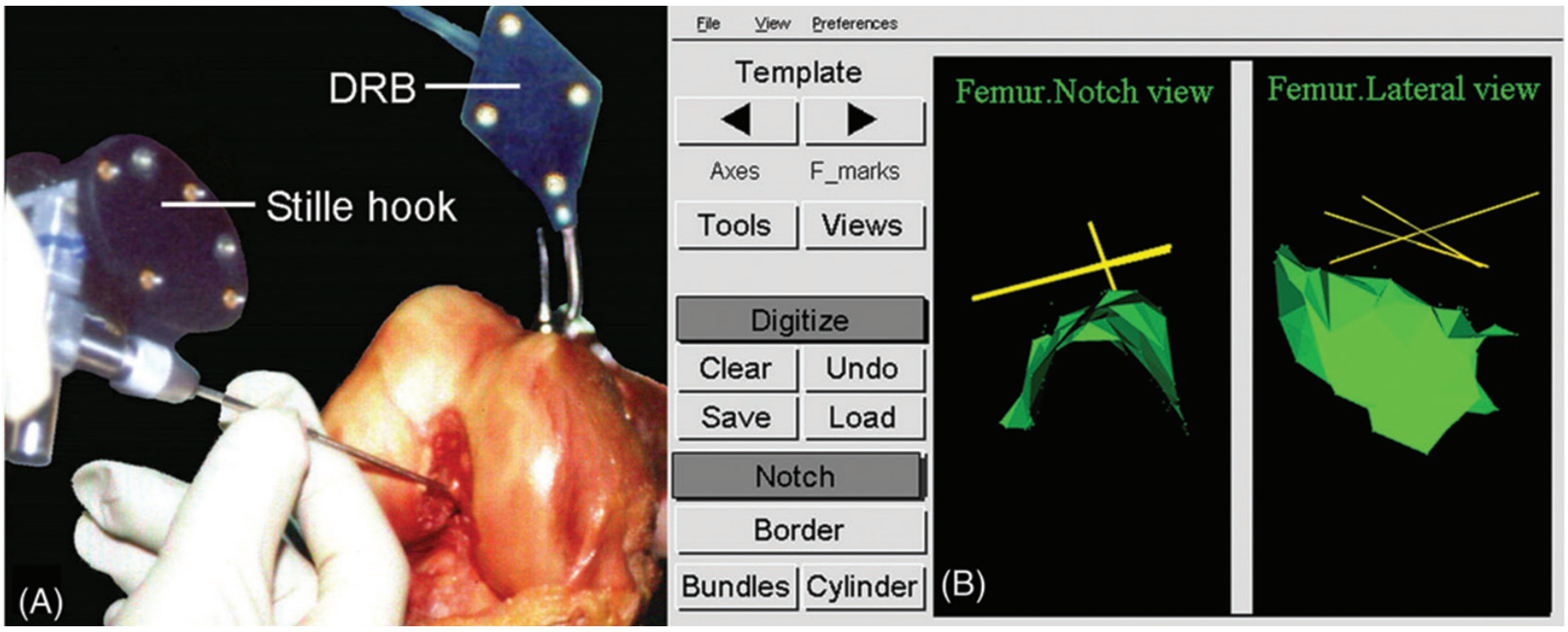

Figure 4. A) Digitizing the notch surface points with the computer-tracked Stille hook. The femur is tracked through the dynamic reference base (DRB). B) The digitized notch surface is visualized in three dimensions with a Levenberg-Marquardt algorithm for better orientation. The CAS system is calculating the cylinder-algorithm to fit the notch surface. Left: notch view; right: lateral-medial view

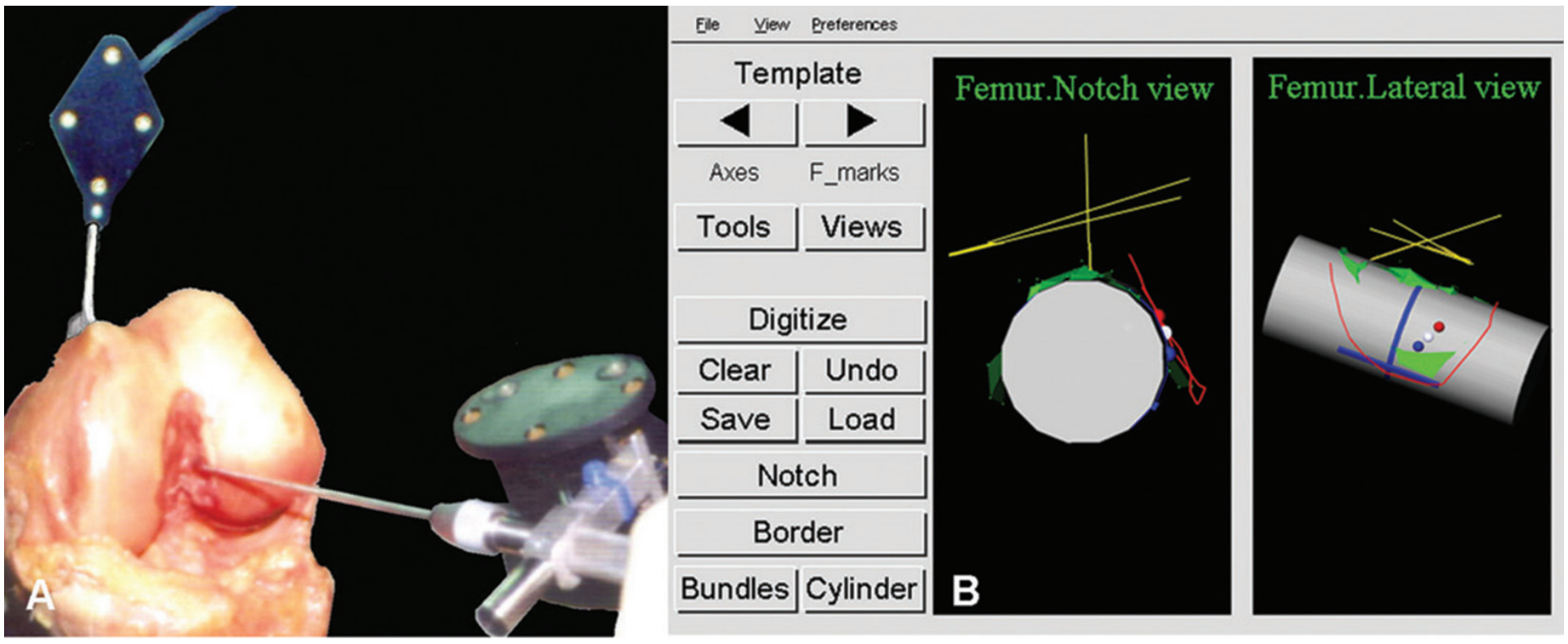

Figure 5. A) Digitizing the cartilage line points at the medial notch wall of the lateral femoral condyle with the tip of the Stille hook. B) The CAS system positions the scaled template with the anatomic red AM, blue PL and white ACL centers. Left: notch view; right: lateral-medial view.

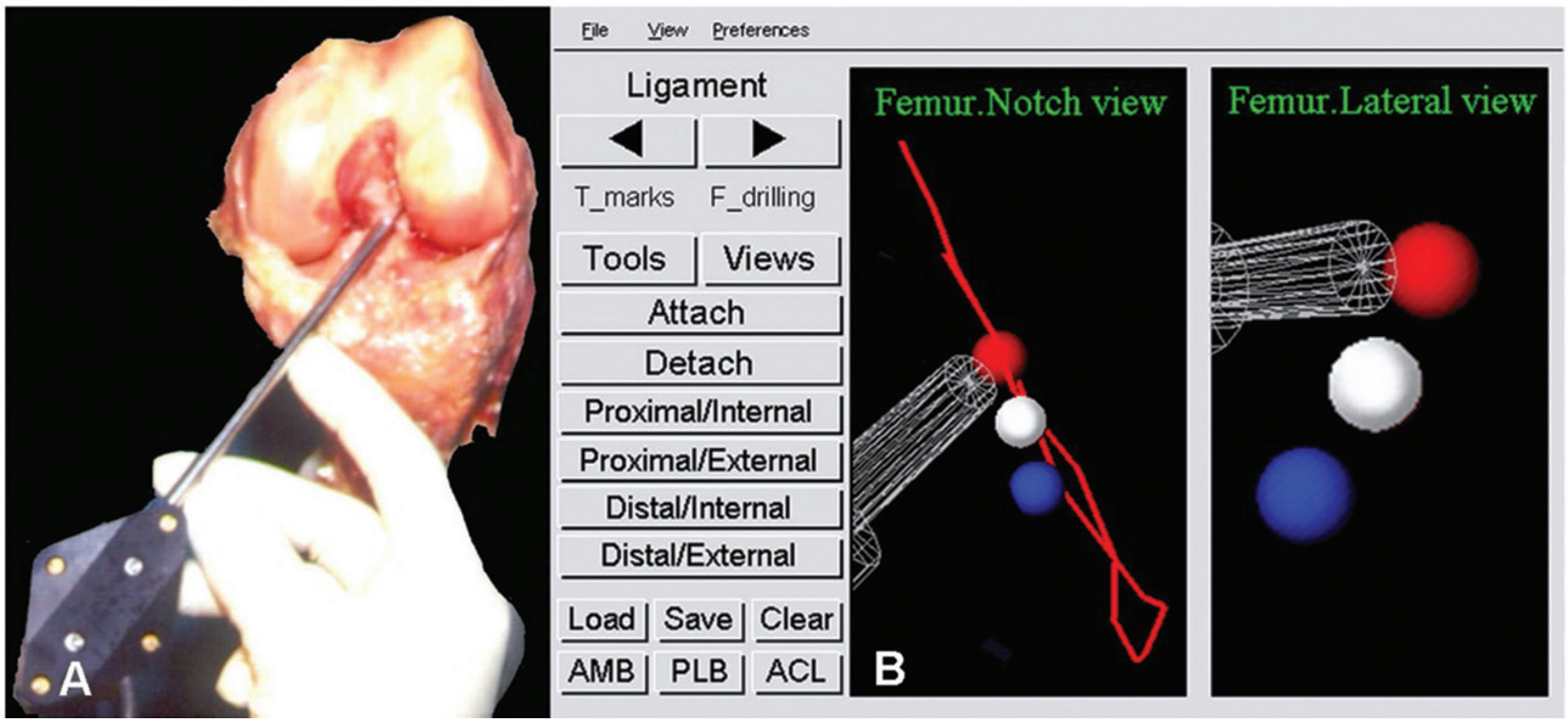

Figure 6. A) Marking of the drill-hole location in the notch with a physical indent of the computer-tracked awl. B) The red anatomic AM center is the target point for the mark by the transparent pedicle awl, as visualized on the CAS system monitor. Left: notch view; right: lateral-medial view.

Accuracy and precision of the femoral template

To address the second research question concerning the accuracy and precision of AM and PL tunnel positioning by the template incorporated in the SurgiGATE CAS system, the procedure was tested by the first author (J.L.) on 31 of the 33 specimens from which it was developed. Two specimens of the original group could not be measured as these bones had been used for other experiments in our laboratory. The accuracy and precision were deter- mined by calculating the differences between the positions of the template centers and those of the real anatomic centers in the 3D coordinate system of the CAS system. The mean difference expressed the accuracy of the method, representing how accurately the surgeon could locate the insertion centers using the method. The standard deviation (SD) is a measure of the precision of the method for this group of specimens.

First, the 3D coordinate system of the CAS system was defined (Figure 7) and the templates with the AM and PL centers were positioned in the individual knees. This was done according to the steps specified by the SurgiGATE system. As a result, the template AM (AMt) and PL (PLt) centers in the individual knees were expressed as positions in the defined CAS system 3D coordinate system. In the second step, the system was used as a 3D digitizer to define the 3D position of the anatomic AM (AMa) and PL (PLa) centers in the same CAS 3D coordinate system, similar to the method employed during the development phase.

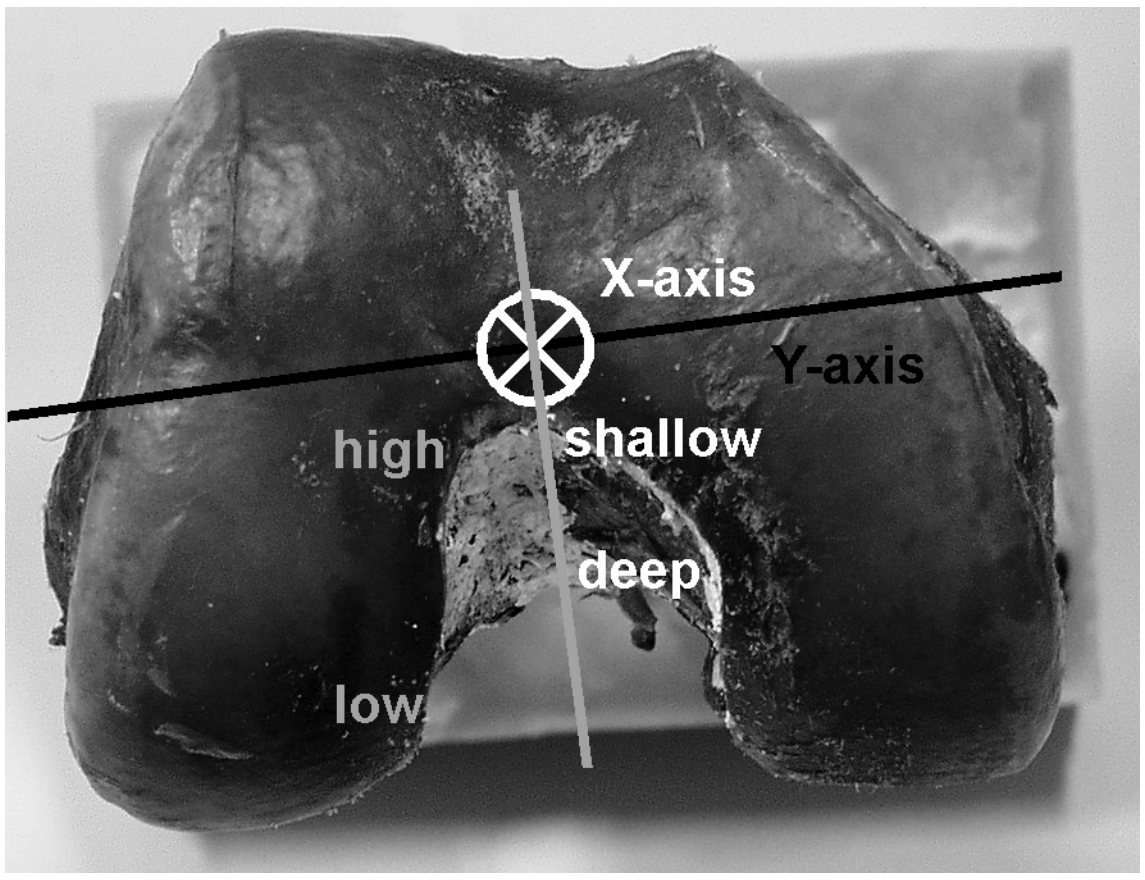

Figure 7. Three-dimensional coordinate system as defined in the SurgiGATE CAS system for the accuracy and precision measurements of the femoral template. The axes of the femur were defined by digitizing points with the Stille hook. The long Z-axis (white) between the distal point in the middle of the condyles and the middle of the shaft 10 cm proximal above the knee, where the femur was cut, is comparable to the shallow-deep direction in the notch. (This is in contrast with the regular situation, where the trochantor major femoralis is digitized.) The medial-lateral Y-axis (gray line) between the two femoral epicondyles, perpendicular to the notch wall, will not be taken into account, since the tunnel is placed at the bony surface. The X-axis (black line) follows from the other two axes and runs from ventral to dorsal, comparable to the high-low direction in the notch.

Finally, the differences between anatomic and template centers were defined by calculating the mean and SD of the distances between both centers in the 31 specimens in all three planes of the 3D CAS coordinate system: deep-shallow along the roofline (Z-axis); high-low from the roof (X-axis); and perpendicular to the surface (Y-axis). However, since the tunnel is placed at the bony surface, the distance perpendicular to the surface (Y) is not important and was not evaluated further. The 95% CI was also calculated. To determine the accuracy and precision in a single value, the total distance in the 2D plane of the medial wall of the lateral condyle (deep-shallow Z against high-low X) was calculated as a vector by means of Pythagoras' theorem.

Results

Femoral template

In all 33 femora, a cylinder could be fitted to the notch surface. The mean radius of all cylinders was 10.5 mm (±1.0 mm). The second-degree polynominal curves, which were fitted to the cartilage edge data to create the cylindrical origin, showed a mean explained variance (R2) of 92% (±7%).

The mean distance in the longitudinal direction on the cylinder surface from the most dorsal point of the posterior joint cartilage edge to the center of the total ACL insertion (Z) was 5.9 mm (SD = 1.7). The mean φ-angle in the transverse plane was 0.9 rad (SD = 0.1). The center of the AM was further from the top at 6.9 mm (SD = 1.9) and 1.1 rad (SD = 0.2), while the PL center was closer to the top at 4.5 mm (SD = 2.1) and 0.6 rad (SD = 0.2) (Table I and Figure 8). The area in which 95% of the centers were positioned ranged in the deep-shallow direction from 6.6 mm (ACL) to 7.6 mm (AM) and 8.4 mm (PL). In the high-low direction, 95% of the centers were positioned within 6.0 mm (ACL), 7.0 mm (PL) and 8.0 mm (AM). The variation in the positions of the anatomical centers, as defined by the SD of the direct distance D between the centers and the most dorsal point of the cartilage border (the 2D vector), was 1.7 mm for the ACL, 2.0 mm for the PL, and 2.2 mm for the AM (Table I and Figure 8).

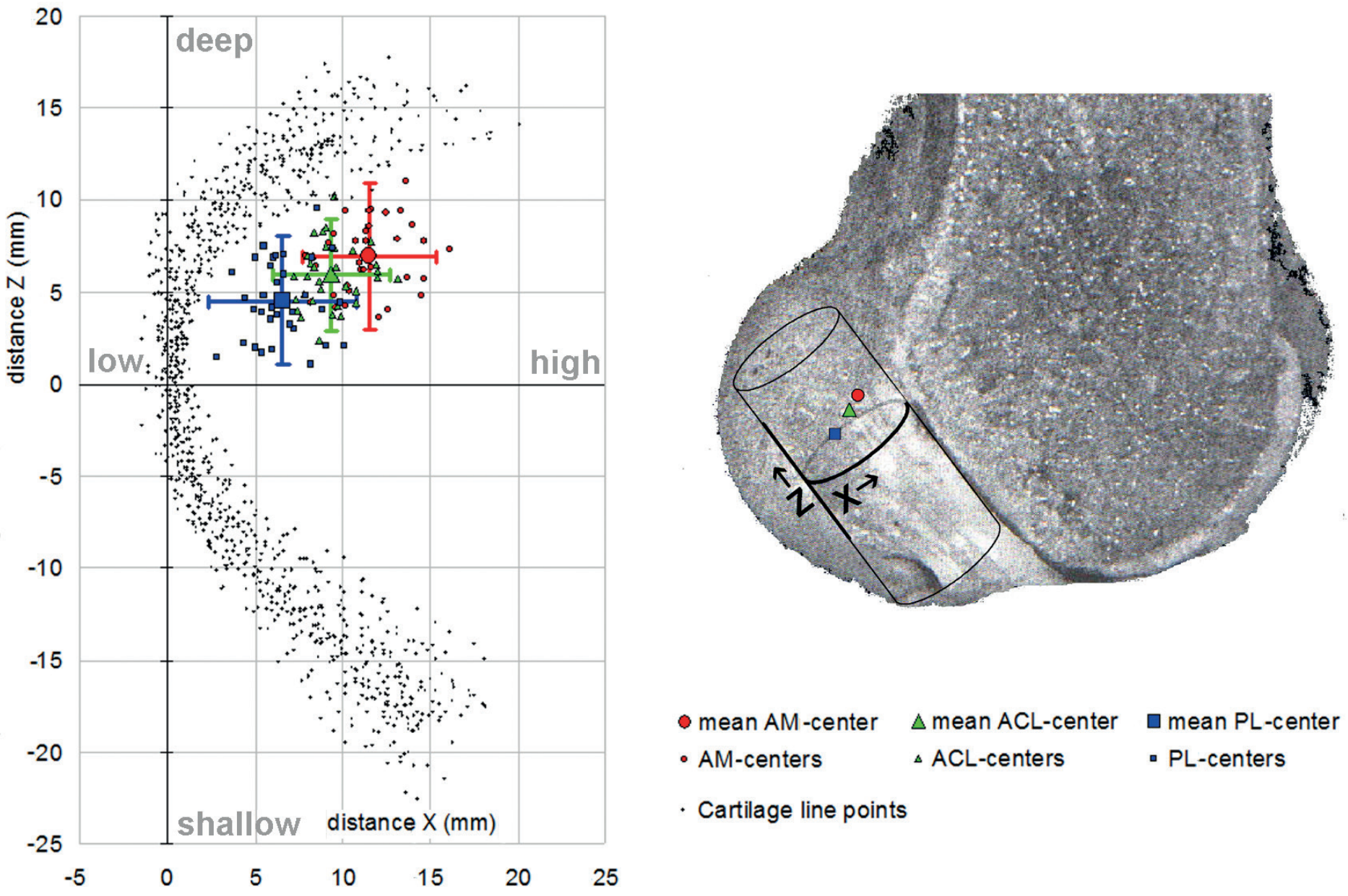

*Figure 8. Left: Diagram of the points on the cylinder surface; Right: Lateral view of a femur (with the lateral condyle dissected) showing the alignment of the 3D cylinder template including the projections on the surface of the origin of the coordinate system (the apex of the cartilage border) and the mean position of the centers of the ACL, AM and PL. Z is the distance in the shallow-deep direction; X is the distance in the low-high direction. The error bars represent 1.96*SD, containing 95% of the individual centers (95% CI).*

Table I. Mean anatomical positions and variations (SD) of the insertion centers in the template, relative to the apex of the cartilage border

n = 33	**Z (mm) deep-shallow**	**φ (rad)**	**XD (mm) high-low**	**2D vector D (mm)**
ACL	5.9 ± 1.7	0.9 ± 0.1	9.4 ± 1.5	11.2 ± 1.7
AM	6.9 ± 1.9	1.1 ± 0.2	11.6 ± 2.0	13.6 ± 2.2
PL	4.5 ± 2.1	0.6 ± 0.2	6.5 ± 1.8	8.2 ± 2.0

Accuracy and precision of the femoral template

The accuracy of the system, i.e., the mean distance between the AM and PL centers suggested by the template and the real anatomic centers, was close to 0 mm in all directions (Table II and Figure 9). The area in which 95% of the template centers were positioned was within 7.2 mm in the deep-shallow direction and 7.9 mm in the high-low direction for the AM, and within 7.2 mm and 6.0 mm in those respective directions for the PL, resulting in a precision (SD) in positioning of the AMt and PLt centers compared to the AMa and PLa centers in the deep-shallow direction (Z-axis) of 1.8 mm for both centers. In the high-low direction (X-axis) the precision of the PL was somewhat better than the AM (1.5 mm versus 2.0 mm).

The accuracy in the 2D plane of the condyle wall, representing the absolute deviation of the template centers from the anatomic centers, was 2.5 mm for the AM and 2.2 mm for the PL, with the precision being 1.2 mm for both centers (Table II).

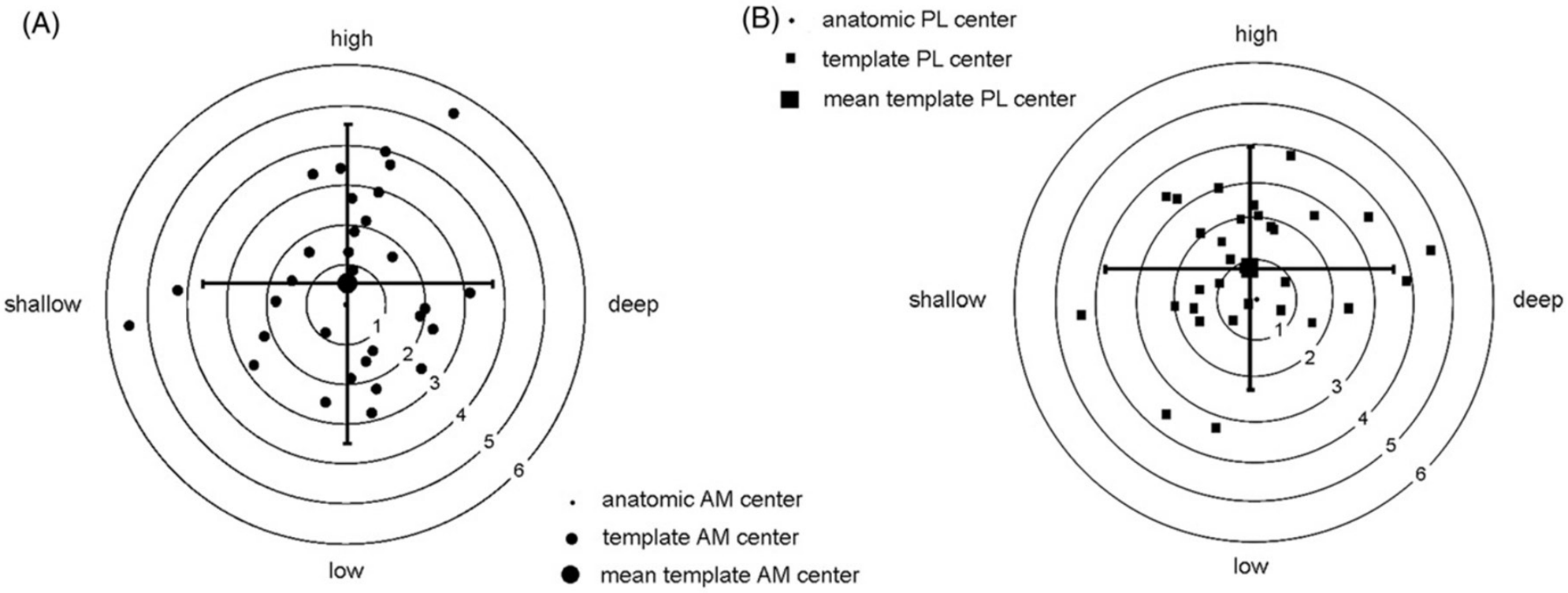

*Figure 9. The positions of the template centers relative to the anatomic centers (bull's eye) for AM (A) and PL (B). The circles indicate the distance in mm. The total error is composed of the accuracy, represented by the distances in the high-low and shallow-deep directions between the bull's eye and the mean template centers, and the precision, represented by 1.96*SD (black lines).*

Table II. Accuracy and precision of the tunnels placed by the template using the CAS system, relative to the anatomical centers

	Accuracy (mean in mm)			Precision (SD in mm)		
n = 31	**Deep-shallow**	**High-low**	**2D vector**	**Deep-shallow**	**High-low**	**2D vector**
AM	0.1	0.6	2.5	1.8	2.0	1.2
PL	0.2	0.7	2.2	1.8	1.5	1.2

Discussion

Accurate tunnel placement is one of the main difficulties in ACL reconstruction. Various methods, from conventional guiding instruments to computer navigation and robotic systems, have been developed to help the surgeon position tunnel entrances at the desired location, mostly based on isometry or prevention of notch impingement [38]. The use of computer-assisted systems for femoral tunnel positioning during ACL reconstructions has been shown to improve accuracy [44–47]. In anatomical double-bundle ACL reconstruction, the two grafts are supposed to be attached at the original anatomic sites. To the authors' knowledge, no navigation system exists for determining the femoral tunnel at the anatomical positions for AM and PL grafts based on in situ digitization of landmarks. This study showed the possibility of developing a computer-assisted interactive technique, using a computer model which positions the marks for the femoral tunnel(s) in the individual knee at the anatomical centers. This computer model is an average cylindrical template, developed by statistical shape analysis of 33 femoral notches containing the positions of the centers of the ACL, AM and PL. The anatomical variation of the insertion centers in the cylinder, with SDs ranging between 1.5 and 2.1 mm, was consistent with 95% of the centers lying within 4.3 mm of the mean position (1.96*SD 2D vector, Table I).

The accuracy of the developed method (2.2 and 2.5 mm for the AM and PL tunnels, respectively) was very similar to the anatomical variation of the real AM and PL centers defined in the template, i.e., 2.2 and 2.0 mm, respectively. The precision in this set of specimens was 1.2 mm for both tunnels. These values are smaller than the usual bone tunnel diameters, of approximately 8–10 mm. These results were comparable with those from several other studies which have quantified the accuracy or precision of ACL navigation systems [40, 43–45]. However, the measurements in three of those studies only compared the position of the preoperatively planned tunnels with the postoperative results, not with the actual position of the anatomical insertion centers; two of the studies [43, 44] used sawbones, and one [45] used cadaveric knees. Musahl et al. [42] defined the accuracy and precision of preoperative tunnel planning with an active robotic system in relation to a tunnel placed in the actual femoral ACL insertion, the values being 1.3 mm (mean) and 1.0 (SD), respectively. The reported precision is similar to our own result, while the accuracy seems superior. However, the system also showed a deviation of 1.3 mm between preoperatively planned tunnels and postoperative results [45].

Disadvantages of the system, as presented in this study, relative to the traditional arthroscopic single-bundle reconstruction technique are, obviously, the costs of the navigation system, the slightly longer operative time (on the order of 10 minutes), and the use of the DRB, which causes an extra wound and subsequent discomfort for the patient. A limitation of this software version was the necessity for visual inspection of the cylinder fit, since algorithm convergence did not always yield the correct solution on the first trial. However, template positioning was possible for each knee in the study, the notch surface being refined with additional points. This limitation could be solved by an algorithm that allows for continuous monitoring of the sufficiency of the input data. Furthermore, the method cannot be used in ACL-deficient knees with notch deformation due to chronic instability.

In addition to the 3D approach, the benefits of the presented system are the use of the CAS system in defining the location of the femoral drill hole, based on the average knee anatomy. Even with several starting conditions, the total calculation time of the optimization algorithm for the cylinder was approximately 10–15 seconds on a standard personal computer. In contrast to other CAS systems, which use radiographic overlays [34], computer graphic overlays added to the fluoroscopic view [44] or CT scans [45, 46], the method proposed in this study requires no extra images and no fluoroscopy. It is a simple CAS arthroscopic method, which enables the surgeon to place the graft at the anatomic AM, PL or ACL center. The SurgiGATE CAS system can also help in using an outside-in drill technique, avoiding notch impingement through virtual planning of the ligaments, and predicting the graft elongation pattern as a function of the knee flexion angle. Pitfalls in tunnel drilling such as dorsal notch outbreak of the drill hole and cartilage damage may be prevented using this method.

Conclusions

The method developed in this study combines anatomic placement with the accuracy of a CAS system. Intraoperative digitization of intra-articular landmarks, which are visible and easily found during endoscopic navigation without the use of other imaging techniques, makes the system easy to use and independent of the preoperative planning methods. With a precision of 2.4 mm, the system has a small variability in anatomical tunnel placement relative to a 10-mm bone tunnel diameter. Further studies are required to validate the system on other specimens and to determine the degree of precision required in anatomic ACL double-bundle reconstruction to affect clinical performance.

Acknowledgments The authors would like to thank Marwan Sati, Ivan Bourquin, Willem van de Wijdeven, Rene van der Venne and Huub Peeters for their contributions to this work.

Declaration of interest This study was funded by grant 99-W14 from the AO Research Fund, Association for Osteosynthesis Foundation, Switzerland.

References

1. Mae T, Shino K, Matsumoto N, Hamada M, Yoneda M, Nakata K. Anatomical two-bundle versus Rosenberg's isometric bi-socket ACL reconstruction: A biomechanical comparison in laxity match pretension. Knee Surg Sports Traumatol Arthrosc 2007;15(4):328–334.
2. Woo SL, Kanamori A, Zeminski J, Yagi M, Papageorgiou C, Fu FH. The effectiveness of reconstruction of the anterior cruciate ligament with hamstrings and patellar tendon. A cadaveric study comparing anterior tibial and rotational loads. J Bone Joint Surg Am 2002;84(6):907–914.
3. Yagi M, Wong EK, Kanamori A, Debski RE, Fu FH, Woo SL. Biomechanical analysis of an anatomic anterior cruciate ligament reconstruction. Am J Sports Med 2002;30(5):660–666.
4. Musahl V, Plakseychuk A, VanScyoc A, Sasaki T, Debski RE, McMahon PJ, Fu FH. Varying femoral tunnels between the anatomical footprint and isometric positions: Effect on kinematics of the anterior cruciate ligament-reconstructed knee. Am J Sports Med 2005;33(5):712–718.
5. Yamamoto Y, Hsu WH, Woo SL, Van Scyoc AH, Takakura Y, Debski RE. Knee stability and graft function after anterior cruciate ligament reconstruction: A comparison of a lateral and an anatomical femoral tunnel placement. Am J Sports Med 2004;32(8):1825–1832.
6. Radford WJ, Amis AA. Biomechanics of a double prosthetic ligament in the anterior cruciate deficient knee. J Bone Joint Surg Br 1990;72(6):1038–1043.
7. Yagi M, Wong EK, Kanamori A, Debski RE, Fu FH, Woo SL. Biomechanical analysis of an anatomic anterior cruciate ligament reconstruction. Am J Sports Med 2002;30(5):660–666.
8. Loh JC, Fukuda Y, Tsuda E, Steadman RJ, Fu FH, Woo SL. Knee stability and graft function following anterior cruciate ligament reconstruction: Comparison between 11 o'clock and 10 o'clock femoral tunnel placement. Arthroscopy 2003;19(3):297–304.
9. Ishibashi Y, Tsuda E, Tazawa K, Sato H, Toh S. Intraoperative evaluation of the anatomical double-bundle anterior cruciate ligament reconstruction with the OrthoPilot navigation system. Orthopedics 2005;28(10 Suppl): s1277–s1282.
10. Yasuda K, Kondo E, Ichiyama H, Tanabe Y, Tohyama H. Clinical evaluation of anatomic double-bundle anterior cruciate ligament reconstruction procedure using hamstring tendon grafts: Comparisons among 3 different procedures. Arthroscopy 2006;22(3):240–251.
11. Järvelä T. Double-bundle versus single-bundle anterior cruciate ligament reconstruction: A prospective, randomize clinical study. Knee Surg Sports Traumatol Arthrosc 2007;15(5):500–507.
12. Yagi M, Kuroda R, Nagamune K, Yoshiya S, Kurosaka M. Double-bundle ACL reconstruction can improve rotational stability. Clin Orthop Relat Res 2007;454: 100–107.
13. Harner CD, Poehling GG. Double bundle or double trouble. Arthroscopy 2004;20(10):1013–1014.
14. Kohn D, Busche T, Carls J. Drill hole position in endoscopic anterior cruciate ligament reconstruction. Results of an advanced arthroscopy course. Knee Surg Sports Traumatol Arthrosc 1998;6(Suppl 1):S13–S15.
15. Topliss C, Webb J. An audit of tunnel position in anterior cruciate ligament reconstruction. Knee 2001;8(1):59–63.
16. Behrend H, Stutz G, Kessler MA, Rukavina A, Giesinger K, Kuster MS. Tunnel placement in anterior cruciate ligament (ACL) reconstruction: Quality control in a teaching hospital. Knee Surg Sports Traumatol Arthrosc 2006;14(11):1159–1165.
17. Sommer C, Friederich NF, Müller W. Improperly placed anterior cruciate ligament grafts: Correlation between radiological parameters and clinical results. Knee Surg Sports Traumatol Arthrosc 2000;8(4):207–213.
18. Moisala AS, Järvelä T, Harilainen A, Sandelin J, Kannus P, Järvinen M. The effect of graft placement on the clinical outcome of the anterior cruciate ligament reconstruction: A prospective study. Knee Surg Sports Traumatol Arthrosc 2007;15(7):879–887.
19. Markolf KL, Hame S, Hunter DM, Oakes DA, Zoric B, Gause P, Finerman GA. Effects of femoral tunnel placement

on knee laxity and forces in an anterior cruciate ligament graft. J Orthop Res 2002;20(5):1016–1024.
20. Zavras TD, Race A, Amis AA. The effect of femoral attachment location on anterior cruciate ligament reconstruction: Graft tension patterns and restoration of normal anterior-posterior laxity patterns. Knee Surg Sports Traumatol Arthrosc 2005;13(2):92–100.
21. Jonsson H, Kärrholm J, Elmqvist LG. Laxity after cruciate ligament injury in 94 knees. The KT-1000 arthrometer versus roentgen stereophotogrammetry. Acta Orthop Scand 1993;64(5):567–570.
22. Takeuchi R, Saito T, Mituhashi S, Suzuki E, Yamada I, Koshino T. Double-bundle anatomic anterior cruciate ligament reconstruction using bone-hamstring-bone compo- site graft. Arthroscopy 2002;18(5):550–555.
23. Luites JW, Wymenga AB, Blankevoort L, Kooloos JG. Description of the attachment geometry of the anteromedial and posterolateral bundles of the ACL from arthroscopic perspective for anatomical tunnel placement. Knee Surg Sports Traumatol Arthrosc 2007;15(12):1422–1431.
24. Colombet P, Robinson J, Christel P, Franceschi JP, Djian P, Bellier G, Sbihi A. Morphology of anterior cruciate ligament attachments for anatomic reconstruction: A cadaveric dissection and radiographic study. Arthroscopy 2006;22(9):984–992.
25. Mochizuki T, Muneta T, Nagase T, Shirasawa S, Akita KI, Sekiya I. Cadaveric knee observation study for describing anatomic femoral tunnel placement for two-bundle anterior cruciate ligament reconstruction. Arthroscopy 2006;22(4):356–361.
26. Takahashi M, Doi M, Abe M, Suzuki D, Nagano A. Anatomical study of the femoral and tibial insertions of the anteromedial and posterolateral bundles of human anterior cruciate ligament. Am J Sports Med 2006;34(5):787–792.
27. Edwards A, Bull AM, Amis AA. The attachments of the anteromedial and posterolateral fibre bundles of the anterior cruciate ligament. Part 2: Femoral attachment. Knee Surg Sports Traumatol Arthrosc 2007;16(1):29–36.
28. Ferretti M, Ekdahl M, Shen W, Fu FH. Osseous landmarks of the femoral attachment of the anterior cruciate ligament: An anatomic study. Arthroscopy 2007;23(11):1218–1225.
29. Iriuchishima T, Ingham SJ, Tajima G, Horaguchi T, Saito A, Tokuhashi Y, van Houten AH, Aerts MM, Fu FH. Evaluation of the tunnel placement in the anatomical double-bundle ACL reconstruction: A cadaver study. Knee Surg Sports Traumatol Arthrosc 2010;18(9):1226–1231.
30. Bernard M, Hertel P, Hornung H, Cierpinski T. Femoral insertion of the ACL. Radiographic quadrant method. Am J Knee Surg 1997;10(1):14–21.
31. Milankov M, Miljkovic N. A new positioning device for precise femoral insertion of the anterior cruciate ligament autograft. Knee Surg Sports Traumatol Arthrosc 2000;8(3):149–153.
32. Hantes ME, Dailiana Z, Zachos VC, Varitimidis SE. Anterior cruciate ligament reconstruction using the Bio- TransFix femoral fixation device and anteromedial portal technique. Knee Surg Sports Traumatol Arthrosc 2006;14(5):497–501.
33. Hiraoka H, Kuribayashi S, Fukuda A, Fukui N, Nakamura K. Endoscopic anterior cruciate ligament reconstruction using a computer-assisted fluoroscopic navigation system. J Orthop Sci 2006;11(2):159–166.
34. Klos TV, Banks SA, Habets RJ, Cook FF. Sagittal plane imaging parameters for computer-assisted fluoroscopic anterior cruciate ligament reconstruction. Comput Aided Surg 2000;5(1):28–34.
35. Pace A, Fergusson C. Preoperative computerized radiograph measurement of Blumensaat's line as an aid to correct placement of the femoral tunnel in ACL reconstruction. J Knee Surg 2006;19(3):176–180.
36. Dessenne V, Lavallée S, Julliard R, Orti R, Martelli S, Cinquin P. Computer-assisted knee anterior cruciate ligament reconstruction: First clinical tests. J Image Guid Surg 1995;1(1):59–64.
37. Sati M, Stäubli H, Bourquin Y, Kunz M, Käsermann S, Nolte LP. Clinical integration of computer-assisted technology for arthroscopic anterior cruciate ligament reconstruction. Operat Tech Orthoped 2000;10(1):40–49.
38. Sati M, Stäubli H, Bourquin Y, Kunz M, Nolte LP. Real-time computerized in situ guidance system for ACL graft placement. Comput Aided Surg 2002;7(1):25–40.

39. Müller-Alsbach UW, Staubli AE. Computer aided ACL reconstruction. Injury 2004;35(Suppl 1):S-7.
40. Plaweski S, Cazal J, Rosell P, Merloz P. Anterior cruciate ligament reconstruction using navigation: A comparative study on 60 patients. Am J Sports Med 2006;34(4):542–552.
41. Ishibashi Y, Tsuda E, Fukuda A, Tsukada H, Toh S. Future of double-bundle anterior cruciate ligament (ACL) reconstruction: incorporation of ACL anatomic data into the navigation system. Orthopedics 2006;29(10 Suppl): S108–S112.
42. Musahl V, Burkart A, Debski RE, van Scyoc A, Fu FH, Woo SL. Anterior cruciate ligament tunnel placement: Comparison of insertion site anatomy with the guidelines of a computer-assisted surgical system. Arthroscopy 2003;19(2):154–160.
43. Petermann J, Kober R, Heinze R, Frölich JJ, Heeckt P, Gotzen L. Computer-assisted planning and robot-assisted surgery in anterior cruciate ligament reconstruction. Operat Tech Orthoped 2000;10(1):50–55.
44. Klos TV, Habets RJ, Banks AZ, Banks SA, Devilee RJ, Cook FF. Computer assistance in arthroscopic anterior cruciate ligament reconstruction. Clin Orthop Relat Res 1998(354):65–69.
45. Picard F, DiGioia AM, Moody J, Martinek V, Fu FH, Rytel M, Nikou C, LaBarca RS, Jaramaz B. Accuracy in tunnel placement for ACL reconstruction. Comparison of traditional arthroscopic and computer-assisted navigation techniques. Comput Aided Surg 2001;6(5):279–289.
46. Burkart A, Debski RE, McMahon PJ, Rudy T, Fu FH, Musahl V, van Scyoc A, Woo SLY. Precision of ACL tunnel placement using traditional and robotic techniques. Comput Aided Surg 2001;6(5):270–278.
47. Musahl V, Burkart A, Debski RE, van Scyoc A, Fu FH, Woo SL. Accuracy of anterior cruciate ligament tunnel placement with an active robotic system: A cadaveric study. Arthroscopy 2002;18(9):968–973.
48. Sidles JA, Larson RV, Garbini JL, Downey DJ, Matsen FA III. Ligament length relationships in the moving knee. J Orthop Res 1988;6(4):593–610.

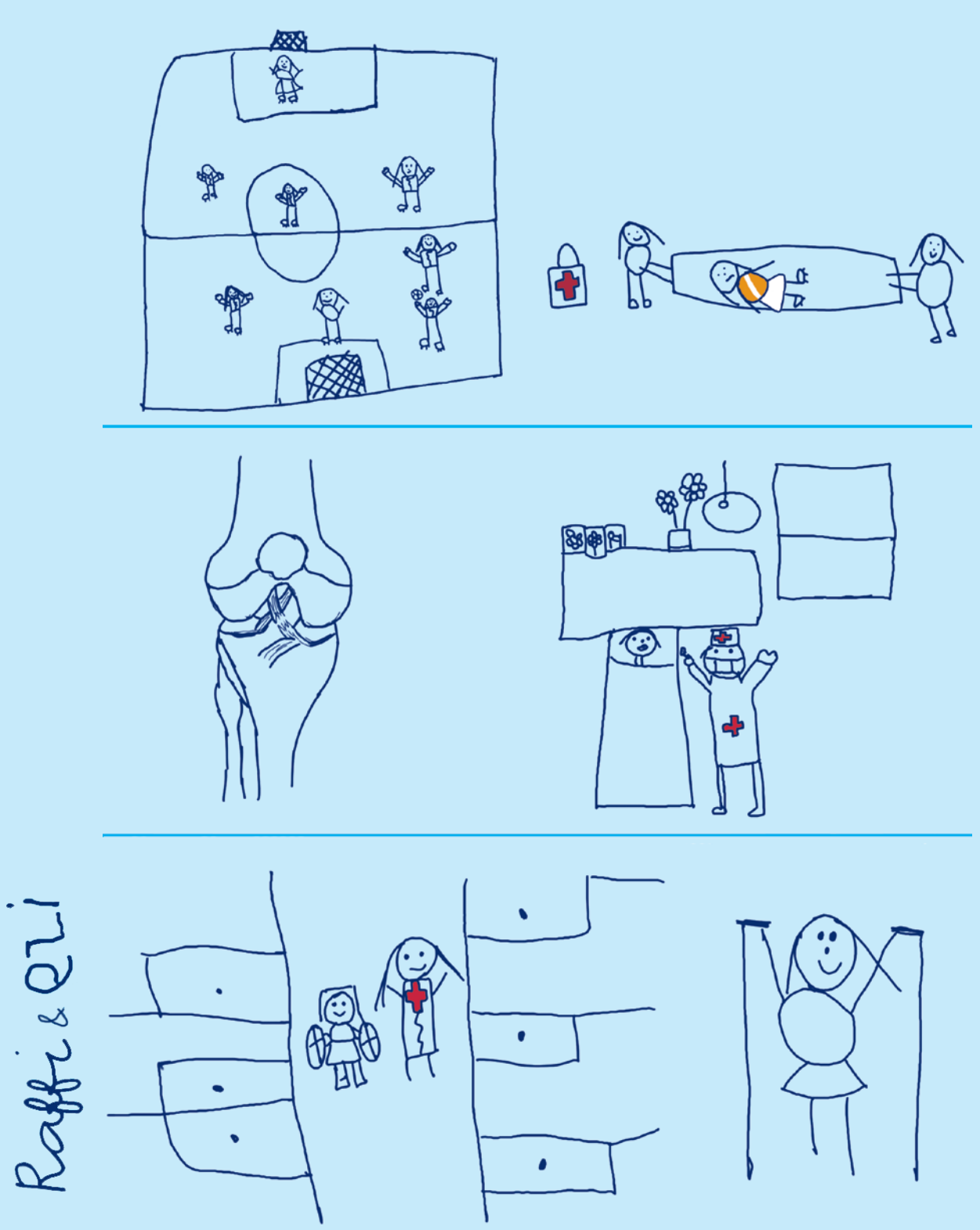
Raffi & Elli

CHAPTER 6

Accuracy of a computer-assisted planning and placement system for anatomical femoral tunnel positioning in anterior cruciate ligament reconstruction

Joan W.H. Luites, Ate B. Wymenga, Leendert Blankevoort,
Denise Eygendaal and Nico Verdonschot

The International Journal of Medical Robotics and Computer Assisted Surgery 2014 Dec;10(4):438-446

Abstract

Background

Femoral tunnel positioning is a difficult, but important factor in successful anterior cruciate ligament (ACL) reconstruction. Computer navigation can improve the anatomical planning procedure besides the tunnel placement procedure.

Methods

The accuracy of the computer-assisted femoral tunnel positioning method for anatomical double bundle ACL reconstruction with a three dimensional template was determined with respect to both aspects for AM and PL bundles in 12 cadaveric knees.

Results

The accuracy of the total tunnel positioning procedure was 2.7 mm (AM) and 3.2 mm (PL). These values consisted of the accuracies for planning (AM:2.9 mm; PL:3.2 mm) and for placement (about 0.4 mm). The template showed a systematic bias for the PL-position.

Conclusions

The computer-assisted templating method showed high accuracy for tunnel placement and has promising capacity for application in anatomical tunnel planning. Improvement of the template will result in an accurate and robust navigation system for femoral tunnel positioning in ACL reconstruction.

Introduction

Clinical successful reconstruction of the anterior cruciate ligament (ACL) depends on several different factors. Tunnel positioning is one of the most important factors, with femoral graft placement influencing graft laxity patterns [1,2] and clinical outcome most [3,4]. Recent research advocates anatomical placement, restoring normal knee function better than isometric placement [2,5]. However, correct tunnel placement is difficult [6,7]. In anatomical double-bundle reconstruction, placement of the anteromedial bundle and posterolateral bundle has become even more critical to benefit optimally from the biomechanical advantages of the technique [8]. Computer navigation can improve the accuracy and the precision of tunnel placement [9–17]. The positive effect of computer-assisted tunnel placement in ACL reconstruction depends first on the accuracy of planning the target at the correct anatomical positions. Since femoral tunnel placement is more difficult [18] and more important [7] than tibial placement, this study focuses on femoral placement.

There are several methods used in computer assisted surgery to determine the planned tunnel position. Initially these systems based optimal placement on graft isometry and avoidance of notch impingement using intraoperative real-time digitizing [19,20]. With the emerging need for anatomical placement, systems were equipped with templates to assist determining the anatomical positions. These templates existed as two-dimensional (2D) overlays on fluoroscopic images [15,17,21], or utilized pre- and/or intra-operative application of Bernard's Quadrant method [22; 16, 23] either using CT scans [12]. Some methods use active robotic systems [12], while other systems have intra-operative real-time control possibilities [17]. A valuable addition to these systems could be the introduction of refined three-dimensional (3D) image-based templates [24]. However, these systems do not use the potential of real-time digitizing during computer navigation, with which individual alignment of the template and the patient´s anatomy can be achieved.

In a previous study [25], an individualized anatomical-tunnel-placement planning method was developed using intra-operative in situ digitization of landmarks in the patient´s knee. For this purpose, the femoral anatomical insertion centers of the anteromedial (AM) and posterolateral (PL) bundles in the notch of 33 knees were quantified. The insertion geometry was transformed into a standardized computer template containing the mean AM, PL and ACL centers. Using a morphing technique, this standardized template can be 'projected' onto the anatomy of an individual knee during the reconstruction procedure. This is done by digitizing landmarks intra-operatively, thus providing guidelines for planning the anatomical tunnel positions. Subsequently, computer navigation is used for tunnel placement by marking the tunnel positions for the drilling procedure. In this system, computer navigation is used not only for accurate tunnel placement, but also for determining the individual anatomical tunnel positions using the guidelines for planning incorporated in the morphable template. In the previous study, the template determined the AM and PL positions in 31 of the 33 knees with an accuracy within 2.5 mm.

However, it is uncertain how well surgeons would be able to reproduce the anatomical positions using the templated tunnel positioning procedure in other knees. Therefore the purpose of this study was to calculate the accuracy of the planning procedure (how accurate is the template) ánd the placement procedure (how accurate can a planned tunnel be placed) during application of the computer-assisted morphable templating technique by surgeons in a tunnel positioning procedure in 12 cadaveric knees. The true anatomical positions of the femoral AM and PL centers served as the gold standard.

Materials and methods

First, measurements on 12 knee specimens were performed to determine the actual 3D positions of the AM and PL anatomical insertions centers. Second, the tunnel positioning procedure was performed by the surgeons to determine the AM and PL tunnel positions using the morphable templating technique in a computer-assisted surgical system. Finally, the collected data were analyzed to determine the agreement of the tunnel positions with the true anatomical AM and PL positions.

Twelve knee specimens were prepared for the measurements and dissected while keeping the ligaments intact. The ACL was separated in an AM and PL bundle during passive knee movement. The fibers of the ligament tensed in flexion combined with anterior translation (AM) were discerned from those fibers tensed in and near extension (PL) [26]. The collateral ligaments, PCL and menisci were removed and followed by resection of the bundles of the ACL. The outlines of the AM and PL insertion sites were marked with an indelible highlighter, so that the sites could be easily identified later.

The SurgiGATE CAS system (Medivision, Oberdorf, Switzerland) was used for two purposes in this study. In the first part of the study, it served as a 3D digital measurement device for the anatomical measurements, since the system allows real-time tracking of bones and interactive digitization and labeling of anatomical structures identified under direct visual or endoscopic control [19]. It consists of an opto-electronic navigation system (Optotrak 3020, Northern Digital, Canada), a computer and computer-tracked devices. The Optotrak system tracks the 3D position of active infrared markers (LED) with an accuracy of 0.1–0.3 mm [19], resulting in similar accurate determination of landmarks, digitized by the system. The LEDs are located in the Dynamic Reference Bases (DRBs), which are fixed to the patients' bones to allow real-time tracking. LEDs are also attached to specially designed surgical instruments, like a palpation device (Stille hook) to digitize structures and a marking device (awl) to mark points. During the second part of the study, the system was used to perform the tunnel positioning procedure. This was done using the adapted ACL software-module with the specially developed morphable template [25].

Two orthopaedic surgeons, both experienced in ACL surgery, performed all measurements of both procedures (anatomical measurements and tunnel positioning). One surgeon had already used the CAS system with the template in an in vitro study. The other had no previous experience with computer-assisted surgery.

Data acquisition

Femoral coordinate system for CAS

To perform the anatomical measurements and the tunnel positioning procedure with CAS, a DRB with LEDs was fixed to the femur thereby enabling tracking of the boney structures. The software in which the template was implemented [19], imposed to define a 3D coordinate system of the femur first. Therefore, four points on the femur were digitized using the palpation device to identify the two axes: the medial-lateral axis between the medial and lateral femoral epicondyle and the long axis between the center of the notch at the distal end and the midpoint of the shaft at the proximal end of the specimen. The third axis was determined as the cross-product of the two defined axes, completing the coordinate system. The orientation of the coordinate system and the position of the origin is sensitive to inaccuracies during digitization of the landmarks. This means that the CAS coordinate systems are not completely equal for all measurement sessions on all knees. Besides that, this femoral coordinate system is less suitable to provide insight in the orientation of the inaccuracies of the method within the notch from a surgical view. Therefore, another coordinate system will be defined later to perform the accuracy calculations.

Anatomical measurements to be used as the gold standard

To determine the AM and PL anatomical insertions centers in the individual knee, a number of points distributed on the marked outlines of both insertions were digitized with the palpation device of the CAS system. This was done under visual control, viewing directly at the insertion site to measure accurately. This measurement was also repeated for the ACL insertion as a whole. The 3D coordinates of these three clouds of digitized points in the previous defined CAS coordinate system were stored and used to calculate the centers of the insertions after transformation to another coordinate system, later in the analysis. Although this method to define the AM and PL centers serve as the gold standard to which the navigated measurements can be compared, it had obviously a measurement error. This error was calculated by determining the differences of the calculated insertion centers between the two measurements of the two surgeons. The measurement error included the accuracy of the digitization method of the CAS system, the accuracy of the surgeon digitizing the outline points and the calculation method of the center. The anatomical centers could be determined with an accuracy of 1.0–1.5 mm.

Tunnel positions

During the second part of the study, the surgeons did not look directly at the femoral notch. An arthroscopic system was used, providing the surgeons a surgical view in the notch, looking at the monitor. To determine the AM and PL planned tunnel positions with the templated CAS system, the steps in the implemented ACL-module were followed [25]. The total tunnel positioning procedure consists of two separate steps: (1) planning the anatomical locations using the template procedure and (2) virtually placing the tunnels by digitally marking the centre of the tunnel using CAS.

1. For template alignment during the planning procedure, the notch was interactively digitized as a cloud of points by running the palpation device over the notch surface (avoiding the PCL insertion area) while viewing at the arthroscopic monitor. Subsequently, the cartilage border was digitized by various points distributed over the osteocartilage transition line. After digitizing these two structures, the special template module calculated the template position, consisting of a cylinder with the AM and PL center locations. The algorithm used the notch surface points to fit the cylinder, resulting in its position, orientation and size. The cartilage border information was used to determine the rotation of the cylinder about its long axis. The position of the cylinder in the notch was visualized on the CAS monitor with the AM and PL locations, displayed as small 3D spheres. The surgeon visually checked

roughly the size and position of the cylinder relative to the notch on the monitor, to verify adequate cylinder fit and sizing. Subsequently, the 3D coordinates of the final AM and PL template locations (TL), the planned tunnel positions, in the previous defined coordinate system were stored.

2. To determine the final AM and PL placed tunnel positions in the notchwall, the surgeon used the computer-tracked awl during the placement procedure. The point of the awl was visual at the CAS monitor, as well as the 3D spheres that represented the AM and PL template locations. Viewing at the CAS monitor the AM and PL tunnel positions were located by the awl, targeting either 3D sphere; simultaneously the awl touched the condylar bone in the knee; at the moment the surgeon became satisfied that the awl was pointing at the target he defined the placed tunnel positions, storing the 3D coordinates of the tunnel marks (TM) using the 'storage' button.

Both surgeons performed the measurements twice on all 12 specimens, on two different days, surgeon 1 on day 1 and day 7, surgeon 2 on day 1 and day 30, resulting in four data sets. The different time intervals are not considered to influence the outcome. Since the computer program determines the positioning of the cylinder based on randomly collected points, the surgeon cannot influence the gathering of information during the first measurement and applying it during the second measurement. Therefore, a potential bias is not present. Before the measurements, both surgeons practiced with the system to become familiar with the equipment and proceedings.

Calculations

In the first instance, all data were collected relative to the individually defined CAS coordinate systems, which were not suitable for the accuracy calculations. As this coordinate system is not suitable for accuracy calculations, a new reproducible and uniform coordinate system was defined. This coordinate system was defined at the medial wall of the femoral condyle, oriented as described during the second ESSKA scientific workshop in 1996 [27] (Figure 1). Since all tunnels will be in the bone of the notch wall, the positions of the anatomical centers, the template locations, as well as the positions of the tunnel marks were projected onto a 2D plane at the surface of the notch wall, making it possible to between the anatomical centers (gold standard) and the tunnel marks were calculated in HL (Y) and in DS (X) directions for each of the four measurements and expressed in two values. The accuracy (the agreement between the positions) was calculated using the mean of all the individual absolute differences describe distances between centers and tunnels in the surgical navigation directions for the intercondylar notch: high–low and deep–shallow [27].

For this, in all specimens, a coordinate system with the same origin in the same plane was determined with a program designed in Matlab® (version 7 The MathWorks, Inc.). The stored 3D coordinates of the digitized points at the outlines of the ACL, AM and PL insertions, as well as the points on the cartilage border were used to define the XY plane at the notch wall (Figure 2). This was done through an algorithm, fitting a plane through all insertion outline points and cartilage border points with a least squares approach. The X-axis was set parallel to the line between the first, high deep point of the cartilage line, and the last, high shallow point. The direction of this axis is between deep and shallow (DS). The Y-axis was defined perpendicular to the X-axis, in the high–low direction (HL) at the plane of the condyle wall.

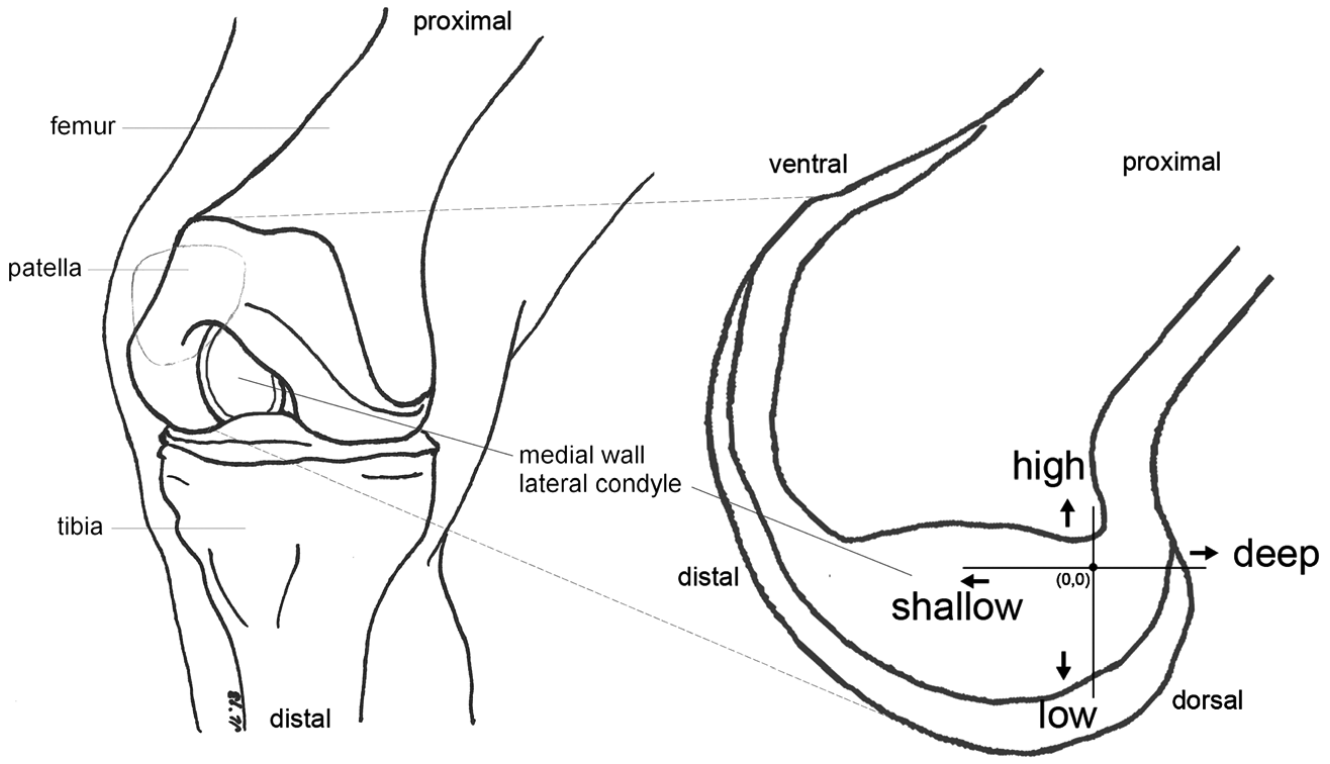

Figure 1. The coordinate system as defined in each femur. Left: The knee with its intercondylar notch. Right sagittal view: The anterior cruciate ligament inserts at the high–deep part of the medial notch wall of the lateral condyle. The center of the ACL insertion (0,0) becomes the origin of the new defined femoral coordination system, the X-axis runs in the deep–shallow direction, the Y-axis determines the position in high–low direction at the medial notch wall.

The center of the ACL, calculated by means of the average of all points on the outline of the ACL insertion, was projected onto the XY plane and defined as the origin (0,0) of the new 2D coordinate system. Similarly, the positions of the AM and PL anatomic centers (AC) were calculated. Then, AM and PL insertions centers, the AM and PL template locations and the positions of the tunnel marks were projected and defined in the new coordinate system relative to the new origin.

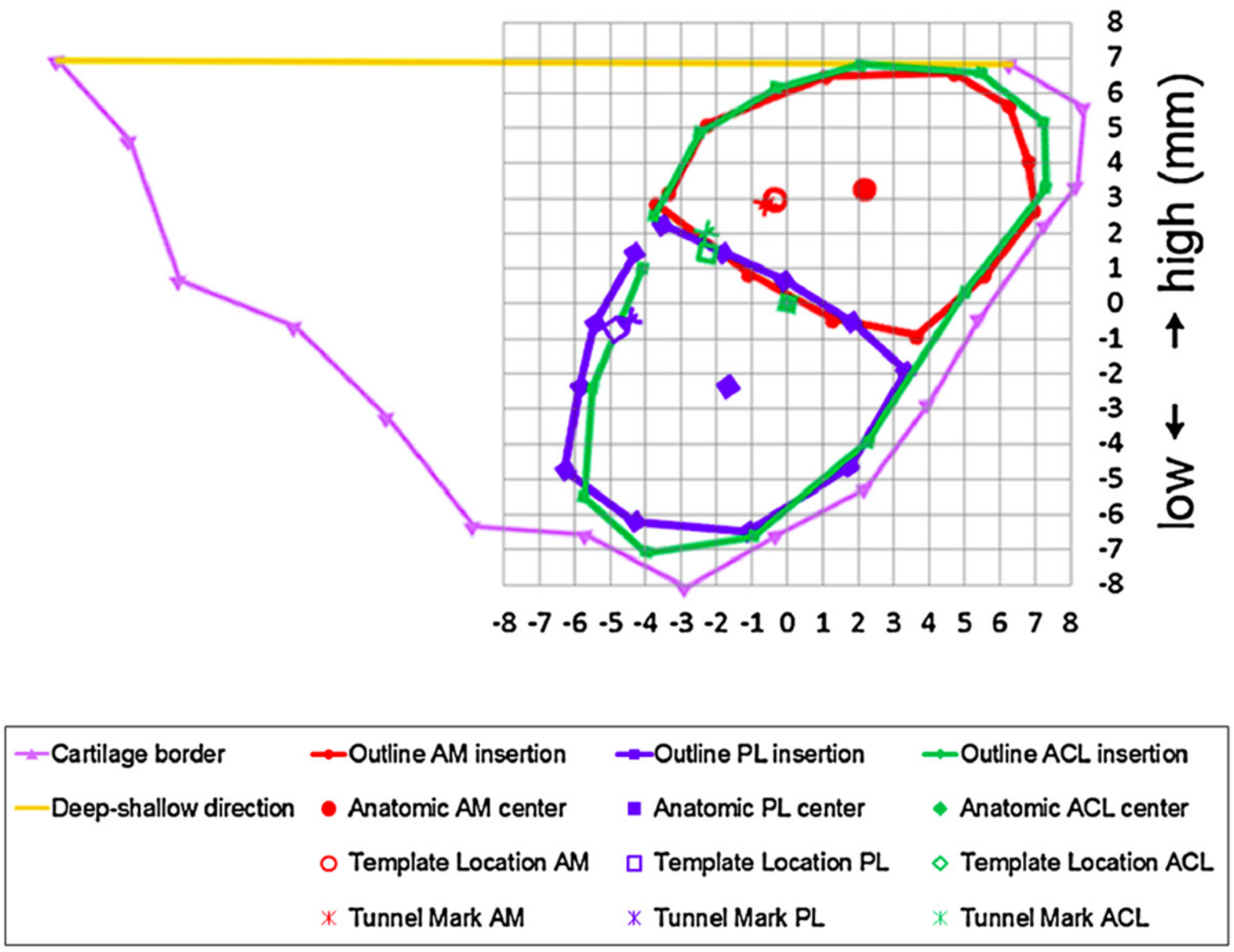

Figure 2. All points at the surface of the condyle wall, with the anatomic ACL center as origin of the coordinate system.

Data analysis

To define the validity of the total tunnel positioning procedure for both bundles, the differences in positions between the anatomical centers (gold standard) and the tunnel marks were calculated in HL (Y) and in DS (X) directions for each of the four measurements and expressed in two values. The accuracy (the agreement between the positions) was calculated using the mean of all the individual absolute differences [$\Delta XY = \surd\,(X_{AC} - X_{TM})^2 + (Y_{AC} - Y_{TM})^2$]. The precision (the repeatability of the procedure) was defined by means of the standard deviation (SD) of the absolute differences. The tunnel placement errors as quantified above could be the result of errors within the template and its placement (planning procedure) or by the inability of surgeons to identify the correct tunnel position guided by the template (placement procedure).
To identify the errors of the planning procedure the differences in positions of the template locations and the anatomical centers were calculated. The bias (a possible systematic deviation) of the AM or PL template locations relative to the anatomic centers, was calculated as the mean difference of all individual differences in DS [$\Delta X = X_{AC} - X_{TL}$] and HL [$\Delta Y = Y_{AC} - Y_{TL}$] directions. The mean absolute difference defined the accuracy (Figure 3).
Similarly, the accuracy of the placement procedure, i.e. the accuracy with which the surgeons place the tunnels, was calculated as the mean absolute difference between the positions of the tunnel marks and template locations. To determine whether a learning curve for the placement procedure was present, Student's t-test ($\alpha = 0.05$, $P < 0.05$) for the absolute differences of the tunnel marks and template locations from both measurements of one surgeon, was performed to detect any improvement in the accuracy during the course of the measurements.

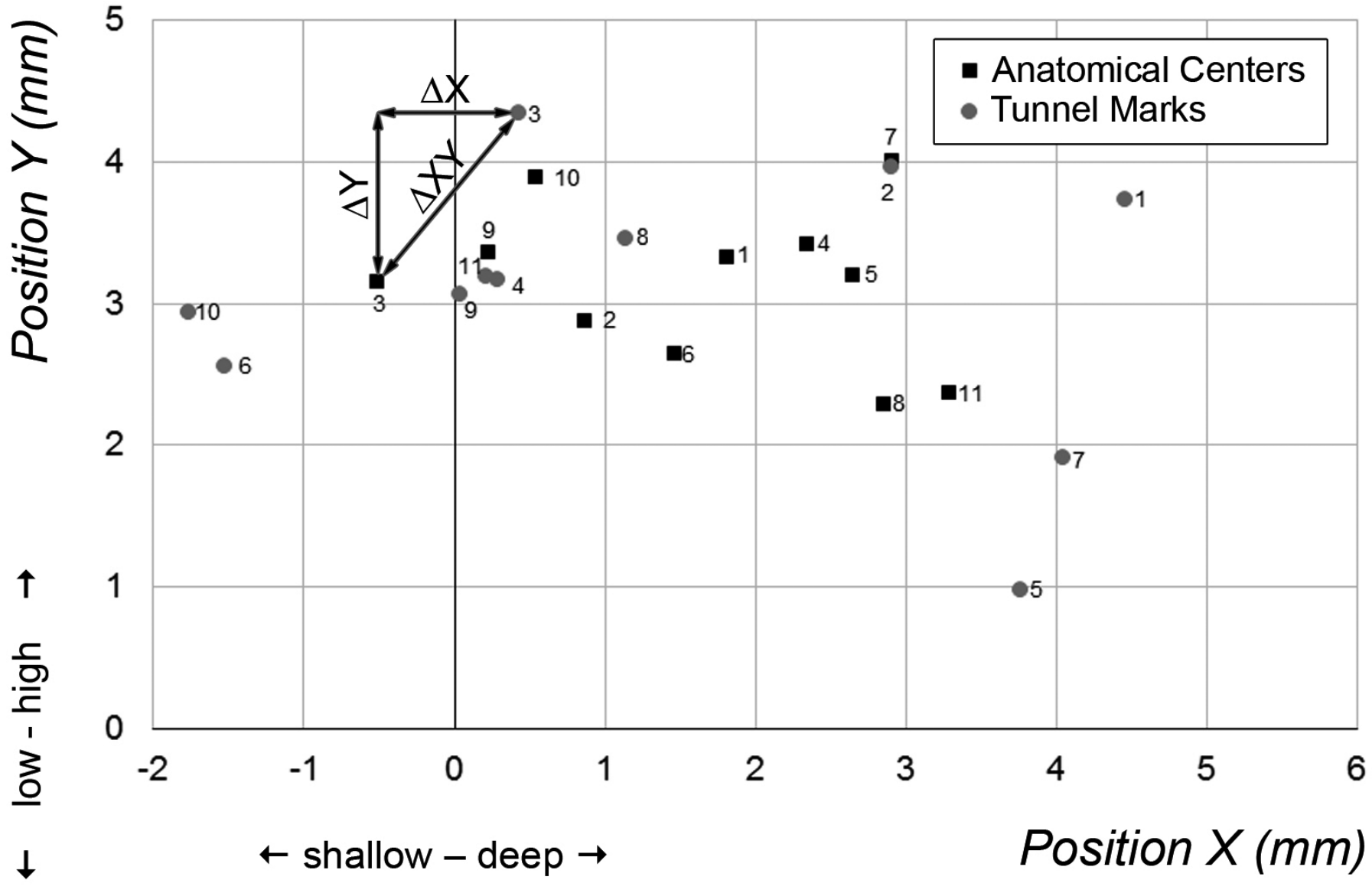

Figure 3. The positions of the AM anatomical centers (squares) and AM tunnel locations (spheres) from one measurement session. The numbers indicate the 12 individual specimens. The mean difference in positions between the anatomical centers and tunnel locations as calculated in both directions to define bias. The accuracy was defined calculating the mean of the absolute differences.

The intra- and inter-surgeon variability, the reproducibility of the total tunnel positioning procedure within and between the surgeons, was also determined, calculating the absolute differences (accuracy) and SD (precision) between the positions of the tunnel marks of both measurement moments for each surgeon (intra) and between surgeons (inter).
The accuracy with which the surgeons placed the tunnels during the placement procedure (the mean absolute difference between the positions of the tunnel marks and the template locations), was 0.4 mm (range 0.0–1.1 mm). There was no learning curve for the placement procedure, since the accuracy during the second measurements was not improved (P > 0.05).
The intra-surgeon measurements of the total tunnel positioning procedure showed an accuracy of 2.9 and 3.1 mm for AM and PL tunnel marks, respectively. Likewise, the precision was 1.2 and 1.9 mm (Table 3). The accuracy of the inter-surgeon reproducibility of the total tunnel positioning procedure was 3.2 mm for AM tunnel marks and 3.0 mm for PL tunnel marks, with precisions of 1.6 and 1.7 mm, respectively (Table 3).

Table 1. The accuracy (mm) and precision (mm) of the tunnel positioning procedure by the surgeon using the template and CAS

	AM bundle		**PL bundle**	
	Accuracy	**Precision**	**Accuracy**	**Precision**
A1	2.3	0.8	2.7	0.9
A2	3.2	1.1	3.5*	1.9
B1	2.5	1.0	3.6*	1.5
B2	2.6	0.8	3.4*	1.7
Overall	**2.7**	**1.0**	**3.2**	**1.6**

The differences in positions between the anatomical centers (AC) and the tunnel marks (TM) for the four different measurements; A/B=surgeon A/B; 1/2=measurement 1/2; Accuracy (mean absolute difference) and Precision (SD absolute differences)
**Significant difference in positions AC and TM, P<0.05*

Results

The accuracy of the total tunnel positioning procedure was 2.7 mm for the AM tunnel marks with a precision of 1.0 mm. The accuracy for the PL tunnel marks was 3.2 mm with a precision of 1.6 mm (Table 1). The bias for the AM template locations reflected during the planning procedure was 0.8 mm in the high direction and 0.6 mm in the deep direction. For the PL template locations, the bias was 2.3 mm in the high direction and 0.2 mm in the shallow direction (Table 2 and Figure 4). The accuracy of the planning procedure (the mean absolute difference between the positions of the template locations and the anatomical centers) was 2.9 mm (AM) and 3.2 mm (PL).

Table 2 Absolute positions (mm) of the actual anatomical centres of the ACL, AM and PL in the 12 femora of the current study and the positions according to the guidelines of Luites et al. (2000) and Piefer et al. (2012) in deep–shallow (DS) direction at Blumensaat's line and in high–low (HL) direction at condyle depth

	AM bundle				**PL bundle**			
	Bias		**Accuracy**	**Precision**	**Bias**		**Accuracy**	**Precision**
	HL	**BS**			**HL**	**DS**		
A1	0.1	0.4	2.4	0.7	1.3	-0.3	2.6	0.9
A2	1.5	1.1	3.5	1.1	2.8	0.1	3.6	1.8
B1	1.1	0.2	2.6	1.3	2.3	-0.7	3.4	1.4
B2	0.4	0.6	2.8	0.7	2.7	0.1	3.3	1.7
Overall	**0.8**	**0.6**	**2.9**	**1.1**	**2.3**	**-0.2**	**3.2**	**1.5**

The differences in the positions between the anatomical centers (AC) and the template locations (TL) for the four different measurements; bias (mean difference) in high–low (HL, positive is high) and deep–shallow (DS, positive is deep) direction; accuracy (mean absolute difference) and precision (SD absolute differences)

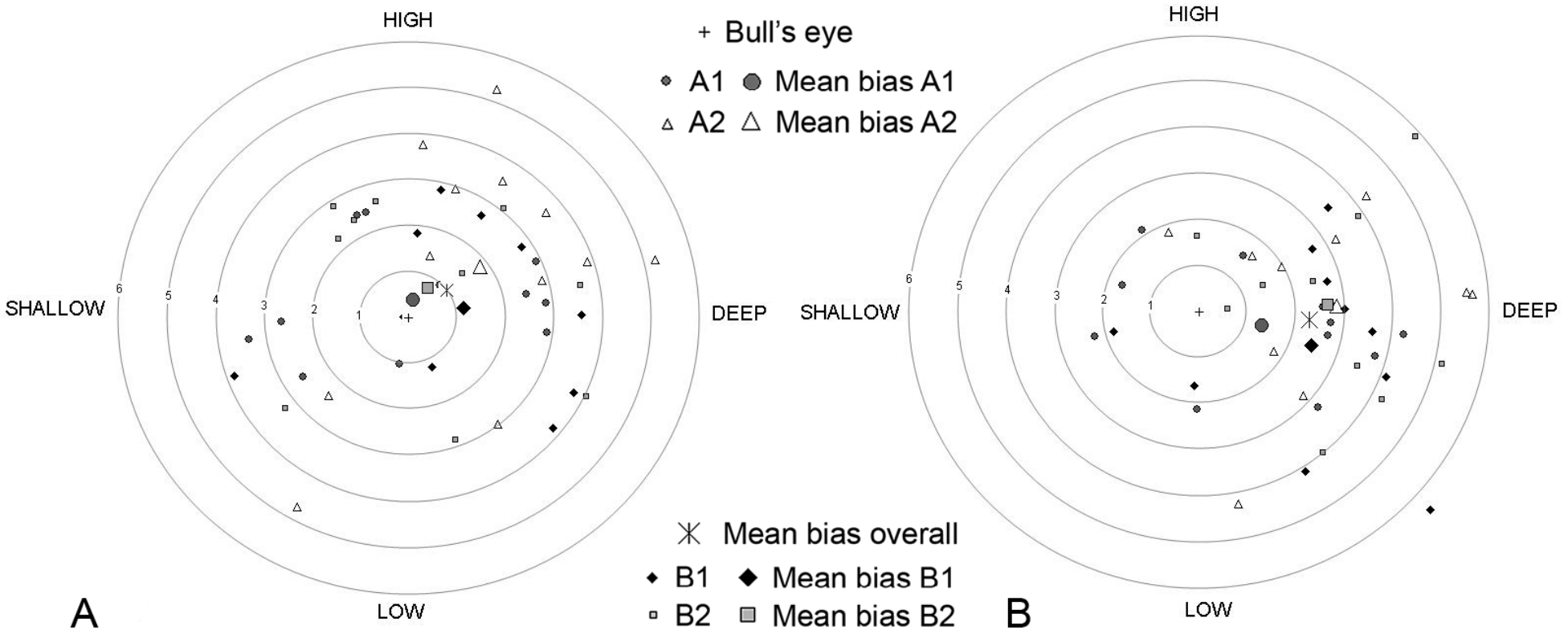

Figure 4. The bias of the planning procedure using the template and CAS. The dots represent the individual differences (N=12) between the anatomical center positions and the tunnel positions for the AM bundle (A) and the PL bundle (B); four different modelled dots are presented as the results of the four different measurement sessions (two measurements by two surgeons). Additionally the four means of the separate sessions are also shown; A/B=surgeon A/B; 1/2=measurement 1/2.

The accuracy with which the surgeons placed the tunnels during the placement procedure (the mean absolute difference between the positions of the tunnel marks and the template locations), was 0.4 mm (range 0.0–1.1 mm). There was no learning curve for the placement procedure, since the accuracy during the second measurements was not improved (P>0.05). The intra-surgeon measurements of the total tunnel positioning procedure showed an accuracy of 2.9 and 3.1 mm for AM and PL tunnel marks, respectively. Likewise, the precision was 1.2 and 1.9 mm (Table 3). The accuracy of the inter-surgeon reproducibility of the total tunnel positioning procedure was 3.2 mm for AM tunnel marks and 3.0 mm for PL tunnel marks, with precisions of 1.6 and 1.7 mm, respectively (Table 3).

Table 3. The intra-surgeon and inter-surgeon reproducibility of the tunnel marking procedure (mm)

	AM bundle		PL bundle	
	Accuracy	**Precision**	**Accuracy**	**Precision**
Intra A1-A2	3.0	1.1	2.5	1.5
Intra B1-B2	2.8	1.4	3.8	2.2
Overall INTRA	**2.9**	**1.2**	**3.1**	**1.9**
Inter A1-B1	3.3	2.2	2.9	1.5
Inter A2-B2	3.9	1.9	2.9	1.9
Inter A1-B2	2.3	0.7	1.8	1.0
Inter A2-B1	3.8	2.2	3.4	1.8
Overall INTER	**3.2**	**1.6**	**3.0**	**1.7**

The mean differences in the positions between the tunnel marks (TM) of the measurements within (intra) and between (inter) the two surgeons: accuracy (mean absolute 2D difference) and precision (SD absolute differences)

Discussion

Computer navigation during femoral ACL tunnel positioning can assist in accurate tunnel placement at a predefined planned target and can also contribute to determining the planning target at the anatomical positions. Other CAS systems often use additional two-dimensional imaging to provide guidelines for anatomical positioning [12,15–17,21,23]. The CAS system tested in this study uses a three-dimensional morphable femoral template that can be adapted intra-operatively to the patients' knee, to determine anatomical tunnel positions in the individual [25]. In this study we assessed the accuracy of this imageless tunnel positioning procedure, consisting of the navigated planning procedure and the navigated placement procedure, calculating the distances between the anatomical centers and the tunnel positions.
The accuracy of the tunnel positioning procedure is determined at c. 3 mm. This value is constructed from the accuracies of (1) the planning procedure using the template implemented in the CAS system and (2) the placement procedure using the real-time navigation function of the CAS system [19].

1. The accuracy of the planning procedure with the template is related to the reproducibility of the positions of the AM and PL center locations within the template. In the process of defining the template by using 31 knee specimens, this reproducibility, reflected by the standard deviations of the mean center positions, appeared to be 2.2 mm (AM) and 2.0 mm (PL) [25]. Performing the planning procedure with the template implemented in the CAS system at the 31 knee specimen of the development study, resulted in slightly worse accuracy of the template positions relative to the anatomical centers (2.5 mm for AM and 2.2 mm for PL, Table 4). As shown in this study, when performed by surgeons on other specimens, the planning procedure loses some accuracy (AM: 2.9 mm and PL: 3.2 mm).

2. The inaccuracy of the CAS placement procedure, marking the center of the tunnel given by the positions of the template was small (0.4 mm) and corrected in some cases the inaccuracy of the template locations.

To summarize, the largest part of the inaccuracy is allocated to the bias and inaccuracy of the center positions in the template itself. The deviations of the template locations relative to anatomical centers from the knees in this study were relatively small (<0.8 mm) and random in all directions, except for the high low direction of the PL bundle, where a systematic error of 2.3 mm was found.

The accuracies and precisions of anatomical tunnel placement methods has been the subject of a limited number of studies (Table 4). Without computer assistance, accuracies of the placement of obtained tunnels relative to the preplanned ideal tunnel locations appeared to be 7 mm [15] and 4.2 mm [11]. Computer assistance resulted in accuracies for tunnel placement of 2.5 mm [15] and 2.7 mm [11], which is an improvement of the placement procedure. However, the system used in this study, can place the tunnels almost at the position of the planned tunnel, according the mean absolute difference of 0.4 mm between the planned tunnels (template locations) and the drilled tunnels (tunnel marks). The precision of our system (0.2 mm) seems also better, than from those used in the other studies: 1.9 mm [11] and 1.7 mm [15]. The active robotic system studied by Burkart [10] and Musahl [12] showed a placement precision of c. 1 mm, the placement accuracy was 1.3 mm [12]. In another study [28], the accuracy of the planning procedure of the robotic system was measured: the CAS planning station provided a tunnel location that was on average 1.3 mm away from the actual femoral ACL insertion. This method seems more accurate than our planning procedure, however, different methods for calculating the anatomical insertion centers were used and accuracy measurements were performed on projections at the sagittal plane by Musahl [28] and in this study at the bony surface. However, application of a similar method in vivo in a level-I study could not demonstrate more accurate and precise placement of the femoral tunnel relative to conventional tunnel placement [29]. Since the surgeries in that study were performed by highly experienced surgeons, the benefits of navigation were perhaps too small for this group. The accuracy between the obtained tunnel location and the anatomical center was not calculated.

The repeatability measurements of the system indicated that differences between and within observers may occur which are in the same range as the accuracy of the template itself, although we admit that these repeatability measurements were done with only two surgeons who repeated the measurements only two times. The measurements did not show any learning effect for tunnel placement. Since feedback about the accuracy was not present, this was indeed not to be expected. A positive finding of the study was that, even without this feedback, tunnel placement was very accurate.

The main errors in the measurements are probably caused by the sensitivity of the template to other coordinates for the digitized landmarks during the planning procedure. However, there is room for improving this procedure. First, by correcting the systematic bias of the PLB center with 2.3 mm in the low direction. Second, by making the template more robust against small variations of the geometry of the notch surface and cartilage border by adding boundary conditions to the algorithm restricting the position of the cylinder solely to possible solutions. With the current possibilities, the cylinder can be too large or placed with the wrong orientation. This can be prevented by restricting the maximum diameter of the cylinder and its orientation within the notch.

The advantage of our system is the possibility to plan the AM and PL tunnels at the anatomical positions without using additional intraoperative images. Also, the planning system and placement procedure uses the individual 3D geometric data. This is important because there is only moderate correlation between 2D and 3D measurement of intercondylar notch geometry [30]. Therefore, the 3D approach is advocated [24]. The system can also be used to determine notch impingement and elongation patterns of virtually planned ligaments [19].
In this study we focused on the computer assisted femoral ACL placement; in another study the effect of method application at knee laxity results was evaluated in an in vitro study [31]. However, at this stage we do not know what the clinical implications are of the errors found in this study.
Although computer navigation can improve the accuracy and precision of tunnel placement, the positive influence on functional outcomes is reported only rarely [32]. Most studies did not find additional functional effects of accurate tunnel placement using CAS [15,33,34]. However, the actual tunnel position in these patient studies in relation to the anatomical position is not always clearly documented or there was no difference in the 2D registered tunnel position in the CAS group and the tunnel position in the manually navigated control group [35]. Therefore the lack of functional effect could be caused by inaccurate planning of the tunnel position. Besides that, the optimal tunnel position is still a subject of debate [36]. Accepted methods used in most CAS systems target average positions (quadrant method), without taking the large anatomical variations into account. The aim of the template method described in this study, is to respond better to these individual geometrical varieties. In addition to the optimal position, it is also unknown which error-threshold of tunnel placement accuracy is necessary during ACL reconstruction.
In conclusion, we can state that the computer-assisted system contributed to accurate anatomical tunnel positioning, showing high accuracy for navigated tunnel placement with small variation. Using real time navigation without additional (intraoperative) imaging, 3D anatomical tunnel planning with computer-assisted morphable templating technique is an innovative method with capacity for improvement of the accuracy, overcoming the systematic bias and making the template more robust against small variations in the geometry of the notch surface and cartilage border.

Ethics The study protocol for this laboratory study was reviewed and accepted by the institutional review board prior to testing.

Conflict of Interest All authors declare to have no potential conflicts of interests in relation to this manuscript.

Funding No specific funding.

Table 4. Literature overview of the accuracy (mm) and precision (mm) in femoral tunnel planning and placement systems

			Anatomical Centers-Planned Tunnels			Planned Tunnels-Actual Tunnels		Anatomical Centers-Actual Tunnels	
Studies	**number and kind specimen**	**Tunnel planning method**	**Accuracy planning**	**Precision planning**	**Tunnel placement method**	**Accuracy place-ment**	**Precision place-ment**	**Accuracy planning & place-ment**	**Precision planning & placement**
Current study	12 cadaveric knees	SurgiGATE CAS system with developed template	AM: 2.9 PL: 3.2	AM: 1.1 PL: 1.5	SurgiGATE CAS system with developed template	AM: 0.4 PL: 0.4	AM: 0.2 PL: 0.2	AM: 2.7 PL: 3.2	AM: 1.0 PL: 1.6
Luites et al 2011 (25)	31 cadaveric knees[1]	SurgiGATE CAS system with developed template	AM: 2.5 PL: 2.2	AM: 1.2 PL: 1.2					
Picard et al 2001 (11)	20 sawbones	CT scanned specimen with preoperative surgical planning			real time navigation technique using CT and bone registration (KneeNav™ ACL)	2.7	1.9		
	20 sawbones	conventional femoral guide pin			conventional femoral guide pin	4.2	1.8		
Chouteau 2008 (15)	Knees of 37 patients	preoperative X-ray planning using Triangle method of Benareau			CAS	2.5	1.1		
	Knees of 36 patients				Traditional technique	7.0	1.5		
Burkart et al 2001 (10)	10 sawbones	preoperative CT planning using quadrant method (Caspar®)			active robotic system (Caspar®)		1.05[2]		
	10 sawbones	free hand placement			experienced surgeons		1.1-1.5[2]		
	10 sawbones	free hand placement			fellows		2-2.2[2]		
Mushal et al 2002 (12)	10 fresh frozen cadaveric knees	preoperative CT planning using quadrant method (Caspar®)			active robotic system (Caspar®)	1.3	0.9		
Mushal et al 2003 (28)	8 fresh frozen cadaveric knees							1.3	1.0

The accuracy and precision of tunnel planning method (differences in positions between anatomical centres and planned tunnels); tunnel placement methods (differences in positions between anatomical centres and actually drilled tunnels); and for combined tunnel planning and placement methods (differences in positions between planned tunnels and actually drilled tunnels).

[1] These cadaveric specimen were used to develop the mean femoral template.

*[2] With the radius of sphere mentioned in the article, the SD is estimated at ½ * radius.*

References

1. Markolf KL, Hame S, Hunter DM, et al. Effects of femoral tunnel placement on knee laxity and forces in an anterior cruciate ligament graft. J Orthop Res 2002; 20: 1016–1024.
2. Zavras TD, Race A, Amis AA. The effect of femoral attachment location on anterior cruciate ligament reconstruction: graft tension patterns and restoration of normal anterior-posterior laxity patterns. Knee Surg Sports Traumatol Arthrosc 2005; 13: 92–100.
3. Moisala AS, Jarvela T, Harilainen A, et al. The effect of graft placement on the clinical outcome of the anterior cruciate ligament reconstruction a prospective study. Knee Surg Sports Traumatol Arthrosc 2007; 15: 879–887.
4. Sommer C, Friederich NF, Muller W. Improperly placed anterior cruciate ligament grafts: correlation between radiological parameters and clinical results. Knee Surg Sports Traumatol Arthrosc 2000; 8: 207–213.
5. Musahl V, Plakseychuk A, VanScyoc A, et al. Varying femoral tunnels between the anatomical footprint and isometric positions: effect on kinematics of the anterior cruciate ligament- reconstructed knee. Am J Sports Med 2005; 33: 712–718.
6. Sudhahar TA, Glasgow MM, Donell ST. Comparison of expected vs actual tunnel position in anterior cruciate ligament reconstruction. Knee 2004; 11: 15–18.
7. Behrend H, Stutz G, Kessler MA, et al. Tunnel placement in anterior cruciate ligament (ACL) reconstruction: quality control in a teaching hospital. Knee Surg Sports Traumatol Arthrosc 2006; 14: 1159–1165.
8. Zantop T, Diermann N, Schumacher T, et al. Anatomical and nonanatomical double-bundle anterior cruciate ligament reconstruction: importance of femoral tunnel location on knee kinematics. Am J Sports Med 2008; 36: 678–685.
9. Klos TV, Habets RJ, Banks AZ, et al. Computer assistance in arthroscopic anterior cruciate ligament reconstruction. Clin Orthop Relat Res 1998; 354: 65–69.
10. Burkart A, Debski RE, McMahon PJ, et al. Precision of ACL tunnel placement using traditional and robotic techniques. Comput Aided Surg 2001; 6: 270–278.
11. Picard F, DiGioia AM, Moody J, et al. Accuracy in tunnel placement for ACL reconstruction. Comparison of traditional arthroscopic and computer-assisted navigation techniques. Comput Aided Surg 2001;6: 279–289.
12. Musahl V, Burkart A, Debski RE, et al. Accuracy of anterior cruciate ligament tunnel placement with an active robotic system a cadaveric study. Arthroscopy 2002; 18: 968–973.
13. Eichhorn J. Abstracts from the 23rd Annual Meeting of the Arthroscopy Association of North America: three years of experience with computer navigation-assisted positioning of drilling tunnels in anterior cruciate ligament replacement (SS-67). Arthroscopy 2004; 20: e31–e32.
14. Kodali P, Yang S, Koh J. Computer-assisted surgery for anterior cruciate ligament reconstruction. Sports Med Arthrosc 2008; 16: 67–76.
15. Chouteau J, Benareau I, Testa R, et al. Comparative study of knee anterior cruciate ligament reconstruction with or without fluoroscopic assistance a prospective study of 73 cases. Arch Orthop Trauma Surg 2008; 128: 945–950.
16. Kawakami Y, Hiranaka T, Matsumoto T, et al. The accuracy of bone tunnel position using fluoroscopic-based navigation system in anterior cruciate ligament reconstruction. Knee Surg Sports Traumatol Arthrosc 2011; 20: 1503–1510.
17. Shafizadeh S, Balke M, Wegener S, et al. Precision of tunnel positioning in navigated anterior cruciate ligament reconstruction. Arthroscopy 2011; 27: 1268–1274.
18. Kohn D, Busche T, Carls J. Drill hole position in endoscopic anterior cruciate ligament reconstruction. Results of an advanced arthroscopy course. Knee Surg Sports Traumatol Arthrosc 1998; 6(Suppl 1): S13–S15.
19. Sati M, Staubli H, Bourquin Y, et al. Real-time computerized in situ guidance system for ACL graft placement. Comput Aided Surg 2002; 7: 25–40.
20. Jalliard R, Lavallee S, Dessenne V. Computer assisted reconstruction of the anterior cruciate ligament. Clin Orthop

Relat Res 1998; 354: 57–64.
21. Klos TV, Banks SA, Habets RJ, Cook FF. Sagittal plane imaging parameters for computer-assisted fluoroscopic anterior cruciate ligament reconstruction. Comput Aided Surg 2000; 5: 28–34.
22. Bernard M, Hertel P, Hornung H, Cierpinski T. Femoral insertion of the ACL. Radiographic quadrant method. Am J Knee Surg 1997; 10: 14–21.
23. Sabczynski J, Dries SP, Hille E, Zylka W. Image-guided recon- struction of the anterior cruciate ligament. Int J Med Robot 2004; 1: 125–132.
24. Hoshino Y, Kim D, Fu FH. Three-dimensional anatomic evalua- tion of the anterior cruciate ligament for planning reconstruction. Anat Res Int 2012; 2012: 569704.
25. Luites JW, Wymenga AB, Blankevoort L, et al. Development of a femoral template for computer-assisted tunnel placement in anatomical double-bundle ACL reconstruction. Comput Aided Surg 2011; 16: 11–21.
26. Luites JW, Wymenga AB, Blankevoort L, Kooloos JG. Description of the attachment geometry of the anteromedial and posterolateral bundles of the ACL from arthroscopic perspective for anatomical tunnel placement. Knee Surg Sports Traumatol Arthrosc 2007; 15: 1422–1431.
27. Amis AA, Jakob RP. Anterior cruciate ligament graft positioning, tensioning and twisting. Knee Surg Sports Traumatol Arthrosc 1998; 6(Suppl 1): S2–12.
28. Musahl V, Burkart A, Debski RE, et al. Anterior cruciate ligament tunnel placement: Comparison of insertion site anatomy with the guidelines of a computer-assisted surgical system. Arthroscopy 2003; 19: 154–160.
29. Meuffels DE, Reijman M, Verhaar JA. Computer-assisted surgery is not more accurate or precise than conventional arthroscopic ACL reconstruction a prospective randomized clinical trial. J Bone Joint Surg Am 2012; 94: 1538–1545.
30. van Eck CF, Martins CA, Kopf S, et al. Correlation between the 2-dimensional notch width and the 3-dimensional notch volume a cadaveric study. Arthroscopy 2011; 27: 207–212.
31. Luites JW, Wymenga AB, Blankevoort L, et al. Computer-assisted anatomically placed double-bundle ACL reconstruction: an in vitro experiment with different tension angles for the AM and the PL graft. Med Eng Phys 2012; 34: 1031–1036.
32. Plaweski S, Cazal J, Rosell P, Merloz P. Anterior cruciate ligament reconstruction using navigation: a comparative study on 60 patients. Am J Sports Med 2006; 34: 542–552.
33. Hart R, Krejzla J, Svab P, et al. Outcomes after conventional versus computer-navigated anterior cruciate ligament reconstruction. Arthroscopy 2008; 24: 569–578.
34. Cheng T, Liu T, Zhang G, Zhang X. Computer-navigated surgery in anterior cruciate ligament reconstruction: are radiographic outcomes better than conventional surgery? Arthroscopy 2011; 27: 97–100.
35. Meuffels DE, Reijman M, Scholten RJ, Verhaar JA. Computer assisted surgery for knee ligament reconstruction. Cochrane Database Syst Rev 2011: CD007601.
36. Howell SM. Be sensible and cautious about criticizing tunnel placement in ACL reconstruction. J Bone Joint Surg AM 2012; 94: e133: 1–2.


Raffi & Eli

CHAPTER 7

Computer-assisted anatomically placed double-bundle ACL reconstruction: an in vitro experiment with different tension angles for the AM and the PL graft

Joan W.H. Luites, Ate B. Wymenga, Leendert Blankevoort,
Jan G.M. Kooloos and Nico Verdonschot

Medical Engineering & Physics 2012 34:1031–1036

Abstract

Anterior cruciate ligament reconstruction techniques are evolving with innovations like double-bundle (DB) grafts and computer assistance. The current DB techniques do not appear to make the clinical difference yet. Insight in various techniques may lead to better results. In this study, the anterior laxity of a DB reconstruction with an anteromedial (AM) graft fixated in 90° of flexion and a posterolateral (PL) graft fixated in 20° and computer-assisted anatomically placed femoral attachments was compared to normal values and single-bundle grafts. In 8 fresh-frozen human cadaveric knees, the anterior laxity was tested from 0° to 90° flexion, with a 100 N anterior tibial load in joints with 1) intact ACL, 2) torn ACL, 3) single-bundle (SB) graft tensed with 15 N in 20°, 4) anatomic AM graft tensed with 15 N in 90°, 5) anatomic PL graft tensed with 15 N in 20°, 6) anatomic DB graft (4+5). All reconstructions caused a posterior position of the tibia. Relative to the normal anterior laxity, the single-bundle techniques showed significantly increased laxities: The SB technique in 0° (+1.1 mm) and 15° (+1.7 mm); The AM reconstructions in 45° (+1.6 mm) and 90° (+1.5 mm); The PL reconstructions in all angles (from +1.4 to +2.3 mm), except in 0°. The anatomic DB technique showed no significantly increased laxities and restored normal laxity in all angles.

Introduction

The Anterior Cruciate Ligament (ACL) can be characterized by two functional bundles, the anteromedial (AM) and the posterolateral (PL) bundles [1,15]. Both bundles have different tension patterns in relation to the knee flexion angle, resulting in different contributions to determining the laxity of the joint. The AM bundle is rather tight over the entire range of motion, but mostly tensed in flexion. The PL fibers are tight at the lower flexion angles, near extension [1,13,25,33,37]. A reconstruction technique with two grafts, placed at the anatomical positions of the two functional bundles, combining the functions of both bundles, should theoretically result in a physiological behavior of the reconstruction, constraining anterior laxity over the complete range of motion [44,45]. Nevertheless, a systematic review of 4 patient studies employing this technique did not show a significantly better clinical outcome of double-bundle versus single-bundle reconstruction [29]. Improvement of the double-bundle technique could contribute to a better clinical outcome [9]. Since graft function is affected by graft tension and knee flexion angle at the moment of graft fixation [18,31,41,45], we hypothesized that tensioning the AM and PL bundles at the flexion angles at which they contribute most to anterior stability, may lead to a further optimization of ACL functioning. Hence, it is hypothesized that tensioning of the PL bundle is best done at 20° of flexion [31,33,41] whereas the AM bundle is preferably tensed in 90° of flexion [33,37,44].

The objective of this study was to measure the anterior laxity characteristics of a doublebundle reconstruction technique. The main goal was to address the ability to restore normal anterior laxities through a computer-assisted anatomically placed double-bundle quadriceps-bone reconstruction of the ACL. To assess the individual constraining capacity of the two grafts in this double-bundle reconstruction technique and the synergistic effects combining both, the relative contributions of the AM and PL bundles were also analyzed. To place the results of the double-bundle technique in perspective, the anterior laxity of a normal knee, an ACL-deficient knee and a knee reconstructed with a single-bundle graft positioned at the femoral 11 or 1 o'clock position, was also determined.

The hypothesis tested in this study was that the anatomic double-bundle reconstruction, with the PL tensed at 20° and the AM at 90° of flexion, will approximate normal anterior translation, measured in six angles ranging from 0° till 90°.

Methods

Eight fresh cadaver knees, obtained from autopsy and kept frozen until the time of use, were screened for absence of abnormalities on radiographs. The age of the donors at the time of death ranged from 58 to 91 years. The bones were cut approximately 20 cm from the joint line. The knees were thawed overnight and the grafts were harvested: the bone-patellar tendon-bone graft for the single-bundle reconstructions. The quadriceps tendon with a bone block of the proximal patella was prepared for the double-bundle technique. This graft is very suitable to be used as a DB graft, since it has tendon tissue over the whole bone block, which could be split into two slips. The quadriceps tendon has similar properties as the BPB graft

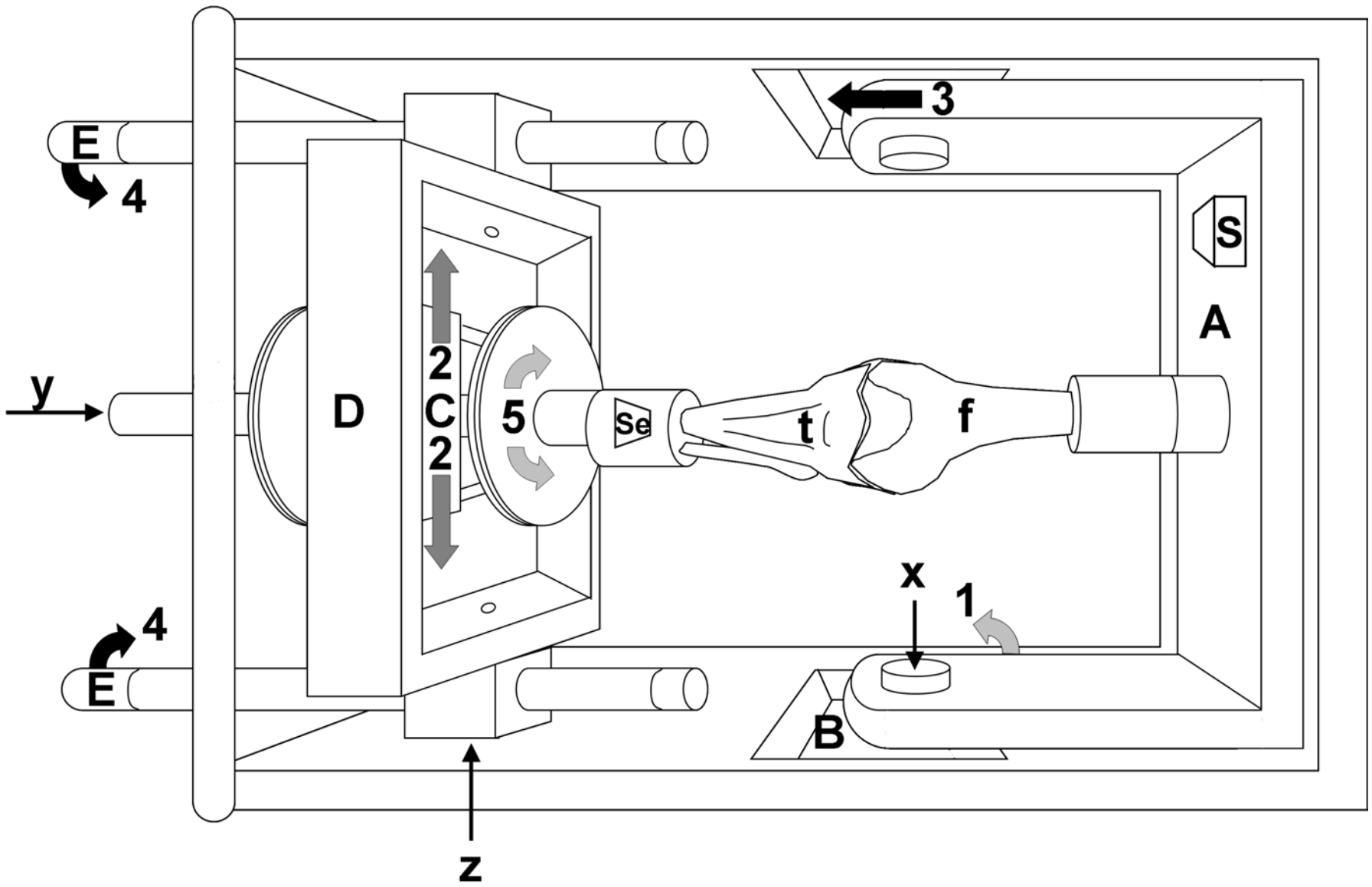

Figure 1. The knee joint motion and loading apparatus from proximal.

[39]. Subsequently, all muscle tissue was removed; the medial and lateral capsule and ligament tissue of the knee joint were kept intact.
The femur (f) is mounted at bracket (A). Flexion (1) is achieved by manual rotation of bracket A around the joint in axis x. The tibia (t) is free tot move in varus-valgus rotation and medial-lateral translation, through translation (2) of block C in slot D. Proximal-distal translation of the femur, allowed through translation of bracket A in slot B, is forced into an axial compression towards the tibia (3) applying 25 N at both sides. Anterior-posterior translation of the tibia, allowed through block D around axis z, is forced towards anterior (5) applying 50N at E (2x). Internal-external translation (5) around axis y is restrained to the rotation position of the normal knee in 0°. The source (S) of the Fastrak system is mounted onto bracket A; the sensor (Se) onto the tibia-cylinder.

A knee loading system, in which knees could be subjected to different loads in various flexion angles, was used for the experiments (Figure 1). This system was previously used and extensively described in an in vitro study [5] and based on an earlier developed motion and loading apparatus [6]. There was a special fixation method of the femoral and tibial bones in the system. The bones were embedded with polymethylmethacrylate (PMMA) in plastic cylinders, which were part of the apparatus. When the PMMA hardened, it was possible to repeatedly remove the specimen, locate and drill the femoral and tibial tunnels and replace the knee in exactly the same position in the cylinders of the apparatus again. Subsequently, the grafts were fixated. The position of the femur was fixed and the tibia was free to move in four degrees of freedom, i.e. anterior/posterior translation, medial/lateral translation, proximal/distal translation and varus/valgus rotation. Besides the flexion, axial internal and external rotation of the tibia was restrained to the rotation position of the normal intact knee in the corresponding flexion angles during the tests. This was done to prevent the influence of variable coupled axial rotations on the AP translation which may mask the true effects of the procedures on AP translation. Furthermore, an axial force of 50 Newton was applied. This force was applied along the tibial axis, to simulate a compressive force to the knee joint and avoid sub-luxation, particularly in the ACL-deficient knee. The non-metallic design of the system made it possible to record motions of the tibia with an electromagnetic 3Space Fastrak tracking system (Polhemus Navigation Sciences, Colchester, Vermont USA). The source of the Fastrak system was attached to the part of the knee system were the femoral bone was fixed and the sensor to the tibial part. The anterior laxity of the knee resulting from an anterior force was measured, as explained later, at various flexion angles under 6 different conditions of the ACL: 1) intact; 2) ACL-deficient; 3) single-bundle (SB) reconstruction; 4) anatomic anteromedial bundle (AM) reconstruction; 5) anatomic posterolateral bundle (PL) reconstruction; 6) anatomic double-bundle (DB) reconstruction.

1) The first measurements were performed with an intact knee. After fixating the specimen in the apparatus, the axial force of 50N was applied and the knee was moved 3 times over the complete range of motion to precondition the joint. Then the knee was positioned in 6 flexion angles (0°, 15°, 30°, 45°, 60° and 90°). At every angle the three-dimensional (3D) position of the unloaded tibia relative to the femur was recorded with the Fastrak system. The rotation positions of the knee in the various angles were noted, to be used in the following tests. The same recordings were performed after the tibia was loaded with an anterior force of 100N to obtain the anterior translation.

2) For the second condition, the ligament was cut and all ACL tissue was removed. After the 3 pre-conditioning cycles over the range of motion, the measurements with the tibia unloaded and loaded in anterior direction were performed in the 6 flexion angles, with the rotation fixed in the position as measured in the intact condition.

3) The first reconstruction that was performed, was the SB reconstruction. Placement was achieved, outside the apparatus, by applying two commonly used drill guides to position the tibial and femoral tunnels, respectively. The tibial tunnel was positioned using the PCL Oriented Placement Marking Hook™ [Arthrex Inc., USA] and drilled with an 11 mm-drill. This guide places a tibial tunnel in the anatomical ACL attachment avoiding notch impingement [19,21,30,34,48]. The femoral tunnel was positioned with the transtibial femoral guide™ [Arthrex Inc., USA] with a 7 mm offset, placed in the over-the-top position at 11 0'clock. With this instrument a femoral tunnel is placed at the so-called 'isometric zone' [21,48]. An 11 mm-tunnel was drilled in the femur. Then the knee was repositioned in the motion- and loading apparatus and the Bone-Patellar tendon-Bone (BPB) graft was positioned in both tunnels. In the femoral hole, the bone was located proximally, the tendon distally. The bone in the tibial tunnel was lateral and the tendon medial. Before tensioning the graft, the tibia was translated posteriorly and manually held in that position. Then the graft was tensioned with 15 Newton (N) on a pretensioning spring device in 20° of knee flexion [21]. With that initial tension, the graft was preconditioned with 3 motion cycles of the knee. It was observed that the tension measured on the spring device, varied with knee flexion, during the loading cycles. However, at 20°, the pretension of 15 N was regained. Subsequently, the graft was fixated with interference screws in the drill holes, while care was taken to maintain the pretension on the graft. Finally, all measurements were performed and recorded. After the recordings of all tests, the whole BPB-graft was removed.

4) For the AM reconstruction, the Quadriceps Tendon Bone graft (QTB) with the bone block was prepared by dividing the tendon into two slips which ends were sutured to make a solid fixation possible. The anatomical position of the femoral tunnel was determined with a computer-assisted system (CAS, SurgiGATE, Medivision, Switzerland). Since the QTB graft had one bone block, only one tunnel had to be made. Using the specifically developed 3D femoral template [24], incorporated in the ACL-module (MEM Institute for Biomechanics, Switzerland), the tunnel was positioned at the anatomical center of the ACL. Therefore the surface of the notch and the posterior joint cartilage edge at the medial wall in the lateral notch were digitized. With these data the computer template, with the centers of the AM and PL bundles and the ACL, was displayed in the notch. The ACL center position was marked with a computer-tracked awl and an 11 mm-tunnel was drilled using a K-wire. This tunnel never overlapped the tunnel of the SB reconstruction. It did overlap the positions of the AM and PL anatomic centers. Subsequently, the bone block was positioned in the femoral tunnel. Then CAS was used to determine the correct position relative to the AM center, since the template also contained the anatomical AM center location, visible at the monitor. After digitizing the center of the AM tendon slip at the bone block, it was rotated until the bone mark was at the same position as the AM template mark. The knee was repositioned in the knee motion- and loading apparatus. A titanium interference screw was used to fixate the block at the femoral site. The tendon slip at the anatomical AM position was guided with the sutured end through the tibial tunnel at the medial side [16,23]. The graft was tensioned in 90° of flexion with 15 N, with the tibia translated posteriorly. Then the graft was preconditioned with 3 motion cycles of the knee. Finally, it was fixed with the sutures around a screw, which was placed medial from the exit of the tibial tunnel at the tibial surface. Finally, all measurements were performed and recorded.

5) To test the anatomic PL-reconstruction, the PL tendon was fixated. It was positioned at the lateral side of the tibial tunnel and tensioned in 20° flexion with 15 N. After the 3 conditioning cycles, the tendon was fixated in 20° flexion, through the sutures at a screw placed laterally relative to the tibial tunnel exit, with the tibia manually placed in a posteriorly translated position. Finally, all measurements were performed and recorded.

6) For the measurements of the knees with the anatomic DB technique, both the AM and PL grafts were fixated as described above. The measurements were performed and recorded.

To define a coordinate system relative to which rotations and translations were calculated, the sensor of the Fastrak system was mounted upon a stylus after the experiments. With this 3D digitizer, the point posterior of the tibial anterior cruciate insertion site at the tibial plateau was recorded. Next, the point 15 mm proximal to this recorded point was defined in the software as the origin of the tibial coordinate system [6]. Then the position along the anterior-posterior axis of the unloaded tibia in the intact knee, was calculated for all flexion angles (Figure 2).

The same was done for the condition in which the tibia was loaded with 100 N anterior force. The difference between the positions in anterior-posterior (AP) direction of the unloaded - and 100 N-loaded tibia was defined as the anterior laxity of the knee throughout the range of motion. In all reconstruction techniques, the tibia translated in posterior direction during

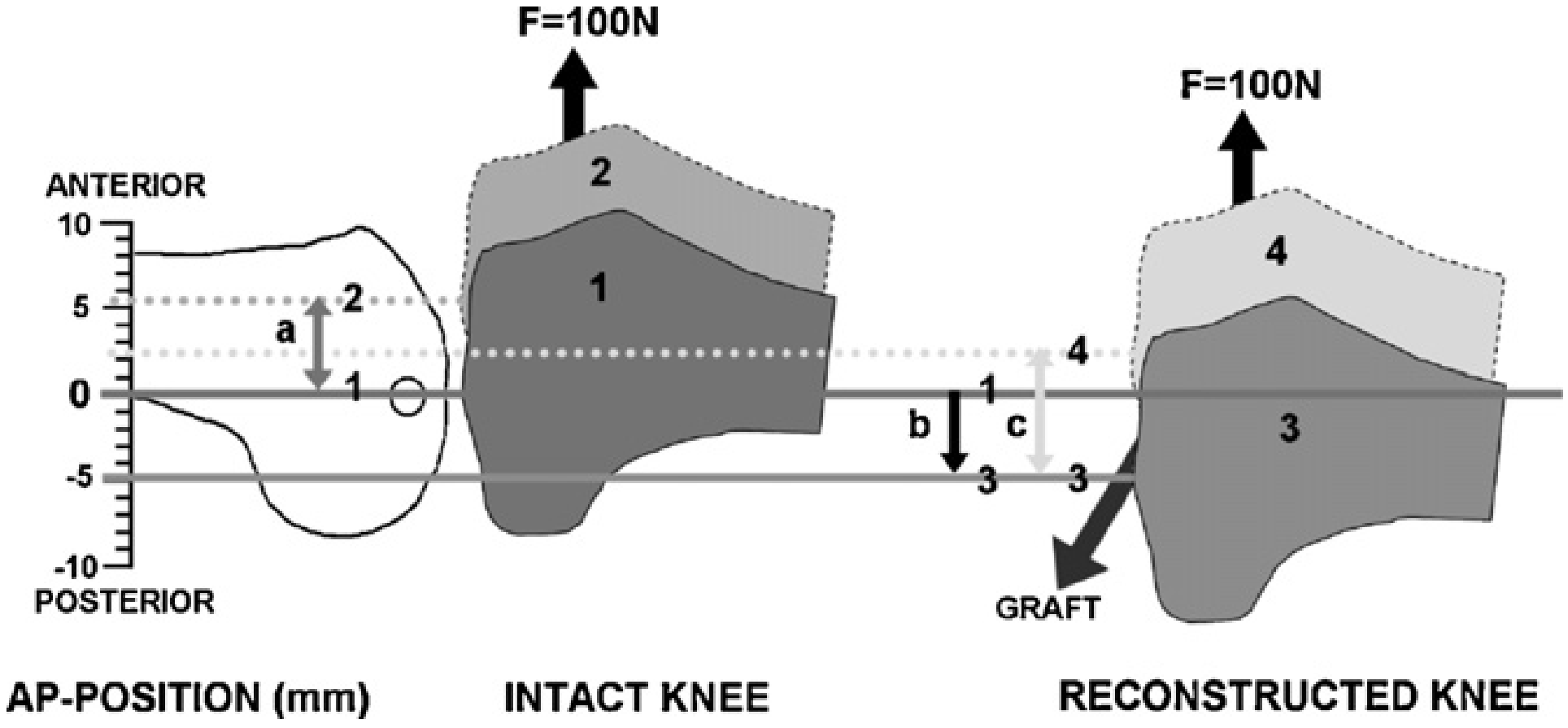

Figure 2. Lateral view of a fixed femur and a moving tibia; 1) The initial anatomic AP-position of the unloaded tibia relative to the fixed femur in the intact knee is defined as 0 mm; 2) An anterior force (100N) applied to the tibia causes an anterior shift relative to the anatomic AP-position, which represents (a) the normal anterior laxity (a=2-1); 3) During graft fixation, the tibia is repositioned resulting in a new position of the unloaded tibia in the reconstructed knee: AP-position after ACL reconstruction. The difference in AP-position between the intact and reconstructed unloaded knee is defined as (b) the AP-error (b=1-3); 4) An anterior force (100N) applied to the tibia in the reconstructed knee, causes an anterior shift relative to the AP-position, which represents (c) the anterior laxity of the reconstructed knee (c=4-3).

tensioning and fixation of the graft. This led to a more posterior tibia position in the unloaded reconstructed knee relative to the position of the unloaded tibia of the intact knee. This posterior translation is referred to as the AP-error of the tibia.

Statistical analysis was performed using SPSS® (12.0.1 for Windows, SPSS Inc., Chicago, IL). For all conditions, the mean anterior laxity in all 6 flexion angles was calculated as an average of all knees. Normal quantile plots were performed and data was tested for normality with the Shapiro Wilk test, significance was set at $P< .05$. The laxities of all separate reconstruction techniques were compared with the laxity of the intact knee with the non-parametric Wilcoxon Signed Rank test. The same was done for the AP-errors of the reconstructed knees to determine if these were significantly different from zero. This study was powered to detect a 1-mm difference in anterior laxity ($\alpha = .05$). To detect differences between the 4 reconstruction techniques, the laxity and AP-error from each reconstruction were also compared to each of the other techniques with the non-parametric Wilcoxon Signed Rank test. Finally, the Friedman Rank Test was performed to determine which technique had the best laxity results over all specimens for a given flexion angle. In each individual knee, the laxity results of all four reconstruction techniques in that flexion angle were ranked, with the smallest laxity value nominated as the best result. This ranking was done for all knees, resulting in an average ranking value for each reconstruction technique in that flexion angle. This procedure was repeated for each of the 6 flexion angles considered.

Table 1 Anterior Laxity of the Tibia in Response to 100 N Anterior Tibial Load (Mean ± SD in mm)

Flexion angle	**ACL reconstructions**					
	ACL intact	**ACL #**	**AM**	**PL**	**ADB**	**SB**
0°	4.9 ± 0.6	8.7 ± 1.8*	5.5 ± 1.5	5.5 ± 2.0	4.7 ± 2.1	6.0 ± 1.0*
15°	6.3 ± 1.5	12.7 ± 3.6*	7.8 ± 1.6	8.0 ± 1.4*†	7.0 ± 1.1‡	8.0 ± 1.4*†
30°	6.9 ± 2.2	14.2 ± 4.1*	7.7 ± 1.6	8.3 ± 2.0*†	7.2 ± 1.5	7.7 ± 1.8
45°	5.5 ± 2.1	11.0 ± 5.4*	7.1 ± 1.3*	7.8 ± 1.7*†‡	6.5 ± 1.1	6.8 ± 2.3
60°	4.7 ± 2.4	10.4 ± 4.1*	6.2 ± 1.5	7.1 ± 2.8*	5.6 ± 1.2	5.9 ± 2.1
90°	3.8 ± 2.3	7.1 ± 3.5*	5.4 ± 2.6*	5.9 ± 2.6*‡	5.2 ± 1.6	4.8 ± 1.8

ACL intact: knee with the intact ACL; ACL #: knee with deficient ACL; AM: anatomic single-bundle reconstruction of the anteromedial graft; PL: Anatomic single-bundle reconstruction of the posterolateral graft; ADB: anatomic double-bundle reconstruction with quadriceps tendon bone graft; SB: single-bundle reconstruction with bonepatellar tendon-bone graft
**P < 0.05 compared with ACL intact; †P < 0.05 compared with ADB; ‡P < 0.05 compared with ISB*

Results

The laxity of the knees with an intact ACL showed a typical pattern as function of flexion, with an increasing anterior laxity from 0° of flexion up to 30° of flexion after which the laxity decreased again (Table 1; Figure 3). The mean laxity in 90° flexion was the smallest over the range of motion tested. However, the effect of flexion angle on the anterior laxity was not statistically significant (P > .05).

In knees with the ACL cut, the tibia translated anteriorly in the unloaded condition. The anterior laxity was significantly increased by a factor of two relative to the intact knee in all flexion angles (P-values ranged between .012 and .025) (Table 1; Figure 4).

The increased anterior laxity after cutting the ACL, was significantly reduced by all reconstruction techniques (Figure 4). The laxity patterns of the reconstructed knees were similar to those of the intact knee. The outcome of the Friedman Rank Test showed that the knees with the double-bundle technique had the smallest anterior laxity in the lower flexion angles: in 0°, 15°, 30° and 45°. The SB technique showed the smallest laxity data in the higher flexion angles 60° and 90°.

The anterior laxity values of the SB reconstructions were higher than in the intact knees. In the positions near extension (0° and 15°), the laxity (1.1 mm and 1.7 mm) was significantly higher than the normal laxity (P = .007 and P = .045 respectively). The differences in the higher flexion range (30°-90°) were small and not significant. In 15°, the laxity of the SB was also significantly higher (1 mm, P = .016) than the laxity of the DB in 15°.

In the knees with the anatomical AM reconstructions, the anterior laxity of 1.6 mm in 45 and 90 degrees of flexion were statistically significantly (P = .038 and P = .030 respectively) higher

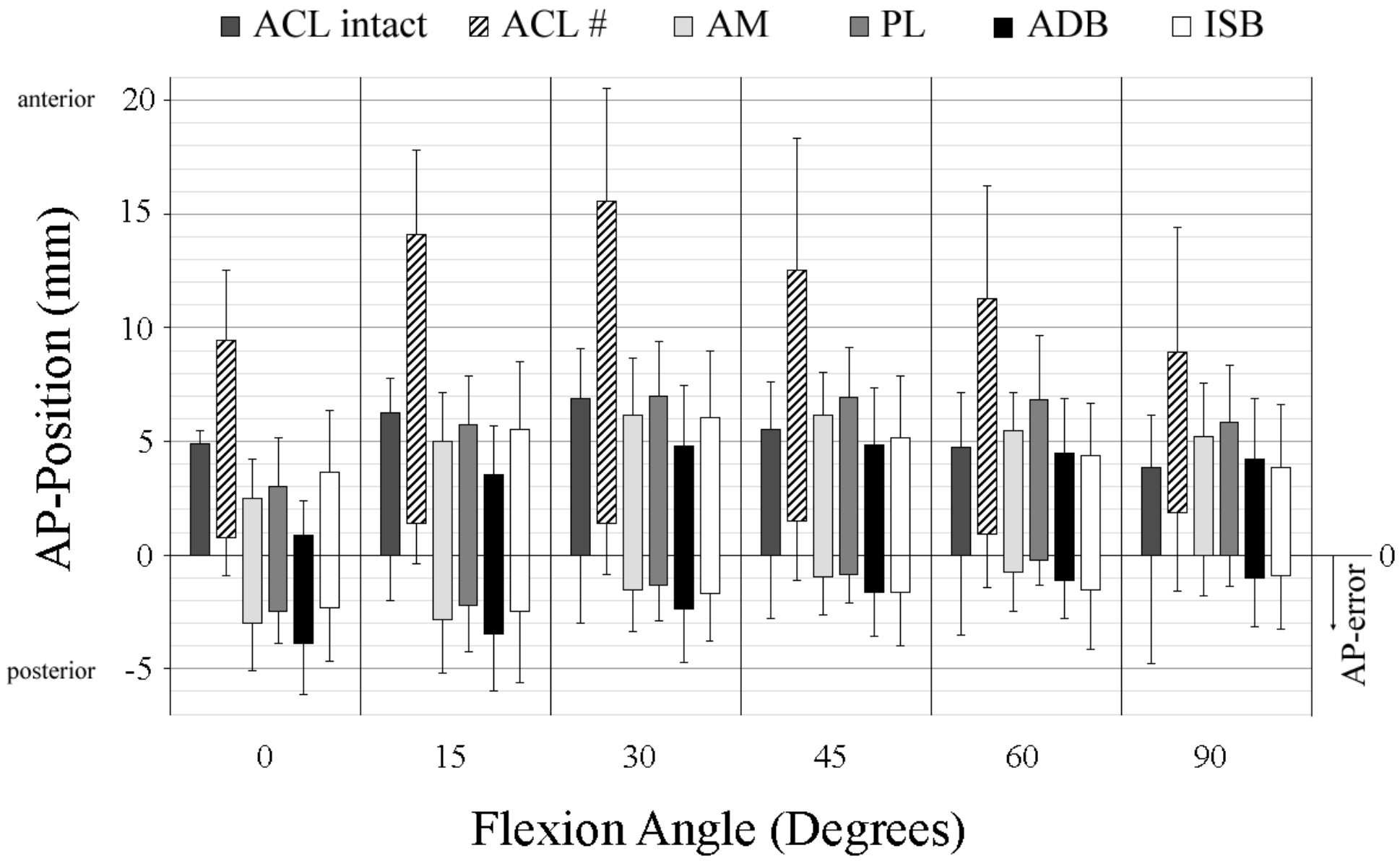

Figure. 3 The mean (±SD) anterior laxity (mm) of the knees (N=8) under 6 conditions in various knee flexion angles.

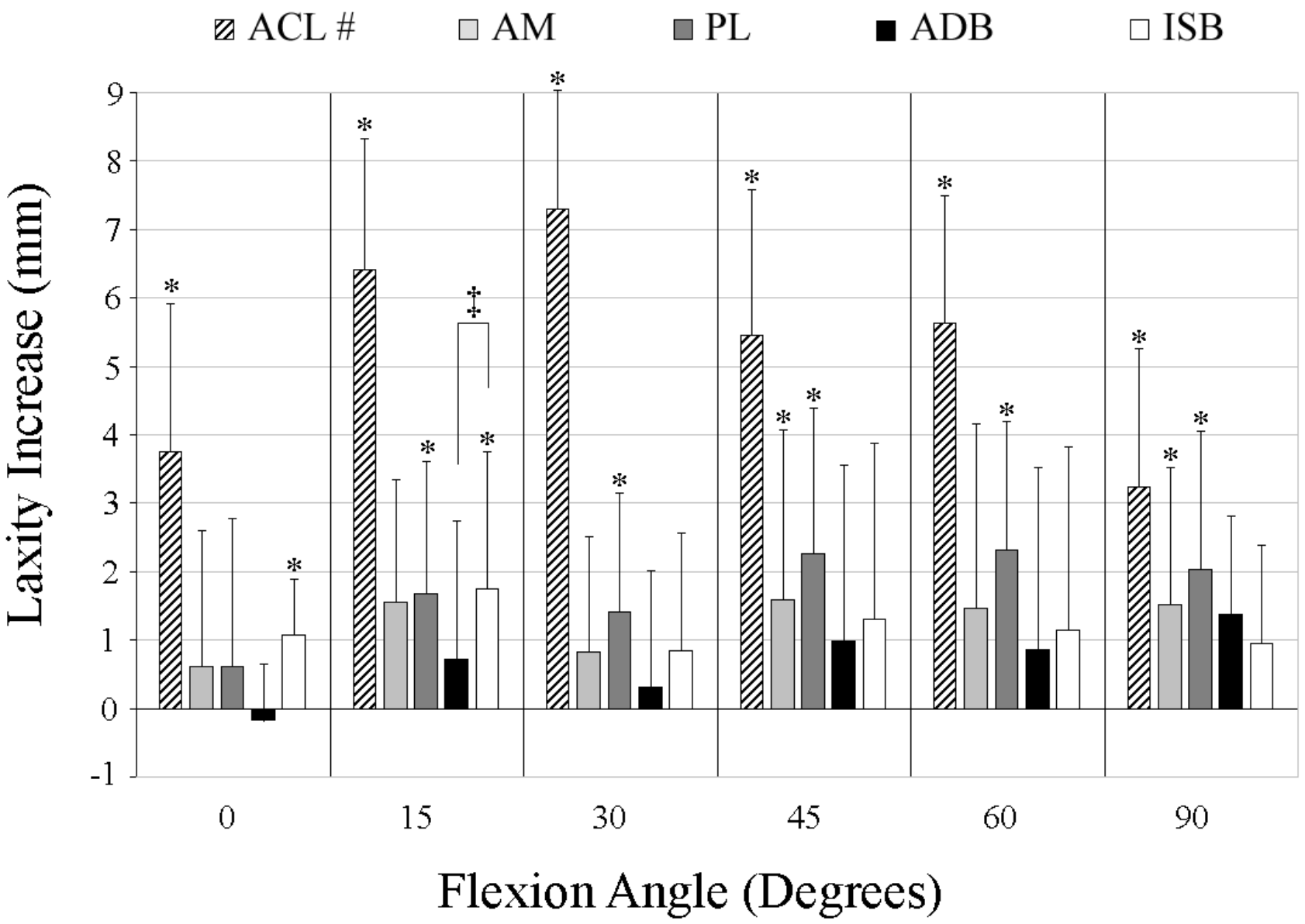

Figure 4. The mean (+SD) anterior laxity increase (in mm) of the tibia of the ACL deficient knees (N=8) and knees with the 4 ACL reconstructions, relative to the knees with intact ACL, in various knee flexion angles.

compared to the intact knees. The anterior laxity increases at 0, 15, 30 and 60°, ranging between 0.6 and 1.5 mm, were not statistically different from the intact laxity.

The anatomic PL reconstructions restored the anterior laxity in 0°; the increase, on average 0.6 mm, did not differ significantly from the laxity of the intact knees (P = .410). In all other angles the laxities were significantly higher than the normal laxity, with an increase ranging between 1.4 to 2.4 mm (60°) (P-values ranged between .023 and .049).

The anatomic DB reconstructions normalised the anterior laxity of the intact knees best over the complete range of motion. In 0° the laxity of the DB was, on average smaller than normal, (4.7 mm the DB technique vs 4.9 mm for the intact ACL), however the difference was not significantly different from zero. In the other angles the DB laxity differed from normal laxity with values between 0.3 mm and 1.4 mm (90°), but the total laxity was not statistically significant different from the intact-ACL laxities.

After every reconstruction, the tibia had a posterior position in the unloaded condition, compared to the intact knee. This AP-error, caused by the fixation of the graft, arose especially in the lower flexion angles, with maximal values for knee extension (Table 2; Figure 3). All techniques caused significant AP-errors in 0° and 15° flexion (P-values ranged between .012 and .036). The anatomic DB and the SB also had a significant AP-error in 30° (P = .017 and P = .042 respectively), the DB also in 45° (P = .045). The AP-errors of the DB technique seemed larger than those of the SB technique (0.7-1.6 mm), but did not differ significantly.

Table 2 Posterior Translation of the Tibia caused by manual repositioning during Fixation (Mean ± SD in mm)

Flexion angle		ACL reconstructions				
	ACL intact	**ACL #**	**AM**	**PL**	**ADB**	**SB**
0°	0	-0.8 ± 1.7	3.0 ± 2.1*	2.5 ± 1.4*	3.9 ± 2.2*	2.3 ± 2.4*
15°	0	-1.4 ± 1.8	2.8 ± 2.4*	2.2 ± 2.0*	3.5 ± 2.5*	2.5 ± 3.1
30°	0	-1.4 ± 2.2	1.5 ± 1.8	1.3 ± 1.6	2.4 ± 2.4*	1.7 ± 2.1
45°	0	-1.5 ± 2.7	1.0 ± 1.7	0.8 ± 1.3	1.7 ± 2.0*	1.7 ± 2.4
60°	0	-0.9 ± 2.3	0.7 ± 1.8	0.2 ± 1.1	1.1 ± 1.7	1.5 ± 2.6
90°	0	-1.8 ± 3.5	0.1 ± 2.0	0.0 ± 1.4	1.1 ± 1.0	0.9 ± 2.3

ACL #: deficient ACL; AM: anteromedial graft; PL: posterolateral graft; ADB: anatomic double-bundle reconstruction; SB: single-bundle reconstruction
**P < 0.05 compared with ACL intact*

Discussion

In this study the anterior laxity in normal knees and in knees with several differently placed grafts was evaluated. With this experiment, the hypothesis was tested that a double-bundle reconstruction with two grafts positioned and tensed at both its anatomical attachment centers, thus combining the functionality of both bundles, would be able to mimic the intact ACL functioning over the complete range of motion.

The results of this study were in line with those of other studies [22,42,44]. The intact knee was most stable in extension and in 90° of flexion and most lax at a flexion angle of 30° [18,35,42,44,45]. In knees where the ACL was cut, anterior laxity was significantly increased. The amount of increase was somewhat smaller, ca. 35%, than in other studies, most likely caused by the use of a lower anterior load (100 N) compared to the other studies (134 N) [22,42]. The anatomically placed DB reconstruction showed anterior laxity values closest to those observed in the intact knee. In contrast, none of the single-bundle grafts, SB, AM or PL, were capable of restoring the anterior laxity in all flexion angles [35,45]. The AM reconstructions did not restore the normal anterior laxity in 45° and 90° flexion [22], and the PL reconstructions failed in restoring the normal values at higher flexion angles [33,45]. The SB reconstructions could not normalize the anterior laxity in 0° and 15° flexion [18,42,44]

The testing methodology revealed a posterior translation of the unloaded tibia in all reconstructed knees relative to the tibial position in intact knees. This AP-error has previously been reported in other in vitro reconstruction studies [7,11,14,26-28]. In agreement with those studies, the reconstructed knees showed the largest AP-errors in extension. In the higher flexion angles the AP-error was smaller since the posterior cruciate ligament restrained the posterior tibial translation [26]. The AP-error can be explained by the graft forces generated during graft tensioning and subsequent fixation. The clinical consequences are unknown. In only one clinical study, the tibial position relative to the femur was measured at different post-operative times relative to the pre-operative ACL-deficient condition [40]. This study showed that the tibia may considerably shift anteriorly during the post-operative time. It was not clear what the influence of this anterior repositioning was on the clinical anterior laxity results or physiological joint motion. Further in vivo studies should be performed to determine the consequences of intra-operative AP-errors on postoperative function after the ligament remodeling period. In the meantime, it is important to be aware that tension protocols can cause an AP-error, which places the tibia in a non-anatomic position relative to the femur. Both flexion angle and graft tension influence the tibial positioning [7,14,26,28]. Besides that, the relative preoperative anterior position of the tibia and the reduction of the subluxation before graft tensioning plays a role. Höher proposed a standardized force of reduction since this force influences the laxity outcomes [18]. In conclusion, one can apply different strategies to control the intra-operative AP-error.

The initial anatomic AP-position of the unloaded tibia in the knees with the intact ACL served as the starting position (0 mm). The lower limit of each bar represents the mean AP-positions (-SD) of the unloaded tibia. The upper limit of each bar represents the mean AP-positions (+SD) of the 100N-loaded tibia. The difference between these two tibial positions, i.e. the length of the bar, is the anterior laxity. The difference between the AP-position of the unloaded intact tibia and the posterior tibial position in the unloaded reconstructed knees, the negative part of the bar, is the AP-error.

The AM graft was fixated in 90° with 15N. It was observed during the conditioning cycles that the tension registered at the pretension spring device, in the grafts increased near extension. This tension increase in an AM graft, when moving the knee towards extension was also reported by others [12,31,48] and may explain the normalized laxity values in the lower flexion angles. The applied tension protocol was not sufficient to normalize the laxity in the higher angles. Increasing the tension does not seem to be the solution as May et al found that graft fixation with 44 N in 90° resulted in laxity results smaller than normal, accompanied with a very high in-situ force and a large tibial posterior displacement [27]. Hence, it appears that 90° of flexion is not the optimal knee angle for tensioning the graft. In addition, Miura also reported the overload of the AM graft near extension if the graft was fixated in 60° of flexion [31]. Vercillo found that fixation in 15° knee flexion resulted in lower forces compared to the forces in the intact AM bundle over the complete range of motion [41]. Hence, it appears to be difficult to establish an adequate tensioning protocol which is perhaps caused by the finding in this study that ACL-reconstructive forces are affected not only by flexion angle and tension force but also by tibial-femoral AP-errors which are ignored in most contemporary tensioning protocols.

The PL graft normalized the laxity only for knee extension, despite the fixation in 15° knee flexion which seems to be the most appropriate fixation angle [31,41]. The initial graft tension was somewhat low compared to other studies [31,41,45]. Since the tension on PL grafts increases towards extension [4,31,46], our tension protocol was sufficient to restore laxity for knee extension. A higher tensile force at 15° knee flexion can thus be advocated, which will result in laxity values closer to normal in 15° and 30°.

Obviously there are several limitations to the current study. It is an in vitro study with specimens of donors of relatively high age. Furthermore, some questions remain unanswered in this study, because we measured the anterior laxity with the rotation fixed, although functional stability also includes a rotational component, as is seen in pivot-shift tests and dynamic analyses [36]. However, by fixation of the internal-external rotation to a preset value, we were able to solely measure effects on anterior laxity, without interference of changes in axial rotations. We accepted that this went at a cost relative to anatomical reality. From other studies, it is clear that there is a contribution of the PL graft in restoring the stability in rotational direction [13,20,43-45,47]. One of the study aims was to show that the PL, tensed in 20° of flexion, also contributed significantly to the anterior laxity results in the lower flexion angles. The results were in line with others [22,45].

Conclusion

Although a PL reconstruction tensed with 15 N in 20° restored normal anterior laxity only in 0° and an AM reconstruction tensed with 15 N in 90° failed in restoring normal anterior laxity in 45° and 90°, the anatomic double-bundle technique, positioned with CAS, produced anterior laxity values close to normal over the complete range of motion. However, this was accompanied with a posterior tibial-femoral AP-position. Therefore, additional studies are required to further improve the tensioning protocol of anatomic double-bundle reconstructions, which considers the tension force and flexion angle, but also the tibial-femoral AP-position.

Acknowledgements The authors would like to thank Willem van de Wijdeven and Huub Peeters for their contributions to this work. This study was funded by grant 99-W14 from the AO Research Fund, Association for Osteosynthesis Foundation, Switzerland.

Conflict of interest The authors declare that there are no conflicts of interest.

References

1. Amis AA, Dawkins GP (1991) Functional anatomy of the anterior cruciate ligament. Fibre bundle actions related to ligament replacements and injuries. J Bone Joint Surg Br 73:260-267.
2. Amis AA, Jakob RP (1998) Anterior cruciate ligament graft positioning, tensioning and twisting. Knee Surg Sports Traumatol Arthrosc 6 Suppl 1:S2-S12.
3. Arnold MP, Kooloos J, van KA (2001) Single-incision technique misses the anatomical femoral anterior cruciate ligament insertion: a cadaver study. Knee Surg Sports Traumatol Arthrosc 9:194-199.
4. Arnold MP, Verdonschot N, van KA (2005) ACL graft can replicate the normal ligament's tension curve. Knee Surg Sports Traumatol Arthrosc 13:625-631.
5. Barink M, Meijerink H, Verdonschot N, van KA, De Waal MM (2007) Asymmetrical total knee arthroplasty does not improve patella tracking: a study without patella resurfacing. Knee Surg Sports Traumatol Arthrosc 15:184-191.
6. Blankevoort L, Huiskes R, de Lange A (1988) The envelope of passive knee joint motion. J Biomech 21:705-720.
7. Brady MF, Bradley MP, Fleming BC, Fadale PD, Hulstyn MJ, Banerjee R (2007) Effects of initial graft tension on the tibiofemoral compressive forces and joint position after anterior cruciate ligament reconstruction. Am J Sports Med 35:395-403.
8. Colombet P, Robinson J, Christel P, Franceschi JP, Djian P, Bellier G et al. (2006) Morphology of anterior cruciate ligament attachments for anatomic reconstruction: a cadaveric dissection and radiographic study. Arthroscopy 22:984-992.
9. Crawford C, Nyland J, Landes S, Jackson R, Chang HC, Nawab A et al. (2007) Anatomic double bundle ACL reconstruction: a literature review. Knee Surg Sports Traumatol Arthrosc 15:946-964.
10. Edwards A, Bull AM, Amis AA (2007) The attachments of the anteromedial and posterolateral fibre bundles of the anterior cruciate ligament : Part 2: Femoral attachment. Knee Surg Sports Traumatol Arthrosc 16:29-36.
11. Elmans L, Wymenga A, van KA, van der WP, Mommersteeg TJ, Blankevoort L (2003) Effects of twisting of the graft in anterior cruciate ligament reconstruction. Clin Orthop Relat Res 409:278-284.
12. Friederich NF, O'Brien WR (1998) Anterior cruciate ligament graft tensioning versus knee stability. Knee Surg Sports Traumatol Arthrosc 6 Suppl 1:S38-S42.
13. Gabriel MT, Wong EK, Woo SL, Yagi M, Debski RE (2004) Distribution of in situ forces in the anterior cruciate ligament in response to rotatory loads. J Orthop Res 22:85-89.
14. Gertel TH, Lew WD, Lewis JL, Stewart NJ, Hunter RE (1993) Effect of anterior cruciate ligament graft tensioning direction, magnitude, and flexion angle on knee biomechanics. Am J Sports Med 21:572-581.
15. Girgis FG, Marshall JL, Monajem A (1975) The cruciate ligaments of the knee joint. Anatomical, functional and experimental analysis. Clin Orthop Relat Res 106:216-231.
16. Harner CD, Baek GH, Vogrin TM, Carlin GJ, Kashiwaguchi S, Woo SL (1999) Quantitative analysis of human cruciate ligament insertions. Arthroscopy 15:741-749.
17. Hefzy MS, Grood ES, Noyes FR (1989) Factors affecting the region of most isometric femoral attachments. Part II: The anterior cruciate ligament. Am J Sports Med 17:208-216.
18. Hoher J, Kanamori A, Zeminski J, Fu FH, Woo SL (2001) The position of the tibia during graft fixation affects knee

kinematics and graft forces for anterior cruciate ligament reconstruction. Am J Sports Med 29:771-776.

19. Howell SM (1998) Principles for placing the tibial tunnel and avoiding roof impingement during reconstruction of a torn anterior cruciate ligament. Knee Surg Sports Traumatol Arthrosc 6 Suppl 1:S49-S55.
20. Ishibashi Y, Tsuda E, Fukuda A, Tsukada H, Toh S (2008) Stability evaluation of single-bundle and double-bundle reconstruction during navigated ACL reconstruction. Sports Med Arthrosc 16:77-83.
21. Larson RV, Metcalf MH (1999) Significance of ligament placement, tensioning and fixation in ligament reconstruction. Tech Orthop 14:43-51.
22. Loh JC, Fukuda Y, Tsuda E, Steadman RJ, Fu FH, Woo SL (2003) Knee stability and graft function following anterior cruciate ligament reconstruction: Comparison between 11 o'clock and 10 o'clock femoral tunnel placement. Arthroscopy 19:297-304.
23. Luites JW, Wymenga AB, Blankevoort L, Kooloos JG (2007) Description of the attachment geometry of the anteromedial and posterolateral bundles of the ACL from arthroscopic perspective for anatomical tunnel placement. Knee Surg Sports Traumatol Arthrosc 15:1422-1431.
24. Luites JW, Wymenga AB, Blankevoort L, Kooloos JG, Verdonschot N (2011) Development of a femoral template for computer-assisted tunnel placement in anatomical double-bundle ACL reconstruction. Computer Aided Surgery 16: 11–21.
25. Mae T, Shino K, Matsumoto N, Hamada M, Yoneda M, Nakata K (2007) Anatomical two-bundle versus Rosenberg's isometric bi-socket ACL reconstruction: a biomechanical comparison in laxity match pretension. Knee Surg Sports Traumatol Arthrosc 15:328-334.
26. Mae T, Shino K, Nakata K, Toritsuka Y, Otsubo H, Fujie H (2008) Optimization of graft fixation at the time of anterior cruciate ligament reconstruction. Part I: effect of initial tension. Am J Sports Med 36:1087-1093.
27. Mae T, Shino K, Nakata K, Toritsuka Y, Otsubo H, Fujie H (2008) Optimization of graft fixation at the time of anterior cruciate ligament reconstruction. Part II: effect of knee flexion angle. Am J Sports Med 36:1094-1100.
28. Melby A, III, Noble JS, Askew MJ, Boom AA, Hurst FW (1991) The effects of graft tensioning on the laxity and kinematics of the anterior cruciate ligament reconstructed knee. Arthroscopy 7:257-266.
29. Meredick RB, Vance KJ, Appleby D, Lubowitz JH (2008) Outcome of Single-Bundle Versus Double-Bundle Reconstruction of the Anterior Cruciate Ligament: A Meta-Analysis. Am J Sports Med.
30. Miller MD, Olszewski AD (1997) Cruciate ligament graft intra-articular distances. Arthroscopy 13:291-295.
31. Miura K, Woo SL, Brinkley R, Fu YC, Noorani S (2006) Effects of knee flexion angles for graft fixation on force distribution in double-bundle anterior cruciate ligament grafts. Am J Sports Med 34:577-585.
32. Mochizuki T, Muneta T, Nagase T, Shirasawa S, Akita KI, Sekiya I (2006) Cadaveric knee observation study for describing anatomic femoral tunnel placement for two-bundle anterior cruciate ligament reconstruction. Arthroscopy 22:356-361.
33. Mommersteeg TJ, Huiskes R, Blankevoort L, Kooloos JG, Kauer JM (1997) An inverse dynamics modeling approach to determine the restraining function of human knee ligament bundles. J Biomech 30:139-146.
34. Morgan CD, Kalman VR, Grawl DM (1995) Definitive landmarks for reproducible tibial tunnel placement in anterior cruciate ligament reconstruction. Arthroscopy 11:275-288.
35. Musahl V, Plakseychuk A, VanScyoc A, Sasaki T, Debski RE, McMahon PJ et al. (2005) Varying femoral tunnels between the anatomical footprint and isometric positions: effect on kinematics of the anterior cruciate ligament-reconstructed knee. Am J Sports Med 33:712-718.
36. Ristanis S, Stergiou N, Patras K, Vasiliadis HS, Giakas G, Georgoulis AD (2005) Excessive tibial rotation during high-demand activities is not restored by anterior cruciate ligament reconstruction. Arthroscopy 21:1323-1329.
37. Sakane M, Fox RJ, Woo SL, Livesay GA, Li G, Fu FH (1997) In situ forces in the anterior cruciate ligament and its bundles in response to anterior tibial loads. J Orthop Res 15:285-293.
38. Sidles JA, Larson RV, Garbini JL, Downey DJ, Matsen FA, III (1988) Ligament length relationships in the moving knee. J Orthop Res 6:593-610.

39. Staubli HU, Schatzmann L, Brunner P, Rincon L, Nolte LP (1996) Quadriceps tendon and patellar ligament: cryosectional anatomy and structural properties in young adults. Knee Surg Sports Traumatol Arthrosc 4:100-110.
40. van Kampen A, Wymenga AB, van der Heide HJ, Bakens HJ (1998) The effect of different graft tensioning in anterior cruciate ligament reconstruction: a prospective randomized study. Arthroscopy 14:845-850.
41. Vercillo F, Woo SL, Noorani SY, Dede O (2007) Determination of a safe range of knee flexion angles for fixation of the grafts in double-bundle anterior cruciate ligament reconstruction: a human cadaveric study. Am J Sports Med 35:1513-1520.
42. Woo SL, Kanamori A, Zeminski J, Yagi M, Papageorgiou C, Fu FH (2002) The effectiveness of reconstruction of the anterior cruciate ligament with hamstrings and patellar tendon . A cadaveric study comparing anterior tibial and rotational loads. J Bone Joint Surg Am 84-A:907-914.
43. Yagi M, Kuroda R, Nagamune K, Yoshiya S, Kurosaka M (2007) Double-bundle ACL reconstruction can improve rotational stability. Clin Orthop Relat Res 454:100-107.
44. Yagi M, Wong EK, Kanamori A, Debski RE, Fu FH, Woo SL (2002) Biomechanical analysis of an anatomic anterior cruciate ligament reconstruction. Am J Sports Med 30:660-666.
45. Yamamoto Y, Hsu WH, Woo SL, Van Scyoc AH, Takakura Y, Debski RE (2004) Knee stability and graft function after anterior cruciate ligament reconstruction: a comparison of a lateral and an anatomical femoral tunnel placement. Am J Sports Med 32:1825-1832.
46. Zantop T, Diermann N, Schumacher T, Schanz S, Fu FH, Petersen W (2008) Anatomical and nonanatomical double-bundle anterior cruciate ligament reconstruction: importance of femoral tunnel location on knee kinematics. Am J Sports Med 36:678-685.
47. Zantop T, Herbort M, Raschke MJ, Fu FH, Petersen W (2007) The role of the anteromedial and posterolateral bundles of the anterior cruciate ligament in anterior tibial translation and internal rotation. Am J Sports Med 35:223-227.
48. Zavras TD, Race A, Amis AA (2005) The effect of femoral attachment location on anterior cruciate ligament reconstruction: graft tension patterns and restoration of normal anterior-posterior laxity patterns. Knee Surg Sports Traumatol Arthrosc 13:92-100.
49. Zavras TD, Race A, Bull AM, Amis AA (2001) A comparative study of ‘isometric’ points for anterior cruciate ligament graft attachment. Knee Surg Sports Traumatol Arthrosc 9:28-33.

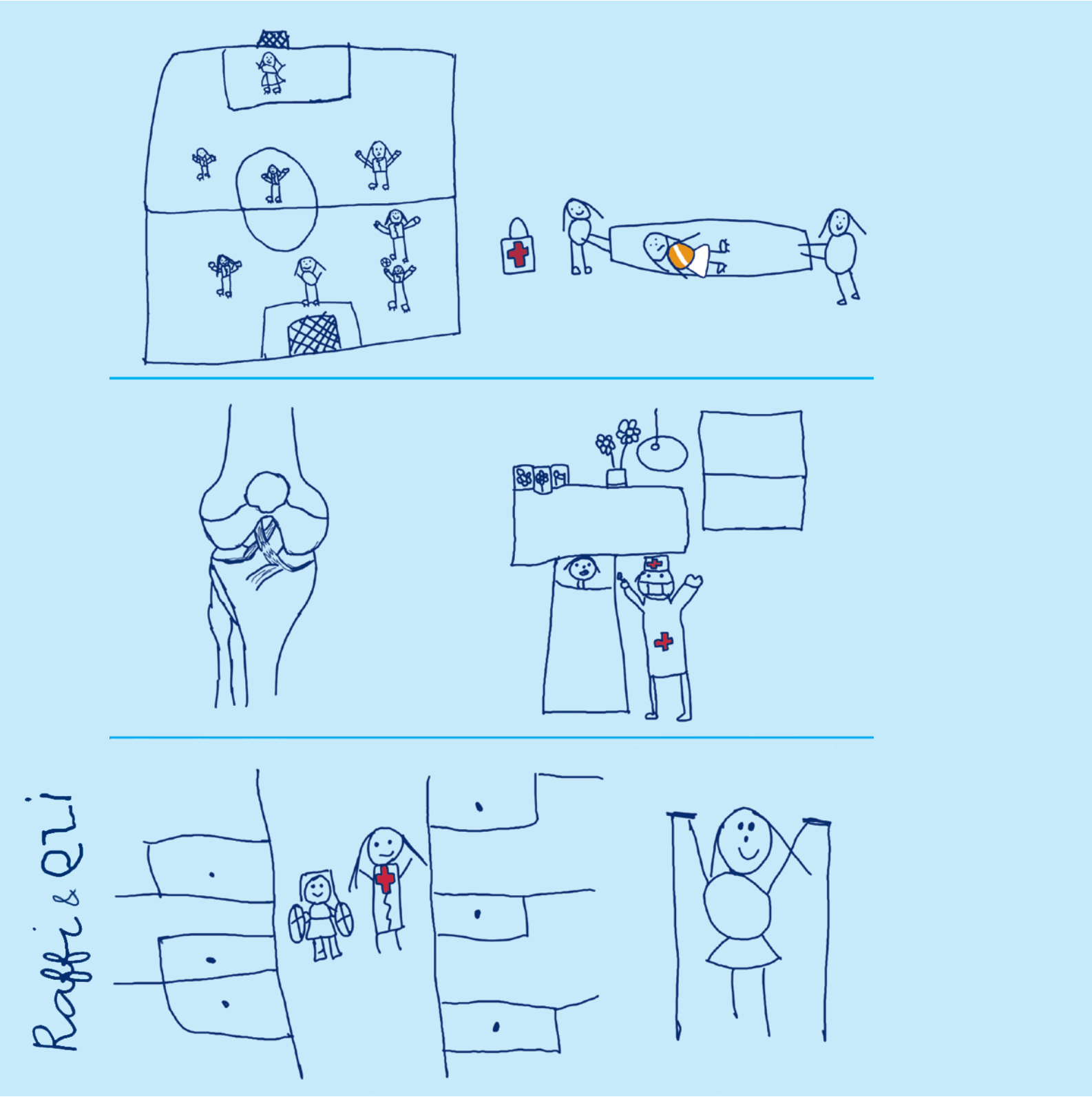
Raffi & Eli

CHAPTER 8

Femoral guides for tunnel positioning in ACL reconstruction in literature: an historical overview

Joan W.H. Luites and Nico Verdonschot

Abstract

Purpose

A crucial factor in the success rate of ACL reconstruction surgery is the placement and drilling of the femoral tunnel. Various tunnel placement concepts have passed through history. Femoral guides have been developed, to achieve accurate tunnel positions according to a technical concept. The purpose of this study was to describe the history of these devices and explore the relations of these guides with the ACL reconstruction concepts and the evolution of both in course of time. We also reviewed the accuracy of guides.

Methods

A literature search to determine papers describing femoral guides was performed, resulting in 22 publications describing 22 guides. Through qualitative analysis, various categories of surgical concepts influencing the guide design, were determined, to which the guides were assigned. The results of studies validating femoral guides were analysed and overall conclusions were summarized.

Results

Two main groups, based on the placement procedure, can be distinguished: 1) surgeon oriented guides which placement is determined by the surgeon and 2) aiming devices which placement is determined through its design and the connection to the anatomical shape of the intercondylar notch. Within these groups, two subgroups have been made, based on the joint entry of the instruments: A) the rear entry approach, with drilling from outside the joint inwards and B) the inside out technique with drilling starting inside the notch. Finally, the guides have been assigned to the isometrical or anatomical concept. The validation studies demonstrated the increase of accurate tunnel placement with guides relative to free hand placement. The endo femoral aimer (EFA) seems insufficient for anatomical tunnel placement.

Conclusion

Multiple guides have been developed, facilitating the various goals and concepts in femoral tunnel placement and following the evolution of the surgical concepts. The EFA influenced the popularity of the isometric concept largely. Nowadays, it is still in use, through the anteromedial portal, for anatomical tunnel placement, with various results. Newly developed anatomical guides should be validated in future to determine their accuracy.

Introduction

The cruciate ligaments structures of the knee have a long history, first mentioned in the ancient Egyptian medical papyrus rolls (3000 BC). Hippocrates (460–370 BC) described the results of ligament pathology and Claudius Galen (129-199 AD) named the structures “ligament genu cruciata” [29, 41]. In 1836, the Weber brothers described and drew the different bundles and tension patterns of the ligaments. The first clinical case of rupture of the anterior cruciate ligament (ACL) was described in 1837 by Adams [2]. Mayo Robson performed the first surgery, repairing both anterior and posterior cruciate ligaments, in 1895 [58]. In 1913, Grekow performed the first intra-articular reconstruction for both ruptured cruciate ligaments. To achieve this, he drilled holes in the femur, through which he routed free preparated fascia latae tissue, graft material replacing the ligaments. The ends were stitched against the ligament remnants on the tibia [38]. Hey Groves was the first to publish a complete ACL reconstruction in 1917 [40]. He drilled a tunnel through the femoral condyle to reposition the proximal part of the fascia latae tendon as an ACL replacement in the femoral intercondylar notch. In 1938, Palmer described the treatment of ruptured cruciate ligaments from the superior insertion, leading sutures through double femoral canals (Figure 1). These canals had to be drilled with great precision. For this purpose he constructed a drill adjuster, the first described device to facilitate femoral canal placement and drilling (Figure 2) [68]. Only after 30 years, in 1968, an imitation of Palmer’s idea of a drill guide was published by Lam [47]. Since then, multiple femoral guides have been developed.

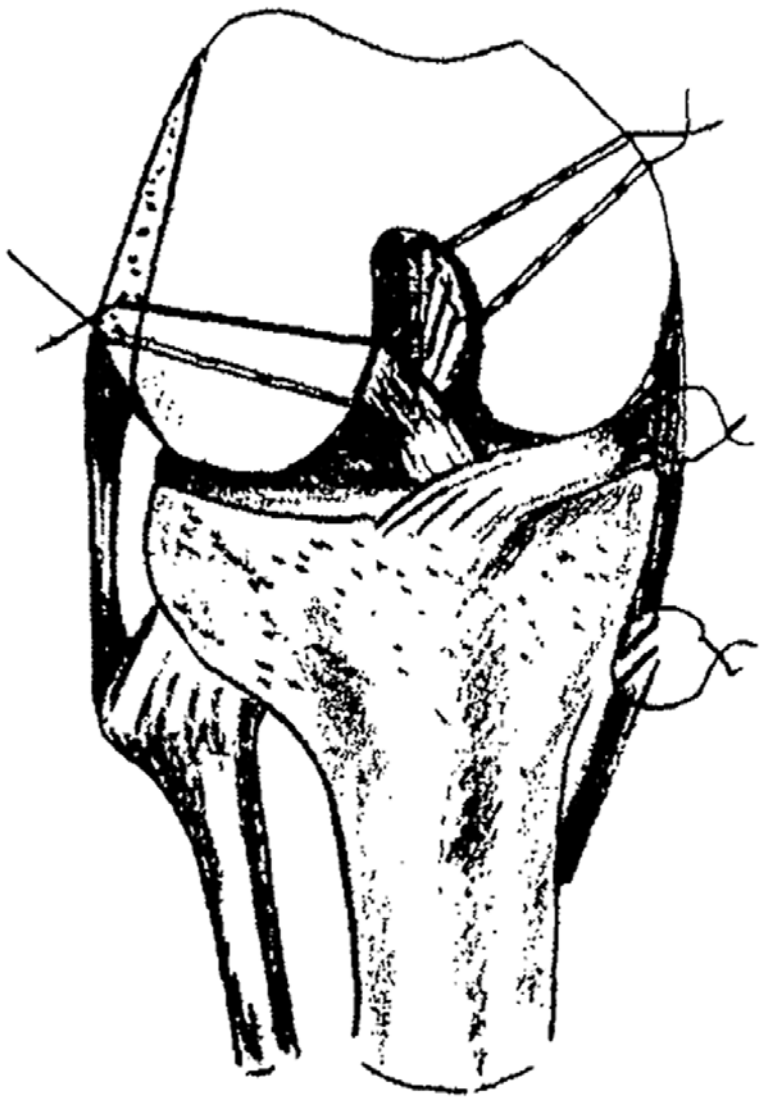

Figure 1. Both crucial ligaments fixated with silk sutures through two femoral canals. (From: Palmer 1938) [68]

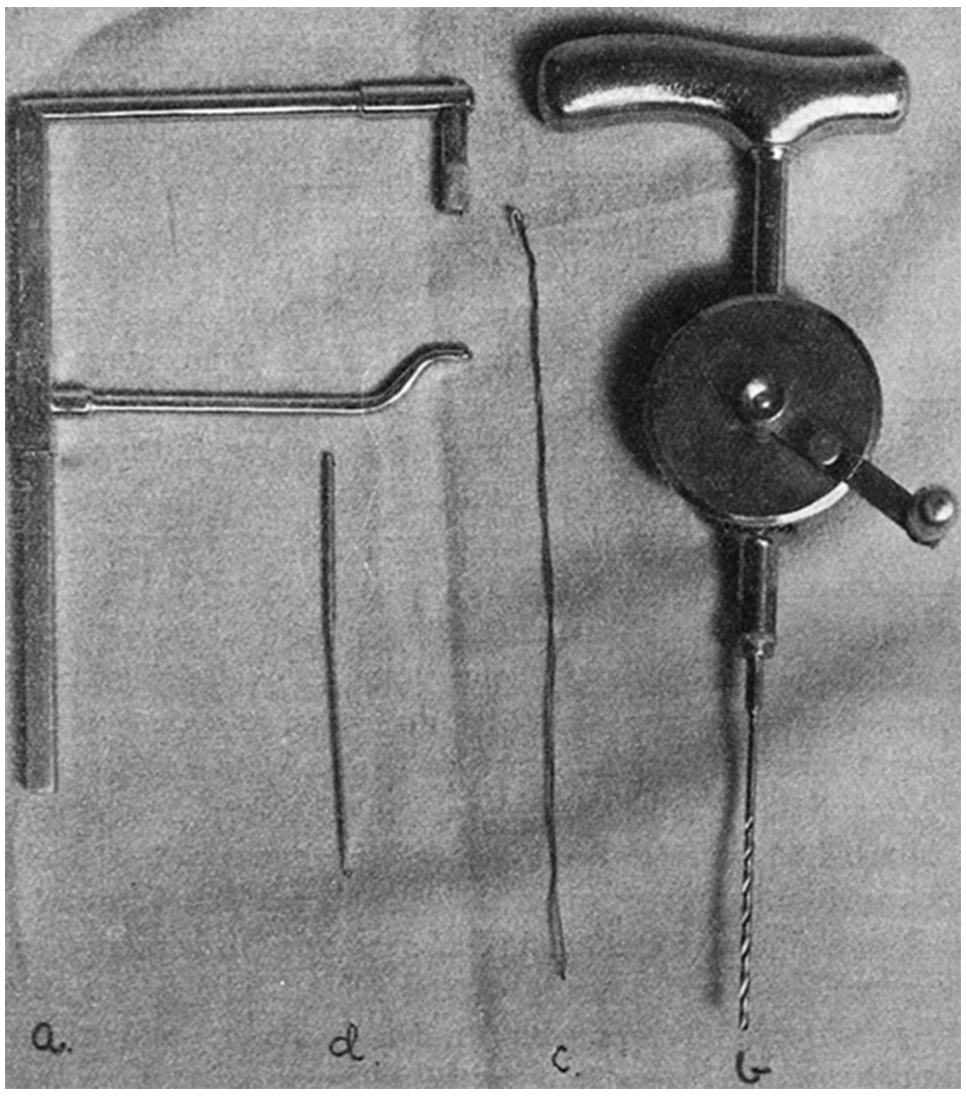

Figure 2. Drill adjuster (a) and drill (b) developed by Palmer. (From: Palmer 1938) [68]

The femoral guides facilitate the surgeon in femoral tunnel placement according to the surgical concept of the ACL reconstruction. Various concepts for ACL reconstruction and in particular femoral graft placement have been developed, described and promoted in the history, which, in the meanwhile, spans over a century. The purpose of this paper is to take a closer look at the guides and their concepts, to discover the relations with the evolution of the strategies of ACL reconstruction throughout history. We also reviewed the accuracy of guides, since validation of the guides is necessary to determine its usefulness.

Methods

Surgical concepts and drill designs

A literature search to determine femoral guides was performed using the PubMed database, the Cochrane Collaboration Library and the Google search engine. The following search terms were used, “anterior cruciate ligament”, “guide”, “aiming”, “device”, “instrument’, “drill”, “tunnel”, “positioning”, “placement” and “location”. The search was performed between March 2015, and November 15, 2015, while being limited to articles written in English, German and French. Broad search query terms were used to identify all possibly applicable studies. Inclusion criteria included all articles that described a guiding or aiming device for femoral tunnel placement. The reference lists of the included studies were reviewed to search for additional articles that may have been missed on the initial searches. Articles missed through the search, but already known and describing a femoral guide, were also included.

Multiple femoral guides and devices were found, described in patents, however, only if a guide was described in a publication found in the PubMed database or the Cochrane Collaboration Library, it was included in the analysis. This resulted in 22 publications, describing 22 various guides developed between papers 1938 and 2015 (Table 1) [7, 11, 18, 23, 31, 37, 39, 43, 46–48, 50, 52, 57, 60, 66, 68, 70, 71, 77, 80, 82]. A guide recently developed and tested research group was also included

Next, a qualitative analysis was performed. The rich history of ACL-reconstruction surgery methods was reviewed to determine the various surgical concepts of femoral tunnel placement. The guides were analyzed to define the concepts influencing the designs. Finally, the guides were divided in categories based on these concepts.

Validation

It is important to know how accurate a guide positions the femoral tunnel. We selected the studies validating femoral guides, resulting in an overview of the results of 16 studies (one with unpublished data) (Table 2) [1, 9, 17, 28, 30–33, 60, 72, 76, 78, 81–83]. These results were analysed and overall conclusions described.

Results

Surgical concepts

Reviewing the rich history of ACL reconstruction surgery methods, we have identified five main aspects in the concepts relative to femoral tunnel placement (Table 1):

Table 1 Anterior Laxity of the Tibia in Response to 100 N Anterior Tibial Load (Mean ± SD in mm)

GUIDES	A	B	C	D	E	F	G	H	I	J		VS†
Palmer 1938 [68]	+		+		+		+		+			
Lam 1968 [47]		+	+		+		+	+		+[a]	[a] Dental scaler determined position [20]	
Stewart 1969 [77]		+	+		+		+		+			
Rhinelander 1970 [71]		+	+		+		+		+			
Theve 1975 [80]	+		+		+		+		+			
Eriksson 1976 [23]	+	+	+				+		+			
Lindstrand 1982 [48]	+	+	+				+		+			
Hewson 1983 [39]	+		+				+[b]	+[b]	+		[f] H=G ACL fibers are isometric	
Odensten 1986 [66]	+	+[c]			+	+[d]	+[d]		+		[c] Mini-arthrotomy [d] H=G: central ACL fibers are isometric [67]	[32, 66]
Beyer 1988 [11]	+		+[e]		+	+[f]	+[f]	+			[e] Transtibial [f] H=G [67]	
Kariya 1989 [43]		+		+	+	+		+	+			
Bassi 1990 [7]		+	+	+	+	+		+	+			
Mattheck 1991 [57]		+	+			+		+		+[g]	[g] Plastic circle determined position	
Raunest 1991 [70]		+	+[h]		+			+		+[i]	[h] Mini-arthrotomy [i] Isometer determined position	
Marans 1992 [52]		+	+[j]	+	+	+		+		+	[j] Mini-arthrotomy	#
Hernandez 1993 [37]		+	+	+	+	+		+	+			
Laboureau 1997 [46]		+		+		+	+			+[k]	[k] Adjustable according to quadrant method [10]	
Milankov 2000 [60]		+		+		+	+			+[l]	[l] Adjustable according to quadrant method [10]	[60]
Christel 2008 [18]		+		+		+	+			+[m]	[m] Dependent to position AM-tunnel	
Lubowitz 2009 [50]		+		+		+	+			+		
Gelber 2012 [31]		+		+		+	+		+			[31]
Watanabe 2015 [82]		+		+		+	+		+			[82]
Luites 2015		+		+		+	+			+		‡

Femoral tunnel placement concepts: A) Suture canals vs B) graft tunnel; C) arthrotomy vs D) arthroscopy; E) Outside in approach vs F) Inside out approach; G) anatomical vs H) isometrical; I) Surgeon oriented drill guide vs J) Aiming device. †Validation Studies; # [9, 17, 28, 30, 31, 61, 75, 79, 80, 83, 85]; ‡ (Luites et al, unpublished data 2015).

- Drilling and/or placement of suture canals or a femoral tunnel
- Arthrotomy or arthroscopical surgery
- Rear entry (outside in) or inside out drilling
- Anatomical or isometrical placement
- Surgeon oriented guides or aiming devices

Suture canals vs femoral tunnel

Various techniques have been developed to route graft material in the joint. In relation to drill guides facilitating femoral tunnel drilling, two variations are seen. Small bore canals were drilled to pass sutures attached to the graft, mostly in the early days (Figure 1, Figure 3) [23, 68]. The other method is the drilling of a larger femoral tunnel through the condyle, introduced by Grekow [38]. This method became the most commonly used technique.

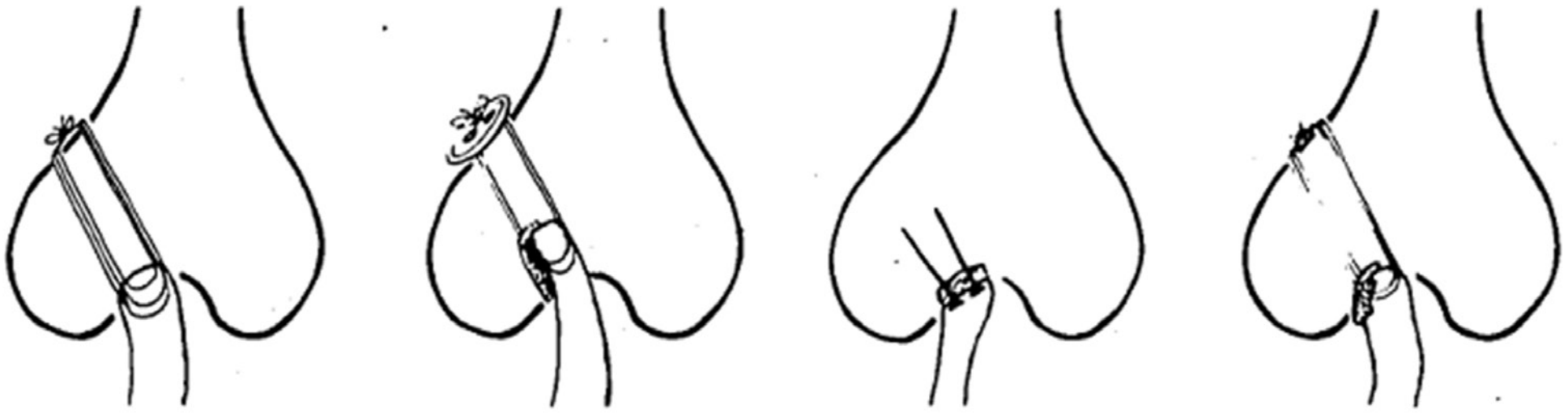

Figure 3. Four modifications from Eriksson of the Jones procedure, using the medial part of the patellar tendon. From left to right: A ligament flap without bone is attached to the femur with sutures pulled through two small canals. The ligament flap with a piece of patellar bone is pulled into one big femoral tunnel, with two sutures pulled through small canals and tied over a button. The ligament flap with a piece of patellar bone is attached to the femur with one or two small Palmer nails. The ligament flap with a piece of patellar bone is attached to the femur with sutures pulled through two small canals. (With kind permission from Wolters Kluwer Health: Eriksson, 1976) [23]

Arthrotomy vs arthroscopy

Until the eighties, surgeries to reconstruct the ACL were performed opening the joint with an incision, an arthrotomy. Thus, the intra-articular space where the new graft had to be positioned was accessible. In 1980, Dandy performed the first arthroscopically assisted ACL reconstruction [21]. During the 90s, arthroscopic ACL reconstruction became the preferred method of surgical treatment over conventional, old-fashioned procedures, due to the benefits of keyhole surgery, such as reduced post-operative morbidity, improved cosmetics, increased speed of recovery and enhanced range of motion [14]. Initially, two incisions were made during the procedure to drill the tibial and femoral tunnels. During the nineties, single-incision endoscopic ACL reconstruction became the standard [34].

Rear entry vs inside out

Palmer stated that the canal drilling had to be performed from the outside of the condyle inwards, to prevent opening of the joint very widely [68]. O'Donoghue reported drilling from within out could easy damage the posterior cruciate ligament and recommended the use of protective sleeves on the drill points or outside in drilling [65]. Lam recommended this technique as drilling from within the knee results in damage of the femoral articular cartilage [47].

Marshall claimed that drilling from within could not result in a posterior enough position of the tunnel [56]. Hewson, also advised drilling from the outside to prevent damage to the residual ligament and surrounding ligament synovium [39]. With the introduction of the arthroscopic procedures, new drilling techniques developed. The previous concerns disappeared and rear entry drilling through a second incision [3] was replaced by the one-incision technique, drilling the femoral tunnel from the inside of the notch through the tibial tunnel, the transtibial technique [34].

Anatomical vs isometrical concepts

Two conceptual thoughts have been present since the first reconstructions, the anatomical concept and the tension concept. During the history these concepts have resulted in various reconstruction goals and techniques. The reconstruction technique of Hey Groves was obviously a replacement at the anatomical insertions sites, as well as of his follower, Palmer, who even performed double-bundle ACL repairs in the 30s [68]. Before Hey Groves published his technique, Fick, in 1911, described the tension pattern of the two ACL bundle, with the 'upper medial bundle' being tightest in extension and the 'lower lateral bundle' tightest in flexion. He noticed that some ACL fibers are tensioned over the complete range of motion [25]. In line with this observation Cowan reported in 1963 that it would be difficult to produce a new ligament with the complexity of the normal anatomical arrangement of the ACL [20]. And a single tubular graft composed of parallel fibers could not reproduce both ACL bundles and their tension patterns. His compromise was the placing of the femoral drill hole at a point, where the substitute ligament remained firm throughout the full range of flexion and extension and did not limit this range. To find this point in the femoral intercondylar notch, he used a dental scaler, placed with its sharp point in the bone, measuring the distance between this point and the tibial tuberosity in all positions of the knee, during knee movement over the full range of motion [47]. In the eighties Hewson and Odensten and Gillquist confirmed the importance of isometry [39, 67]. However, Odensten and Gillquist described the distance between the central points of the normal attachment areas of the ACL as isometric during flexion and extension, where others positioned the isometric point or zone more proximal and posterior near the over-the-top position [4]. This controversy was typical for that period, when the concept of isometricity became a hot topic in ACL reconstruction with many studies reporting the various femoral isometric positions [12, 16, 26, 36, 74].

Surgeon oriented guides vs aiming devices

Although all drill guides aid in placing tunnels at a predetermined point in the notch, two different techniques can be distinguished. In the first technique, the surgeon has to determine the correct point himself conform the concept that was chosen to reconstruct the ACL. Positioning these guides depends on the surgeons knowledge and skills and are therefore 'surgeon oriented guides'. In the second technique, the design of the drill guide supports in determining the correct point. The surgeon has to position the guide according the accompanying placement protocol and the guide ensures tunnel placement at the anatomical or isometrical position. In this paper, these second category of guides will be referred to as 'aiming devices'.

Drill guide and aiming device designs

We defined four aspects of the abovementioned concepts to have influenced femoral guide design. Since guides facilitate tunnel placement determining the drill location, the aspect of the tunnel diameter (small suture canals or a large femoral tunnel) did not had much influence at the guide design. Based on the other four aspects, we divided the guides in two main groups, with two subgroups. This grouping resulted in a more or less chronological order, with the exception of the anatomical reconstruction group of the surgeon oriented inside-out guides:

1. Surgeon oriented guides
    A. Rear entry guides
        i. for anatomical reconstruction
        ii. for isometrical reconstruction
    B Inside-out guides
        i. for isometrical reconstruction
        ii. for anatomical reconstruction

2. Aiming devices
    A Rear entry device
        i. for anatomical reconstruction
    B Inside-out
        i. for isometrical reconstruction
        ii. for anatomical reconstruction

1.A.i Surgeon oriented rear entry guides for anatomical reconstruction

In 1938, Palmer described the first constructed femoral drill guide. In his thesis, he describes a suturing technique for ACL rupture at the superior insertion at early stage, attaching two sutures at the broad end of the ligament, passing them through two canals and knotted at the outside of the femoral condyle (Figure 1) [68]. The canal drilling had to be performed from the outside of the condyle inwards, to prevent opening of the joint very widely. Palmer emphasized the importance of the absolutely exact position of the canals, at the anatomical insertion area. To achieve this, he constructed the 'drill adjuster' (Figure 2). The movable shank of the adjuster was placed by the surgeon at the position in the intercondylar notch were the canals were planned, the upper shank came at the lateral outside of the femoral condyle surface. The drill was placed in the adjuster and secured the bore as it broke through into the joint at the position of the tip of the shank.

Palmer's device was unnoticed for a long time until the sixties, when surgeons started to re-use his guide, adapted it or developed new guides to facilitate femoral canal and tunnel drilling. Theve [80] and Eriksson [23] modified Palmer's drill adjuster to be able to drill two parallel channels from outside in through the femoral condyle for the sutures in ACL reconstruction procedures modified from Jones (Figure 4) [42].

The Lund drill, developed by Lindstrand as a modification of the commercial French Landanger drill guide, could be used for drilling one tunnel up to four parallel canals for sutures and was used for ACL and posterior cruciate ligament reconstructions (Figure 5) [48]. Where guides of Theve and Eriksson only could work in one plane, this guide was freely adjustable in all planes allowing to position the canals at the required location. The guide could be anchored easily to the bone for stability during drilling.

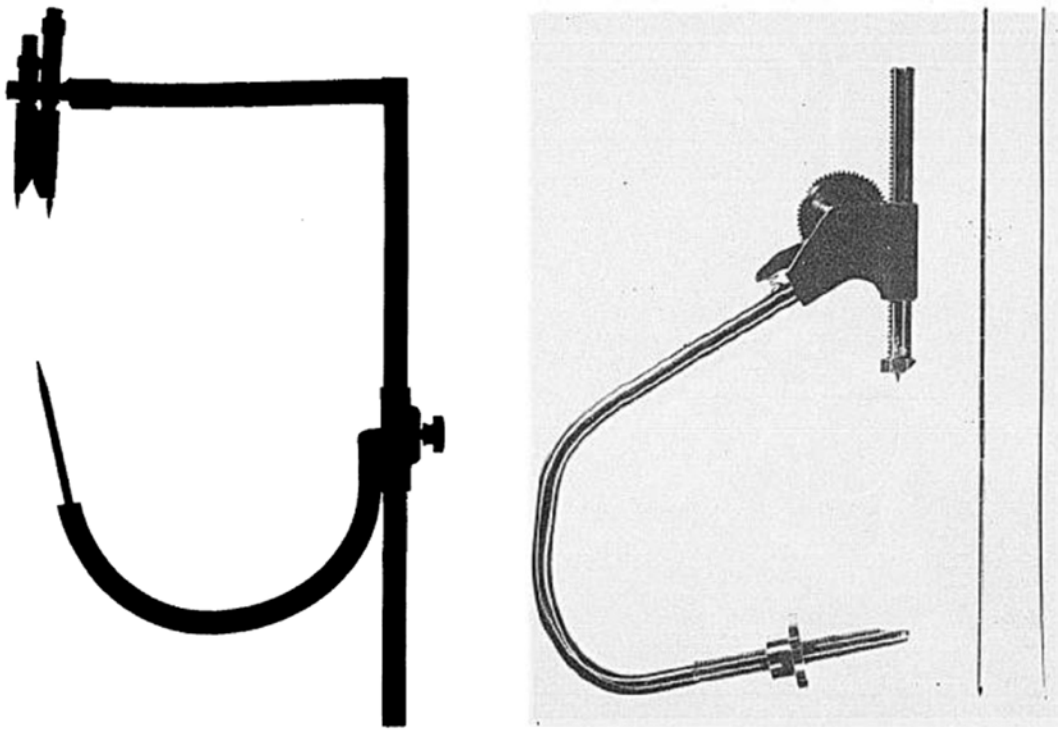

Figure 4. Two modifications of Palmer's drill adjuster.
Left: Theve's drill guide. (From Theve, 1975) [80];
Right: Eriksson's Karolinska or Stille drill. (With kind permission from Wolters Kluwer Health: Eriksson, 1976) [24]

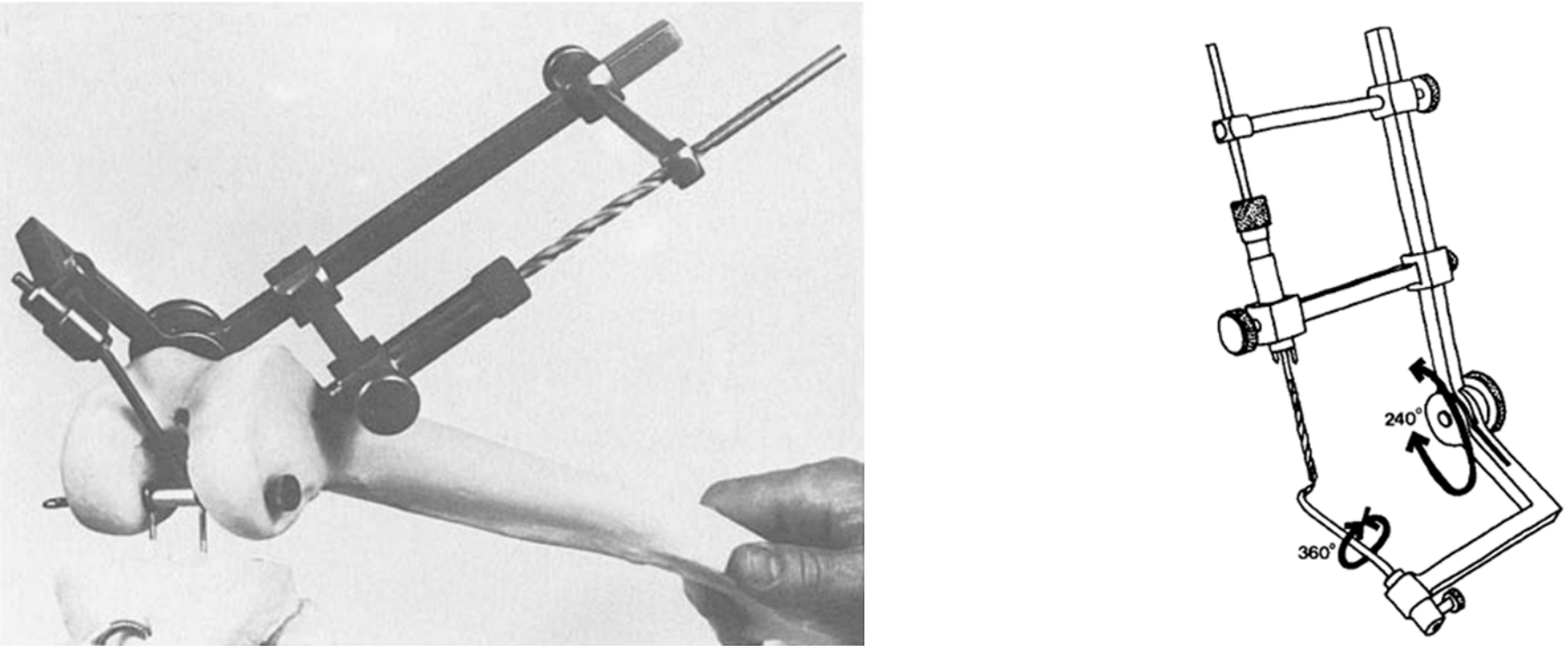

Figure 5. The Lund drill is free adjustable by rotating the aiming pin 360° and the frame 240°. (With kind permission from Springer Science+Business Media: Lindstrand, 1982) [48]

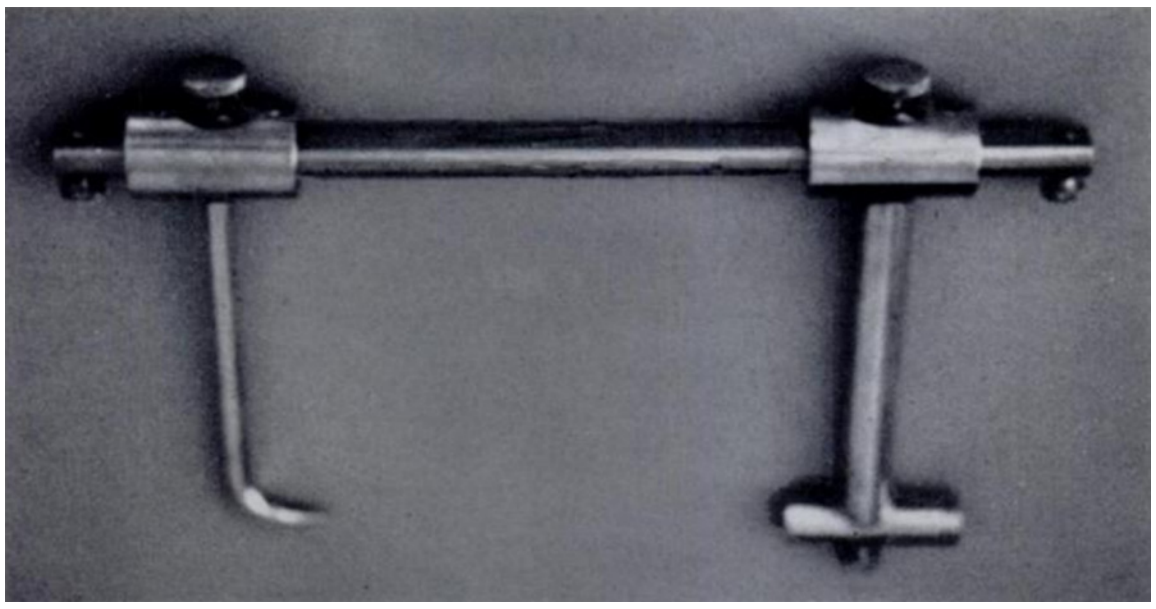

Figure 6. Drill guide developed by Lam, the aiming tip on the left had to be placed at a predetermined point in the notch. The drill sleeve on the right guides the drill from the outside of the femoral condyle, towards the predetermined point. (With kind permission from Elsevier: Lam 1968) [47]

Lam, Stewart, Rhinelander, Hewson and Blauth developed similar guides as Palmers adjuster (Figure 6 and Figure 7), using it in reconstructions according to modifications of the Jones procedure [13, 39, 47, 71, 77]. Jones drilled a tunnel through the femoral condyle to pass the proximal detached part of the patellar tendon [42].



Figure 7. Left: a-d Rear entry drill guides of a) Rhinelander; b) Stewart; c) Eriksson; d) Hewson;
Right: The ideal location for the femoral tunnel. (With kind permission from Wolters Kluwer Health: Hewson, 1983) [39]

Lam recommended the use of the guide for drilling from outside the lateral femoral condyle entering the knee at a predetermined point in the notch, as drilling from within the knee results in damage of the femoral articular cartilage [47]. Although Lam, in the first instance, followed Cowan's concept of isometry to define the optimal tunnel location [20], later he reported that it was impossible to locate an isometric point, therefore he decided to perform a more anatomical reconstruction, following the instructions of Jones [42]. Rhinelander modified a C-clamp with drill guide and a special drill, which he had previously used for internal fixation of knee and ankle fractures, for use in ligament repair according to the Lam modification [71]. Hewson emphasized the accuracy of the tibial and femoral tunnels and stated the ideal femoral location as an isometric position, which is at the anatomical insertion (Figure 7) [39]. With his guide he wanted to improve certain features and eliminate inaccuracy and fragility of other drill guides. Despite the use of the guide, Hewson recognized that the accuracy of the placement lies with the surgeon.

1.A.ii Surgeon oriented rear entry guides for isometrical reconstruction

As mentioned above, Lam used his guide in first instance to drill a tunnel at the optimal location for an isometric reconstruction. He described that Cowan used a dental scaler to determine that point, where the distance till the tibial tuberosity was constant throughout the full arc of knee movement. Later in 1991, this principle was used again by Raunest [70]. At the retrograde marking hook, which had to be hooked behind the femoral shaft, an isometer could be attached (Figure 8). With his device, possible tunnel positions in the intercondylar notch could be tested for isometry before tunnel drilling. After determining the most isometric point, an adjustable C-ring is attached to the marking hook end and the guide pin sleeve is placed at the correct femoral entry position.

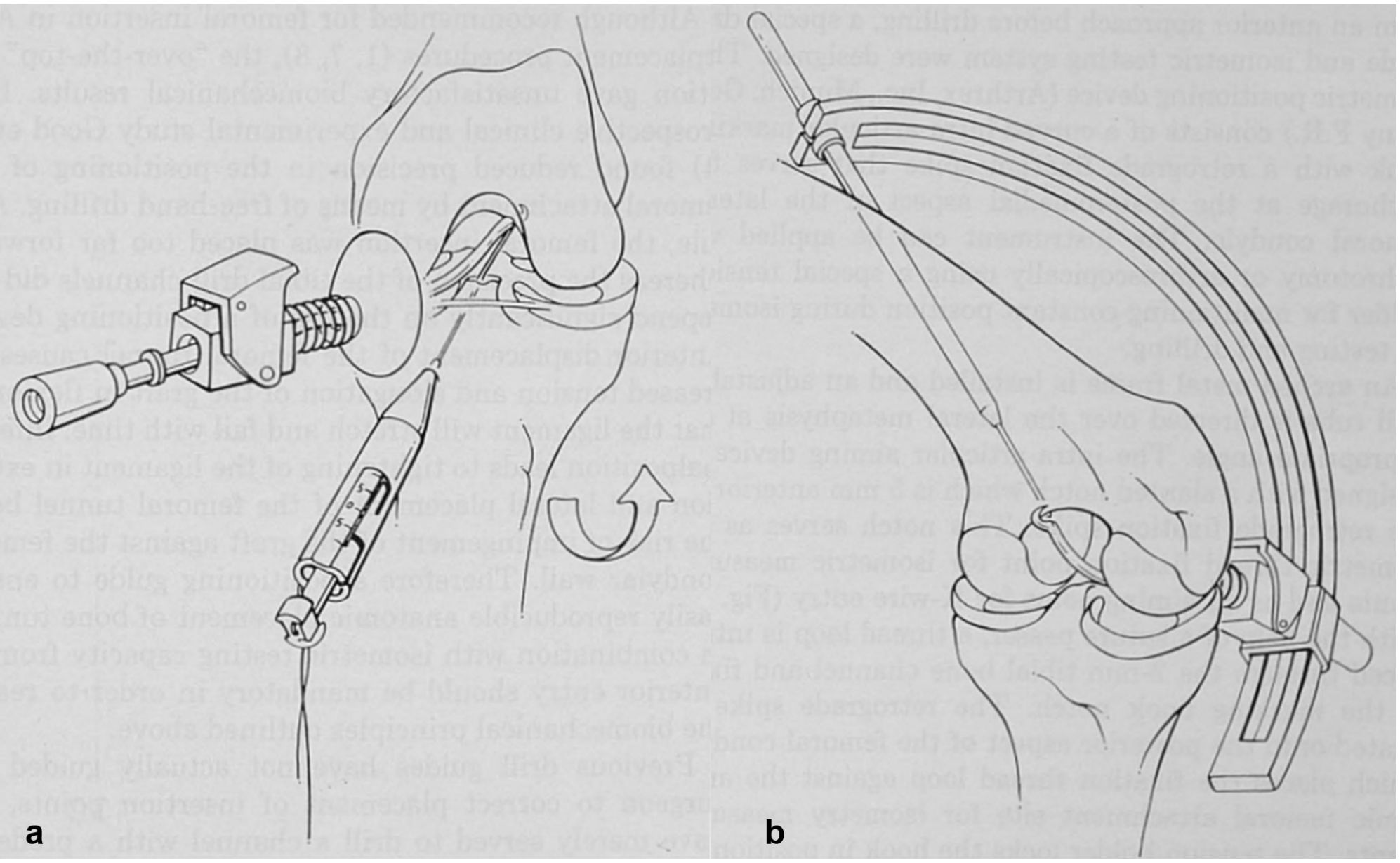

Figure 8. a-b Drill guide developed by Raunest et al; a) The marking hook is positioned behind the posterior femoral cortex, the isometer tested the points for isometry. b) When the most isometric point is found, the C-ring is attached to the marking hook and the guide pin sleeve is positioned at the entrance point at the femoral condyle. (With kind permission from Wolters Kluwer Health: Raunest 1991) [70]

The Rhomboid guide developed by Kariya and Kurosawa has a probe, rhomboidal frame and a drill sleeve (Figure 9). The tip of the probe is positioned under arthroscopic control at the described intraarticular target point in the femoral intercondylar notch, '4 mm below the corner on the ceiling and on the lateral side wall of the femoral intercondylar notch —4 mm anterior to the posterior articular surface' [43]. Because of its rhomboid frame, any arbitrary extraarticular point at the femoral condyle can be chosen as entry point, in contrary to fixed guides like Hewson's guide.

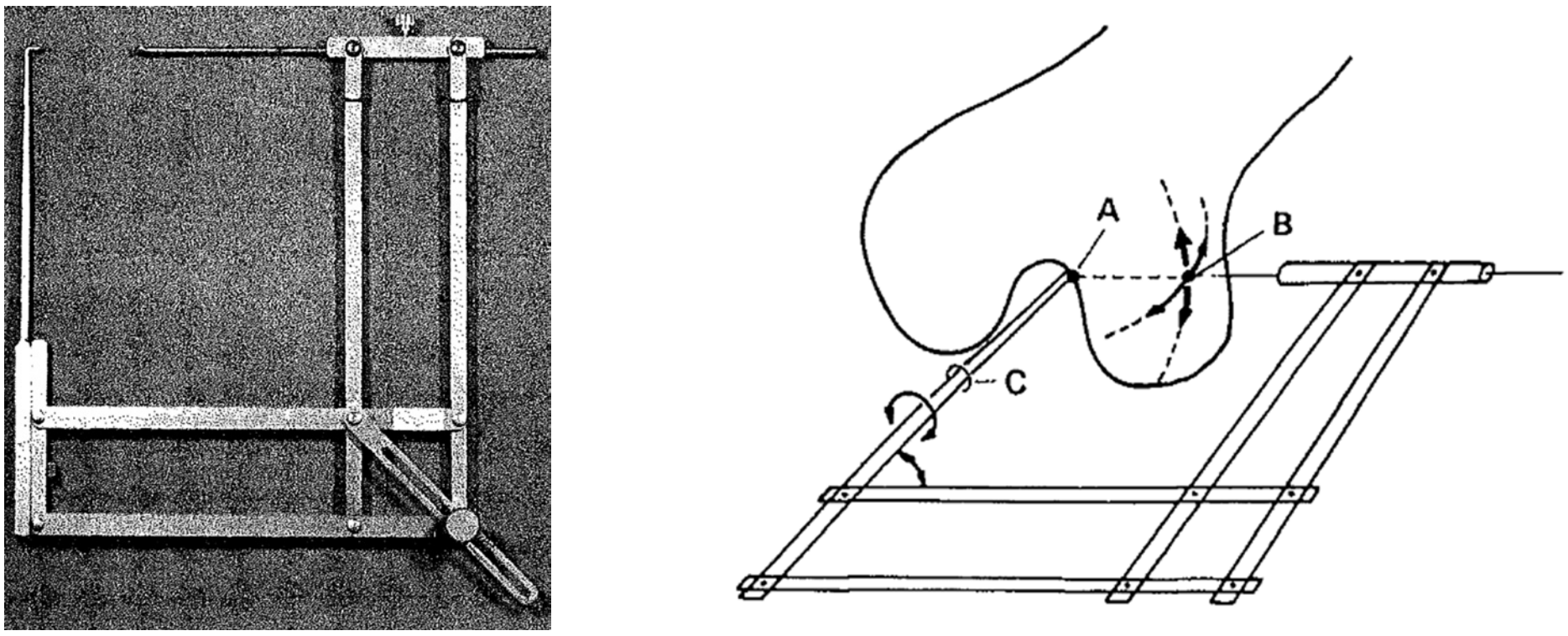

Figure 9. Left: The Rhomboid guide developed by Kariya et al. Right: The rhomboidal frame allows positioning of the extraarticular wire at any point, adjusting rotation at the intraarticular wire and movement of the frame angle. (With kind permission from Elsevier: Kariya et al, 1989) [43]

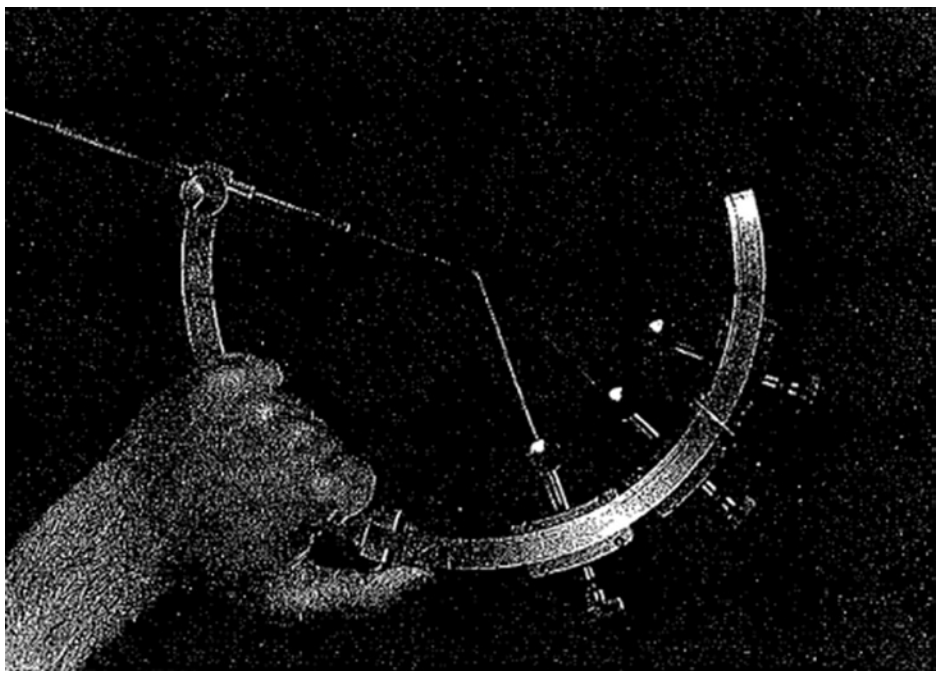

Figure 10. The semi-circular shaped outside-in drill guide developed by Bassi and Fioriti allows positioning of the femoral entrance at the best location. (From Bassi and Fioriti, 1990) [7]



Figure 11. The mounted G.U.I.A. for isometric femoral tunnel positioning. (With kind permission from A. Hernandez: Hernandes, 1993) [37]

The advantage of the Rhomboid guide, positioning the entrance of the femoral tunnel at the best possible area is also seen by the outside-in guide developed by Bassi and Fioriti, a semi-circular shaped guide, in which the 'centrator' had to be placed at the isometric site in the femoral notch (Figure 10) [7].

1.B.i Surgeon oriented inside out guides for isometrical reconstruction

The G.U.I.A. (Universal Coupled Isometric Guide) is a universal simple guide, developed for multiple purposes use in all types of ligament reconstruction, open or arthroscopic surgery and for positioning intraarticular wires (Figure 11). The guide has two cannulae, one of 2 mm for an orienting wire, which should be placed in the posterolateral portion of the intercondylar sulcus. In this way the cannula of 9 mm is positioned at the isometric position, located immediately below and in front of the region known as "over-the-top", guiding the drill to the correct isometric place [37].

1.B.ii Surgeon oriented inside out guides for anatomical reconstruction

Following Odensten and Gillquist (described later) [66], Beyer constructed an arthroscopic guide being able to drill a single tunnel through tibia and femur in one pass (Figure 12) [11]. This technique, drilling the femoral tunnel inside-out was in contrast with the outside-in drilling technique, which was commonly used till then. This so-called unitunnel technique, reduced surgical morbidity, since no extra incision for the guide was necessary. The aligned tunnels limited the stress of the graft at the entrance and exit points. Beyer adhered the opinion that the isometric area was located at the anatomical insertion [67], therefore the tunnels had to be placed at the insertion in order to achieve isometry. The aiming post had to be positioned at the tibial insertion; The tibial drilling post was positioned at the tibial entrance point. The femoral post to stabilize the guide was fixated at the femoral condyle aligned for the femoral target zone. After drilling the tunnels, the graft was fixated in the femoral tunnel, followed by the testing of isometry using an isometer. When the ideal isometric position at the tibia was found, the graft was fixated.

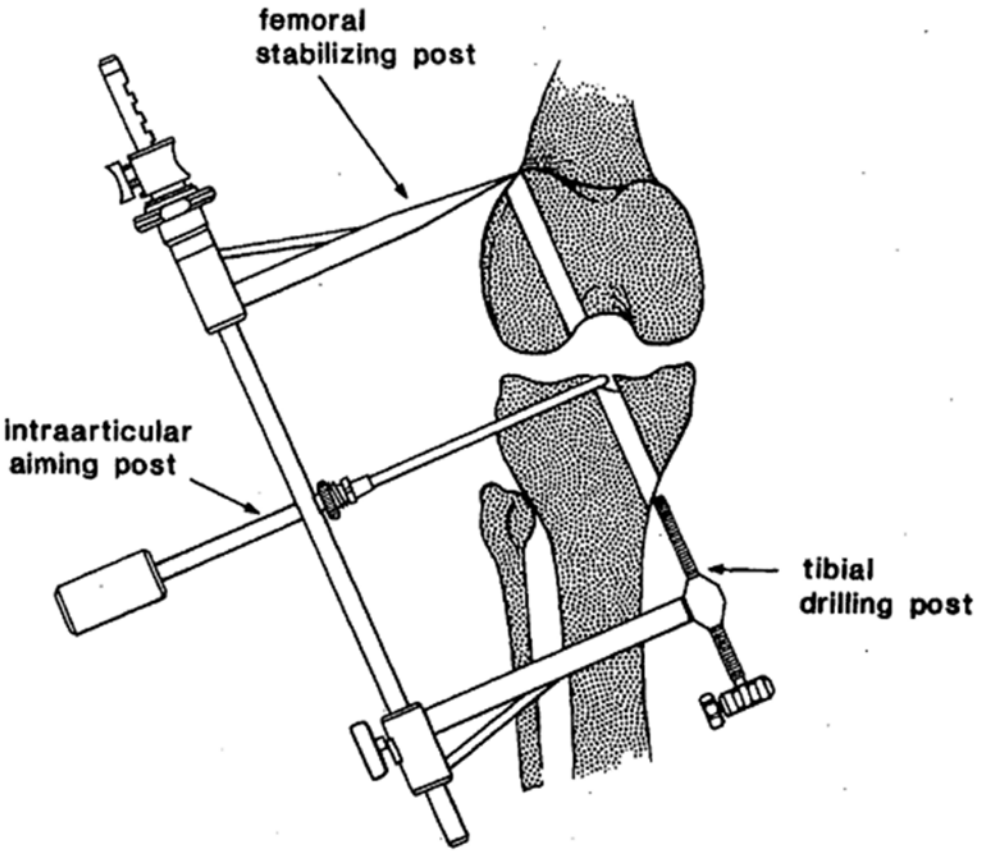

Figure 12. An arthroscopic guide for drilling a single tunnel through the tibia and femur in one line. The intraarticular aiming post was positioned at the tibial anatomical insertion center. (With kind permission from A.Beyer: Beyer, 1988) [11]

Clancy, who advocated anatomical reconstructions [19], constructed a curved 42-degree drill guide with a flexible guide pin and flexible cannulated drill (Smith & Nephew Clancy anatomic cruciate guide/flexible drill system, Smith & Nephew, London, England) (Figure 13). The design of the curved endoscopic guide facilitates easily placement of the tunnel at the anatomical centers, introducing it through the AM portal. In the described method, the tunnel location is marked first at the center of the footprint with a 45° microfracture awl at an 70° arthroscopic view through the anterolateral portal after carefully defining the femoral footprint [8, 15, 69]. Cain advocates placing the tunnel at the 9:30 position at an oblique angle for a horizontal tunnel with an oval entrance [15]. Rasmussen indicates tunnel placement inferior to the lateral intercondylar ridge, directly onto the bifurcate ridge, approximately 7 mm superior to the inferior chondral junction (with the knee in 80° of flexion) [69].



Figure 13. a) Curved 42-degree femoral drill guide handle, flexible guide pin, and rigid reamer; b) Curved femoral drill guide positioned at the anatomical ACL center. (With kind permission from Smith&Nephew; Images courtesy of Smith & Nephew, Inc.)

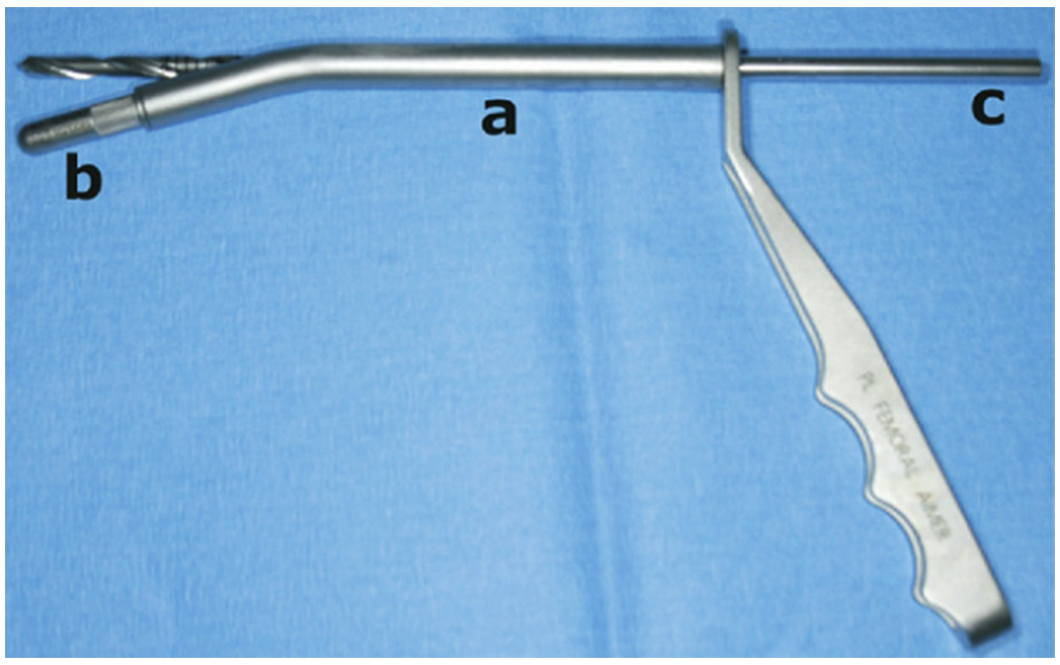

Figure 14. The Posterolateral Femoral aimer with a guide sleeve (a) for the introduction of a laser beam and a 4.5 mm solid drill (c). Post b is positioned in the AM tunnel. (With kind permission from Elsevier: Christel, 2008) [18]



Figure 15. The BullsEye Femoral Footprint Guide has an open tip for clear visualization of the femoral footprint. (With kind permission from Elsevier: Gelber, 2011) [31]

Christel presented an anatomical guide for the posterolateral tunnel, Posterolateral Femoral aimer (Smith & Nephew Endoscopy). It consist of a post, which has an angle of 15° with the guide pin sleeve (Figure 14) [18]. The post has to be placed through an accessory anteromedial portal in the anteromedial tunnel, which is drilled with a standard Endofemoral aimer (Smith & Nephew Endoscopy) through the anteromedial portal. The guide pin is rotated towards the posterolateral insertion site, till a laser mark, which is send through the sleeve, is aligned with the previously marked PL center. This device allows positioning of an extra tunnel at 8-9 mm in front of and below the anteromedial tunnel, leaving a 2-3 mm bone bridge between both.

The BullsEye Femoral Footprint Guide (ConMed Limvatec, Largo, FL) was described by Gelber (Figure 15) [31]. This guide has a window at its oval end for easy visualization during placement at the intermediate point between the AM and PL femoral footprints or in the center of the lateral bifurcate ridge when this could be identified.
The latest guide described in literature is the Specially Designed Laser-Pointed Drill Guide from Watanabe et al. (Figure 16) [82]. Similar as Christel, a laser emitter was incorporated. The tibial

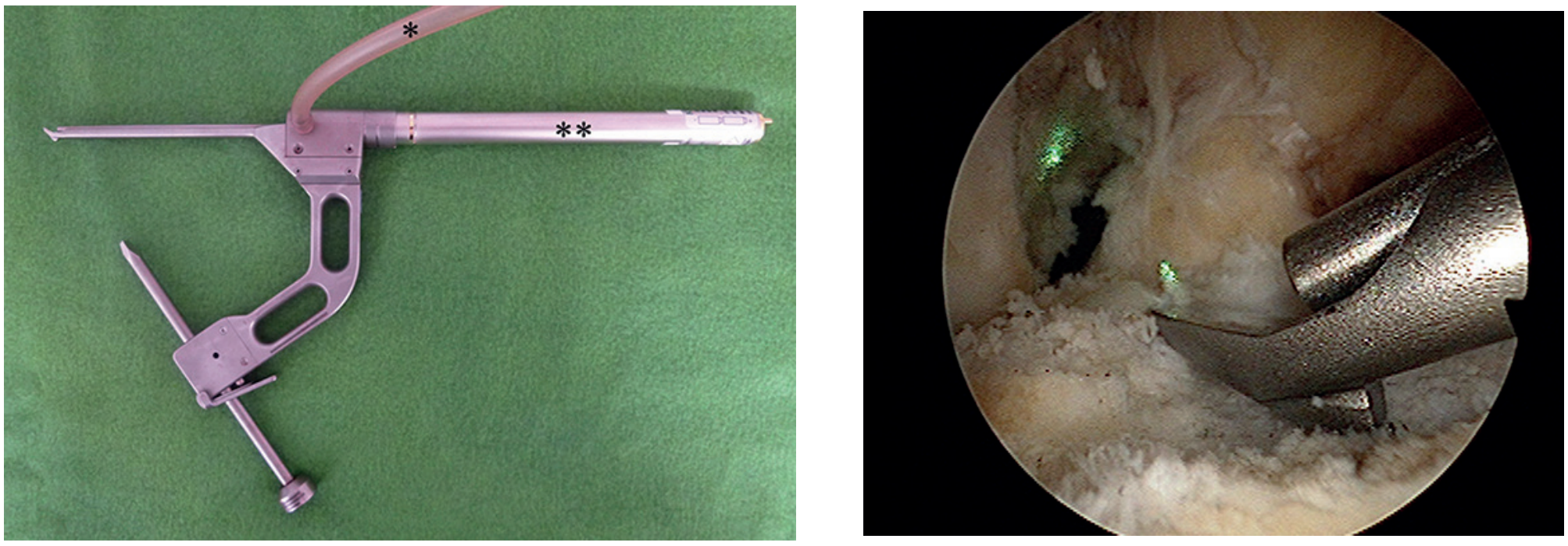

Figure 16. a) The tibial drill guide consist of a aiming post with a laser emitter at the right end (**), and distal a guide sleeve for the guide wire and drill pin; b) The laser beam is send through the post reflecting at the end towards the femoral insertion. (With kind permission from Elsevier: Watanabe, 2015) [82]

drill guide had a hole through which the laser beam passed. The end of this sleeve has to be positioned at the tibial footprint. The laser beam is reflected at the end of the device by a mirror, aligned along the axis of the tibial tunnel. By directing the laser beam at the target location, the anatomic centrum of the femoral footprint located 2 to 3 mm posterior of the residents ridge, both tunnels are positioned in one line following the concepts of Odensten and Gillquist and Beyer [11, 66]. A New Special Drill Guide Pin introduced through the tibial tunnel marks the positions for the AM and PL tunnel.

2.A.i Rear entry aiming device for anatomical reconstruction

The aiming device from Blauth et al. seems a rear entry guide, however, instead of a intraarticular aiming pin, the aiming post ends in a changeable hockey stick-like part [13]. The intra-articular part had to be positioned behind the posterior edge of the lateral femoral condyle with its curvature abutting the notch roof (Figure 17). With this additional part and the instruction, the guide has turned into an aiming device, guiding tunnel placement at the posterior part of the intercondylar notch near the cartilage line. The device was used in a double-bundle technique according to Müller [63], replacing the ACL with two strips, replacing both AM and PL bundle, with an over-the-top graft and a graft at the femoral anatomical insertion.

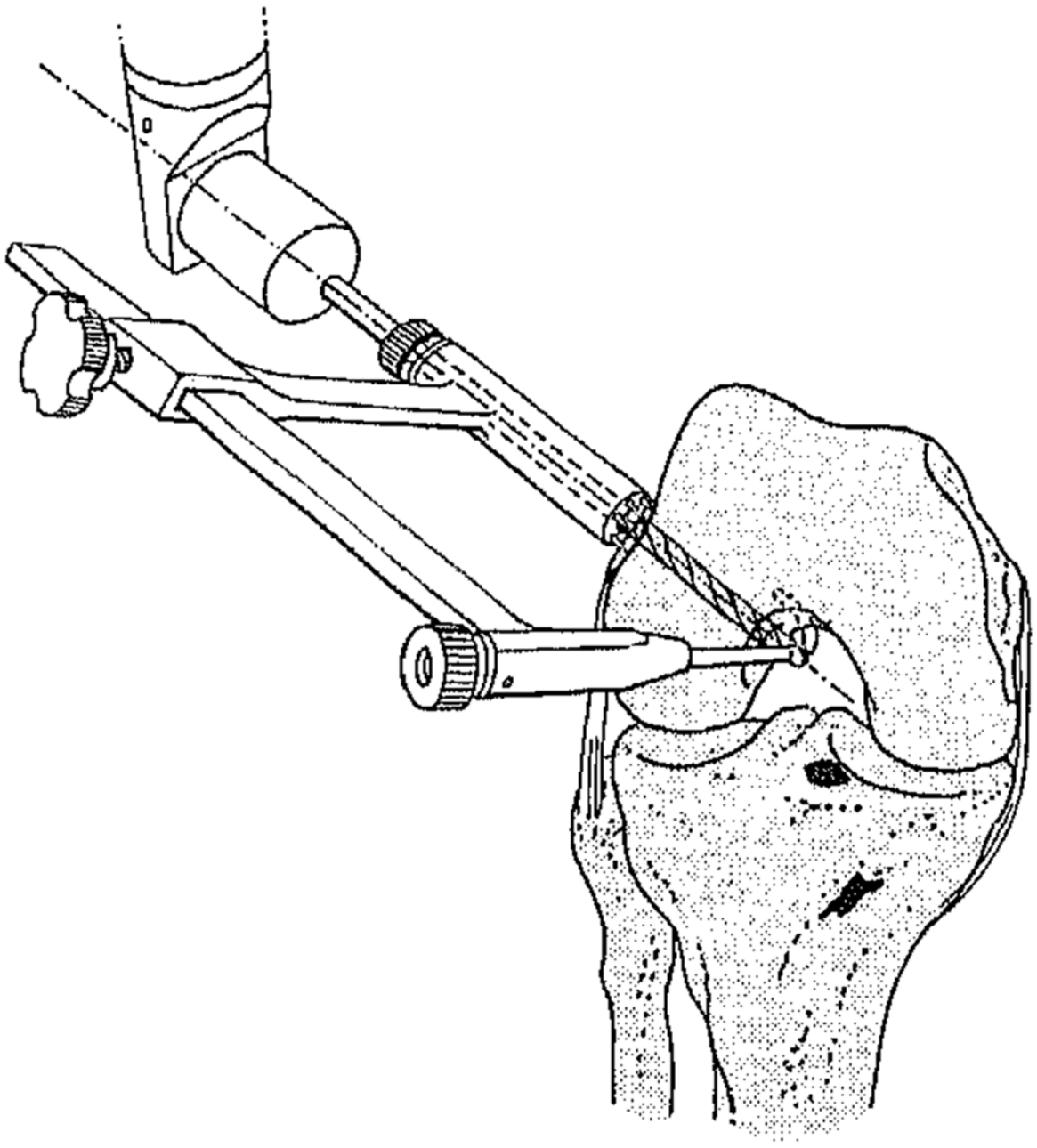

Figure 17. The hockey stick-like part is positioned behind the posterior edge of the lateral femoral condyle with its curvature abutting the notch roof. (With kind permission from Springer: Blauth, 1984) [13]

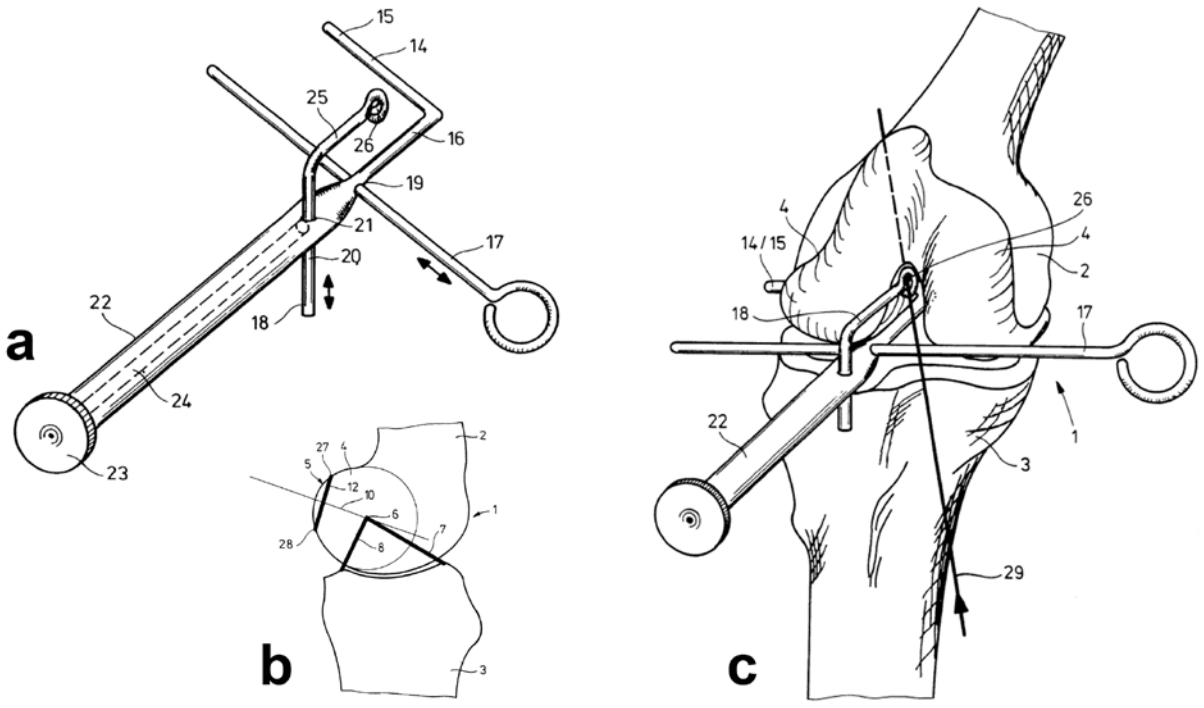

Figure 18. a) The isometric guide designed by Mattheck in 1988; b) the guide is positioned from the anterior approach. (From European Patent No. 88105614NWA1) [57]

2.B.i Inside out aiming devices for isometrical reconstruction

Mattheck et al. developed a guide to position the femoral tunnel at the geometrical center of the femoral condyle, being the femoral isometric point [57]. The guide, positioned through an arthrotomy, could be adapted to the anatomical features of the individual patient by mounting a plastic disk with the size of the femoral condyle radius (Figure 18). The correct size of the disk was measured preoperative at a lateral radiograph of the patients knee.

Patterson's inside-out guide [52], which had to be entered through the anteromedial arthroscopic portal, had an outrigger which had 'objective' positioning instructions: it had to be placed into the over-the-top position at the junction of the wall and roof of the femoral notch (Figure 19). This resulted in a femoral tunnel posterior in the notch, just anterior and distal to the over-the-top-position, at the 'isometric spot', which is in the anteroproximal corner of the femoral ACL attachment [4, 5]. The guide could be used in arthroscopical techniques or open and mini-open ACL procedures.
The Endoscopic Femoral Aimer (EFA) builds on Patterson's concept, using the posterior cortex of the notch as a physical reference of the guide (Figure 20) [34, 59]. The tongue of the guide rests on the posterior femoral cortex and is placed in the 11 (right knee) or 1 (left knee) o'clock



Figure 19. Inside out disassembled arthroscopic aiming device developed by Paterson. (With kind permission from Elsevier: Marans, 1992) [52]

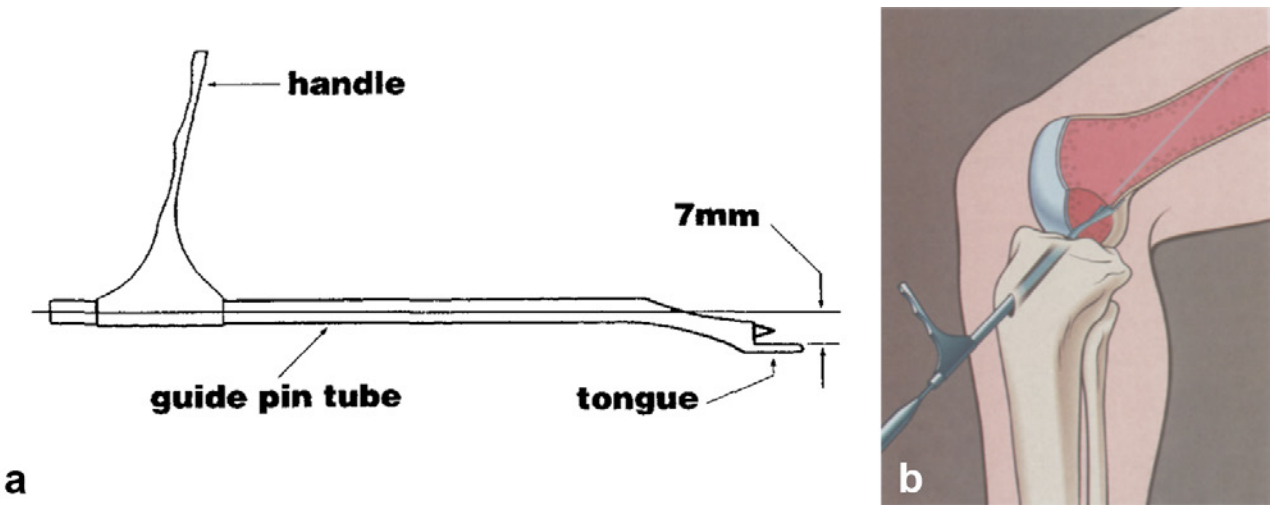

Figure 20. a) The Endoscopic Femoral Aimer with its parts and offset; b) Placement of the EFA in the knee, with its tongue behind the posterior femoral cortex. (With kind permission from Elsevier: McGuire, 1996) [59]

position, resulting in, assumed, anatomical placement of the guide pin and the center of the femoral tunnel. Additional gain of this aimer was the concept introducing the guide through the tibial tunnel, not only resulting in concentric tunnel axes, but also optimally profit from the advances of arthroscopic ACL reconstruction with this one-incision technique. This guide could also be adapted to the size of the individual knee, choosing a different offset, placing the tunnel as far as possible posterior in the notch, leaving a 1- to 2-mm posterior cortical rim, thus avoiding posterior breakout. Although this guide claimed positioning of the femoral tunnel at the anatomical insertion, studies demonstrated that this single incision transtibial technique with the EFA positioned at 11/1 o'clock misses the anatomical femoral ACL insertion [6].

Laboureau and Marnat-Perrichet (1997) developed an adjustable guide for arthroscopic isometric femoral tunnel placement (Figure 21) [46]. Their design resembles the EFA. It has a tongue that has to be positioned behind the posterior cortex at 10 or 2 o'clock. The distance between the tongue and the exit point of the guidewire is adjustable, according to a distance measured at preoperative lateral radiographs. The guide has to be positioned with an angle of 25° relative to the tibial plateau with the knee in 90° of flexion. Next, the knee is positioned in 50° of flexion, drilling the tibial an femoral tunnel in one line.

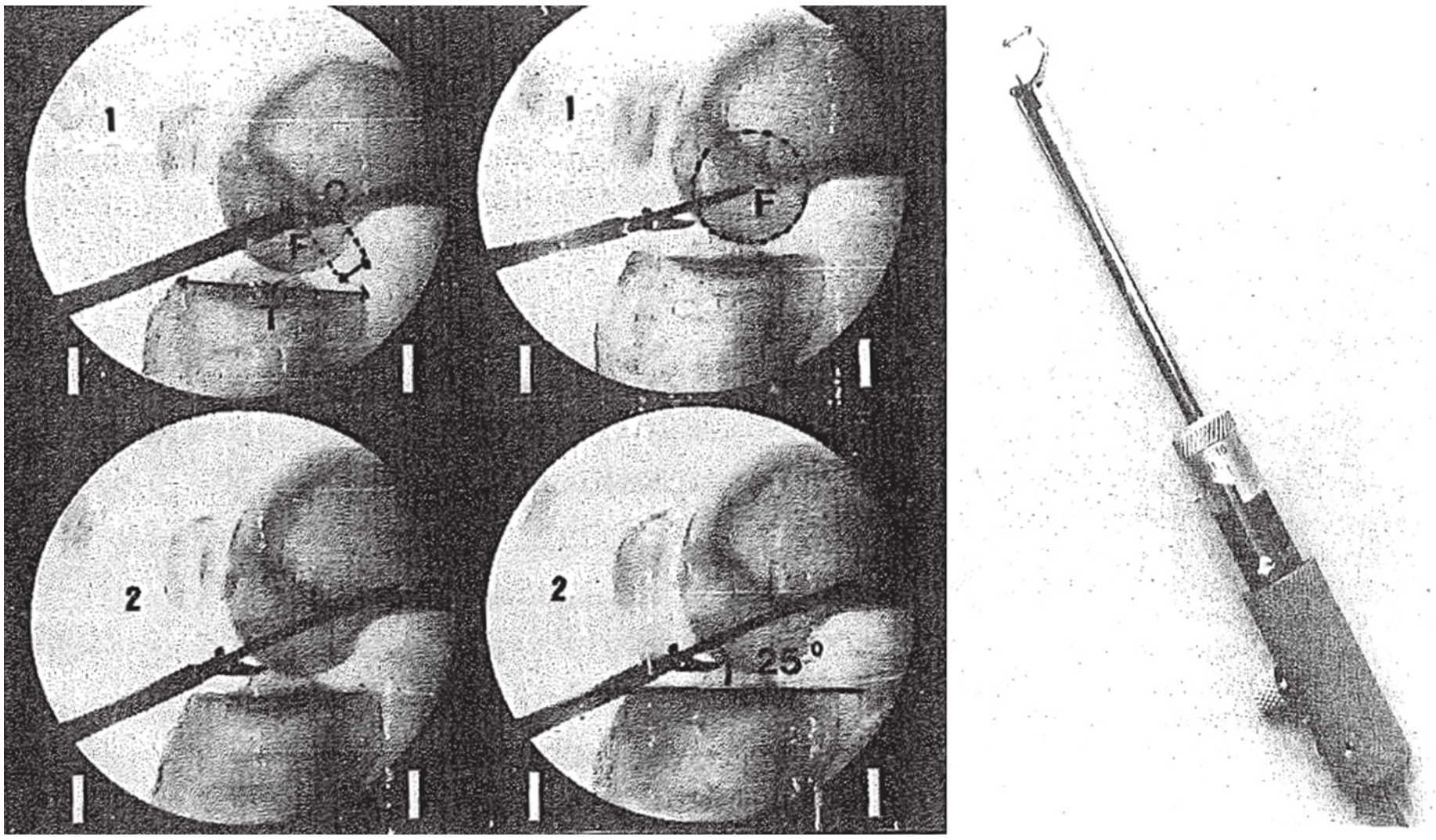

Figure 21. a) The distance between F and O is measured on preoperative radiographs; b) The offset distance of the femoral aimer can be adjusted to the distance FO with a adjusting knob. (With kind permission from Springer Science+Business Media: Laboureau and Marnat-Perrichet, 1997) [46]

2.B.ii Inside out aiming devices for anatomical reconstruction

Odensten & Gillquist found that tunnels positioned at the central points of the attachment on the femur and tibia resulted in isometricity of the reconstruction [67]. Their approach to develop a guide was different than from other surgeons before. They examined normal cadaver knees to determine the dimensions of the attachment sites of the ACL in relation to each other and the to the axes of femur and tibia. The total ligament length of the midpoint distance was 31 mm and the average angle of the long axis of the ligament with the long axis of the femur in

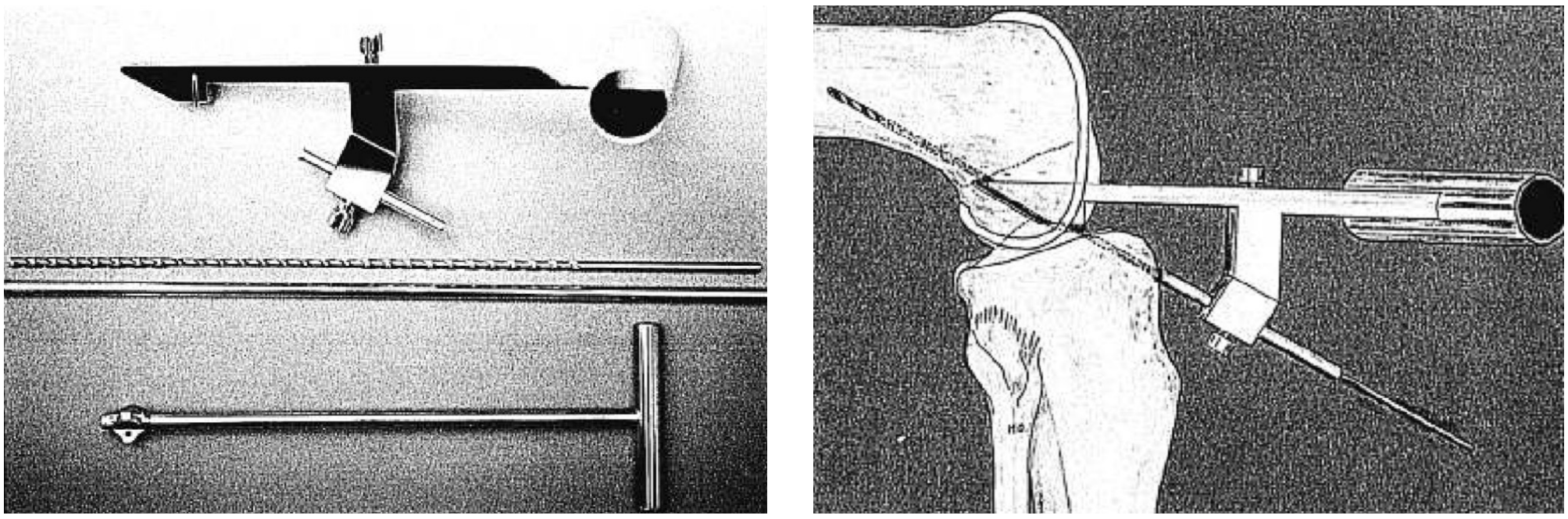

Figure 22. Left: Drill guide, guide pin, cannulated drill and router of Odensten & Gillquist; Right: The femoral tunnel is placed 31 mm from the tibial tunnel with an angle of 28° to the long axis of the femur. (With kind permission from Springer Science+Business Media: Odensten and Gillquist, 1986) [67]

the coronal plane in 90° of knee flexion was 28°. With these dimensions a drill guide was constructed (Figure 22a) [67]. They provided a clear description of placement of the guide: at the tibial attachment point, 23 mm posterior to the anterior edge of the tibial plateau and 7 mm from the closest cartilage border on the medial tibial condyle, according to their anatomical findings. With this tibial placement, the upper end of the drill corresponds to the posterior end of Blumensaat's line. Proper alignment of the guide can also be checked through an engraved line on the frame, which should correspond to the meniscosynovial junction (Figure 22b). With this guide both tunnels could be drilled in one straight line during a mini arthrotomy procedure. Odensten and Gillquist were the first to test the validity of their guide [32].

After Bernard et al. [10] published their radiographic quadrant method, Milankov and Miljkovic developed an adjustable femoral aiming device with a sliding Kirschner wire (Figure 23a) to place the tunnel at the individuals anatomical 25%-25% position, in the distal corner of the most superoposterior quadrant [60]. The adjustment of the guide was based on measurements at the patients preoperative lateral radiogram. The guide could be positioned hitching the hook on the posterior side behind the edge of the lateral femoral condyle (Figure 23b).



Figure 23. a) The adjustable aiming device has a sliding guide for a Kirschner wire, which is positioned at the distance measured on preoperative radiographs; b) The hook of the guide has to be positioned behind the posterior femoral cortex. (With kind permission from Springer Science+Business Media: Milankov and Miljkovic, 2000) [60]

Figure 24. The Transportal Femoral Guide has a 30° angled, longer off set tip to facilitate more anatomical tunnel placement. (With kind permission from Elsevier: Lubowitz, 2009) [50]

The guide introduced by Lubowitz, is an adjusted EFA (Figure 24) [50]. The Transportal Femoral Guide (TPG) has a 30° angled, longer offset tip, which minimizes impingement and improves stabilization over the back wall. It should be positioned through the AM portal at 10 o'clock.

The most recently developed inside out aiming device is the guide for anatomical femoral tunnel placement (GAFT) (Figure 25). This guide is developed according to averaged anatomical measurements of the femoral footprint relative to landmarks in the intercondylar notch. The design of the guide, together with the placement protocol, support the surgeon in accurate anatomical tunnel placement at the center of the anatomic ACL for single bundle reconstruction or at the centers of the AM and PL for double bundle reconstruction.

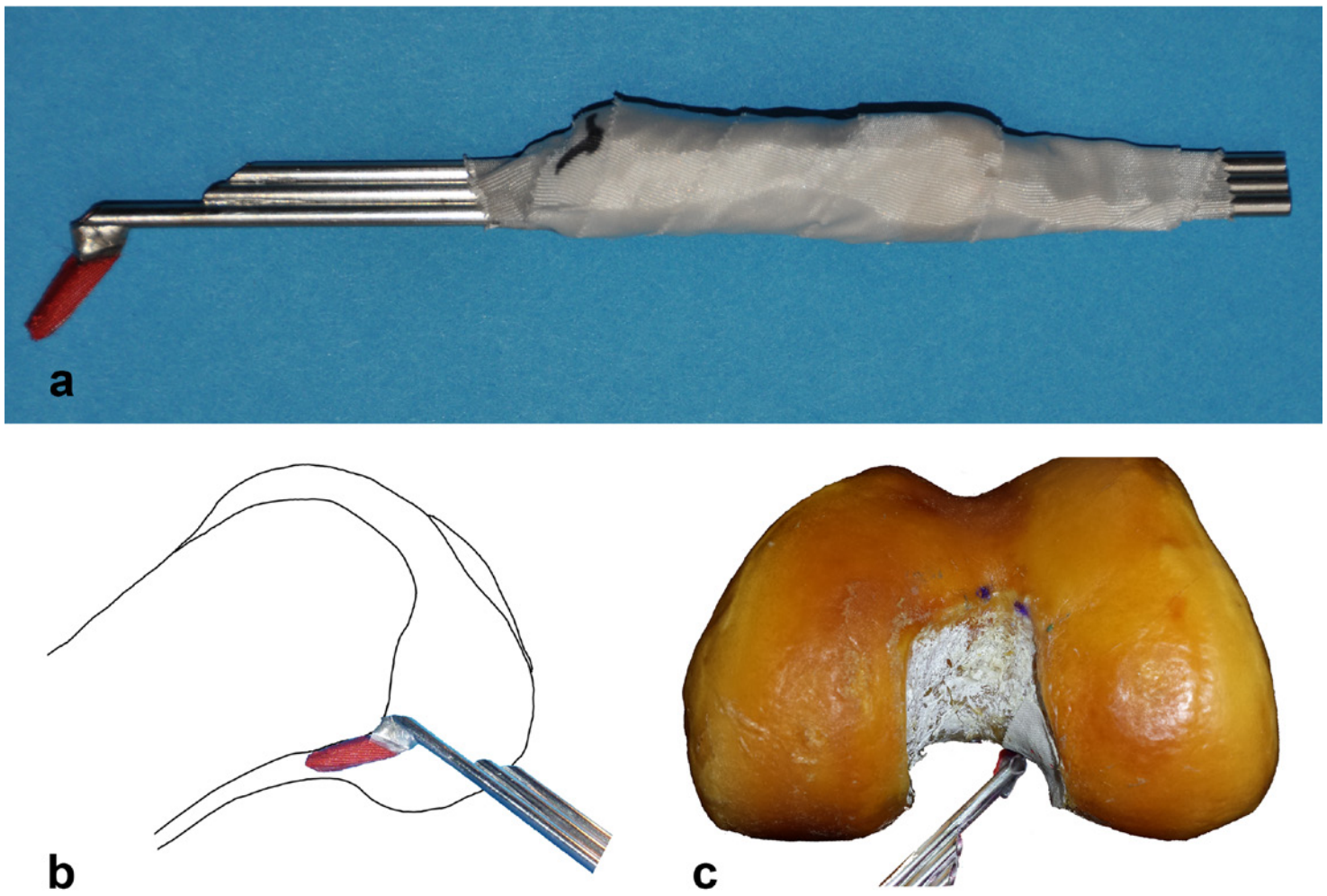

Figure 25. a) Prototype of the guide for anatomical femoral tunnel placement (GAFT); b) The tongue is positioned behind the femoral cortex in the intercondylar notch; c) at the 1.30 position. (With kind permission from Luites, 2015)

Validation

Various studies reported the accuracy of femoral tunnel placement using femoral drill guides [1, 31, 33] and aiming devices [9, 17, 28, 30–33, 60, 66, 72, 76, 78, 81–83]. The results, summarized in table 2, demonstrate that femoral drilling using an anatomical aimer results in more accurate tunnel placement than freehand drilling [32, 60, 66]. Most studies report that transtibial use of the EFA does not result in accurate anatomical positioning [1, 31, 78, 80, 85, Chapter 9]. However, Rue et al. demonstrated the opposite, with the guide at the 10.30 o'clock position resulting in a 50% overlap of the AM ánd PL footprint [72]. When the EFA was positioned through the medial portal, this resulted in more anatomical placement than transtibial use [30, 76, 83]. Nevertheless, the design of the guide, with an off set and a the tongue for placement behind the posterior cortex, obstructs rotating it towards a lower clock position, keeping the guide in full contact with the bone, due to the posterior border of the femoral condyle cartilage. Therefore it is not possible to reach the location for the ACL center reliable, even from a anteromedial approach; The PL center cannot be reached at all [9]. These result are not surprising, since the EFA was developed for isometrical tunnel placement in the more proximal zone of the AM insertion area, near the over the top position as demonstrated by the study of Gelber [31].

Some studies reported tunnel positioning with a regular wire pin through an accessory medial portal, without any guiding support, was more anatomical than transtibial tunnel placement using an EFA [27, 81]. However, these wire positioning were done by specialists, with over average arthroscopic ACL anatomy knowledge and ACL reconstruction experience.

Discussion

Numerous drill guides and aiming devices have been developed during history, following the evolving ACL reconstruction concepts. The guide designs have been influenced by several factors in these various concepts, in order to facilitate the selected goals during surgery. The choice between the drilling of suture canals or a large femoral tunnel, related to the fixation technique of the graft, influenced the guide design hardly. The surgical technique, facilitation during an arthrotomy or an arthroscopical procedure, resulted in a strong development of techniques and devices. The drilling direction from outside-in or inside-out, partly related to the aforementioned open or closed surgery technique, also influenced the guide design largely. The two concepts of anatomical and isometrical tunnel placement consist from the start of ACL reconstruction history. The isometrical concept experienced a highlight after the evolution of the arthroscopical procedure in the eighties and nineties. The previous aspects influenced the guide designs. Relative to the concept of isometry, it seemed to have evolved the other way around: a guide design influenced the development of a concept, at least of its popularity. During the arthroscopical procedure, femoral tunnel placement became more difficult since the surgeon had less vision and control relative to the open surgical technique. The EFA was developed to support arthroscopical transtibial tunnel placement. Its easy use definitely seemed to contribute to the popularity of the isometrical ACL reconstruction technique, until the revival of the anatomical concept at the beginning of this century. This resulted in usage of this popular guide in anatomical tunnel placement. And allthough anatomical placement can be achieved, positioning the guide through the anteromedial portal, this seems not the ideal situation. The EFA is not designed for his application, which influences the accuary in indivual usage.

Besides the division in tunnel placement concept, an important difference in the positioning protocol of guides has been found. The surgeon oriented drill guides have to be positioned accurately by the surgeon at a predetermined point, led by his anatomical knowledge and technical skills. The guides of the other group, the aiming devices, have designs which support the surgeon in correct placement of the guide and consequential tunnel placement. Especially, the aiming devices could be useful in ACL reconstruction for less experienced surgeons performing low volume of this type of surgery.

To be able to select the best guide for a certain surgical concept, knowledge about the accuracy in tunnel placement of the guide is important. Accurate femoral tunnel positioning is an important factor in all ACL reconstruction techniques. In vitro studies have shown that variations in tunnel and/or graft locations influence knee kinematics, whether it concerns isometric versus non-isometric [12, 86, 87], isometric versus anatomical [49, 55], or anatomical versus non-anatomical in single [55] or double-bundle ACL reconstructions [85]. Femoral tunnels placed too anterior can result in grafts that are tensed near extension and lax in flexion [55]. More vertical placed tunnels result in less rotational stability near extension, critical in the pivot shift phenomenon [49]. Double bundle techniques using double femoral tunnels increase the complexity of tunnel placement [35]. Besides that, femoral tunnel malpositioning is reported as the main cause of graft failure [53, 62] and an important factor related to a successful clinical outcome [24, 73, 84].

In the last 15 years only a few new guides have been described in literature [18, 31, 50, 60, 82, Chapter 9], despite the obvious development of multiple new guides, regarding the patents published on the internet. Accuracy results for the latest, anatomical guides, have not been published and validation studies for the EFA demonstrated the insufficient accuracy for anatomical tunnel placement. This lack in ACL surgery literature hinders surgeons choosing a valid femoral guide.

Besides guides, numerous other techniques to improve accurate femoral tunnel placement in ACL reconstruction have been developed. Anatomical position guidelines using the various imaging methods ranging from radiographs [10], CT-scans and MRI [79] and fluoroscopic computer overlays [44, 61], as well as techniques like (real time) computer assisted navigation and robotic systems. These latter systems achieved good accuracy results for anatomical tunnel placement with errors of 1.3 mm [64] and 2.9-3.2 mm [51]. Nevertheless, computer assistance for tunnel placement seemed to have disappeared from the ACL surgery room, probably due to relatively high costs against low returns and questionable clinical benefits [45, 54]. Hence, a validated femoral guide seems a good alternative to improve femoral tunnel placement against relatively low costs. That does not alter the situation, that the lack of clinical proof for the need of more accurate anatomical femoral tunnel placement is still a source for future studies, in which accurate measurement of postoperative tunnel location plays an important role [22].

Conclusion

Multiple femoral guides and aiming devices have been developed. They facilitate the various goals and concepts in femoral tunnel placement, following the evolution of the surgical ACL reconstruction concepts. Allthough, the EFA seemed to have influenced the popularity of the isometric concept largely. Since the EFA is not ideal for anatomical tunnel placement, the surgical concept of the last decade, new guides have been developed. The next step, which is often lacking, should be the validation of these guides, resulting in knowledge about the accuracy and, eventually, resulting in accurate clinical anatomical femoral tunnel placement.

Gelber 2011 [32]	EFA	5	AM	Quadrant method by Forsythe et al.[26]		In DS direction: 19.7% and in HL direction: 30.3% >Similar to the position of the AM insertion >4 mm deeper and higher than BullsEye
	Bullseye		AAM			In DS direction: 26.9% and in HL direction: 40.8% >intermediate position between the AM and PL bundles
Strauss 2011 [79]	EFA	6	TT	1. Distance native ACL center – guide pin 2. Overlap percentage of the reamed femoral tunnel and the native ACL femoral insertion site	7.6 ± 0.5-mm superior and posterior	Overlap with the native ACL femoral insertion 30.0% ± 12.6%, (most posterior-superior portion)
Celentao 2012 [17]	EFA	7	AAM†	Distance ACL center – position guide	A; 8.6 ± 1.8 mm B: 3.2 ± 1.5 C: 2.0 ± 0.9 mm	Angle required to place guide at position C: In frontal plane: 54°±11° (range 32°-68°) In axial plane: 44°±6° (range 36°-59°)
Tompkins 2012 [82]	EFA	7	TT	Distance center ACL – center tunnel aperture Tunnel aperture % contained within native footprint	6.0 ±1.9 mm	61.2% ± 24% of the tunnel within native femoral footprint
	Wire freehand		AcM		3.6 ± 1.2 mm	97.7% ± 5% of the tunnel within native femoral footprint
Gadikota 2012 [29]	EFA	7.5	TT	Distance center ACL – center tunnel aperture	3.0 ± 1.5 mm more anterior and proximal	27.1% ± 17.4% outside the ACL footprint
	Freehand		AM	Amount of coverage ACL insertion by the tunnels	2.1 ± 0.9 mm	13.6% ± 15.7% of the tunnel outside the ACL footprint
	Freehand		OutI		1.5 ± 1.2 mm	10.8% ± 10.8% of the tunnel outside the ACL footprint
Steiner 2012 [78]	EFA	6	TT	Distance center ACL – pin placed by instrument	5.8 ± 1.0 mm	
			AM		In centre	
	42 curved EFA Clancy		TT		In centre	
			AM		In centre	
Watanabe 2015 [83]	Special laser guide			Quadrant method		AM: DS 28.7% ± 6.7% and HL 23.8% ± 8.2% PL: DS 36.6% ± 6.8% and HL 48.4% ± 10.6%
Luites 2015 unpublished data	GAFT		AM†	Distance ACL center – marked position guide during visual placement	ACL: 1.8 ± 0.9 mm (0.2-3.2) AM: 1.6 ± 0.9 mm (0.4-2.9) PL: 1.9 ± 1.0 mm (0.6-3.9)	
	GAFT		AM†	Distance ACL center – marked position guide during arthroscopic placement Average means for 5 clinicians.	ACL: 3.0 ± 1.5 mm (0.9-7.1) AM: 2.7 ± 1.3 mm (0.9-6.6) PL: 2.8 ± 1.7 mm (0.2-6.4)	
	EFA		TTγ	Distance ACL center – marked position guide during visual placement	10h: 2.8 ± 1.5 mm (0.2-5.4) 11h: 4.1 ± 1.1 mm (2.4-6.0)	

**recalculated by this study to distance between 25%/25% position and the tunnel center (screw); †simulated*

Table 2. Accuracy of femoral guides and aiming devices

Study	Guide	OS	Tech	Measurements	Distance native center - tunnel	Result other measurements
Good 1987 [33]	Inside-out	-	Mini-arthro-tomy	Position at lateral radiograph %BS in deep-shallow direction		Native center: 66±4% (ca 2 mm) Guide: 67±5% (ca 2.5 mm) 76% of femoral tunnels within ±SD (2 mm) of native center
	Freehand					Freehand: 60±8% (ca 4 mm) 47% of femoral tunnels within ±SD (2 mm) of native center
Grøntvedt 1996 [34]	Rear entry	-	Rear	Distance marked ACL center – tunnel center in 3D coordinate system	Ca. 4 mm anterior	
	EFA	7	TT		ca. 2 mm anterior and 4 mm more proximal	
Milankov 2000 [61]	Inside-out			Distances at the intercondylar notch per- and postoperative* Quadrant method [10]	Total 2.5 mm: Deep-shallow: 1.8 mm High-low: 1.4 mm	In high-low direction at: 28.46±2.29% instead of 25%
	Quadrant method			Corel Draw 8	5.9 mm, mostly deep-shallow	In high-low direction at: 35.31±7.1% instead of 25%
Wiwattana-warang 2005 [84]	EFA	?	TT	Distance ACL center - femoral tunnel entry point	10.36 mm	
			AM		9.67 mm	
Rue 2008 [74]	EFA	7	TT		AM: 4.2 ± 1.5 mm (2.3-6.0) PL: 4.1 ± 1.2 mm (2.7-6.0)	AM 50% ± 23% (2%-83%) PL 51% ± 24% (16%-97%)
Gavriilidis 2008 [31]	EFA	6	TT	Method 1. Distance closest point ACL footprint (margin) - guide wire (tunnel) Method 2. Distance posterior part femoral condyle - center tunnel		1. Median 6.20 mm (range 5.80–6.70 mm) 2. Median 6.10 mm (range 5.80–6.40 mm)
			AM			1. Median 2.80 mm (range 2.40–3.10 mm) 2. Median 5.25 mm (range 4.90–5.60 mm)
Abebe 2009 [1]	EFA	7	TT	ACL center intact knee – tunnel center using 3D modeling in 2D sagittal plane	Total 8.5±2.1 mm 5.0 ± 1.6 mm anterior 5.7 ± 3.4 mm superior	
	Rear entry	-	AM		Total 3.2±1.0 mm: 0.9 ± 1.8 mm posterior 1.7 ± 1.7 mm superior	
Behrendt 2010 [9]	EFA	7	AM	Mm K-wire tot center ACL Mm/% at deep-shallow direction of the ACL length DS	5 knees 1.5-2.0 mm In 5 knees 3-4 mm In 6 knees 4.5-6 mm	Length ACL: 15 mm (range 14-18 mm) K-wire to AM end 5 mm (range 3-8 mm) K-wire to PL end 10 mm (range 9-12 mm) = at 69% of ACL-insertion (range 55-80%)

References

1. Abebe ES, Moorman CT, Dziedzic TS, Spritzer CE, Cothran RL, Taylor DC, Garrett WE, DeFrate LE (2009) Femoral tunnel placement during anterior cruciate ligament reconstruction: an in vivo imaging analysis comparing transtibial and 2-incision tibial tunnel-independent techniques. Am J Sports Med 37:1904–1911.
2. Adams R (1847) Abnormal conditions of the knee joint. In Todd RB (ed) Cyclop Anat Physiol vol III Sherwood Gilbert Piper, London 48–78.
3. Aglietti P, Buzzi R, D'Andria S, Zaccherotti G (1992) Arthroscopic anterior cruciate ligament reconstruction with patellar tendon. Arthroscopy 8:510–516.
4. Amis AA, Beynnon B, Blankevoort L, Chambat P, Christel P, Durselen L, Friederich N, Grood E, Hertel P, Jakob R, Müller W, O'Brien M, O'Connor J (1994) Proceedings of the ESSKA Scientific Workshop on Reconstruction of the Anterior and Posterior Cruciate Ligaments. Knee Surg Sport Traumatol Arthrosc 2:124–132.
5. Amis AA, Zavras T (1995) Isometricity and graft placement during anterior cruciate ligament reconstruction. Knee 2:5–17.
6. Arnold MP, Kooloos J, Kampen A (2001) Single-incision technique misses the anatomical femoral anterior cruciate ligament insertion: a cadaver study. Knee Surg Sport Traumatol Arthrosc 9:194–199.
7. Bassi PB, Fioriti M, Bassi (1990) A new guide in the surgical reconstruction of the cruciate ligaments. Ital J Orthop Traumatol 16:215–219.
8. Bedi A, Altchek DW (2009) The "footprint" anterior cruciate ligament technique: an anatomic approach to anterior cruciate ligament reconstruction. Arthroscopy 25:1128–1138.
9. Behrendt S, Richter J (2010) Anterior cruciate ligament reconstruction: drilling a femoral posterolateral tunnel cannot be accomplished using an over-the-top step-off drill guide. Knee Surg Sports Traumatol Arthrosc 18:1252–1256.
10. Bernard M, Hertel P, Hornung H, Cierpinski T (1997) Femoral insertion of the ACL. Radiographic quadrant method. Am J Knee Surg 10:14–21.
11. Beyer AH (1988) A unitunnel technique for arthroscopic anterior cruciate ligament reconstruction. Bull Hosp Jt Dis Orthop Inst 48:164–169.
12. Blankevoort L, Huiskes R, Kampen A Van (1991) ACL reconstruction: simply a matter of isometry? Passiv motion Charact Hum knee Exp Comput simulations PhD thesis, University of Nijmegen, pp 151–162.
13. Blauth W (1984) Die zweizügelige Ersatzplastik des vorderen Kreuzband der Quadricepssehne. [2-strip substitution-plasty ofthe anterior cruciate ligament with the quadriceps tendon]. Unfallheilkunde 87:45–51.
14. Bray RC, Dandy DJ (1987) Comparison of Artliroscopic and Open Techniques in Carbon Fibre Reconstruction of the Anterior Cruciate Ligament : Long-Term Follow-up After 5 Years. Arthroscopy 3:106–110.
15. Cain EL, Clancy WG (2002) Anatomic endoscopic anterior cruciate ligament reconstruction with patella tendon autograft. Orthop Clin North Am 33:717–725.
16. Cazenave A, Laboureau JP (1990) [Reconstruction of the anterior cruciate ligament. Determination of the pre- and peroperative femoral isometric point]. Rev Chir Orthop Reparatrice Appar Mot 76:288–292.
17. Celentano U, Cardoso MPA, Martins CAQ, Ramirez CP, van Eck CF, Smolinski P, Fu FH (2012) Use of transtibial aimer via the accessory anteromedial portal to identify the center of the ACL footprint. Knee Surg Sports Traumatol Arthrosc 20:69–74.
18. Christel P, Sahasrabudhe A, Basdekis G (2008) Anatomic double-bundle anterior cruciate ligament reconstruction with anatomic aimers. Arthroscopy 24:1146–1151.
19. Clancy WG (2015) Anatomic ACL reconstruction: The final answer? Knee Surg Sports Traumatol Arthrosc 23:636–639.
20. Cowan D (1963) Reconstruction of the Anterior Cruciate Ligament by the Method of Kenneth Jones (1963). Proc R Soc Med 336–338.

21. Dandy DJ, Flanagan JP, Steenmeyer V (1982) Arthroscopy and the Management of the Ruptured Anterior Cruciate Ligament. Clin Orthop Relat Res 167:43–49.
22. van Eck CF, Schreiber VM, Mejia HA, Samuelsson K, van Dijk CN, Karlsson J, Fu FH (2010) “Anatomic” anterior cruciate ligament reconstruction: a systematic review of surgical techniques and reporting of surgical data. Arthroscopy 26:S2–12.
23. Eriksson E (1976) Sports injuries of the knee ligaments: their diagnosis, treatment, rehabilitation, and prevention. Med Sci Sport 8:133–144.
24. Fernandes TL, Fregni F, Weaver K, Pedrinelli A, Camanho GL, Hernandez AJ (2014) The influence of femoral tunnel position in single-bundle ACL reconstruction on functional outcomes and return to sports. Knee Surg Sports Traumatol Arthrosc 22:97–103.
25. Fick R (1911) Handbuch der Anatomie und Mechanik der Gelenke. 3 Teil: Spezielle Gelenk- und Muskelmechanik. Gustav Fischer, Jena.
26. Friederich NF, O’Brien WR (1998) Anterior cruciate ligament graft tensioning versus knee stability. Knee Surg Sports Traumatol Arthrosc 6 Suppl 1:S38–S42.
27. Gadikota H, Sim J, Behrendt S, Richter J (2010) Anterior cruciate ligament reconstruction: drilling a femoral posterolateral tunnel cannot be accomplished using an over-the-top step-off drill guide. Knee Surg Sports Traumatol Arthrosc 18:1252–1256.
28. Gadikota HR, Sim JA, Hosseini A, Gill TJ, Li G (2012) The Relationship Between Femoral Tunnels Created by the Transtibial, Anteromedial Portal, and Outside-In Techniques and the Anterior Cruciate Ligament Footprint. Am J Sports Med 40:882–888.
29. Galen C (1968) On the usefulness of parts of the body (trans: May MT). Cornell Univ Press New York.
30. Gavriilidis I, Motsis EK, Pakos EE, Georgoulis AD, Mitsionis G, Xenakis TA (2008) Transtibial versus anteromedial portal of the femoral tunnel in ACL reconstruction: a cadaveric study. Knee 15:364–367.
31. Gelber PE, Erquicia J, Abat F, Torres R, Pelfort X, Rodriguez-Baeza A, Alomar X, Monllau JC (2011) Effectiveness of a footprint guide to establish an anatomic femoral tunnel in anterior cruciate ligament reconstruction: computed tomography evaluation in a cadaveric model. Arthroscopy 27:817–824.
32. Good L, Odensten M, Gillquist J (1987) Precision in reconstruction of the anterior cruciate ligament: A new positioning device compared with hand drilling. Acta Orthop 58:658–661.
33. Grøntvedt T, Pena F, Engebretsen L (1996) Accuracy of femoral tunnel placement and resulting graft force using one-or two-incision drill guides. A cadaver study on ten paired knees. Arthroscopy 12:187–192.
34. Hardin GT, Bach BR, Bush-Joseph CA (2003) Endoscopic Single-Incision Anterior Cruciate Ligament Reconstruction Using Patellar Tendon Autograft Surgical Technique. Am J Knee Surg 16:135–144.
35. Harner CD, Poehling GG (2004) Double bundle or double trouble? Arthroscopy 20:1013–1014.
36. Hefzy MS, Grood ES, Noyes FR Factors affecting the region of most isometric femoral attachments. Part II: The anterior cruciate ligament. Am J Sports Med 17:208–216.
37. Hernandez A (1993) Universal coupled isometric guide for ligament reconstruction of the knee (“ G.U.L.A .”). Rev Paul Med 111:422–426.
38. Hesse E (1914) Über den Ersatz der Kreuzbänder des Kniegelenkes durch freie Fascientransplantation [On the replacement of the cruciate ligaments with transplanted free fascia grafts]. Verh Dtsch Ges Chir 188–189.
39. Hewson GF (1983) Drill guides for improving accuracy in anterior cruciate ligament repair and reconstruction. Clin Orthop Relat Res 119–124.
40. Hey Groves E (1917) Operation for the repair of crucial ligaments. Lancet 674–675.
41. Hippocrates (1928) On wounds in the head. In: the surgery fractures joints (trans: Whittington ET). Loeb Class Libr vol III William Heinemann, London Harvard Univ Press Cambridge, MA.
42. Jones KG (1963) Reconstruction of the anterior cruciate ligament using the central one-third of the patellar ligament. J Bone Joint Surg Am 45:925–932.

43. Kariya Y, Kurosawa H (1989) Arthroscopically aided anterior cruciate ligament reconstruction using a new drill wire guide. Arthroscopy 5:227–231.
44. Klos T V, Habets RJ, Banks AZ, Banks SA, Devilee RJ, Cook FF (1998) Computer assistance in arthroscopic anterior cruciate ligament reconstruction. Clin Orthop Relat Res 65–69.
45. Klos TVS (2014) Computer-assisted Anterior Cruciate Ligament Reconstruction. Four Generations of Development and Usage. Sport Med Arthrosc Rev 22:229–236.
46. Laboureau JP, Marnat-Perrichet F (1997) Isometric Reconstruction of the Anterior Cruciate Ligament: Femoral and Tibial Tunnel Placement. In Yahia L (ed) Ligaments and Ligamentoplasties Springer Berlin Heidelberg, pp 209–225.
47. Lam S (1968) Reconstruction of the Anterior Cruciate Ligament Using the Jones Procedure an Its Guy’s Hospital Modification. J Bone Jt Surg Br 50-A:1213–1224.
48. Lindstrand A, Stenstrom A, Tjornstrand B (1982) The Lund Drill Guide An Instrument for Repair or Reconstruction of the Cruciate Ligaments. Arch Orthop Trauma Surg 99:231–233.
49. Loh JC, Fukuda Y, Tsuda E, Steadman RJ, Fu FH, Woo SLY (2003) Knee stability and graft function following anterior cruciate ligament reconstruction: Comparison between 11 o’clock and 10 o’clock femoral tunnel placement. 2002 Richard O’Connor Award paper. Arthroscopy 19:297–304.
50. Lubowitz JH (2009) Anteromedial portal technique for the anterior cruciate ligament femoral socket: pitfalls and solutions. Arthroscopy 25:95–101.
51. Luites JWH, Wymenga AB, Blankevoort L, Eygendaal D, Verdonschot N (2014) Accuracy of a computer-assisted planning and placement system for anatomical femoral tunnel positioning in anterior cruciate ligament reconstruction. Int J Med Robot Comput Assist Surg 10:438–446.
52. Marans H, Hendrix M, Paterson R (1992) A new femoral drill guide for arthroscopically assisted anterior cruciate ligament replacement. Arthroscopy 8:234–238.
53. Marchant BG, Noyes FR, Barber-Westin SD, Fleckenstein C (2010) Prevalence of nonanatomical graft placement in a series of failed anterior cruciate ligament reconstructions. Am J Sports Med 38:1987–1996.
54. Margier J, Tchouda SD, Banihachemi J-J, Bosson J-L, Plaweski S (2015) Computer-assisted navigation in ACL reconstruction is attractive but not yet cost efficient. Knee Surg Sports Traumatol Arthrosc 23:1026–1034.
55. Markolf KL, Hame S, Hunter DM, Oakes DA, Zoric B, Gause P, Finerman GAM (2002) Effects of femoral tunnel placement on knee laxity and forces in an anterior cruciate ligament graft. J Orthop Res 20:1016–1024.
56. Marshall JL, Warren RF, Wickiewicz TL, Reider B (1979) The anterior cruciate ligament: a technique of repair and reconstruction. Clin Orthop Relat Res 97–106.
57. Mattheck C, Huber-Betzer H, Börner M (1991) Ein neues Zielgerat und zwel neue Kreuzbandanker zur Befestigung von prothetischem Kreuzbandersatz am Femur. Biomed Tech 36:20–23.
58. Mayo Robson A (1903) Ruptured crucial ligaments and their repair by operation. Ann Surg 37:716–718.
59. McGuire D, Hendricks S, Grinstead G (1996) Use of an endoscopic aimer for femoral tunnel placement in anterior cruciate ligament reconstruction. Arthroscopy 12:26–31.
60. Milankov M, Miljkovic N (2000) A new positioning device for precise femoral insertion of the anterior cruciate ligament autograft. Knee Surg Sports Traumatol Arthrosc 8:149–153.
61. Moloney G, Araujo P, Rabuck S, Carey R, Rincon G, Zhang X, Harner C (2013) Use of a fluoroscopic overlay to assist arthroscopic anterior cruciate ligament reconstruction. Am J Sports Med 41:1794–1800.
62. Morgan JA, Dahm D, Levy B, Stuart MJ (2012) Femoral Tunnel Malposition in ACL Revision Reconstruction. J Knee Surg 25:361–368.
63. Müller W (1992) Treatment of acute Tears. In Jakob R, Staübl H-J (eds) knee cruciate ligaments Springer Heidelberg, Berlin, Berlin, Heidelberg, pp 279–288.
64. Musahl V, Burkart A, Debski RE, Van Scyoc A, Fu FH, Woo SLY (2003) Anterior cruciate ligament tunnel placement: Comparison of insertion site anatomy with the guidelines of a computer-assisted surgical system. Arthroscopy

19:154–160.
65. O'Donoghue DH (1963) A method for the replacement of the Anterior Cruciate Ligament of the knee. J Bone Joint Surg Am 45:905–924.
66. Odensten M, Gillquist J (1986) A modified technique for anterior cruciate ligament (ACL) surgery using a new drill guide system for isometric positioning of the ACL. Clin Orthop Relat Res 213:154–158.
67. Odensten M, Gillquist J (1985) Functional anatomy of the anterior cruciate ligament and a rationale for reconstruction. J Bone Jt Surg Am 67:257–262.
68. Palmer I (1938) On the injuries to the ligaments of the knee joint: A clinical study. Acta Chir Scand 91:1–282.
69. Piefer JW, Pflugner TR, Hwang MD, Lubowitz JH (2012) Anterior cruciate ligament femoral footprint anatomy: systematic review of the 21st century literature. Arthroscopy 28:872–881.
70. Rasmussen JF, Lavery KP, Dhawan A (2013) Anatomic anterior cruciate ligament reconstruction with a flexible reamer system and 70° arthroscope. Arthrosc Tech 2:e319–322.
71. Raunest J (1991) Application of a new positioning device for isometric replacement in anterior cruciate ligament repair and reconstruction. J Trauma 31:223–229.
72. Rhinelander FW, Brahms MA (1970) Modification of C-clamp for use in restoration of cruciate ligaments. Clin Orthop Relat Res 71:217–218.
73. Rue J-PH, Ghodadra N, Bach BR (2008) Femoral tunnel placement in single-bundle anterior cruciate ligament reconstruction: a cadaveric study relating transtibial lateralized femoral tunnel position to the anteromedial and posterolateral bundle femoral origins of the anterior cruciate ligament. Am J Sports Med 36:73–79.
74. Sadoghi P, Kröpfl A, Jansson V, Müller PE, Pietschmann MF, Fischmeister MF (2011) Impact of tibial and femoral tunnel position on clinical results after anterior cruciate ligament reconstruction. Arthroscopy 27:355–364.
75. Sidles JA, Larson R V, Garbini JL, Downey DJ, Matsen FA (1988) Ligament length relationships in the moving knee. J Orthop Res 6:593–610.
76. Steiner M (2010) Independent Drilling of Tibial and Femoral Tunnels in Anterior Cruciate Ligament Reconstruction. J Knee Surg 22:171–176.
77. Steiner ME, Smart LR (2012) Flexible instruments outperform rigid instruments to place anatomic anterior cruciate ligament femoral tunnels without hyperflexion. Arthroscopy 28:835–843.
78. Stewart J (1969) Athletic injuries particularly to the ligaments of the knee: Diagnosis, repair and physical rehabilitation. Am J Orthop 52–57.
79. Strauss EJ, Barker JU, McGill K, Cole BJ, Bach BR, Verma NN (2011) Can anatomic femoral tunnel placement be achieved using a transtibial technique for hamstring anterior cruciate ligament reconstruction? Am J Sports Med 39:1263–1269.
80. Tanaka Y, Shiozaki Y, Yonetani Y, Kanamoto T, Tsujii A, Horibe S (2011) MRI analysis of the attachment of the anteromedial and posterolateral bundles of anterior cruciate ligament using coronal oblique images. Knee Surg Sports Traumatol Arthrosc 19 Suppl 1:S54–59.
81. Theve N, Häggmark T, Engberg T (1975) A drill guide for repair of the anterior cruciate ligament of the knee. Acta Chir Scand 141:82–84.
82. Tompkins M, Milewski MD, Brockmeier SF, Gaskin CM, Hart JM, Miller MD (2012) Anatomic femoral tunnel drilling in anterior cruciate ligament reconstruction: use of an accessory medial portal versus traditional transtibial drilling. Am J Sports Med 40:1313–1321.
83. Watanabe S, Takahashi T, Hino K, Kutsuna T, Ohnishi Y, Ishimaru M, Miura H (2015) Short-Term Study of the Outcome of a New Instrument for All-Inside Double-Bundle Anterior Cruciate Ligament Reconstruction. Arthroscopy 31:1893–1902.
84. Wiwattanawaran N, Rujiwetponstorn V (2005) Positioning of femoral tunnel in anterior cruciate ligament reconstruction using femoral aimer guide. J Med Assoc Thai 88:1545–1550.
85. Yasuda K, Kondo E, Ichiyama H, Tanabe Y, Tohyama H (2006) Clinical evaluation of anatomic double-bundle ante-

rior cruciate ligament reconstruction procedure using hamstring tendon grafts: comparisons among 3 different procedures. Arthroscopy 22:240–251.

86. Zantop T, Diermann N, Schumacher T, Schanz S, Fu FH, Petersen W (2008) Anatomical and nonanatomical double-bundle anterior cruciate ligament reconstruction: importance of femoral tunnel location on knee kinematics. Am J Sports Med 36:678–685.
87. Zavras TD, Race A, Bull MJ, Amis AA (2000) A comparative study of ’isometric’ points for anterior cruciate ligament graft attachment. Knee Surg Sport Traumatol Arthrosc 9:28–33.
88. Zavras TD, Race A, Amis AA (2005) The effect of femoral attachment location on anterior cruciate ligament reconstruction: graft tension patterns and restoration of normal anterior-posterior laxity patterns. Knee Surg Sports Traumatol Arthrosc 13:92–100.

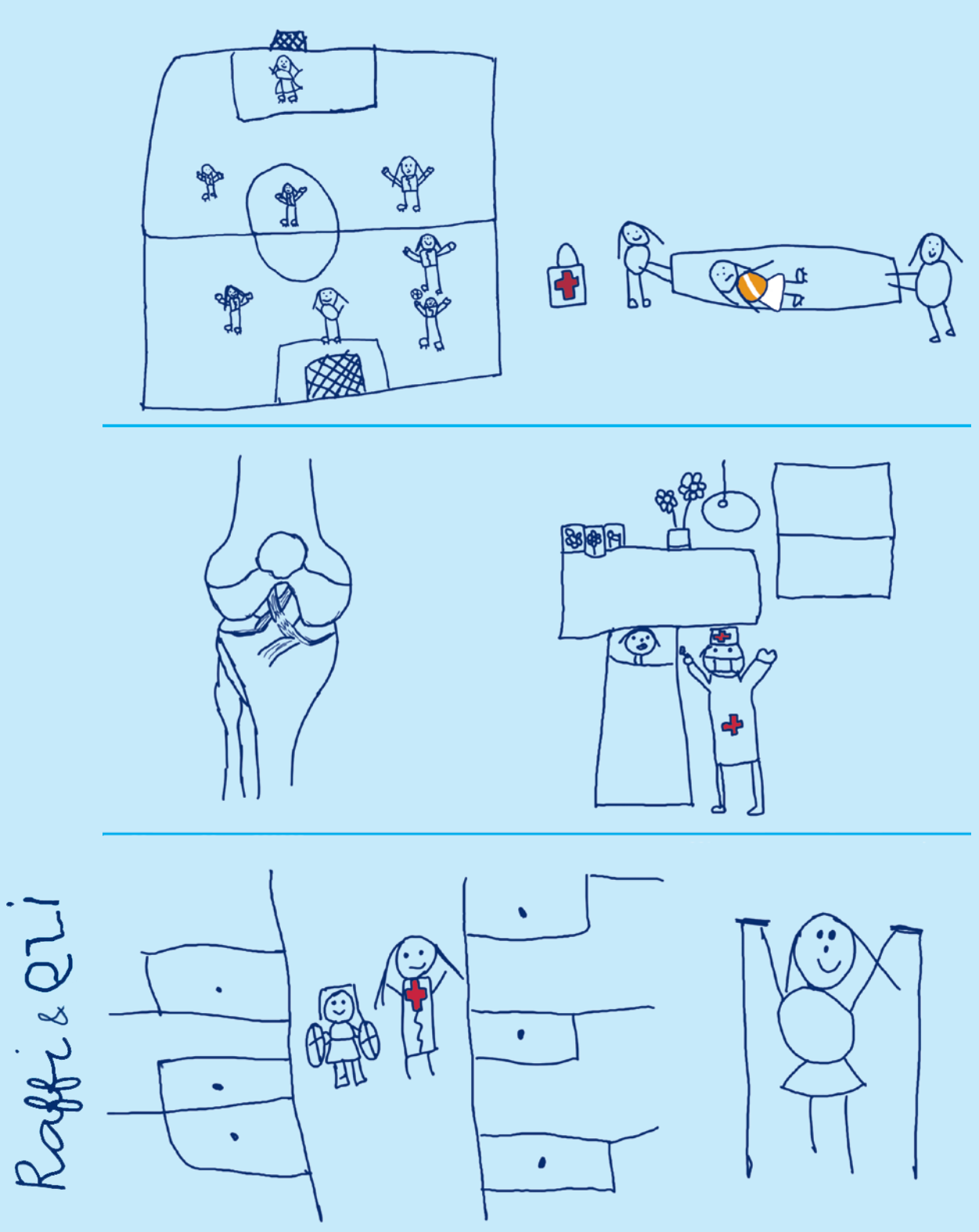
Raffi & Eli

CHAPTER 9

GAFT: An accurate guide for anatomical femoral tunnel placement in double or single bundle ACL reconstruction

Joan W.H. Luites, Ate B. Wymenga and Nico Verdonschot

Abstract

Purpose

The validation of a new guide for anatomical femoral tunnel (GAFT) placement in double bundle anterior cruciate ligament (ACL) reconstruction, determining 1) the correctness of the design and 2) the accuracy of protocolled arthroscopical placement by first users.

Methods

In 12 cadaveric femora, with marked positions of the actual ACL, anteromedial (AM) and posterolateral (PL) insertions, the design was tested, determining the tunnel mark locations placed with the GAFT under visual control. The accuracy of arthroscopical placement was determined with the tunnel locations marked by five physicians using the GAFT from the arthroscopic view. Placement errors, calculated as the distance between insertion centers and tunnel marks were defined as 'accurate' (<3 mm), 'incorrect' (>5 mm) and 'intermediate' (3-5 mm); performances as 'excellent' (>90% accurate tunnel locations) and 'moderate' (>20% incorrect).

Results

100% AM, 92% ACL and 83% PL tunnel marks placed with the GAFT under visual control were accurate, with mean placement errors of 1.6±0.9 mm (AM), 1.8±0.9 mm (ACL) and 1.9±1.0 mm (PL). Performances of physicians, placing the GAFT in the arthroscopic view, varied between excellent and moderate, with mean errors between 1.7±0.5 mm and 3.5±2.3 mm. Overall 58% of the tunnel marks was accurate, 33% intermediate and 9% incorrect.

Conclusion

The results of this study confirm the experimental validity of the GAFT design and its protocolled arthroscopical use by first users. Although the design enables accurate tunnel mark placement, the study also highlights that not following the placement protocol results in undesirable variations including incorrect placement.

Introduction

In the last decade, the anatomical double bundle concept replacing a ruptured anterior cruciate ligament (ACL) has become popular. This technique reconstructs the functional anteromedial (AM) and posterolateral (PL) bundles [12], through tunnels at their anatomical insertion. Correct anatomical tunnel positioning is important, especially regarding the femoral tunnel, since this factor influences knee kinematics [22, 35]. However, malpositioning is the main cause of graft failure [21, 27] and an important factor related to unsuccessful clinical outcome [8, 32].

To facilitate positioning of the femoral tunnel holes, aiming devices and drill guides have been used from the early history of ACL reconstruction. The most well-known and widely used femoral guide is the endoscopic femoral aimer (EFA) [25], described by McGuire et al. in 1996 [24]. This offset guide, based on the concept of Paterson [20], is introduced through the tibial tunnel. Its tongue is positioned behind the posterior cortex of the intercondylar notch, a physical reference for the guide, aiming at the 11 (right knee) or 1 (left knee) o'clock position. McGuire et al. [24] defined the resulting tunnel location as an anatomic tunnel placement. However, others called this 'over-the-top position' the isometric spot [20]; a tunnel at this position resulted in an isometrical ACL reconstruction, conform the concept of the late eighties [29], replacing the more or less isometrically acting AM bundle [12].

As the anatomical reconstruction concept gained popularity in the late nineties, the standard EFA offset guide has been used to facilitate anatomical tunnel positions [16]. However, the possibilities of using this guide with the transtibial (TT) technique in single or double bundle anatomic ACL reconstructions are limited. The lowest accurate position, rotating the EFA as laterally as possible, is tunnel placement at 10.30 in the AM center [2]. The ACL center, towards 10 o'clock, cannot be reached [1, 2, 9]. Various solutions have been introduced such as modified TT techniques [30], the introduction of the guide through the AM portal [1, 15] which is easier and more accurate [7]; or an adjusted EFA, the Transportal Femoral Guide (TPG) [17]. Its 30° angled, longer offset tip minimizes impingement and improves stabilization over the back wall, positioning it through the AM portal at 10 o'clock. However, the center of the PL bundle cannot be reached, because the cartilage of the lateral femoral condyle limits access [2]. Gelber et al. [11] and Christel et al. [6] reported alternatives for the offset guides, although these designs use no physical reference. Other surgeons do not use femoral aiming devices, but a curved drill guide and flexible reamers [5], a microfracture awl [33], or only a guidewire either transtibial [3] or through the AM portal [9].

Positioning femoral tunnels without the aid of an aiming device, or a guide without an objective placement protocol supported by a design using femoral landmarks as physical reference, means that tunnel placement depends completely on the surgeon's knowledge, skill and experience. However, it should be noted that 85% of the ACL-surgeons in the US perform less than 10 ACL reconstructions on an annual basis [10].

As far as the authors know, no aiming device for placement of the tunnels in anatomical single and double bundle ACL reconstruction has been validated and reported in literature. Based on anatomical measurements [19], we developed an aiming guide for anatomical femoral tunnel placement (GAFT) (Figure 1A). The average positions of the centers of the ACL and the AM and

PL bundles in 35 femora relative to landmarks in the intercondylar notch, have been transferred into the design of a device (Figure 1B-C). The guide is builds upon the concept of the EFA, also using the structures of the femoral notch as reference for correct and stable guide placement. Positioning the tongue of the GAFT behind the femoral cortex at the transition of the notch roof and notch wall, at 10.30 or 1.30, places the tubes towards the notch wall, resulting in tunnel mark placement at the center of the ACL for anatomical single bundle reconstruction or at the AM and PL centers for double bundle reconstruction (Figure 1D-G). The purpose of the current study was to validate the new guide, determining 1) the correctness of the guide design and 2) the accuracy of tunnel mark placement with the guide during application in an arthroscopical placement procedure by first users.

Figure 1. Dorsal view at the distal femur with the marked insertions of the actual ACL, divided in a proximal anteromedial (AM) part and a distal posterolateral (PL) part.

Material and methods

The validity of the guide was determined in cadaveric femora, in which the anatomical insertion sites were marked to be able to calculate the positions of the actual anatomical insertion centers. For this purpose twelve knee joints of unknown sex and age (pairs excluded), preserved in formalin and without gross deformation of the bony structures, were dissected. The ACL was separated in AM and PL fibers applying passive translation during flexion (tension of AM fibers) and extension (tension of the PL fibers) of the knee with intact ligaments and menisci. The separation was continued till the femoral insertion site and the tibial attachment site. After dissection of all tissue, both bundles were removed from the insertion sites, including the fan-like extension fibers [26], marking the insertion outlines with ink (Figure 2). Subsequently, two experiments were conducted positioning the guide in the twelve femora to determine 1) the correctness of the guide design and 2) the accuracy of tunnel placement with the guide during application in a protocolled arthroscopical placement procedure.

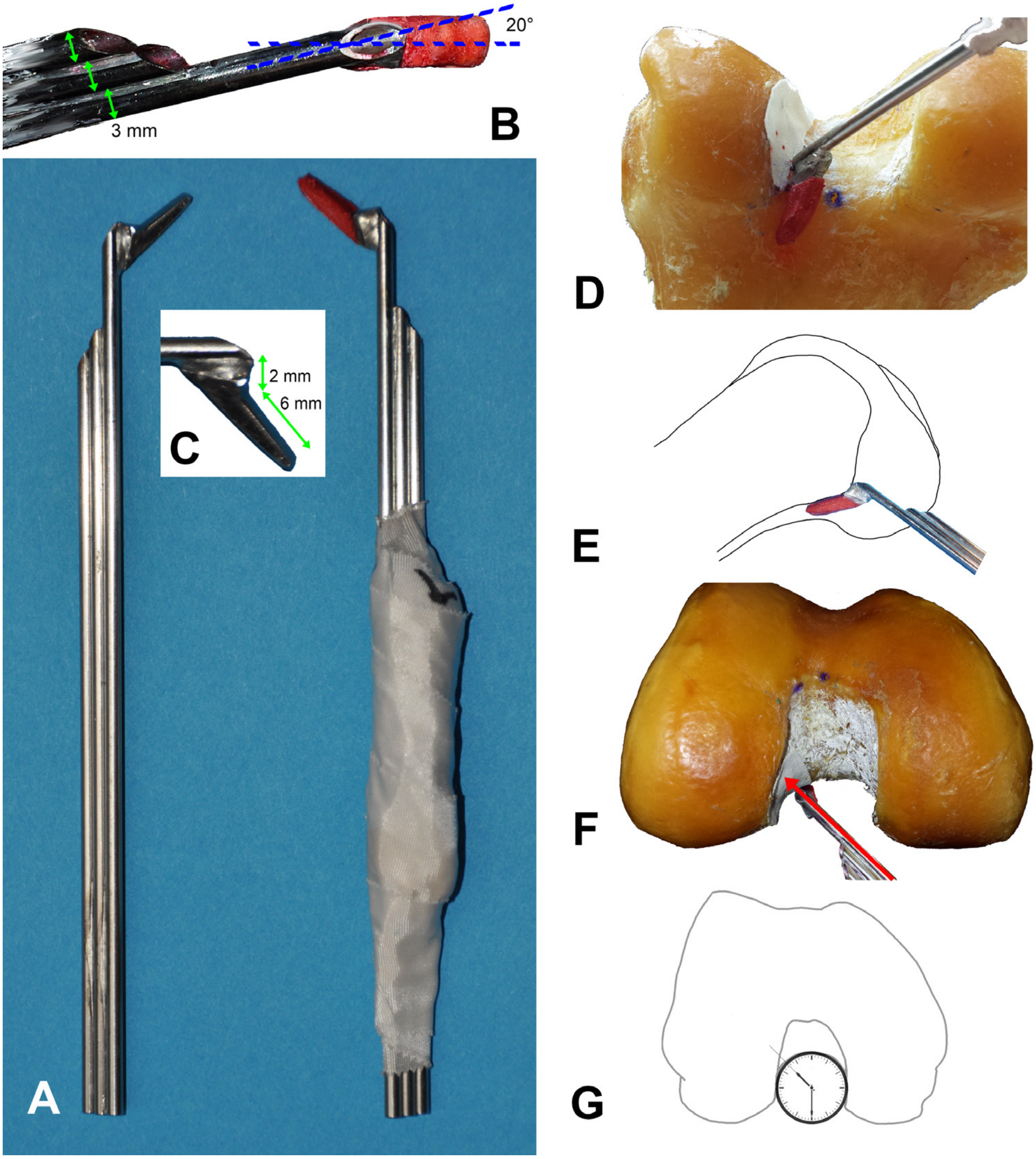

Figure 2. A) The GAFT, guide for anatomic femoral tunnel placement in single bundle or double bundle ACL reconstructions. B) It consists of three tubes (diameter 3 mm), with a tongue positioned at an angle of 20° towards lateral to the AM tube and C) an offset of 2 mm, resulting in two guides: for left (prepared for the experiments with red marked part and 'handle') and right knees. D) The guide placement protocol prescribes placement of the posterior offset part above the tongue (red part) against the posterior cortex and femoral condyle and E) the tongue behind the cortex, F) from an anteromedial approach in a 120° flexed knee, at the transition of the roof and wall of the intercondylar notch, which is defined as the (G) 10.30 (left) or 1.30 (right) o'clock position, with the notch wall in vertical position. The applied angles locate the tubes for AM (red point), ACL (green point) and PL (blue point) tunnels at the correct position near the anatomical insertion centers.

1) Correctness of GAFT design

The correctness of the design in combination with the placement protocol is determined positioning the GAFT under optimal conditions without obstructing factors, i.e. under direct visual control, in the intercondylar femoral notch according to the placement protocol by a researcher (JL). The approach simulates introduction of the guide through an anteromedial portal in a femur positioned in 120° of knee flexion. The tongue was positioned behind the posterior edge at the transition of the notch roof and wall with the extension of the handgrip at the 10.30/1.30 o'clock position for right/left femora, relative to the outlet of the posterior intercondylar notch (Figure 1 D-G). The locations of the ACL, AM and PL tunnels were marked, inserting an in ink dipped K-wire through the three tubes of the device (set 1A, 1B and 1C). Later, the distances of the tunnel marks relative to the actual anatomical insertion centers, the placement error, were calculated.

To be able to interpret the results achieved with the GAFT, this experiment was repeated with a commercially available EFA with a 7-mm offset (Arthrex, Naples, USA). The femur was fixed at 90° of flexion and the researcher positioned the EFA in the intercondylar notch simulating a transtibial approach. First the tongue was positioned at the original isometric position of 11/1 o'clock, the position of the AM bundle in left/right femora. Secondly, the guide was positioned at 10/2 o'clock, the assumed position for the ACL center. Both tunnel positions were marked (set 2A and 2B) to be able to determine the distances relative to the actual anatomical insertion AM and ACL centers.

2) Accuracy of protocolled arthroscopical tunnel placement with the GAFT

The GAFT placement protocol, consisting of visual (Figure 1 D-G) and textual instructions, was send to five orthopedic trained professionals with various arthroscopic experience in knee joint examinations and ACL reconstructions using different techniques (Table 1). During the experiment, the physicians saw and used the GAFT for the first time. To simulate arthroscopic conditions, an endoscopic camera was used, creating an arthroscopic view of the intercondylar notch on a monitor. With the femur positioned under an angle of 120°, the instruments were guided through artificial portals, the GAFT from medial and the endoscope from lateral, to restrict motility (Figure 3). All physicians placed the GAFT under arthroscopic control looking at the monitor, according to the guide placement protocol in the twelve femora. The three tunnel locations (ACL, AM and PL) of all measurement sessions with the five physicians were marked (set 3A-C until set 7A-7C) to be able to determine the distances relative to the actual anatomical insertion centers.

Figure 3. The GAFT was placed under arthroscopic control, looking at the monitor, with the femur positioned under an angle of 120°. The GAFT (from medial) and the endoscope (from lateral) were guided through artificial portals to restrict motility.

Table 1. The positions of the ACL, AM and PL centers relative to the femoral dimensions (%) in 6 femurs (A-F)

	Experience	**Performed arthroscopic interventions**	**Attended ACL reconstructions**	**Performed ACL-reconstructions**	**Technique**
1	**Surgeon 1.5y**	450	100	30	transtibial
2	**Resident 5.5y**	120	60	20	50% transtibial 50% anatomic
3	**Resident 5.5y**	66	10	16	anatomic
4	**Resident 5y**	15	10	2	transtibial anatomic
5	**Resident 5y**	20	20	0	-

Data collection and processing

The correctness of the GAFT design and the accuracy of the protocolled arthroscopical tunnel placement with the GAFT were described with the tunnel placement error. This placement error was defined as the distance between the positions of the actual anatomical insertion centers and the tunnel location marks at the bony surface. First, the 3-dimensional (3D) coordinates of various points in the intercondylar notch were digitized using an optical tracking system (Polaris, NDI Medical, Ontario Canada), accuracy 0.35 mm. This included:

- points at the marked outline of the ACL, AM and PL insertions,
- points at the surface of the notch wall at the medial side of the lateral condyle,
- points of the ACL, AM and PL tunnel location marks from the GAFT,
- points of the 10 and 11 o'clock tunnel location marks from the EFA.

In the second step, the 3D coordinates of all these points were loaded into an in-house created software program designed in MATLAB (version 7, The MathWorks Inc., Natick, MA, USA). The actual insertion center was determined as the center of gravity of the area enclosed by the points on the insertion outlines (Figure 4A). Since the notch wall is a concave surface, the calculated gravity center will be positioned above the notch wall surface (Figure 4B). Therefore a method was developed, resulting in the projection of the actual centers and the tunnel marks in the same plane. All points at the notch surface were used to fit a plane with a least squares approach (Figure 4C); The points of the insertion outlines were projected on this plane, as were the tunnel marks (Figure 4D). Then, the center of the insertion was determined as the center of gravity of the area enclosed by the points on the outlines (Figure 4E). Finally, the tunnel placement error was calculated as the distance in the plane between the actual insertion center and the position of the tunnel mark, defining the tunnel location (Figure 4E). The 10 and 11 o'clock EFA mark points were compared with the anatomical AM centers as well as the ACL centers. This method was applied to all twelve femora after both sessions from the researcher and the sessions of the five physicians, resulting in 7 sets of tunnel placement errors.

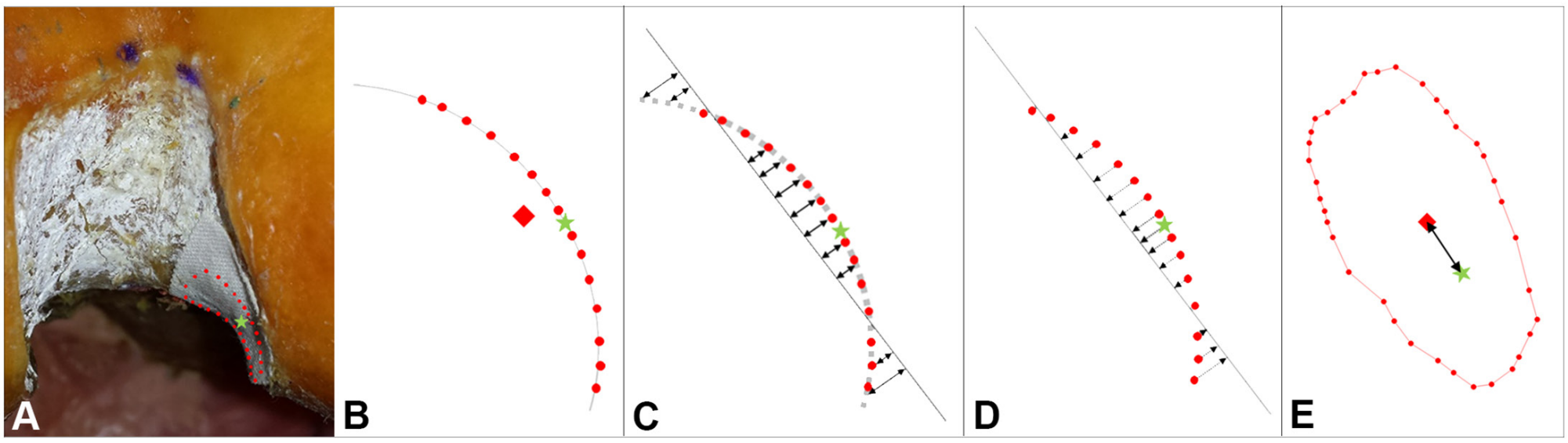

Figure 4. A) The ACL insertion outline (red dots) and the ACL tunnel mark (green star) at the concave notch wall. B) The center of the ACL insertion (red diamond), calculated as center of gravity of the area enclosed by the outline, will be positioned above the notch wall (grey line). C) A plane was fitted through all digitized points in the notch (notch surface points=grey squares, red dots=ACL insertion outline, green star=ACL tunnel mark) with the least squares approach (black arrows). D) The points at the ACL insertion outline and the ACL tunnel mark are projected at the plane. E) The ACL center (red diamond) is calculated as the center of gravity of the area enclosed by the line through the points of the ACL insertion outline. The tunnel placement error (black arrow) is determined as the 2D distance between the ACL center and the ACL tunnel mark.

Statistical data analysis

For all sets, the means, standard deviations and ranges of the placement errors were calculated. For further interpretation of the results and to qualify the size of the errors in a clinical perspective, we defined two limits for the placement errors. Markolf et al. [23] reported the influence of tunnel location variations at knee kinematics. Placement at 10 or 12 o'clock compared to the standard 11 o'clock position, which positions differ approximately 3-4 mm, did not result in significant different knee biomechanics, neither did placement 2.5 mm posterior of the standard 11 o'clock position. Placement 5 mm anterior of the 11 o'clock position resulted in significant different AP laxity. Therefore, all tunnel marks with placement errors within 3 mm were defined as 'accurate' and tunnel marks with errors beyond 5 mm as 'incorrect'. Tunnel marks with errors between 3 and 5 mm were defined as 'intermediate'. The number of accurately placed tunnel marks and the number of incorrectly placed tunnel marks were counted. Physicians with more than 90% accurately placed tunnel marks were defined to perform 'excellent', when the number of incorrectly placed tunnel marks exceeded 20%, the performance was defined 'moderate'. The errors of the tunnel marks placed with the EFA were compared with the AM and ACL tunnel marks placed with the GAFT using the Students' paired t-test to test for a significant difference ($\alpha = .05$, $P < .05$).

Results

1) Correctness of GAFT design

All AM tunnel marks (100%) placed with the GAFT according to the placement protocol under direct visual control had accurate positions within 3 mm of the actual insertion center; this applies for 92% the ACL tunnel marks and 83% of the PL tunnel marks (table 2). Three tunnel marks, one ACL and two PL, showed intermediate errors, with a maximum of 3.9 mm. Hence, the AM tunnel mark placements were most accurate, with errors smaller than 2.9 mm and a mean of 1.6 mm. The PL tunnel marks demonstrated a slightly larger error resulting in a mean of 1.9 mm. The mean ACL placement error was 1.8 mm.

The placement errors for the EFA at 10 and 11 o'clock were significantly larger than the place-

Table 2. Tunnel placement errors for the tunnel mark locations placed by a researcher using the GAFT and EFA under direct visual

Guide	Mean±SD (mm)	P-value	Range (mm)	Tunnel placement Accurate < 3 mm	Intermediate 3-5 mm	Incorrect > 5 mm
Anatomic Gaft						
ACL	1.8 ± 0.9		0.2 – 3.2	11 (92%)	1 (8%)	0
PL	1.9 ± 1.0		0.6 – 3.9	10 (83%)	2 (17%)	0
AM	1.6 ± 0.9		0.4 – 2.9	12 (100%)	0	0
Standard EFA						
10 o'clock	2.8 ± 1.5[a] 2.4 ± 0.9[b]	.043[c] .009[d]	0.2 – 5.4 1.2 – 3.6	8 (67%) 9 (75%)	3 (25%) 3 (25%)	1 (8%) 0
11 o'clock	4.1 ± 1.1[a] 2.9 ± 1.5[b]	< .000[c] < .000[d]	2.4 – 6.0 0.9 – 5.4	2 (17%) 6 (50%)	8 (67%) 5 (42%)	2 (17%) 1 (8%)

[a] relative to anatomic ACL tunnel, [b] relative to anatomic AM tunnel, [c] relative to ACL error GAFT, [d] relative tot AM error GAFT

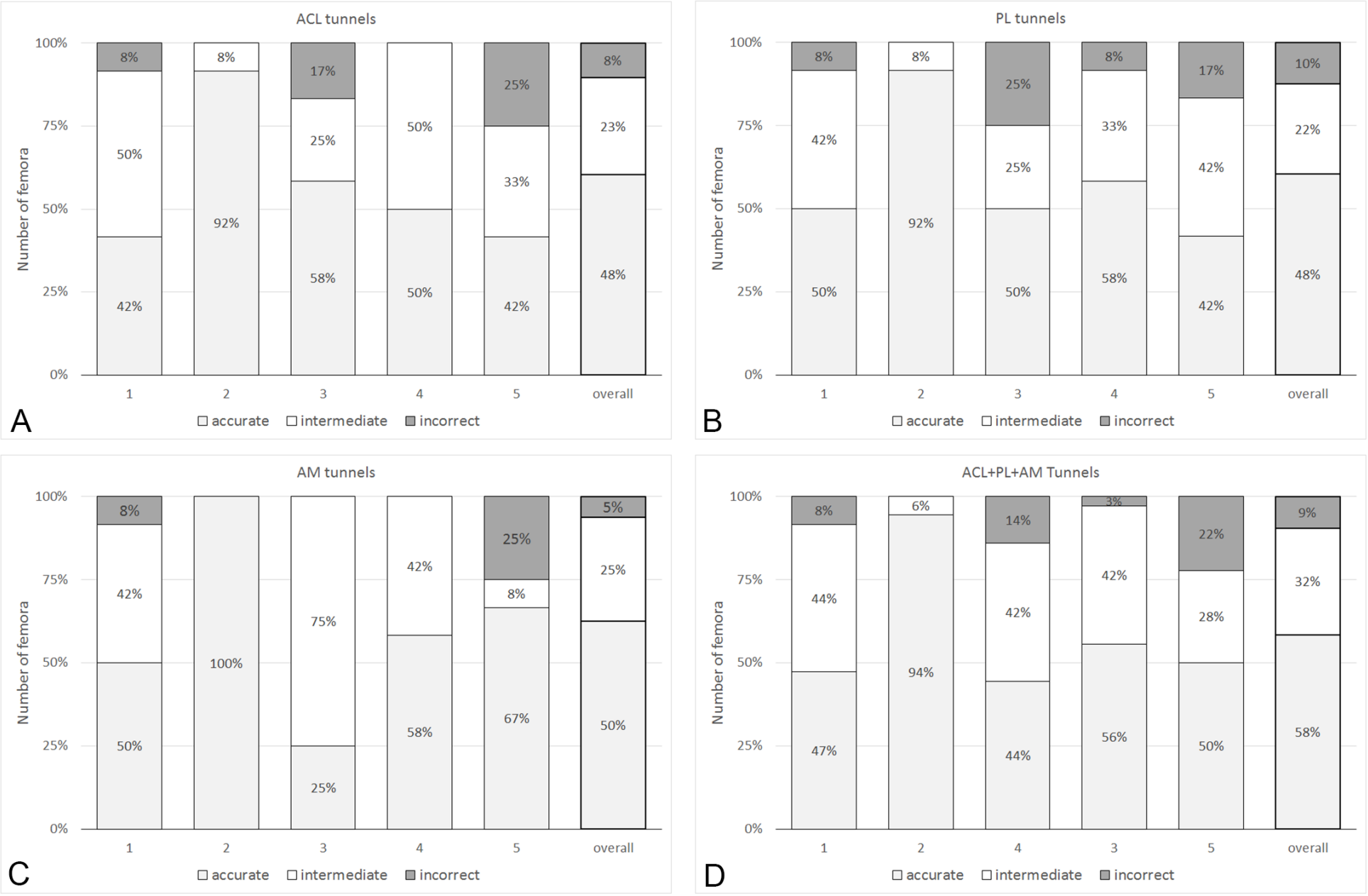

Figure 5. The number of femora (%) with accurate (error<3 mm), intermediate (error>3-5 mm) and incorrect (error>5 mm) tunnel placement by physicians 1-5 using the GAFT and a bar with the overall results for (A) ACL tunnels; (B) PL tunnels; (C) AM tunnels; (D) ACL+PL+AM tunnels.

Table 3. Tunnel placement errors for the tunnel locations placed by physicians 1-5 using the GAFT under arthroscopic control

	1	2	3	4	5	Overall physicians
ACL tunnel						
Mean (mm)	3.1	2.0	3.4	2.9	3.5	3.0
SD (mm)	1.4	0.8	1.2	1.3	2.3	1.5
Range (mm)	0.9 – 5.6	0.9 - 3.6	2.3 – 5.7	0.9 – 4.8	0.5 – 7.1	0.9 – 7.1
PL tunnel						
Mean (mm)	3.1	2.0	3.1	2.7	2.9	2.8
SD (mm)	1.5	1.0	2.2	1.5	1.9	1.7
Range (mm)	0.7 – 5.5	0.8 – 4.1	0.2 – 6.4	0.8 – 5.3	0.4 - 5.6	0.2 – 6.4
AM tunnel						
Mean (mm)	3.0	1.7	3.2	2.5	3.1	2.7
SD (mm)	1.1	0.5	0.9	1.1	2.0	1.3
Range (mm)	1.7 – 5.2	0.9 – 2.4	1.5 – 4.4	1.1 - 4.4	0.6 – 6.6	0.9 – 6.6
Overall tunnels	**1**	**2**	**3**	**4**	**5**	**Overall tunnels& physicians**
Mean (mm)	3.1	2.0	3.4	2.9	3.5	3.0
SD (mm)	1.4	0.8	1.2	1.3	2.3	1.5
Range (mm)	0.9 – 5.6	0.9 - 3.6	2.3 – 5.7	0.9 – 4.8	0.5 – 7.1	0.9 – 7.1

ment errors from the GAFT, relative to both anatomic AM (10: P=.009; 11: P<.000) and ACL centers (10: P=.043; 11: P<.000). The EFA produced larger numbers of tunnel marks with intermediate placement errors and incorrectly placed tunnel marks.

2) Accuracy of protocolled arthroscopical tunnel placement with the GAFT

Overall, 58% of the tunnel marks positioned by the physicians were placed accurately; 9% were placed incorrectly (table 3 and figure 5). The individual performance varied between excellent (95% accurately placed tunnel marks) and moderate (22% incorrect placed tunnel marks). The mean placement errors by the physicians using the GAFT ranged between 1.7 mm and 3.5 mm. Tunnel mark placement within the physicians was consistent. Although the tunnel marks with the largest mean errors were placed by the resident with the least experience, no direct one-to-one relationship between obtained accuracy and clinical experience regarding the number of performed ACL reconstructions was detected. One resident, ranked secondly in terms of ACL-experience, approached the results of the protocolled guide placement under visual control by the researcher.

Discussion

This study demonstrates that the GAFT has an adequate design to position tunnel location marks near the anatomical insertion centers following the placement protocol; protocolled arthroscopical tunnel placement can be performed accurately by physicians using the GAFT.

Femoral tunnel positioning in anterior cruciate ligament reconstruction is an important factor for successful outcome. An aiming device can be helpful in accurate positioning and drilling of the tunnels. The femoral anatomical aiming guide we developed for anatomical single or double bundle tunnel placement, is based on the anatomical average positions of the femoral ACL insertion and its functional bundles, the AM and PL, in the notch. The device is designed with the philosophy to obtain an accurate positioning without extensive anatomical knowledge of the exact ACL insertion at an arthroscopic view. Skill is important to position the guide accurately at the 10.30 o'clock position in the notch, physically supported by the intercondylar structures, thus resulting in the tubes targeting at the anatomical insertions.

The results of the tunnel mark placement using the GAFT under direct visual control during the first experiment, support the correctness of the guide design in combination with the placement protocol. The mean placement errors between 1.6 and 1.9 mm remained well within the defined acceptable accuracy limit. The maximal error was 3.9 mm, signifying no tunnel marks were placed incorrectly. Compared to tunnel mark positioning with the EFA at 11 or 10 o'clock, the GAFT placed the tunnel marks more anatomically with smaller mean and maximum placement errors relative to both AM and ACL centers. The results with the EFA in the current study match with the findings in previous studies reporting tunnel placement using the EFA with a transtibial approach is in the AM bundle insertion site and cannot reach the ACL center [1, 2, 9].

Protocolized arthroscopical tunnel placement with the GAFT by future users resulted in accuracy performances varying between the surgeons from excellent to moderate. The results were consistent within the surgeons. Overall, more than half of the tunnel marks (58%) were placed accurately and only a small number (9%) was incorrect. Since the results of the guide optimally positioned according to the placement protocol under visual control showed accurate tunnel mark placements, the inaccuracy of the arthroscopic placement is caused by inadequate positioning of the guide by the user. One resident approximated the results of visual guide placement, demonstrating the potential accuracy of the guide placed following the placement protocol from an arthroscopical view. The other users, performing worse with larger tunnel mark placement errors, obviously, positioned the guide not optimally. We could not determine a direct one-to-one relation between the clinical experience regarding the number of performed ACL reconstructions and the accuracy of tunnel mark placement. The best performing resident did not have the highest number of ACL reconstructions, however had experience in positioning femoral tunnels with a guide through the anteromedial portal. The most experienced surgeon only performed transtibial tunnel placements. The most incorrect placements (22%) were performed by the resident without experience in performed ACL reconstruction. Apparently, his lack of guide placement experience influenced his performance, still, he managed to place 50% of the tunnel marks accurate. Since all users saw and used the guide at the placement session for the very first time, capacity for improvement in the tunnel mark placement is obvious when the users are gaining more experience and feedback on their guide placement accuracy by implementing a training session with instruction and feedback before clinical usage.

The question remains what the meaning is of the size of the placement errors found in this study. In an attempt to place the results in a perspective we choose to define some limits. These limits were based on results of Markolf et al. [23]. However, no general accepted limits (in mm) have been defined in literature. Further research is necessary to determine the real clinical influence of tunnel placement errors, as found in this study.

We can compare the arthroscopic results of the current study to a previously published study on tunnel mark placement errors using a computer assisted surgery (CAS) planning and placement system executed by two experienced surgeons. The placement errors with CAS ranged between 2.3 and 3.2 mm for AM tunnels and 2.7 and 3.6 mm for PL tunnels [18]. These results, obtained using the same 12 femora and measurement methods as in the current study, are comparable with the worse results of the residents, meaning the GAFT has probably more potential than the CAS system.

Reflecting the current results with other findings in the literature, we found four studies examining the accuracy of endoscopic femoral drill guides studies with concepts comparable to the current study, calculating the positions of the drill holes relative to the anatomical centers of the ACL [1, 13, 14, 34]. Good et al. [13] determined the relative tunnel positions at the sagittal depth of the femoral condyles, measured at lateral femoral radiographs of an endoscopic femoral drill guide aiming at tunnel placement in the anatomic ACL center in 30 patients [29]. These positions were compared with the mean position of the actual anatomical centers in 10 cadaveric knees and with free hand drilled tunnels in 17 patients. The mean anatomical centre was positioned at 66% of the sagittal depth. The SD of the mean actual center, 4% (2 mm), was chosen as an acceptable limit for tunnel errors. 76% of the tunnels placed with the guide was positioned within 2 mm of the mean position of the actual center, between 62% and 70% of the sagittal depth versus 47% of the free hand placed tunnels. Grontvedt et al. [14] compared a two-incision drill guide with the one-incision EFA (7 mm offset). He found a significant anterior placement of tunnels placed by a two-incision drill guide in 10 cadaveric knees relative to the anatomical center with a difference of about 4 mm on average in high-low direction. The EFA positioned the tunnels on average at about 2 mm anterior and 4 mm more proximal compared to the anatomical centers. The placements resulted in graft forces twice as high as in the normal ACL, but did not differ significantly from each other. The position errors are larger than in the current study, although they are explainable, since the guides have been positioned aiming at the over-the-top positions. Wiwattanawarang et al. [34] reported the mean distances between the anatomical ACL centers and tunnel marks placed with an EFA at the 11/1 o'clock position. The error was 10.36 mm using the guide transtibial in 19 cadaveric knees and 9.67 mm using the guide through a medial arthrotomy approach in 18 cadaveric knees. These results are even worse than our errors for 11 o'clock positions placed under visual control. Abebe et al. [1] compared anatomical placement with the transtibial technique using the EFA (7 mm offset) and the anteromedial technique using a 2-incision Retro-drill guide. Two 2 highly-experienced surgeons, one in the TT-technique, the other in the AM-technique, performed their method at 8 patients. The tunnel placement errors, distances between the tunnel centers and ACL-centers in the sagittal plane, were calculated using MRI and CT techniques. The mean error for the TT-method was 8.5±2.1 mm, the AM-method resulted in a mean error of 3.2±1.0 mm. Overall, we can conclude that the results of the current study are comparable to or better than the validation results of studies addressing the accuracy of other femoral guides.

Three studies tested the accuracy of CAS systems of which two also reported data about free hand drilling. The methods used for the error analysis were comparable to ours [4, 28, 31].

Burkart et al. [4] reported the precision of tunnel center positions at 4 times 10 sawbones for freehand drilling: 2.3 mm and 2.1 mm (fellows) and 1.5 mm and 1.2 mm (experienced surgeons). The precision for the active robotic system (CASPAR®) was 1.1 mm. The standard deviations (=precision) in the current study ranging from 0.5 mm (most accurate resident) till 2.3 mm (unexperienced resident) at twelve cadaveric bones are in line with the presented precisions in Burkart's study. Hence, with the GAFT, it seems possible to approach the precision values of an active robotic system. Picard et al. [31] determined the surgical error (i.e. the mean difference between the planned and actual tunnel) in free hand transtibial tunnel placement using a conventional femoral pin guide versus tunnel placement with a computer assisted navigation technique (KneeNav™). Both methods were performed in 20 foam knee bones by two orthopedic surgeons experienced in ACL reconstruction. They found a mean error of 4.2±1.8 mm for freehand drilling and of 2.7±1.9 mm for computer assisted. Musahl et al. [28] reported smaller tunnel placement errors of 1.3±1.0 mm, measured at lateral CT images. The placement was performed with an active robotic system (CASPAR®) in 8 fresh frozen cadaveric knees using the 25%-25% values of the quadrant method for tunnel planning. The results of the current study are better than freehand drilling and for most residents, at least equal to navigated femoral tunnel placement.

Limitations

Our study had obvious limitations. The experiments were confined to ex-vivo measurements and were applied to twelve dissected cadaveric femoral bones preserved in formalin. However, we had a distribution of femoral sizes and we did not detect any difference between the fixated bone relative to the surgical reality. Furthermore, the number of bones used in this study is comparable to what is used in other studies on this topic [4, 14, 28, 31]. Another limitation might be the absence of the tibia and femoral capsula during the placements under arthroscopic control. However, the goal was to determine the accuracy of guide and tunnel mark placement from an arthroscopic view, looking at the monitor and this was accomplished. From a more clinical point of view a limitation may be that we did not drill the actual tunnels, but compared the position of the tunnel marks, with accurate methods, relative to the insertion centers. The position of the tunnels were marked with a K-wire, fitting perfectly in the tubes of the GAFT. In the clinical situation, this K-wire is used as the mark itself and drilled into the notch. The tunnel is then reamed placing a cannulated drill over the K-wire. The center of a drilled tunnel will correspond with the position of the K-wire mark in the current study. This study has been focusing on determining the basic potential of the guide, however, accuracy in clinical practice should be the subject of further research.

Conclusions

The results of this study confirm the experimental validity of the GAFT design and its protocolled arthroscopical use by first users. Although the design enables accurate tunnel mark placements for anatomical single (ACL) or double bundle (AM and PL) ACL reconstruction, the study also highlights that not following the placement protocol results in undesirable variations including incorrect placement. Further study is necessary to validate the guide in the clinical setting.

References

1. Abebe ES, Moorman CT, Dziedzic TS, Spritzer CE, Cothran RL, Taylor DC, Garrett WE, DeFrate LE (2009) Femoral tunnel placement during anterior cruciate ligament reconstruction: an in vivo imaging analysis comparing transtibial and 2-incision tibial tunnel-independent techniques. Am J Sports Med 37:1904–1911.
2. Behrendt S, Richter J (2010) Anterior cruciate ligament reconstruction: drilling a femoral posterolateral tunnel cannot be accomplished using an over-the-top step-off drill guide. Knee Surg Sports Traumatol Arthrosc 18:1252–1256.
3. Brophy RH, Pearle AD (2009) Single-bundle anterior cruciate ligament reconstruction: a comparison of conventional, central, and horizontal single-bundle virtual graft positions. Am J Sports Med 37:1317–1323.
4. Burkart A, Debski RE, McMahon PJ, Rudy T, Fu FH, Musahl V, van Scyoc A, Woo SL (2001) Precision of ACL tunnel placement using traditional and robotic techniques. Comput Aided Surg 6:270–278.
5. Cain EL, Clancy WG (2002) Anatomic endoscopic anterior cruciate ligament reconstruction with patella tendon autograft. Orthop Clin North Am 33:717–725.
6. Christel P, Sahasrabudhe A, Basdekis G (2008) Anatomic double-bundle anterior cruciate ligament reconstruction with anatomic aimers. Arthroscopy 24:1146–1151.
7. Dargel J, Schmidt-Wiethoff R, Fischer S, Mader K, Koebke J, Schneider T (2009) Femoral bone tunnel placement using the transtibial tunnel or the anteromedial portal in ACL reconstruction: a radiographic evaluation. Knee Surg Sport Traumatol Arthrosc 17:220–227.
8. Fernandes TL, Fregni F, Weaver K, Pedrinelli A, Camanho GL, Hernandez AJ (2014) The influence of femoral tunnel position in single-bundle ACL reconstruction on functional outcomes and return to sports. Knee Surg Sports Traumatol Arthrosc 22:97–103.
9. Gadikota HR, Sim JA, Hosseini A, Gill TJ, Li G (2012) The Relationship Between Femoral Tunnels Created by the Transtibial, Anteromedial Portal, and Outside-In Techniques and the Anterior Cruciate Ligament Footprint. Am J Sports Med 40:882–888.
10. Garrett WE, Swiontkowski MF, Weinstein JN, Callaghan J, Rosier RN, Berry DJ, Harrast J, Derosa GP (2006) American Board of Orthopaedic Surgery Practice of the Orthopaedic Surgeon: Part-II, certification examination case mix. J Bone Joint Surg Am 88:660–667.
11. Gelber PE, Erquicia J, Abat F, Torres R, Pelfort X, Rodriguez-Baeza A, Alomar X, Monllau JC (2011) Effectiveness of a footprint guide to establish an anatomic femoral tunnel in anterior cruciate ligament reconstruction: computed tomography evaluation in a cadaveric model. Arthroscopy 27:817–824.
12. Girgis FG, Marshall JL, Monajem A (1975) The cruciate ligaments of the knee joint. Anatomical, functional and experimental analysis. Clin Orthop Relat Res 216–231.
13. Good L, Odensten M, Gillquist J (1987) Precision in reconstruction of the anterior cruciate ligament: A new positioning device compared with hand drilling. Acta Orthop 58:658–661.
14. Grøntvedt T, Pena F, Engebretsen L (1996) Accuracy of femoral tunnel placement and resulting graft force using one-or two-incision drill guides. A cadaver study on ten paired knees. Arthroscopy 12:187–192.
15. Harner CD, Honkamp NJ, Ranawat AS (2008) Anteromedial Portal Technique for Creating the Anterior Cruciate Ligament Femoral Tunnel. Arthroscopy 24:113–115.
16. Loh JC, Fukuda Y, Tsuda E, Steadman RJ, Fu FH, Woo SLY (2003) Knee stability and graft function following anterior cruciate ligament reconstruction: Comparison between 11 o’clock and 10 o’clock femoral tunnel placement. 2002 Richard O’Connor Award paper. Arthroscopy 19:297–304.
17. Lubowitz JH (2009) Anteromedial portal technique for the anterior cruciate ligament femoral socket: pitfalls and solutions. Arthroscopy 25:95–101.
18. Luites JWH, Wymenga AB, Blankevoort L, Eygendaal D, Verdonschot N (2014) Accuracy of a computer-assisted planning and placement system for anatomical femoral tunnel positioning in anterior cruciate ligament recon-

struction. Int J Med Robot Comput Assist Surg 10:438–446.

19. Luites JWH, Wymenga AB, Blankevoort L, Kooloos JGM (2007) Description of the attachment geometry of the anteromedial and posterolateral bundles of the ACL from arthroscopic perspective for anatomical tunnel placement. Knee Surg Sports Traumatol Arthrosc 15:1422–1431.
20. Marans H, Hendrix M, Paterson R (1992) A new femoral drill guide for arthroscopically assisted anterior cruciate ligament replacement. Arthroscopy 8:234–238.
21. Marchant BG, Noyes FR, Barber-Westin SD, Fleckenstein C (2010) Prevalence of nonanatomical graft placement in a series of failed anterior cruciate ligament reconstructions. Am J Sports Med 38:1987–1996.
22. Markolf KL, Hame S, Hunter DM, Oakes DA., Zoric B, Gause P, Finerman GAM (2002) Effects of femoral tunnel placement on knee laxity and forces in an anterior cruciate ligament graft. J Orthop Res 20:1016–1024.
23. Markolf KL, Jackson SR, McAllister DR (2010) A comparison of 11 o'clock versus oblique femoral tunnels in the anterior cruciate ligament-reconstructed knee: knee kinematics during a simulated pivot test. Am J Sports Med 38:912–917.
24. McGuire D, Hendricks S, Grinstead G (1996) Use of an endoscopic aimer for femoral tunnel placement in anterior cruciate ligament reconstruction. Arthroscopy 12:26–31.
25. McGuire D, Paterson R (1996) Femoral guide and methods of precisely forming bone tunnels in cruciate ligament reconstruction of the knee. US Patent 5520693 A.
26. Mochizuki T, Fujishiro H, Nimura A, Mahakkanukrauh P, Yasuda K, Muneta T, Akita K (2014) Anatomic and histologic analysis of the mid-substance and fan-like extension fibres of the anterior cruciate ligament during knee motion, with special reference to the femoral attachment. Knee Surg Sports Traumatol Arthrosc 22:336–344.
27. Morgan JA, Dahm D, Levy B, Stuart MJ (2012) Femoral Tunnel Malposition in ACL Revision Reconstruction. J Knee Surg 25:361–368.
28. Musahl V, Burkart A, Debski RE, Van Scyoc A, Fu FH, Woo SLY (2003) Anterior cruciate ligament tunnel placement: Comparison of insertion site anatomy with the guidelines of a computer-assisted surgical system. Arthroscopy 19:154–160.
29. Odensten M, Gillquist J (1986) A modified technique for anterior cruciate ligament (ACL) surgery using a new drill guide for isometric positioning of the ACL. Clin Orthop Relat Res 154–158.
30. Piasecki DP, Bach BR, Espinoza Orias AA, Verma NN (2011) Anterior cruciate ligament reconstruction: can anatomic femoral placement be achieved with a transtibial technique? Am J Sports Med 39:1306–1315.
31. Picard F, DiGioia AM, Moody J, Martinek V, Fu FH, Rytel M, Nikou C, LaBarca RS, Jaramaz B (2001) Accuracy in tunnel placement for ACL reconstruction. Comparison of traditional arthroscopic and computer-assisted navigation techniques. Comput Aided Surg 6:279–289.
32. Sadoghi P, Kröpfl A, Jansson V, Müller PE, Pietschmann MF, Fischmeister MF (2011) Impact of tibial and femoral tunnel position on clinical results after anterior cruciate ligament reconstruction. Arthroscopy 27:355–364.
33. Tompkins M, Milewski MD, Brockmeier SF, Gaskin CM, Hart JM, Miller MD (2012) Anatomic femoral tunnel drilling in anterior cruciate ligament reconstruction: use of an accessory medial portal versus traditional transtibial drilling. Am J Sports Med 40:1313–1321.
34. Wiwattanawaran N, Rujiwetponstorn V (2005) Positioning of femoral tunnel in anterior cruciate ligament reconstruction using femoral aimer guide. J Med Assoc Thai 88:1545–1550.
35. Zantop T, Wellmann M, Fu FH, Petersen W (2008) Tunnel positioning of anteromedial and posterolateral bundles in anatomic anterior cruciate ligament reconstruction: anatomic and radiographic findings. Am J Sports Med 36:65–72.

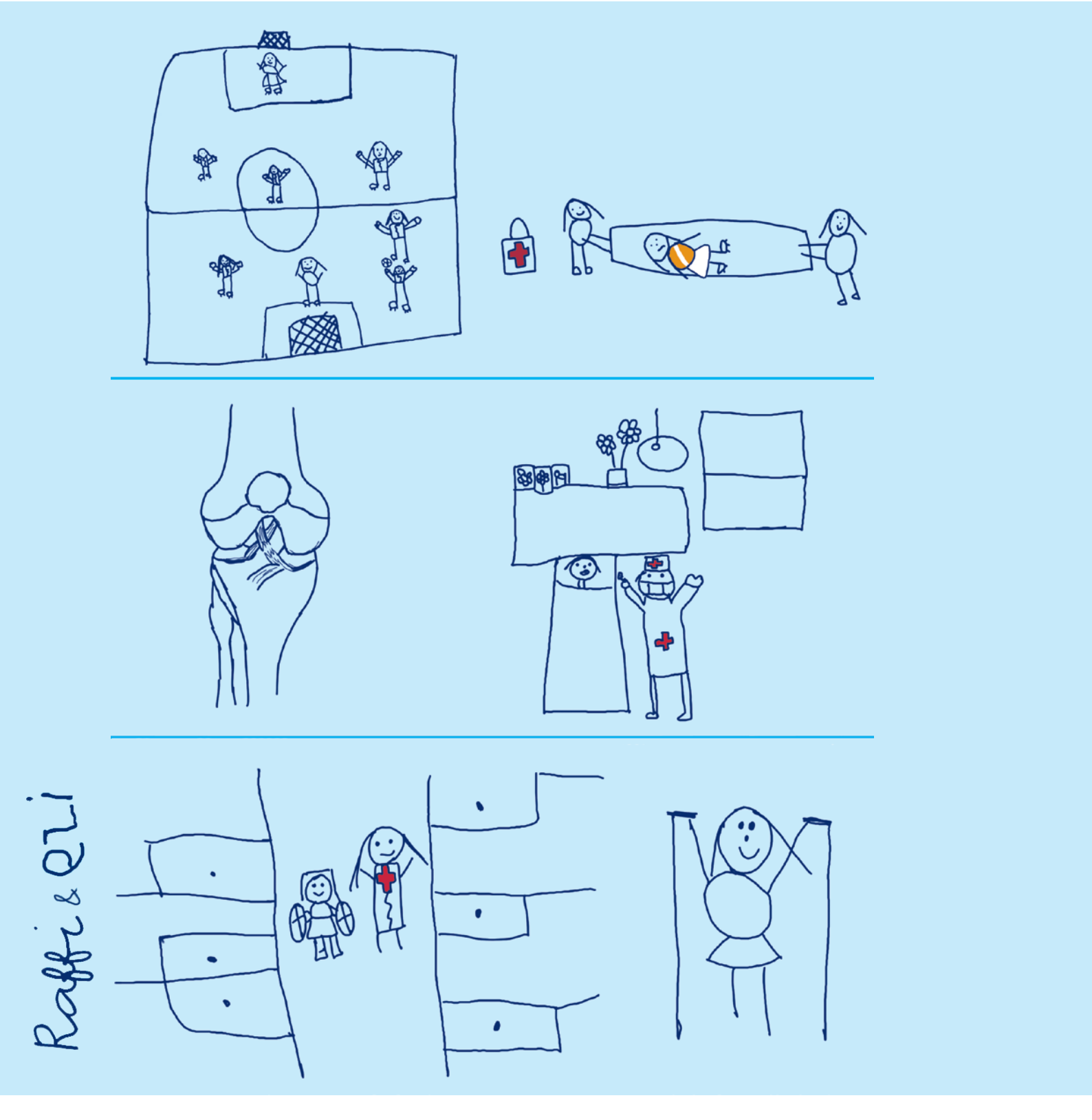
Raffi & Eli

CHAPTER 10

A personalized three-dimensional printed mold for accurate femoral tunnel positioning in anterior cruciate ligament reconstruction

Joan W.H. Luites, Thomas J. Maal, Ronald Vreeken, Pawel K. Tomaszewski
and Nico Verdonschot

Abstract

Background

Accurate femoral tunnel placement in anatomical anterior cruciate ligament (ACL) reconstruction is an important factor for clinical success. Rapid prototyping can be used to produce 3-dimensional (3D) printed patient specific instruments that have the potential to improve accurate femoral tunnel placement.

Purpose

The goal of this study was to develop and assess the accuracy of a patient specific 3D mold for femoral tunnel(s) placement at the center of the ACL footprint or the center of the anteromedial (AM) and posterolateral (PL) bundles.

Methods

The origins of the ACL, AM and PL bundles were located and marked on twelve cadaveric femurs with leaded wires. The mean center positions from six femurs were calculated using computed tomography (CT) scans and applied to the six other femurs. In those femurs an area in the intercondylar notch, including the applied mean centers, was selected and a 3D mold of the surface with three tunnel holes was printed. The molds were positioned in the intercondylar notches and the tunnel center locations were marked with ink. The accuracy was calculated as the distance between the actual insertion centers and the tunnel marks.

Results

The six molds fitted uniquely in each of their respective intercondylar notches resulting in a stable position of the device. The mean tunnel mark placement errors were 1.2±0.5 mm (AM), 1.2±0.6 mm (ACL) and 1.3±0.7 mm (PL) with individual errors ranging between 0.6 mm and 2.1 mm.

Conclusion

CT-based 3D imaging in combination with mean ACL center positions enables the development of a unique and stable 3D printed mold which positions the femoral tunnels for ACL reconstruction with an accuracy of 1.3 mm relative to the native anatomical center positions in cadaver femurs. This technique has the potential to standardize femoral tunnel placement and reduce tunnel malposition. Further clinical research is needed to develop and validate a device which can be used in orthopedic practise.

Introduction

In the last 20 years, with the introduction of the double bundle anterior cruciate ligament (ACL) reconstruction, there is growing interest in performing more anatomic placement of ACL grafts [37]. The ultimate goal is to restore the original anatomy as well as function of the ruptured ACL through reconstruction of the anteromedial (AM) and posterolateral (PL) bundles at their anatomical centers resulting in superior clinical success [32]. However, the femoral tunnel location and placement continues to be the most important source of problems in single bundle ACL reconstruction [26, 31], let go in reconstructions with two bundles [15].

First of all, there is a wide variation in size and shape of the ACL origin [22] and the division between the AM and PL bundle attachment is functional, not visible. Secondly, the femoral insertion can be divided in a direct attachment of the midsubstance fibers and the fanlike fibers of the indirect attachment [29], resulting in two concepts about the tunnel location(s): at the center of the direct insertion ór at the center of the complete insertion area [23]. However, the division in direct and indirect insertions is impossible to distinguish by macroscopic observation [19] and assessment of the center(s) of the femoral footprint, with or without the indirect attachment, is complicated by arthroscopic distortion [16, 17].

Free hand femoral tunnel placement by experienced surgeons has been shown to have large placement errors of 4.2 mm [36] and increasing placement variations (SD's up to 4.5 mm) in surgeons with less experience [5]. To achieve better accuracy, supporting techniques and devices like fluoroscopic assistance [21, 30], active computer assisted surgery (CAS) systems [33], real time navigation systems [7, 25, 34, 42] and aiming devices and drill guides [6, 13, 14, 28] have been developed. Aiming devices and drill guides are the cheapest solution, however, accurate tunnel placement with these instruments remains a challenging task [2]. The most important reason is the freedom of guide positioning for the surgeon.

In the quest for a solution decreasing the degrees of freedom in guide placement, the possibilities in personalizing parts of the guide which would be snap-fit on the femur in only one position should be explored. These opportunities could be found in stereolithography or three-dimensional (3D) printing [18], a technique with which a 3D object can be quickly fabricated on the basis of 3D images derived from computer tomography (CT) scans. In the last decade, this rapid prototyping process has been evolved, resulting in the application of this technique for the development of surgical instruments [40]. With the 3D printing technique, a patient customized device based of the individual femoral intercondylar notch surface, fitting in only one position, can be manufactured. The optimal tunnel positions should be incorporated in this patient specific instrument. Since the margins of the ACL origin at CT-scans are difficult to determine, incorporating the individual anatomical centers is not easy. Therefore an alternative method to define the ACL, AM and PL centers in the patients knee at CT should be applied. Applying guidelines for average center positions at CT-scans seems a possible solution. Most methods use the two-dimensional (2D) definition of the average ACL center relative to the notch contours using the quadrant method [3] with Blumensaat's line and notch height [4, 11]. However, optimally using the possibilities of CT, a three-dimensional (3D) center position is desired. An alternative method is defining the center position relative to the dimensions of the distal femur (depth, height and width), which can be easily measured at CT images.

The goal of this study was to explore the possibilities of the 3D printing technique combined with the center determination method and to determine the accuracy in femoral cadaveric bones. The hypothesis of the current study is that a 3D printed patient customized 3D mold can be developed which allows unique notch fit and correct anatomic localization of the ACL, AM and PL center positions for drilling the tunnels in anatomic single bundle or double bundle ACL reconstruction.

Methods

In the present study, six 3D printed patient customized 3D molds with incorporated ACL, AM and PL holes for tunnel localization at the average center positions of the total insertion site were developed. The CT-data of twelve cadaver femurs (A-L) was used. The information about the average ACL, AM and PL insertion center positions of six femurs (A-F) was applied to the six other femurs (G-L). The positions were incorporated within the six customized 3D molds, derived from the CT-data of the intercondylar notch shape of each individual femur (G-L). The 3D printed molds were validated by evaluating the notch fit and determining the tunnel placement accuracy, calculating the distance between the proposed tunnel center positions marked with the individual 3D molds (T) and the actual insertion centers (A) in the six cadaver femurs (G-L). The process flow is presented in Figure 1.

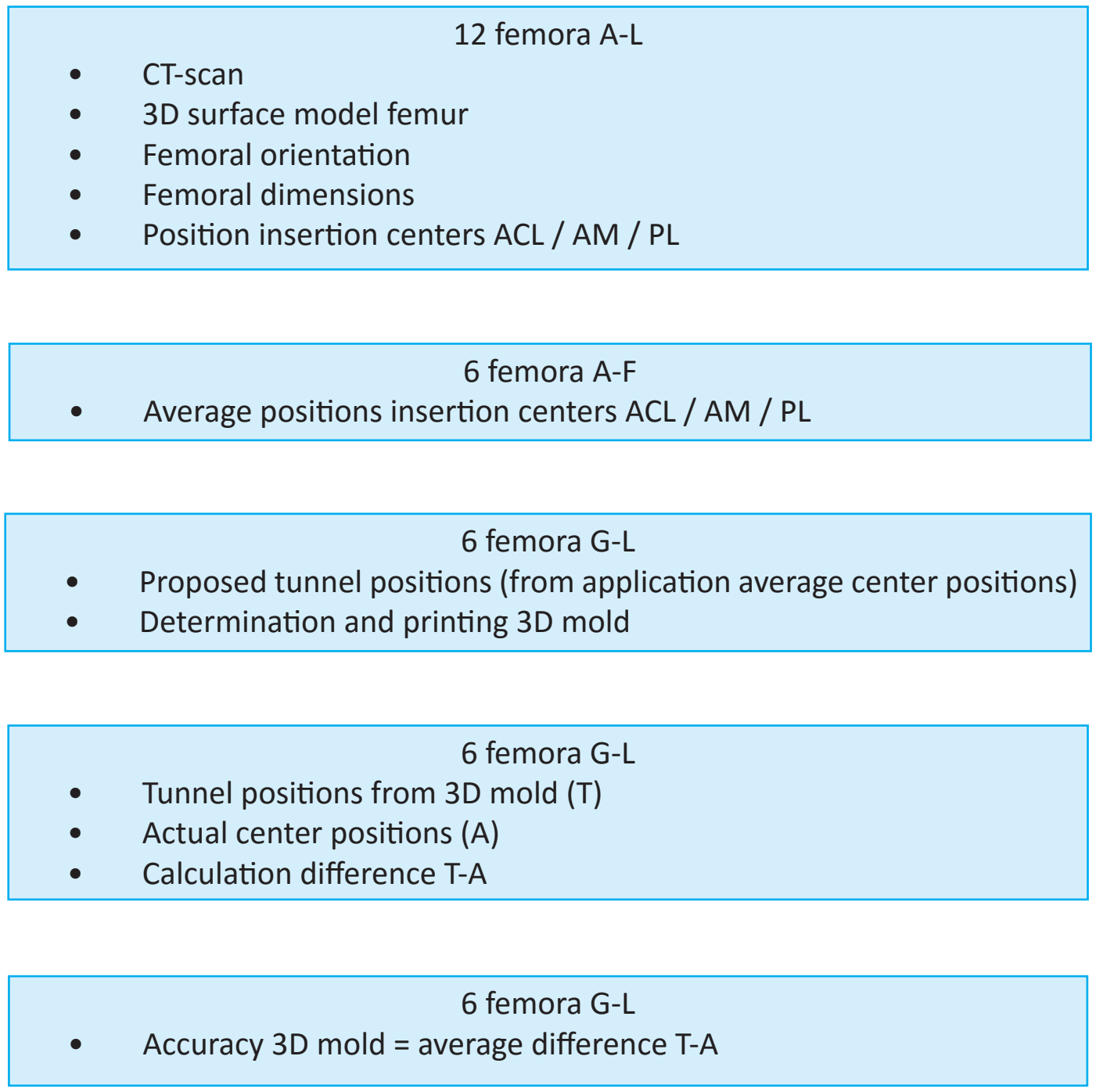

12 femora A-L

- CT-scan
- 3D surface model femur
- Femoral orientation
- Femoral dimensions
- Position insertion centers ACL / AM / PL

6 femora A-F

- Average positions insertion centers ACL / AM / PL

6 femora G-L

- Proposed tunnel positions (from application average center positions)
- Determination and printing 3D mold

6 femora G-L

- Tunnel positions from 3D mold (T)
- Actual center positions (A)
- Calculation difference T-A

6 femora G-L

- Accuracy 3D mold = average difference T-A

Figure 1. Flow Chart Accuracy analysis 3D mold.

Anatomical data collection and processing

Twelve cadaveric femoral bones (A-L) fixated in formalin, with leaded wire marked insertion outlines of the ACL footprint, divided in the AM and PL parts including the fanning fiber bundles of the indirect insertion [29], were used in the current study. CT-scans were obtained with a SOMATOM Sensation 64 (Siemens AG, Munich, Germany); Slice thickness was 0.6 mm and slice increment 0.3 mm. The CT-data was loaded into Mimics 14.01 (Materialize N.V., Leuven, Belgium) and the distal femoral bones were segmented into surface models. These models were loaded in an in-house created MATLAB software code (The MathWorks Inc., Natick, Massachusetts, USA) to determine the distal femoral coordinate system. Then, the outlines of the insertion sites of the ACL, AM and PL were determined and modelled separately.

The dimensions (mm) of all femurs were determined as height in distoproximal (DP) direction, depth in anteroposterior (AP) direction and width in mediolateral (ML) direction (Figure 2). For the height, the circle method adapted from Amis et al. was applied [1]. At 50% of the medial condyle width, a circle was fitted in the sagittal plane following the dorsal contour of the condyle. The top of the circle determined the proximal end. The first distal slice in the axial plane determined the distal end. The height was defined as the distance between the distal and proximal points. The depth was defined as the distance between the first anterior and last posterior slice in the coronal plane. The width was defined as the distance between the first medial and last lateral slice in the sagittal plane.

In all specimens, the models of the insertion outlines were imported in Rhinoceros (version 5 2013, McNeel North America, Seattle, USA). The centroid area command was used to calculate and plot the insertion centers of ACL, AM and PL. The visual information of the center position from these plots was used to position the centers at that spot relative to the insertion outlines in Mimics software. The coordinates of the centers in the femoral coordinate system were obtained and the positions relative to the femoral dimensions were calculated (Figure 2).

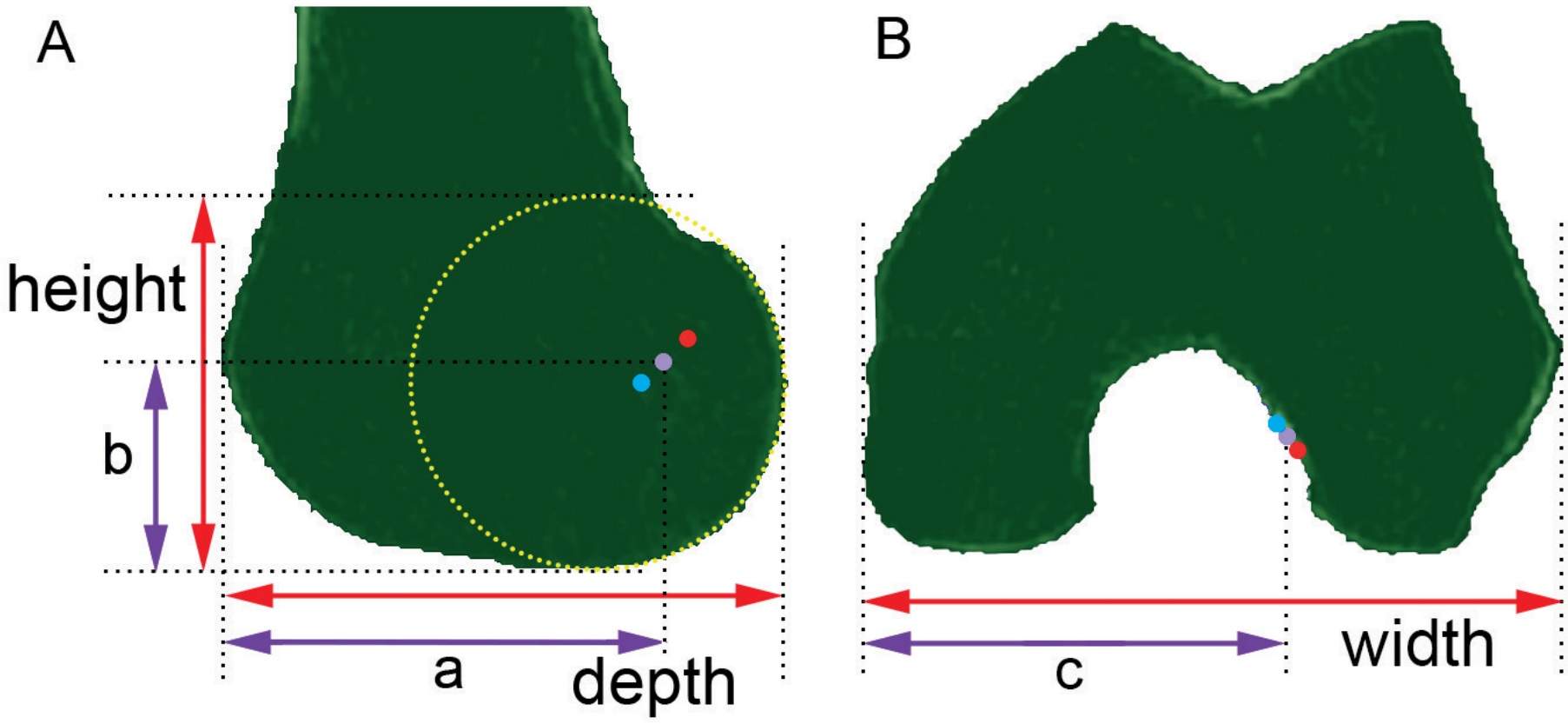

Figure 2. The dimensions of the distal femur and the relative positions (a, b and c) of the ACL center (purple circle); The relative positions for the AM (red circle) and PL (blue circle) centers have also been calculated. A) The height of the femoral condyle is defined between the distal and proximal end. The proximal end is determined by the top of a circle, fitted through the posterior medial condyle in the sagittal plane [1], at 50% of the medial condyle in the coronal and axial plane. The depth of the femur is defined between the first and last slide in anteroposterior direction. B) The width of the femur is defined between the first and last slide in mediolateral direction.

Table 1. The positions of the ACL, AM and PL centers relative to the femoral dimensions (%) in 6 femurs (A-F)

	DP*	AP*	ML*
ACL	65 ± 4	22 ± 2	60 ± 2
AM	69 ± 3	26 ± 3	58 ± 2
PL	61 ± 4	19 ± 2	61 ± 2

**DP: distoproximal, femoral height; AP: anteroposterior, femoral length; ML: mediolateral, femoral width*

Average center positions

To define the average ACL, AM and PL insertion center positions, the dimensions of the distal femur and the center positions from six, random selected, femurs (A-F) were measured in Mimics. The average positions of the ACL, AM and PL centers relative to the femoral dimensions were consistently showing small standard deviations (Table 1).

3D mold preparation

The data of the average center positions from the six femurs (A-F) was applied to six other femurs (G-L) using Mimics. Due to slice thickness and increment of 0.6 and 0.3 mm of the CT-scans and the variable bony contour of the intercondylar notch wall, small adaptations to the average positions had to be made to make sure the center was located at the bony surface. These adaptations ranged on average between 0.5±0.4 mm (AM), 0.6±0.4 mm (ACL) and 0.8±0.7 mm (PL).

The shape information of the six femoral models (G-L) including the average ACL, AM and PL center positions based on models (A-F) was filed and loaded in Autodesk® 3ds Max® 2014 (Autodesk Inc., San Rafael, California, USA) to develop the 3D molds for bones G-L. The molds were shaped like a cross, including the concave contour of the intercondylar notch wall transitioning into the notch roof and part of the posterior cortex at the femoral shaft to develop a unique fitting object (Figure 3). At the positions of the ACL, AM and PL centers, three cylindrical holes (0.5 mm) were applied. The mold was printed at 3D Worknet BV (Ede, The Netherlands) with Selective Laser Sintering (SLS) using PA2200 material.

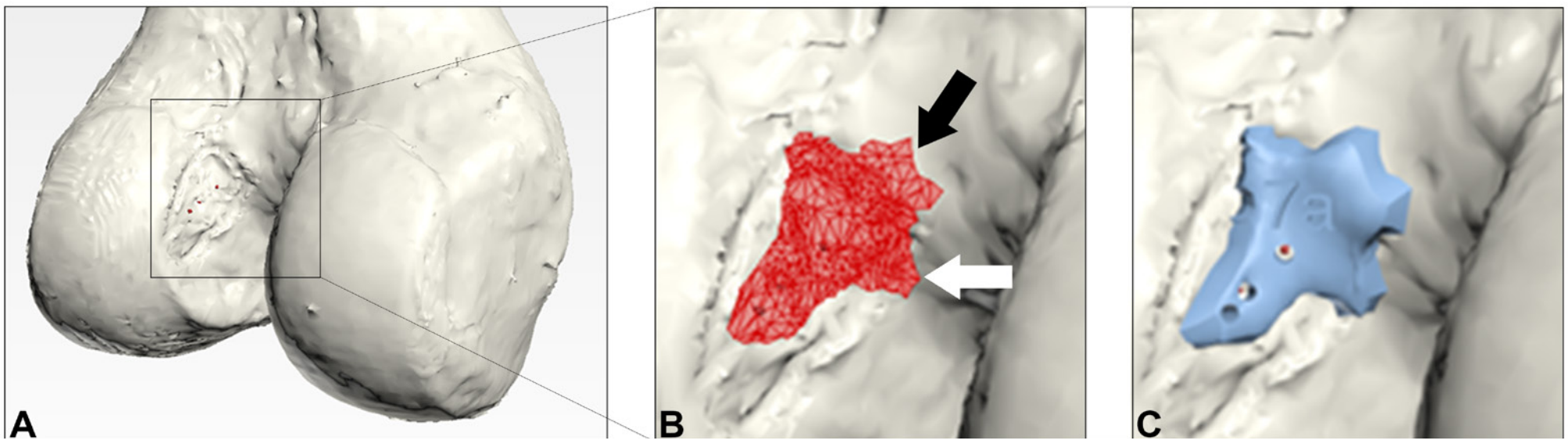

Figure 3. A) The shaping of the mold in Autodesk® 3ds Max® 2014 (Autodesk Inc., San Rafael, California, USA) using the STL file of the distal femur with the marked positions of the ACL, AM and PL centers; B). The selected surface includes the concave contour of the intercondylar notch wall transitioning into the notch roof (white arrow) and part of the posterior cortex at the femoral shaft (black arrow) to produce a shape, which could only fit in one way on the notch surface; C). Building of the 3D mold at the surface with three cylindrical holes (0.5 mm) at the positions of the ACL, AM and PL centers.

Data analysis of 3D mold validation

The six printed molds with the three pre-drilled positions for anatomical single bundle (ACL) or double bundle (AM and PL) tunnel placement were applied to the six femurs (G-L) (Figure 4). The molds were positioned based on 'feeling' of the correct fit with the intercondylar notch surface. After drill guide placement, the tunnel positions were marked at the femoral notch surface with a K-wire dipped in ink. The 3-dimensional (3D) coordinates of the ACL, AM and PL tunnel marks, points at the marked outline of the ACL, AM and PL insertions and various points at the surface of the notch wall at the medial side of the lateral condyle were digitized using an optical tracking system (Polaris, NDI Medical, Ontario Canada), with an accuracy 0.35 mm. The results were post-processed in MATLAB (version 7, The MathWorks Inc., Natick, Massachusetts, USA). All points at the notch surface were used to fit a plane with a least squares approach (Figure 5). The points of the insertion outlines were projected on this plane, as were the tunnel mark points. Then, the center of the insertion was determined as the center of gravity of the area enclosed by the points on the outlines. Finally, the tunnel placement error in the plane of the bony surface was calculated as the distance between the 2D position of the actual insertion center (A) and the 2D position of the tunnel mark (T), defining the tunnel location. The mean difference defined the accuracy of the tunnel positioning using the 3D molds method, the standard deviations represented the precision.

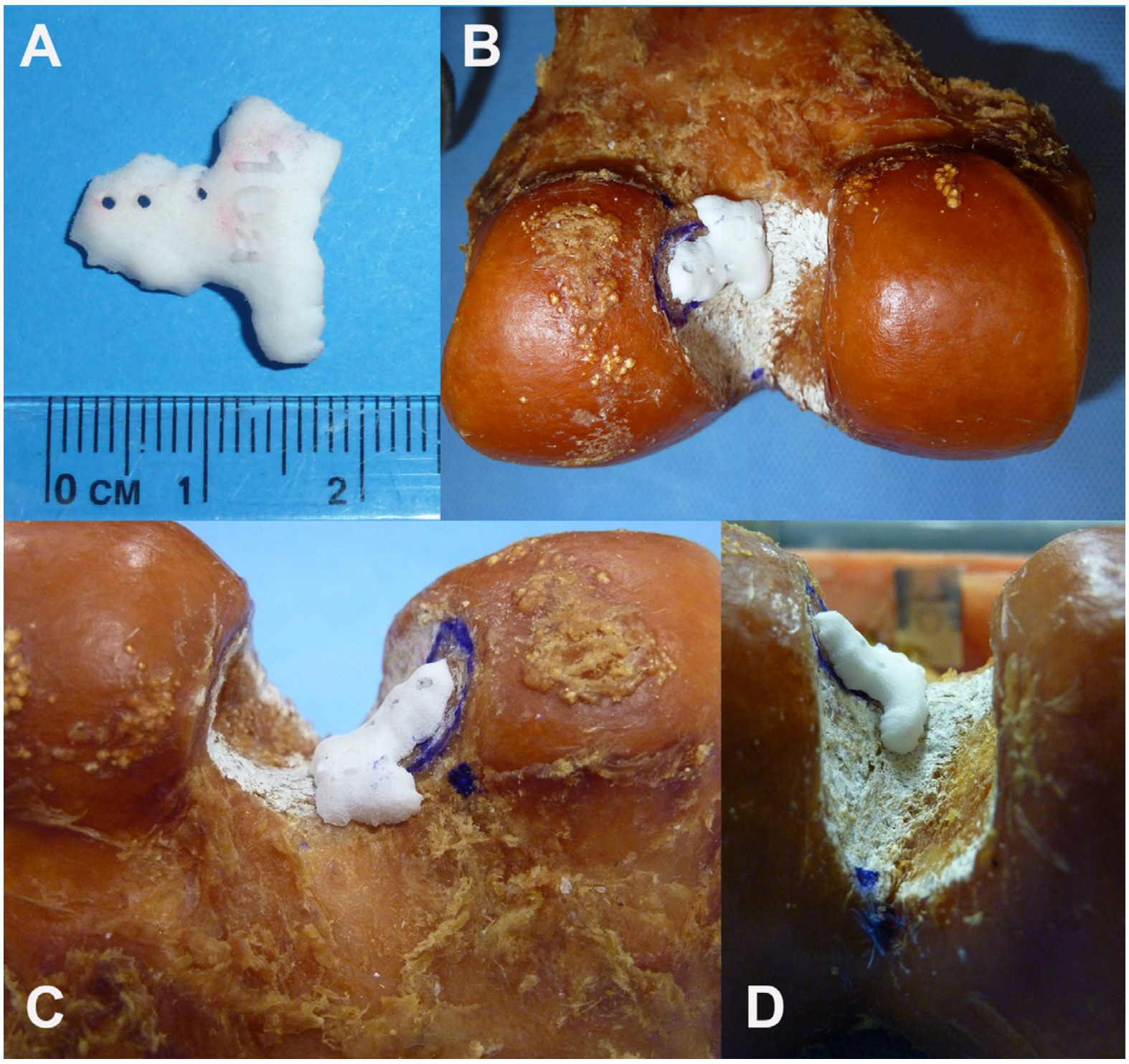

Figure 4. A) The 3D printed mold; positioned in the intercondylar notch B) dorsal view; C) proximal view and; D) distal view .

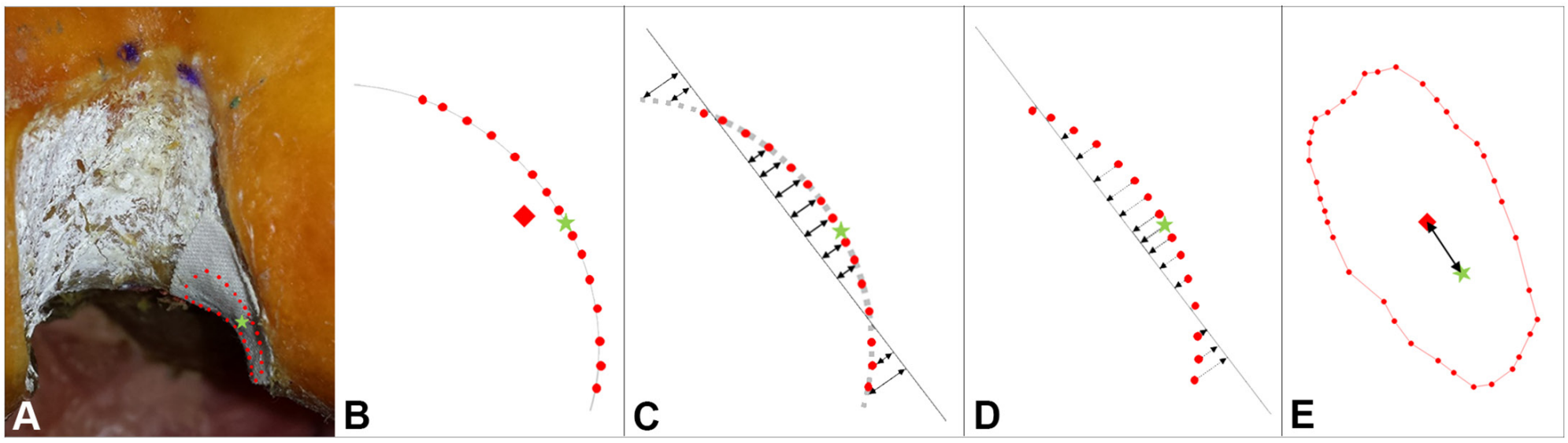

Figure 5. A) The ACL insertion outline (red dots) and the ACL tunnel mark (green star) at the concave notch wall. B) The center of the actual ACL insertion (red diamond A), calculated as center of gravity of the area enclosed by the outline, will be positioned above the notch wall (grey line). C) A plane was fitted through all digitized points in the notch (notch surface points=grey squares, red dots=ACL insertion outline, green star=ACL tunnel mark T) with the least squares approach (black arrows). D) The points at the ACL insertion outline and the ACL tunnel mark are projected at the plane. E) The actual ACL center (red diamond A) is calculated as the center of gravity of the area enclosed by the line through the points of the ACL insertion outline. The tunnel placement error (black arrow) is determined as the 2D distance between the actual ACL center (A) and the ACL tunnel mark (T).

Results

All six molds fitted uniquely in the intercondylar notch. They could be placed in only one position at the surface, resulting in a stable position of the device (Figure 3). The accuracy of the tunnel positions derived from the mold in the six femurs (G-L) was excellent (Table 2), with mean errors being nearly similar for all tunnels ranging between 1.2 and 1.3 mm. Precision varied between 0.5 mm (AM), 0.6 mm (ACL) and 0.7 mm (PL), respectively. The individual errors in tunnel positions ranged from 0.6 mm to 2.1 mm with the largest error for an AM tunnel (Table 2).

Table 2. The tunnel placement errors* of the 3D mold (mm)

	ACL	AM	PL
Femur 1	0.8	2.1	1.9
Femur 2	1.3	0.9	0.6
Femur 3	1.6	1.1	0.8
Femur 4	0.6	1.2	0.6
Femur 5	0.8	1.3	1.9
Femur 6	2.0	0.8	1.7
Mean	1.2	1.2	1.3
SD	0.6	0.5	0.7

**The distance between the digitized tunnel marks obtained with the mold and the calculated anatomical centers in the lateral plane in the individual femurs.*

Discussion

Femoral tunnel position influences the clinical success of ACL reconstruction [10, 27, 41, 43], but remains a challenging task [26, 31]. Various methods of improving accuracy of tunnel placement have been developed and various outcomes have been reported. The present paper presents a new technique facilitating accurate anatomical tunnel placement combining a previously developed method for determination of 3D femoral ACL center positions and the potentials of the new technology of rapid prototyping, by printing a 3D customized mold with incorporated ACL, AM and PL tunnel holes derived from individual 3D CT data. Unique fitting of the 3D mold at the surface of the intercondylar notch has the potential to increase the accuracy of a tunnel placement device independent of surgeons guiding the device.

The accuracy results, the mean differences between the tunnel center marks and the actual insertion centers (gold standard) were within 1.2 mm, which is promising and better as compared to two other tunnel placement methods previously developed by the current authors. These methods were tested on the same femurs, using the same analysis methods, which insures valid comparison between the prior method and the 3D printed mold. The first method, a real time computer assisted system with a template to position the tunnels, adapted to the femoral notch, resulted in accuracies between 2.5 mm and 3.5 mm [24]. The second experiment with a newly developed femoral guide, the GAFT (guide for anatomical femoral tunnels), showed errors of 1.7 and 2.0 mm in hands of the most skillful surgeons during arthroscopic placement tests on cadaveric femur specimens (unpublished data).

The method in the current study has accuracy similar to the surgical robot system CASPAR® with a reported accuracy of 1.3±1.0 mm [33]. In other studies, good accuracies for tunnel placement using a guidewire positioned visually at the center of the ACL footprint in an outside-in technique were reported by Gadikota et al. (1.5 ± 1.2 mm [12]) and Kaseta et al. (1.9 ± 1.0 mm [20]). However, the placement of the guidewire in these methods largely depends of the surgeon's knowledge and skills. The 3D patient specific mold technique of the current study is at least as accurate as anything reported in the literature and therefore a very promising method to be further developed for clinical use.

It should be noted that the current study has certain limitations. One of the limitations is the use of cadaveric specimens fixated in formalin. The intercondylar notch was dissected down to the bone, leaving no soft tissue. The mold fitted perfectly and uniquely on this bare surface. Although the shape of the mold is also an important factor, contributing to the perfect and unique fit, further research should explore whether a mold in the intercondylar notch of a patients knee covered with soft tissue will fit with equal perfection. Furthermore, the total insertion site, including the indirect insertion of the fanlike fibers besides the direct midsustance fibers, was used to determine the insertion center position. The concept was tested in only a limited number of specimens, comparable to some other studies [13]. Despite the limited number, the results of the mean position of the ACL centers, relative to the femoral dimensions, are almost equal to the means measured in all twelve femurs (unpublished data). Another limitation is the use of CT-scans in this study, which is not standard in knee surgery. Besides that, we applied average guidelines for tunnel positions. These average positions obviously result in deviations from the native insertion centers. A mold with the personalized center position seems to be the optimal method, which could improve the accuracy. However, the native insertion center is difficult to detect in individual CT-images. Purnell et al. [38] described the position relative to the bony landmarks in the notch, with the resident's ridge or lateral intercondylar ridge representing the anterior border of the femoral ACL insertion and the lateral bifurcate ridge dividing the AM and PL parts. However, the identification of the bony landmarks is not always easy and their presence is often variable [8, 9, 35]. MRI, the standard imaging method in preoperative knee surgery, could possibly be an alternative, but the determination of the individual ACL insertion areas has a mean error of over 5 mm [39]. Furthermore, it is more challenging to obtain accurate bone shapes from MRI images.

Conclusion

CT-based 3D imaging in combination with mean ACL center positions enables development of a unique and stable 3D printed mold which positions the femoral tunnels for ACL reconstruction with an accuracy of 1.3 mm mm relative to the native anatomical center positions in cadaver femurs. This technique has the potential to standardize femoral tunnel placement and reduce tunnel malposition. Further clinical research is needed to develop and validate a device which can be used in orthopedic practise.

References

1. Amis AA, Beynnon B, Blankevoort L, Chambat P, Christel P, Durselen L, Friederich N, Grood E, Hertel P, Jakob R, Müller W, O’Brien M, O’Connor J (1994) Proceedings of the ESSKA Scientific Workshop on Reconstruction of the Anterior and Posterior Cruciate Ligaments. Knee Surg Sport Traumatol Arthrosc 2:124–132.
2. Behrend H, Stutz G, Kessler MA, Rukavina A, Giesinger K, Kuster MS (2006) Tunnel placement in anterior cruciate ligament (ACL) reconstruction: quality control in a teaching hospital. Knee Surg Sports Traumatol Arthrosc 14:1159–1165.
3. Bernard M, Hertel P, Hornung H, Cierpinski T (1997) Femoral insertion of the ACL. Radiographic quadrant method. Am J Knee Surg 10:14–21.
4. Bird JH, Carmont MR, Dhillon M, Smith N, Brown C, Thompson P, Spalding T (2011) Validation of a new technique to determine midbundle femoral tunnel position in anterior cruciate ligament reconstruction using 3-dimensional computed tomography analysis. Arthroscopy Elsevier Inc. 27:1259–1267.
5. Burkart A, Debski RE, McMahon PJ, Rudy T, Fu FH, Musahl V, van Scyoc A, Woo SL (2001) Precision of ACL tunnel placement using traditional and robotic techniques. Comput Aided Surg 6:270–278.
6. Christel P, Sahasrabudhe A, Basdekis G (2008) Anatomic double-bundle anterior cruciate ligament reconstruction with anatomic aimers. Arthroscopy 24:1146–1151.
7. Degenhart M (2004) Computer-navigated ACL reconstruction with the OrthoPilot (R). Surg Technol Int 12:245–251.
8. van Eck CF, Morse KR, Lesniak BP, Kropf EJ, Tranovich MJ, van Dijk CN, Fu FH (2010) Does the lateral intercondylar ridge disappear in ACL deficient patients? Knee Surg Sports Traumatol Arthrosc 18:1184–1188.
9. Farrow LD, Chen MR, Cooperman DR, Victoroff BN, Goodfellow DB (2007) Morphology of the femoral intercondylar notch. J Bone Joint Surg Am 89:2150–2155.
10. Fernandes TL, Fregni F, Weaver K, Pedrinelli A, Camanho GL, Hernandez AJ (2014) The influence of femoral tunnel position in single-bundle ACL reconstruction on functional outcomes and return to sports. Knee Surg Sports Traumatol Arthrosc 22:97–103.
11. Forsythe B, Kopf S, Wong AK, Martins CAQ, Anderst W, Tashman S, Fu FH (2010) The location of femoral and tibial tunnels in anatomic double-bundle anterior cruciate ligament reconstruction analyzed by three-dimensional computed tomography models. J Bone Joint Surg Am 92:1418–1426.
12. Gadikota HR, Sim JA, Hosseini A, Gill TJ, Li G (2012) The Relationship Between Femoral Tunnels Created by the Transtibial, Anteromedial Portal, and Outside-In Techniques and the Anterior Cruciate Ligament Footprint. Am J Sports Med 40:882–888.
13. Gelber PE, Erquicia J, Abat F, Torres R, Pelfort X, Rodriguez-Baeza A, Alomar X, Monllau JC (2011) Effectiveness of a footprint guide to establish an anatomic femoral tunnel in anterior cruciate ligament reconstruction: computed tomography evaluation in a cadaveric model. Arthroscopy 27:817–824.
14. Good L, Odensten M, Gillquist J (1987) Precision in reconstruction of the anterior cruciate ligament: A new positioning device compared with hand drilling. Acta Orthop 58:658–661.
15. Harner CD, Poehling GG (2004) Double bundle or double trouble? Arthroscopy 20:1013–1014.
16. Hoshino Y, Rothrauff BB, Hensler D, Fu FH, Musahl V (2014) Arthroscopic image distortion—part I: the effect of lens and viewing angles in a 2-dimensional in vitro model. Knee Surg Sport Traumatol Arthrosc Epub:10.1007/s00167–014–3336–3.
17. Hoshino Y, Rothrauff BB, Hensler D, Fu FH, Musahl V (2014) Arthroscopic image distortion—part II: the effect of lens angle and portal location in a 3D knee model. Knee Surg Sport Traumatol Arthrosc Epub:10.1007/s00167–014–3268–y.
18. Hull CW (1986) Apparatus for production of three-dimensional objects by stereolithography. US Patent 45753330.
19. Iwahashi T, Shino K, Nakata K, Otsubo H, Suzuki T, Amano H, Nakamura N (2010) Direct anterior cruciate liga-

ment insertion to the femur assessed by histology and 3-dimensional volume-rendered computed tomography. Arthroscopy 26:S13–20.

20. Kaseta MK, DeFrate LE, Charnock BL, Sullivan RT, Garrett WE (2008) Reconstruction technique affects femoral tunnel placement in ACL reconstruction. Clin Orthop Relat Res 466:1467–1474.
21. Klos TV, Habets RJ, Banks AZ, Banks SA, Devilee RJ, Cook FF (1998) Computer assistance in arthroscopic anterior cruciate ligament reconstruction. Clin Orthop Relat Res 65–69.
22. Kopf S, Musahl V, Tashman S, Szczodry M, Shen W, Fu FH (2009) A systematic review of the femoral origin and tibial insertion morphology of the ACL. Knee Surg Sport Traumatol Arthrosc 17:213–219.
23. Luites JWH, Verdonschot N (2015) Radiographic positions of femoral ACL, AM and PL centres: accuracy of guidelines based on the lateral quadrant method. Knee Surg Sport Traumatol Arthrosc Epub:10.1007/s00167–015–3681–x.
24. Luites JWH, Wymenga AB, Blankevoort L, Eygendaal D, Verdonschot N (2014) Accuracy of a computer-assisted planning and placement system for anatomical femoral tunnel positioning in anterior cruciate ligament reconstruction. Int J Med Robot Comput Assist Surg 10:438–446.
25. Luites JWH, Wymenga AB, Blankevoort L, Kooloos JMG, Verdonschot N (2011) Development of a femoral template for computer-assisted tunnel placement in anatomical double-bundle ACL reconstruction. Comput Aided Surg 16:11–21.
26. Marchant BG, Noyes FR, Barber-Westin SD, Fleckenstein C (2010) Prevalence of nonanatomical graft placement in a series of failed anterior cruciate ligament reconstructions. Am J Sports Med 38:1987–9196.
27. Mascarenhas R, Cvetanovich GL, Sayegh ET, Verma NN, Cole BJ, Bush-Joseph C, Bach BR (2015) Does Double-Bundle Anterior Cruciate Ligament Reconstruction Improve Postoperative Knee Stability Compared With Single-Bundle Techniques? A Systematic Review of Overlapping Meta-analyses. Arthroscopy 31:1185–1196.
28. McGuire D, Hendricks S, Grinstead G (1996) Use of an endoscopic aimer for femoral tunnel placement in anterior cruciate ligament reconstruction. Arthroscopy 12:26–31.
29. Mochizuki T, Muneta T, Nagase T, Shirasawa S-I, Akita K-I, Sekiya I (2006) Cadaveric knee observation study for describing anatomic femoral tunnel placement for two-bundle anterior cruciate ligament reconstruction. Arthroscopy 22:356–361.
30. Moloney G, Araujo P, Rabuck S, Carey R, Rincon G, Zhang X, Harner C (2013) Use of a fluoroscopic overlay to assist arthroscopic anterior cruciate ligament reconstruction. Am J Sports Med 41:1794–1800.
31. Morgan JA, Dahm D, Levy B, Stuart MJ (2012) Femoral Tunnel Malposition in ACL Revision Reconstruction. J Knee Surg 25:361–368.
32. Mundi R, Bhandari M (2016) Cochrane in CORR®: Double-bundle Versus Single-bundle Reconstruction for Anterior Cruciate Ligament Rupture in Adults (Review). Clin Orthop Relat Res 1–3.
33. Musahl V, Burkart A, Debski RE, Van Scyoc A, Fu FH, Woo SLY (2003) Anterior cruciate ligament tunnel placement: Comparison of insertion site anatomy with the guidelines of a computer-assisted surgical system. Arthroscopy 19:154–160.
34. Nakagawa T, Takeda H, Nakajima K, Nakayama S, Fukai A, Kachi Y, Kawano H, Miura T, Nakamura K (2008) Intraoperative 3-dimensional imaging-based navigation-assisted anatomic double-bundle anterior cruciate ligament reconstruction. Arthroscopy 24:1161–1167.
35. Norman DG, Getgood A, Thornby J, Bird J, Turley GA, Spalding T, Williams MA (2014) Quantitative topographic anatomy of the femoral ACL footprint: a micro-CT analysis. Med Biol Eng Comput 52:985–895.
36. Picard F, DiGioia AM, Moody J, Martinek V, Fu FH, Rytel M, Nikou C, LaBarca RS, Jaramaz B (2001) Accuracy in tunnel placement for ACL reconstruction. Comparison of traditional arthroscopic and computer-assisted navigation techniques. Comput Aided Surg 6:279–289.
37. Pombo MW, Shen W, Fu FH (2008) Anatomic double-bundle anterior cruciate ligament reconstruction: where are we today? Arthroscopy 24:1168–1177.

38. Purnell ML, Larson AI, Clancy W (2008) Anterior cruciate ligament insertions on the tibia and femur and their relationships to critical bony landmarks using high-resolution volume-rendering computed tomography. Am J Sports Med 36:2083–2090.
39. Rachmat HH, Janssen D, Zevenbergen WJ, Verkerke GJ, Diercks RL, Verdonschot N (2014) Generating finite element models of the knee: How accurately can we determine ligament attachment sites from MRI scans? Med Eng Phys 36:701–707.
40. Rankin TM, Giovinco NA, Cucher DJ, Watts G, Hurwitz B, Armstrong DG (2014) Three-dimensional printing surgical instruments: are we there yet? J Surg Res 189:193–197.
41. Sadoghi P, Kröpfl A, Jansson V, Müller PE, Pietschmann MF, Fischmeister MF (2011) Impact of tibial and femoral tunnel position on clinical results after anterior cruciate ligament reconstruction. Arthroscopy 27:355–364.
42. Sati M, Stäubli H, Bourquin Y, Kunz M, Nolte LP (2002) Real-time computerized in situ guidance system for ACL graft placement. Comput Aided Surg 7:25–40.
43. Zhu Y, Tang R-K, Zhao P, Zhu S-S, Li Y-G, Li J-B (2013) Double-bundle reconstruction results in superior clinical outcome than single-bundle reconstruction. Knee Surg Sports Traumatol Arthrosc 21:1085–1096.

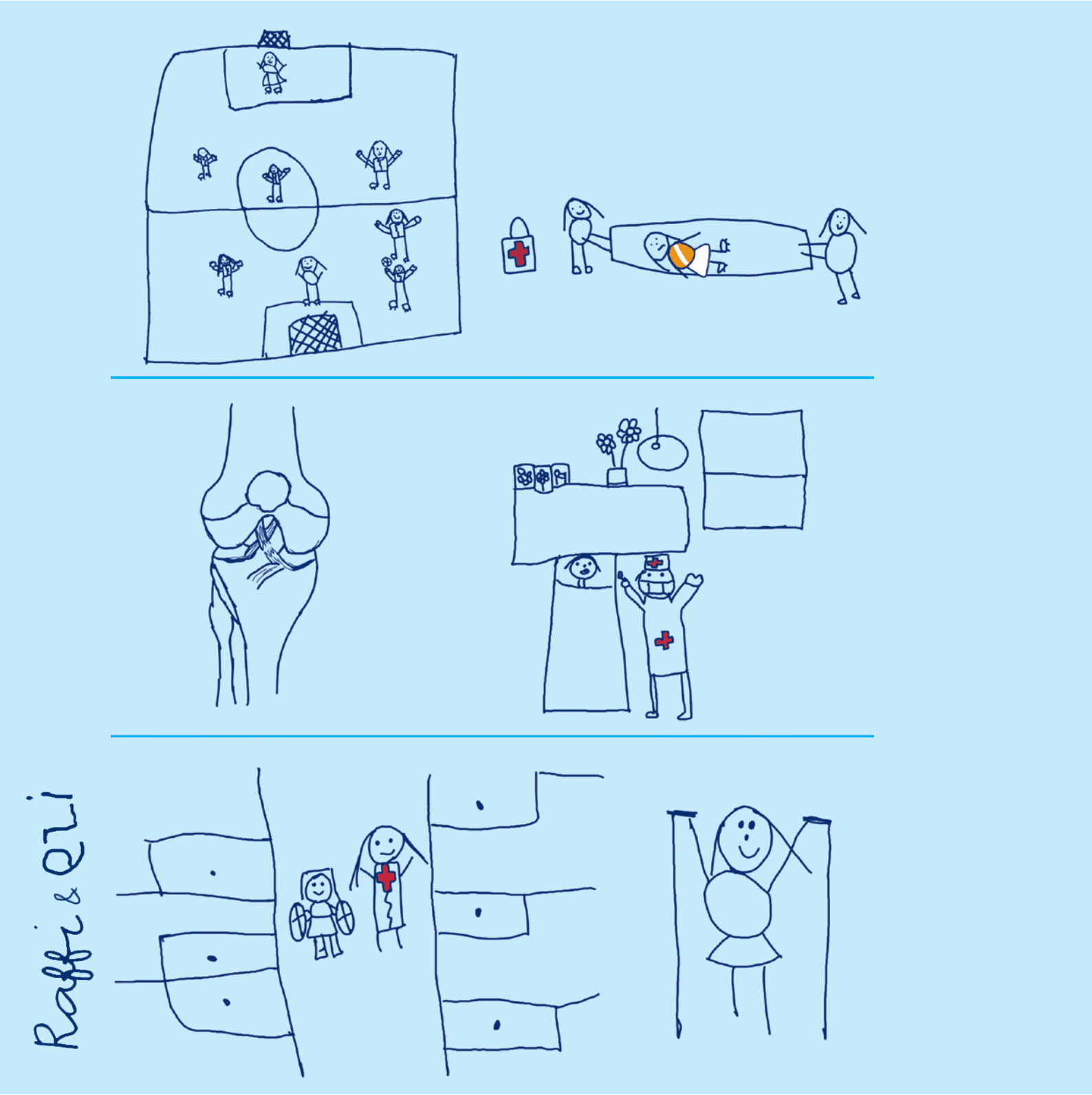
Raffi & Eli

CHAPTER 11

Summary & General discussion

Summary

Knee joint stability is, besides muscle activity, provided by the ligaments in and around the knee. The anterior cruciate ligament (ACL) within the knee joint, is one of the important structures maintaining knee stability. However, this structure is one of the most injured ligaments with 200.000 ruptures in 2006 in de United States. A torn ACL has a large effect on knee functioning. In absence of this structure, the knee becomes instable, negatively influencing daily functioning. More intensive activities, like sports can become impossible. An instable knee is exposed to multiple small traumas causing arthritis. This will result in early damage of the knee, resulting in increasing pain and disability at early age.

A ruptured ACL can be treated conservatively, with physical therapy, restoring knee instability through training of muscle strength and stability exercises. Another option is surgical reconstruction of the ligament. In 2003, over 120.000 ACL reconstructions have been performed in the United States. Hence, this number is more than 50% of the reported ACL ruptures. In the Netherlands approximately 8000 to 9000 ACL reconstructions have been performed in 2012. The surgery does not always turns out to be successful; the reported success rate vary between 69% and 95%. Rates about return to sports activities, especially at the pre trauma level, are relatively low. This could be caused by surgical techniques that are still sub-optimal.

During arthroscopic surgery a torn ACL is replaced by a substitute, a graft, often a hamstrings tendon or part of the patellar tendon. This tendon is positioned in tunnels drilled in the thigh bone (femur) and in the lower tibial bone. The tunnels have to be positioned and drilled accurately. Several choices can be made relative to the tunnel positions. Approximately 50% of ACL reconstruction failures can be attributed to tunnel malplacement in the femoral bone. Tunnel position accuracy correlates with clinical success. A correct placement is essential. However, consensus about the correct location is missing.

In the past decade, placement at the original ACL insertion site has become more popular. However, during an arthroscopical intervention, the anatomical insertion site of the ACL is difficult to determine. Various commercially available instruments, like surgical aiming guides, facilitate determination of the correct tunnel location. However, often these guides aim at isometrical placement: tunnel placement at a location at which the tension of the new graft remains low throughout the complete range of motion, thereby preventing new ruptures. However, isometric placement is a compromise, which was developed during the development of the arthroscopical ACL surgery technique, which decreased the technical options of the surgeon.

In this thesis, the original location of the anatomical ACL insertion is identified. Methods facilitating the determination of the correct femoral tunnel location and supporting the accurate tunnel placement have been developed and validated.

The general introduction in **chapter 1**, describes the aspects of the anterior cruciate ligament and the surgical options for reconstruction from a historical perspective. The ligament structure has been known from the old Egyptian times. The first reconstruction surgeries have been performed at the end of the 19th century, at first, attempting to sew a torn ligament. Around 1910-1920, the first reconstruction techniques were developed, replacing the ACL using tendons of muscles. During the history of ACL reconstruction, lasting about a century now, numerous techniques and methods have been developed and tested. The concept considering the femoral tunnel placement has been a major aspect in that development. During the first 75 years, the reconstruction techniques have been performed during open knee surgeries, an arthrotomy. This provided a relatively wide exposure of the surgical area in the knee. Most surgeons aimed at replacement of the new graft at the original anatomical insertion site. To reach this goal, various surgical guides were developed to locate that position as accurately as possible. Some surgeons developed another concept, in which the tension of the new graft remained constant over the complete range of motion to prevent a new rupture: the isometric technique. The introduction of the arthroscopic technique in the beginning of the eighties, limiting the surgeon's sight and possibilities, resulted in standardization of this isometric concept during the next decade. At first, endoscopic instruments focused on isometric femoral tunnel placement. However, technical development diminished the urge for an isometric compromise and arthroscopic anatomical placement gained popularity again at the end of the last century. Besides replacement of the graft at the anatomical site, the anatomical concept expanded in recovering the two functional bundles of the ACL. These bundles, with fibers arranged in an anteromedial (AM) and a posterolateral (PL) bundle, provide a reciprocal role in the knee stability. Reconstruction of both bundles, thus mimicking the original ACL structure, should result in knee functioning more closely to normal. However, these double bundle techniques demand even more accuracy of the femoral tunnel placement.

Determination of the correct tunnel position demands knowledge of the location of the original anatomical insertion site of the ACL from the surgical perspective during an arthroscopy. The location of the insertion of the two functional ACL bundles relative to identifiable landmarks in the knee, visible during arthroscopy, have been described in **chapter 2**. In this study, the femoral and tibial bones of 35 knee joints were dissected from muscles and tissue till the ACL insertion. The outlines of the marked insertion sites were digitized with a 3-dimensional (3D) measurement system, as was done with the landmarks, visible and identifiable endoscopically. The positions of the mean centers of the AM and PL bundles, as well as of the ACL as whole, relative to the landmarks were calculated. These results can support a surgeon in determining the anatomical tunnel positions, in single bundle (ACL) as well as in double bundle (AM and PL) ACL reconstructions.

The position of the femoral ACL center has been described relative to two structures, which can be identified on lateral radiographs, i.e. the line of Blumensaat and the condyle depth. We applied this quadrant technique to 29 femoral specimens and determined the radiographical position of the AM and PL centers. The mean values resulted in a guideline for pre-operative planning of the tunnel positions in a double bundle ACL reconstruction or for post-operative tunnel position evaluation. The accuracy of this guideline was determined in **chapter 3** and compared with the accuracy of an average guideline, presented by Piefer, who combined the mean results of eight different studies. We determined the radiographic positions of the AM, PL and ACL centers at 12 dissected femoral bones. Next, the guidelines of our study and from Piefer were applied at the 12 radiographs. The accuracy of both guidelines was calculated determining the mean differences between de true anatomical center positions and the locations defined by the guidelines. Finally, the accuracy between the two guidelines was compared, resulting in a inferior accuracy of Piefer's guideline, compared to the guideline from our study. In 92% of the cases calculated with Piefer's guideline, the PL tunnel location error would be larger than 3 mm, a misplacement which, possibly, has effect on knee functioning. The relatively large errors produced by the guidelines proposed by Piefer could be explained by the fact that he averaged results of various studies, although these studies determined different quantities (which are not to be averaged). Most variation was seen in the definition of the insertion site and the determination of the center location. Some studies included the overall insertion site, both the direct attachment area of the mid band fibers as well as the so-called indirect attachment area with the synovial tissue attaching into the bony structure. Other studies only used the direct insertion site. In the choice of tunnel placement, it seems important to have in mind which concept is aimed for, in order to follow the corresponding guideline.

In **chapter 4**, the 3D positions of the anatomical centers of the AM, PL and ACL were determined relative to the distal part of the femur. We obtained CT-scans of 12 femora with marked outlines of the ACL insertion, including the separation into the two functional bundles. The 3D data of the CT-scans were uploaded in a software program to calculate the geometry of the femur. After uniform orientation of all femora, the insertion centers were localized. Next, the dimensions of the distal femur, width, depth and height, were determined. Finally, we calculated the center positions relative to the femoral dimensions, resulting in a mean position with only small variations reflected in standard deviations between 1.3-1.4 mm. This variation is smaller than the center position variation determined at lateral radiographs using the widely used quadrant method. Since the results are consistent, the reported results could be used as guideline in preoperative tunnel placement planning or postoperative evaluation of the tunnel position.

The dissected specimens from the study described in chapter 2 were also used in **chapter 5** for the development of a computer template including the position of the femoral insertion center facilitating accurate femoral tunnel positioning. Both AM and PL, as well as the ACL centers were 3D digitized relative to two reference structures in the femoral intercondylar notch of the knee joint: the notch surface and the cartilage bone transition. A cylinder model with the positions of the mean AM, PL and ACL centers was developed averaging all 3D data. This computer template can be projected in the patient's knee using a computer assisted surgery (CAS) system. After digitizing the notch surface and the cartilage bone transition of the lateral femoral condyle, the computer scales the cylinder to the patient's knee and positions it in the correct position. The positions of the three centers are projected in the notch. Finally, the surgeon can drill accurately the tunnel(s) at the projected location of the anatomical centers using a computer-tracked drill.

The validation of this computer template has been described in **chapter 6**. At two different moments, two orthopedic surgeons, experienced in ACL reconstructions, positioned the ACL template in 12 dissected femora, marking the proposed projected AM, PL and ACL center positions. The accuracy of the template positioning, determining the anatomical tunnel location, was calculated comparing positions of the marked centers from the template with the positions of the true anatomical centers. The accuracy of marking a predefined point with the CAS system, tunnel mark placement, was also calculated. The accuracy of determining the tunnel location using the CAS system to position the average template was approximately 3 mm. We regard this result as acceptable, as it will probably not result in a changed biomechanical behavior of the knee joint. The accuracy of computer assisted tunnel mark placement was excellent with a mean error of 0.4 mm, resulting in an overall error of the total procedure (tunnel localization by template positioning and placement by marking) within 3 mm. The inter- and intra-surgeon reproducibility of the overall procedure, calculated using the results of double measurements within and between the two surgeons, were comparable to the accuracy of the total procedure (about 3 mm).

In **chapter 7**, the developed CAS placement system including the femoral template, was used in a cadaver experiment, comparing the stability of the anatomical double bundle (ADB) ACL reconstruction with the isometric single bundle (ISB) ACL reconstruction. First, the stability in anterior and posterior direction of eight intact cadaveric knee specimens was determined, measuring the position of the tibia relative to the femur in loaded and unloaded conditions. Next, the ACL was cut and the measurements were repeated. After that, the ACL was reconstructed using four different methods: 1) with an AM graft tensed with 15N in an angle of 90°; 2) with a PL graft tensed with 15N in an angle of 15°; 3) with a ADB using the AM and PL graft; 4) with a standard isometric technique. All reconstructions recovered the increased instability of the knee after cutting the ACL. The ADB best approached the stability of the normal knee with the intact ACL over de complete range of motion, whereas the ISB failed in the smaller flexion angles. The ADB technique can lead to even better results using higher tension values and fixating the AM in a different angle.

During the history of ACL reconstructions, surgeons developed various concepts to restore a torn ACL. Multiple instruments have been developed to facilitate the executing of the different aspects of the various concepts during surgery. The guides supporting in drilling the femoral ACL tunnel at the correct location take a prominent position in the reconstruction history. The instruments vary at the different technical aspects: a) drilling canals for the graft sutures or tunnel drilling for the graft; b) drilling a tunnel inside-out or reversed; c) use during an arthrotomy or an arthroscopy; d) anatomical or isometrical positioning; e) a surgeon-oriented guide, placed by the surgeon at the desired location and supporting him in drilling the tunnel or an aiming device, placing the tunnel at the correct location through the design. An historical overview of these instruments and the supported concepts has been given in **chapter 8**. Within this context the results of guide validation studies were also been described. During the last decade, guides mostly facilitated arthroscopical anatomical tunnel placement. Although various studies addressed the accuracy of the older femoral guides, literature with the validation results of the newest guides is lacking.

The anatomical femoral insertion center positions from chapter 2 were used to develop a surgical aiming device resulting in localization ánd placement of a tunnel in the ACL-center for an anatomical single bundle ACL reconstruction or two tunnels in the AM and PL centers for an anatomical double bundle ACL reconstruction. The guide validation study is described in **chapter 9**. After several test designs, a prototype, based on the design of the commonly used endoscopic guide for isometric tunnel placement, was developed: the ‘guide for anatomic femoral tunnel placement’, the GAFT. This prototype was tested in a cadaveric experiment using twelve femoral bones. Experiments were performed using direct guide placement under visual control, testing the accuracy of the guide design, as well as guide placement using an arthroscopic view at the monitor by orthopedic surgeons and residents, testing the accuracy of the practical endoscopic use. The accuracy of direct guide placement was compared to the accuracy of a standard endoscopical femoral aimer at the 11 (isometric placement) and 10 (anatomical placement) o'clock position. Tunnel mark placement errors with GAFT, calculated as the distance between the tunnel marks and the true anatomical centers, were small. The mean error was between 1.6 and 1.9 mm for the three tunnel mark positions. All AM tunnel mark errors, positioned with the GAFT were within 3 mm from the anatomical AM insertion center. No tunnel mark showed a deviation larger than 5 mm. The tunnel marks of the isometric guide, positioned under visual control at 11 ánd 10 o'clock, showed larger errors with means of 4.1 and 2.8 mm, respectively. The results for the GAFT confirms the correctness of its design, turning it in potency suitable for accurate anatomical tunnel placement. An important condition to achieve this potential accuracy during an arthroscopic surgery is accurate application of the guide positioning protocol. This condition became apparent during the arthroscopic guide placement by four residents and one orthopedic surgeon. The accuracy results varied from excellent (mean error of 1 mm) till moderate (mean error of 3.5 mm). We could not detect a relationship between the accuracy and the experience of the surgeon/resident.

The results of chapter 4, the 3D positions of the anatomical centers relative to the dimensions of the distal femur at CT-scans, served as basic data to produce an innovative 3D printed mold fitting uniquely in a patient's knee, as described in **chapter 10**. The insertion center positions found in six femora, using the method from chapter 4, have been used to calculate the ACL, AM and PL tunnel positions in six other femora. A computer program generated a print file for a 3D mold from the 3D tunnel position data, including the surface structure data of the femoral intercondylar notch. Six molds were 3D printed and positioned in the notch, marking the tunnel positions. The tunnel mark position errors, the distance between the tunnel marks and the true anatomical centers, appeared to be small with means of 1.2 and 1.3 mm. These results are promising for the development of a personalized aiming guide for accurate tunnel localization and placement in anatomical single bundle or double bundle ACL reconstructions in the future.

General discussion

BACKGROUND

It is demonstrated in this thesis that a tissue as small as less than 2.5 cm^2 with a long history of research studies, still can provide work for more than a decade for one researcher. The insertion area of the anterior cruciate ligament in the femoral intercondylar notch, I refer to, remains a hot topic in the orthopedic literature. This thesis addresses several aspects of the anatomical insertion and how to drill a femoral tunnel for the ACL graft during the reconstruction of a torn ligament at that position. However, it is also clear that there is still work to do.

An ACL rupture is a very common injury and often treated with surgery to restore the ligament in an ACL reconstruction. Untreated ACL-deficient knees are often instable, resulting in functional limitations and an increased risk of additional injury of the menisci eventually resulting in osteoarthritis (OA). ACL reconstruction is aiming at restoring knee stability and near normal kinematics in order to prevent OA and providing the patient the possibility to return to his or her pre-injured activity level.

Successful outcome after ACL reconstructions, achieving normal or nearly normal knee function, is rated between 69% and 95% [3, 4, 67]. It is not demonstrated irrefutable yet that ACL reconstruction decreases the chance of OA [18]. This could be due to various factors, like additional meniscus injury occurring at the same time as the ACL injury, influencing the outcomes [5]. Claes et al. reported a percentage of 28% of reconstructed knees showing radiological signs of osteoarthitis [10]; 50% of these patients had an meniscectomy, compared to 16% of the patients without meniscectomy. Nevertheless, studies do report better knee stability after anatomical ACL reconstruction [65], a condition which is important in the prevention of OA.[2] Return to sport percentages between 51% [34] and 66% [3] are reported, with 45% returning to their pre-injury level and 29% playing competitive sport [3]. These numbers leave room for improvement.

Many aspects of the ACL reconstruction techniques can be listed for improvement. The basic thought is to better reproduce the conditions of the native ACL. Since femoral tunnel malpositioning is the main cause (50%) of graft failure [39, 47], this aspect is an important candidate to improve the overall quality of ACL reconstruction. In this thesis we developed methods for better anatomic tunnel positioning (determining the anatomic location) and placement (actually placing the tunnel), by answering nine research questions as stated in the introduction. We determined the positions of the anatomical insertion from arthroscopic perspective (1), at radiographs (2) and with CT-scans (3); developed a computer template positioning the femoral tunnels with CAS (4), validated it (5) and applied it in an experiment with single- and double-bundle reconstructions (6); disclosed the concepts behind femoral tunnels in ACL reconstruction using femoral guides (7) and developed an anatomical guide (8) and a personalized mold for tunnel placement (9).

Despite the answers produced during the work of this thesis, some issues remain: Firstly, the choice for the best tunnel location(s) derived from the anatomical insertion. Secondly, femoral tunnel placement accuracy and the discussion about the clinical relevance of double bundle grafts and the added value of innovations such as the use of computer assisted surgery (CAS). Thirdly, the quest for the best tunnel positioning and placement method. These three issues are discussed below.

Anatomical tunnel location(s)

The best tunnel location is still subject of discussion within the orthopaedic community. Although the literature suggests that the concept of anatomical reproduction has become more favorable relative to the isometric reconstruction technique over the last decade [11, 19], it still is unclear what the best position is for the femoral tunnel within this anatomical concept [24]. Through history, the anatomical area is determined, resulting in variable findings. Besides the anatomical variation within a group of human subjects [33], the actual definition and determination of the insertion area is also variable. Firstly, dissection is dependent to individual experience and skills during determination of the insertion outlines, especially when the ACL is dissected in the two functional bundles. The outcome of the dissection, therefore, is subjected to human error and bias [25], with various proposals of the 'true' positions of the centers of the bundles [6, 12, 17, 21], including of this thesis including (**Chapter 2**) Secondly, the insertion can be divided in the ACL fibers of the midsubstance, inserting direct to the notch, and the broader attachment margin of the natural ACL with the surface membrane,[45] later referred to as the direct and indirect insertion [44]. Iriuchishima reported a significant different position of the centers of the AM and PL bundles when the fan-like extension (indirect) fibers were either included or not included [26].

This aspect of direct and indirect fibers provokes a new debate about the best tunnel location concept. Mochizuki concluded that, in contrast to the midsubstance fibers, the fanlike fibers cannot be reconstructed easily using a tunnel technique [26]. However, the fanlike fibers and the underlying bone are additional parts of the ligament unit which functions as one complex, contributing to the constraining function of the ligament [29]. Although this complex structure cannot be replaced by a simple graft, it seems justified to include this area during anatomical reconstruction and position the tunnel in the center of the whole insertion area. Moreover, it is important during ACL reconstruction to clearly make a choice for a tunnel location concept in relation to this aspect and use the correct guidelines, as in this thesis (**Chapter 3**), it is shown that application of an average guideline composed of various concepts [53], results in less accurate tunnel placement.

Furthermore, Iwahashi et al. and Sasaki et al. reported the impossibility to distinguish the direct and indirect insertions by macroscopic observation [27, 58]. The question is whether more sophisticated dissection methods reveal more information, especially concerning the biomechanical properties of the direct and indirect insertion, similar as the differences reported recently in the microstructural properties of the AM and PL bundle [64]. This kind of information could contribute to the definition of the optimal ACL replacement technique, resulting in the optimal choice for tunnel location. Furthermore, with the current techniques of bio-enhanced ACL repair [55], tissue engineering [52], and techniques with cell source and growth factors [35], it could be possible in the future to reconstruct the ACL more physiologically with more biological implant techniques.

Femoral tunnel placement accuracy

Anatomical reproduction of the native ACL attachment increased the interest in double bundle techniques, as well as the development of various fixation methods, over the last 15 years. The two main concepts are two bundles in one central tunnel or two bundles in two tunnels for AM and PL reconstruction. The different attachment positions of the two bundles should result in an additional stability effect on the anterior laxity by the PL-graft over the stability from an anatomical single AM-graft as demonstrated in the in-vitro study of Loh [36] and amplified by the results presented in this thesis (**Chapter 6**). However, in the initial phase of the double bundle technique, some specialists, like Harner [22], asked the question whether one should 'bother the trouble' for double bundle reconstructions, since there is no evidence for superior clinical results and the technique is more demanding, increasing the risk of failure. Eriksson proposes to favor single bundle techniques, as long as the additional value of double-bundle techniques have not been proven with evidence-based medicine including randomized studies with a long follow-up [16].

Various clinical studies have been performed since, but the results are diverse. Where some studies report clinical evidence in favor of the double bundle reconstructions [48, 63, 66], other studies could not find clinical differences for lower positioned tunnels relative to higher tunnels [28, 62] or between single and double bundle ACL reconstruction [30, 59]. These variable results in clinical studies added to the extra risks associated with double bundle reconstructions, is emphasized in the recent published opinion of Lubowitz [38], stating a continual prefererence for single bundle reconstructions.

The same issue, lack of clinical evidence, is also often seen in clinical studies comparing tunnel placement using conventional methods and computer assisted surgery systems. CAS is claimed to improve accuracy during tunnel placement [50, 51, 61], and was demonstrated in this thesis (**Chapter 5**), but is not supported by clinical studies [15]. Since it is demonstrated that the position of the femoral tunnels influences the in-vitro kinematic outcome [36, 41, 42, 49, 68, 69], it is research worthy to philosophize about the causes of the discrepancy between the in-vitro outcomes and clinical results. Four questions about this aspect can be posed: 1) What is the postoperative accuracy of femoral tunnels in clinical studies relative to the anatomical positions? 2) Which accuracy in anatomical tunnel placement is necessary to result in normal in-vitro tested biomechanical stability 3) Which accuracy in anatomical tunnel placement is necessary to result in clinically better outcome? 4) Which in-vitro stability difference results in clinically relevant benefits?

What is the postoperative accuracy of femoral tunnels in clinical studies relative to the anatomical positions?

It is remarkable that multiple clinical studies comparing ACL-grafts at different tunnel positions, do not report data about the final postoperative tunnel position [15, 30, 59, 62]. Jepsen et al. did measure the postoperative tunnel positions, but did not include the outcome in his conclusion [28]. Their intention was to compare the clinical outcomes of grafts positioned at the high (11:00) and low (10:00) positions in the notch. They reported that there were no clinical differences, but actually they did not detect a difference in the postoperative clock position between both tunnels. The femoral tunnel placement method was apparently not accurately enough to position the grafts at the planned positions. Therefore the conclusion that there were no clinical differences between the high and low tunnel positions should not have been drawn from this study.

The importance of data about postoperative femoral tunnel positions is also referred to by others for both cadaveric [13] and clinical studies [14], but the discussion has not led to the application of better methods to determine the anatomical accuracy yet. In this thesis (Chapter 4), we introduced a new 3D method to quantify postoperative femoral tunnel placement, however, the results are based on average anatomical center positions, as is true for other methods published in literature [6, 37]. Since patients show variation in ACL anatomy [33], more accurate methods to compare the 3D tunnel position with the individual ACL-attachment site must be defined. Two studies made a comparison of the femoral tunnel with the ACL insertion at the contralateral side [7, 60], with methods which could be explored in the future.

Studies which compared conventional versus CAS tunnel placement methods did measure the postoperative femoral tunnel positions. Some studies could not detect tunnel position differences [43, 54], while others reported a significant more optimal accurate postoperative tunnel placement relative to a pre-planned position with CAS compared to the conventional method, however, without clinical benefit [9, 23]. The surgeons in one study were experienced and positioned the tunnels anatomically without CAS [43]. Besides that, the postoperative tunnel position measurement methods were not adequate to accurately determine anatomical placement [9, 23, 43, 54].

In a recent retrospective study, Ahn et al. choose a different starting point. He reported the relationship between postoperative tunnel position and the long-term clinical outcomes after double bundle ACL reconstructions [1]. The patients were divided in two groups, based on their postoperative tunnel positions. In the anatomic group both AM and PL tunnels were located within two specific segments determined with the quadrant method. If either the AM or PL tunnel was not in that segment, the patients were assigned to the non-anatomic group. The tunnel postions for the AM tunnels differed significantly between both groups with only 3% of the tunnels of the nonanatomic group in the anatomical segment; The PL tunnel positions were not different, 67% of the non-anatomical group was in the anatomic segment.The results showed, that the clinical outcomes and graft maturation at a second look arthroscopy of the anatomic group were better than the outcomes of the non-anatomic group. Wether the postoperative measurement method is the most adequate to determine anatomical positioning will not be discussed here, but this study relates the postoperative tunnel position to clinical outcome, an inevitable need in future studies.

Which accuracy in anatomical tunnel placement is necessary to result in normal in-vitro tested biomechanical stability?

Several studies have been performed to evaluate the influence of various femoral tunnel positions on in-vitro knee kinematics [36, 41, 42, 49, 68, 69]. However, a value for the maximal allowable anatomical tunnel positioning error, which would still result in normal biomechanical behavior, has not been established yet. In this thesis (**Chapter 3**), combining the results of previous mentioned biomechanical studies, the limit was set at 3-4 mm. However, this value is not similar for the entire insertion area and can vary for deviations in the various directions in the intercondylar notch. Kinematics are more sensitive to anterior displacement relative to posterior deviations [41]. Further research to determine the maximum tunnel position error relative to the anatomical insertion is therefore needed.

Which accuracy in anatomical tunnel placement is necessary to result in clinically better outcome?

It is informative to relate the anatomical tunnel position error to in-vitro biomechanical consequences, however, in the end it is all about the relation of the tunnel position to clinical improved biomechanical outcomes. Ahn et al. demonstrated clinical differences between anatomical and non-anatomical tunnel positions, but did not report about the accuracy of the tunnel positions [1]. Chouteau et al. reported the difference in tunnel position errors between CAS (2.5 mm) and a conventional method (7.0 mm), but did not detect a clinical benefit for the more accurate method [9]. Therefore, the answer to this question is not clear and still a subject for future research.

Which in-vitro stability difference results in clinically relevant benefits?

It is also possibile to relate the in-vitro stability differences, resulting from the different tunnel positions, to functional relevant better outcome. Seon et al. reported significantly better intra-operative internal rotational stability (2°) for the lower 10 o'clock tunnel relative to the higher 11 o'clock tunnel [62]. This did not result in a reduction of the residual pivot-shift phenomenon 2 years postoperative. Since they did not report the postoperative tunnel positions, it is not possible to relate this effect to the tunnel positions. Still, a 2° in-vitro difference seems not clinically relevant in terms of functional activities. Therefore, a topic for further research is to explore the relation between the intra-operative kinematics and clinical outcomes.

TUNNEL POSITIONING AND PLACEMENT METHODS: GRADING THE VARIOUS OPTIONS

The anatomical insertion geometry and methods to position and place the femoral tunnel at that native anatomical location were the topics in this thesis. A listing can be made to identify the various devices and techniques for tunnel positioning and placement together with several aspect determining the usability of the methods in clinical practice (Table I). With the results of this thesis, we made an analysis of the following methods:

- **Freehand placement**
  In this method, the surgeon utilizes his anatomical knowledge, skills and experience to determine the correct anatomical location without specific drill guides or aiming devices, but only with a guide wire or awl.
- **Standard endoscopic femoral aimer**
  This is the standard guide, originally developed for arthrosopic isometric tunnel placement, placing the guide at the 11/1 o'clock position at the intercondylar notch. Nowadays it is often used through the anteremedial portal for anatomic tunnel placement at positions rotated more lateral towards 10/2 or even 9/3 o'clock.
- **Anatomical aimer (GAFT)**
  The design of this device in combination with the placement protocol support the surgeon to determine the correct tunnel location(s) at the native anatomical insertion.

- **Personalized 3D printed mold with average tunnels**
  This 3D aid is a personalized device which is printed based on the combination of patients CT-data and average 3D tunnel positions in the distal femur. It fits uniquely at the surface of the intercondylar notch, indicating the anatomical tunnel positions.
- **Computer Assisted Surgery with incorporated template**
  This CAS system is developed in the projects of this thesis and exploits the possibilities of CAS technique by realtime digitizing the patiënts knee intra-operatively. The template includes the positions for anatomic single bundle tunnel at the ACL-center and for double bundle tunnels at AM and PL centers.
- **CASPAR** (computer-assisted surgical planning and robotics; U.R.S.-Orho, Rastatt, Germany)
  This surgic al robotic system is an active CAS system, which solely drills the tunnel, after tunnel positioning preplanned by the surgeon, based on the quadrant method at lateral views of CT-data.

Various aspects play a role in grading the methods. We divided them in aspects with major and minor influence on the grading:

Major aspects

- Accuracy anatomical placement
  The most important aspect, in the context of this thesis, with ACL reconstruction aiming-for reproduction of the native ligament positioning the graft at the anatomical insertion, is the accuracy.
  Average errors < 2 mm: ++; Between 2 and 4 mm: +; > 4 mm:-
- Clinical effect
  Although the influence of inaccuracy of tunnel placement on clinical outcome is not exactly known, we tried to estimate this aspect, by categorizing the accuracy.
  Unacceptable errors > 5 mm, have influence on the postoperative knee kinematics and will affect the clinical outcome negatively:- ; Errors < 5 mm will not have a negative clinical effect: 0
- Dependency surgeon
  The application of a device requires more or less specific anatomical knowledge about the exact ACL-insertion and skills from the surgeon due to technique which is adapted in the device. The less dependency, the more the device is suitable for universal use.
  Major dependency: +++; Intermediate dependency: ++; Minor dependency: +; No dependency: 0
- Extra costs
  Naturally, the costst for the instruments and conditions required in the methods play a major role. High extra costs: +++; Moderate extra costs: ++; Low extra costs: +; No extra costs: 0
- Additional time
  Related to the costs-aspect is the additional pre-operative time for preplanning or intra-operative time which is required to execute the method.
  Preplanning: +; No preplanning:-; Extra OK time: +; No extra time: 0

Minor aspects

- Conditions
  Some methods require extra conditions influencing the applicability.
- Additional opportunities
  Some methods have some extra opportunities
- Capacity for improvement
  Some devices are at the end stage of development: 0; In some devices, there is room for development regarding the improvement of the accuracy or patient specific tunnel positioning: +
- Flexibility
  Some devices are focused on one goal in (anatomic) tunnel positioning: 0, other devices can be used flexible for various tunnel locations after adaptations: +; some devices can be applied directly for other tunnel positions: ++
- Availability
  All devices have been developed, however, some devices are available: +; some devices are not on the market any more: 0; or not available yet:-

Table 1. The aspects of the various methods for tunnel positioning and placement

Technique	**Free hand**	**Standard EFA**	**Anatomical guide (GAFT)**	**Personalized mold average tunnels**	**CAS**	**Current study**
Accuracy anatomical placement	Range – till +	AM: - [a] / + [b] PL: - [a,b]	+	++	+	++
Clinical effect	-	-	0	0	0	0
Dependency skill surgeon	+++	++	+	0	+	0
Extra costs	0	+	+	++	+++	+++
Additional time	0	0	0	+	+	++
Pre planning **OK time**	- 0	- 0	- 0	+ 0	+ -	+ +
Conditions	-	-	-	CT scan	DRB's [c]	CT scan DRB's [c]
Additional opportunities	-	-	-	-	Notch impingement	Active drilling system
Capacity for improvement	+	0	+	++	++	++
Flexibility	++	0	0	+	+	+
Availability	+	+	-	-	0	+

[A] Transtibial; [b] Anteromedial portal; [c] DRB's: Dynamic reference bases for tracking instruments and bones

Considering, and in the context of this thesis, the accuracy of anatomical tunnel placement as the most important aspect, the results of personalized 3D printed mold and the robotic system CASPAR, are the most promising methods. CASPAR, the active robotic system, acts during tunnel drilling independent of the surgeons skills. A disadvantage of the CASPAR system is the requirement of a CT-scan for pre-operative planning; CT-scans are not a commonly used imaging modality during ACL treatment. The CAS system with the, in this thesis developed template, has a slightly lower accuracy compared to the robotic system. However, due to the real-time navigation, extra imaging is not required. Other disadvantages are the extra time for preplanning (CASPAR) and during surgery and the wounds caused by the trackers, which are required for intra-operative navigation. In addition, computer systems are sensitive for disruptions, require a learning curve and have relatively high costs [40]. In the view of availability, the development of CAS systems for tunnel placement in ACL reconstructions seems to be stagnating. Besides aforementioned reasons, this could be possibly due to the previously discussed lack of scientific evidence of clinical advantage of the use of CAS in tunnel positioning and placement [20]. Nowadays CAS is mainly used for the evaluation of the biomechanics and kinematics of knee motion [32], but clinically hardly utilized anymore.

Free hand placement is, obviously, the cheapest method, taking the least time and usable without any conditions. However, on average, this method has the largest error variation regarding anatomic tunnel positioning, since accuracy is completely dependent of the surgeon's knowledge, skills and experience [8]. In reported studies, this technique is often used, however, mostly by ACL reconstructions experts. For the individual surgeon performing only a few reconstructions in a year, this method is not recommended. Besides increased anatomical knowledge, using additional support, like intra-operative fluoroscopic control could improve the accuracy [31, 46]. However, this will increase the costs and the patient is exposed to extra radiation.

The aspect of the surgeon determining the tunnel position holds, besides the disadvantage of larger risk at inaccuracy, also an advantage. When the concept of tunnel location changes, the surgeon can, in theory, immediately adapt the tunnel position. Free hand positioning is therefore flexible. This is completely in contrast with the EFA, anatomical guides and aimers, of which the design should be adapted. For the other methods the guidelines of the average tunnel positions should be adapted, which is possible, but takes research and implementation time.

In view of the costs, an important aspect in care nowadays, femoral aiming guides are, besides the freehand technique, the cheapest solution. A standard EFA guide has more versions with several offset sizes, which can be chosen relative to the notch size. Costs are limited to the first purchase of the guides and the sterilization costs. However, application of a standard EFA guide, especially used in the classical transtibial manner, results in non-anatomical placement. Using this guide through the anteromedial portal, which has become the standard nowadays, results in better accuracy for the AM-tunnel. However, larger revision rates are reported for this technique [56]. Furthermore, application in an anatomical double bundle reconstruction technique is doubtful, because of the impossibility to reach the anatomical position for the PL-tunnel. This is in contrast with the possibilites of the anatomical aimer device, developed in this thesis, which positions the PL tunnel at the anatomical insertion accurately. This instrument has one size and comes in two versions, one for right and one for left knees, and can be used repeatedly, reducing the costst. Although the accuracy is in potential high, as with the EFA guide, the actual obtained accuracy is dependent on the surgeon's exactness following the placement protocol. Besides that, the guide has not yet been validated in clinical practice. At the commercial market, other anatomical guides/aimers are available. For these devices, the clinical accuracy performances are unclear, since these results are not available in literature. In order to grade these guides, validity studies are required.

The most innovative tunnel placement method which is developed in this thesis is the 3D printed personalized mold. The accuracy of the application of this device should be surgeon independent, although the concept has to prove itself in a clinial patient series. The in vitro results in cadaveric femora are very encouraging. Although the mold has to be produced separately for each patient, costs are limited, since costs for 3D printing have reduced substancially over the last few years. However, the method has to be adopted in clinical practise. A disadvantage is, like in CASPAR, the use of CT-scans for the production of the 3D print file. In this method, the regular CT could be replaced by a cone beam CT, which has sufficient quality to produce the 3D mold, but reduces radiation. The most commonly imaging technique used during ACL rupture treatment, MRI has, at this moment, insufficient power to map the bony contour reliably for the production of a 3D print of the surface. The evolution of the MRI technique in the future could make this technique suitable to produce the 3D mold, including the patient specific ACL attachment.

From this analysis as listed in Table 1 it becomes clear that free hand tunnel positioning and the use of EFA guides are the cheapest techniques, yet show the largest risks for inaccurate placement. Therefore, these methods are not advisable, especially for low volume surgeons. Validated anatomic guides and aiming devices make a cheaper compromise for the accurate, though expensive and sensitive CAS and robotic systems. The concept with the 3D printed mold, is a promising, relatively cheap method with high accuracy results and less unconditional demands. However, this technique requires valorisation in the market.

FINAL REMARKS

Many aspects of femoral tunnel position in ACL reconstruction technique, like anatomical placement, double bundle techniques and tunnel position accuracy, have evolved during the last decennia. The work in this thesis has contributed with new knowledge and methods for more accurate anatomical femoral tunnel postioning and placement. However, proof for better clinical outcome relative to the established techniques is lacking. Because the clinical benefit is unclear, it is not possible yet to study the cost effectiveness of these methods accurately. Therefore, the choice for a tunnel positioning method and placement device remains a personal choice for the surgeon. This urges the need for new research studies with long-term follow up and study design with accurate postoperative tunnel position measurements, to detect the clinical advantages and overall cost efficiency of these new techniques [57]. Furthermore, multiple aspects of ACL reconstruction still can be improved, enough to start another decade of ACL research.

References

1. Ahn JH, Kim JD, Kang HW (2015) Anatomic Placement of the Femoral Tunnels in Double-Bundle Anterior Cruciate Ligament Reconstruction Correlates With Improved Graft Maturation and Clinical Outcomes. Arthroscopy 1–10.
2. Andriacchi TP, Mündermann A, Smith RL, Alexander EJ, Dyrby CO, Koo S (2004) A framework for the in vivo pathomechanics of osteoarthritis at the knee. Ann Biomed Eng 32:447–457.
3. Ardern CL, Taylor NF, Feller JA., Webster KE (2012) Return-to-Sport Outcomes at 2 to 7 Years After Anterior Cruciate Ligament Reconstruction Surgery. Am J Sports Med 40:41–48.
4. Bach BR (2003) Revision anterior cruciate ligament surgery. Arthroscopy 19 Suppl 1:14–29.
5. Barenius B, Ponzer S, Shalabi A, Bujak R, Norlén L, Eriksson K (2014) Increased risk of osteoarthritis after anterior cruciate ligament reconstruction: a 14-year follow-up study of a randomized controlled trial. Am J Sports Med 42:1049–1057.
6. Bernard M, Hertel P, Hornung H, Cierpinski T (1997) Femoral insertion of the ACL. Radiographic quadrant method. Am J Knee Surg 10:14–21.
7. Bowers AL, Bedi A, Lipman JD, Potter HG, Rodeo S a, Pearle AD, Warren RF, Altchek DW (2011) Comparison of anterior cruciate ligament tunnel position and graft obliquity with transtibial and anteromedial portal femoral tunnel reaming techniques using high-resolution magnetic resonance imaging. Arthroscopy 27:1511–1522.
8. Burkart A, Debski RE, McMahon PJ, Rudy T, Fu FH, Musahl V, van Scyoc A, Woo SL (2001) Precision of ACL tunnel placement using traditional and robotic techniques. Comput Aided Surg 6:270–278.
9. Chouteau J, Benareau I, Testa R, Fessy MH, Lerat JL, Moyen B (2008) Comparative study of knee anterior cruciate ligament reconstruction with or without fluoroscopic assistance: a prospective study of 73 cases. Arch Orthop Trauma Surg 128:945–950.
10. Claes S, Hermie L, Verdonk R, Bellemans J, Verdonk P (2013) Is osteoarthritis an inevitable consequence of anterior cruciate ligament reconstruction? A meta-analysis. Knee Surg Sports Traumatol Arthrosc 21:1967–1976.
11. Clancy WG (2015) Anatomic ACL reconstruction: The final answer? Knee Surg Sports Traumatol Arthrosc 23:636–639.
12. Colombet P, Robinson J, Christel P, Franceschi J-P, Djian P, Bellier G, Sbihi A (2006) Morphology of anterior cruciate ligament attachments for anatomic reconstruction: a cadaveric dissection and radiographic study. Arthroscopy 22:984–992.
13. Van Eck CF, Samuelsson K, Vyas SM, van Dijk CN, Karlsson J, Fu FH (2011) Systematic review on cadaveric studies of anatomic anterior cruciate ligament reconstruction. Knee Surg Sports Traumatol Arthrosc 19 Suppl 1:S101–108.
14. Van Eck CF, Schreiber VM, Mejia HA, Samuelsson K, van Dijk CN, Karlsson J, Fu FH (2010) “Anatomic” anterior cruciate ligament reconstruction: a systematic review of surgical techniques and reporting of surgical data. Arthroscopy 26:S2–12.
15. Eggerding V, Reijman M, Rjpm S, Jan V, De M (2014) Computer-assisted surgery for knee ligament reconstruction (Review). Cochrane Libr.
16. Eriksson E (2007) Anatomic double bundle ACL reconstruction. Knee Surg Sport Traumatol Arthrosc 15:945–945.
17. Ferretti M, Ekdahl M, Shen W, Fu FH (2007) Osseous landmarks of the femoral attachment of the anterior cruciate ligament: an anatomic study. Arthroscopy 23:1218–1225.
18. Fleming BC, Hulstyn MJ, Oksendahl HL, Fadale PD (2005) Ligament injury, reconstruction and osteoarthritis. Curr Opin Orthop 16:354–362.
19. Fu FH, Eck CF Van, Tashman S, Irrgang JJ, Moreland MS (2015) Anatomic anterior cruciate ligament reconstruction: a changing paradigm. Knee Surg Sport Traumatol Arthrosc 23:640–648.
20. Goradia VK (2014) Computer-assisted and Robotic Surgery in Orthopedics : Where We Are in 2014. Sport Med Arthrosc Rev 22:202–205.
21. Guo L, Yang L, Wang A-M, Wang X-Y, Dai G (2009) Roentgenographic measurement study for locating femoral

insertion site of anterior cruciate ligament: a cadaveric study with X-Caliper. Int Orthop 33:133–137.

22. Harner CD, Poehling GG (2004) Double bundle or double trouble? Arthroscopy 20:1013–1014.
23. Hart R, Krejzla J, Sváb P, Kocis J, Stipcák V (2008) Outcomes after conventional versus computer-navigated anterior cruciate ligament reconstruction. Arthroscopy 24:569–578.
24. Howell SM, Hull M, McAllister D (2012) Be sensible and cautious about criticizing tunnel placement in ACL reconstruction. J Bone Joint Surg Am 94:e133.
25. Iriuchishima T, Ingham SJM, Tajima G, Horaguchi T, Saito A, Tokuhashi Y, Van Houten AH, Aerts MM, Fu FH (2010) Evaluation of the tunnel placement in the anatomical double-bundle ACL reconstruction: a cadaver study. Knee Surg Sports Traumatol Arthrosc 18:1226–1231.
26. Iriuchishima T, Ryu K, Aizawa S, Fu FH (2016) The difference in centre position in the ACL femoral footprint inclusive and exclusive of the fan-like extension fibres. Knee Surg Sport Traumatol Arthrosc 24:254-259.
27. Iwahashi T, Shino K, Nakata K, Otsubo H, Suzuki T, Amano H, Nakamura N (2010) Direct anterior cruciate ligament insertion to the femur assessed by histology and 3-dimensional volume-rendered computed tomography. Arthroscopy 26:S13–20.
28. Jepsen CF, Lundberg-Jensen AK, Faunoe P (2007) Does the position of the femoral tunnel affect the laxity or clinical outcome of the anterior cruciate ligament-reconstructed knee? A clinical, prospective, randomized, double-blind study. Arthroscopy 23:1326–1333.
29. Jung H-J, Fisher MB, Woo S (2009) Role of biomechanics in the understanding of normal, injured, and healing ligaments and tendons. Sport Med Arthrosc Rehabil Ther Technol 1:9.
30. Kang HJ, Wang XJ, Wu CJ, Cao JH, Yu DH, Zheng ZM (2015) Single-bundle modified patellar tendon versus double-bundle tibialis anterior allograft ACL reconstruction: a prospective randomized study. Knee Surg Sports Traumatol Arthrosc 23:2244–2249.
31. Klos TV, Habets RJ, Banks AZ, Banks SA, Devilee RJ, Cook FF (1998) Computer assistance in arthroscopic anterior cruciate ligament reconstruction. Clin Orthop Relat Res 65–69.
32. Koh J, Marcus MS (2014) Computer-assisted Anterior Cruciate Ligament (ACL) Reconstruction : The US Perspective. Sport Med Arthrosc Rev 22:206–214.
33. Kopf S, Musahl ÆV, Tashman ÆS, Szczodry M, Shen ÆW, Fu ÆFH (2009) A systematic review of the femoral origin and tibial insertion morphology of the ACL. Knee Surg Sport Traumatol Arthrosc 17:213–219.
34. Langford JL, Webster KE, Feller JA (2009) A prospective longitudinal study to assess psychological changes following anterior cruciate ligament reconstruction surgery. Br J Sports Med 43:377–381.
35. Leong N, Kabir N, Arshi A, Nazemi A, Wu B, Petrigliano F a, McAllister DR (2015) Evaluation of polycaprolactone scaffold with basic fibroblast growth factor and fibroblasts in an athymic rat model for anterior cruciate ligament reconstruction. Tissue Eng Part A 21:1859–1868.
36. Loh JC, Fukuda Y, Tsuda E, Steadman RJ, Fu FH, Woo SLY (2003) Knee stability and graft function following anterior cruciate ligament reconstruction: Comparison between 11 o'clock and 10 o'clock femoral tunnel placement. 2002 Richard O'Connor Award paper. Arthroscopy 19:297–304.
37. Lorenz S, Elser F, Mitterer M, Obst T, Imhoff AB (2009) Radiologic evaluation of the insertion sites of the 2 functional bundles of the anterior cruciate ligament using 3-dimensional computed tomography. Am J Sports Med 37:2368–2376.
38. Lubowitz JH (2015) Editorial Commentary: ACL Reconstruction: Single-Bundle Versus Double-Bundle. Arthroscopy 31:1197–1198.
39. Marchant BG, Noyes FR, Barber-Westin SD, Fleckenstein C (2010) Prevalence of nonanatomical graft placement in a series of failed anterior cruciate ligament reconstructions. Am J Sports Med 38:1987–1996.
40. Margier J, Tchouda SD, Banihachemi J-J, Bosson J-L, Plaweski S (2015) Computer-assisted navigation in ACL reconstruction is attractive but not yet cost efficient. Knee Surg Sports Traumatol Arthrosc 23:1026–1034.
41. Markolf KL, Hame S, Hunter DM, Oakes D a, Zoric B, Gause P, Finerman G a M (2002) Effects of femoral tunnel

placement on knee laxity and forces in an anterior cruciate ligament graft. J Orthop Res 20:1016–1024.

42. Markolf KL, Jackson SR, McAllister DR (2010) A comparison of 11 o'clock versus oblique femoral tunnels in the anterior cruciate ligament-reconstructed knee: knee kinematics during a simulated pivot test. Am J Sports Med 38:912–917.
43. Meuffels DE, Reijman M, Verhaar JAN (2012) Computer-Assisted Surgery Is Not More Accurate or Precise Than Conventional Arthroscopic ACL Reconstruction: A Prospective Randomized Clinical Trial. J Bone Joint Surg Am 94:1538–1545.
44. Mochizuki T, Fujishiro H, Nimura A, Mahakkanukrauh P, Yasuda K, Muneta T, Akita K (2014) Anatomic and histologic analysis of the mid-substance and fan-like extension fibres of the anterior cruciate ligament during knee motion, with special reference to the femoral attachment. Knee Surg Sports Traumatol Arthrosc 22:336–344.
45. Mochizuki T, Muneta T, Nagase T, Shirasawa S-I, Akita K-I, Sekiya I (2006) Cadaveric knee observation study for describing anatomic femoral tunnel placement for two-bundle anterior cruciate ligament reconstruction. Arthroscopy 22:356–361.
46. Moloney G, Araujo P, Rabuck S, Carey R, Rincon G, Zhang X, Harner C (2013) Use of a fluoroscopic overlay to assist arthroscopic anterior cruciate ligament reconstruction. Am J Sports Med 41:1794–1800.
47. Morgan JA, Dahm D, Levy B, Stuart MJ (2012) Femoral Tunnel Malposition in ACL Revision Reconstruction. J Knee Surg 25:361–368.
48. Muneta T, Koga H, Mochizuki T, Ju Y-J, Hara K, Nimura A, Yagishita K, Sekiya I (2007) A prospective randomized study of 4-strand semitendinosus tendon anterior cruciate ligament reconstruction comparing single-bundle and double-bundle techniques. Arthroscopy 23:618–628.
49. Musahl V, Burkart A, Debski RE, Van Scyoc A, Fu FH, Woo SLY (2003) Anterior cruciate ligament tunnel placement: Comparison of insertion site anatomy with the guidelines of a computer-assisted surgical system. Arthroscopy 19:154–160.
50. Musahl V, Burkart A, Debski RE, Van Scyoc A, Fu FH, Woo SL-Y (2002) Accuracy of anterior cruciate ligament tunnel placement with an active robotic system: A cadaveric study. Arthrosc J Arthrosc Relat Surg 18:968–973.
51. Nakagawa T, Hiraoka H, Fukuda A, Kuribayashi S, Nakayama S, Matsubara T, Nakamura K (2007) Fluoroscopic-based navigation-assisted placement of the tibial tunnel in revision anterior cruciate ligament reconstruction. Arthroscopy 23:443.e1–4.
52. Nau T (2015) Regeneration of the anterior cruciate ligament: Current strategies in tissue engineering. World J Orthop 6:127–136.
53. Piefer JW, Pflugner TR, Hwang MD, Lubowitz JH (2012) Anterior cruciate ligament femoral footprint anatomy: systematic review of the 21st century literature. Arthroscopy 28:872–881.
54. Plaweski S, Cazal J, Rosell P, Merloz P (2006) Anterior cruciate ligament reconstruction using navigation: a comparative study on 60 patients. Am J Sports Med 34:542–552.
55. Proffen BL, Sieker JT, Murray MM (2015) Bio-Enhanced Repair of the Anterior Cruciate Ligament. Arthroscopy 31:990–997.
56. Rahr-Wagner L, Thillemann TM, Pedersen AB, Lind MC (2013) Increased risk of revision after anteromedial compared with transtibial drilling of the femoral tunnel during primary anterior cruciate ligament reconstruction: results from the Danish Knee Ligament Reconstruction Register. Arthroscopy 29:98–105.
57. Rayan F (2015) Review of evolution of tunnel position in anterior cruciate ligament reconstruction. World J Orthop 6:252.
58. Sasaki N, Ishibashi Y, Tsuda E, Yamamoto Y, Maeda S, Mizukami H, Toh S, Yagihashi S, Tonosaki Y (2012) The femoral insertion of the anterior cruciate ligament: discrepancy between macroscopic and histological observations. Arthroscopy 28:1135–1146.
59. Sastre S, Popescu D, Núñez M, Pomes J, Tomas X, Peidro L (2009) Double-bundle versus single-bundle ACL reconstruction using the horizontal femoral position: A prospective, randomized study. Knee Surg Sport Traumatol

Arthrosc 18:32–36.

60. Scanlan SF, Lai J, Donahue JP, Andriacchi TP (2012) Variations in the three-dimensional location and orientation of the ACL in healthy subjects relative to patients after transtibial ACL reconstruction. J Orthop Res 30:910–918.
61. Schep NWL, Stavenuiter MHJ, Diekerhof CH, Martens EP, van Haeff CM, Broeders I a MJ, Saris DBF (2005) Intersurgeon variance in computer-assisted planning of anterior cruciate ligament reconstruction. Arthroscopy 21:942–947.
62. Seon JK, Park SJ, Lee KB, Seo HY, Kim MS, Song EK (2011) In vivo stability and clinical comparison of anterior cruciate ligament reconstruction using low or high femoral tunnel positions. Am J Sports Med 39:127–133.
63. Seon JK, Song EK, Bae BH, Park SJ, Yoon TR, Cho SG, Lee JJ, Kim MS (2007) Kinematic study following double-bundle, anterior cruciate ligament reconstruction. Int Orthop 31:623–628.
64. Skelley NW, Castile RM, York TE, Gruev V, Lake SP, Brophy RH (2015) Differences in the Microstructural Properties of the Anteromedial and Posterolateral Bundles of the Anterior Cruciate Ligament. Am J Sports Med 43:928–936.
65. Taketomi S, Inui H, Nakamura K, Hirota J, Sanada T, Masuda H, Takeda H, Tanaka S, Nakagawa T (2014) Clinical outcome of anatomic double-bundle ACL reconstruction and 3D CT model-based validation of femoral socket aperture position. Knee Surg Sports Traumatol Arthrosc 22:2194–2201.
66. Ventura A, Iori S, Legnani C, Terzaghi C, Borgo E, Albisetti W (2013) Single-bundle versus double-bundle anterior cruciate ligament reconstruction: assessment with vertical jump test. Arthroscopy 29:1201–1210.
67. Yasuda K, Tanabe Y, Kondo E, Kitamura N, Tohyama H (2010) Anatomic double-bundle anterior cruciate ligament reconstruction. Arthroscopy 26:S21–34.
68. Zantop T, Herbort M, Raschke MJ, Fu FH, Petersen W (2007) The role of the anteromedial and posterolateral bundles of the anterior cruciate ligament in anterior tibial translation and internal rotation. Am J Sports Med 35:223–227.
69. Zavras TD, Race A, Amis AA (2005) The effect of femoral attachment location on anterior cruciate ligament reconstruction: graft tension patterns and restoration of normal anterior-posterior laxity patterns. Knee Surg Sports Traumatol Arthrosc 13:92–100 .

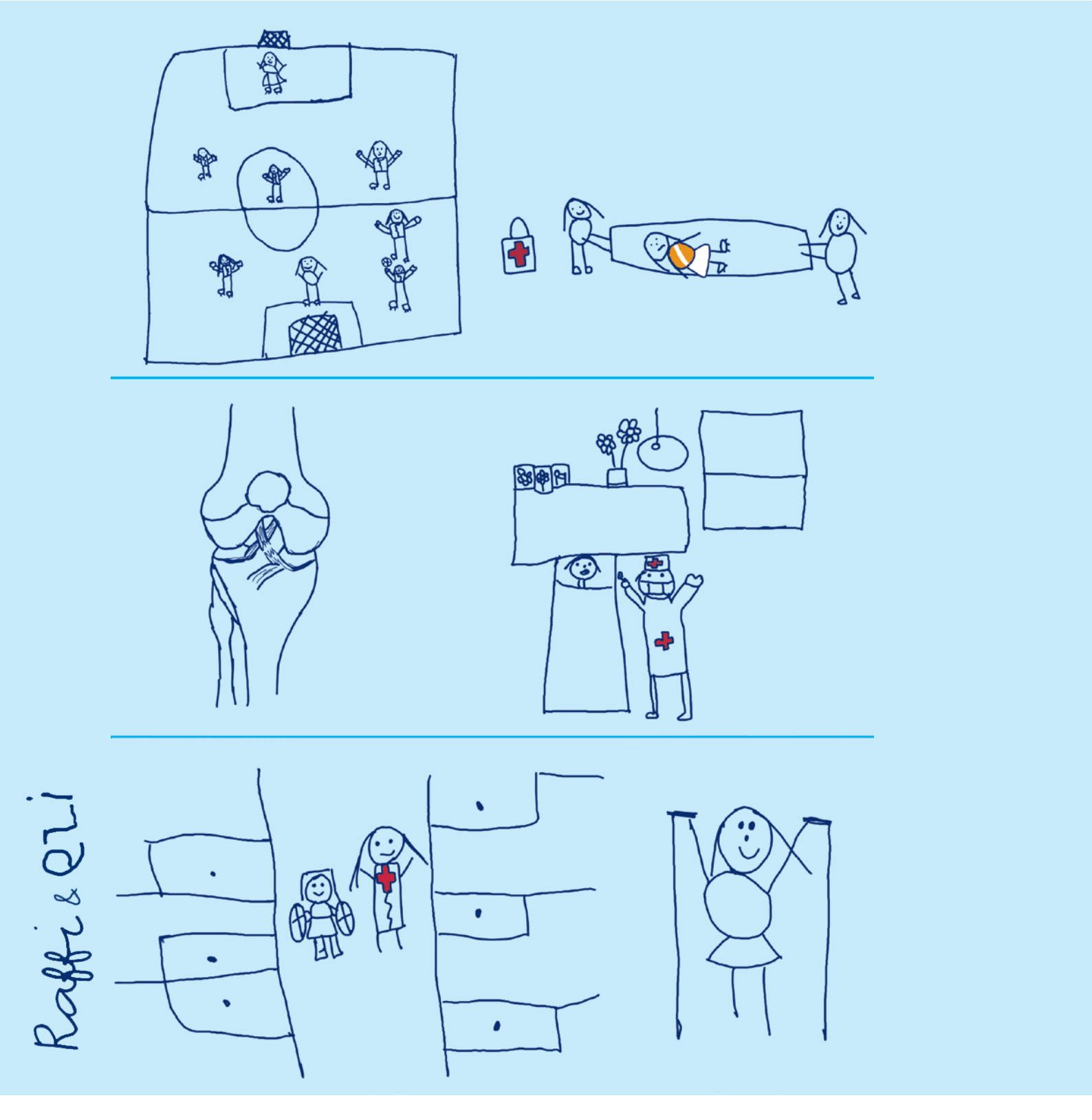
Raffi & Eli

CHAPTER 12

Samenvatting
Dankwoord
Curriculum Vitae

Samenvatting

De stabiliteit van de knie wordt, naast spieractiviteit, verzorgt door bandstructuren in en om de knie. De voorste kruisband (VKB), een band die in het kniegewricht loopt, speelt daarbij een belangrijke rol. Dit ligament is echter de meest voorkomende structuur die door een trauma wordt beschadigd (ruim 200.000 VKB rupturen werden geregistreerd in de VS in 2006). Een gescheurde VKB heeft een grote invloed op het functioneren van de knie. Door het ontbreken van de structuur verliest de knie stabiliteit, waardoor het dagelijkse functioneren negatief wordt beïnvloedt en intensievere activiteiten, zoals sporten, zelfs onmogelijk kunnen worden. Een instabiele knie zal onderhevig zijn aan veelvuldige kleine trauma's, die gewrichtsslijtage bevorderen. Hierdoor zal de knie op vroege leeftijd beschadigd raken met nog meer pijn met mogelijke invaliditeit tot gevolg.

Een mogelijke behandeling voor een gescheurde kruisband is conservatieve therapie, bijvoorbeeld fysiotherapie, waarbij men de stabiliteit van de knie met behulp van spierkrachttraining en stabiliteitsoefeningen tracht te herstellen. Daarnaast wordt een kruisbandletsel vaak hersteld met behulp van een operatie waarbij geprobeerd wordt de VKB te reconstrueren. In de Verenigde Staten werden in 2003 ruim 120.000 VKB-reconstructies uitgevoerd, dat is dus meer dan de helft van het gerapporteerde aantal VKB blessures. In Nederland werden in 2012 ongeveer 8000 tot 9000 hersteloperaties uitgevoerd. Dat de operatie niet bij iedereen succesvol is blijkt uit de succes percentages, variërend van 69% tot 95%, die worden gerapporteerd. Ook de terugkeer naar sportactiviteiten, met name naar het niveau van vóór de blessure, is relatief laag. Dit heeft onder andere te maken met specifieke handelingen van de operatie die niet optimaal worden uitgevoerd.

De voorste kruisband wordt tijdens een kijkoperatie, een arthroscopie, vervangen door een nieuwe structuur, de zogenaamde graft. Dit is meestal een deel uit de pees van de Hamstrings of van de pees van de knieschijf. Deze peesgraft wordt in de knie geplaatst in geboorde tunnels in het onderbeen en in het bovenbeen. De tunnelplaatsing moet zeer nauwkeurig uitgevoerd worden, waarbij diverse keuzes gemaakt kunnen worden. Ongeveer 50% van falende gevallen van de hersteloperatie kan worden verklaard door een verkeerde plaats van de tunnel in het bovenbeen. Die nauwkeurigheid van de positie correleert met het klinische succes. Een juiste plaatsing is dus essentieel. Echter, consensus over de beste locatie ontbreekt.

De laatste jaren is er een trend zichtbaar, die pleit voor plaatsing op de positie waar de oorspronkelijke kruisband zich bevond. Echter, tijdens een kijkoperatie is met name die plek op het bovenbeen moeilijk te bepalen. Er zijn diverse hulpmiddelen op de markt, zoals een chirurgische guide, die ondersteunen bij het selecteren van de juiste locatie. Echter, deze guides zijn vooral gericht op plaatsing op een locatie, waarbij de nieuwe kruisband zo min mogelijk op spanning komt om een nieuwe ruptuur te voorkomen, de zogenaamde 'isometrische positie'. Maar deze positie is een compromis, met name ontstaan tijdens de ontwikkeling van de kijkoperatie, waarbij een arts minder technische mogelijkheden kreeg.

In dit proefschrift is onderzocht wat de oorspronkelijke locatie van de aanhechting van de voorste kruisband is en zijn methoden ontwikkeld en getest die, gebruik makend van de moderne technologie, de plaatsing van de tunnel in het bovenbeen op de juiste plek faciliteren.

De algemene inleiding in **hoofdstuk 1** beschrijft de aspecten van de voorste kruisband en de chirurgische mogelijkheden met betrekking tot herstel vanuit een historisch perspectief. De structuur was al bekend in de Egyptische oudheid; de eerste hersteloperaties stammen van eind 19e eeuw, waarbij allereerst werd geprobeerd om de gescheurde band te hechten. Rond 1910-1920 werden de eerste operatietechnieken ontwikkeld, waarbij de VKB werd hersteld met behulp van andere pezen. In de geschiedenis van de VKB-reconstructies, die nu circa 100 jaar bestaat, zijn ontelbare technieken en methodieken ontwikkeld en getest.
Een belangrijke ontwikkeling is het concept met betrekking tot de plaatsing van de bovenbeen tunnel geweest. Tijdens de eerste 75 jaar werden de hersteloperaties uitgevoerd terwijl de knie werd opengemaakt, op die manier was er redelijk veel zicht op het operatiegebied. De meeste chirurgen probeerden de nieuwe graft op de oorspronkelijke locatie te herstellen. Hiervoor werden hulpmiddelen ontwikkeld in de vorm van chirurgische haakjes (guides) om die locatie op het bovenbeen zo nauwkeurig mogelijk te bereiken. Sommige chirurgen bedachten een concept waarbij de spanning in de nieuwe kruisband zo laag mogelijk moest blijven tijdens het bewegen ter voorkoming van een nieuwe ruptuur: de isometrische plaatsing.
Door de introductie van de kijkoperatie, waarbij de arts nog minder zicht en mogelijkheden had, werd dit concept tijdens de jaren ‘80 meer en meer de standaard methode. De endoscopische hulpmiddelen waren ook gericht op deze isometrische plaatsing van de tunnel in het bovenbeen. Echter, de technische vooruitgang tornde aan dit compromis en arthroscopisch anatomische plaatsing werd weer populairder aan het einde van de vorige eeuw. Het herstel van de anatomie kwam nog meer tot uiting in de nieuwe technieken waarbij, naast anatomische graft plaatsing, ook de functionele tweedeling van de VKB werd getracht te herstellen. De VKB bestaat namelijk uit vezels die gegroepeerd liggen in twee bundels, de anteromediale (AM) en posterolaterale (PL), die beide een aanvullende rol in de stabiliteit van de knie hebben. Het herstel van beide bundels, waarbij de oorspronkelijke structuur beter wordt benaderd, zou tot een meer normale kniefunctie kunnen leiden. Deze zogenaamde dubbelbundel technieken vereisen echter nog meer nauwkeurigheid ten aanzien van de tunnelplaatsing in het bovenbeen.

Om de juiste positie van de tunnel te kunnen bepalen, is het belangrijk om te weten waar de plaats van de oorspronkelijke kruisband in de knie is vanuit het perspectief dat de chirurg heeft tijdens een arthroscopische ingreep. In **hoofdstuk 2** staat beschreven waar de aanhechting van de twee functionele bundels van de voorste kruisband zich bevinden ten opzichte van herkenbare referentiepunten in de knie tijdens de kijkoperatie. In de studie werden hiervoor 35 femora (bovenbeen botstukken) en tibiae (onderbeen botstukken) geprepareerd, ontdaan van spieren en ander weefsel, tot en met de aanhechting van de VKB. De gemarkeerde posities werden vervolgens met een 3-dimensionaal meetsysteem in kaart gebracht. Dit gebeurde ook met de referentiestructuren, die zichtbaar en herkenbaar zijn tijdens een kijkoperatie. De posities van de gemiddelde centra van zowel de AM en PL bundel, als de ACL als geheel, werden beschreven ten opzichte van de referenties. Met de resultaten kan een chirurg tijdens een VKB reconstructie de beoogde anatomische posities van de tunnels bepalen, zowel voor een enkel- als een dubbelbundel techniek.

In de ontwikkeling van hulpmiddelen is de positie van het ACL centrum op het bovenbeen ook beschreven ten opzichte van twee radiologisch herkenbare structuren, de Blumensaatlijn en de condyldiepte op een laterale röntgenfoto. In een studie hebben wij deze kwadrant techniek toegepast op 29 preparaten en de radiologische posities van de AM- en PL centra bepaald. De gemiddelde waarden vormen een richtlijn voor de tunnel posities in een dubbelbundel reconstructie, die voor de preplanning of als postoperatieve controle kunnen worden gebruikt. In **hoofdstuk 3** hebben we de nauwkeurigheid van deze richtlijn bepaald en vergeleken met de nauwkeurigheid van een gemiddelde richtlijn, door Piefer samengesteld uit de resultaten van 8 verschillende studies. Hiervoor hebben we op 12 geprepareerde bovenbeen botstukken opnieuw de radiologische posities van de AM- en PL centra en van de ACL als geheel, bepaald. Vervolgens werden de richtlijnen vanuit onze studie en die van Piefer toegepast. De nauwkeurigheid van beide richtlijnen werd berekend uit de verschillen tussen de werkelijke centrum posities en de voorspelde locaties. Vervolgens werd bepaald of de nauwkeurigheid tussen beide richtlijnen verschilde. Het bleek dat de richtlijn van Piefer minder nauwkeurig was, dan die van onze studie.
In 92% van de gevallen zou de fout in de PL tunnel van Piefer groter zijn dan 3 mm, een fout die mogelijk gevolgen heeft voor het functioneren van de knie. De methoden die Piefer combineerde, maakten gebruik van verschillende meetmethoden. Met name de definitie van de aanhechting en het centrum varieerden. Sommige studies gebruikten de gehele aanhechting, dus de directe aanhechting van de vezels in het midden van de band mét de zogenaamde indirecte aanhechting van het synoviale weefsel dat overgaat in de botstructuur, anderen definieerden alleen de directe aanhechting. Het is belangrijk om bij de keuze van de tunnelpositie rekening te houden welk concept men wil volgen, om de goede richtlijn te kunnen kiezen.

In **hoofdstuk 4** worden de 3D posities van de anatomische centra van de AM en PL en VKB als geheel, bepaald ten opzichte van het onderste deel van het bovenbeen. We hebben CT-scans gemaakt van de 12 geprepareerde bovenbenen met de gemarkeerde aanhechting van de VKB en de twee functionele bundels die ook gebruikt zijn in de studie van hoofdstuk 3. De 3D data van de CT-scans werd ingeladen in een computer programma waarmee de geometrie van het bovenbeen kan worden berekend. Nadat alle bovenbenen op dezelfde manier waren georiënteerd, zijn de centra van de inserties gelokaliseerd. Vervolgens werden de afmetingen van het bovenbeen, voor diepte, breedte en hoogte bepaald. Daarna werden de posities van de centra relatief tot de afmetingen berekend, waarna alle uitkomsten werden gemiddeld. De centra bleken slechts met een kleine variatie gepositioneerd te zijn ten opzichte van de dimensies van bovenbeen getuige de standaard deviaties van 1.3-1.4 mm. Dit is minder gevarieerd dan de bepaling van de positie op laterale röntgenfoto's volgens de bekende kwadrant methode. Deze consistente resultaten kunnen worden gebruikt als richtlijn voor preoperatieve tunnel positie planning of postoperatieve tunnel positie beoordeling.

De geprepareerde bovenbeen botstukken uit de studie van hoofdstuk 2 zijn in **hoofdstuk 5** gebruikt om een computermodel te ontwikkelen, met daarin de plaats van het centrum van de bovenbeen aanhechting. De positie van de centra van zowel de AM als PL bundel, als de gehele ACL, werden 3-dimensionaal (3D) in kaart gebracht ten opzichte van twee referentiestructuren in de holte van het bovenbeen in het kniegewricht, de intercondylaire notch. Deze referenties zijn het oppervlakte van die holte en de kraakbeenrand die daar loopt. Met behulp van alle 3D gegevens werd een cilindermodel ontwikkeld met daarop de posities van de gemiddelde AM,

PL en ACL centra.
Met behulp van een computer geassisteerd operatie (CAS) systeem kan het computermodel in het bovenbeen van een patiënt worden geprojecteerd. Hiervoor moet het oppervlak van de notch en de kraakbeenrand van de condyl worden gedigitaliseerd. Vervolgens schaalt de computer de cilinder naar de knie van de patiënt en positioneert hem op de goede positie. Daarna projecteert het systeem de posities van de 3 centra in de notch. Tot slot kan de chirurg de tunnel(s) met behulp van een aan de computer gekoppelde boor die ook zichtbaar wordt op het computerscherm, met precisie aanbrengen op de plek van de geprojecteerde anatomische centra.

De validatie van dit ontwikkelde computermodel wordt in **hoofdstuk 6** beschreven. Twee ervaren orthopedisch chirurgen hebben op twee verschillende tijdstippen het computermodel geplaatst in 12 geprepareerde bovenbeen botstukken en de geprojecteerde AM, PL en VKB centra gemarkeerd. Door de posities van de gemarkeerde centra in het geplaatste cilindermodel te vergelijken met de posities van de werkelijke anatomische centra, kon de nauwkeurigheid van het plaatsen van het computermodel, de anatomische tunnel lokalisering, worden berekend. Tevens is de nauwkeurigheid bepaald van de mogelijkheid dat het CAS systeem wordt gebruikt om een gedefinieerd punt te markeren, de tunnel plaatsing. De nauwkeurigheid van de procedure om met behulp van het computer systeem en het gemiddelde computermodel de tunnelpositie te lokaliseren was ongeveer 3 mm. Dit lijkt een acceptabele fout, die geen biomechanische consequenties heeft. De nauwkeurigheid van computer geassisteerde tunnel plaatsing was met gemiddeld 0.4 mm, uitstekend, waardoor de afwijking van de procedure gemiddeld 3 mm bleef. De intra- en interobserver reproduceerbaarheid van de procedure, berekend met behulp van de resultaten van de dubbele metingen binnen en tussen de twee chirurgen, was vergelijkbaar met de nauwkeurigheid van totale procedure; ca. 3 mm.

In **hoofdstuk 7** is het ontwikkelde CAS plaatsingssysteem gebruikt in een in vitro experiment, waarbij de stabiliteit van een anatomische dubbelbundel (ADB) VKB reconstructie werd vergeleken met de isometrische enkelbundel (IEB) VKB reconstructie. Allereerst werd in 8 intacte kadaverknieëen de stabiliteit in voor-achterwaartse richting gemeten, door de positie van het onderbeen ten opzichte van het bovenbeen te bepalen in een onbelaste- en een belaste conditie. Vervolgens werd de VKB doorgesneden en werden de metingen herhaald. Daarna werd de VKB op verschillende manieren gereconstrueerd: 1) met een AM graft opgespannen met 15 N in respectievelijk 90°; 2) met een PL-graft opgespannen met 15 N in 15°; 3) met een ADB bestaande uit de AM and PL graft; 4) met een standaard IEB techniek. Alle reconstructies herstelden de ontstane instabiliteit na het doorsnijden van de VKB. Daar waar de ADB de normale stabiliteit over de gehele bewegingsrange benaderde, kwam de IEB echter tekort in de lage flexie hoeken. Met behulp van een verbeterd fixatieprotocol, met een hogere spanning en in een lagere hoek voor de AM, zal de ADB techniek nog betere resultaten kunnen geven.

In de geschiedenis van VKB-reconstructies hebben chirurgen diverse concepten ontwikkeld om een gescheurde voorste kruisband te herstellen. Om de verschillende aspecten daarvan tijdens de operatie uit te kunnen voeren, zijn diverse richtinstrumenten (guides) ontwikkeld. Deze instrumenten onderscheiden zich op het vlak van de verschillende keuzes op het technische vlak: a) Het boren van kanaaltjes voor hechtingen of van een tunnel voor de graft; b) Van binnen naar buiten boren of andersom; c) Een open operatietechniek of via een kijkoperatie;

d) Anatomische of isometrische plaatsing; e) Een richtinstrument dat de chirurg op de gewenste locatie moet positioneren en ondersteunt in het boren of een richtinstrument dat middels het ontwerp de tunnel op de juiste positie plaatst. In **hoofdstuk 8** geven we een overzicht van deze richtinstrumenten en de concepten die ze ondersteunen. Tevens is er een overzicht van de uitkomsten van de diverse guide validatie studies. In de laatste decennia faciliteren de richtinstrumenten vooral de arthroscopische anatomische tunnel plaatsing. Hoewel er diverse studies zijn gedaan naar de nauwkeurigheid van richtinstrumenten, ontbreekt literatuur met de validatie resultaten van deze nieuwste instrumenten.

De resultaten van de anatomische posities van de insertie centra uit hoofdstuk 2 zijn gebruikt voor de ontwikkeling van een chirurgisch richtinstrument dat moet leiden tot nauwkeurige lokalisatie én plaatsing van de tunnel in het ACL-centrum voor een anatomische enkelbundel reconstructie of van twee tunnels in de AM- én PL-centra voor een anatomische dubbelbundel VKB reconstructie. De validatiestudie van dit instrument is beschreven in **hoofdstuk 9**. Na diverse test-instrumenten werd een prototype ontwikkeld, gebaseerd op het design van een veel gebruikte endoscopische guide voor isometrische tunnel plaatsing, de ‘guide for anatomic femoral tunnel placement’, de GAFT. Dit prototype werd getest in een in vitro opstelling met twaalf bovenbenen. Experimenten werden uitgevoerd met directe plaatsing onder visuele controle om de nauwkeurigheid van het design van de guide te testen, alsook middels plaatsing via een arthroscopisch beeld op de monitor door orthopeden (in opleiding) om de nauwkeurigheid van de arthroscopische hanteerbaarheid te testen.
De nauwkeurigheid van de directe plaatsing werden vergeleken met die van een standaard arthroscopisch richtinstrument (endoscopic femoral aimer) op de 11 uur (isometrische plaatsing) en 10 uur positie (anatomische plaatsing). De fouten in het markeren van de tunnel positie, berekend als de afstand tussen de tunnel markeringen van de guide en de anatomische centra, waren klein. De gemiddelde fout voor de drie tunnel markeringsposities lag tussen de 1.6 en 1.9 mm. Alle AM tunnel markeringen geplaatst met de GAFT bevonden zich binnen 3 mm van het anatomische insertie centrum. Geen van de geplaatste tunnel markeringen had een afwijking groter dan 5 mm. De fouten in de tunnel markeringen van een isometrische guide gepositioneerd onder visuele controle op 11 uur én 10 uur waren gemiddeld groter met respectievelijk 4.1 mm en 2.8 mm. Dit resultaat betekent dat de gegenereerde guide in potentie geschikt is voor nauwkeurige anatomische tunnel plaatsing. Een belangrijke voorwaarde om deze potentiële nauwkeurigheid tijdens een arthroscopische ingreep te bewerkstelligen, is accurate toepassing van het plaatsingsprotocol. Deze voorwaarde kwam aan het licht tijdens de arthroscopische plaatsing van de guide door 4 assistenten en een orthopedisch chirurg. De nauwkeurigheid varieerden van ‘uitstekend’ (gemiddelde fout van 1 mm) tot ‘middelmatig’ (gemiddelde fout van 3.5 mm). We konden deze nauwkeurigheid overigens niet relateren aan de ervaring van de assistent/orthopeed.

De resultaten van hoofdstuk 4 (de 3D posities van de anatomische centra ten opzichte van de afmetingen van het onderste deel van het femorale bot op CT-scans) kunnen ook fungeren als basis voor de productie van een innovatieve geprinte 3D mal die past in de knie van de patient, zoals beschreven in **hoofdstuk 10**. De resultaten gevonden met behulp van de methode uit hoofdstuk 4 van zes bovenbenen, zijn gebruikt om de tunnel posities voor de ACL, AM en PL in zes andere bovenbenen te berekenen. In een computer programma is deze informatie, inclusief de structuur van het oppervlak van de intercondylaire notch, gebruikt om een printbestand voor een 3D mal te genereren. De zes mallen zijn uitgeprint en in de notch geplaatst, waarna de posities van de tunnels zijn gemarkeerd. De fouten in de tunnel markeringsposities, de afstand tussen de tunnel markeringen en de anatomische centra, waren klein met gemiddelden van 1.2 en 1.3 mm. Deze resultaten zijn veelbelovend voor de ontwikkeling van een gepersonaliseerd richtinstrument voor nauwkeurige tunnel lokalisaties en plaatsingen in anatomische enkelbundel of dubbelbundel VKB reconstructies in de toekomst.

Dankwoord

Toen ik tijdens mijn wetenschappelijke stage in 1997 op het Orthopaedic Research Lab van de Radboud de positie van de aanhechting van de voorste kruisband aan het onderzoeken was, kon ik niet vermoeden dat dit werk 19 jaar later zou uitmonden in dit proefschrift en mijn promotie. Een hele bevalling, langer en zwaarder dan die andere 2, maar alle inzet is beloond. Al heb ik veel werk zelf gedaan, dit resultaat had ik niet gered zonder hulp van de mensen die altijd in mij zijn blijven geloven en degenen die mij ook praktisch hebben ondersteund. Tijd om deze personen te bedanken dus. En zoals iedereen weet, ben ik nogal perfectionistisch, dus ga er maar even goed voor zitten, want het is een behoorlijk lang verhaal geworden.

Als eerste wil ik mijn promotor, professor doctor ingenieur Verdonschot bedanken. Beste Nico, jij hebt je taak als promotor dubbel en dwars waar gemaakt. Zelfs toen je mijn promotor nog niet was, heb je mij vaak geholpen. Ook op vlakken die niets met een promotie te maken hadden. Ik ben je ontzettend dankbaar dat je in mij bent blijven geloven en dat je zelfs op je vrije dinsdagavond de tijd nam om bij jou thuis aan de keukentafel te overleggen over mijn artikelen en experimenten. Je was altijd scherp en kritisch, maar gaf mij tegelijkertijd de ruimte om mijn visie uit te leggen. Dit eindresultaat was er nooit gekomen zonder jou. Ontzettend bedankt!

Zonder mijn co-promotor, Dr. Wymenga, was dit boekje ook niet ontstaan. Beste Ate, bedankt dat jij je destijds niet klakkeloos hebt neergelegd bij het compromis om de femorale tunnel bij een voorste kruisband reconstructie, vanwege de technische beperkingen van een kijkoperatie, op een isometrische plek te boren. In plaats daarvan ging je op zoek naar een methode om de originele anatomische positie tijdens een kijkoperatie te bepalen. Dat idee werd mijn stage, later gevolgd door een anderhalf jaar durend project, waarin we samen een computermodel hebben ontwikkeld. Een innovatieve ontwikkeling, die helaas niet erg interessant bleek voor een voorste kruisband reconstructie. Die computergestuurde techniek bleek veel interessanter bij totale knievervangingen, waardoor je je focus dan ook naar dat vlak verlegde. In de tussentijd ben je betrokken gebleven en heb je regelmatig een bijdrage geleverd aan onze nieuwe onderzoeken en artikelen, met deze promotie als gevolg. Bedankt.

De leden van de manuscriptcommissie, voorzitter Kees van Laarhoven, Cees Slump en Ron Diercks wil ik bedanken voor hun interesse en de positieve beoordeling van dit proefschrift.

In de beginjaren was Leendert Blankevoort de initiator achter de ontwikkeling van de template. Ook toen hij verhuisde naar Amsterdam was hij altijd bereid om zijn kennis en kunde aan te wenden om de artikelen die ik schreef te verbeteren. Ik wil hem daarvoor hartelijk danken.

Uiteraard wil ik ook de andere co-auteurs die een bijdrage hebben geleverd aan de experimenten en artikelen in mijn proefschrift heel hartelijk bedanken voor hun bijdrage: Jan Kooloos, Denise Eygendaal, Lianne Zevenbergen, Sarthak Misra, Dennis Janssen, Thomas Maal en Rinaldo Vreeken met een extra bedankje voor Pawel Tomaszewski, die me in de laatste onderzoeken ook praktisch heeft ondersteund.

Een aantal personen wil ik bedanken voor de belangrijke praktische bijdragen die ze hebben geleverd. Op de eerste plaats wil ik dan graag Willem van de Wijdeven noemen, de technische man van het ORL. Altijd wist hij een oplossing voor een technisch probleem te verzinnen, zelfs al moest daarvoor een stuk van de bezemsteel worden afgezaagd. Voor de ontwikkeling van het computermodel kregen we ondersteuning vanuit Zwitserland. Marwan Sati had op het MEM Instituut in Bern de basis gelegd voor een computer navigatiesysteem die de isometrische positie van de femorale tunnel kon bepalen. René van der Venne (ORL) hielp met de vertaling van de resultaten naar computertaal en Yvan Bourquin paste het navigatieprogramma aan, zodat het door ons ontwikkelde computermodel onderdeel werd van de procedure. Huub Peeters (ORL) ondersteunde in de berekeningen van het experiment. Bart Nienhuis en Noël Keijsers (Sint Maartenskliniek Research) zetten hun Matlab kwaliteiten in om een programma te schrijven dat me in meerdere studies hielp bij de berekeningen. Vanuit het ORL leverde Wouter Gevers deze bijdrage tijdens de laatste onderzoeken. John Berns van de afdeling Radiologie van de Sint Maartenskliniek assisteerde bij het maken van radiologische opnamen van de femora. En natuurlijk Ineke van het ORL, die alle afspraken met Nico regelde. Iedereen bedankt.

Enkele geneeskunde studenten hebben een bijdrage geleverd aan dit project tijdens hun stage. René van Ampting onderzocht de radiografische posities, Karin van de Gronde testte de eerste versie van het anatomische richtinstrument, het ‘haakje’, Gudo van Hoogzaad segmenteerde de femora voor de 3D CT data en Jaimy Meijs hielp tijdens de validatie tests van de tweede versie van het richtinstrument. Allen wil ik danken voor hun inzet, ik hoop dat de stages en mijn begeleiding een bijdrage hebben geleverd aan hun wetenschappelijke vorming.

In de periode dat ik, voornamelijk thuis en in de Radboud aan de onderzoeken en artikelen van dit boekje werkte, ben ik 13 jaar werkzaam geweest als onderzoeker en kwaliteitsadviseur op de Sint Maartenskliniek. Een tijd waar ik aan de ene kant met gemengde gevoelens op terugkijk, maar waarin ik aan de andere kant altijd met plezier mijn werk heb uitgevoerd, met name omdat ik fijne collega’s had waar ik altijd terecht kon. Cheriel, Joke en Lilian, mijn Research collega’s tot het laatste moment, bedankt dat ik altijd met mijn verhaal bij jullie terecht kon/kan en bedankt voor jullie ondersteuning. Hetzelfde geldt voor Niki, Amber, Astrid en Marcia, inmiddels ook ex-SMKers, bedankt. Alle andere (ex-)Research collega’s wil ik bedanken voor de gezelligheid op de afdeling. Elders in de SMK had ik nog enkele ‘gewone’ collega’s waar ik even langs kon lopen om mijn gedachten en gevoelens te delen: Henriette, Christel, Gabriëlle, Mirjam, Marian (bedankt voor de tip over de slingers), Laura, Alexandra en Marjolein, jullie ook bedankt voor jullie tijd en belangstelling, vooral in de mens achter de onderzoeker.

Promoveren in je eigen tijd heeft zijn nadelen, maar zoals Cruijff al zei ‘elk nadeel heb zijn voordeel’. Je kunt je eigen tijd indelen en er wat langer over doen, zodat je gewoon kunt deelnemen aan het sociale leven. Dat heb ik dus ook volop gedaan in de afgelopen 19 jaar. Mijn belangrijkste bezigheid was natuurlijk het voetbal en tijdens mijn promotieperiode heb ik bij diverse clubs gespeeld. Ik wil graag alle speelsters van die clubs bedanken voor hun samenspel, zowel op als buiten het veld. Een extra woordje van dank voor mijn huidige medespeelsters van Orion veterinnen, waarmee ik nog wekelijks veel plezier beleef in de (kunstgras) wei. We hebben een superteam en dat geldt zeker niet alleen ten aanzien van de prestaties (‘kampioenen’), maar ook voor de sociale activiteiten met ons weekendje weg als jaarlijks terugkerend hoogtepunt. Uiteraard denk ik hierbij ook aan alle ex-speelsters, waarvan ik Yvonne wil bedanken voor haar hulp met de lay-out van dit boekje en het digitale magazine. En niet te vergeten de speelsters van Orion 3 en alle supporters.

De laatste 5 jaar is donderdagavond samba-avond. Samen met een fijne en diverse club trommelliefhebbers vormen we een ‘krachtige’ sambaband, Força. Gelukkig heb ik nog enige muzikaliteit in me ontdekt, want nix is heerlijker dan uit je dak gaan, rammend op een grote trommel. Vooral als we met z’n allen tijdens een optreden onze heerlijke, swingende sambamuziek maken, waar het publiek van geniet. Thanks Forçaatjes, voor de muziek, de gezelligheid en vooral ook voor jullie vriendschap.

Naast deze ‘teamactiviteiten’ heb ik ook nog tijd gemaakt om met andere vriendinnen leuke dingen te doen, vandaar dat de promotie even op zich liet wachten. Met het risico dat ik iemand vergeet, wil ik er hier toch een aantal noemen. Christina, Sheila and Steve, thanks your hospitality and for making my time in the United States, were I started to write my first article, very special with sweet (soccer) memories. Anneke en Yvonne, Maaike, Fien, Irmgard, Inge en Geertje, alle vrouwen waarmee we zo vaak de camping op roze zaterdag onveilig maakten en verder iedereen die ik niet kan benoemen in dit dankwoord, omdat het dan wel erg lang wordt. Allemaal bedankt.

Ons eigen ‘roze’ clubje mag dan de laatste tijd wat minder samen doen, Gemma en Wendy, Sanne en Saskia, Kim en Sandra, Nicole en Anouska, bedankt voor jullie vriendschap. Dat laatste geldt ook voor Marianne en Marjolein, fijn dat ik altijd bij jullie terecht kan. Bedankt voor jullie luisterend oor en alle tips en tricks die het leven en dan met name de communicatie met anderen, makkelijker (zouden kunnen) maken.

Nog een speciaal woordje voor mijn paranimfen. Gemma, jij hebt het begin van dit project meegemaakt. Ik ken je nu al meer dan de helft van mijn leven en daar ben ik dankbaar voor. Het kon niet anders dan dat jij mijn paranimf werd. Marianne, je bent niet alleen mijn sambamaatje, maar ook mijn klankbord. Naast dat we veel lol hebben, leer ik ook veel van jou. Heel fijn dat je mijn paranimf wilt zijn.

Ik wil ook mijn zus Patty en haar gezin, Iwan, Yara, Kay en Rawi, mijn familie en met name Hannij en Henk, Ria en tante Zus, schoonzus Hanneke en de rest van mijn schoonfamilie bedanken voor hun belangstelling.

Joost en Richard, jullie zijn niet alleen de papa’s van onze meisjes, maar ook goede vrienden, die mijn traject voor een groot deel hebben meegemaakt. Bedankt voor het luisteren naar een verhaal over het zoveelste afgewezen artikel, het delen in de vreugde van een geaccepteerd artikel en voor jullie ondersteuning. T’is ook erg bijzonder en gezellig om elke week als een groot gezin aan tafel te zitten. Dat zal zeker blijven gebeuren, ook na mijn promotie.

Mijn ouders, Simon en Truus, hebben mij altijd gesteund en ook al wisten ze niet wat ik precies deed, trots zijn ze altijd geweest. De afgelopen jaren stonden ze iedere donderdag klaar om hun kleinkinderen op te vangen, als ik weer zo nodig iets voor mijn onderzoek moest doen. Lieve pap en mam, bedankt voor alles, dit werk draag ik mede aan jullie op.

Lieve Moon, jij hebt het grootste gedeelte van mijn promotietocht meegemaakt en vooral ook de moeilijke tijden. Hoewel we ons nu in woelige wateren bevinden, wil ik jou zeker speciaal bedanken. Zonder jou hadden we geen mooie meisjes en had ik ook deze promotie niet kunnen behalen. Dank je wel dat je er altijd was, vooral als je weer eens alleen met Raffi en Ezi iets ging doen, omdat ik aan mijn proefschrift moest werken.

Last but not least, Raffi en Ezi, onze mooie meisjes, heel hun leven ben ik al bezig geweest met dit boekje. Soms merkten ze daar helemaal niets van, maar vooral in het laatste jaar heb ik diverse uitjes met hen aan mij voorbij laten gaan om nog even aan een artikel te werken. Ik ben ontzettend trots op jullie en ik vind het super dat jullie zo’n mooie voorkant hebben gemaakt voor dit boekje, de kers op de taart! Lieve meiden, ik beloof jullie dat ik vanaf nu mijn best zal doen om mijn werk in mijn nieuwe baan gewoon tijdens kantoortijd af te krijgen, zodat ik meer van en met jullie kan genieten van de leuke dingen in het leven.

Tot slot:

Soms gaat het goed
Soms gaat het minder
Soms gaat het grandioos
En soms gaat het ruk
Soms zit het mee, soms zit het tegen
Soms heb je pech
En soms geluk

Soms heb je eb
En soms heb je vloed
En of je nu feestviert
Of ervoor bloed
Alles komt goed
Alles alles alles komt goed

De Dijk (featuring Thomas Acda) – Alles komt goed (tekst Huub van der Lubbe)

Curriculum vitae

OVER DE AUTEUR / ABOUT THE AUTHOR

Joan Luites werd op 24 september 1968 in Dreumel geboren, waar ze ook opgroeide. Ze fietste 6 jaar naar het Pax Christi College in Druten en behaalde in 1986 haar Atheneum diploma. Daarna volgde ze de opleiding fysiotherapie in Nijmegen, die ze in 1991 afrondde. Na enkele jaren werkzaam te zijn geweest als fysiotherapeut/fitnesstrainer, startte ze in 1994 met het doorstroomprogramma Bewegingswetenschappen van de studie Biomedische Gezondheidswetenschappen aan de Katholieke Universiteit in Nijmegen. Tijdens een extra stage bij het Orthopaedic Research Lab (ORL) van de Radboud onderzocht ze de aanhechting van de voorste kruisband (VKB) in de knie. In 1997 ontving ze haar bul. De VKB studie werd in 1998 op de Sint Maartenskliniek voortgezet met een onderzoeksproject van anderhalf jaar, waarvan de resultaten in de jaren erna werden verwerkt tot vier artikelen. Na een korte periode werkzaam te zijn geweest op het ORL (2000-2002), keerde Joan terug naar de Sint Maartenskliniek. Daar werkte ze tot 2009 op de afdeling OrthoResearch aan diverse klinische orthopedie studies, die resulteerden in verschillende publicaties en promoties van orthopeden (in opleiding). Tussen 2007 en 2013 was Joan als lid van de Ondernemingsraad betrokken bij de organisatie. Vanaf 2009 combineerde ze haar onderzoekstaak met de functie van kwaliteitsadviseur, waarin ze onder andere de tevredenheid van SMK-patiënten onderzocht. Vanaf 2014 tot eind 2015 heeft ze het VKB onderzoek voortgezet, resulterend in vijf aanvullende artikelen, die tezamen met de vier eerdere publicaties dit proefschrift vormen. Momenteel werkt Joan als projectcoördinator op de afdeling Klinische Geriatrie van het Radboudumc aan de evaluatie van vervroegde verplaatsing van de oncologische nazorg bij kwetsbare ouderen met kanker van het ziekenhuis naar de eerste lijn.

Joan Luites (24 september 1968) was born and raised in Dreumel. After completing secondary school at the Pax Christi College in Druten in 1986, she started to study physical therapy in Nijmegen, graduating in 1991. After working for a few years as a physical therapist/fitnesstrainer, she started the study Biomedical Health Science at the Radboud University in 1994. During an internship at the Orthopaedic Research Lab (ORL), Joan studied the attachment of the anterior cruciate ligament (ACL) of the knee. After her graduation in 1997, this project was continued in 1998 at the Sint Maartenskliniek in a research project for one year and a half; the results were processed in the years following, resulting in four publications. After a short period at the ORL (2000-2002), she returned to the Sint Maartenskliniek, were she performed various clinical orthopedic studies at the OrthoResearch Department, resulting in several publications and PhD graduations from orthopedic surgeons (residents). Joan attended the employees council between 2007 and 2013. From 2009, she combined her research tasks with a function as quality advisor. From 2014 till end 2015, the ACL project was continued, resulting in five additional papers, incorporated in this thesis together with the previous four. Currently, Joan works as a project coordinator at the Department of Geriatrics of the Radboudumc, evaluating the early displacement of aftercare in fragile elderly with cancer from the hospital to the primary care.

LIST OF PUBLICATIONS

This thesis

Articles in international papers

Luites JWH, Wymenga AB, Blankevoort L, Kooloos JGM. Description of the attachment geometry of the anteromedial and posterolateral bundles of the ACL from arthroscopic perspective for anatomical tunnel placement. Knee Surg Sports Traumatol Arthrosc. 2007 Dec;15(12):1422-1431.

Luites JWH, Wymenga AB, Blankevoort L, Kooloos JGM, Verdonschot N. Development of a femoral template for computer-assisted tunnel placement in anatomical double-bundle ACL reconstruction. Comput Aided Surg. 2011;16(1):11-21.

Luites JWH, Wymenga AB, Blankevoort L, Kooloos JGM, Verdonschot N. Computer-assisted anatomically placed double-bundle ACL reconstruction: An in vitro experiment with different tension angles for the AM and the PL graft. Medical Engineering & Physics 2012 (34):1031– 1036.

Luites JWH, Wymenga AB, Blankevoort L, Eygendaal D, Verdonschot N. Accuracy of a computer-assisted planning and placement system for anatomical femoral tunnel positioning in anterior cruciate ligament reconstruction. Int J Med Robot 2014 (4):438-446.

Luites JWH, Verdonschot N. Radiographic positions of femoral ACL, AM and PL centres: accuracy of guidelines based on the lateral quadrant method. Knee Surg Sports Traumatol Arthrosc. 2015 Jul 4 [Epub ahead of print].

Posters and presentations

Wymenga AB, Luites JWH, Blankevoort L, Kooloos JGM. 3D insertion geometry of the ACL: A study of the anatomical position of the two bundles frmo a surgical perspective.*8th European Society of Sports Traumatology, Knee Surgery and Arthroscopy (ESSKA) Congress*, Nice, France, 1998. Poster presentation.

Luites JWH, Wymenga AB, Blankevoort L. 3D insertion geometry of the anterior cruciate ligament. A study of the three-dimensional insertion sites of the two ACL bundles from the surgical point of view. *The 1998 Scientific Meeting of the Dutch Arthroscopy Association.* Papendal, The Netherlands, 1998. Podium presentation. Published in KSSTA (1998) 6:259.

Wymenga AB, Luites JWH, Blankevoort L, vd Venne R, Sati M and Stäubli H-U. Double-bundle anatomic ACL reconstruction with CAS. *4th CAOS-Symposium on Computer Assisted Orthopaedic Surgery*, Davos, Switzerland, 1999. Poster presentation, awarded Best Poster.

Luites JWH, Wymenga AB, Blankevoort L, Kooloos JGM, Sati M. Double-bundle anatomical anterior cruciate ligament reconstruction with CAS. II. An in vitro study of the anterior laxity in knees with anatomical double-bundle versus isometric single bundle reconstructions. ***Scientific Meeting of the Dutch Arthroscopy Association.*** Ede, The Netherlands, 2000. Podium presentation. Published in KSSTA (2001) 9:58.

Wymenga AB, Sati M, Luites JWH, Bourquin Y, Blankevoort L, vd Venne R, Kooloos JGM, Stäubli H-U. Computer-assisted placement of a double-bundle ACL though 3D fitting of a statistically-generated template into individual knee geometry. *5th CAOS-Symposium on Computer Assisted Orthopaedic Surgery*, Davos, Switzerland, 2000. Podium presentation, awarded Best Paper.

Luites JWH, Wymenga AB, Sati M, Bourquin Y, Blankevoort L, vd Venne R, Kooloos JGM, Stäubli H-U. Computer-assisted placement of a double-bundle ACL through 3D fitting of a statistically-generated template into individual knee geometry. *CAOS/USA Fourth Annual North American Program on Computer Assisted Orthopaedic Surgery*, Pittsburgh, PA, USA, 2000. Podium presentation.

Luites JWH, Wymenga AB, Blankevoort L, Kooloos JGM, Sati M. Double-bundle anatomic ACL reconstruction with Computer Assisted Surgery; Part 2: An in-vitro study of the anterior laxity in knees with anatomic double-bundle versus isometric single-bundle reconstructions. *CAOS/USA Fourth Annual North American Program on Computer Assisted Orthopaedic Surgery*, Pittsburgh, PA, USA, 2000. Podium presentation.

Luites JWH, Wymenga AB, Sati M, Bourquin Y, Blankevoort L, vd Venne R, Kooloos JGM, Stäubli H-U. CComputer-assisted placement of a double-bundle ACL through 3D fitting of a statistically-generated template into individual knee geometry. *Third International Conference on Medical Image Computing and Computer-Assisted Intervention (MICCAI)*, Pittsburgh, PA, USA, 2000. Podium presentation.

Luites JWH, Wymenga AB, Blankevoort L, Kooloos JGM, Sati M. Double-bundle anatomic ACL reconstruction with CAS; An in-vitro study of the anterior laxity in knees with anatomic double-bundle versus isometric single-bundle reconstructions. *Third International Conference on Medical Image Computing and Computer-Assisted Intervention (MICCAI)*, Pittsburgh, PA, USA, 2000. Podium presentation.

Luites JWH, Wymenga AB, Blankevoort L, Kooloos JGM. Insertion geometry of the two bundles of the Anterior Cruciate Ligament. *9th European Society of Sports Traumatology, Knee Surgery and Arthroscopy (ESSKA) Congress*, London, England, 2000. Poster presentation.

Luites JWH, Wymenga AB, Blankevoort L, Kooloos JGM, vd Venne R, Sati M, Bourquin Y. Computer-assisted anatomic ACL-graft placement with a 3D femoral template. *9th European Society of Sports Traumatology, Knee Surgery and Arthroscopy (ESSKA) Congress*, London, England, 2000. Podium presentation.

Luites JWH, Wymenga AB, Blankevoort L, Kooloos JGM, Sati M. Double-bundle anatomic ACL reconstruction with Computer Assisted Surgery (CAS). *9th European Society of Sports Traumatology, Knee Surgery and Arthroscopy (ESSKA) Congress*, London, England, 2000. Poster presentation.

Luites JWH, Wymenga AB, Sati M, Bourquin Y, Blankevoort L, vd Venne R, Kooloos JGM, Stäubli H-U. Double-bundle anatomic ACL reconstruction with Computer Assisted Surgery. *World Biomechanics Symposium*, Amsterdam, The Netherlands, 2000. Podium presentation.

Luites JWH, Wymenga AB, Blankevoort L, Kooloos JGM. Endoscopic 3D insertion geometry of the two functional bundles of the Anterior Cruciate Ligament. *14th Annual Meeting Nederlandse Vereniging voor Arthroscopie*, Ermelo, The Netherlands, 2004. Podium presentation.

Luites JWH, Wymenga AB, Blankevoort L, Kooloos JGM. Endoscopic insertion geometry of the two functional bundles of the Anterior Cruciate Ligament. 5th *Biennial International Society for Computer Assisted Orthopaedic Surgery (ISAKOS) Congress*, Hollywoord, Florida, 2005. E-poster.

Book chapter

Luites JWH, Wymenga AB, Sati M, Bourquin Y, Blankevoort L, vd Venne R, Kooloos JGM, Stäubli H-U. Computer-assisted placement of a double-bundle ACL through 3D fitting of a statistically-generated template into individual knee geometry. In Delp SL, DiGoia AM and Jaramaz B (Ed) Springer Lecture Notes in Computer Science (LNCS) Volume 1935 Medical Image Computing and Computer-Assisted Intervention MICCAI 2000 Proceedings, pp 1096-1103.

Luites JWH, Wymenga AB, Blankevoort L, Kooloos JGM, Sati M. Double-bundle anatomic ACL reconstruction with CAS; An in-vitro study of the anterior laxity in knees with anatomic double-bundle versus isometric single-bundle reconstructions. In Delp SL, DiGoia AM and Jaramaz B (Ed) Springer Lecture Notes in Computer Science (LNCS) Volume 1935 Medical Image Computing and Computer-Assisted Intervention MICCAI 2000 Proceedings, pp 1173-1175.

Other

Luites JWH. 1th *Annual meeting International Society for Computer Assisted Orthopaedic Surgery (ISAKOS) CAOS-International*, Davos, Switzerland, 2001. Chairmen session III- Reconstructive Knee Surgery.

Other papers and abstracts

Articles in (in)ternational papers

Brinkman JM, Schwering PJ, Blankevoort L, Kooloos JGM, Luites JWH, Wymenga AB. The insertion geometry of the posterolateral corner of the knee. J Bone Joint Surg Br. 2005 Oct;87(10):1364-8. Erratum in: J Bone Joint Surg Br. 2006 Jun;88(6):837. Koolos, JG [corrected to Kooloos, JG].

Luites JWH, Spruit M, Hellemondt GG, Horstmann WG, Valstar ER. Failure of the uncoated titanium ProxiLock femoral hip prosthesis. Clin Orthop Relat Res. 2006 Jul;448:79-86.

Luites JWH, Brinkman JM, Wymenga AB, van Heerwaarden RJ. Fixation stability of opening- versus closing-wedge high tibial osteotomy: a randomised clinical trial using radiostereometry. J Bone Joint Surg Br. 2009 Nov;91(11):1459-1465.

Brinkman JM, Luites JWH, Wymenga AB, van Heerwaarden RJ. Early full weight bearing is safe in open-wedge high tibial osteotomy. Acta Orthop. 2010 Apr;81(2):193-198.

van Ochten JHM, van Tienen T, Luites JWH, Defoort K en Wymenga AB. Anatomische reconstructie van posterolaterale hoek letsels van de knie. Een prospectieve case serie, resultaten na 1 jaar. Ned Tijd Ortho. 2011 (1):4-10.

Pakvis D, Luites JWH, van Hellemondt GG, Spruit M. A cementless, elastic press-fit socket with and without screws. Acta Orthop. 2012 (5):481-487.

deVos MJ, Verdonschot N, Luites JWH, Anderson PG, Eygendaal D. Stable fixation of the IBP humeral component implanted without cement in total elbow replacement: A radiostereometric analysis study of 16 elbows at two-year follow-up. Bone Joint J. 2014 (2):229-236.

Posters and presentations

Luites JWH, Spruit M, Hellemondt GG, Horstmann WG, Valstar ER. Failure of the uncoated titanium ProxiLock^{TM} femoral hip prosthesis. *16th Annual Meeting of the European Orthopaedic Research Society (EORS),* Bologna, Italy, 2006. Poster presentation.

Luites JWH, Brinkman J-M. van Heerwaarden RJ, Valstar ER, Wymenga AB. Een RCT naar de stabiliteit van de Open vs Gesloten wig Hoge Tibiakop Osteotomie mbv radiostereometrie. *NOV Voorjaarsvergadering*, Utrecht, The Netherlands, 2006. Podium presention.

Luites JWH, Brinkman J-M. van Heerwaarden RJ, Valstar ER, Wymenga AB. Stability of opening vs closing wedge high tibial osteotomy measured with röntgen sterophotogrammetric analysis in a randomised clinical trial. ***12**th **European Society of Sports Traumatology, Knee Surgery and Arthroscopy (ESSKA) 2000 Congress***, Innsbruck, Austria, 2006. Podium presentation.

Luites JWH, Brinkman J-M, van Heerwaarden RJ, Wymenga AB. Stability of opening vs closing wedge high tibial osteotomy measured with röntgen sterophotogrammetric analysis in a randomised clinical trial. *54th Northic Orthopaedic Federation (NOF) Congress,* Amsterdam, The Netherlands, 2008. Podium presentation, nomination best paper.

Brinkman J-M, Luites JWH, Wymanga AB, van Heerwaarden RJ. Early full weight bearing in Medial open wedge HTO using an angle stable implant is safe- an RSA anlysis of stability. *13th European Society of Sports Traumatology, Knee Surgery and Arthroscopy (ESSKA) 2000 Congress*, Porto, Portugal, 2008. Podium presentation. Published in KSSTA (2008) 16 (suppl 1):S63.

MJ de Vos, Luites JWH, Eygendaal D. Stable fiation of the humeral component of the IBP^{TM} Total Elbow Prosthesis. A RSA study of 16 prosthesis with 2 years follow-up. *Congress of the European Society for Surgery of the Shoulder and the Elbow (SECEC)*, Brugge, Belgium, 2008. Podium presentation.

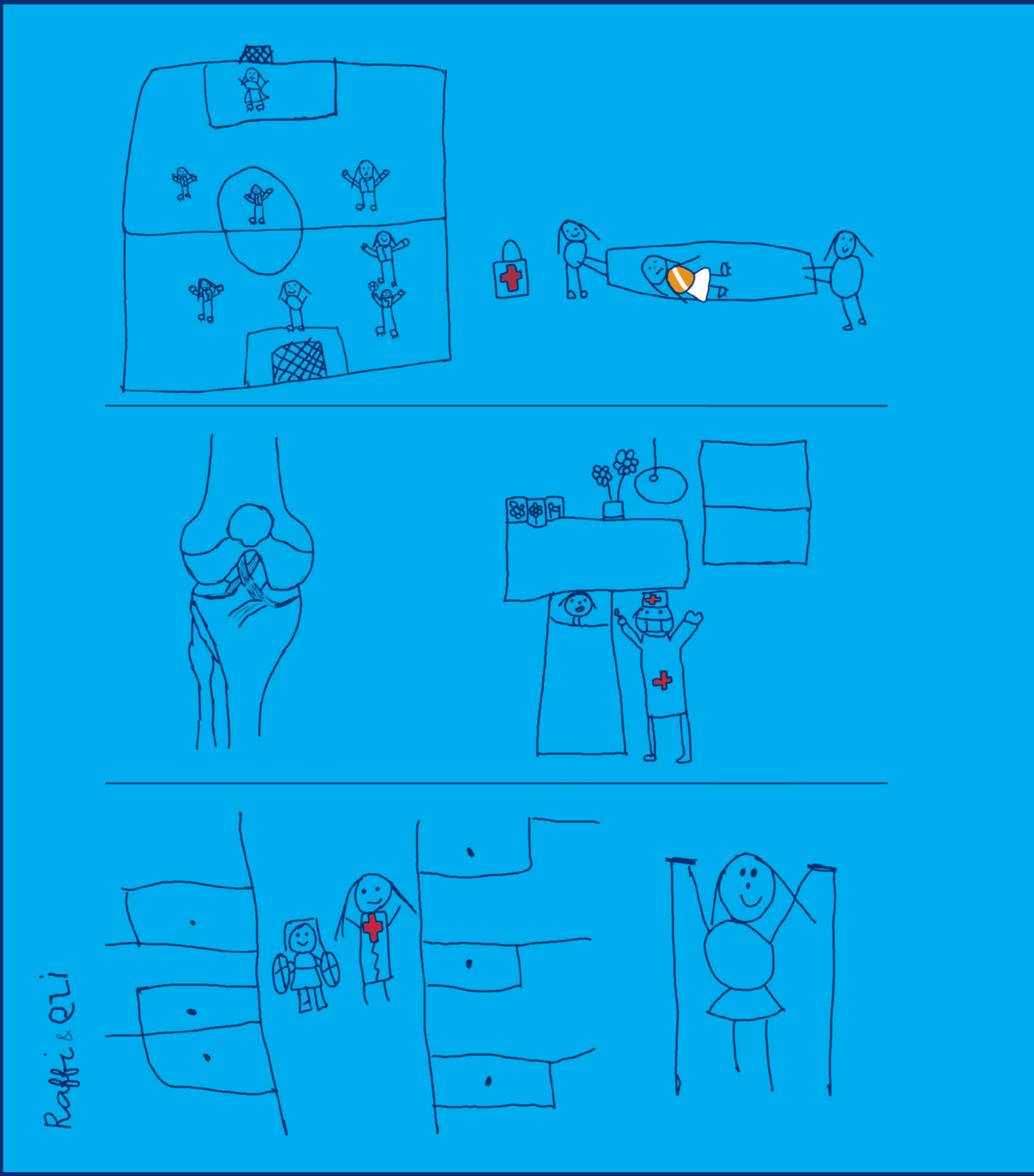

Sint Maartenskliniek